



**HAL**  
open science

## Transversus Abdominis Plane Block for Anterior Lumbar Interbody Fusion: a randomized controlled trial

Alice Coquet, Audrey Sion, Antoine Bourgoin, Mickael Ropars, H el ene Beloeil

### ► To cite this version:

Alice Coquet, Audrey Sion, Antoine Bourgoin, Mickael Ropars, H el ene Beloeil. Transversus Abdominis Plane Block for Anterior Lumbar Interbody Fusion: a randomized controlled trial. *Spine Journal*, 2023, 23 (8), pp.1137-1143. 10.1016/j.spinee.2023.03.013 . hal-04088362

**HAL Id: hal-04088362**

**<https://hal.science/hal-04088362v1>**

Submitted on 16 May 2023

**HAL** is a multi-disciplinary open access archive for the deposit and dissemination of scientific research documents, whether they are published or not. The documents may come from teaching and research institutions in France or abroad, or from public or private research centers.

L'archive ouverte pluridisciplinaire **HAL**, est destin ee au d ep ot et  a la diffusion de documents scientifiques de niveau recherche, publi es ou non,  emanant des  tablissements d'enseignement et de recherche fran ais ou  trangers, des laboratoires publics ou priv es.



Distributed under a Creative Commons Attribution - NonCommercial 4.0 International License

**Transversus Abdominis Plane Block for Anterior Lumbar Interbody Fusion: a randomized controlled trial**

Alice Coquet <sup>a</sup>, Audrey Sion <sup>a</sup>, Antoine Bourgoin <sup>b</sup>, Mickael Ropars<sup>b</sup>, , Helene Beloeil <sup>c</sup>

**Authors' affiliations**

a Univ Rennes, CHU Rennes, Anesthesia and Intensive Care Department, F-35000 Rennes, France

b Univ Rennes, Inserm, LTSI-UMR 1099; Orthopaedics and Trauma Department, Rennes University Hospital, F-35000 Rennes, France

c Univ Rennes, CHU Rennes, Inserm, CIC-1414, COSS 1242, Anesthesia and Intensive Care Department, F-35000 Rennes, France

**Corresponding author:** Helene Beloeil, Pole Anesthésie-Réanimation Medecine Interne Geriatrie, CHU Rennes, 2 avenue Henri Le Guillou, 35033 Rennes Cedex, France.

Telephone : +033(0)299282422

Email: helene.beloeil@chu-rennes.fr

**Conflicts of interest:** none

**Keywords:** Transversus Abdominis Plane Block, Anterior Lumbar Interbody Fusion

**Funding**

This study was funded by a grant from the APICIL foundation.

**Acknowledgments**

Valerie Visseiche and Ludovic Meuret for their assistance with the study

**Author contributions**

*AC had full access to all of the data in the study and takes responsibility for the integrity of the data and the accuracy of the data analysis. AS and HB contributed to the conception and design of the study. AC, AB, MR, AS, HB contributed to the acquisition, analysis and interpretation of the data. AC wrote the first draft of the manuscript. AB, MR, AS and HB critically revised the manuscript. AC was responsible for the statistical analysis. All authors approved the final version of the manuscript.*

**Abstract**

**Background context :** ALIF (Anterior Lumbar Interbody Fusion) is a lumbar arthrodesis technique via an anterior approach that is less invasive than the posterior approaches. However, it is associated with specific pain in the abdominal wall.

**Purpose :** The objective of this study was to determine whether performing a bilateral ultrasound-guided TAP (Transversus Abdominis Plane) block allows a reduction in morphine consumption in the first 24 hours after surgery.

**Study design :** This study is a prospective single-centre, randomized, double-blind study.

**Patient sample :** Patients undergoing ALIF surgery were included and randomized into two groups. Both groups received a TAP block performed at the end of surgery with either ropivacaine or placebo.

**Outcome measures :** The primary outcome measure was morphine consumption in the first 24 hours. The main secondary outcomes were immediate postoperative pain and opioid-related side effects

**Methods :** Intra- and postoperative anaesthesia and analgesia protocols were standardized. A bilateral ultrasound-guided TAP block was performed with 75 mg (in 15 ml) of ropivacaine per side or isotonic saline serum depending on their assignment group.

**Results:** Forty-two patients were included in the study (21 per group). Morphine consumption at 24 hours (28 mg [18 – 35] in the ropivacaine group vs 25 mg [19 – 37] in the placebo group ( $p=0.503$ )) were not significantly different between the 2 groups.

**Conclusion :** TAP block with ropivacaine or placebo provided a similar postoperative analgesia when associated with a multimodal analgesia protocol for ALIF.

**Keywords :** Transversus Abdominis Plane Block, Anterior Lumbar Interbody Fusion

## Introduction

Anterior Lumbar Interbody Fusion (ALIF) is a surgical procedure currently performed for treatment of chronic low back pain due to degenerative disc disease, post-discectomy low back pain and L5-S1 spondylolisthesis. This procedure was originally described for surgical management of Pott's disease, before Capener et al. published in 1982 its first application in spondylolisthesis treatment [1]. This procedure remains highly relevant nowadays, as its anterior approach prevents the large and extensive dissection of paravertebral muscles due to posterior approaches and leading to sagittal instability and back pain postponing postoperative rehabilitation [2,3]. Less invasive procedures associated with multimodal analgesia are the pillars of the development of enhanced recovery after surgery. The transversus abdominis plane (TAP) block is an ultrasound-guided regional anaesthetic technique that

targets the T7 and L1 spinal nerves by injecting local anaesthetics between the internal oblique and transversus abdominis muscles located in the antero-lateral part of the abdomen wall [4,5]. The benefit of this block has been shown in a variety of clinical situations including various types of abdominal surgery [6–8], retroperitoneal surgery and nephrectomy [9,10]. The benefit of a bilateral TAP block has also been shown in hysterectomy procedures [11] and caesarean sections [12,13]. These surgeries as well as ALIF imply a Pfannenstiel incision. Thus, a bilateral TAP block could be proposed for postoperative analgesia after ALIF. Two retrospective studies [14,15] and one feasibility study [16] with no control group previously suggested a significant analgesic effect of the TAP block after ALIF. We therefore hypothesized that a bilateral TAP block would be associated with a better analgesia measured by the postoperative morphine consumption when compared with a control group after ALIF.

## **Material and methods**

### *Ethics*

The study was approved by an ethics committee (CPP Ouest II number: PP 16.05.21. Date: 06/06/2016) and the National Drug Agency (ANSM) (22/06/2016) and registered on the European EudraCT (2016-001413-24) and clinical trials (NCT02884440). Written informed consent was obtained from all participating patients before inclusion in the study.

### *Study design, Setting and participants*

This was an investigator-initiated, prospective, single centre, parallel-group, double-blind randomized, and controlled trial conducted in the Rennes Teaching hospital. We studied patients older than 18 years scheduled for ALIF. The non-inclusion criteria were allergy to

ropivacaine, weight under 50kgs, contraindication to TAP block (pregnancy, coagulation disorder, skin infection at puncture site), contraindication to paracetamol, ketoprofen and nefopam (allergy, creatinine clearance  $<50$  ml/min, history of peptic ulcer, acute glaucoma, benign prostatic hypertrophy, seizures and cardiac failure), and consumption of opioids within 24 hours before surgery. Patients subject to legal protection measures (guardianship or curatorship) or deprived of their liberty were not included in the study.

#### *Randomization and blinding*

Patients underwent randomization in a 1:1 ratio to undergo a TAP block (TAP block group) with ropivacaine or with placebo (placebo group), using a computer-generated random number list prepared by an statistician with no clinical involvement in the trial. Patients were enrolled by investigators, who were physicians in charge. Treatment was assigned following the randomization list by a research pharmacist with no clinical involvement in the trial. Treatment assignments were concealed from patients, medical staff, nurses, non-medical research staff and the statistician. Syringes for TAP block injection were prepared with 0.5% ropivacaine or saline solution according to the treatment group by the hospital pharmacy, and brought to the anesthesiologist in charge of the patient without any distinctive sign. Outcome assessors were unaware of the assignment throughout the study.

#### *Intraoperative and postoperative care*

All patients received a general anaesthesia with Target controlled infusion (TCI) propofol and remifentanyl, muscle relaxants as needed, ketamine (initial bolus of  $0.15$  mg.kg<sup>-1</sup> followed by continuous infusion of  $0.1$  mg.kg<sup>-1</sup>.h<sup>-1</sup> until 30 minutes before the end of surgery) and dexamethasone 8 mg. Postoperative analgesia was multimodal, started in operating room at the end of the procedure with paracetamol (1g every 6 hours), nefopam (20mg every 6 hours) and ketoprofen (50mg every 6 hours). An intravenous morphine titration was initiated

in the recovery room followed by patient-controlled intravenous analgesia (PCIA) of morphine for the first 24 hours, and then followed by oral opioid. All medications were first administered IV and then orally as soon as it was possible. All patients received a bilateral ultrasound-guided TAP block (with either ropivacaine or placebo) at the end of the surgical procedure. Briefly, the probe was placed transversally in the midline of the anterior abdominal wall and moved laterally to identify external and internal oblique muscles and transversus abdominis muscle, with the transversus abdominis plane located between the deep fascia and the transverse abdominis muscle. The needle was introduced through the abdominal wall and its extremity placed in the transversus abdominis plane. After an aspiration test to clear an intra-vascular position of the needle, an injection of 15 mL of 0.5% ( 5 mg / ml) ropivacaine or placebo in the transversus abdominis plane was performed. Then the procedure was repeated on the other side of the abdomen. Investigators visualized the ropivacaine spread (in two planes: anterior-posterior and cranial-caudal) in the correct space. The anesthesiology team, including the physician in charge, and the nurses in the recovery room and in ward were unaware of the treatment group.

#### *Primary Outcome*

The primary outcome was the total dose of opioid consumption within the first 24 hours after surgery (measured as intravenous morphine equivalents in mg).

#### *Secondary Outcomes*

Secondary outcomes were : opioid consumption in the recovery room ; total opioid consumption within 48 hours after surgery; pain intensity score according to the Visual Analog Scale (VAS ; 0 for no pain and 10 for severe intolerable pain) at 1, 6, 12, 24 hours postoperatively, and at patient's first ambulation ; occurrence of nausea and vomiting ;

duration of ileus ; delay for urinary catheter removal after surgery ; delay before first meal ; delay before patient's first ambulation. In-hospital length of stay was recorded and the overall patient's satisfaction at hospital discharge was measured as follows : 3 = weak, 2 = medium, 1 = good and 0 = very good.

#### *Data collected*

Primary and secondary outcomes were recorded by physicians or nurses involved in the patient's management, blinded of treatment group. TAP block quality (structures' visualization, needle's visualization, product's diffusion) was assessed by the anesthesiologist performing the block using a score from 0 (very low quality) to 10 (excellent quality). The presence of blood or digestive fluid in the needle, and the occurrence of signs of local anesthetics' intoxication were also reported.

#### *Sample size calculation*

The mean morphine consumption after ALIF surgery in our center assessed in 20 patients was  $25 \pm 5$  mg per day (mean  $\pm$  SD) (unpublished data). In order to show a 30 % difference in morphine consumption, we calculated that 20 patients per group would be needed to detect these differences, with an alpha level of 0.05 and a beta level of 0.10.

#### *Statistical analysis*

All data analyses were performed on an intention-to-treat basis. For quantitative continuous variables, position and dispersion parameters (mean, standard deviation, median, interquartile range) were calculated. For qualitative variables, proportion rates were calculated. For groups comparison, we used independent-samples t-tests for normally



distributed continuous variables, and Mann-Whitney U-tests for non-normally distributed continuous variables.  $\chi^2$  tests were performed for categorical variables. Statistical analysis was performed using R software. A  $p \leq 0.05$  was considered to be statistically significant for all the comparisons.

## Results

⇒ Between November 2016 and May 2019, 43 patients were enrolled in the study and 42 patients were randomized (21 in each group) and analyzed.. One patient in the Ropivacaine group and one in the control group did not receive a TAP block. Minor alteration of the predefined anesthesia protocol occurred in 4 patients in the control group (use of sufentanil  $n=2$ , addition of pregabalin  $n=2$ ). These data are summarized in Figure 1. The groups were comparable (Table 1) and all patients were chronically receiving non-opioid analgesics.

Surgery were one level ALIFs for 31 patients (74 %) (control group  $n=16$ , ropivacaine group  $n=15$ ), two levels for 8 patients (19%) ( $n=4$  per group) and three levels for 2 patients ( $n=1$  per group) ( $p=0.9$ ). Midline sub-umbilical incision was used for 13 patients in each group, and Pfannenstiel incision for 6 patients in each group. One patient had a posterior approach in the control group and data was missing for 2 patients in the ropivacaine group and 1 in the placebo group. It was a first surgery for 29 patients (69%), respectively 13 and 16 patients in the control and ropivacaine group ( $p=0.20$ ). Indications for surgery were mainly degenerative disc disease (29 patients, 15 in the control group and 14 in the intervention group) and spondylolisthesis (5 patients in each group). Morphine consumption was similar between the two groups: median dose of morphine consumed at 24 hours was 28 [Interquartile range: 18 – 35] mg in the ropivacaine group and 25 [19 – 37] mg in the placebo group ( $p=0.503$ ) (Figure 2).

The median dose of morphine received in morphine titration in PACU was 12 [6 – 18] mg in the ropivacaine group and 12 [7 – 16] mg in the placebo group, and did not differ significantly between the groups ( $p = 0.920$ ). The median dose of morphine consumed in the 48 hours following surgery was 41 [18 – 56] mg in the ropivacaine group and 45 [29 – 64] mg in the placebo group,  $p=0.496$  (Figure 3).

Data on pain assessments and other secondary outcomes are presented in Table 2 and results were similar between groups. There was no significant difference between groups regarding delay before first meal (day 0: 26% vs 32% and day 1: 74% vs 58% in the ropivacaine and placebo group, respectively), first flatus (day 0: 1% vs 5% and day 1: 45% vs 50%), urinary catheter removal (day 1: 29% vs 24% and day 2 66% vs 57%) and first ambulation (day : 85% vs 76%). In the ropivacaine group, 15 patients (71 %) had a satisfaction score at discharge of 1 (good), 4 patients (19 %) had a score of 0 (very good) and 2 (10 %) had a score of 2 (medium), vs 17 patients (85 %) with a score of 1 and 3 patients (15 %) with a score of 0 in the control group ( $p=0.530$ ).

TAP block quality criteria were as follows: Data were available for 18 patients (86%) in the ropivacaine group and 16 patients (76%) in the placebo group. In the ropivacaine group, the median visualization scores were 9 [8 – 10] for anatomical structures, 8 [8 – 9] for the needle and 9 [8 – 10] for diffusion in the ropivacaine group, versus 10 [9 – 10], 9 [8 – 9] and 9 [8 – 10] in the placebo group (no significant difference, respectively  $p=0.249$ ,  $p=0.455$  and  $p=0.499$ ), respectively. No blood reflux or digestive fluid was reported in either group. None of the patients showed signs of local anesthetic intoxication.

## Discussion

In our study, a bilateral TAP block with ropivacaine was not associated with a decrease in morphine consumption in the first 24 postoperative hours after anterior lumbar interbody fusion. We also did not show any significant difference between the groups concerning the dose of morphine administered in PACU and the total dose of morphine consumed 48 hours

after the surgery. Postoperative pain scores did not differ significantly between the groups, nor did the frequency of PONV occurrence. Three previous studies suggested an analgesic effect of the TAP block after ALIF. Both Esmende et al [14] and Reisener et al [15] reported a reduction in opioid consumption and PONV in retrospective studies. Soffin et al [16] reported a series of 32 patients without a control group with low postoperative pain. Several reasons can be put forward to explain our results. First of all, the TAP block allows anesthesia of the abdominal wall by blocking the anterior branches of the spinal nerves from the roots T7 to L1, which travel in the plane of the transverse muscle [5]. The sensory innervation of the spine and the posterior muscular and aponeurotic structures is ensured on the one hand by the dorsal branches of the spinal nerves and their branches of division (somatic system), and on the other hand by the sinus-vertebral nerves (vegetative system) whose termination is double, in the communicating branches (between the sympathetic trunk and the spinal nerves) and in the anterior branch of the spinal nerves, very close to the spine [17]. The TAP block is therefore not active on nociceptive impulses from the spinal structures, and probably does not allow analgesia of the entire surgical intervention area. In our study, when collecting pain scores, the area and type of pain were not specified. We were therefore unable to determine whether patients who received a TAP block were better relieved at the abdominal level than those who did not, while presenting pain of spinal origin was sufficient to explain the pain scores observed. It is also possible that the patients presented visceral pain, mediated by the vegetative nervous system, on which the TAP block is not active. Other regional anesthesia techniques could therefore be considered to allow better postoperative analgesia in lumbar spine surgery. Thus, the benefit of epidural anesthesia has already been suggested by some authors [18–20]. We can also hypothesize that the posterior approach of the TAP block (at the level of the lateral aponeurotic end of the transverse muscle) [21], which has been shown to allow diffusion of the local anesthetic in the paravertebral spaces [22], could be an alternative. It should be noted that the two groups benefited from multimodal analgesia combining the systematic use of ketamine, dexamethasone, paracetamol, ketoprofen and nefopam, which is not the case in many

studies having shown the effectiveness of TAP block in different surgical fields [9,11]. This might explain the low consumption of morphine at 24 hours in the control group in our study when compare with other studies. A recent review of the literature on the benefit of TAP block for postoperative analgesia highlighted the small number of randomized trials that have compared the TAP block to optimized multimodal analgesia strategies [23]. There are several limitations to our study. Firstly, the TAP block was performed at the end of surgery for logistical reasons. Regional analgesia is classically performed before the surgical incision, in order to cover the nociceptive stimuli related to the intervention, limit morphine consumption and adverse effects of morphine, including hyperalgesia [24]. A pre-incisional TAP block was shown to be associated with a reduction of morphine consumption 48 hours after laparotomy hysterectomy compared to TAP block performed at the end of the intervention and to placebo (mean dose  $\pm$  sd in mg  $21\pm4$ ,  $33\pm5$ ,  $66\pm5$  respectively;  $p<0.0001$ ) [25]. However, there is no formal proof of the superiority of pre-incision regional analgesia in the literature, due to contradictory results [26,27]. Secondly, we did not assess the analgesic efficacy of the TAP block by directly testing the dermatoma involved in order to ensure the blinding of the treatment group. However, the TAP and the spread of ropivacaine were visualized in all patients. Thirdly, the variance of morphine consumption was broader than what was expected originally and used to base the power calculation. We cannot rule out a lack of power in the study. Finally, as this is a single-center study, the external validity of our results may be questioned.

## **Conclusion**

In conclusion, among patients undergoing anterior lumbar interbody fusion, TAP block did not improve postoperative analgesia when a multimodal analgesia protocol is used.

**Disclosure:** none

**References**

- [1] Capener N. Spondylolisthesis. *BJS (British Journal of Surgery)* 1932;19:374–86. <https://doi.org/10.1002/bjs.1800197505>.
- [2] Shen FH, Samartzis D, Khanna AJ, Anderson DG. Minimally invasive techniques for lumbar interbody fusions. *Orthop Clin North Am* 2007;38:373–86; abstract vi. <https://doi.org/10.1016/j.ocl.2007.04.002>.
- [3] Lubansu A. [Minimally invasive spine arthrodesis in degenerative spinal disorders]. *Neurochirurgie* 2010;56:14–22. <https://doi.org/10.1016/j.neuchi.2009.12.002>.
- [4] Rafi AN. Abdominal field block: a new approach via the lumbar triangle. *Anaesthesia* 2001;56:1024–6. <https://doi.org/10.1111/j.1365-2044.2001.2279-40.x>.
- [5] Beloeil H, Zetlaoui PJ. TAP bloc et blocs de la paroi abdominale. *Annales Françaises d'Anesthésie et de Réanimation* 2011;30:141–6. <https://doi.org/10.1016/j.annfar.2010.12.015>.
- [6] Liu L, Xie Y-H, Zhang W, Chai X-Q. Effect of Transversus Abdominis Plane Block on Postoperative Pain after Colorectal Surgery: A Meta-Analysis of Randomized Controlled Trials. *Medical Principles and Practice: International Journal of the Kuwait University, Health Science Centre* 2018;27:158–65. <https://doi.org/10.1159/000487323>.
- [7] Gao T, Zhang J-J, Xi F-C, Shi J-L, Lu Y, Tan S-J, et al. Evaluation of Transversus Abdominis Plane (TAP) Block in Hernia Surgery: A Meta-analysis. *Clin J Pain* 2017;33:369–75. <https://doi.org/10.1097/AJP.0000000000000412>.
- [8] Ghimire A, Bhattarai B, Prasad JN, Shah SP. The Analgesic Effectiveness of Ipsilateral Transversus Abdominis Plane Block in Adult Patients Undergoing Appendectomy: A Prospective Randomized Controlled Trial. *Kathmandu University Medical Journal* 2015;13:361–5. <https://doi.org/10.3126/kumj.v13i4.16838>.
- [9] Parikh BK, Waghmare VT, Shah VR, Mehta T, Butala BP, Parikh GP, et al. The analgesic efficacy of ultrasound-guided transversus abdominis plane block for retroperitoneoscopic donor nephrectomy: A randomized controlled study. *Saudi Journal of Anaesthesia* 2013;7:43–7. <https://doi.org/10.4103/1658-354X.109808>.
- [10] Covotta M, Claroni C, Costantini M, Torregiani G, Pelagalli L, Zinilli A, et al. The Effects of Ultrasound-Guided Transversus Abdominis Plane Block on Acute and Chronic Postsurgical Pain After Robotic Partial Nephrectomy: A Prospective Randomized Clinical Trial. *Pain Med* 2020;21:378–86. <https://doi.org/10.1093/pm/pnz214>.
- [11] Carney J, McDonnell JG, Ochana A, Bhinder R, Laffey JG. The transversus abdominis plane block provides effective postoperative analgesia in patients undergoing total abdominal

- hysterectomy. *Anesth Analg* 2008;107:2056–60. <https://doi.org/10.1213/ane.0b013e3181871313>.
- [12] Abdallah FW, Halpern SH, Margarido CB. Transversus abdominis plane block for postoperative analgesia after Caesarean delivery performed under spinal anaesthesia? A systematic review and meta-analysis. *Br J Anaesth* 2012;109:679–87. <https://doi.org/10.1093/bja/aes279>.
- [13] Champaneria R, Shah L, Wilson MJ, Daniels JP. Clinical effectiveness of transversus abdominis plane (TAP) blocks for pain relief after caesarean section: a meta-analysis. *International Journal of Obstetric Anesthesia* 2016;28:45–60. <https://doi.org/10.1016/j.ijoa.2016.07.009>.
- [14] Esmende SM, Solomito MJ, Eisler J, Finkel KJ, Kainkaryam PP, Maffeo-Mitchell CL. Utility of the transversus abdominis plane and rectus sheath blocks in patients undergoing anterior lumbar interbody fusions. *Spine J* 2022:S1529-9430(22)00191-7. <https://doi.org/10.1016/j.spinee.2022.04.019>.
- [15] Reisener M-J, Hughes AP, Okano I, Zhu J, Lu S, Salzmänn SN, et al. The association of transversus abdominis plane block with length of stay, pain and opioid consumption after anterior or lateral lumbar fusion: a retrospective study. *Eur Spine J* 2021;30:3738–45. <https://doi.org/10.1007/s00586-021-06855-8>.
- [16] Soffin EM, Freeman C, Hughes AP, Wetmore DS, Memtsoudis SG, Girardi FP, et al. Effects of a multimodal analgesic pathway with transversus abdominis plane block for lumbar spine fusion: a prospective feasibility trial. *Eur Spine J* 2019;28:2077–86. <https://doi.org/10.1007/s00586-019-06081-3>.
- [17] Auroche P. Innervation des articulations zygapophysiales du rachis lombaire. *Anat Clin* 1983;5:7–11. <https://doi.org/10.1007/BF01798879>.
- [18] Cata JP, Noguera EM, Parke E, Ebrahim Z, Kurz A, Kalfas I, et al. Patient-controlled epidural analgesia (PCEA) for postoperative pain control after lumbar spine surgery. *J Neurosurg Anesthesiol* 2008;20:256–60. <https://doi.org/10.1097/ANA.0b013e31817ffe90>.
- [19] Schenk MR, Putzier M, Kügler B, Tohtz S, Voigt K, Schink T, et al. Postoperative analgesia after major spine surgery: patient-controlled epidural analgesia versus patient-controlled intravenous analgesia. *Anesth Analg* 2006;103:1311–7. <https://doi.org/10.1213/01.ane/0000247966.49492.72>.
- [20] Schroeder KM, Zahed C, Andrei AC, Han S, Ford MP, Zdeblick TA. Epidural anesthesia as a novel anesthetic technique for anterior lumbar interbody fusion. *Journal of Clinical Anesthesia* 2011;23:521–6. <https://doi.org/10.1016/j.jclinane.2011.01.008>.
- [21] Mallan D, Sharan S, Saxena S, Singh TK, Faisal null. Anesthetic techniques: focus on transversus abdominis plane (TAP) blocks. *Local Reg Anesth* 2019;12:81–8. <https://doi.org/10.2147/LRA.S138537>.

- [22] Carney J, Finnerty O, Rauf J, Bergin D, Laffey JG, Mc Donnell JG. Studies on the spread of local anaesthetic solution in transversus abdominis plane blocks. *Anaesthesia* 2011;66:1023–30. <https://doi.org/10.1111/j.1365-2044.2011.06855.x>.
- [23] Tran DQ, Bravo D, Leurcharusmee P, Neal JM. Transversus Abdominis Plane Block: A Narrative Review. *Anesthesiology* 2019;131:1166–90. <https://doi.org/10.1097/ALN.0000000000002842>.
- [24] Fletcher D, Martinez V. Opioid-induced hyperalgesia in patients after surgery: a systematic review and a meta-analysis. *British Journal of Anaesthesia* 2014;112:991–1004. <https://doi.org/10.1093/bja/aeu137>.
- [25] Amr YM, Amin SM. Comparative study between effect of pre- versus post-incisional transversus abdominis plane block on acute and chronic post-abdominal hysterectomy pain. *Anesth Essays Res* 2011;5:77–82. <https://doi.org/10.4103/0259-1162.84199>.
- [26] Xia J, Olson TJP, Tritt S, Liu Y, Rosen SA. Comparison of preoperative versus postoperative transversus abdominis plane and rectus sheath block in patients undergoing minimally invasive colorectal surgery. *Colorectal Disease* 2020;22:569–80. <https://doi.org/10.1111/codi.14910>.
- [27] Abdallah F, Chan V, Brull R. Transversus Abdominis Plane Block: A Systematic Review. *Regional Anesthesia & Pain Medicine* 2011. <https://doi.org/10.1097/AAP.0b013e3182429531>.

## Figure captions

**Figure 1:** Flow chart

**Figure 2:** Cumulated morphine consumption (mg) 24 hours after surgery. The thick horizontal line is the median, the lower and upper edges of the box correspond to the first and third quartiles. The upper whisker extends to the largest value no further than  $1.5 \times \text{IQR}$  from the upper edge and the lower whisker extends to the smallest value at most  $1.5 \times \text{IQR}$  from the lower edge. Data beyond the end of the whiskers are plotted individually as outlying points.

**Figure 3:** Morphine consumption (mg) in PACU and 48 hours after surgery. The thick horizontal line is the median, the lower and upper edges of the box correspond to the first and third quartiles. The upper whisker extends to the largest value no further than  $1.5 \times \text{IQR}$  from the upper edge and the lower whisker extends to the smallest value at most  $1.5 \times \text{IQR}$

from the lower edge. Data beyond the end of the whiskers are plotted individually as outlying points.

Table 1 : Patients characteristics

<b>Variable</b>	<b>Ropivacaine</b> n = 21	<b>Placebo</b> n = 21
Age, years	46 [39 - 52]	50 [44 - 54]
Gender female/ male	9 (43 %) / 12 (57 %)	7 (33%) / 14 (63 %)
BMI,	26 [27 - 29]	25 [22 -27]
Preoperative pain (NPS)	4 [2 – 6]	4 [2 – 5]
ASA 1/2	13 (62 %) / 8 (38%)	13 (62 %) / 8 (38%)

Data are presented as median (IQR) or n(%) when appropriate. NPS: numerical pain score.

BMI: body mass index

Table 2 :

<b>Variable</b>	<b>Ropivacaine</b> n = 21	<b>Placebo</b> n = 21
NPS 1 h	7 [4 – 8]	6 [3 – 7]
NPS 6h	2 [2 – 3]	2 [1 – 4]
NPS 12h	3 [2 – 4]	2 [0 – 4]
NPS 24h	2 [2 – 3]	2 [0 – 4]
NPS : first ambulation	2 [0 – 3]	3 [2 – 5]
PONV	3 (14%)	4 (19%)
Length of stay (days)	4 [4 – 6]	4 [4 – 6]

Data are presented as median (IQR) or n(%) when appropriate. NPS: numerical pain score.

PONV: postoperative nausea and vomiting. Data were not statistically different.



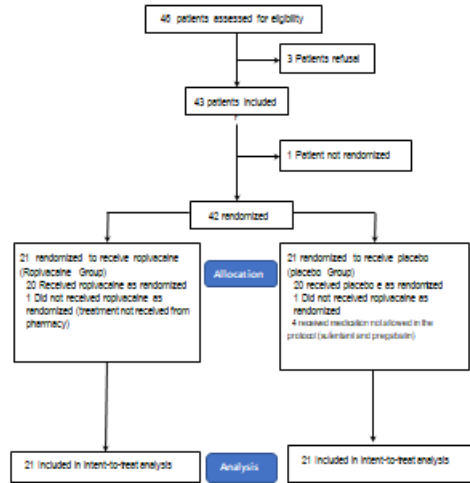


Figure 2

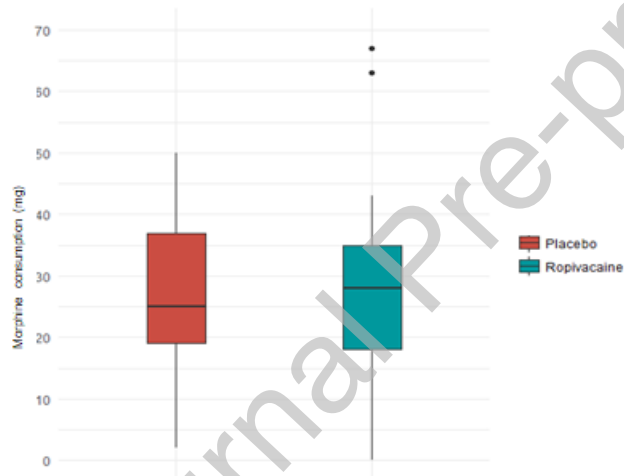
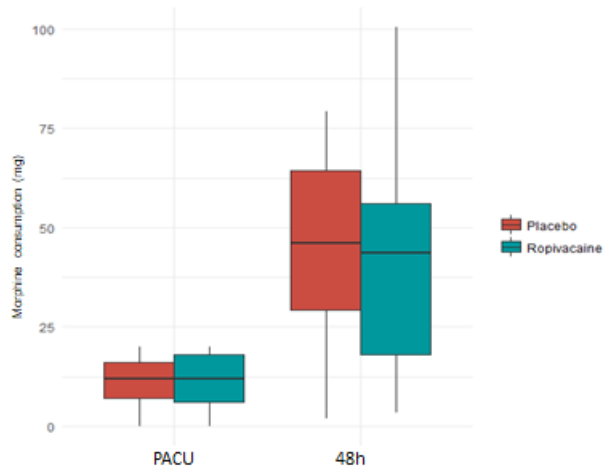


Figure 3



Journal Pre-proof