



HAL
open science

French practical guidelines for the diagnosis and management of idiopathic pulmonary fibrosis – 2021 update. Full-length version

Vincent Cottin, Philippe Bonniaud, Jacques Cadranel, Bruno Crestani, Stéphane Jouneau, Sylvain Marchand-Adam, Hilario Nunes, Lidwine Wémeau-Stervinou, Emmanuel Bergot, Elodie Blanchard, et al.

► To cite this version:

Vincent Cottin, Philippe Bonniaud, Jacques Cadranel, Bruno Crestani, Stéphane Jouneau, et al.. French practical guidelines for the diagnosis and management of idiopathic pulmonary fibrosis – 2021 update. Full-length version. *Respiratory Medicine and Research*, 2023, 83, pp.100948. 10.1016/j.resmer.2022.100948 . hal-04087431

HAL Id: hal-04087431

<https://hal.science/hal-04087431>

Submitted on 4 Apr 2024

HAL is a multi-disciplinary open access archive for the deposit and dissemination of scientific research documents, whether they are published or not. The documents may come from teaching and research institutions in France or abroad, or from public or private research centers.

L'archive ouverte pluridisciplinaire **HAL**, est destinée au dépôt et à la diffusion de documents scientifiques de niveau recherche, publiés ou non, émanant des établissements d'enseignement et de recherche français ou étrangers, des laboratoires publics ou privés.

French practical guidelines for the diagnosis and management of idiopathic pulmonary fibrosis - 2021 update. Full-length version

Vincent Cottin ¹, Philippe Bonniaud ², Jacques Cadranet ³, Bruno Crestani ⁴, Stéphane Jouneau ⁵, Sylvain Marchand-Adam ⁶, Hilario Nunes ⁷, Lidwine Wémeau-Stervinou ⁸, Emmanuel Bergot ⁹, Elodie Blanchard ¹⁰, Raphaël Borie ⁴, Arnaud Bourdin ¹¹, Cécile Chenivesse ¹², Annick Clément ¹³, Emmanuel Gomez ¹⁴, Anne Gondouin ¹⁵, Sandrine Hirschi ¹⁶, François Lebargy ¹⁷, Charles-Hugo Marquette ¹⁸, David Montani ¹⁹, Grégoire Prévot ²⁰, Sébastien Quetant ²¹, Martine Reynaud-Gaubert ²², Mathieu Salaun ²³, Olivier Sanchez ²⁴, Bruno Trumbic ²⁵, Karim Berkani ²⁶, Pierre-Yves Brillet ²⁷, Marion Campana ²⁸, Lara Chalabreysse ²⁹, Gérard Chatté ³⁰, Didier Debieuvre ³¹, Gilbert Ferretti ³², Jean-Michel Fourrier ³³, Nicolas Just ³⁴, Marianne Kambouchner ³⁵, Bertrand Legrand ³⁶, Frédéric Le Guillou ³⁷, Jean-Pierre Lhuillier ³⁸, Anas Mehdaoui ³⁹, Jean-Marc Naccache ⁴⁰, Catherine Paganon ⁴¹, Martine Rémy-Jardin ⁴², Salim Si-Mohamed ⁴³, Philippe Terrioux ⁴⁴; OrphaLung network

¹ National Coordinating Reference Center for Rare Lung Diseases, Pneumology Department, Louis Pradel Hospital, Hospices Civils de Lyon (HCL), UMR 754, IVPC, INRAE, Member of OrphaLung, RespiFil, Radico-ILD2 and ERN-LUNG, Lyon University, Claude Bernard Lyon 1 University, 28 avenue Doyen Lépine, Lyon F-69677 CEDEX, France. Electronic address: vincent.cottin@chu-lyon.² Constitutive Reference Center for Rare Lung Diseases, Bourgogne University Hospital Center and Faculty of Medicine and Pharmacy, Bourgogne-Franche Comté University, INSERM U123-1, Dijon, France.

³ Constitutive Reference Center for Rare Lung Diseases, Assistance Publique-Hôpitaux de Paris (AP-HP), Tenon Hospital, Sorbonne University, GRC 04 Theranoscan, Paris, France.

⁴ Constitutive Reference Center for Rare Lung Diseases, Pneumology Department A, AP-HP, Bichat Hospital, Paris, France.

⁵ Expert Center for Rare Lung Diseases in Adults, Pneumology Department, Pontchaillou Hospital, IRSET UMR1085, Rennes 1 University, Rennes, France.

⁶ Expert Center for Rare Lung Diseases in Adults, Pneumology Department, CHRU, Bretonneau Hospital, Tours, France.

⁷ Constitutive Reference Center for Rare Lung Diseases, Pneumology Department, Avicenne Hospital, Bobigny, AP-HP, Sorbonne Paris Nord University, Bobigny, France.

⁸ Constitutive Reference Center for Rare Lung Diseases, Heart-Lung Institute, Pneumology and Immuno-allergology Department, CHRU of Lille, Lille, France.

⁹ Expert Center for Rare Lung Diseases in Adults, Pneumology Department, Pneumology and Thoracic Oncology Department, Côte de Nacre Hospital, Caen University Hospital Center, Caen, France.

- ¹⁰ Expert Center for Rare Lung Diseases in Adults, Pneumology Department, Haut Levêque Hospital, Bordeaux University Hospital Center, Pessac, France.
- ¹¹ Expert Center for Rare Lung Diseases in Adults, Pneumology and Addictology Department, INSERM U1046, CNRS UMR 921, Arnaud de Villeneuve Hospital, Montpellier University Hospital Center, Montpellier, France.
- ¹² Constitutive Reference Center for Rare Lung Diseases, Pneumology and Immuno-allergology Department, Albert Calmette Hospital, Lille Regional University Hospital Center, Infection and Immunity Center of Lille U1019 - UMR 9017, Lille University, Lille University Hospital Center, CNRS, Inserm, Pasteur Institute of Lille, Lille, France.
- ¹³ Resource and Expert Center for Pediatric Cystic Fibrosis, Reference Center for Rare Respiratory Diseases (RespiRare), Pediatric Pneumology Department, Armand Trousseau Children's Hospital, Paris Est University Hospital Center, Sorbonne University, Paris, France.
- ¹⁴ Expert Center for Rare Lung Diseases, Pneumology Department, Brabois Hospitals, Nancy Regional University Hospital Center, Vandoeuvre-les Nancy, France.
- ¹⁵ Expert Center for Rare Lung Diseases, Pneumology Department, HP, Jean Minjoz University Hospital Center, Besançon, France.
- ¹⁶ Expert Center for Rare Lung Diseases, Pneumology Department, New Civil Hospital, Strasbourg, France.
- ¹⁷ Expert Center for Rare Lung Diseases, Pneumology Department, Maison Blanche University Hospital Center, Reims, France.
- ¹⁸ Expert Center for Rare Lung Diseases, FHU OncoAge, Nice cedex 1, Pneumology and Thoracic Oncology Department, Institute of Research on Cancer and Aging (IRCAN), Pasteur Hospital, Nice University Hospital Center, Côte d'Azur University, CNRS, INSERM, Nice, France.
- ¹⁹ Expert Center for Rare Lung Diseases, National Coordinating Reference Center for Pulmonary Hypertension, Pneumology and Pneumological Intensive Care Unit, DMU 5 Thorinno, Inserm UMR S999, Faculty of Medicine, AP-HP, Paris-Sud University Hospital Center, Bicêtre Hospital, Paris-Saclay University, Le Kremlin-Bicêtre, France.
- ²⁰ Expert Center for Rare Lung Diseases, Pneumology Department, Larrey University Hospital Center, Toulouse, France.
- ²¹ Expert Center for Rare Lung Diseases, Pneumology and Physiology Department, Grenoble Alpes University Hospital Center, Grenoble, France.
- ²² Expert Center for Rare Lung Diseases, Pneumology Department, AP-HM, Nord University Hospital Center, Marseille, Aix Marseille University, IRD, APHM, MEPHI, IHU-Méditerranée Infection, Marseille, France.

- ²³ Expert Center for Rare Lung Diseases, Pneumonology, Thoracic Oncology and Respiratory Intensive Care Department & CIC 1404, Charles Nicole Hospital, Rouen University Hospital Center, IRIB, QuantiIF-LITIS Laboratory, EA 4108, Rouen University, Rouen, France.
- ²⁴ Expert Center for Rare Lung Diseases, Pneumonology and Intensive Care Department, Georges Pompidou European Hospital, AP-HP, Paris, France.
- ²⁵ Cap Evidence, Paris, France.
- ²⁶ Pierre de Soleil Clinic, Vétraz Monthoux, France.
- ²⁷ UPRES EA 2363, Radiology Department, AP-HP, Avicenne Hospital, Paris 13 University, Bobigny, France.
- ²⁸ Pneumonology and Thoracic Oncology Department, Orléans Regional Hospital Center, Orléans, France.
- ²⁹ Pathological Anatomy Department, East Hospital Group, HCL, Bron, France.
- ³⁰ Pneumonology Practice and Protestant Infirmary, Caluire, France.
- ³¹ Pneumonology Department, GHRMSA, Emile Muller Hospital, Mulhouse, France.
- ³² Diagnostic and Interventional Radiology Department, Grenoble Alpes University Hospital Center, Grenoble Alpes University, Grenoble, France.
- ³³ Pierre Enjalran Association for Idiopathic Pulmonary Fibrosis (APEFPI), Meyzieu, France.
- ³⁴ Pneumonology Department, Victor Provo Hospital Center, Roubaix, France.
- ³⁵ Pathology Department, AP-HP, Avicenne Hospital, Bobigny, France.
- ³⁶ Medical Practice of Bourgogne, ULR 2694 METRICS, CERIM, Lille University, Lille University Hospital Center, Tourcoing, Lille, France.
- ³⁷ Pneumonology Practice, Esquirol Health Pole, Le Pradet, France.
- ³⁸ Pneumonology Practice, La Varenne Saint-Hilaire, France.
- ³⁹ Pneumonology and Thoracic Oncology Department, Eure-Seine Hospital Center, Évreux, France.
- ⁴⁰ Pneumonology, Allergology and Thoracic Oncology Department, Paris Saint-Joseph Hospital Group, Paris, France.
- ⁴¹ Pneumonology Department, Louis Pradel Hospital, HCL, Bron, France.
- ⁴² Heart-Lung Institute, Radiology and Thoracic Imaging Department, Lille Regional University Hospital Center, Lille, France.

⁴³ Cardiovascular and Thoracic Imaging Department, Louis Pradel Hospital, HCL, INSA-Lyon, UJM-Saint Etienne, CNRS, Inserm, CREATIS UMR 5220, Lyon University, Claude Bernard Lyon 1 University, U1206, Villeurbanne, France.

⁴⁴ Pneumonology Practice, Meaux, France.

Keywords:

Biopsy; Interstitial lung disease; Pulmonary fibrosis; Usual interstitial pneumonia.

*** Corresponding author.**

E-mail address:

vincent.cottin@chu-lyon.fr (V. Cottin).

Abstract

Background:

Since the latest 2017 French guidelines, knowledge about idiopathic pulmonary fibrosis has evolved considerably.

Methods:

Practical guidelines were drafted on the initiative of the Coordinating Reference Center for Rare Pulmonary Diseases, led by the French Language Pulmonology Society (SPLF), by a coordinating group, a writing group, and a review group, with the involvement of the entire OrphaLung network, pulmonologists practicing in various settings, radiologists, pathologists, a general practitioner, a health manager, and a patient association. The method followed the "Clinical Practice Guidelines" process of the French National Authority for Health (HAS), including an online vote using a Likert scale.

Results:

After a literature review, 54 guidelines were formulated, improved, and then validated by the working groups. These guidelines addressed multiple aspects of the disease: epidemiology, diagnostic procedures, quality criteria and interpretation of chest CT scans, lung biopsy indication and procedures, etiological workup, methods and indications for family screening and genetic testing, assessment of the functional impairment and prognosis, indication and use of antifibrotic agents, lung transplantation, management of symptoms, comorbidities and complications, treatment of chronic respiratory failure, diagnosis and management of acute exacerbations of fibrosis.

Conclusion:

These evidence-based guidelines are intended to guide the diagnosis and practical management of idiopathic pulmonary fibrosis.

Introduction

Idiopathic pulmonary fibrosis (IPF) is the most common form of chronic idiopathic interstitial lung disease (ILD) in adults within the broad group of ILDs. It is a chronic, irreversible disease of unknown cause, characterized histologically by an excess of fibroblasts and extracellular matrix in the lung. It occurs mainly from the age of 60, and is limited to the lungs. The histopathological and/or radiological presentation of IPF is similar to that of usual interstitial pneumonia (UIP). The evolution is chronic and progressive, with possible acute exacerbations. The list of acronyms repeatedly used in this text is presented in [Table 1](#).

In France, its prevalence is estimated at 8.2 per 100,000 inhabitants (i.e. about 5500 patients), and its annual incidence at 2.8 per 100,000 inhabitants (i.e. about 1800 new cases per year) [1]. It is therefore a rare disease according to the European definition.

In France, the diagnosis and management of IPF is based on a National Reference Center for Rare Lung Diseases, OrphaLung (national coordinating reference center, constitutive reference centers), and regional Expert Centers within the framework of the National Rare Disease Plan. Physicians, researchers and patients who want to learn more about these structures are invited to consult the Web-site “maladies-pulmonaires-rares.fr/” [2]. This network is part of the "RespiFil" rare disease care network (www.respifil.fr), dedicated to rare lung diseases, that brings together three reference centers and their regional centers: the RespiRare Reference Center for Rare Respiratory Diseases in Children, the OrphaLung Reference Center for Rare Lung Diseases in Adults and the PulmoTension Reference Center for Severe Pulmonary Arterial Hypertension.

Since the publication in 2017 of the first update of the French guidelines for the diagnosis and management of IPF [3], new data have been published on several important features of IPF and are taken into account in this second update:

- _ Radiological diagnostic criteria;
- _ Advances in genetics and indications for genetic testing;
- _ Identification of risk factors for exacerbation such as pollution;
- _ Better consideration of comorbidities including malnutrition, frailty, emphysema;
- _ Better assessment of the risk of bronchial cancer;
- _ Experience and data from registers with regard to treatments;
- _ Definition and management of progressive non-IPF pulmonary fibrosis.

The incidence of IPF increases with age, and the disease typically appears insidiously during the 6th or 7th decade of life [4,5]. IPF rarely appears before the age of 50: the youngest patients are likely to later show signs of connective tissue disease (CTD), which is subclinical when the diagnosis of IPF is made [6]; they may also carry familial IPF [7]. IPF is more common in men than in women (sex ratio of 1.5–1.7) and a history of smoking is found in 70–75% of patients [8]. The main other risk factors are listed in [Table 2](#) [9].

Table 1
List of commonly used acronyms.

Abbreviation	Significance
ANCA	Antineutrophil cytoplasmic antibodies
ANSM	French Agency for the Safety of Medicines and Health Products
COPD	Chronic obstructive pulmonary disease
TBLB	Transbronchial lung biopsy
VATS lung biopsy	Video-assisted thoracoscopic lung biopsy
LC	Lung cancer
TBCB	Transbronchial lung cryobiopsy
FVC	Forced vital capacity
DIP	Desquamative interstitial pneumonia
DLco	Diffusing capacity for carbon monoxide
MDD	Multidisciplinary discussion
ECMO	Extracorporeal membrane oxygen therapy
RCT	Randomized controlled trial
PFT	Pulmonary function tests
AE	Adverse event
IPF	Idiopathic pulmonary fibrosis
PH	Pulmonary hypertension
HR	<i>Hazard ratio</i>
95% CI	95% confidence interval
BMI	Body mass index
IPAF	Interstitial Pneumonia with Autoimmune Features
Kco(DLco/VA)	Transfer coefficient for carbon monoxide
BAL	Bronchoalveolar lavage
NAC	N-acetylcysteine
NT-proBNP	N-terminal pro-brain natriuretic peptide
HP	Hypersensitivity pneumonitis
UIP	Usual interstitial pneumonia
ILD	Interstitial lung disease
NSIP	Non-specific interstitial pneumonia
COP	Cryptogenic organizing pneumonia
QoL	Quality of life
RB-ILD	Respiratory bronchiolitis-associated interstitial lung disease
GERD	Gastroesophageal reflux disease
OSA	Obstructive sleep apnea
CPFE	Combined pulmonary fibrosis and emphysema syndrome
SGRQ	Saint-George hospital respiratory questionnaire
SPLF	<i>Société de pneumologie de langue française</i> (French Learned Society of Pulmonology)
SRIF	Smoking-Related Interstitial Fibrosis
PFS	Progression-free survival
CT	Computed tomography
6MWT	6 min walk test

The diagnosis of IPF should be considered in any patient with chronic exertional dyspnea, cough, bilateral dry crackles (velcro type) at the lung bases and/or nail clubbing, this clinical picture occurring in an unexplained manner, in the absence of warning signs that would guide the diagnosis towards a systemic disease [10]. More rarely, the disease may be revealed by an acute exacerbation [11].

Table 2
Main risk factors for idiopathic pulmonary fibrosis (modified from Ley et Colard [9]).

Exposures related to the occupational and extra-occupational environment
<ul style="list-style-type: none">• Tobacco smoke• Plant/animal, textile, metal, wood dust• Stone / sand / silica
Genetic variants
<ul style="list-style-type: none">• <i>TERT, TERC, RTEL1, PARN, NAF1, DKC1, TINF2</i>• <i>SFTPC, SFTPA1, SFTPA2</i>• <i>MUC5B</i>• <i>ELMOD2</i>• <i>TOLLIP</i>

DKC1: dyskerin pseudouridine synthase 1; ELMOD2: ELMO domain-containing 2; MUC5B: mucin 5B; NAF1: nuclear assembly factor 1 ribonucleoprotein; PARN: poly(A)-specific ribonuclease; RTEL1: regulator of telomere elongation helicase 1; SFTPA2: surfactant protein A2; SFTPC: surfactant protein C; TERT, TERC: telomerase complex genes; TINF2: TERF1: interacting nuclear factor 2; TOLLIP: toll interacting protein.

Methods

Responsibility of the groups

This document written by French IPF specialists is an update of the French guidelines for the diagnosis and management of IPF published in 2013 and 2017 [3,12], based on a critical review of the literature published later in this field. It results from the coordinated efforts of a coordinating group, a writing group and a review group set up on this occasion.

The document was written in compliance with Good Clinical Practice (GCP) guidelines, according to the "Clinical Practice Guidelines" process of the French National Authority for Health (HAS) [13]. The tasks of the coordinating group were to submit the drafting and validation protocol to the SPLF and Revue des Maladies Respiratoires (RMR), to conduct a systematic review and a synthesis of the literature, to draft a first version of the document intended to the writing group, to organize and ensure the smooth running of the drafting and validation protocol and to submit the guidelines validated by the writing and review groups to the SPLF and RMR for publication.

The tasks of the writing group were to assess the first version of the document drafted by the coordinating group, to assess guidelines using a scale ("I agree", "I hesitate", "I disagree"), to identify the items to be revised, to propose suggestions on the form and content, and to validate the document to be submitted to the review group.

The tasks of the review group - consisting of pulmonologists practicing in University Hospital Centers (excluding Expert Centers), General Hospital Centers, or in the private sector, specialized radiologists, and pathologists specialized in thoracic diseases - were to assess using a scale ranging from 1 (total disagreement) to 9 (total agreement) all the addressed themes and corresponding guidelines in the document submitted by the coordinating group. The votes were conducted electronically and analyzed anonymously. A guideline proposal was included in the guideline text submitted for opinion to the review group if it was

approved by at least 80% of the members of the writing group. The rating had to be based on the synthesis of the data published in the literature (attached to the questionnaire), and the reader experience in the field. The members of the review group could only answer the parts of the questionnaire that felt within their area of expertise.

Composition of the groups

Coordinating group: Vincent Cottin (Lyon), Philippe Bonniaud (Dijon), Jacques Cadranel (Paris), Bruno Crestani (Paris), Stéphane Jouneau (Rennes), Sylvain Marchand-Adam (Tours), Hilario Nunes (Bobigny), Lidwine Wemeau-Stervinou (Lille).

Writing group: coordinating group extended to all the heads of the constitutive centers of the Reference Center and Expert Centers for Rare Lung Diseases (see [Appendix 1](#)): Emmanuel Bergot (Caen), Élodie Blanchard (Bordeaux), Arnaud Bourdin (Montpellier), Cécile Chenivresse (Lille), Annick Clément (Paris), Emmanuel Gomez (Nancy), Anne Gondouin (Besançon), Sandrine Hirschi (Strasbourg), François Lebagy (Reims), Charles-Hugo Marquette (Nice), David Montani (Le Kremlin Bicêtre), Grégoire Prévot (Toulouse), Sébastien Quetant (Grenoble), Martine Reynaud-Gaubert (Marseille), Mathieu Salaun (Rouen), Olivier Sanchez (Paris), and Raphaël Borie (Paris).

Review group: expanded to the physicians below:

Private practice pulmonologists: Gérard Chatté (Caluire), Frédéric Le Guillou (La Rochelle), Jean-Pierre Lhuillier (La Varenne Saint Hilaire), Philippe Terrioux (Meaux).

Pulmonologists from General Hospital Centers: Karim Berkani (Cran Gevrier), Marion Campana (Orléans), Didier Debievre (Mulhouse), Nicolas Just (Roubaix), Anas Mehdaoui (Évreux), Jean-Marc Naccache (Paris).

Radiologists: Pierre-Yves Brillet (Bobigny), Gilbert Ferretti (Grenoble), Martine Rémy-Jardin (Lille), Salim Si-Mohamed (Lyon). Pathologists: Marianne Kambouchner (Bobigny), Lara Chalabreysse (Lyon).

General practitioners: Bertrand Legrand (Tourcoing). Paramedics: Catherine Paganon (nursing executive; Lyon).

Associations of patients: Jean-Michel Fourier, Pierre Enjalran Association for Idiopathic Pulmonary Fibrosis. RespiFil: Meryem Sari-Hassoun.

It should be noted that the representatives of general practitioners, paramedics and patient associations read the document for information, possible comments and suggestions, but did not participate in the votes given its medical and scientific specificity.

Steps for drafting guidelines

The various steps for drafting these guidelines were as follows:

_ Collection of preliminary comments and suggestions from the Reference and Expert Centers and their private and hospital pulmonologist correspondents;

_ Drafting of a first version of the document by the coordinating group;

_ Reading of the first version of the document by the writing group;

_ Responses and revised version by the coordinating group;

- _ Reading and votes of the review group;
- _ Responses to and revised version of questions with insufficient consensus level by the coordinating group;
- _ Reading and votes of the review group;
- _ Responses and revised version by the coordinating group;
- _ Reading by the Scientific Council of the SPLF;
- _ Responses and revised version by the coordinating group;
- _ Submission for publication.

A guideline was included in the guideline text if it was approved by at least 90% of the members of the review group ($\geq 90\%$ of the review group's responses in the [5–9] range) (Appendix 2).

The guidelines were formulated as follows:

- _ "It is recommended to" means that the measure should be applied in most patients (e.g., treatment with proven efficacy).
- _ "It is proposed to" means that the measure may be applied to a portion of patients (e.g., treatment with very likely efficacy).
- _ "It is not recommended to" means that the measure should not be applied in most patients (e.g., ineffective treatment).
- _ "It is recommended not to" means that the measure should not be applied (e.g., treatment with potentially harmful effects).

The guideline methodology was approved by the Scientific Council of the SPLF on October 27, 2016 and for the update on September 23, 2021. The Scientific Council of the SPLF issued a favorable opinion on the guideline relevance, drafting, and applicability on September 23, 2021. The group composition was approved by the OrphaLung Scientific Council on March 26, 2021.

Logistical support was provided by the company Carely, from a donation to the Association pour l'amélioration de la prise en charge des maladies pulmonaires rares, for an independent medical writer and technical support for electronic voting.

The declarations of interests of the experts of the different groups are appended to this document and published in electronic format.

Diagnosis

IPF mainly appears after the age of 60, with a male predominance [14,15]. The clinical signs of IPF are not specific, and the diagnosis is often made (too) late.

The initial presentation combines exertional dyspnea with progressive onset, and non-productive cough; bilateral dry crackles (dry, inspiratory, reproducing the noise of "velcro", velcro type) are almost constant and appear early [16,17], and are associated with radiological signs of fibrosis [18]. Nail clubbing is present in almost 50% of cases but lacks specificity [19]. Weight loss or impaired general condition are rarer but associated with a poor prognosis [20]. Cyanosis and signs of right ventricular failure are only observed at an advanced stage.

In the absence of treatment, the disease progresses to chronic respiratory failure and death. Precapillary pulmonary hypertension (PH) is often present at an advanced stage, in particular when emphysema is associated. The presence of an UIP pattern on the CT scan and/or histopathological examination is mandatory to make the diagnosis of IPF.

In practice, the presence of IPF should be suspected in adults with newly diagnosed ILD of apparently unknown etiology when the following signs are present:

- _ Crackles at both lung bases;
- _ Unexplained pattern of symptomatic or asymptomatic bilateral pulmonary fibrosis on chest X-ray or CT scan;
- _ Typically observed in a subject over the age of 60, who is most often a man.

A comparable clinical picture can be observed more rarely in middle-aged adults (age 40–60), especially in case of family history of pulmonary fibrosis or clinically undiagnosed CTD [10].

Radiological and histopathological criteria for a positive diagnosis IPF is a fibrosing ILD of unknown cause, associated with an UIP pattern on the CT scan (Table 3) and/or histopathological examination (Table 4) [10]. Indeed, according to international guidelines, the positive diagnosis of IPF is based on the following combination of criteria [10,21]:

1. Ruling out other possible causes of ILD (e.g., environmental exposure at work or at home, CTD or vasculitis, drug toxicity),
And one of the following two criteria:
 2. UIP pattern on the CT scan (Table 3),
- Or
3. Specific combination of CT and histopathological patterns.

Examples of CT patterns are shown in Figs. 1 to 6, and examples of histopathological patterns in Figs. 7 to 10.

A diagnostic algorithm is shown in Fig. 11. When no lung biopsy is performed, the diagnosis may be made in the presence of idiopathic ILD (in the absence of any associated extra-respiratory manifestation and etiological context), if the high-resolution chest CT scan shows an UIP pattern (Fig. 1).

When a lung biopsy is performed, the diagnosis of IPF is made based on a combination of the chest CT scan pattern and the lung biopsy showing an UIP pattern (Fig. 12). In all cases, it is essential to take into account the clinical context, because it determines a priori the likelihood of a diagnosis of IPF, the potential usefulness and feasibility of a biopsy, and in some cases allows proposing, within the context of a multidisciplinary discussion (MDD), a "provisional working diagnosis" to guide the management (see dedicated section). These criteria are almost identical to those recently proposed by the Fleischner Society [22].

In all cases, the other forms of ILD should be ruled out to make the diagnosis of IPF, in particular those related to an environmental, including occupational, exposure, a drug or a systemic disease, especially CTD.

It should be noted that the reproducibility of the identification of honeycombing, even by radiologists expert in ILD, is relatively low, in particular when emphysema is present [23]. Similarly, the interradiologist reproducibility to identify an UIP pattern is moderate [24].

Table 3
Classification of the patterns observed on high-resolution chest CT scans (adapted from Raghu et al. [10]).

UIP pattern	Probable UIP pattern	Indeterminate for UIP pattern	Pattern suggestive of another diagnosis
Subpleural and basal (sometimes diffuse) predominance Distribution often heterogeneous (areas of normal lung interspersed with fibrosis), occasionally diffuse, may be asymmetrical	Subpleural and basal predominance; Distribution often heterogeneous (areas of normal lung interspersed with reticulation and traction bronchiectasis/bronchiolectasis)	Subpleural and basal predominance ("early UIP pattern") Distribution of fibrosis suggesting no specific cause ("truly indeterminate pattern")	Peribronchovascular predominance Perilymphatic predominance Predominance in the mid and upper regions of the lung Subpleural sparing
Honeycombing with or without peripheral traction bronchiectasis and bronchiolectasis Presence of irregular thickening of interlobular septa Usually superimposed with a reticular pattern, mild ground glass opacities May have pulmonary ossification	Reticular pattern with peripheral traction bronchiectasis and bronchiolectasis May have mild ground-glass opacities Absence of subpleural sparing	Discrete reticulations; mild ground-glass opacities or distortion may be present ("early ILD pattern") Pattern of fibrosis suggesting no specific cause ("truly indeterminate pattern")	Evidence suggesting another diagnosis, including: Abnormal CT scan findings o Cysts o Extensive mosaic pattern* or three-density pattern** o Predominant ground-glass opacities o Diffuse micronodules o Centrilobular nodules o Nodules o Consolidations • Others o Pleural plaques (asbestosis should be suggested) o Esophageal dilation (connective tissue disease should be suggested) o Distal clavicular erosions (rheumatoid arthritis should be considered) o Significant adenomegaly (other causes should be considered) o Pleural effusions, pleural thickening (connective tissue disease or drug-induced ILD should be considered)

UIP: usual interstitial pneumonia; ILD: interstitial lung disease.

*Suggestive of hypersensitivity pneumonitis.

**Pattern previously described as the "head cheese sign", a terminology that has not been adopted internationally.

For patients with a probable UIP pattern on the CT scan, lung biopsy is not mandatory to make the diagnosis of IPF with a high level of confidence if the MDD concludes that there is no more likely differential diagnosis, and that the clinical context is highly suggestive (e.g., male gender, age over 60 and a history of smoking). However, a biopsy is recommended by international guidelines, when it can be performed without increased risk, if these conditions are not met [25]. Monitoring the evolution is important to confirm or rule out the diagnosis of IPF in all cases where it is initially made only as a provisional working diagnosis, in particular if no lung biopsy was performed.

Table 4
Idiopathic pulmonary fibrosis: histopathological criteria (from Raghu et al. [10]).

UIP pattern	Probable UIP pattern	Indeterminate for UIP pattern	Pattern suggestive of another diagnosis
Dense fibrosis with architectural distortion (destructive scarring and/or honeycombing)	Some histological features from column 1 are present but to an extent that precludes a definite diagnosis of UIP	Fibrosis with or without architectural distortion, with features favoring either a pattern other than UIP or features favoring UIP secondary to another cause*	Features of other histologic patterns of idiopathic interstitial pneumonias (e.g., absence of fibroblastic foci or loose fibrosis) in all biopsies
Predominant subpleural and/or paraseptal distribution of fibrosis	And	Some histological features from column 1 but with other features suggesting an alternative diagnosis†	Histological findings indicative of other diseases (e.g. HP, Langerhans cell histiocytosis, sarcoidosis, LAM)
Patchy involvement of lung parenchyma by fibrosis Fibroblastic foci Absence of features to suggest an alternate diagnosis	Absence of features to suggest an alternative diagnosis Or Honeycombing only		

IPF: idiopathic pulmonary fibrosis; LAM: lymphangiomyomatosis; HP: hypersensitivity pneumonitis; UIP: usual interstitial pneumonia; idiopathic ILD: idiopathic interstitial lung disease.

*Granulomas, hyaline membranes (different from those associated with acute exacerbations of IPF, which may reveal the disease in some patients), significant bronchiocentric involvement, areas of interstitial inflammation without fibrosis, marked chronic pleural fibrosis, organizing pneumonia. These findings are not always obvious or easy to identify by an untrained examiner, and their presence should be specifically investigated.

†The findings that should alert on the possibility of another diagnosis are the presence of inflammatory infiltrates located remote from the honeycombing, areas of lymphoid hyperplasia that may include secondary germinal centers, and a particular distribution of the involvement centered on the bronchioles, that may include extensive peribronchiolar metaplasia.

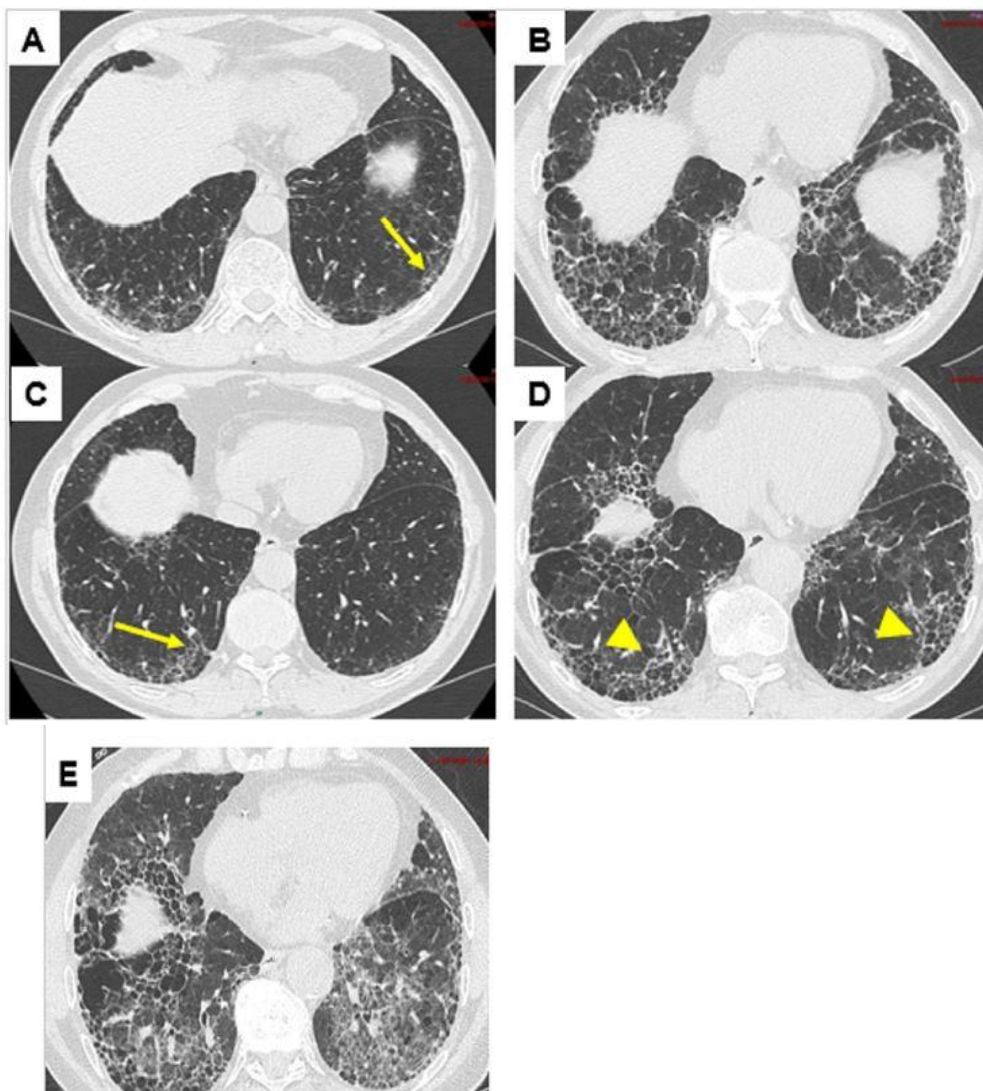


Fig. 1. Usual interstitial pneumonia (UIP) pattern on the chest CT scan. A, C: probable UIP pattern, with predominantly subpleural and basal reticular opacities, traction bronchiolectasis (arrows), in the absence of any sign incompatible with this diagnosis. B, D: UIP pattern on the follow-up CT scan, with predominantly subpleural and basal reticular opacities, honeycombing (arrowheads), traction bronchiectasis, in the absence of any sign incompatible with this diagnosis. E: chest CT scan performed at the time of an acute exacerbation of fibrosis, showing a ground-glass appearance in addition to pre-existing opacities.

Methods for performing and contribution of the chest CT scan

A high-resolution chest CT scan is mandatory to confirm the diagnosis of IPF. It allows optimally assessing the topography of the lesions. The technical conditions for performing this examination are presented in [Table 5](#) [10,26]. The radiological diagnosis of IPF is essentially based on images obtained by volume chest CT scan. Its yield in detecting all anomalies, even subtle or focal, is superior to the sequential acquisitions.

Cardinal signs of IPF on the chest CT scan

Honeycombing consists of small cystic air spaces with a homogeneous diameter (3–10 mm, sometimes up to 25 mm) and thick walls. It is usually associated with fine reticulations and subpleural traction bronchiectasis or bronchiolectasis [27] ([Fig. 1](#), [Fig. 2](#)). Honeycombing ([Fig. 1](#), photographs B and D) often corresponds to the stacking of multiple layers of subpleural cysts, but a single-layer arrangement is possible, and it can then be difficult to differentiate honeycombing from paraseptal emphysema or traction bronchiolectasis [23]. The inter-observer agreement level in the identification of honeycombing is low [28,29], the disagreements most often concern other subpleural lesions leading to comparable patterns (e.g., traction bronchiolectasis, paraseptal emphysema or subpleural cysts) [29]. Using sagittal or coronal CT reconstructions may be helpful.

Traction bronchiectasis and bronchiolectasis ([Fig. 2](#), photographs C and D) are a key feature of pulmonary fibrosis, the appearance of which varies from a discreet irregularity in the walls of the bronchi/ bronchioles to marked dilations of pseudo-varicose veins [30–33]. They are usually peripheral/subpleural, and associated with honeycomb cysts [10]. Peripheral bronchiolectasis should be present to discuss a probable UIP pattern on the CT scan.

Ground-glass opacities are defined by areas of increased lung parenchyma density without obliterating the bronchial walls and pulmonary vessels [27]. It is important to be able to distinguish "pure" ground-glass opacities from those superimposed on a finely reticulated pattern [34]. The former are uncommon in UIP and their presence in a patient with IPF should suggest an acute exacerbation ([Fig. 1](#) image E) [35,36]. In contrast, ground-glass opacities superimposed on a finely reticulated pattern ("texture" or "heterogeneous" ground glass) are suggestive of parieto-alveolar fibrosis and may be observed in IPF in the absence of acute exacerbation. The coexistence of bronchiectasis/bronchiolectasis allows differentiating these two situations [34].

In about 50% of cases, the CT scan [21,37] shows a characteristic UIP or probable UIP pattern, allowing making the diagnosis of IPF if the examination is performed by a pulmonological and radiological team experienced in the field of ILD and in a compatible context. In other cases, imaging is not characteristic and the diagnosis cannot be confirmed without performing a lung biopsy. Sometimes a pattern suggestive of another diagnosis on the CT scan may correspond to true UIP on the lung biopsy.

Table 5

Technical guidelines for the initial CT workup of interstitial lung disease [10,26].

-
1. Non-contrast CT scan examination
 2. Volume acquisition of the chest with selection of the following parameters
 - Sub-millimeter collimation
 - Shortest rotation time
 - Highest pitch
 - Adaptation of the kilovoltage and milliamperage to the patient's morphotype:
 - Classically: 120 kV and ≤ 240 mAs;
 - Low kilovoltage with milliamperage adjustment in lean patients
 - Use of techniques to reduce irradiation doses during acquisition (automated milliamperage modulation)
 3. Thin-section reconstruction (≤ 1.5 mm)
 - Contiguous or overlapping sections
 - Use of high-spatial-frequency algorithms
 - Use of iterative reconstruction algorithms
 4. Number of acquisitions
 - Decubitus: end of deep inspiration (volume mode)
 - Decubitus: expiration (volume or sequential mode)
 - Prone: end of inspiration (volume or sequential mode)
 5. Dosimetric guidelines
 - 1–3 mSv (reduced dose examinations)
 - Prohibit "ultra-low dose" examinations (< 1 mSv)
-

Classification of CT patterns

International guidelines recommend to classify the CT images into four distinct categories, referred to as "UIP pattern" (Fig. 1), "probable UIP pattern" (Figs. 2 and 3), "indeterminate for UIP pattern" (Figs. 5 and 6), and "pattern suggestive of another diagnosis" (Fig. 13) [10]. The terms "aspect", "appearance", or "pattern" are synonymous.

In an idiopathic context, the positive predictive value of an UIP pattern on the CT scan is of 90–100% [38–41]. However, not all patients with IPF have a typical UIP pattern on the CT scan [40–42].

Usual interstitial pneumonia pattern

On the CT scan, IPF is characterized by an UIP pattern. Images showing basal and subpleural honeycombing are needed to confirm the diagnosis of UIP [10] (see Fig. 1, photographs B and D). It may be associated or not with peripheral traction bronchiectasis or bronchiolectasis (a few millimeters from the pleura; see Fig. 2, photographs C and D). UIP predominates in the subpleural and basal regions, although a lesser involvement of the upper lobes may be seen. More rarely, the cranio-caudal distribution of the lesions appears relatively uniform [43,44].

The involvement may be asymmetrical in up to 25% of cases [45] and UIP may be associated with mediastinal lymphadenopathy [46], with a poor prognosis [47]. Ground-glass opacities may be observed, but they are not predominant and are usually superimposed on discrete reticulations. More rarely, calcified, ossified micronodules are found within areas of fibrosis; this pattern, referred to as dendriform ossification when extended, is more common in UIP (29%) than in other fibrosing pulmonary diseases [48]. A pattern of pleuroparenchymal

fibroelastosis at the apex is sometimes observed [49]. The permissible proportions of these rare or atypical patterns are not well established, as cases may be classified as having UIP/IPF during the MDD. UIP may be revealed by an acute exacerbation or coexist with emphysema.

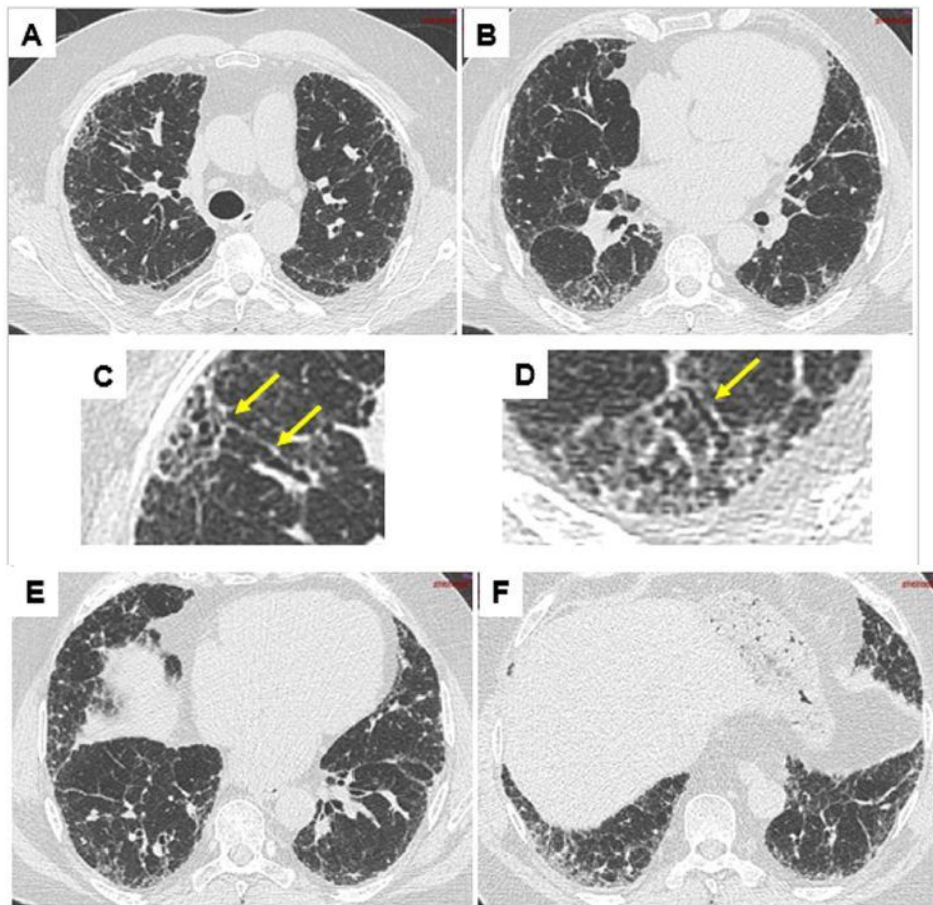


Fig. 2. Probable usual interstitial pneumonia pattern on the CT scan. Presence of predominantly subpleural and basal reticular opacities, traction peripheral bronchiolectasis, in the absence of any sign incompatible with this diagnosis, but without honeycombing. C, D: enlargement of A and B showing traction peripheral bronchiolectasis (arrows).

7

Probable usual interstitial pneumonia pattern

In the previous version of the international guidelines, a peripheral reticular pattern predominating at the lung bases but not associated with honeycombing features on chest x-ray was considered a "possible UIP pattern" [21]. However, recent studies have shown that the probability of observing a histopathological picture of UIP is very high in patients with a "possible UIP" pattern on the CT scan according to the 2011 criteria [50] in the clinical context of IPF [44,51–54]. Therefore, the "possible UIP" category has been removed, and the patterns previously classified as "possible UIP" are now classified as "probable UIP pattern" or "indeterminate for UIP pattern". The peripheral reticular pattern predominating at the lung bases associated with peripheral traction bronchiectasis/bronchiolectasis should be considered "probable UIP" [10] (Figs. 2 and 3). As in UIP, the ground-glass opacities may be seen in probable UIP, but they are not predominant.

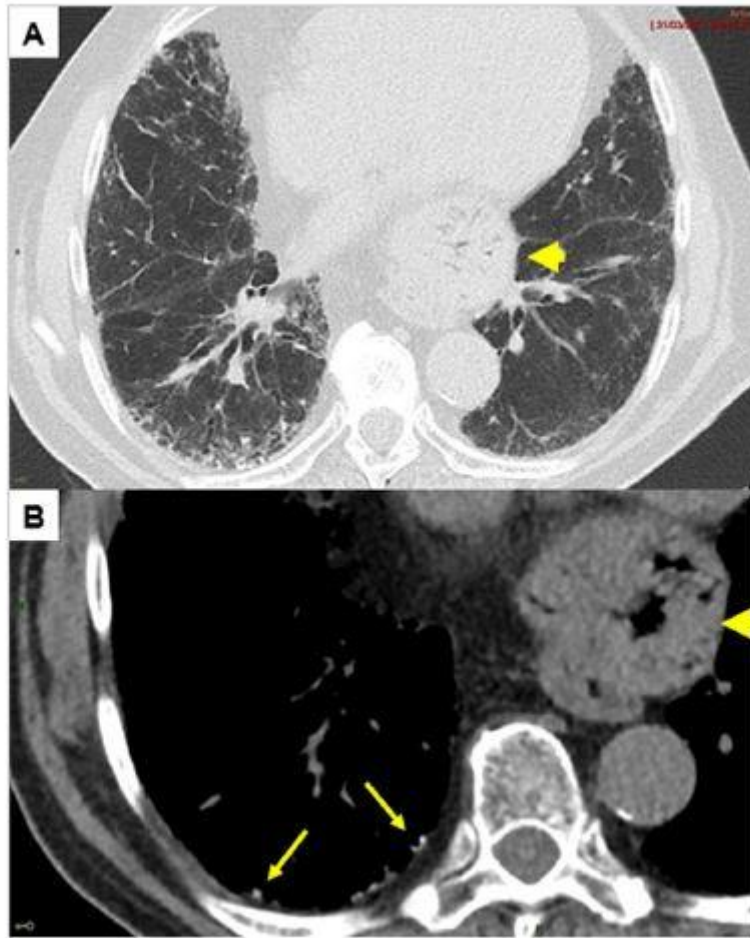


Fig. 3. Peripheral microcalcifications (arrows) in a patient with a probable usual interstitial pneumonia pattern on the CT scan. A: parenchymal windows. B: mediastinal window. Also note a large hiatal hernia (arrowheads).

The final diagnosis during the MDD will be IPF in the vast majority of patients with a "probable UIP" pattern on the CT scan in a suggestive clinical context, once the histopathological results and the other criteria have been taken into account, and especially when the lesions are more extensive.

Indeterminate for usual interstitial pneumonia pattern

It is now established that atypical radiological patterns are observed in about 30% of subjects with a histopathological picture of UIP [55]. Therefore, fibrosis that is not associated with criteria for UIP or a "probable UIP" pattern on the CT scan, and without signs suggesting clearly another diagnosis, should be classified as indeterminate for UIP patterns. For example, this may be lesions distributed without subpleural predominance and apico-basal gradient, or the coexistence in the same patient of several different patterns (Figs. 5 and 6).

The indeterminate for UIP category also includes a subgroup of patients in whom the CT scan shows very limited discrete subpleural reticulations, without definite signs of fibrosis, suggesting early UIP.

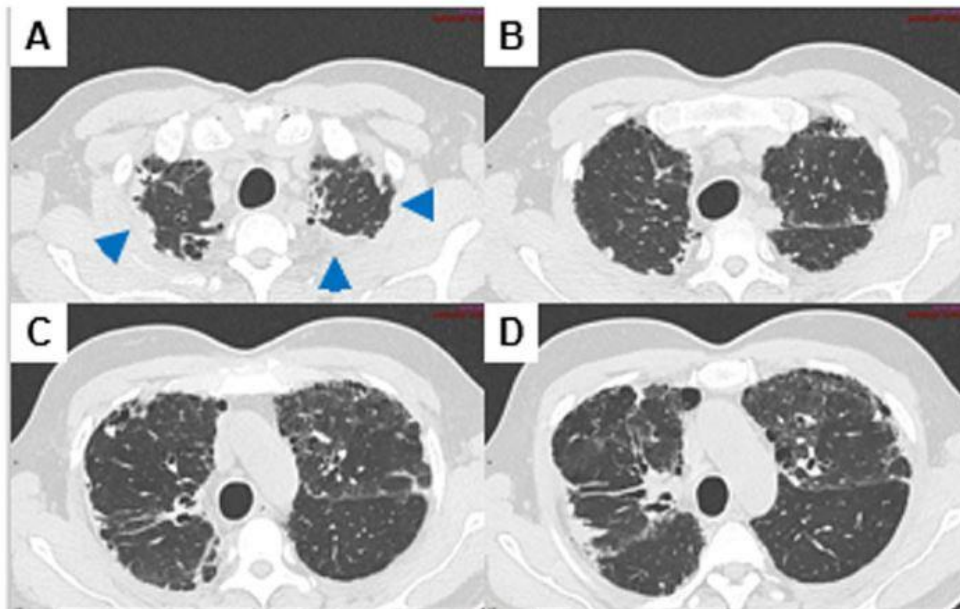
In this context, the presence of Velcro crackles should be investigated on auscultation and the fact that the subpleural opacities do not represent gravity-dependent atelectasis should be checked on the CT scans acquired with the patient placed in prone position and at maximum inspiratory apnea.

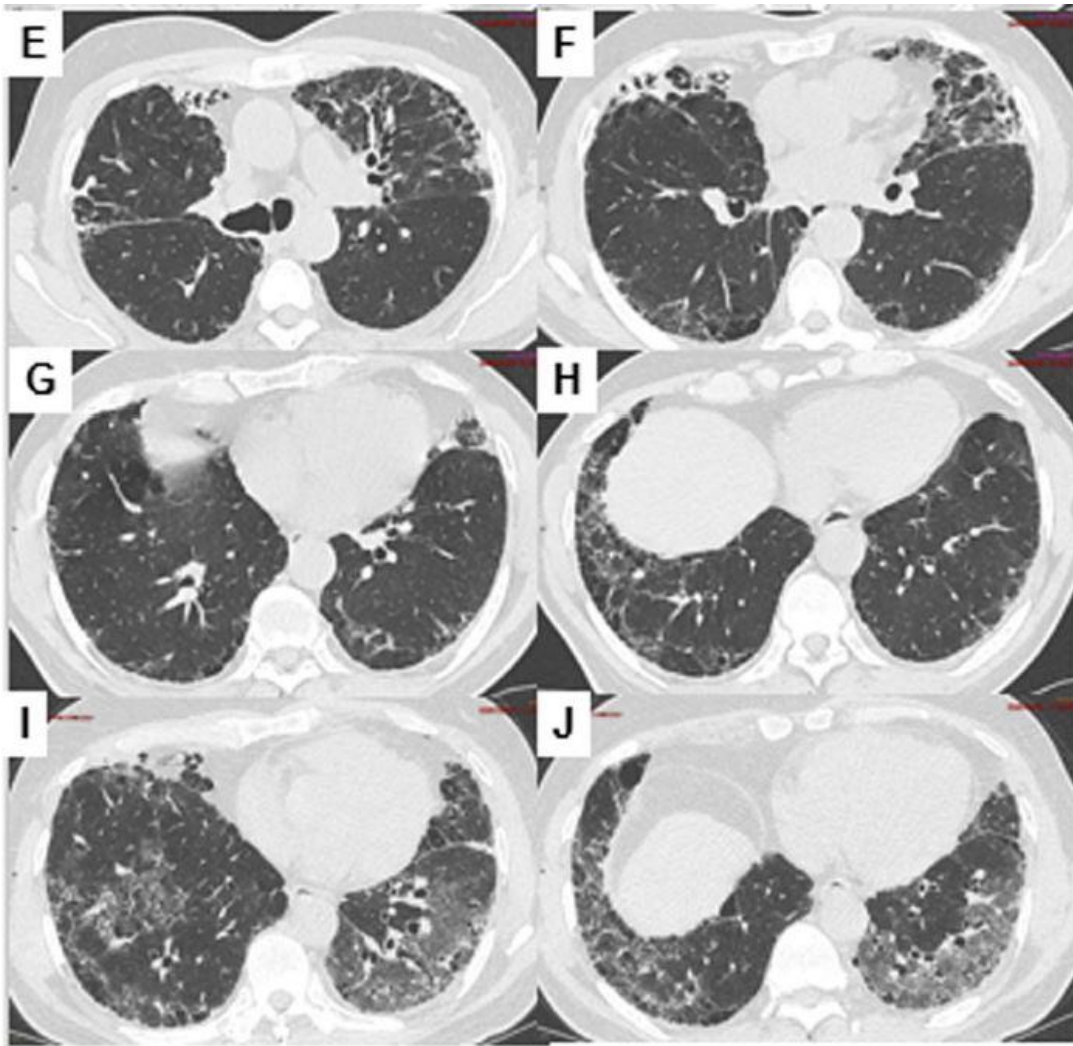
Patterns suggestive of another diagnosis

Some fibrosing lung lesions are clinically suggestive of IPF while associated with CT features suggestive of another diagnosis (Fig. 13). They may include a bronchocentric distribution of fibrosis in the upper lobes or a diffuse mosaic pattern, including a three-density pattern, strongly suggestive of hypersensitivity pneumonitis (HP) [56], a fibrotic retraction from the hilum to the superior and posterior region suggestive of sarcoidosis, extended ground-glass opacities sparing the subpleural areas, suggestive of fibrosing non-specific interstitial pneumonia (NSIP).

More rarely, the CT scan shows an UIP or probable UIP or indeterminate for UIP pattern, but other findings of the assessment are suggestive of another diagnosis.

Fig. 4. Pleuroparenchymal fibroelastosis pattern at the apex (A–D, arrowheads), and probable usual interstitial pneumonia pattern at the lung bases (E–H) on the CT scan (parenchymal window). I, J: presence of additional ground-glass opacities during an acute exacerbation of fibrosis.





CT patterns associated with acute exacerbations

On the CT scan, patients with acute exacerbations show bilateral pure ground-glass opacities, possibly associated with consolidations, superimposed on the previous features of fibrosis (Fig. 1, photograph E). Such features are highly suggestive of an acute exacerbation and, if no prior CT images are available, they may support the diagnosis of underlying IPF if the clinical context allows it.

Guideline 1. It is recommended to make the diagnosis of IPF in patients with an usual interstitial pneumonia pattern on the CT scan, including in particular the presence of honeycombing, in an appropriate clinical context, after ruling out other causes of usual interstitial pneumonia.

Place of lung biopsy

The diagnosis of IPF may be made when a radiological (Table 3) and/or histopathological pattern of UIP (Table 4) is present in an idiopathic context. When the radiological pattern is not that of UIP, the diagnosis of IPF can only be made if the combination of the radiological and histopathological patterns discussed during the MDD concludes to UIP [21].

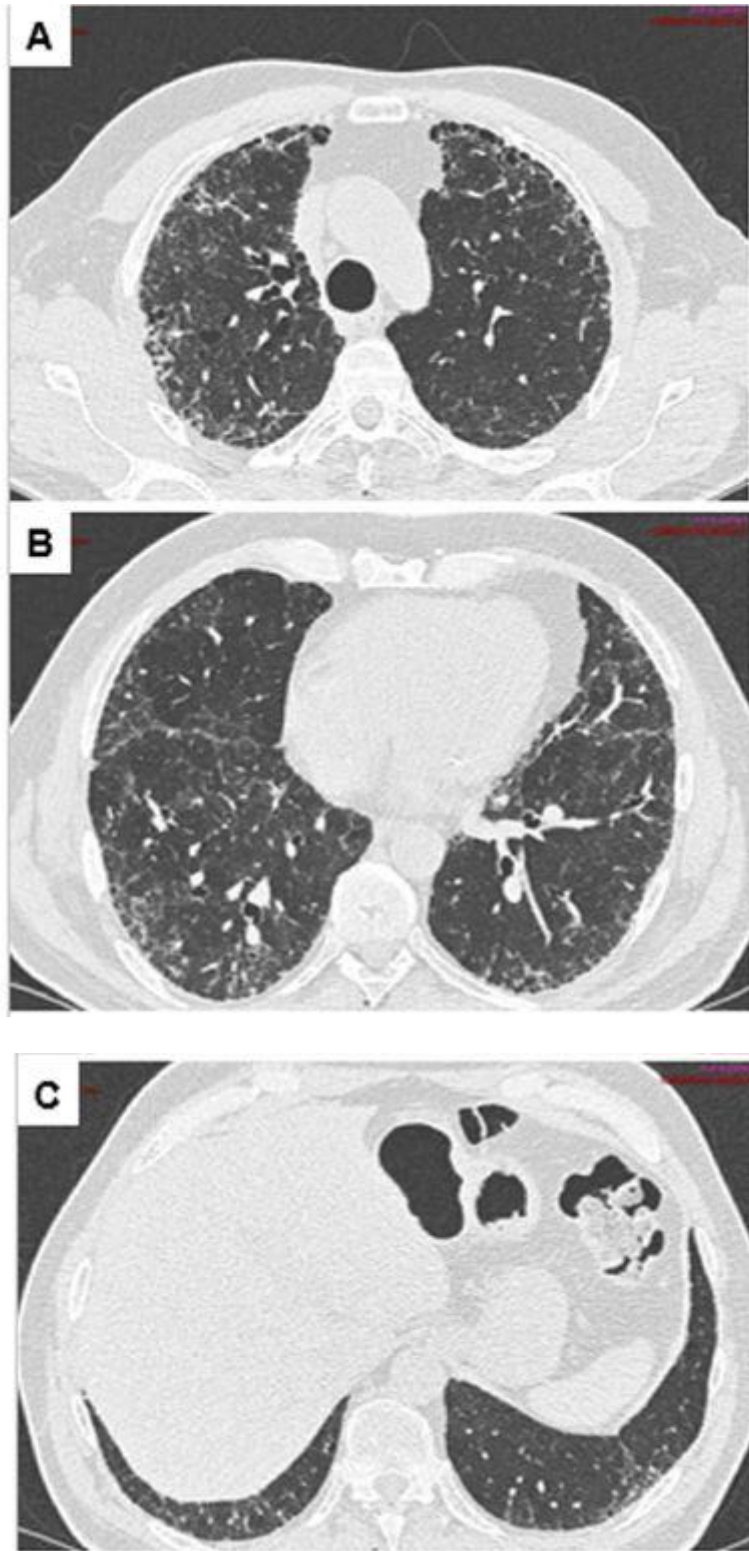


Fig. 5. Indeterminate for usual interstitial pneumonia (UIP) pattern on the CT scan. Presence of reticular opacities and traction bronchiectasis, absence of honeycombing. The lesions are not distributed as in UIP (absence of apico-basal gradient).

Table 6
Proposed contraindications to video-assisted thoracoscopic lung biopsy.

- Rapid worsening of the disease (unplanned biopsy)
- Low respiratory reserve (threshold values in the following range: FVC <60–70%, DLco <35–40%)
- Oxygen therapy at rest
- Pulmonary hypertension
- Significant or multiple comorbidities
- Physiological age >75 years
- Immunosuppression

FVC: forced vital capacity, DLco: diffusing capacity for carbon monoxide.

Table 7
Lung biopsy conditions in case of suspected idiopathic pulmonary fibrosis.

Place	Surgical center with video-assisted thoracoscopic lung biopsy activity for interstitial lung disease, and pathologist experienced in the diagnosis of interstitial lung disease
Technique	Video-assisted surgery or cryobiopsy (transbronchial forceps biopsies are excluded)*
Samples	Deep, in several lobes**, by avoiding lingula and middle lobe ends, as well as the areas of severe honeycombing destruction.

*To obtain a biopsy of sufficient size.

**Lesions may differ depending on the lobes.

Video-assisted thoracoscopic lung biopsy

Conditions for performing video-assisted thoracoscopic lung biopsy The decision to propose video-assisted thoracoscopic (VATS) lung biopsy is left to the clinicians' discretion at the end of the MDD, and should take into account the assessment of the potential risk of the biopsy [57,58], the age, the presence of comorbidities, the stage, pulmonary function tests (PFT), the progression of ILD, and potential therapeutic consequences. It should not be performed in an emergency situation in a patient with progressive ILD [59] and after the age of 75 [60]. The contraindications are shown in Table 6 and the technical conditions in Table 7. The biopsy should be performed and analyzed by an experienced team (pulmonologist, thoracic surgeon, pathologist).

The biopsy sites (at least two in two different lobes) are discussed beforehand with the radiologist and the surgeon. The biopsy may confirm the diagnosis of UIP or show other patterns such as NSIP or HP. The biopsy also allows performing a mineralogical analysis.

Diagnostic yield

VATS lung biopsy is the reference method in patients who can tolerate single-lung ventilation. Surgical biopsy via thoracotomy is no longer performed. The risks of surgical lung biopsy may exceed its benefits in patients with respiratory failure or significant comorbidities. The decision to perform or not the biopsy should therefore be made on a case-by-case basis, depending on the overall clinical condition of the patient [10]. It is important to

collect multiple fragments in two or three different lobes because the histopathological findings may vary from one lobe to another, or even show discordant features (e.g., coexistence of UIP features in one lobe and fibrotic NSIP in another lobe; the prognosis is then that of UIP, and the diagnosis that of IPF).

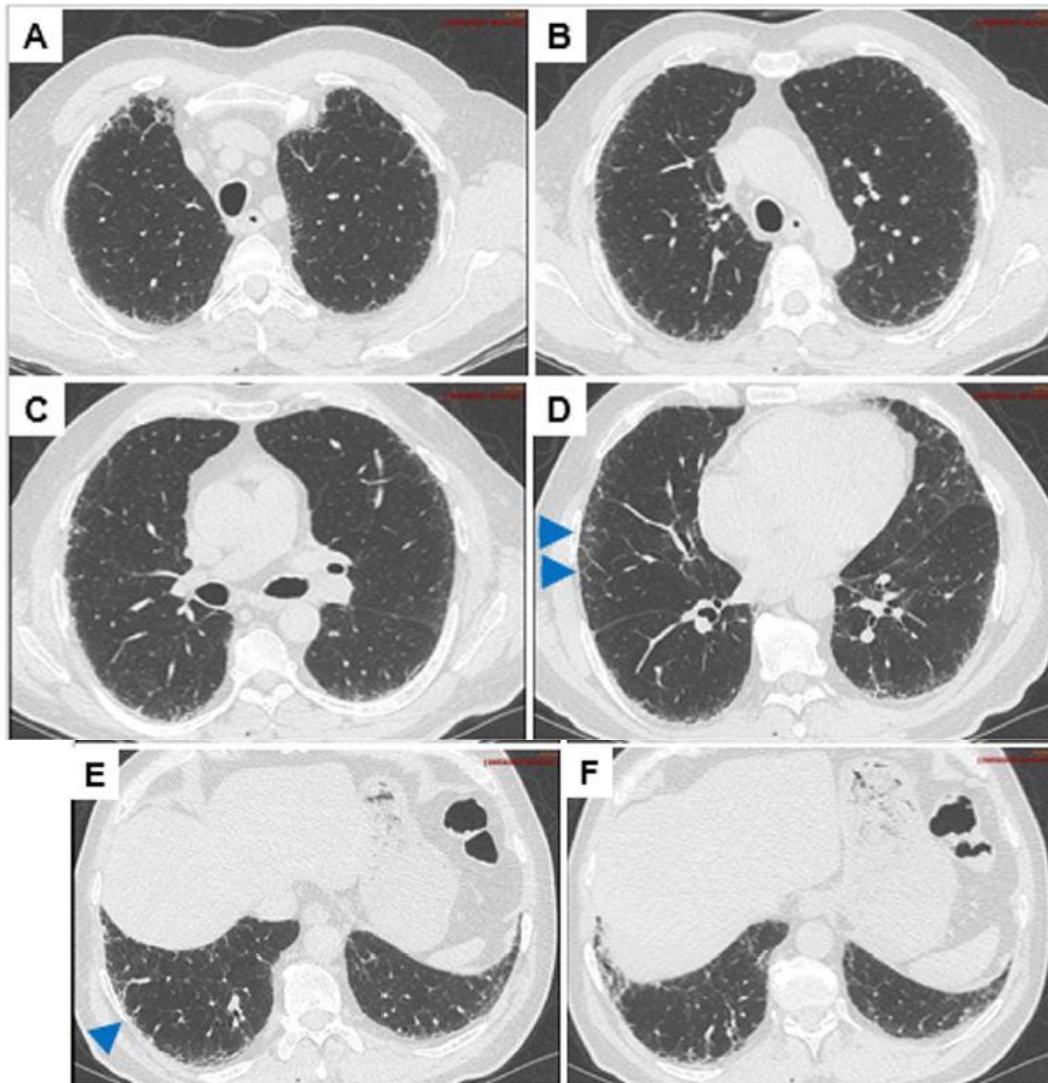


Fig. 6. Indeterminate for usual interstitial pneumonia (UIP) pattern on the CT scan suggestive of early UIP. Presence of predominantly subpleural and basal reticular opacities (arrowheads), in the absence of any sign incompatible with this diagnosis and without honeycombing.

No published study has compared the outcome of patients with suspected IPF and a non-UIP radiological pattern, who underwent or not VATS lung biopsy [10]. However, 26 studies have assessed the diagnostic yield of VATS lung biopsy based on the conclusions of the MDDs [61–86]. All of these studies included patients with ILD of unknown etiology, without excluding those who showed an UIP pattern on the chest CT scan. The yield, sensitivity and specificity of VATS lung biopsy would be 92.7%, 91% and 58%, respectively [87].

The meta-analysis of the unweighted data indicates that VATS lung biopsy provides usable samples in 100% of cases, which is probably not the case in daily practice [10]. The proportion of VATS lung biopsy allowing making an accurate diagnosis (i.e. the diagnostic yield of the method) is high - 88.2% of cases on average (26 studies) - the result being

considered unclassifiable in a minority of cases (11.8%; 26 studies). The final diagnosis is IPF in about one-third of cases (31.9%), and the examination allows identifying many other potentially treatable etiologies of ILD (infection, sarcoidosis, HP, eosinophilic pneumonia, lymphangiomyomatosis, cryptogenic organizing pneumonia, vasculitis) [10].

The iatrogenic risk is low if the disease is at an early stage and if emergency biopsies are excluded. The initial hospital mortality is 1.7%, and then reaches 2.4% and 3.9% at 30 days and 90 days, respectively [57]. Some deaths are probably due to the progression of the underlying disease because the mortality specifically associated with the procedure is lower (mean: 1.7%). No deaths have been observed in many studies, suggesting that the procedure-associated mortality may depend on variables specific to the operating center, such as the selection of eligible patients. Other complications observed include exacerbations (mean: 6.1%), bleeding (0.8%), severe hemorrhage (0.2%), persistent air leak (5.9%), respiratory infections (6 0.5%), neuropathic pain (4.5%), and delayed healing (3.3%) [10].

The actual effect of VATS lung biopsy can only be estimated with a very low level of confidence due to the experimental design of the studies analyzed, the variable sample sizes and the risk of selection bias due to the inclusion of non-consecutive patients.

Overall, the risk/benefit ratio of VATS lung biopsy appears favorable in most patients with newly diagnosed ILD of uncertain etiology in whom the CT scan shows an indeterminate for UIP pattern of ILD or supports another diagnosis [10]. In addition, the confirmation of the diagnosis is associated with other benefits that are more difficult to quantify, related to the possibility of better specifying the prognosis, stopping diagnostic explorations and starting treatment adapted to the disease. In patients with a probable UIP pattern, the usefulness of the biopsy depends on the clinical probability of IPF [10].

However, since the benefit of VATS lung biopsy is not clearly demonstrated, the decision should be based on the conclusion of the MDD. On the other hand, in patients showing an UIP pattern on the CT scan, the risk/benefit ratio of VATS lung biopsy is clearly unfavorable: the probability of making a diagnosis other than UIP is low, and the contribution of VATS lung biopsy is limited to a confirmatory role [10].

Very often, VATS lung biopsy is not performed (contraindication, high iatrogenic risk, patient refusal) while the CT scan only shows an indeterminate for UIP pattern or a pattern suggestive of another diagnosis, or even a probable UIP pattern associated with a low clinical probability: it is then not possible to definitely diagnose IPF according to international guidelines [10]. If the diagnosis of IPF is the most likely, a provisional so-called "working" diagnosis is made, based on the decisions made during the MDD. It has been shown that clinicians make this working diagnosis in case of provisional diagnosis made with high confidence (estimated between 70% and 90%) [88].

Histopathological criteria for usual interstitial pneumonia

The characteristic histopathological criterion for UIP (Figs. 7–10) is the presence, on low magnification microscopy, of disseminated (sparse) areas of dense fibrosis that disorganizes the lung architecture, often taking a honeycomb microscopic appearance, and alternating with areas of preserved or less affected parenchyma [10].

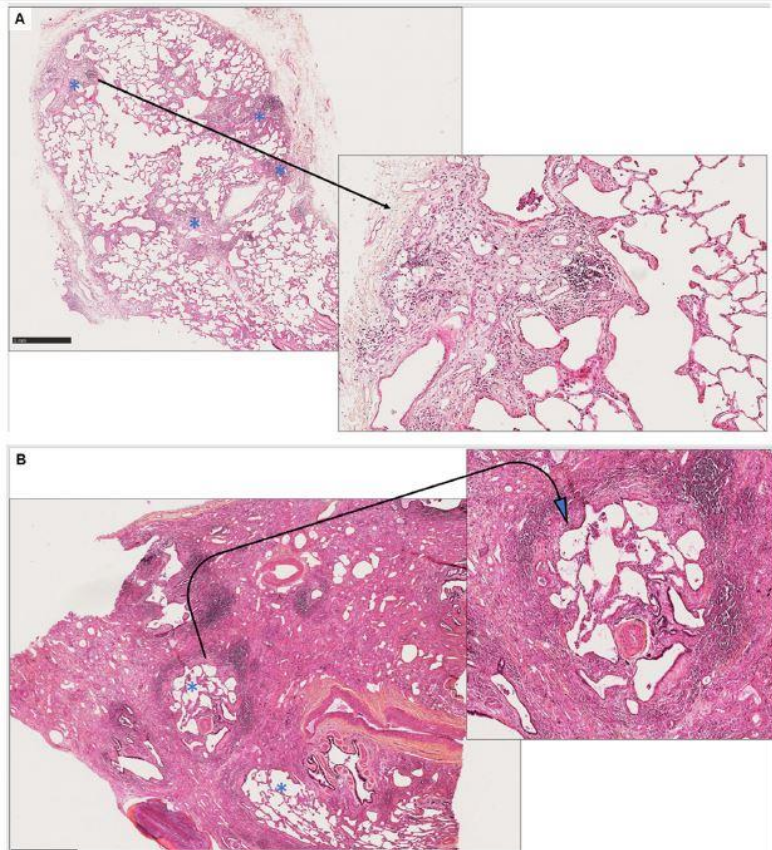


Fig. 7. Definite usual interstitial pneumonia pattern on the histopathological examination. A. Upper lobar biopsy: small fibrotic growths under the pleura and around a septal wall (asterisks). Insert: at higher magnification, it is a recent conjunctive matrix (not yet collagenized), in the presence of moderate mixed inflammation. B. Lower lobar biopsy (same patient): the alveolar architecture is massively destroyed by diffuse collagenous fibrosis. Persistence of two smaller pulmonary lobules (asterisks), one of which is surrounded by a ring of recent fibrosis, itself surrounded by an inflammatory ring (insert).

Typically, the involvement predominates in the subpleural and paraseptal parenchyma. Inflammation is usually mild, consisting of disseminated lymphoplasmacytic infiltrates, associated with hyperplasia of type 2 pneumocytes and bronchial epithelium. The fibrotic areas are mainly composed of dense collagen deposits, and disseminated convex subepithelial foci of fibroblasts and myofibroblasts (called fibroblastic foci) are also usually observed. The honeycomb microscopic appearance is that of fibrotic air cysts often lined by bronchiolar epithelium and filled with mucus and inflammatory cells. Metaplasia of interstitial smooth muscle fibers is usually observed in areas of fibrosis and in honeycombing. The UIP pattern may be asserted when all these anomalies are observed, in particular honeycombing, the presence of which is however not mandatory if all the other typical features are present.

UIP should be differentiated from NSIP, that is characterized by mutilating diffuse fibrosis with a uniform appearance and a comparable time to onset in different areas. Fibroblastic foci are exceptional in NSIP. Honeycombing, when present, is usually moderate. Inflammation is variable in intensity, but usually more severe than in UIP. The sparing of the subpleural spaces, the presence of an inflammatory process in the bronchioles and/or increased fibrosis around the bronchioles, the presence of repair buds of organizing pneumonia, commonly observed in NSIP, are useful findings to rule out the diagnosis of UIP.

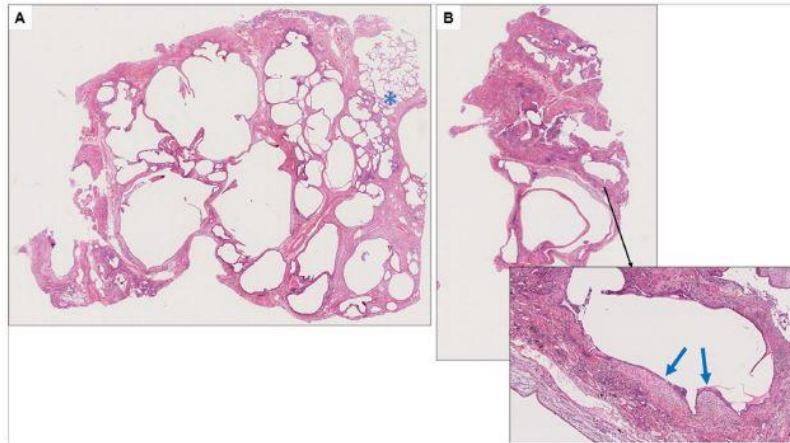


Fig. 8. Usual interstitial pneumonia pattern on the histopathological examination. A. Lung biopsy of a honeycomb remodeling area; distended alveolar cavities are framed by mutilating collagenous fibrosis. Top right (asterisk): persistence of a small preserved alveolar area in abrupt transition with this area of fibrotic destruction. B. A biopsy sample taken in the vicinity shows a recent fibroblastic focus (arrows) leaning against a honeycomb cavity, showing the persistence of a fibrotic growth (insert).

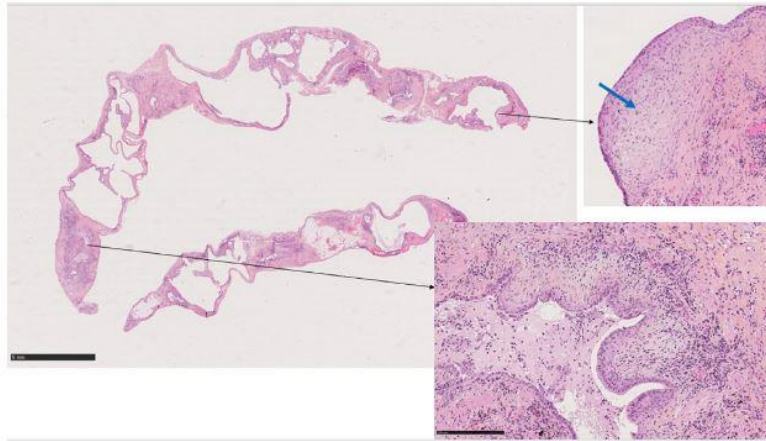


Fig. 9. Probable usual interstitial pneumonia pattern on the histopathological examination. The biopsy is performed in a narrow strip of lung parenchyma destroyed by fibrosis, with honeycomb remodeling. No area of healthy alveolar parenchyma is represented. Focal presence of foci of recent fibrosis similar to recent fibroblastic foci (arrow) placed against a honeycomb cavity and around a distal airway (inserts). The small size of the samples taken from a single lobe justifies a close comparison with the clinical and CT scan presentation.

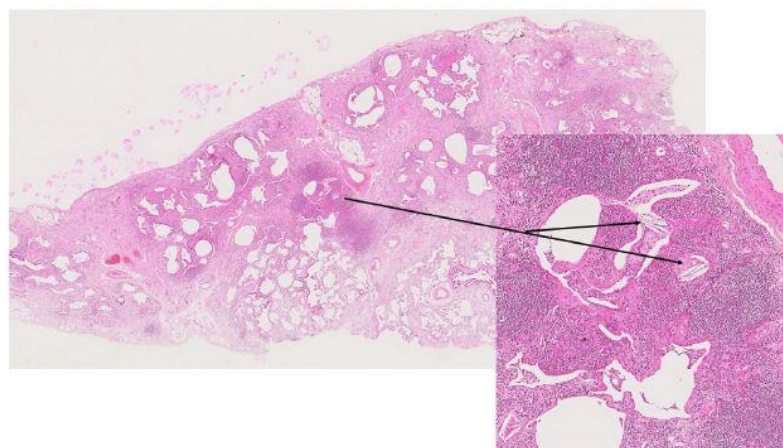


Fig. 10. Indeterminate for usual interstitial pneumonia (UIP) pattern on the histopathological examination. This histological section shows massive lung destruction by an area of predominantly subpleural fibrosis, with honeycombing. Attention is drawn to a cluster of dense lymphocyte inflammation around a fragmented bronchiole (insert). The presence of two giant cells with a fatty acid and cholesterol crystal resorption activity (arrows) around such bronchiolar inflammation is sufficient to rule out UIP. The diagnosis of fibrotic hypersensitivity pneumonitis was made.

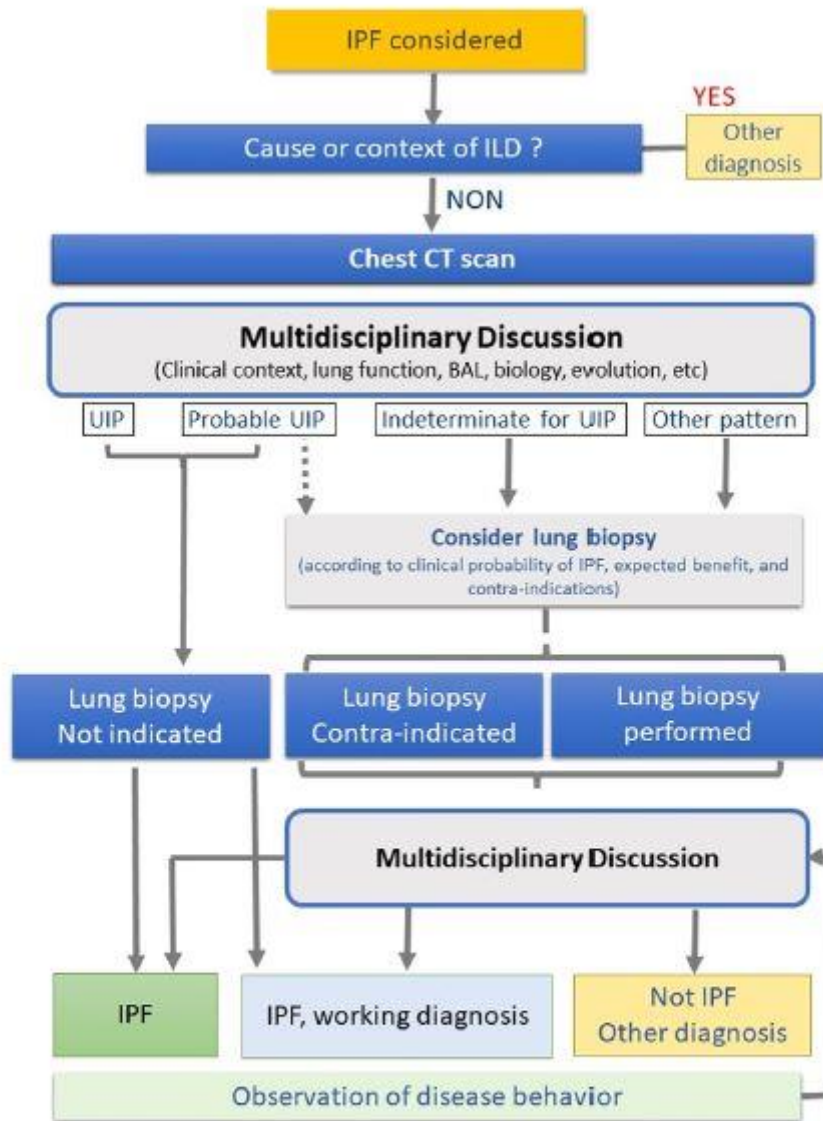


Fig. 11. Diagnostic algorithm in a patient with suspected idiopathic pulmonary fibrosis. IPF: idiopathic pulmonary fibrosis; UIP: usual interstitial pneumonia; ILD: interstitial lung disease; CT: computed tomography; provisional working diagnosis: see subchapter "Diagnosis validation".

Some characteristic histopathological features may help to confirm or rule out other differential diagnoses such as HP (e.g., distribution centered on the bronchioles, lymphocytic bronchiolitis, extensive peribronchiolar metaplasia, poorly delineated non-necrotizing granulomas of peribronchiolar interstitial tissue), an acute exacerbation of IPF, or acute interstitial pneumonia (hyaline membranes), a scarring form of fibrosing cryptogenic organizing pneumonia (COP) (predominance of the organizing pneumonia pattern), pneumoconiosis (e.g., asbestosis, significant dust spots, silicotic nodule), sarcoidosis (marked presence of well-delineated non-necrotizing epithelioid granulomas), interstitial fibrosis associated with smoking (extensive respiratory bronchiolitis and subpleural and/or peribronchiolar eosinophilic collagen deposition with low cellular infiltration, without architectural distortion), and pleuroparenchymal fibroelastosis (predominant subpleural and intra-alveolar fibrosis with elastosis and visceral pleural fibrosis predominantly in the upper areas).

Table 8
Transbronchial cryobiopsy: formal and relative contraindications (from Hetzel et al. [94]).

-
- Absolute: high hemorrhagic risk
- Abnormal blood clotting
 - Deep thrombocytopenia*
 - Treatment with anticoagulants or antiplatelet agents (clopidogrel and other thienopyridines)
- Relative:
- Aspirin treatment
 - Pulmonary hypertension**
 - Severe respiratory functional impairment***
-

*Platelets $< 50 \times 10^9/L$.

**Systolic pulmonary arterial pressure > 50 mmHg on ultrasound.

***FVC $< 50\%$ and/or DLco $< 35\%$ of predicted values.

The specificity of these features is variable, ranging from patterns strongly supporting a differential diagnosis to much less suggestive patterns, the significance of which should be compared with the data of the clinical, radiological and biological workup during the MDD [10].

Transbronchial lung cryobiopsy

Standardized methods for the relatively recent transbronchial lung cryobiopsy (TBCB) technique have been proposed in 2018 by an international expert consensus, based on a systematic literature review [94]. TBCB aims to provide a minimally invasive alternative to surgical biopsy [95], with comparable indications (i.e., patients with a probable UIP or indeterminate for UIP pattern or a pattern suggestive of another diagnosis) [10].

The main complications of TBCB are pneumothorax and endobronchial hemorrhages, experienced by about 9% and 30% of patients, respectively (including moderate-to-severe hemorrhages in 4.9%) [85,87]. The risk of pneumothorax is increased in the presence of a histopathological UIP pattern, fibrotic reticulations on the CT scan and a biopsy site adjacent to the pleura. Hemorrhages can generally be controlled during fibroscopy (e.g., systematic deployment of an occlusion balloon) [94]. Persistent air leak is reported in 2% of patients [87]. The mortality rate at 30–60 days is 0.7% (compared to 1.7% after VATS lung biopsy) [87]. Other authors report a higher mean mortality rate (2–2.7%) [10,96]. Indeed, the procedure exposes to a risk of potentially life-threatening exacerbation of IPF [94,96], that remains difficult to quantify.

The formal and relative contraindications of the technique are shown in Table 8 [94]. They are focused on the prevention of the hemorrhagic risk. For example, PH may increase this risk, and should be systematically assessed before performing TBCB when clinical or radiological warning signs are found. Age is not considered a limiting factor. However, the failure rate of the technique could be increased in case of severe obesity (body mass index [BMI] > 35).

		Histopathological pattern				Biopsy not performed
		UIP	Probable UIP	Indeterminate for UIP	Other pattern	
Pattern on the chest CT scan	UIP	IPF	IPF	IPF	Non-IPF	IPF
	Probable UIP	IPF	IPF	IPF, working diagnosis**	Non-IPF	IPF, working diagnosis**
	Indeterminate for UIP	IPF	IPF, working diagnosis**	To be discussed during a MDD*	Non-IPF	To be discussed during a MDD*
	Other pattern	To be discussed during a MDD*	Non-IPF	Non-IPF	Non-IPF	To be discussed during a MDD*

Each situation must be discussed during a MDD. The situation of an UIP pattern on the CT scan and a lung biopsy available is theoretical, since a biopsy is not performed if an UIP or probable UIP pattern is seen on the CT scan.

Fig. 12. Idiopathic pulmonary fibrosis: summary diagnosis after ruling out a cause of fibrosis (modified from Raghu et al. [9]). MDD: multidisciplinary discussion; IPF: idiopathic pulmonary fibrosis; UIP: usual interstitial pneumonia. *Low probability of IPF or unclassifiable interstitial lung disease, to be assessed according to the clinical probability, and to be reassessed according to the evolution. **If high clinical probability of IPF (including men >60 years old or women >70 years old), compatible broncho-alveolar lavage (if performed), and to be reassessed according to the evolution.

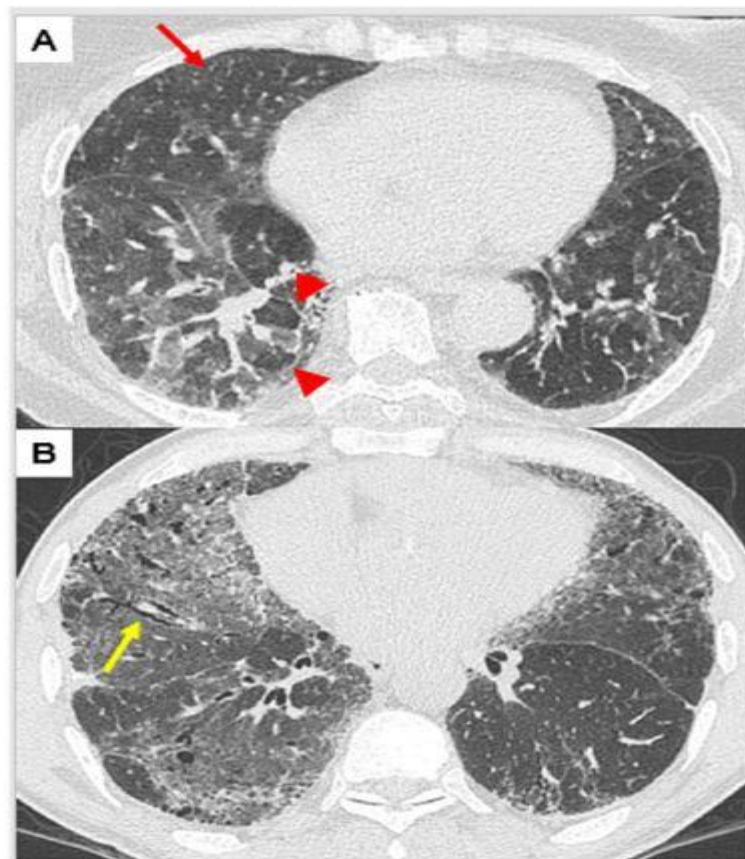


Fig. 13. Patterns suggestive of another diagnosis on the CT scan. A: ground-glass hyperattenuation resulting in a mosaic pattern (arrowheads: lobular hypodensity) and centrilobular micronodules (arrow) during avian hypersensitivity pneumonitis. B: ground-glass hyperattenuation, diffuse intralobular reticulation and traction bronchiectasis (arrow), in idiopathic non-specific interstitial pneumonitis.

The procedure should not be performed in case of rapid disease progression or high risk of exacerbation. Its contribution in patients with fibrosing ILD with deep respiratory functional impairment remains unclear [94].

The procedure is performed using an endotracheal tube or a rigid bronchoscope, under deep analgo-sedation, or even under general anesthesia. The distance to the pleura should be controlled by fluoroscopy. The biopsy should provide 3–5 specimens, each measuring about 5 mm in diameter, taken in the lung parenchyma periphery, beyond the middle third, but remotely from the pleura (>1 cm) in order to limit the risk of bleeding and pneumothorax, respectively. The yield would be better when the samples are taken from different segments of the same lobe [97]. Such samples usually allow identifying easily the characteristic features of UIP [98] (Fig. 14).

Diagnostic yield

According to a systematic review followed by a meta-analysis, the mean diagnostic yield of TBCB in the assessment of ILD is 83.7%, with sensitivity and specificity of 87% and 57%, respectively; these figures reach 92.7%, 91% and 58%, respectively, with VATS lung biopsy [87].

No published study has compared the clinical outcome of patients who underwent or not TBCB [10]. However, several studies allow assessing the diagnostic yield of TBCB based on the conclusions of MDDs [84,85,90–92,99–109]. These studies included patients with ILD of unknown etiology, without excluding those showing an UIP pattern on the CT scan. The analysis of the unweighted pooled data indicates that TBCB provides usable samples in 96% of cases, and these samples allow making an accurate diagnosis in 83% of cases. Thus, TBCB allows making an accurate diagnosis in 80% of cases [10].

A multicenter prospective randomized trial that has included 65 patients with ILD whose diagnosis required a biopsy has investigated the concordance between the results of the analysis of the specimens taken by TBCB versus by VATS lung biopsy, both in terms of histopathological results (agreement of 70.8%) and MDD conclusions (agreement of 76.9%). Both methods lead to almost identical conclusions (agreement of 95%) when the diagnosis is made with a high level of confidence during the MDD after analysis of the specimens taken by TBCB. The analysis of surgical biopsies allows reclassifying TBCB that have led to uncertain or unclassifiable results with a high level of confidence (23%) [96]. However, another prospective study with a limited sample size (21 patients with ILD) has found an insufficient correlation (agreement of 38%) between TBCB and VATS lung biopsy [110]. TBCB would be poorly effective in differentiating UIP lesions from NSIP lesions [111]. Thus, it appears that the concordance between TBCB and VATS lung biopsy is high in case of suspected IPF and TBCB could be proposed as a first line only in centers trained in this technique [112].

A study has explored the place of TBCB in the diagnostic algorithm and suggested a diagnostic contribution comparable to that of surgical lung biopsy to achieve a diagnostic consensus during the MDD [84,109].

In the future, the diagnostic yield of minimally invasive biopsy techniques could be improved by coupling the histopathological examination with molecular analyzes (using an artificial intelligence algorithm), especially if the histopathological examination is not conclusive or shows unclassifiable fibrosis [93,113].

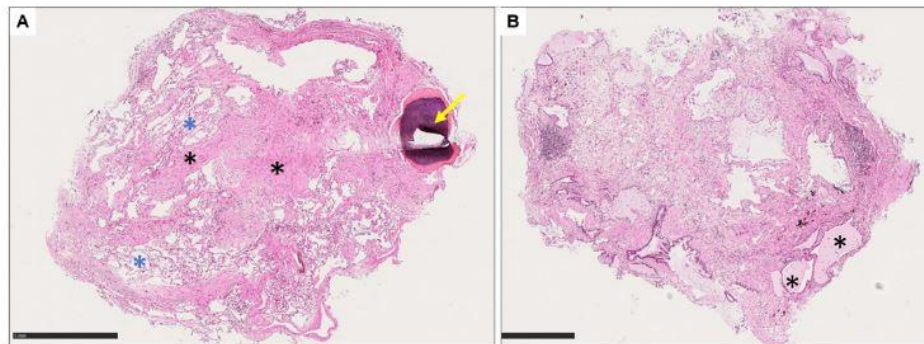


Fig. 14. Lung cryobiopsies: probable usual interstitial pneumonia (UIP) pattern on the histopathological examination. A. Lower lobar biopsy showing lobular destruction by fibrotic bands (black asterisks) between which some preserved alveoli persist (blue asterisks). There is no inflammation. At the right end, a focus of bone metaplasia (arrow), commonly seen in UIP. B. Upper lobe biopsy shows some microcystic honeycomb distensions (asterisks) and early fibroblastic foci formation.

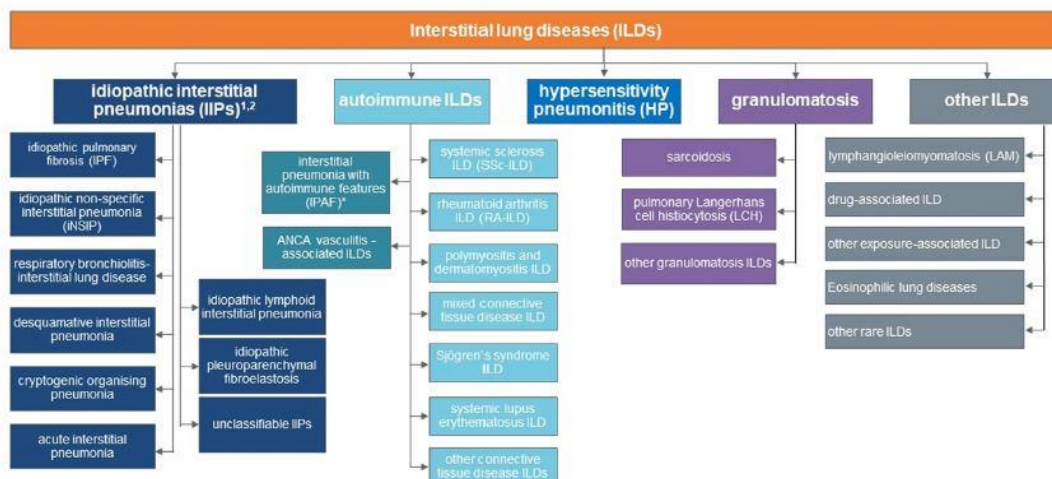


Fig. 15. Main interstitial lung diseases [114–117]. Typically fibrosing diseases are shown in bold. ANCA: anti-neutrophil cytoplasmic antibodies; IPF: idiopathic pulmonary fibrosis; IP: interstitial pneumonia; ILD: interstitial lung disease; NSIP: non-specific interstitial pneumonia.

The expert consensus and international guidelines currently recommend that only experienced centers trained to manage its potential complications can perform TBCB [10,94].

Guideline 2. It is recommended to consider a lung biopsy in patients whose diagnosis of IPF remains uncertain at the end of the multidisciplinary discussion, in particular in the absence of a (definite or probable) usual interstitial pneumonia pattern on the CT scan.

The decision to propose a biopsy is made in the context of a multidisciplinary discussion after assessment of the risk that depends on the age, the functional impact of the disease, the presence of comorbidities, and the evolution of interstitial pneumonia.

Lung biopsy is usually performed by thoracoscopy, or possibly by cryobiopsy in some centers.

Forceps transbronchial lung biopsy

Forceps transbronchial lung biopsies (TBLB) during flexible bronchoscopy may show basic signs of UIP [10,89,90]. However, because of their small size, these samples do not allow assessing the lung architecture, expose to the risk of false negatives [90], and do not allow highlighting disseminated anomalies such as granulomas [10]. The risk of pneumothorax is of about 10% and persistent air leaks complicate the outcomes in about 6% of patients [10]. Forceps TBLB is not recommended for the diagnosis of IPF [10].

Recent studies suggest that the use of artificial intelligence programs applied to the analysis of molecular signatures identified in samples obtained by TBLB in patients with ILD would increase the probability of UIP or non-UIP [91–93].

Differential diagnosis

The positive diagnosis of IPF requires ruling out other fibrosing ILDs of known or unknown cause [10,114]. They mainly include HP, lung diseases in a context of CTD/autoimmunity (in particular rheumatoid arthritis and systemic sclerosis), pneumoconioses (asbestosis, silicosis), drug-induced ILD, sarcoidosis (stage IV) and, with regard to idiopathic forms, NSIP and unclassifiable fibrosis (Fig. 15) [114–117].

Lists of inhaled antigens responsible for HP and agents associated with drug-induced lung disease are available on the Internet (see <http://maladies-pulmonaires-rares.fr/1> or <https://www.hplung.com/>; www.pneumotox.com).

These conditions are discussed based on the data from patient's questioning, physical examination and imaging, and are generally little challenging for the differential diagnosis with IPF, except pulmonary asbestosis and chronic fibrosing forms of HP (including avian type), the radiological presentation of which is sometimes comparable to that of IPF. It is therefore essential to investigate the presence of environmental lung diseases. According to a study, a thorough environmental investigation and a new reading of biopsies may sometimes lead to reconsider the initial diagnosis of IPF for a chronic form of HP [118]. An assessment by an environmental consultant is useful. Patients should be questioned on their professional background and, in case of doubt, referred to a consultation specialized in occupational disorders. Standardized questionnaires and lists are useful to identify an occupational cause (asbestos) or an exposure to an organic antigen (see website <http://maladies-pulmonaires-rares.fr/2>).

An UIP pattern on the CT scan does not preclude its idiopathic or secondary nature. In some cases, fibrotic HP may have an UIP pattern that is not distinguishable from that of IPF. Three-density patterns are specific to HP and virtually allow ruling out the diagnosis of IPF [56]. The presence of hypo-attenuation (or even mosaic) areas and centrolobular micronodules, and the absence of predominance at the lung bases are other guidance features supporting HP [119].

1 <http://maladies-pulmonaires-rares.fr/ckfinder/userfiles/files/documents-telecharger/RPA/RPA%20causes%20PHS%202010.pdf>

2 <http://maladies-pulmonaires-rares.fr/ckfinder/userfiles/files/documents-telecharger/RPA/RPA%20causes%20PHS%202010.pdf>

Drug causes are relatively rare in UIP [120]. The potential identification of a cause of chronic ILD rules out the diagnosis of IPF.

Published questionnaires are used to guide the clinical investigation aimed at identifying exposures in all types of environments (home, work, other places frequently visited) [121–123]. These questionnaires may be adapted to better understand cultural habits and geographical differences. The investigation should also explore exposures that are known risk factors for IPF (Table 2) [9].

The detection of specific circulating antibodies to highlight the potential involvement of an antigen, the responsibility of which would not have been suspected during the clinical investigation, is not very useful to rule out the diagnosis of HP and is not recommended.

Once the causes of ILD ruled out, the diagnosis of idiopathic ILD is made, and it is then important to distinguish IPF from other forms of idiopathic ILD based on imaging and, if available, histopathological findings. In practice, the differential diagnosis of IPF mainly includes fibrosing NSIP, other idiopathic ILD, chronic HP, ILD with rough CTD and unclassifiable forms of idiopathic ILD.

Guideline 3. In patients with suspected IPF, searching for evidence supporting a specific cause of interstitial lung disease is recommended, in particular an exposure to drugs, an inhaled antigen, mineral particles, connective tissue disease or systemic vasculitis.

Table 9
Main additional laboratory tests useful for the diagnosis of IPF.

Systematic
Complete blood count
Creatininemia
Transaminases, gamma-glutamyl-transferase, alkaline phosphatases
Anti-nuclear antibodies (connective tissue diseases)
Anti-cyclic citrullinated peptide antibodies, rheumatoid factor (rheumatoid arthritis)
Anti-neutrophil cytoplasmic antibodies
Depending on the context
C-reactive protein
Connective tissue disease-specific autoantibodies:
• Systemic sclerosis: anti-Scl-70/topoisomerase-1, anti-centromere, anti-RNA polymerase III, anti-U1RNP, anti-Th/To, anti-PM/Scl, U3 RNP (fibrillar), anti-Ku antibodies
• Myositis: creatine phosphokinase, myoglobin, aldolase, anti-tRNA-synthetase (anti-Jo1, and other antibodies if available), anti-MDA5, anti-Mi-2, anti-NXP2, anti-TIF1-gamma, anti-SRP, anti-HMGCR, anti-SAE, anti-U1RNP, anti-PM/Scl75, anti-PM/Scl100, anti-Ku antibodies
• Sjögren syndrome: anti-SSA/Ro antibodies (anti-SSB/La are not very useful)
Precipitins if suspected antigen exposure
Creatine phosphokinase
Blood protein electrophoresis

HMGCR: 3-hydroxy-3-methylglutaryl-CoA reductase; MDA5: melanoma differentiation-associated protein 5; NXP2: nuclear matrix protein 2; PM/Scl: polymyositis/scleroderma; SAE: small ubiquitin-related modifier-activating enzyme; SRP: signal recognition particle; SSA: Sjögren's-syndrome-related antigen A; Th/To: ribonucleoprotein Th/to; TIF1-gamma: transcriptional intermediary factor 1-gamma; U1RNP: ribonucleoprotein U1.

Laboratory workup

ILD showing an UIP pattern on the CT scan and/or histopathological examination [124] may be the inaugural clinical manifestation of CTD or vasculitis [125,126].

When a diagnosis of IPF is suspected, the presence of extra-respiratory signs and auto-antibodies suggestive of CTD should be investigated, especially if the patient is a woman and/or younger than 50 years.

Laboratory workup for the detection of connective tissue disease or vasculitis

The positive diagnosis of IPF requires ruling out other possible causes of ILD, in particular CTD-associated ILD (CTD-ILD). A targeted laboratory workup is therefore mandatory but there is no consensus regarding what it should include. According to the 2018 international guidelines, only a few biomarkers should be systematically investigated, the other assays being performed on a case-by-case basis depending on the clinical orientation, or if anti-nuclear antibodies are detected (e.g. suspected systemic sclerosis or vasculitis) (Table 9) [10]. An assessment of inflammatory myopathy is proposed, especially if the radiological and clinical presentation is suggestive (young subject, clinical, biological or electromyographic signs of dermatomyositis, acute or subacute onset, overlapping pattern of NSIP/organizing pneumonia on the CT scan), but some authors suggest to systematically detect anti-Jo1 antibodies, or even other myositis-associated antibodies.

A specialist's opinion (e.g. rheumatologist, internist, dermatologist) is usually requested only when clinical or biological warning signs or atypical features of suspected IPF (e.g. female gender, age <50 years) are present. The presence of auto-antibodies without extra-respiratory manifestation is possible in IPF as in the general population (in particular anti-nuclear antibodies, rheumatoid factor). During the evolution, the appearance of signs, symptoms or serological abnormalities suggestive of CTD may lead to question the diagnosis of IPF. The presence of anti-neutrophil cytoplasmic antibodies (ANCA) is investigated because of their possible presence in IPF, the possible association of IPF with ANCA-associated vasculitis (microscopic polyangiitis), and the risk of developing vasculitis (alveolar hemorrhage, glomerulonephritis) in a patient with "IPF" and ANCA, including myeloperoxidase-specific ANCA [127].

The laboratory workup also includes parameters allowing detecting an extra-respiratory involvement, or even a telomeropathy: complete blood count, mean red cell volume, creatininemia, liver function tests. The presence of precipitins should be investigated in case of exposure to organic antigens or suspected HP. The presence of infectious agents should be investigated in case of doubt about infection, in particular by bronchoalveolar lavage (BAL; see below). The presence of a lymphoproliferative disease should be investigated (protein electrophoresis and immunoelectrophoresis, urinary immunofixation, cryoglobulinemia) in case of presentation suggestive of non-IPF ILD.

Table 10

Main additional examinations useful during the initial diagnostic workup of suspected IPF apart from the laboratory workup.

Systematic	<ul style="list-style-type: none"> • High-resolution chest CT scan. • Forced vital capacity, diffusing capacity for carbon monoxide (transfer factor) • Doppler echocardiography
Sometimes	<ul style="list-style-type: none"> • Total lung capacity, arterial blood gas test at rest • 6 min walk test with measurement of percutaneous oxygen saturation • Cytological count in the bronchoalveolar lavage • Video-assisted surgical lung biopsy or transbronchial cryobiopsy
Depending on the context	<ul style="list-style-type: none"> • Detection of infectious agents in the bronchoalveolar lavage • Gastroesophageal reflux disease: Upper GI endoscopy, pH-metry • Sleep apnea: ventilatory polygraphy: polysomnography • Genetic testing

Table 11

Recommended conditions for performing bronchoalveolar lavage (from Meyer et al. [132]).

<ul style="list-style-type: none"> • Use of a fiberoptic bronchoscope, with the patient in a semi-sitting position • Total volume of sterile saline solution instilled ranging between at least 100 mL and at most 300 mL • Fractional processing of saline instillation in 3–5 times, recovered immediately by gentle aspiration after each instillation • For satisfactory exploration of the deep lung, the recovered volume of saline solution must be $\geq 30\%$ of the instilled volume • The analysis of the cytological formula could be biased if the recovered volume is $< 30\%$, and especially if it is $< 10\%$ of the total instilled volume • If the recovered volume is $< 5\%$ due to saline solution retention in the explored segment, the examination should be stopped to avoid the risk of lung parenchyma injury and/or release of inflammatory mediators, caused by excessive distention • An overall volume of at least 5 mL is necessary for the analysis of the cytological formula • The optimal volume is 10–20 mL • It is acceptable to pool all aspirated aliquots (including the first one) for routine examinations
--

Interstitial pneumonia associated with autoimmune features

In the context of CTD-ILD, the lung involvement is often an inaugural, predominant, or even isolated manifestation, explaining the fact that the rheumatological diagnostic criteria are only partially met. It has been proposed to refer to these patients as "Interstitial Pneumonia with Autoimmune Features" (IPAF) but the clinical utility of this research definition remains to be confirmed [128].

Other additional tests useful for the diagnosis

The proposed tests are listed in [Table 10](#).

Detection of specific markers

A specific biomarker should ideally allow identifying IPF within other ILDs. Some biomarkers currently appear as potential candidates in this regard [10]: matrix metalloprotease (MMP)₇ (matrilysin-1) [129,130], surfactant protein D (SPD) [129], CA125 [131]. The use of chemokine ligand-18 (CCL-18) and Krebs von den Lungen-6 (KL-6) has also been proposed. However, these tests give an erroneous result in more than a third of patients, they are expensive, their availability is limited, and none is validated [10].

Guideline 4. In patients with suspected IPF, it is recommended to perform a laboratory workup, the negativity of which will support the diagnosis of IPF including:

– **Antinuclear antibody testing (connective tissue diseases), anticyclic citrullinated peptide antibody testing, rheumatoid factor testing (rheumatoid arthritis), anti-neutrophil cytoplasmic antibody testing (systemic vasculitis);**

– **And, depending on the clinical, biological, and radiological context: systemic sclerosis-specific antibody testing (anti-centromeres, anti-topoisomerase-1, anti-U3RNP), myositis assessment (creatine phosphokinase, anti-synthetase antibodies and rare myositis-associated antibodies), anti-Sjögren syndrome antibody testing (anti-SSA), clinically oriented precipitin testing.**

Bronchoalveolar lavage

The BAL technique should follow international guidelines [132] ([Table 11](#)). In particular, contraindications should be respected and performing BAL should be avoided if the respiratory status of the patient does not allow it.

In IPF, the examination shows increased counts of neutrophils (>3%) or even eosinophils (>1%, but usually less than the neutrophil count). A lymphocyte profile (>30%) suggests a diagnosis other than IPF: sarcoidosis, HP, NSIP, CTD, drug-induced or radiation pneumonia, lymphoproliferative disease, organizing pneumonia [132–135].

The diagnostic contribution of the BAL is especially important when the radiological presentation is not that of UIP, if chronic HP is considered [21,136], or in case of exposure to asbestos for a mineralogical study.

Diagnostic yield

No published study has compared the outcome of patients in whom a cytological evaluation of the BAL fluid was performed or not [10]. However, several studies have described the distribution of the cell populations observed in the various types of ILD [133,137–143]. These studies have included patients with IPF and have variously assessed, according to the authors, the proportion of neutrophils, macrophages, lymphocytes, eosinophils, as well as the CD4/CD8 ratio. The cell counts have then been compared to those usually observed in other

ILDs. Most studies have presented the results as a proportion of cell populations, but not as a positive or negative diagnostic value. Nevertheless, lymphocytosis >30% in the BAL should suggest HP and rule out the diagnosis of IPF [133]. Table 12 shows the mean proportion of cell populations in normal subjects and patients with IPF. The diagnostic yield of the CD4/CD8 ratio is low; this examination is not useful for the diagnosis of IPF.

Regarding the differential diagnosis between IPF and other ILDs, the cytological analysis of the BAL has a low discriminating power due to the limited number of studies available, their small sample sizes and the wide range of mean values [10].

Although none of the included studies has reported complications associated with BAL, it is an invasive technique that requires time and resources, may be associated with adverse effects, and is uncomfortable in some patients [10]. Some experts think that the examination could (slightly) increase the risk of IPF exacerbation [144].

Overall, the benefit/risk ratio of the BAL appears favorable in patients with a probable UIP or indeterminate for UIP pattern or a pattern suggestive of another diagnosis, because the examination helps to identify or rule out some characterized etiologies (including eosinophilic pneumonia, sarcoidosis, infection) with limited disadvantages (complications, resources, costs). On the other hand, the risks exceed the expected benefit when an UIP pattern is seen on the CT scan.

Guideline 5. In patients with suspected IPF, it is proposed to perform a bronchoalveolar lavage in the absence of an usual interstitial pneumonia pattern on the CT scan, and if the risk associated with the examination is considered low.

Genetic testing

At least 30% of patients with sporadic or familial IPF carry genetic variants associated with an increased risk of pulmonary fibrosis [145–147]. However, identified mutations in the telomerase complex have also been identified in other ILDs [148–151].

Genetic variants are associated with an increased risk of fibrosis, but its presentation (phenotype) is varied (IPF, but also idiopathic NSIP, unclassifiable fibrosis, CTD-ILD, etc.). In a young subject with IPF (before the age of 60, and especially before the age of 50), a family or genetic form should be investigated. In the current state of knowledge, the management depends more on the presentation of the disease (IPF or not, in particular) than on genetic abnormalities, that is why the genetic forms of pulmonary fibrosis are still classified as IPF (and thus "idiopathic") when the radiological and/or histological diagnostic criteria are met. In other words, genetic variants are considered a risk factor rather than a cause.

Familial pulmonary fibrosis

Familial pulmonary fibrosis is defined by the presence of at least two cases of pulmonary fibrosis in the same family [152], but any ILD, of known or unknown cause, may be familial and associated with a genetic disease. Between 2 and 20% of IPF are familial and they follow an autosomal dominant mode of inheritance [152]. Within an affected family, ILD is more common in men, smokers and elderly subjects.

Table 12
Bronchoalveolar lavage: mean proportion of cell populations observed in healthy subjects and in patients with idiopathic pulmonary fibrosis (from Raghu et al. [10]).

	Healthy subjects	IPF patients
Macrophages	>85%	49%–83%
Lymphocytes	10%–15%	7.2%–26.7%
Neutrophils	<3%	5.9%–22%
Eosinophils	<1%	2.4%–7.5%
CD4/CD8 ratio	0.9–2.5	1.4–7.2

On the CT scan, familial ILD is most often characterized by an UIP or indeterminate for UIP pattern, and more rarely by a NSIP or organizing pneumonia pattern [153]. Histopathologically, UIP patterns are usually found, but unclassifiable forms or patterns of NSIP, HP or organizing pneumonia have been observed [153]. The progression profile of familial pulmonary fibrosis is comparable to that of sporadic forms [148,154].

The main genes involved in the onset of genetic pulmonary fibrosis are listed in Table 13 [155]. No genetic factor consistently associated with sporadic IPF has been identified.

Table 13
Main genes associated with lung fibrosis (adapted from Borie et al. [155]).

Gene	Function	Associated diseases	Transmission	Variation
<i>TERT, TR, RTEL1, PARN, NAF1, TINF2/DKC1</i>	Telomerase	Congenital dyskeratosis, telomeropathy	X-linked autosomal dominant/recessive	Mutations [563–566]
<i>SFTPC-SFTPA1, SFTPA2/SFTPB-ABCA3</i>	Surfactant	Lung cancer, combined pulmonary fibrosis and emphysema syndrome	Autosomal dominant/recessive	Mutations [161]
<i>ELMOD2</i>	Antiviral response		Monogenic	No mutation identified [567]
<i>NF-1</i>	Tumor suppressor	Neurofibromatosis	Autosomal dominant	Mutations [568]
<i>NKX-2 (TTF1)</i>	Transcription factor	Neuropathy, hypothyroidism	Autosomal dominant	Mutations and deletions [569]
<i>HPS-1 to 8/AP-3B1</i>	Lysosomes	Hermansky-Pudlak	Autosomal recessive	Mutations [570]
<i>FAM111B</i>	Unknown	Myopathy, poikiloderma	Autosomal dominant	Mutations [571]

Mutations in telomere-associated genes

The telomerase complex catalyzes the addition of repeated DNA sequences at the telomeres, thus protecting chromosomes from shortening during mitosis. It consists of several proteins, including telomerase reverse transcriptase (TERT). Mutations in the TERT gene are most commonly found in familial fibrosis; these mutations induce various extra-respiratory [149], mucocutaneous (dyskeratosis congenita with nail dystrophy, localized skin hyperpigmentation and oral leukoplakia), hematological (myelosuppression, myelodysplasia, acute leukemia, anemia), hepatic (cirrhosis, portal hypertension) impairments, as well as cellular and humoral immune deficiencies, exudative retinopathy and a central neurological impairment.

In case of mutation in the TERT gene, the occurrence of ILD depends on the age: absent before 40 years, it occurs in more than 60% of patients carrying mutations after 60 years [156]. Mutations affecting other components of the telomerase complex or interacting with it (referred to as telomere-associated genes) have been described in association with pulmonary fibrosis (RTEL1, PARN, RAF1, DKC1, TINF2, NOP10, NHP2, CTC1). Some types of familial emphysema are also related to mutations in genes involved in the telomerase complex.

A mutation in telomere-associated genes is frequently associated with a decrease in telomere length measured on circulating leukocytes, but measuring this length does not allow diagnosing the mutation. Telomere shortening occurs physiologically with age [157], in case of exposure to tobacco or pesticides, and in many chronic diseases. In sporadic IPF, short telomeres may be observed in the absence of mutations in the telomere-associated genes [157].

Table 14
Screening for mutations in telomere- and surfactant-associated genes is indicated in a patient with idiopathic interstitial lung disease [162].

Screening for mutations in telomere-related genes

Idiopathic fibrosing interstitial lung disease in a subject over 40 years old with at least one of the following criteria:

1. History of interstitial lung disease in a relative (familial fibrosis)
 2. Personal or family history of congenital dyskeratosis, with nail dystrophy, localized skin hyperpigmentation and/or oral leukoplakia
 3. Personal or family history of compatible hematological abnormality (thrombocytopenia, bone marrow aplasia, myelodysplasia, acute leukemia, anemia of central origin)
 4. Personal or family history of compatible liver abnormality (NASH, cryptogenic cirrhosis, portal hypertension)
 5. Premature (before the age of 30) and/or familial canities
 6. Age between 40 and 50 at the time of the diagnosis of fibrosing interstitial lung disease (and no mutation in surfactant-related genes)*
 7. Short-term lung transplantation project
 8. Indication driven by other criteria and validated during a multidisciplinary discussion (MDD) meeting in which a geneticist (or a genetic counsellor) participates
- Familial interstitial pneumonia not falling into the above cases should be discussed during a MDD

Screening for mutations in surfactant-related genes

Idiopathic fibrosing interstitial lung disease in a subject with at least one of the following criteria:

1. Being under the age of 50 when diagnosed with interstitial lung disease
 2. History of interstitial lung disease in a relative (familial fibrosis) (and absence of mutation in telomere-related genes si the subject is over 50)*
 3. Indication driven by other criteria and validated during a MDD in which a geneticist (or a genetic counsellor) participates
- Familial interstitial pneumonia not falling into the above cases should be discussed in a MDD
-

[*] In a patient meeting both the screening criteria for mutations in telomere- and surfactant-related genes, especially between the ages of 40 and 50, the order in which molecular genetic testing must be performed should be discussed. Most often start with the analysis of surfactant-related genes before the age of 50, and then telomere-related genes if the result is negative and if the subject is over 40; start with the analysis of telomere-related genes after 50 years.

No specific treatment is available for these types of fibrosis. In case of pulmonary fibrosis associated with a mutation in the telomere-associated genes, patients are advised to avoid respiratory, hepatic and medullary toxic agents, whether tobacco, environmental toxic agents or cytotoxic drugs for example. The consequences of genetic abnormalities on the response to treatment in IPF patients are not precisely known, but it has been shown that a mutation in a telomere-associated gene significantly increases the risk of mortality after lung transplantation, in particular due to cytopenia under immunosuppressants, especially

azathioprine [158–160]. Myelodysplasia potentially associated with mutations in telomere-associated genes also increases the risk of lung transplantation. Currently, the drug treatment recommended for patients with IPF associated with a mutation in a telomere-associated gene is identical to that for patients without a mutation.

Other genetic abnormalities

Adult-onset familial ILD may also be due to mutations in the genes encoding the surfactant proteins, SFTPC being the most commonly affected gene with an autosomal dominant transmission, or the SFTPA1, SFTPA2 (associated risk of cancer) or ABCA3 gene. The most common radiological pattern associates predominant ground glass, septal thickening, cysts in the upper regions of the lungs, and then later honeycomb lesions [161]. These mutations are more commonly reported in young patients.

Pulmonary fibrosis has been described in some rare familial syndromes, such as Hermansky-Pudlak syndrome, neurofibromatosis, and syndromes associated with heterozygous mutations in the NKX-2 (TTF1) gene (ILD, hypothyroidism, neurological abnormalities, and poikiloderma).

Genetic testing in patients with IPF or suspected IPF

Indications for genetic testing of telomere- and surfactant-related mutations are shown in Table 14 [162].

The presence of mutations in TERT and TR for the telomere-associated genes (in case of suspected pulmonary fibrosis in telomeropathy) and in SFTPA1, SFTPA2, SFTPC and ABCA3 for the surfactant-related genes is often investigated.

Performing a diagnostic test is not insignificant, especially psychologically and medically and legally, and it should be performed as part of a global management by a multidisciplinary team including a geneticist. In practice, it is performed in expert centers (Appendix 1). Obtaining a written informed consent is mandatory. Results should be provided in consultation and accompanied by a proposal for genetic counseling. A specialized genetics consultation is proposed.

The approach to adopt in subjects related to a patient with a genetic form of IPF remains in the field of clinical research. The risk of transmitting a mutation in the TERT or TR gene for a first-degree relative is always less than 50% (risk of transmission of 50% multiplied by the disease penetrance). When the mutation is confirmed, the risk of developing pulmonary fibrosis is of 60% in men and 50% in women after 60 years [163]. The risk of associated extra-pulmonary manifestations is difficult to estimate.

Guideline 6. In patients with suspected IPF, it is recommended to question them about the presence of a family history of ILD and to investigate the presence of clinical and biological signs supporting a genetic cause (age <50 years; hematological, hepatic or mucocutaneous abnormalities).

Guideline 7. In patients with familial IPF or if there are clinical or biological findings suggesting a genetic cause, it is proposed to perform, during a dedicated consultation (possibly during a specialized genetic consultation), a genealogical tree and a molecular

genetic analysis currently mainly focused on telomere- and surfactant protein-related genes.

Diagnosis validation

Multidisciplinary discussion

The diagnosis of IPF is based on a synthesis of the clinical, radiological, respiratory functional, and possibly histopathological patterns, and it is made during a MDD. Ideally, it is conducted in a specialized center, especially in difficult cases (reference center or regional expert center for rare lung diseases [www.maladies-pulmonaires-rares.fr], or in a pneumology department experienced in ILD), if possible in the presence of each of the relevant specialists experienced in the field of ILD, and in connection with the attending pulmonologist. It integrates all of the available data and is focused in uncertain cases on the important clinical guidance characteristics such as the male gender, age over 60, the presence of crackles, the overall clinical probability of the diagnosis of IPF.

It is important to better clarify the effective decision-making role of the MDD in patients with recently diagnosed ILD of unknown etiology, and clinical features suggestive of IPF. However, no published study has compared the clinical outcome of patients whose management was decided as part of a monodisciplinary assessment (or even by a single practitioner) with the outcome of patients assessed during a MDD [10]. The analysis of the pooled results of five studies that have compared the decisions taken on a monodisciplinary basis and those based on a MDD [121,164–167] has shown a median percentage of concurrent decisions of 70% [168], i.e. a moderate level of agreement. The MDD substantially reduces uncertainties and diagnostic errors in ILD patients, allows adjusting overdiagnoses and wrongly rejected diagnoses of IPF, improves decision reproducibility and the prognostic assessment of difficult cases [166,169,170]. These findings confirm that the MDD is the "gold standard" for the diagnostic decision [10]. In one study, a delayed management in a center experienced in ILD has been associated with a shorter survival [171].

However, the composition of the groups and working methods during the MDDs remain variable from one center to another, and their harmonization is recommended [172]. The relevance of the decisions made during a MDD is closely dependent on the level of expertise of the participants [170,173]. As such, prospective studies should compare the effect of the decisions made during a MDD with that of an early opinion in an expert center (reference center or expert center in France) [173].

Concept of "provisional working diagnosis"

In many patients, a diagnostic certainty may not be achieved according to the current international criteria, although a diagnostic and therapeutic decision is needed. In this case, it is proposed to use the term of "provisional working diagnosis" of IPF, in the absence of any more likely differential diagnosis [174]. This choice is often based on a decision made during a MDD. An international survey of 400 pulmonologists has found that they accept the "working diagnosis" hypothesis with a sufficient level of confidence to delay the lung biopsy and prescribe antifibrotic treatment when the probability of the diagnosis of IPF ranges between 70% and 90% [88]. The concept of working diagnosis may be applied to diagnoses other than IPF.

Table 15
Idiopathic interstitial pneumonia: classification according to the concept of "clinical behavior" of the disease (from Travis et al. [116]).

Clinical behavior of the disease	Therapeutic goal	Follow-up strategy
Reversible (e.g., many cases of RB-ILD, some iatrogenic damage)	Eliminate the potential cause	Short-term observation (3–6 months) to confirm disease regression
Reversible with risk of progression (e.g., cellular NSIP, and some fibrotic NSIP, DIP and COP)	Induce an initial response and then adjust long-term treatment	Short-term observation to confirm treatment response
Stable with residual disease (e.g. some fibrotic NSIP)	Maintain the status	Long-term observation to control maintenance of clinical benefit
Irreversible progression with possibility of stabilization (e.g., some fibrotic NSIP)	Stabilize	Long-term observation to assess disease evolution
Irreversible progression despite treatment (e.g. IPF, some fibrotic NSIP)	Slow down progression	Long-term observation to assess disease evolution, discuss transplantation or palliative treatment

DIP: desquamative interstitial pneumonia; IPF: idiopathic pulmonary fibrosis; NSIP: non-specific interstitial pneumonia; COP: cryptogenic organizing pneumonia; RB-ILD: respiratory bronchiolitis-associated interstitial lung disease.

Follow-up of the “clinical behavior of the disease”

When the initial diagnosis of IPF is not definite (provisional working diagnosis of IPF), important prognostic information is added in case of irreversible progressive worsening of the disease during the follow-up (concept of "clinical behavior of the disease; Table 15) [116,175]. The finding of an irreversible worsening increases the probability of the diagnosis of IPF.

Unclassifiable interstitial lung diseases

No accurate diagnosis can be made after the assessment and the MDD in 12% of patients with ILD seen in expert centers) [176–179]. An international cooperating group has recently proposed to define these unclassifiable forms of ILD by the absence of a main diagnostic hypothesis that can be used as a provisional working diagnosis (level of confidence ranging between 70% and 89%), or even as a diagnosis of near certainty (confidence level $\geq 90\%$) [180].

The prognosis of patients with unclassifiable ILD is intermediate between that of patients with IPF and that of patients with ILD due to another cause, with estimated 2-year survival rates of 70–76% [178,179,181,182]. Factors for a poor prognosis include the age, the presence of Velcro crackles, a low FVC, a DLco less than the predicted value, a high fibrosis score or the presence of traction bronchiectasis on the CT scan [178,179,182].

Guideline 8. In patients with suspected IPF, it is recommended to make the diagnosis based on the integration of all the data available during a multidisciplinary discussion involving pulmonologists, radiologists and pathologists experienced in the field of interstitial lung disease.

Guideline 9. In patients with suspected IPF, it is recommended to conduct the multidisciplinary discussion in coordination with an expert or reference center in order to facilitate the discussion of difficult cases and access to research.

Table 16

Prognostic factors for an increased risk of mortality associated with idiopathic pulmonary fibrosis [47,183–187]).

Demographic factors
• Older age, male gender
Initial signs and symptoms
• BMI <25 kg/m ²
• Dyspnea intensity
• DLco <35–40% of the predicted value
• Nadir of pulse-oximetry oxygen saturation <88% during the 6 min walk test in ambient air
• Extent of honeycombing on the chest CT scan
• Mediastinal lymphadenopathy (≥10 mm)
• Precapillary pulmonary hypertension
Signs and symptoms appearing during the evolution
• Weight loss >5% of body weight
• Worsening of dyspnea
• Absolute decline in FVC >5% (e.g., decrease from 65% to 60% of the predicted value), or absolute decline in FVC >10% of the predicted FVC (e.g. decrease from 65% to 55% of the predicted value), or relative decline in FVC >10% compared to the absolute FVC (e.g., decrease from 2 L to 1.8 L) in 6 months
• Absolute or relative decline in DLco >15% in 6 months
• Decrease in the 6MWT distance by >50 m
• Worsening of fibrosis on the chest CT scan
• Acute exacerbation

FVC: forced vital capacity, DLco: diffusing capacity for carbon monoxide; BMI: body mass index; 6MWT: 6 min walk test.

Prognosis and follow-up

Initial assessment of the prognosis

The disease course is usually chronic and progressive, with a risk of acute exacerbation. The data available suggest that a range of factors are associated with the increased IPF-related mortality (Table 16) [47,183–187].

A low weight at the time of the diagnosis and a weight loss (>5% of body weight) are poor prognostic factors [20,188].

The vital prognosis at 1, 2 and 3 years may be estimated using the GAP (Gender, Age, lung Physiology) calculator or the GAP score based on age, gender and impact on respiratory function (<http://www.acponline.org/journals/annals/extras/gap/>) [185,189]; Integrating the history of respiratory hospitalizations and change in FVC over 24 weeks in the GAP score (longitudinal GAP score) improves the prognostic assessment during the follow-up [190,191]. When the DLco is not available to calculate the GAP score, a fibrosis score based on the CT scan findings may provide the same prognostic information [192]. The composite physiologic index (CPI) score may be used to assess fibrosis severity regardless of the possible presence of emphysema [193]. These various features may be useful to assess the indication of lung transplantation.

Table 17

Additional examinations recommended during the follow-up of idiopathic pulmonary fibrosis.

Every month for 6 months and then every 3 months	If antifibrotic treatment: liver function tests (transaminases, bilirubin, alkaline phosphatase)
Every 3–6 months	Physical examination Forced vital capacity Diffusing capacity for carbon monoxide
Every 6–12 months	6 min walk test
No more than once a year routinely, or as clinically indicated	Non-contrast low-dose chest CT scan
Depending on the context	Contrast chest CT scan Total lung capacity Arterial blood gas test Doppler echocardiography

The respiratory disability should also be assessed. The respiratory function decline is variable over time, even in a given patient, but it allows predicting the mortality [194]. The reassessment of PFT during the evolution has a prognostic value.

Pulmonary function tests

PFT at rest may be used to assess the functional impact (impairment) of the disease and contribute to the prognostic assessment. At rest, they show:

- _ A restrictive ventilatory disorder (decline in total lung capacity, associated with a slow decline in vital capacity);

- _ An early decline in DLco and transfer coefficient (DLCO/VA); it is often the only anomaly detected at the time of the diagnosis in the early forms of IPF;

- _ Normal PaO₂ measurement at rest for a significant period of time; pulmonary gas exchange abnormalities are ideally assessed by determining the alveolo-arterial PO₂ gradient under ambient air.

In addition, exercise PFT show a reduced capacity to exercise that may be assessed by:

- _ The reduction in exercise capacity assessed using the walk distance during the 6MWT or on a cycle ergometer (decreased maximum oxygen consumption and maximum power during exercise);

- _ The decrease in percutaneous oxygen saturation during exercise (decrease in SpO₂ >4%) during an exercise test, standardized or not, in particular during the 6MWT;

- _ Investigating exercise-induced hypoxemia, that is often absent at rest, or an increase in alveolo-arterial PO₂ gradient during a functional test on a cycle ergometer, that may be the only respiratory function abnormality present initially.

In therapeutic trials, as during the follow-up of IPF patients, the FVC is often used because its measurement is reproducible and its decline is related to the prognosis [195–198]. Exercise testing is particularly useful in case of poorly explained dyspnea (dyspneic patients with mild-to-moderate pulmonary impairment) or if respiratory rehabilitation is considered [199,200].

Guideline 10. In patients with a confirmed diagnosis of IPF, it is recommended to assess the forced vital capacity and the diffusing capacity for carbon monoxide.

Guideline 11. In patients with a confirmed diagnosis of IPF, it is proposed to also assess the total lung capacity, walk distance and pulse oxygen saturation during a 6 min walk test.

Follow-up examinations and reassessment of the prognosis

The follow-up of IPF patients allows identifying symptom worsening, monitoring disease worsening using PFT, initiating treatment, taking into account comorbidities, and considering lung transplantation.

Examinations that are useful for the follow-up of patients with IPF are listed in Table 17 . There is no data available to recommend the frequency of chest CT scans during the follow-up. It is proposed not to perform systematic chest CT scans more than once a year; non-contrast low-dose CT scans are then performed with particular attention to the detection of common complications [201] with major consequences on the management, including the contraindication to transplantation (cancer, infections) [201]. There is no rationale for repeating it in patients whose respiratory condition or comorbidities would not allow treating an abnormality discovered on the CT scan. It is justified to repeat it in case of suspected acute exacerbation of IPF (without and then with contrast media injection) because it contributes to the diagnosis of this complication, in case of unexplained clinical change, clinically or radiologically suspected lung cancer, and during the evaluation for lung transplantation.

As with any serious chronic disease, writing advance directives may be helpful. The appropriate time to address this issue varies from one person to another, and depends on the sensitivity of patients, physicians, and their relatives to this issue.

The interval between follow-up visits may be of 3–6 months. These visits should take place in a specialized center (reference center, expert center or hospital department specialized in ILD) at least annually, or more closely in case of deterioration. Quarterly visits should be performed by the attending pulmonologist alternating with a specialized center, preferentially as part of a formal or informal care network involving the attending physician.

Quality of life

The decline in lung function is associated with a deterioration in quality of life (QoL) [202]. The QoL is rarely quantified outside of therapeutic trials. The King's Brief Interstitial Lung Disease (KBILD) questionnaire is currently one of the most used and it is validated in French [203]. Changes in KBILD score of 5.5 for the psychological component, 4.4 for the dyspnea component, and 3.9 for the activity component are considered significant [204].

Guideline 12. In patients with a confirmed diagnosis of IPF, it is proposed to assess the prognosis as follows:

– At the time of the diagnosis, through the measurement of dyspnea severity, pulmonary function testing (forced vital capacity, diffusing capacity for carbon monoxide), the nadir of pulse oxygen saturation during the 6 min walk test, the body mass index, the extent of honeycombing on the high-resolution chest CT scan, the presence of signs of pulmonary hypertension on echocardiography, and using a score such as the GAP score

– During the follow-up, through the evolution of symptoms, the forced vital capacity, the diffusing capacity for carbon monoxide, the body weight, and possibly the presence of signs of pulmonary hypertension on echocardiography, and/or in case of worsening, signs of fibrosis on the chest CT scan.

Guideline 13. In patients with a confirmed diagnosis of IPF, it is recommended to perform during the follow-up at least a physical examination, a respiratory function test including a measurement of the forced vital capacity and a measurement of the diffusing capacity for carbon monoxide every 3–6 months, and a 6 min walk test every 6–12 months.

Guideline 14. In patients with a confirmed diagnosis of IPF, it is proposed to perform a non-contrast chest CT scan at most once a year as part of a systematic follow-up.

Guideline 15. In patients with a confirmed diagnosis of IPF, it is recommended to perform a chest CT scan in case of suspected acute exacerbation of IPF, unexplained clinical change, suspected bronchial cancer, and in case of assessment for lung transplantation.

Guideline 16. In patients with a confirmed diagnosis of IPF, it is recommended to pay particular attention to the detection of lung cancer when a chest CT scan is performed.

Guideline 17. It is proposed to ask patients with a confirmed diagnosis of IPF if they have written advance directives to specify their end-of-life wishes, and/or if they wish to discuss this subject or be accompanied to draft them.

Anti-fibrotic medical treatments of IPF

The methods and results of clinical trials that have shown the efficacy and safety of pirfenidone and nintedanib in the treatment of patients with definite diagnosis of IPF have been detailed in the previous version of these guidelines [3]: we will therefore limit here to recalling the main points of interest.

Pirfenidone

Pirfenidone³ has an antifibrotic effect by limiting the production of profibrotic growth factors, including TGF-beta-1, leading to the inhibition of fibroblast proliferation, myofibroblast differentiation, collagen and fibronectin synthesis, and extracellular matrix production [205]. It also has anti-inflammatory and anti-oxidant properties [205,206].

³ Esbriet_®: laboratoire Roche - 30 cours de l'île Seguin - 92650 Boulogne-Billancourt.

Efficacy

Studies conducted during the initial phases of clinical development of pirfenidone [207–211] have suggested that, at a dose of 1800 mg/day, it reduces the incidence of acute exacerbations, slows down the decline in vital capacity at week 36 [208] and slows down the decline in vital capacity and improves the progression-free survival (PFS) at week 52 [209].

The efficacy of pirfenidone has been further assessed in two phase III multicenter randomized controlled trials (RCTs): CAPACITY-1 (344 patients) and CAPACITY-2 (435 patients) [210]. Pirfenidone was given at a dose of 2403 mg/d or 1197 mg/d in CAPACITY-2, and at 2403 mg/d in CAPACITY-1. Eligible patients had mild-to-moderate IPF (defined by a FVC $\geq 50\%$ and a DLco $\geq 35\%$ of the predicted value) and walked at least 150 m during the 6MWT. The primary endpoint was the absolute difference in percentage of the predicted FVC at week 72.

The intent-to-treat analysis has shown discordant results for the primary endpoint: the difference was significant between the dose of 2403 mg/d of pirfenidone and the placebo in CAPACITY-2 but not significant in CAPACITY-1. The pooled analysis of the CAPACITY studies has shown the statistically significant superiority of pirfenidone at a dose of 2403 mg/d over the placebo in terms of [210]:

- _ Decline in FVC after 72 weeks of treatment (_8.5% vs. 11%; $p = 0.005$);
- _ Percentage of patients with a degradation of the FVC $\geq 10\%$ (21% vs. 31%; $p=0.003$);
- _ Mean walk distance during the 6MWT (_52.8 m vs. _76.8 m; $p < 0.001$);
- _ Duration of the PFS defined by the confirmed decrease $\geq 10\%$ in the percentage of predicted FVC, the decrease $\geq 15\%$ in the percentage of predicted DLco, or the death (HR: 0.74; 95% CI: 0.57–0.96; $p = 0.025$).

These differences are clinically relevant [196,212,213]. A metaanalysis of the two trials of the CAPACITY program [210] and a phase III trial [209] has confirmed the significant improvement in PFS under pirfenidone (HR: 0.70; $p = 0.002$) [214].

Another phase III, double-blind, placebo-controlled RCT, the ASCEND study, has compared the effect of pirfenidone (2403 mg/d) to that of the placebo, given for 52 weeks in 555 patients [211]. The primary endpoint was the change in FVC or death at week 52. The eligibility criteria were similar to those of the CAPACITY program but modified to include a more homogeneous population of patients with a definite diagnosis of IPF and at high risk of progression. At baseline, the mean FVC and the DLco were respectively 67.8 \pm 11.2% and 42% of the predicted value. Notably, 95% of patients had an UIP pattern on the CT scan and about 30% had undergone VATS lung biopsy.

The results at week 52 have shown, under pirfenidone compared to placebo, a 47.9% decrease in the proportion of patients with a $\geq 10\%$ decline in FVC or who died, and a relative 132.5% increase in the proportion of patients without decline in FVC ($p < 0.001$). The results were confirmed in a sensitivity analysis [215]. In addition, there was a reduction in the decline in walk distance during the 6MWT ($p = 0.04$), and a significant improvement in PFS ($p < 0.001$)

under pirfenidone. There was no significant difference in terms of scores of dyspnea, all-cause mortality or IPF mortality [211].

Additional analyzes

Several pooled analyzes of the CAPACITY and ASCEND trials (1247 patients) [211,216–219] have shown that, compared to placebo, pirfenidone (at the dose of 2403 mg/day):

- _ Decreases by 48% the risk of mortality (HR: 0.52; $p = 0.01$), both in terms of all-cause mortality ($p = 0.01$) and IPF-related mortality ($p = 0.006$) [211].

- _ Reduces by 43.8% the proportion of patients who died or experienced a decline $\geq 10\%$ in predicted FVC, and increases by 59.3% the proportion of patients with no decline in FVC [216]; a benefit has also been observed in terms of PFS, 6MWT and dyspnea. The QoL has not been assessed in these studies.

- _ Reduces by 48% the relative risk of urgent unplanned hospitalization for respiratory causes over one year (7% versus 12%; $p = 0.001$), without reducing the frequency of all-cause urgent hospitalizations [217].

- _ Is associated, after 12 months of treatment, with a slowing down of disease progression (defined by a decline $\geq 10\%$ in the predicted FVC or a reduction ≥ 50 m in the 6MWT distance or a reduction in hospitalization for a respiratory cause or in all-cause mortality; 17.0% versus 30.1%; $p < 0.0001$) [220]. The risk of mortality after one or more events confirming a progression was also reduced with pirfenidone (2.1% versus 6.3%; $p = 0.0002$).

- _ Decreases dyspnea progression at 12 months as assessed by the median change in UCSD SOBQ (University of California San Diego vShortness of Breath Questionnaire) score (9.2 versus 13.0 points; $p = 0.009$) in patients with GAP stage II/III IPF at baseline and in those with a FVC $< 80\%$ of the predicted value (8.5 versus 12.0 points; $p = 0.006$) [219].

Long-term and/or real-life efficacy

The open-label long-term follow-up of patients included in the CAPACITY trials has shown a mean decline in FVC by 144.3 mL/year, i.e. a decrease by 9.6% after 180 months compared to baseline, with a mean survival time under treatment with pirfenidone of 77.2 months [221]. The long-term effect of pirfenidone seems to be maintained in the RECAP study (extended open-label follow-up of patients who completed the CAPACITY trials) [222].

The sustained effect has also been observed in several observational studies conducted under usual university hospital practice conditions: the benefit seems to be particularly pronounced in patients with the most severe initial degradation of the FVC [186,223–234].

A pooled analysis of survival data of patients included in the CAPACITY, ASCEND, RECAP trials and those of patients with identical eligibility criteria included in a hospital database (Inova Fairfax Hospital database) has suggested that, compared to the best usual care, pirfenidone extends the mean survival by about 2.5 years (8.7 versus 6.2 years) [235].

Table 18
Long-term tolerance and safety of pirfenidone (from Costabel et al. [221]).

Treatment-emergent adverse event	Incidence (per 100 patients-years of exposure)
Treatment-emergent adverse events (total)	71.9
• IPF	22.0
• Upper airway infection	21.1
• Bronchitis	19.5
Severe treatment-emergent adverse events (total)	53.5
• IPF	11.1
• Lung disease	4.2
• Bronchitis	1.5
Deaths (total)	9.3
• Including IPF	5.4
Treatment discontinuation (total)	
• IPF	17.9
• Lung disease, respiratory failure, acute respiratory distress, rash	7.2
• Nausea	0.5 (each)
	0.4

IPF: Idiopathic Pulmonary Fibrosis.

A European multicenter prospective observational study has included 43 patients with IPF and persistent daily cough for at least eight weeks, who had not received any prior antifibrotic treatments, and has shown that after 12 weeks of treatment, pirfenidone decreased cough by 34%, objectively assessed by a validated device (Leicester Cough Monitor) [236], without any significant improvement in QoL and anxiety measurements [237].

Safety and tolerance

The tolerance of pirfenidone has been assessed in a pooled analysis of data from four RCTs (789 patients exposed to pirfenidone for a median time of 2.6 years, i.e. a cumulative exposure of 2059 patients-years) [238] and from a meta-analysis of 6 RCTs (1073 patients) [239] as well as prospective [8,232] and retrospective [186,229–233,240] multicenter observational studies.

Compared to placebo, the most common adverse events (AEs) reported with pirfenidone are gastrointestinal events (nausea, dyspepsia, diarrhea, anorexia), and fatigue, dizziness, skin manifestations (photosensitivity, rash). They are almost always mild to moderate in intensity and rarely lead to treatment discontinuation. An elevation of transaminases (>3 times the upper limit of normal) has been reported in 2.7% of patients, with an adjusted incidence of 1.7 per 100 patients-years of exposure [238]. These studies have not reported any treatment-emergent AEs.

In the longer term, the RECAP study has analyzed the safety data of 1058 participants exposed to pirfenidone for a mean time of 122 weeks (median: 88 weeks; mean dose: 2091 mg/day), for a total of 2482 patients-years of exposure [221] (Table 18). IPF was the most common cause of severe treatment-emergent AEs (none of which were unexpected), treatment discontinuation and death.

The prospective multicenter PASSPORT study [186,232] has included 1009 patients treated with pirfenidone under real-life conditions for a median time of 442 days and has shown the occurrence of a treatment-emergent AE in 73.4% of patients, the more common being nausea (20.6% of patients) and fatigue (18.5%). Treatment-emergent AEs led to treatment discontinuation in 28.7% of patients after a mean time of 99.5 days. A serious treatment-emergent AE was observed in 5.5% of cases and 6 patients died. Treatment discontinuation was less frequent when the dose of pirfenidone was adjusted according to tolerance.

A pooled analysis of the CAPACITY and ASCEND trials has shown a high prevalence of cardiovascular risk factors and treatments for cardiovascular diseases in these patients and, compared to placebo, the absence of any significant increase in the risk of major cardiovascular events and hemorrhages under pirfenidone (1.8% versus 2.9% and 3.7% versus 4.3%, respectively) [241].

Conditions of use

Pirfenidone has been granted a marketing authorization (MA) in most countries worldwide. In France, pirfenidone has a MA since February 28, 2011 for treating mild-to-moderate IPF (FVC \geq 50% and DLco \geq 30%), at the recommended dose of 2403 mg/day (1 tablet of 801 mg or 3 tablets of 267 mg 3 times per day, taken with food). CYP1A2 inhibitors (fluvoxamine, grapefruit juice) as well as enzyme inducers (tobacco, omeprazole) should be avoided as they reduce treatment efficacy.

The clinical experience of the long-term use of pirfenidone has confirmed the results of phase III RCTs in terms of safety and tolerance, with a treatment discontinuation rate of about 15% due to digestive or cutaneous AEs. Practical advice from this cumulative clinical experience greatly facilitates treatment acceptance, tolerance and observance (Table 19) [242]: for example, they allow limiting treatment discontinuation due to photosensitization in a very sunny region [240].

The management of digestive and cutaneous AEs associates a combination or a succession of measures, including dose reduction, temporary treatment discontinuation and use of symptomatic treatments. Individual dose adjustments allow optimizing the efficacy/tolerance ratio [243,244]. In October 2020, the French National Agency for the Safety of Medicines and Health Products (ANSM) has published a warning and new guidelines on the risks of drug-induced liver injury associated with the use of pirfenidone [245]. This notice states that “Serious cases of drug-induced liver injury have recently been reported with ESBRIET (pirfenidone), some of which with a fatal outcome.

Liver function tests (ALT, AST, bilirubin) should be performed before initiating treatment with ESBRIET (pirfenidone). Thereafter, a workup should be performed monthly for the first 6 months of treatment and then every 3 months throughout treatment.

A physical examination and liver function tests should be performed promptly in patients with symptoms suggestive of drug-induced liver injury such as fatigue, anorexia, right upper abdominal discomfort, dark urine or jaundice.

An increase in transaminases may require a dose reduction, treatment interruption or a permanent discontinuation of treatment with pirfenidone. In patients with a significant increase in liver aminotransferases with hyperbilirubinemia or if clinical signs and symptoms

of drug-induced liver injury are present, treatment with ESBRIET (pirfenidone) should be permanently discontinued” [245].

Nintedanib

Nintedanib esylate⁴ is an inhibitor of tyrosine kinases (TKI) involved in pulmonary fibrosis, in particular TKs associated with the platelet-derived growth factor (PDGF), fibroblast growth factor (FGF) and vascular endothelial growth factor (VEGF) receptors [246,247]. It changes fibroblast biology in IPF patients (proliferation, migration, differentiation into myofibroblasts, extracellular matrix production) [247–250].

Efficacy

The TOMORROW phase II RCT has shown that at a dose of 150 mg twice daily (BID), nintedanib was associated, after 12 months of treatment and compared to placebo, with a slower decline in lung function assessed based on the FVC, a decrease in the incidence of acute exacerbations and a stabilization of the QoL assessed using the Saint-George Hospital respiratory questionnaire (SGRQ) score [251].

The INPULSIS-1 and -2 phase III pivotal RCTs have included a total of 1066 patients and compared nintedanib (150 mg BID) to placebo for 52 weeks [252,253]. Eligibility criteria were: FVC $\geq 50\%$ of the predicted value and DLco ranging between 30% and 79% of the predicted value; radiological pattern at least consistent with the diagnosis of IPF according to a central review; FEV1/FVC ratio ≥ 0.7 (without excluding patients showing an emphysema pattern on the CT scan). Patients at high risk of hemorrhage (history of hemorrhage, dual antiplatelet therapy, anticoagulant treatment), and those with a recent history of myocardial infarction or unstable angina were not eligible. The concomitant administration of corticosteroids at a stable dose (prednisone ≤ 15 mg/d or equivalent) was permitted.

At baseline, patients had a mean FVC and a mean DLco of 80% and 47% of the predicted value, respectively. Notably, about 30% of participants had a possible UIP pattern on the CT scan with traction bronchiectasis without lung biopsy confirmation, preventing making formally the diagnosis of IPF according to international criteria, while most of these criteria would now correspond to probable UIP, reflecting a frequent situation in daily practice.

The primary endpoint, i.e. the slope of the annual FVC decline rate, was significantly less with nintedanib than with placebo in both trials, with a mean difference of 109.9 mL/year ($p < 0.001$) in the pooled analysis of both studies [253]. This beneficial effect on respiratory function was confirmed by the analysis of the relevant secondary endpoints (absolute change in percentage of predicted FCV, proportion of patients without decline in predicted FVC $>5\%$ or $>10\%$). The two key secondary endpoints, i.e. the time to the first acute exacerbation of IPF diagnosed by the investigators and the SGRQ score, were statistically significant in the INPULSIS-2 trial, but not in the INPULSIS-1 trial, nor in the pooled analysis of both trials. However, the pooled analysis of the two trials focused on acute exacerbations suspected or confirmed by an adjudication committee has shown a significant decrease in events with nintedanib (HR: 0.32; $p = 0.001$). In terms of mortality, the analysis has suggested a non significant trend towards nintedanib (HR: 0.70; $p = 0.14$).

--

Table 19

Advice for preventing and managing adverse events associated with pirfenidone treatment.

<i>Administration and dosage adjustments</i>	<ul style="list-style-type: none"> • Take the tablets with food, by adjusting intake to eating habits; in case of associated nausea, the morning dose may be reduced or delayed • The main meal of the day may be associated with the intake of up to 801 mg, the other intakes (267 mg or 534 mg) are associated with secondary snacks (the intake will be, if possible, of at least 1602 mg per day, divided into 3 doses) • Treatment initiation includes a phase of progressive dose escalation in successive steps (up to the recommended daily maintenance dose of 2403 mg/d) over 14 days, or even 4 weeks if needed • Consider temporary treatment discontinuation if symptoms do not improve after dose decrease • A new dose escalation after a temporary discontinuation may be more progressive than initially • All treatment decisions should be made in consultation with the patient and with the aim of balancing the objectives of efficacy and quality of life • Prokinetic agents and proton pump inhibitors may be useful
<i>Prevention of photosensitivity</i>	<ul style="list-style-type: none"> • Avoid/limit sun exposure as much as possible, especially in the middle of the day, late afternoon and during very sunny periods; do not forget that UVA may pass through the cloud layer and car glazing • Avoid sun exposure for a few hours after the meal during which pirfenidone has been taken • Protect from sun by wearing covering clothing, wide-brimmed hats, sunglasses, long-sleeved shirts and long pants, gloves for outdoor activities and driving • Apply thoroughly and frequently sunscreens with high anti-UVA and -UVB protection on exposed areas
<i>Management of rashes</i>	<ul style="list-style-type: none"> • In case of rash, reduce the dose of pirfenidone; if the rash persists after 7 days, discontinue treatment for 15 days, and then resume it very progressively after symptom disappearance • If the rashes are related to an allergic mechanism, pirfenidone treatment should be permanently discontinued

AE: adverse event; UV: ultra-violet.

Additional analyzes

A per-protocol analysis of pooled data from INPULSIS-1 and _2 has not shown any significant change in nintedanib efficacy in predefined subgroups [254,255].

A post-hoc analysis has shown that the effect of nintedanib is independent of the presence or the absence of emphysema and that treatment slows down the functional decline both in patients with a FEV1/FVC ratio >0.8 and in those with a FEV1/FVC ratio ≤0.8 [256], or with a FVC ≥90% of the predicted value.

The analysis of the pooled data from the TOMORROW and INPULSIS trials has shown a non-significant trend towards a decrease in all-cause mortality (HR: 0.70; p = 0.095) and in respiratory-related mortality (HR: 0.62; p = 0.078) [257].

The open-label extension study of INPULSIS (INPULSIS-ON) has shown that the slower FVC decline observed with nintedanib was maintained in the medium term (median follow-up: 45 months, maximum: 68 months), regardless of baseline patient characteristics, including the percentage of the predicted FVC [258].

A phase IIIb exploratory RCT (113 patients) [259] has suggested that after six months of treatment, nintedanib (150 mg BID) is associated, compared to placebo, with a lower radiological progression of pulmonary fibrosis, objectively quantified using the QLF (Quantitative Lung Fibrosis) score, the evolution of which in IPF has been correlated with the progression of the respiratory impairment [260,261].

Table 20
Advice for the management of adverse events associated with nintedanib treatment (modified from Corte et al. [275]).

Diarrhea	4–6 additional daily stools or IV infusion <24 h; no impact on daily-life activities	Administer clinically appropriate antidiarrheal treatment (e.g. loperamide, racecadotril)/Administer protective treatment (diosmectite, 3 g per os before each meal) If diarrhea persists for 8 consecutive days despite optimal management
	More than 6 additional stools per day or anal incontinence or IV infusion ≥24 h or requiring hospitalization or impairing daily-life activities	<ul style="list-style-type: none"> • Reduce the dose to 100 mg BID or discontinue treatment until remission (<4 additional stools/day) • The maximum permissible duration of temporary treatment discontinuation is 4 weeks, treatment being resumed at the reduced dose of 100 mg BID • A new dose escalation is possible within 4 weeks following the dose reduction If diarrhea persists/recurs for ≥8 consecutive days despite reduced doses and optimal symptomatic or prophylactic treatment
Increase in AST or ALT liver enzymes	AST or ALT levels [≥3x; <5x] ULN	<ul style="list-style-type: none"> • Discontinue nintedanib and continue monitoring as planned • Discontinue nintedanib and administer clinically appropriate antidiarrheal treatment until remission (<4 additional stools/day) • Consider treatment resumption at a reduced dose of 100 mg BID • If diarrhea persists/recurs for ≥8 consecutive days despite reduced doses and optimal symptomatic or prophylactic treatment • Discontinue nintedanib and continue monitoring as planned Reduce the dose to 100 mg BID or discontinue nintedanib Repeat measurements of AST, ALT +/- alkaline phosphatase levels, total bilirubin level, eosinophil counts after <ul style="list-style-type: none"> • 48–72 h • About 1 week • About 2 weeks If AST and ALT levels are <3 x ULN after 2 weeks <ul style="list-style-type: none"> • Consider returning to 150 mg BID if nintedanib was given at a reduced dose • Resume nintedanib at a reduced dose of 100 mg BID if it was discontinued; a possible new dose escalation is left to the clinician's discretion • Continue monitoring transaminases every 2 weeks for 8 weeks If AST and ALT levels are ≥3 x ULN after ≥2 weeks <ul style="list-style-type: none"> • Permanently discontinue treatment with nintedanib
	AST or ALT levels [≥5x; <8x] ULN	Discontinue treatment with nintedanib Repeat measurements of AST, ALT +/- alkaline phosphatase levels, total bilirubin level, eosinophil counts after <ul style="list-style-type: none"> • 48–72 h • About 1 week • About 2 weeks If AST and ALT levels are <3 x ULN after 2 weeks <ul style="list-style-type: none"> • Resume nintedanib at a reduced dose of 100 mg BID; a possible new dose escalation is left to the clinician's discretion • Continue monitoring transaminases every 2 weeks for 8 weeks If AST and ALT levels are ≥3 x ULN after ≥2 weeks <ul style="list-style-type: none"> • Permanently discontinue treatment with nintedanib
	AST or ALT levels ≥8 x ULN or signs of severe liver impairment	Permanently discontinue treatment with nintedanib Continue monitoring combining laboratory tests (routine biochemistry and hematology, TSH, serology) and abdominal ultrasound

ALT: alanine aminotransferase; AST: aspartate aminotransferase; ULN: upper limit of normal; TSH: thyroid stimulating hormone.

Several post-hoc analyses of the pooled data from the INPULSIS trials have shown the following additional results:

– Disease progression and the effect of nintedanib (compared to placebo) are comparable between patients whose diagnosis of IPF is based on an UIP pattern on the CT scan and/or histopathological examination (68% of patients) and those only showing a probable UIP pattern on the CT scan (absence of honeycombing), without lung biopsy confirmation (32% of patients) [53,54].

– The slower disease progression with nintedanib, compared to placebo, is evidenced by the more favorable evolution of several physiological parameters between baseline and week 52: proportion of patients with improved or no predicted FVC decline, proportion of patients with an absolute decline in predicted FVC $\geq 5\%$ or $\geq 10\%$, the effect on FVC being independent of baseline DLco ($>40\%$ versus $\leq 40\%$) and the composite physiologic index (CPI; ≤ 45 versus >45); there is no significant difference between nintedanib and placebo with regard to the evolution of the predicted DLco, the CPI and the SpO₂ [262].

– The rate of FVC decline on the one hand, and the occurrence of exacerbations on the other hand, correlate with a significant impairment in QoL according to all or part of the assessment scales used in the INPULSIS trials. QoL impairment is particularly marked in patients with an advanced form of IPF at baseline (GAP II/III; DLco $\leq 40\%$, CPI >45 , SGRQ score <40). The benefit of nintedanib compared to placebo is observed in this subgroup of patients, particularly in terms of SGRQ score [263].

The results of subsequent observational studies, that should be interpreted with caution in the absence of randomization, are consistent with those of the RCTs presented above [264–271].

Safety, tolerance

The TOMORROW [251] and INPULSIS [253] trials have shown that the main AEs associated with nintedanib are digestive and dose-dependent AEs: diarrhea ($>60\%$ of patients), nausea ($>20\%$) and vomiting, and elevated transaminases. Most of these AEs were mild or moderate and led to permanent treatment discontinuation in less 5% of cases. Digestive AEs could be promoted by a low BMI, an impaired general status and the administration of maximum doses of nintedanib, while prednisolone could limit the onset of diarrhea [272].

Extended open-label follow-up studies of patients included in the TOMORROW and INPULSIS (INPULSIS-ON) trials suggest that this safety profile remains stable in the long term (median exposure duration of about 45 months in INPULSIS-ON) [257,258,273].

A study has retrospectively analyzed the pooled data from TOMORROW and INPULSIS according to the baseline level of cardiovascular risk of patients, distinguishing high-risk patients (history of major cardiovascular event [MACE] and/or presence of ≥ 1 cardiovascular risk factor(s); 90% of patients), and low-risk patients (absence of MACE and cardiovascular risk factor). No significant difference was observed between nintedanib and placebo in terms of MACE incidence in participants with a low-to-moderate baseline risk. Similarly, no difference was observed for myocardial infarction and other ischemic heart diseases, assessed separately [274].

Table 21
Pirfenidone and nintedanib: synthesis for the practice.

	Pirfenidone*	Nintedanib*
Indication	Confirmed IPF with FVC \geq 50% and DLco \geq 30%	Confirmed IPF with FVC \geq 50% and DLco \geq 30%
Diagnostic criteria for IPF used in trials	Strict	Patients with criteria for possible UIP, with traction bronchiectasis without honeycombing and without histopathological confirmation
Primary endpoint	Decline in FVC	Slope of FVC decline
Secondary endpoints	6MWT All-cause mortality at 1 year (pooled analysis) Cough	Acute exacerbations (adjudicated) Quality of Life (FVC <70%)
Tolerance	Nausea, digestive disorders Photosensitivity Fatigue, sleep disorders Weight loss	Diarrhea Nausea Weight loss
Recommended dose	3 tablets of 801 mg or 9 tablets of 267 mg/d given in three doses during a meal	2 capsules of 150 mg/d during a meal
Monitoring	Liver function tests (e.g., before treatment, and then every month for 6 months and every 3 months thereafter).	Liver function tests (e.g., before treatment, and then every month for 6 months and every 3 months thereafter).
Prescription	Hospital pulmonologist Exception drug	Hospital pulmonologist Exception drug
Medical benefit	Moderate	Moderate
Added medical benefit MA	Minor (AMB IV) 28/02/2011	Minor (AMB IV) 16/01/2015
Main interactions	<ul style="list-style-type: none"> CYP1A2 inhibitors: fluvoxamine (contraindicated), grapefruit juice, ciprofloxacin, amiodarone, propafenone Other CYP inhibitors: fluoxetine, paroxetine, chlormaphenicol CYP1A2 (or other CYP) inducers: tobacco, omeprazole**, rifampicin 	<ul style="list-style-type: none"> P-gp inhibitors: ketoconazole, erythromycin, ciclosporin P-gp inducers: rifampicin, carbamazepine, phenytoin Pirfenidone
Contraindications	Hypersensitivity/angioedema to pirfenidone Treatment with fluvoxamine Severe liver or kidney failure Tobacco strongly discouraged Child-Pugh C cirrhosis Severe renal failure (creatinine clearance <30 mL/min) Caution in case of Child-Pugh A or B cirrhosis or mild-to-moderate renal failure (creatinine clearance at 30–50 mL/min)	Hypersensitivity to nintedanib or soy Avoid if anticoagulant treatment, high-dose antiplatelet therapy, hemorrhagic risk, or ischemic heart disease Child-Pugh B or C cirrhosis Severe renal failure (creatinine clearance <30 mL/min)
Summary of product characteristics	https://www.ema.europa.eu/en/documents/product-information/esbriet-epar-product-information_fr.pdf	https://www.ema.europa.eu/en/documents/product-information/ofev-epar-product-information_fr.pdf

*For more information, see the summary of product characteristics.

**Other proton pump inhibitors may be used.

MA: marketing authorization; AMB: added medical benefit; FVC: forced vital capacity; DLco: diffusing capacity for carbon monoxide; IPF: idiopathic pulmonary fibrosis; P-gp: p-glycoprotein; MB: medical benefit; 6MWT: 6 min walk test.

Observational studies have not shown any unexpected data regarding drug tolerance or safety [264–271].

Conditions of use

Nintedanib has been granted aMA for the treatment of IPF in most countries worldwide. In France, the MA has been obtained on January 16, 2015, and nintedanib is reimbursed for treatment of mild-to-moderate forms of IPF (FVC \geq 50% and DLco \geq 30%). The recommended dose is 150 mg BID, 12 h apart, taken with food.

Digestive AEs, including diarrhea, are manageable in practice using a strategy combining dose reduction, or even temporary discontinuation of nintedanib, and symptomatic treatment (rehydration, antidiarrheal, antiemetic treatment; Table 20) [275]. Except in patients with severe intolerance, after symptom resolution, treatment may be resumed at a reduced dose of 100 mg BID or at the maximum recommended dose of 150 mg BID. Dose adjustments most often allow continuing treatment, and would be more often needed in patients with slight build [276]. Liver enzyme levels should be measured before initiating treatment and then periodically during its administration. Due to its mode of action (VEGF receptor inhibition), nintedanib should be used with caution in patients at increased risk of hemorrhage (hemorrhagic history, dual antiplatelet therapy, anticoagulant treatment) or gastrointestinal perforation. The concomitant administration of ketoconazole significantly increases the exposure to nintedanib, while that of rifampicin decreases it.

In practice

The comparison of the main practical features of pirfenidone and nintedanib is shown in [Table 21](#).

Antifibrotic treatment (by either molecule) improves patient survival in cohort- and register-based studies [[277–281](#)]. Safety data from observational studies are comparable to data from clinical trials.

No study has assessed whether pirfenidone or nintedanib may cause healing problems in case of surgery. The hemorrhagic risk related to the anti-angiogenic activity of nintedanib is poorly understood in case of surgery. In practice, most teams temporarily discontinue antifibrotic treatment shortly before and up to about three weeks after scheduled major surgery; the practice varies according to lung transplantation teams (in one study, treatments were maintained until transplantation without any particular complication) [[282](#)].

In addition, many new drugs are currently being assessed [[283,284](#)]: in this respect, in case of failure of or intolerance to approved drugs, or in circumstances other than the MA of approved drugs, it is important to refer patients to study sites (reference centers, expert centers) to consider inclusion in these studies, including in studies assessing the effect of combined treatment with pirfenidone and nintedanib or other dual therapies.

When to initiate treatment?

There is currently no specific guideline regarding when antifibrotic treatment should be initiated. In practice, most experts initiate it as soon as the diagnosis of IPF is confirmed. In asymptomatic patients or in patients with preserved respiratory function at the time of diagnosis, an initial observation time before treatment initiation is sometimes proposed because, at this stage, the AEs associated with treatments may exceed their clinical benefits. However, it has been shown that even in patients with preserved lung function, the disease irreversibly worsens, at the same rate, and treatments have the same benefit on FVC decline [[254,285,286](#)].

In the post-hoc analysis of the CAPACITY and ASCEND trials, the effect of pirfenidone on the score of dyspnea was significant compared to placebo in the subgroup of patients who had, at the time of randomization, a FVC \leq 80% or a GAP score II-III, but not in patients with a FVC $>$ 80% or a GAP score I [[285](#)]. In the post-hoc analysis of the INPULSIS trials, nintedanib was associated with a smaller increase in SGRQ score for the QoL in the treated group compared to the placebo group in patients who had, at the time of randomization, a FVC \leq 70%, but there was no difference between nintedanib and placebo in patients with a FVC $>$ 70% [[254](#)]. These findings suggest that the effect of treatment on QoL deterioration and dyspnea worsening is observed in patients whose disease is accompanied by a functional limitation, and may participate in the therapeutic decision. There are insufficient data to recommend treatment initiation in patients with FVC $<$ 50% of the predicted value and/or DLco $<$ 30% of the predicted value, but the data available suggest that treatment efficacy would be comparable [[220,273,287–298](#)], and the indication may be discussed during a MDD.

The choice of first-line treatment (pirfenidone or nintedanib) takes into account the parameters shown in [Table 21](#), in particular with regard to tolerance, drug interactions and comorbidities. The clinicians' experience and preference of patients informed of the expected benefit (including for dyspnea and QoL) and possible AEs of treatments are also taken into account in the decision.

Guideline 18. In patients with a confirmed diagnosis of mild-to-moderate IPF (defined by a forced vital capacity $\geq 50\%$ of the predicted value and a diffusing capacity for carbon monoxide $\geq 30\%$), it is recommended to propose treatment with an antifibrotic agent (pirfenidone or nintedanib).

– This treatment should be initiated and monitored by a pulmonologist experienced in the diagnosis and treatment of IPF and requires regular monitoring of clinical tolerance and liver biology.

– The patient should not smoke during treatment with pirfenidone.

Guideline 19. It is recommended to treat IPF as soon as the diagnosis is made, taking into account the individual assessment of the expected benefit and risks of treatment.

Treatment combinations

Combined treatments with pirfenidone and nintedanib, or even this dual therapy supplemented by one of the new antifibrotic agents being studied, is one of the main avenues for improving IPF treatment [\[299\]](#).

However, in the absence of sufficient data, the pirfenidone-nintedanib combination is not currently recommended outside of a clinical research setting.

Two studies have assessed the pharmacological interactions between these two agents [\[300,301\]](#), and have not shown any significant pharmacokinetic interaction between nintedanib and pirfenidone when given in combination. The clinical effects of dual therapy have been tested in two trials, including a RCT [\[302,303\]](#). As the safety profiles of both drugs are similar, an additive effect is expected on the risk of AEs, including gastrointestinal and liver disorders. These data are too preliminary to recommend the combination of nintedanib and pirfenidone in clinical practice. It is currently being studied in the PROGRESSION-IPF trial [\[304\]](#).

What to do in case of disease progression under antifibrotic treatment?

In the current state of knowledge, the best approach to adopt in case of disease worsening despite the use of antifibrotic treatment remains unknown:

– The disease pathophysiology and data with a low level of evidence suggest that treatment continues to be effective, even if insufficient to fully stabilize the disease [\[218\]](#). It is therefore legitimate to continue treatment without change if it is well tolerated.

– It is possible to switch from one antifibrotic agent to another, but without being able to predict the tolerance of new treatment, and in the absence of data showing that this switch may be clinically beneficial.

– Treatment combination is likely to be less well tolerated than monotherapy, with no certainty of benefit, and is not currently recommended.

These three approaches are the subject of an ongoing therapeutic trial [304].

Table 22
Antifibrotic treatments not recommended in patients with a confirmed diagnosis of idiopathic pulmonary fibrosis.

Treatments that are not recommended for IPF (poor efficacy)	Treatments that are recommended not to be prescribed for IPF (risk of serious harmful effects)
<ul style="list-style-type: none"> • Endothelin-1 receptor A and B antagonist <ul style="list-style-type: none"> ◦ Bosentan [305,306] ◦ Macitentan [307] • N-acetylcysteine-pirfenidone combination [308] • Nintedanib-sildenafil combination [309] • Corticosteroid therapy >15 mg/d (with or without immunosuppressant, apart from an acute exacerbation of fibrosis) [254,310,312–314,572]* • Cyclosporin [315,316] • Colchicine [310,317–319] • Cotrimoxazole [320–322] • Doxycycline [322] • Etanercept [323] • ACE inhibitors, angiotensin II receptor antagonists [324] • Interferon-gamma-1b [325,326]. • N-acetylcysteine [327,328] 	<ul style="list-style-type: none"> • Endothelin-1 receptor A antagonist <ul style="list-style-type: none"> ◦ Ambrisentan [329] • Prednisone-azathioprine-N-acetylcysteine combination [327] • Anticoagulant treatment with warfarin [330,331]

*Except at a low dose (10 mg/day) for treatment of chronic disabling cough with assessment of the benefit/risk ratio of this prescription.

Table 23
Idiopathic pulmonary fibrosis/interstitial lung disease: indications of lung transplantation (from Weill et al. [337]).

When to refer patients to a transplant center?	When to register patients on the waiting list?
Histology of UIP or fibrosing NSIP, regardless of the results of PFT	Decline in FVC $\geq 10\%$ in 6 months (a decline $\geq 5\%$ is associated with a poor prognosis and could justify a registration)
FVC <80% or DLco <40%	Decline in DLco $\geq 15\%$ in 6 months
Dyspnea or functional limitation due to the disease	Desaturation <88% or distance <250 m in 6 min, or decrease >50 m during the 6MWT in 6 months
Need for oxygen therapy even during exercise	PH during right heart catheterization or on echocardiography
For inflammatory ILD, no improvement in dyspnea, oxygen requirements and/or lung function under medical treatment	Hospitalization for respiratory worsening, pneumothorax or acute exacerbation

FVC: forced vital capacity; DLco: diffusing capacity for carbon monoxide; pH: pulmonary hypertension; UIP: usual interstitial pneumonia; ILD: interstitial lung disease; NSIP: non-specific interstitial pneumonia; 6MWT: 6 min walk test.

Non-recommended antifibrotic treatments

An unfavorable conclusion has been issued against many agents assessed as antifibrotic treatment in patients with IPF, due to insufficient efficacy and/or a proven excess risk of harmful effects. Therefore, their prescription is not recommended, or even it is recommended not to use them, respectively. The findings supporting these recommendations were presented in detail in the previous version of these guidelines [3]. We will therefore solely mention them (Table 22) [305–331] and briefly recall a few points of particular interest, in particular the risks associated with treatments the use of which is not recommended.

Triple therapy combining prednisone, azathioprine and N-acetylcysteine exposes to the risk of a significant increase in overall mortality and unplanned hospitalizations compared to placebo, with no significant difference in terms of respiratory function measured through the FVC [327].

Oral corticosteroids not exceeding 10 mg per day of prednisone are sometimes proposed for their effect on cough when it is disabling (see below) [332]. High-dose corticosteroids are proposed in case of acute exacerbation (see below) [21]. It should be noted that in therapeutic trials that have validated the use of pirfenidone and nintedanib (see above), the use of low doses of prednisone (<15 mg/d) was possible in combination with these drugs; the a posteriori

analyses have not shown any interaction with the beneficial effect of these agents and have not suggested the existence of a benefit associated with corticosteroids themselves.

Compared to placebo, warfarin is associated with excess mortality and a high incidence of AEs, with no benefit on disease progression [330]. This excess risk is not related to an increase in hemorrhagic events. Vitamin K antagonists also have a deleterious effect on survival when used in an indication other than IPF [331]. There is no data available on the effect of direct oral anticoagulants in IPF.

Among endothelin-1 receptor A and B antagonists, bosentan [305,306] and macitentan [307] have shown insufficient efficacy, while ambrisentan is explicitly contraindicated due to an AE, compared to placebo, in terms of time to death or respiratory function worsening and a higher rate of hospitalizations for respiratory complications [329].

The INSTAGE randomized trial has assessed the effect of the combination of nintedanib (150 mg BID) with sildenafil (20 mg x 3 times/ day), compared to nintedanib alone, in IPF patients with a DLco \leq 35% of the predicted value, and has not shown any significant difference in SGRQ score at week 12 (primary endpoint) or in dyspnea [309].

Angiotensin-converting enzyme (ACE) inhibitors and angiotensin II receptor antagonists are not useful for the management of IPF, but their prescription is not a problem if they are indicated for a comorbidity.

Guideline 20. In patients with a confirmed diagnosis of IPF, it is recommended not to initiate treatment with oral corticosteroids (with or without immunosuppressant) apart for treating an acute exacerbation of fibrosis or symptomatic treatment of cough (see guidelines 27 and 33).

Guideline 21. In patients with a confirmed diagnosis of IPF, it is recommended not to initiate the following treatments:

- _ Triple therapy with prednisone, azathioprine and N-acetylcysteine;
- _ Oral treatment with a vitamin K antagonist, apart from a recognized indication, in particular a cardiovascular disease (there is no data available on direct oral anticoagulants in IPF);
- _ Ambrisentan, riociguat even in the presence of pulmonary hypertension.

Lung transplantation

The data available show that lung transplantation improves survival of patients with advanced IPF [333–335]. However, as shown by the data from the International Society for Heart and Lung Transplantation (ISHLT) register, the results in IPF are significantly worse than in cystic fibrosis or PH [336].

In terms of indications, a consensus of the ISHLT suggests to split the problem into two questions [337] (Table 23):

- _ When should patients with IPF be referred to a transplant center for evaluation?

_ When should patients be registered on a waiting list?

Schematically, these recommendations call to perform early the assessment in a specialized center, and to register the patient on a waiting list in case of objective disease worsening.

The age by itself is not a contraindication to transplantation [337]. The age limit of about 65 years (physiological age) is relative and should take into account comorbidities. Between the age of 65 and 70, transplantation may be considered in the absence of significant comorbidities. The choice between mono- or bipulmonary transplantation is not unanimous. Compared to monopulmonary transplantation, bipulmonary transplantation has the advantage of leading to a better functional outcome, is associated with a lower cancer mortality rate but also with a higher risk of primary graft dysfunction, with no significant difference in long-term survival between both techniques [338].

In France, there is a super-emergency transplantation procedure giving priority access to a graft for 15 days in case of acute respiratory failure, i.e. in case of intubation or hypoxemia poorly corrected under 12 l/min oxygen therapy. It is intended for patients already registered on the waiting list or who have completed a pretransplant assessment ruling out contraindications to transplantation (or comorbidities that would compromise the prognosis of transplantation).

Extracorporeal membrane oxygenation (ECMO) may be used for this purpose. The outcomes of transplantation after ECMO are almost comparable to those of transplantation under usual conditions. A patient not previously assessed by a transplant team cannot undergo emergency or super-emergency transplantation in case of acute worsening.

Guideline 22. In patients with a confirmed diagnosis of IPF, it is recommended to inform them early about the possibility of lung transplantation, unless there is an obvious contraindication to this treatment.

Guideline 23. In patients with a confirmed diagnosis of IPF, it is proposed to assessed them early in a lung transplant center, unless there is an obvious contraindication to this treatment.

Guideline 24. In patients with a confirmed diagnosis of IPF and aged under 65, it is recommended to consider lung transplantation in severe forms or in case of disease worsening.

_ **Between the ages of 65 and 70, this treatment may be considered in the absence of comorbidity deemed significant by a transplant center.**

Lung transplantation and genetic IPF

A mutation in one of the telomere-related genes (see above) significantly increases the risk of mortality after lung transplantation: this finding shows the importance of investigating the presence of clinical and biological signs (cytopenia, abnormal liver function tests) supporting familial or genetic pulmonary fibrosis during the pre-lung transplant assessment, and to screen for a mutation if needed. Lung transplantation is not contraindicated in this situation, but patients should be informed of the increased risk and it should be discussed together, assessed

hematologically (detection of a hematological anomaly, specialized hematological opinion) and hepatologically. Azathioprine should be avoided.

Guideline 25. In patients with a confirmed diagnosis of IPF, it is recommended to investigate the presence of clinical and biological signs supporting familial or genetic pulmonary fibrosis during the pre-lung transplant assessment.

Lung transplantation and pulmonary hypertension

PH is commonly found during the pre-transplant assessment and transplantation itself [339]. Neither its presence [340] nor its severity [339] is associated with increased mortality after transplantation. PH should be considered as a sign supporting transplantation and not as a contraindication [337], but a right heart function assessment is essential during the pre-transplant assessment.

Transplantation and antifibrotic agents

The inhibitory effect of antifibrotic agents on fibroblast metabolism is associated with a predicted risk of wound healing disorders. In addition, nintedanib may increase the risk of hemorrhage due to its effect on VEGF. However, to date, such complications have not been described after transplantation [341,342], while antifibrotic treatment discontinuation exposes patients to the risk of accelerated disease progression. In practice, it is currently accepted to continue antifibrotic treatment until the transplant.

Other medical treatments

Vaccines

No specific study has assessed the effect of these vaccines in the context of IPF. However, it is very likely that, like other patients with chronic respiratory disease, patients with IPF are at high risk of death if they develop pneumococcal or influenza infection. Despite the absence of evidence, pneumococcal vaccination may be given using the 13-valent pneumococcal polysaccharide conjugate vaccine (Prévenar 13™) supplemented two months later with the 23-valent pneumococcal polysaccharide vaccine (Pneumo 23™).

Patients with IPF or other fibrosing ILD are more vulnerable to SARS-CoV-2 infection, and have an increased mortality compared to a control population in case of COVID-19 [343,344]. In a multivariate analysis, the factors associated with mortality are the age, the male gender, a history of cancer or hematological disease, and the use of oxygen at home (i.e., ILD with chronic respiratory failure), while the type of ILD is not [345]. In other words, the prognosis of SARS-CoV-2 infection is poorer in the fibrosing forms of ILD, but this is explained by the age and comorbidities. Treatments received before infection to treat ILD do not seem to influence the evolution [343–345].

Vaccination against SARS-CoV-2 is recommended in IPF patients, for which they should be given priority. To date, the diagnosis of IPF does not change the choice of vaccine, which depends on availability, population-wide strategies, and the age of the subject. In case of COVID-19 in a patient with IPF, it is recommended to continue antifibrotic treatment if needed.

Guideline 25. It is recommended that patients with a confirmed diagnosis of IPF be advised to be vaccinated against influenza virus, pneumococcus, and SARS-CoV-2, according to current vaccination schedules.

Symptomatic treatments

Cough

The mechanism of cough is variable in IPF: bronchial distortion, airway inflammation, bronchial hypersensitivity, and gastroesophageal reflux disease (GERD) may be involved [346]. Possible therapeutic approaches are based on this mechanism.

Symptomatic treatments are generally quite ineffective on cough in IPF but may be tested. A recent trial that has assessed gefapixant (P2£3 receptor antagonist for cough) has shown negative results [347]. Limited data suggest that moderate-dose oral corticosteroids (not exceeding 10 mg/d of prednisone) may alleviate chronic cough associated with IPF [332,348,349]. This effect is variable. The prolonged prescription of high-dose corticosteroids (>15 mg/d) is not recommended due to a risk of disease worsening [327]. This shows the importance of objectively assessing treatment efficacy (cough severity visual analog scale before and after treatment) and knowing how to discontinue corticosteroid treatment if it is not effective. A therapeutic test with an inhaled corticosteroid for four weeks may be attempted to manage a mechanism of bronchial hypersensitivity. Gabapentin is sometimes suggested to treat a neurogenic component of cough.

Although GERD is common in IPF, a RCT conducted in 18 patients has failed to show any beneficial effect of anti-reflux treatment on cough [350]. Another randomized study assessing omeprazole at a dose of 20 mg BID in 55 patients has shown a 39% decrease in recorded cough events compared to placebo. Patients usually treated with a proton pump inhibitor (PPI), and whose reflux symptoms did not relapse over a two-week withdrawal period before randomization, could participate in this trial [351]. This trial does not allow drawing a definitive conclusion. Omeprazole should be avoided in combination with pirfenidone, but other PPIs may be used. Baclofen may be useful in addition to PPIs to act on non-acid reflux contributing to chronic cough.

An open-label study has shown that in subjects with significant cough in IPF, pirfenidone reduces cough documented by a 24-hour recording, without however improving the QoL [237]. There are no data available on the potential effect of nintedanib on cough.

Expert guidelines based on the CHEST method [346] propose to:

- _ Investigate underlying disease progression, the presence of respiratory infection, or a drug cause;
- _ Investigate GERD clinically and/or by pH-metry, and not to prescribe a PPI when absent;
- _ Suggest a gabapentin test [352] and respiratory rehabilitation techniques;

_ Prescribe symptomatic treatment with low-dose morphine (5 mg of prolonged-release morphine sulfate every 12 h given orally).

Guideline 26. In patients with a confirmed diagnosis of IPF and with disabling cough, it is proposed to:

_ Investigate underlying disease progression, the presence of respiratory infection, or a drug cause;

_ Investigate the presence of gastroesophageal reflux disease and prescribe a proton pump inhibitor if present;

_ Prescribe respiratory rehabilitation techniques;

_ Possibly prescribe low-dose oral corticosteroids (e.g., 10 mg/d of prednisone equivalent), with assessment of its efficacy and tolerance;

_ Possibly prescribe treatment with gabapentin, with assessment of its efficacy and tolerance;

_ Possibly prescribe low-dose morphine treatment, with assessment of its efficacy and tolerance.

Dyspnea

Dyspnea is a major component of impaired QoL in IPF. It is closely associated with cough, anxiety and depression, respiratory function decline, and is predictive of mortality [353–358]. Over time, QoL deterioration and symptoms evolve in parallel with the decline in FVC [263]. Among patients with a FVC < 70%, nintedanib slows down dyspnea deterioration compared to placebo [263].

When possible, respiratory rehabilitation is the most effective non-drug treatment for improving exertional dyspnea [359–364].

Oxygen therapy during exercise may improve exertional dyspnea and exercise capacity (see below).

Morphine derivatives should be given at low doses (10–30 mg/ day) orally and not nebulized [365,366]. Higher-dose morphine derivatives (>30 mg/day of morphine equivalent) may sometimes be used in case of significant dyspnea, but with very careful monitoring of their AEs, in particular respiratory depression [367,368].

Guideline 27. In patients with a confirmed diagnosis of IPF and with painful dyspnea, it is suggested to prescribe low-dose morphine derivatives, with assessment of their efficacy and monitoring of their tolerance (in particular drowsiness and risk of respiratory depression).

Oxygen therapy

Indirect evidence of a beneficial effect of oxygen therapy is suggested in studies that have included patients with obstructive pulmonary disease [369,370]. By extrapolation, long-term oxygen therapy is usually recommended by the American Thoracic Society in serious chronic respiratory failure [371]: PaO₂ ≤ 55 mmHg (7.3 kPa, i.e. SaO₂ ≤ 88%) measured twice at rest in steady state; or PaO₂ ranging between 55 and 60 mmHg (7.3–8.0 kPa) in the presence of at least one of the following criteria: polycythemia (hematocrit > 55%), signs of PH or right heart failure (lower extremity edema), documented signs of right heart failure.

The role of ambulatory oxygen therapy in IPF is now better known. Several uncontrolled studies have suggested a benefit on exercise capacity [372–375]. According to a double-blind RCT comparing ambulatory oxygen therapy to ambient air, it appears to improve exercise capacity but the benefit on dyspnea is uncertain and varies from one patient to another [376]. A more recent crossover trial [377] has assessed the benefit of ambulatory oxygen therapy in patients with fibrosing ILD with exertional dyspnea and desaturation ≤88% during the 6MWT but without resting hypoxemia. The K-BILD (King's Brief Interstitial Lung Disease questionnaire) score for the QoL, the dyspnea score and the activity score were significantly improved by oxygen therapy, with no change in the psychological domain of the questionnaire.

A management algorithm has been proposed based on a consensus using the Delphi method [378]. The majority of experts recommended ambulatory oxygen therapy below a desaturation threshold of 80%, and in case of desaturation at 85–89% associated with symptoms or exercise limitation improving on oxygen due to hypoxemia [378]. According to a small exploratory RCT that has included patients with an exercise-induced desaturation (6MWT) <90%, the effect of ambulatory oxygen therapy given for 12 weeks is comparable to that of ambient air in terms of distance walked during the 6MWT, higher for cough-related QoL, and lower for moderate-to-vigorous exercise duration [379,380].

The decision to implement long-term oxygen therapy should however be carefully considered if the indication is symptomatic, because it is associated with a poorer QoL [202], and the fact of having to move the oxygen device may limit the distance walked [381].

Guideline 28. It is proposed to prescribe long-term oxygen therapy for at least 15 h per day in patients with a confirmed diagnosis of IPF and with serious chronic respiratory failure, defined by a PaO₂ ≤ 55 mmHg (7.3 kPa) at rest or a SpO₂ ≤ 88% on pulse oximetry, or a PaO₂ ranging between 56 and 60 mmHg (7.5–8.0 kPa) or a SpO₂ ≤ 89% in the presence of at least one of the following criteria: polycythemia (hematocrit > 55%), signs of pulmonary hypertension, documented signs of right heart failure, non-apneic nocturnal desaturations.

Guideline 29. It is proposed to use ambulatory oxygen therapy in patients with a confirmed diagnosis of IPF and with exercise-induced desaturation <80%, or exercise-induced desaturation <85–89% associated with significant exertional dyspnea or exercise limitation improving on oxygen.

Respiratory rehabilitation

The majority of studies assessing respiratory rehabilitation are not randomized. Five RCT have shown an improvement in distance walked et/or dyspnea and/or QoL in patients with IPF following a supervised respiratory rehabilitation program [359–363,382–386]. The efficacy of respiratory rehabilitation most often persists for up to six months if physical activity maintenance is supervised [387], but tends to decline thereafter [385]. The maintenance of the efficacy in the longer term is discussed and not found in most studies.

The beneficial effects of respiratory rehabilitation would be more marked in patients with an advanced form of IPF or a greater exercise limitation [388]. However, in other studies, the improvements in the 6MWT were more marked or more sustained when the disease was less severe [389]. The beneficial effects of respiratory rehabilitation would be less pronounced than in chronic obstructive pulmonary disease (COPD) [390]. In a cohort of 402 patients with ILD (including IPF), respiratory rehabilitation was followed by a mean improvement in 6MWT distance by 46 § 3 m, and an improvement in a physical and mental health score (SF-36), with no change in dyspnea score [391].

Not all patients with IPF may be treated with respiratory rehabilitation. Its modalities remain to be specified; it may include exercise training, smoking cessation, psychosocial support, and supportive care. It may be performed at home and may improve the QoL in this context [392]. The indications take into account the functional (respiratory, cardio-circulatory and muscle) impairment measured through the maximum oxygen consumption and/or 6MWT, and the dyspnea-related disability and associated QoL degradation (limitations of activities of daily living and reduced participation in these activities such as walking). In all cases, patients should be encouraged to maintain or preserve appropriate and regular physical activity, which can be guided by the physiotherapist.

Guideline 30. It is proposed to prescribe a respiratory rehabilitation program in patients with a confirmed diagnosis of IPF and with a limited capacity to exercise and/or disabling dyspnea. Respiratory rehabilitation can be performed with ambulatory oxygen therapy if indicated (see guideline 30).

Holistic management

According to the World Health Organization (WHO) International Classification of Functioning, Disability and Health, the impact of chronic lung diseases includes an impairment of normal physical and social activities [393]. Respiratory rehabilitation programs have a well-demonstrated beneficial effect in improving the physical and psychological condition of patients with COPD: a growing body of evidence shows that this is also the case in IPF.

Therapeutic education aims to improve compliance, smoking cessation, self-managed care, the management of exacerbations and, more particularly, a physically active lifestyle. In this regard, it is essential to customize the program in order to facilitate a successful transition from supervised pulmonary rehabilitation to that of everyday life at home.

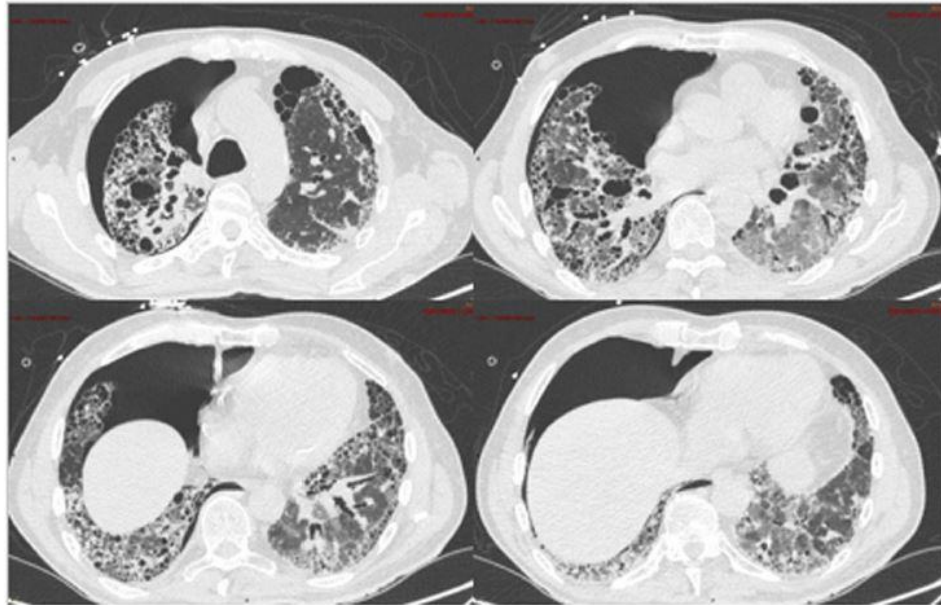


Fig. 16. Parenchymal window of the chest CT scan in a patient with an acute exacerbation of idiopathic pulmonary fibrosis and complete right pneumothorax. Presence of diffuse ground-glass opacities, associated with reticulations and traction bronchiectasis.

Anxiety, depression, panic disorder, death-related anxiety are common in patients with chronic lung disease. Rehabilitation programs effectively reduce this suffering and thereby significantly improve the QoL [394]. Better communication with patients and their caregivers helps to understand their expectations. For example, a survey has shown that patients with IPF are aware of their disease and its prognosis, but are less well informed about its progression and management [395]. Patients highlight the psychological and emotional impact of the disease, which affects their QoL, and the need for support [396]. The nature of patients' need for information changes during the disease course [397].

As soon as the diagnosis is made, a request for long-term illness (LTI) exonerating the user fees should be made. This may be a LTI listed for serious chronic respiratory failure, in case of restrictive syndrome with $\text{PaO}_2 < 60$ mmHg and/or $\text{PaCO}_2 > 50$ mmHg remote from an acute episode; restrictive syndrome with total lung capacity $< 60\%$ of the normal predicted values; or SaO_2 dropping below 90% during a 6MWT; or an off-list LTI for IPF if it requires expensive treatment.

In this context, a medico-social assistance is useful: a set of medico- social support advice is compiled in the brochure entitled "Living with a rare disease in France. Aids and benefits for people with rare diseases and their relatives (family caregivers/caregivers)" updated in December 2020, and available on orpha.net (https://www.orpha.net/orphacom/cahiers/docs/FR/Vivre_avec_une_maladie_rare_en_- France.pdf).

Acknowledging the role of caregivers and supporting them In addition to the patients, their day-to-day caregivers may require support: thus, 31% of caregivers (defined as people who regularly and frequently assist, on a non-professional basis, in performing all or part of the acts or activities of daily life of a person losing his/ her autonomy due to age, illness or disability) neglect their own health. A strategy for mobilizing and supporting caregivers has been implemented at the government level to acknowledge their role and improve their QoL (see <https://www.gouvernement.fr/aidants-unenouvelle-strategie-de-soutien>).

Palliative care

The palliative care approach is still underdeveloped in IPF and palliative care of patients with IPF needs to be developed and structured in France [398]. Compared to patients with cancer, patients with ILD are less managed in palliative care facilities, and their dyspnea is more severe [399]. The use of palliative care facilities for ILD is insufficient. Most patients die in hospital [400].

A randomized study has shown that the collegiate discussion of palliative or supportive care is symptomatically and psychologically acceptable and beneficial [401]. Advance directives of patients with IPF should be collected.

Low- or high-dose morphine derivatives and low-dose benzodiazepines may be used to treat symptoms at the palliative care stage [368]. High-flow oxygenation could be interesting in end-of-life situations, but it is often poorly effective on dyspnea [402].

The potential benefit of specialized palliative care is poorly understood by patients and their caregivers [403]. As the disease progresses, patients and caregivers often underestimate the seriousness of the prognosis [404]. A therapeutic trial is ongoing in France to assess the benefits [405].

Guideline 31. In patients with a confirmed diagnosis of IPF, it is proposed to involve a palliative care specialist in the management of symptoms and end of life.

Complications and comorbidities

Acute exacerbations

Diagnosis

According to the international definition [11], an acute exacerbation of IPF is a clinically obvious acute respiratory deterioration for less than 1 month, due to a parenchymal cause, with a bilateral ground glass appearance (Fig. 16) possibly associated with consolidations on imaging. It may be classified as an idiopathic exacerbation or a triggered exacerbation (by an infection, a diagnostic procedure, a drug cause, an inhalation). In rare cases, the acute exacerbation is indicative of the disease. Acute respiratory worsening is a sign of poor prognosis, even when it has an underlying cause, if it requires a hospitalization [406]. The prognosis of acute exacerbations is poor, with a mortality rate at 3 or 4 months of about 50% [11,407].

Established risk factors include advanced respiratory disease (low DLco, decreased distance walked, PH, hypoxemia, significant dyspnea, recent decline in FVC, high GAP score) [408, 409] and other clinical factors (young age, coronary artery disease, high BMI and history of acute exacerbation), corticosteroid therapy, and the presence of fibroblast foci on biopsy [410,411]. The risk of exacerbation is increased during ozone and nitrogen dioxide pollution peaks [412,413].

CT angiography is essential to rule out pulmonary embolism. The examination also allows ruling out pneumothorax or infectious lung disease. CT angiography does not always allow optimally studying the infiltrating lung disease and identifying the ground glass, because it is

generally performed at free breathing, and the injection of contrast media or the risk of Valsalva maneuver may slightly alter the lung parenchyma density. Additional high-resolution thin section images should be acquired at deep inspiration as a complement in case of insufficient parenchymal study to analyze the opacities added to the previous anomalies, in particular ground-glass opacities.

Additional investigations to identify the cause of respiratory worsening are listed in [Table 24](#).

In this context, VATS lung biopsy is associated with a very high risk and is contraindicated; it would show diffuse alveolar damage associated with an UIP pattern (sometimes associated with lesions of organizing pneumonia) [36].

Guideline 32. In patients with a confirmed diagnosis of IPF, it is recommended to investigate if an acute exacerbation of IPF is present in case of recent worsening of dyspnea for less than one month, that is not related to an extra-parenchymal cause (e.g., pneumothorax, pleurisy, pulmonary embolism), associated with new bilateral ground-glass opacities on imaging, that are not fully explained by heart failure or sodium and water overload.

_ A triggering factor should be investigated (infection, diagnostic procedure, drug-related cause, inhalation).

Table 24
Additional examinations performed in case of acute exacerbation of IPF.

Systematic	<ul style="list-style-type: none"> • C-reactive protein, D-dimer, NT-proBNP assays • Non-contrast chest CT scan, acquired in full inspiration with millimeter sections (to assess ground-glass opacities), followed by CT angiography for the detection of pulmonary embolism (if positive results for D-dimers) • Arterial blood gas test at rest (because hypoxemia worsening [decrease by 10 mmHg in PaO₂] is usual) • Echocardiography if NT-proBNP levels are abnormal • Cytobacteriological examination of the sputum • Detection of respiratory viruses in nasopharyngeal secretions
Not systematic	<ul style="list-style-type: none"> • Pneumococcal and Legionella urinary antigen tests • Assays of anti-nuclear antibodies (if not previously tested), procalcitonin • Spirometry • In case of doubt for an infectious cause, and if the clinical condition of the patient allows it: endobronchial sampling for microbiological analysis (including pneumocystis) and cytological formula, by minimizing the examination duration, the injected volume of saline solution, and the impact on oxygenation.

NT-proBNP: N-terminal pro-brain natriuretic peptide.

Treatment

The acute exacerbation of IPF is a therapeutic emergency because of its poor prognosis. However, treatments used are based on low evidence levels due to the lack of adequate studies of good quality.

Isolated observations and retrospective series have suggested a benefit of immunosuppressants [414]. The phase II RCT (EXAFIP) [415] has failed to show the efficacy of intravenous cyclophosphamide (600 mg/m² on D0, D15, D30, D60) added to corticosteroid therapy, with a tendency towards a detrimental effect. Systemic corticosteroids, recommended internationally although no controlled trial allows confirming their efficacy [416], are frequently prescribed. The benefit/risk ratio of corticosteroid therapy is not known in this indication.

Table 25

Acute exacerbation of IPF: treatment regimen proposed in the EXAFIP trial (from Naccache et al. [415]).

-
- Methylprednisolone IV, 10 mg/kg/d (up to 1000 mg) from D1 to D3,
 - Followed by prednisone
 - 1 mg/kg/d x 1 week
 - 0.75 mg/kg/d x 1 week
 - 0.5 mg/kg/d x 1 week
 - 0.25 mg/kg/d x 1 week
 - 0.125 mg/kg/d (i.e., 10 mg/d in patients with a body weight >65 kg and 7.5 mg/d in patients with a body weight ≤65 kg) for up to 6 months
 - Prophylactic doses of low-molecular-weight heparins for the duration of hospitalization
 - Cotrimoxazole prophylaxis of *Pneumocystis jirovecii* pneumonia
 - Broad-spectrum antibiotics during hospitalization
 - Prevention of corticosteroid-induced osteoporosis and adverse effects of systemic corticosteroids
-

A RCT has not shown any benefit of thrombomodulin [417]. The methodological limitations [418] and unfavorable results [330] of the Japanese trials that have assessed the effect of anticoagulants (warfarin in particular) in IPF have already been mentioned above. There is no demonstrated benefit of low-molecular-weight heparins during acute exacerbations of IPF. Anticoagulant treatment may be prescribed in case of acute symptom worsening and suspected venous thromboembolic disease.

There are no prospective data on the use of pirfenidone and nintedanib in the curative treatment of acute exacerbations [281,419,420]. However, it may be reminded that nintedanib given as background treatment has decreased the incidence of exacerbations assessed in the pooled analysis of the INPULSIS trials [253,421].

There are no prospective data on azithromycin [422]. ECMO sometimes allows overcoming acute respiratory failure until lung transplantation [423]. Management varies widely internationally [424]. In practical terms, the widely used corticosteroid regimen and associated measures from the EXAFIP trial can be cited (Table 25) [415].

Preventive treatment for corticosteroid-induced osteoporosis should be considered when the daily dose of corticosteroids reaches or exceeds 7.5 mg of prednisone equivalent and the estimated duration of corticosteroid therapy is longer than three months [425]. The risk of metabolic complications (diabetes) must also be taken into account.

Guideline 33. It is proposed to treat acute exacerbations of IPF with corticosteroids.

Guideline 34. It is recommended not to use intravenous cyclophosphamide to treat acute exacerbations of IPF.

Invasive and non-invasive ventilation, high-flow oxygen therapy

Several studies including small sample sizes have assessed the use of mechanical ventilation in IPF patients with acute respiratory failure, and have shown a very high hospital mortality rate [426–435]. A systematic review of mechanical ventilation in 135 IPF patients with acute respiratory failure (related or not to an acute exacerbation of IPF) has described a hospital mortality rate of 87% [436]. Nevertheless, the prognosis seems slightly less poor in more recent publications [437,438].

Data on non-invasive ventilation in IPF are limited. A retrospective study that has included a few patients with an acute exacerbation of IPF has suggested that, in this context, non-invasive ventilation may be preferred to invasive ventilation without increasing mortality [439]. It should be noted that minimally-invasive management techniques have improved (high-flow oxygenation).

Indications for transfer to intensive care unit

Given the high mortality associated with mechanical ventilation in IPF, this treatment should only be used after discussion with patients and their caregivers (ideally in advance) of the therapeutic targets, in particular the reduction of unnecessary suffering.

Intensive care measures in patients with acute exacerbation of IPF appear justified when lung transplantation is planned or if a reversible cause of worsening has been identified or if the etiology has not been investigated. In contrast, this transfer often appears to be unreasonable if the project of lung transplantation has been challenged and/or if no cause of acute worsening has been identified after a complete workup [440]. The clinician's appreciation is essential here.

Guideline 35. In case of acute respiratory failure in patients with IPF, it is proposed:

_ To consider hospitalization in a critical care facility (resuscitation or respiratory intensive care) and to use invasive or noninvasive ventilation or high-flow oxygen therapy if patients meet the criteria for lung transplantation according to the super-emergency procedure, in case of inaugural exacerbation of IPF, or if there is a potentially reversible cause or if the etiological diagnosis has not yet been made;

_ To collegially discuss the therapeutic limitations and if possible in advance, and then to reassess them according to the evolution.

Pulmonary hypertension

Epidemiology, diagnosis

Precapillary PH is defined by a mean pulmonary arterial pressure >20 mmHg, a pulmonary artery wedge pressure ≤ 15 mmHg, and pulmonary vascular resistance ≥ 3 Wood units, measured by right heart catheterization [441]. Precapillary PH is reported in about 10% of patients with IPF at the time of diagnosis, and in 30–45% at the time of pre-lung transplant assessment [442]. It is considered severe if the mean pulmonary arterial pressure is ≥ 35 mmHg, or ≥ 25 mmHg with a cardiac index < 2 L/min/m², which is the case in 2–9% of patients with IPF [443, 444].

When present, PH is associated with increased mortality [444], dyspnea, inability to exercise, impaired DLco, increased hypoxemia and a risk of acute exacerbation of IPF [445].

The occurrence of PH in IPF should lead to investigate the presence of a non-IPF cause: thromboembolic venous disease, obstructive sleep apnea (OSA), and/or left heart failure, the prevalence of which is increased in IPF.

Cardiac ultrasound is the first-line non-invasive examination to detect PH: nevertheless cardiac ultrasound with Doppler allows assessing systolic pulmonary arterial pressure in only about half of the patients [446], may under- or overestimate pulmonary pressure [446,447], and the positive and negative predictive values for the diagnosis of precapillary PH are low [448]. Other approaches have been proposed, but they may also fail to detect it: pulmonary artery diameter measured on the chest CT scan [449], BNP assay [450], predictive score [451]. When chest CT angiography is performed, it is preferable to first acquire sections in full inspiration and without contrast media injection, in order to allow comparison with the prior CT scan performed under the same conditions.

Right cardiac catheterization allows distinguishing precapillary PH from postcapillary PH, in particular related to heart failure with preserved systolic function. Right cardiac catheterization is not recommended in case of suspected PH in IPF unless it is performed for specific therapeutic purposes (lung transplantation, diagnosis other than group 1 or 4 PH, inclusion in a trial) [452]. If performed, catheterization should include a capillary refill test in case of doubt about left heart failure (including with preserved systolic function).

Guideline 36. In patients with a confirmed diagnosis of IPF, it is proposed to perform cardiac ultrasound to detect pulmonary hypertension and cardiac comorbidities at the time of the diagnosis of IPF, and chest CT angiography in case of clinical worsening or decline in diffusing capacity for carbon monoxide that cannot be explained by IPF evolution.

Guideline 37. It is proposed to refer patients with IPF for whom signs of severe pulmonary hypertension and/or right ventricular dysfunction are seen on cardiac ultrasound to a specialized center.

Guideline 38. In patients with a confirmed diagnosis of IPF, it is proposed to perform right heart catheterization to diagnose pulmonary hypertension in the following situations:

- _ Pre-transplant assessment;**
- _ Ruling out another diagnosis (group 1 pulmonary hypertension, chronic thromboembolic pulmonary hypertension, heart failure with preserved ejection fraction);**
- _ If an accurate assessment of the prognosis is considered essential;**
- _ If inclusion in a therapeutic trial or treatment of pulmonary hypertension is being considered.**

Treatment

Hypoxemia at rest should be corrected in case of PH. In the presence of precapillary PH, lung or cardiopulmonary transplantation should be considered depending on the age and comorbidities [337].

Specific treatment of PH in IPF is not recommended [452,453].

Trials assessing selective endothelin-1 receptor A antagonists (e.g., ambrisentan) and dual receptor A and B antagonists (e.g., bosentan, macitentan) have shown negative results. Thus, following the unfavorable results of the ARTEMIS-IPF trial in the IPF indication [329] (see above), and due to the early termination of the ARTEMISPH trial in IPF patients with PH, ambrisentan is now contraindicated in IPF (including with severe PH). Regarding bosentan, the BUILD-1 [305] and BUILD-3 [306] trials have shown negative results in IPF, compared to placebo, in terms of 6MWT distance and time to progression, respectively. The results of a third double-blind RCT that has compared bosentan to placebo in IPF patients with PH were totally negative after 16 weeks of treatment [454]. A phase II trial that has compared macitentan to placebo in IPF has shown a negative result in terms of FVC evolution [455].

A phase II study has assessed riociguat (a direct stimulator of soluble guanylate cyclase) in idiopathic ILD with symptomatic PH: the study has been early terminated based on the recommendations of the independent monitoring committee of the trial due to increased mortality and serious AEs in the group treated with riociguat [456,457]. Therefore, the ANSM has warned healthcare professionals to the contraindication of riociguat in patients with PH associated with idiopathic ILD.

As open-label studies using small sample sizes have suggested a positive effect of sildenafil in terms of pulmonary hemodynamics and 6MWT [458–460], the latter has been formally assessed and compared to placebo in a RCT in which 180 IPF patients with a DLco \leq 40% were included (the proportion of patients with PH was not clearly indicated). This trial has failed to show any significant difference at 12 weeks in favor of sildenafil in terms of improvement in 6MWT distance (primary endpoint) [461]. However, sildenafil significantly improved arterial oxygenation, DLco, dyspnea and QoL. An a posteriori analysis has suggested an improvement in 6MWT distance in patients with right ventricular dysfunction on cardiac ultrasound [462]. Data from the international COMPERA register suggest a short-

term functional improvement in some patients treated with pulmonary vasodilators, mainly phosphodiesterase type 5 inhibitors [463].

Two RCTs that have included patients with advanced forms of IPF have shown negative results for the combination of sildenafil with nintedanib [309] and for pirfenidone [464], in terms of SGRQ score and disease progression, respectively.

Positive results have been shown with two treatments that are not currently available in France. A phase IIb/III RCT that has only included 41 patients has found that inhaled nitric oxide (initial dose of 30 mcg/kg) improved the ability to perform moderate-to-high intensity exercise at eight weeks, and stabilized the overall activity, whereas these two criteria worsen under placebo, and the benefit of treatment was maintained during an open-label extension study [465]. A multi-expert, double-blind RCT has assessed inhaled treprostinil, a prostacyclin analog (at a maximum dose of 72 mcg x 4/day) in 326 patients with various forms of ILD, of whom 22.7% had IPF. The trial has shown that inhaled treprostinil is significantly superior to placebo in terms of maximum 6MWT distance at week 16 (primary endpoint; absolute difference: 31 m), as well as in terms of NTproBNP concentrations (decrease by 15% with treprostinil versus increase by 46% with placebo) and proportion of patients with clinical disease progression (22.7% versus 33.1%) [466].

Guideline 39. In patients with a confirmed diagnosis of IPF and with pulmonary hypertension, it is recommended to investigate the presence of and correct hypoxemia at rest, to treat thromboembolic venous disease or left heart failure, and to assess the possibility of lung transplantation.

Guideline 40. In patients with a confirmed diagnosis of IPF and with precapillary pulmonary hypertension secondary to IPF and without any other identified cause, it is not recommended to prescribe specific treatment for pulmonary hypertension.

Gastroesophageal reflux disease

The frequency and severity of acid and non-acid GERD are increased in IPF [467], in particular due to the high prevalence of hiatal hernias in this population [468,469], which is associated with an increased risk of progression and mortality [470]. However, the association between IPF and GERD has recently been questioned [471].

Asymptomatic in half of the cases [15,472–475], GERD is particularly common when fibrosis is radiologically asymmetric [45]. GERD is a risk factor for inhalation, a known cause of pneumonia that could contribute, especially in case of asymptomatic but iterative micro-inhalations, to chronic airway inflammation and fibrosis [476].

Treatment

Two retrospective series have described a stabilization of pulmonary function and oxygen requirements associated with medical or surgical treatment of GERD [319,477]. A randomized trial evaluating laparoscopic GERD surgery in patients with IPF and abnormal acid GERD has shown good tolerance of surgery, but has failed to show any significant benefit in terms of reduction in FVC, acute exacerbations, or mortality [478].

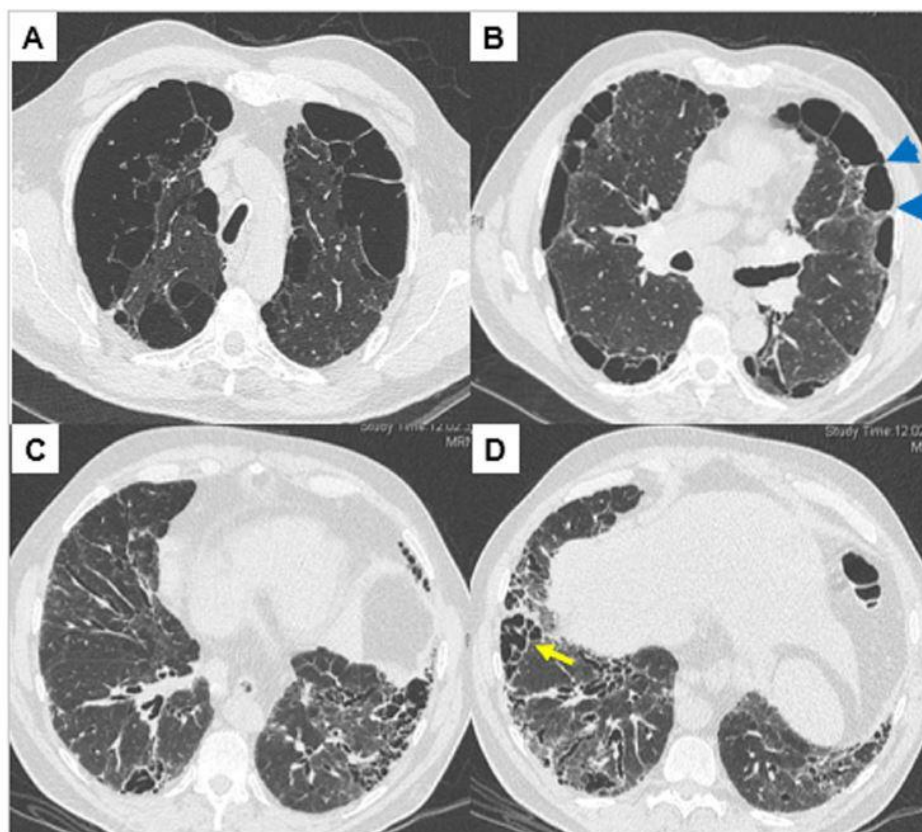


Fig. 17. Parenchymal window of the chest CT scan in a patient with combined pulmonary fibrosis and emphysema syndrome. A: paraseptal emphysema. B: paraseptal emphysema with thickening of the interlobular septa (arrowheads). C, D: probable usual interstitial pneumonia pattern associated with subpleural cysts with thickened walls suggesting the coexistence of emphysema and fibrosis in the same areas (arrow).

Regarding medical treatment with PPIs or H2 receptor antagonists (anti-H2), the results of observational studies [479–481] are contradictory and do not allow drawing conclusions because of biases [482]; the most recent study of excellent methodological quality does not suggest any benefit of PPIs on the risk of mortality or hospitalization [483]. The retrospective analysis of the placebo group of three therapeutic trials has shown a smaller decrease in FVC at week 30 in patients treated with an anti-acid agent (PPI or anti-H2), but these results should be interpreted with caution due to the methodological limitations of this study [484]. A post-hoc study of the population of the CAPACITY-1 and -2 and ASCEND trials (624 patients of whom 291 were treated with an anti-acid agent at study baseline) has not confirmed the benefit of anti-acid treatment on disease functional evolution, and has suggested an increased risk of respiratory infections in patients with a FVC $\leq 70\%$ [485]. Indeed, the increased risk of pneumonia and osteoporosis related to the suppression of gastric acidity by PPI should be taken into account [486]. Omeprazole treatment may improve cough [351]. Compared to the general population, the data available do not allow recommending a different management of GERD in IPF patients [486], but encourage a particular vigilance with regard to a possible reflux and an active management. The possible place of the management of non-acid reflux is not known.

Combining pirfenidone and omeprazole should be avoided because of the risk of drug interaction but other PPIs may be used if necessary (Table 21). A Japanese study has suggested that the use of gastric anti-secretory agents improves the digestive tolerance of pirfenidone [487].

Guideline 41. In patients with a confirmed diagnosis of IPF, it is proposed to question patients about a history or symptoms of gastroesophageal reflux disease.

– When gastroesophageal reflux disease is suspected, it is proposed to explore and treat it according to current guidelines outside the context of IPF.

Emphysema

The presence of emphysema associated with IPF changes the clinical presentation (worsening of dyspnea) and PFT (preserved lung volumes, lower DLco contrasting with the preserved lung volumes, increased oxygen requirements). This presentation is referred to as combined pulmonary fibrosis and emphysema (CPFE) syndrome. An emphysema threshold involving more than 15% of the lungs on the CT scan influences the functional evolution of IPF and would be considered a diagnostic criterion for CPFE syndrome [488]. This syndrome has been associated with most of the genetic anomalies described in IPF. The presence of emphysema complicates the radiological diagnosis of UIP because it makes it difficult to distinguish between honeycombing, emphysema with reticulation [489], and fibrosis with enlarged air spaces (or smoking-related interstitial fibrosis [SRIF]) in the periphery of basal pyramids [490–492] (Fig. 17).

Retrospective data suggest that the evolution of patients with CPFE syndrome is poorer than that of patients with IPF alone [493,494] for an equivalent extension of fibrosis. The prognosis and risk of PH are associated with the combined extension of emphysema and fibrosis [495,496]. The diagnosis of CPFE syndrome allows not to mistakenly attributing preserved lung volume and output to a mild form of IPF. Precapillary PH is particularly common in patients with CPFE syndrome, and is the main predictive factor for mortality [497]. Patients with CPFE syndrome show lower longitudinal changes in FCV and DLco than IPF patients without emphysema [488,498]; the individual follow-up of the FVC and DLco does not allow accurately assessing the prognosis [499].

Treatment

There are currently no data available to recommend a specific management of emphysema in IPF or of fibrosis in CPFE syndrome. The fibrosis component of CPFE syndrome may be treated with antifibrotic agents if the criteria for the diagnosis of IPF (with emphysema) are met, in particular if fibrosis seems to radiologically, functionally and/or evolutionarily predominate over emphysema. A subgroup analysis of patients included in the INPULSIS trials (see below) has suggested a comparable efficacy of nintedanib regardless of the presence of emphysema at baseline [500]. Potential medical treatment (pirfenidone, nintedanib) should be assessed individually taking into account the AEs, the diagnosis of ILD (IPF or not), and the absence of specific data on the potential benefit of treatment in this indication. Given the difficulty of assessing disease evolution (little change in FVC), the evolution should be followed based on a cluster of evidence combining all the data available, including the symptoms.

Guideline 42. In patients with a confirmed diagnosis of IPF, it is recommended to investigate the presence of signs of emphysema on the chest CT scan performed for the diagnosis of IPF, so as not to underestimate the severity of combined pulmonary fibrosis and emphysema syndrome when the lung volumes are preserved.

Guideline 43. In patients with a confirmed diagnosis of IPF, when emphysema is present, it is proposed to manage it according to usual practices. This includes performing alpha-1 antitrypsin deficiency testing, prescribing inhaled therapies if indicated, and managing exacerbations of chronic obstructive pulmonary disease.

Guideline 44. In patients with a confirmed diagnosis of IPF, it is proposed not to take into account the presence of emphysema in the choice of antifibrotic therapies.

Guideline 45. In patients with combined pulmonary fibrosis and emphysema syndrome, it is proposed to monitor more closely the risk of severe pulmonary hypertension.

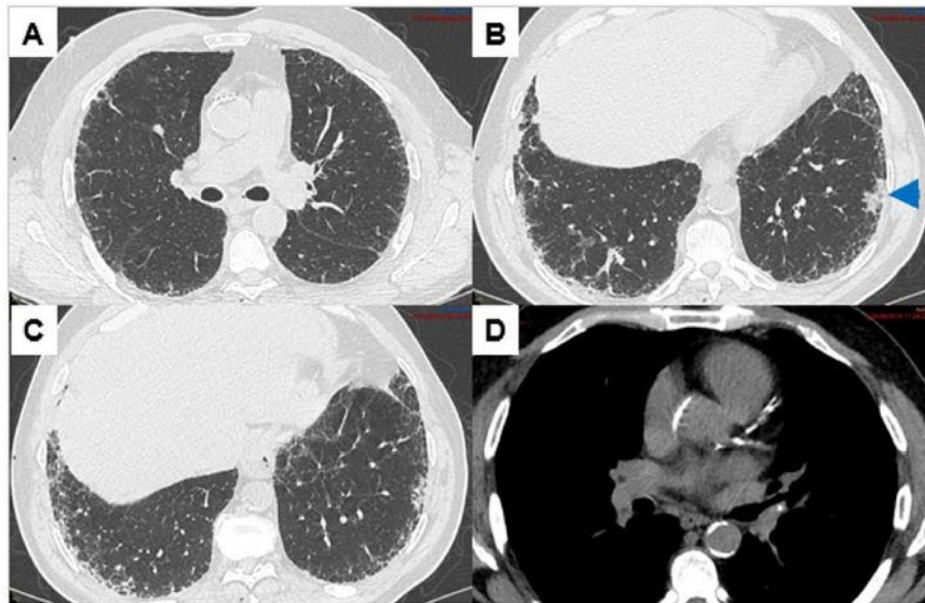


Fig. 18. Chest CT scan showing a lung carcinoma in a patient with idiopathic pulmonary fibrosis. A–C: probable usual interstitial pneumonia pattern (parenchymal window). B: subpleural nodule of the lower left lobe corresponding to a carcinoma (arrowhead). D: coronary calcifications (mediastinal window).

Obstructive sleep apnea

Several studies have shown a high frequency of obstructive sleep apnea (OSA) in patients with IPF [501–505]. A study conducted in 50 IPF patients has shown that 88% of them had OSA [506]. Patient questioning has been shown to be much less sensitive than polysomnography to make this diagnosis, so that the latter is essential for detecting OSA. Obesity is not always present.

The presence of OSA is associated with a more rapid deterioration regardless of IPF severity [507], in particular in case of nocturnal hypoxemia [508], and with an increased frequency of cardiovascular comorbidities [505]. Nevertheless, the clinical significance of detecting and treating OSA is not demonstrated in this context [509], in particular in patients without symptoms of OSA.

Compared to the general population, the data available do not allow recommending a different management of OSA in IPF patients [510]. Continuous positive airway pressure treatment appears to be effective in the context of IPF and could improve the QoL [511].

Guideline 46. In patients with a confirmed diagnosis of IPF and symptoms suggestive of obstructive sleep apnea, it is recommended to perform ventilatory polygraphy or polysomnography.

Guideline 47. When present in patients with a confirmed diagnosis of IPF, it is proposed to treat obstructive sleep apnea according to the current guidelines outside the context of IPF.

Lung cancer

Epidemiology, diagnosis

Several studies have shown the high frequency and poor prognosis of lung cancer (LC) in IPF compared to the general population [512]. A meta-analysis adjusted for age, gender and smoking status was performed in 25 cohorts including 11,976 subjects, of whom 1854 had IPF [201]. The prevalence of LC was 13.7% (95% CI: 10.2–17.3%) in IPF, with an incidence of 6.4% and an annual incidence of 1.8% person-years, and these figures were higher in studies in the Asian population (prevalence: 15.3% versus 11.6%). In a study conducted in the general South Korean population, the cumulative incidence of bronchial cancer in IPF was 1.7% at 1 year, 4.7% at 3 years, and 7.0% at 5 years [513]. The 1- and 2-year survival was 78.5% and 67.8% in IPF patients and 65.5 and 44.2% in LC patients. In the multivariate analysis, the presence of LC was associated with an almost triple independent excess risk of mortality (HR: 2.9). This risk of mortality was also compared to that of LC without IPF in the US epidemiological SEER database: the increased relative risk of all-cause and specific mortality was 1.35 and 1.21, respectively [514]. The physician in charge of the follow-up should be aware of the frequency of LC in the follow-up of IPF, in particular in patients for whom treatment may be offered. There are no data available to recommend to regularly perform a low-dose chest CT scan or its frequency.

The diagnosis of LC in IPF is made at an earlier spreading stage (peripheral nodule) compared to the general population; the lesion is more often located in the lower lobes (in areas of fibrosis) and histology shows the non-small cell type, with an excess of squamous cell carcinomas [514] (Fig. 18). Due to the squamous cell histological type and heavy smoking, the probability of finding an oncogenic addiction is low [515]. The definite diagnosis is challenging because these frail patients are difficult to assess due to underlying respiratory failure [516].

The diagnostic approach could be facilitated by performing 2- [18]-Fluoro-2-deoxy-D-glucose Positron Emission Tomography/Computed Tomography (PET/CT) imaging, highlighting hilar or mediastinal lymphadenopathy accessible to bronchial or esophageal echoendoscopy or metastatic lesions allowing guided biopsies, avoiding the use of risky bronchoscopy or transthoracic puncture [517]. In addition, PET/CT improves the assessment of the size of the primary tumor, the assessment of the mediastinal spread and the accuracy of the diagnosis of LC in ILD. In case of spread LC, investigating the presence of circulating tumor DNA (sensitivity < 70%) could allow making a diagnosis of cancer and possibly investigating an oncogenic addiction, although unlikely in the context of active smoking (see above).

Treatment

The data available do not allow recommending a specific management of LC in IPF. Management should be discussed in an expert center, ideally during an MDD focused on IPF and cancer. The management is more difficult due to the risk of acute respiratory failure and/or acute exacerbation of IPF during cancer treatments (surgical resection, radiotherapy, chemotherapy, targeted therapy, immunotherapy) [518]. Treatment of LC should be as close as possible to the guidelines for the management in the general population. In 2019, the Japanese Respiratory Society has listed all possible treatments for LC associated with IPF [517].

Antifibrotic treatment should be maintained regardless of the discussion of anticancer treatment. Several retrospective studies and a prospective study suggest that pirfenidone would reduce the risk of acute exacerbation in IPF patients treated with surgery [519–522] or chemotherapy [523]. These findings highlight the importance of referring IPF patients with LC to expert centers and the need to individually assess the risk/benefit ratio of the therapeutic project with patients and their caregivers.

In localized cancers, the assessment of operability should be performed until a VO₂max is achieved. The ILD-GAP score also seems to be predictive of postoperative mortality, with a risk increased by 30% in case of a high score [517]. In patients with resectable tumor, lobectomy would improve survival, but the risk of exacerbation would be lower in case of limited resection [524].

In patients with unresectable tumor and in locally advanced cancers, the data available are limited but conventional radiotherapy is not recommended [525], due to the very high risk of radiation pneumonitis and/or severe acute exacerbation (30%) [517,526]. Stereotactic radiation therapy has also been associated with the occurrence of acute radiation pneumonitis and/or acute exacerbation of severe ILD and death [517,526].

In the absence of oncogenic addiction and in patients eligible for chemotherapy, platinum-based dual therapy may be proposed [517]. This proposal is based on retrospective cohorts, most often treated with the carboplatin/paclitaxel combination [517], and on phase II therapeutic trials all conducted in the Asian population [527–529]; no specific problems were associated with the use of bevacizumab in some patients [530]. Immunotherapies for spread LC without oncogenic addiction occurring in smokers cannot currently be proposed outside the framework of dedicated studies due, in particular, to the risk of AEs such as IPF or immune-mediated pneumonitis with highly variable frequencies and severities from one trial to another [531–533].

The management of small cell LC is based on the carboplatin/etoposide combination, including in localized thoracic forms which, in case of IPF, cannot benefit from thoracic radiotherapy [517,534–538].

Guideline 48. It is proposed to inform the physicians in charge of IPF monitoring of the frequency of lung cancer in patients with a confirmed diagnosis of IPF.

Guideline 49. In patients with a confirmed diagnosis of IPF, it is recommended to advise them to quit smoking if they are smokers and to implement smoking cessation support.

Guideline 50. In patients with a confirmed diagnosis of IPF and with lung cancer, it is recommended to take into account IPF in the therapeutic choices.

Other comorbidities

There are many other comorbidities associated with IPF [539]. Cardiovascular diseases are the most common comorbidities: their incidence increases with IPF duration and they are associated with an increased risk of mortality [540,541]. For example, in the German INSIGHTS register, arterial hypertension, coronary artery disease and carotid stenosis and/or stroke were found in about 54%, 25% and 8% of cases, respectively, at baseline [8]. Diabetes is present in about 10–20% of patients, and is associated with a poor prognosis [541]. The risk of thromboembolism is significantly increased, and seems to be associated with advanced IPF with a poor prognosis [542].

Anxiety and depression are common [543–546]. Aging-related frailty is common and is an independent risk factor for QoL deterioration, hospitalization, and mortality [547,548].

According to an observational study that has compared nearly 9300 IPF patients to age- and sex-matched control subjects, the relative risk is 15.5 for PH, about 7 for pulmonary embolism and emphysema, 5.2 for COPD, 3.8 for heart failure, 3.6 for OSA, 2.4 for GERD, 2.1 for myocardial infarction, and 1.7 for deep vein thrombosis [549].

The data available do not allow recommending routine screening for these comorbidities, but the physician in charge of the follow-up (i.e., general practitioner or pulmonologist depending on care organization) should be aware of these comorbidities. A chest CT scan performed for IPF follow-up may detect some of these comorbidities (atheroma, coronary calcifications, sequela of myocardial infarction).

Malnutrition is present in almost a third of IPF patients [187]. Malnutrition, a BMI < 25, and a weight loss during IPF follow-up ($\geq 5\%$ in one year) are associated with a poor prognosis [20,188]. It is advisable to monitor body weight and its evolution and to maintain a nutritional balance. Nutritional support should be considered if necessary, even if its efficacy on the evolution is not demonstrated in IPF.

Finally, using protective ventilation should be advised in any surgery under general anesthesia, to limit the risk of barotrauma.

Guideline 51. In patients with a confirmed diagnosis of IPF, it is proposed to investigate the presence of comorbidities (cardiovascular disorders, venous thromboembolic disease, diabetes, depression), to organize their management in partnership with the attending physician, and to take into account the risk of drug interactions with antifibrotic drugs.

Table 26

Criteria for disease progression in fibrosing ILD. The criteria for progression are assessed despite conventional treatment deemed appropriate.

Criteria used in the INBUILD study: [557]

Occurrence in the previous 24 months (or less) of: - a relative decline in FVC as a percentage of the predicted value:

- $\geq 10\%$ (e.g., decline in FVC from 70% to 63% of the predicted value), or
- by 5–10%, associated with symptom worsening (dyspnea), or
- by 5–10%, associated with an increased extent of fibrosis lesion on the chest CT scan

- or an increased extent of fibrosis lesions on the chest CT scan, associated with symptom worsening (dyspnea)

ERICE criteria: [558]

Occurrence in the previous 24 months (or less) of:

- The criteria used in the INBUILD study listed above, or
- A relative decline in DLco $\geq 15\%$, that cannot be explained by PH or another cause

Criteria of the trial in unclassifiable ILDs: (UIILD) [559]

Occurrence in the previous 6 months (or less) of:

- An absolute decline in FVC as a percentage of the predicted value $\geq 5\%$
- A significant symptom worsening that is not due to a cardiac, pulmonary (unless worsening of underlying ILD), vascular, or other cause, as determined by the investigator

Criteria used in the RELIEF study: [560]

Annual decline in FVC $\leq 5\%$ of the predicted value, based on at least three measurements performed in 6–24 months

FVC: forced vital capacity; DLco: diffusing capacity for carbon monoxide; PH: pulmonary hypertension; ILD: interstitial lung disease.

Antifibrotic treatments in patients with non-IPF progressive pulmonary fibrosis

Concept of interstitial lung disease with a progressive fibrosing phenotype

IPF belongs to the ILD spectrum [550], which includes many diseases associated with varying degrees of inflammatory lesions and fibrosis, with overlaps in their clinical presentation, histological pattern, and radiological signs [551]. Despite conventional treatment, including immunomodulatory treatment with corticosteroids and/or immunosuppressants for most non-IPF fibrosing ILDs, a significant proportion of patients experience a progressive worsening of the disease. This progressive fibrosing phenotype corresponds to a progression characterized by respiratory symptom worsening, decreased lung function and early mortality [114,552,553]. About a quarter of patients with fibrosing ILD would develop a progressive fibrosing phenotype [554], with disease progression and prognosis similar to those of IPF patients [553,555]. Due to common clinical and biological characteristics, ILDs with this progressive phenotype are grouped with IPF under the term “progressive fibrosing ILDs” [556].

ILDs most likely to develop a progressive fibrosing phenotype are idiopathic NSIP, fibrosing HP, CTD-ILDs, in particular ILD associated with systemic sclerosis and rheumatoid arthritis, and unclassifiable ILDs [554].

There are no formal criteria for assessing disease progression in ILD patients but, in clinical practice, it is usually assessed by the longitudinal assessment of lung function, in particular the assessment of the FVC, symptoms, chest CT scan, and possibly clinical events such as acute exacerbations and emergency hospitalizations for respiratory causes [551]. The most widely used criteria are those of the INBUILD trial [557], modified to take into account the DLco [558], assessed over a period of up to two years (Table 26) [557–560]. Disease progression is confirmed if these criteria are met over a shorter period (e.g., one year).

Treatment of interstitial lung diseases with a progressive fibrosing phenotype

The INBUILD study [557] was a phase III, randomized, placebo controlled trial assessing nintedanib for one year in 663 patients with ILD with a progressive fibrosing phenotype, involving at least 10% of lung volume on the chest CT scan, meeting criteria for disease progression in the 24 months prior to inclusion despite conventional treatment (see above), and with a FVC \geq 45% of the predicted value, and a DLco ranging between 30 and 80% of the predicted value. Randomization was stratified according to whether or not the chest CT scan showed an UIP-like pattern. The diagnosis of ILD was fibrosing HP (29%), CTD (29%), idiopathic NSIP (19%), unclassifiable fibrosing ILD (17%), or another cause (12%).

The annualized decline in FVC was - 80.8 mL/year in the nintedanib group and -187.8 mL/year in the placebo group ($p < 0.001$). In the predefined subpopulation of patients with an UIP-like pattern on the CT scan (62% of study patients), the annualized decline in FVC was - 82.9 mL/year in the nintedanib group and - 211.1 mL/year in the placebo group ($p < 0.001$). No difference in therapeutic effect was found in the studied subgroups. The safety profile was similar to that found in the INPULSIS trials, with diarrhea being the most commonly reported AE (62%). Treatment was most beneficial in the subgroup of patients whose progression before inclusion was defined by a decrease in FVC by \geq 10%, whose decline under placebo was more rapid than in the other groups [561]. Blinded patients continued treatment until the end of the trial, i.e. a mean total treatment duration of 15.6 months in the nintedanib group and 16.8 months in the placebo group [562]. The proportion of patients who experienced an acute exacerbation or died was lower in the nintedanib group (13.9%) than in the placebo group (19.6%; HR: 0.67; 95% CI: 0.46–0.98; $p = 0.04$) [562].

The UILD study [559] was a phase II, randomized, placebo-controlled trial assessing pirfenidone for 26 weeks in 253 patients with unclassifiable ILD with a progressive fibrosing phenotype, meeting criteria for disease progression in the 6 months prior to inclusion (defined by an absolute decline in FVC \geq 5%, or a symptomatic worsening not related to a cardiac, vascular or other pulmonary cause), and with a FVC \geq 45% of the predicted value and a DLco \geq 30% of the predicted value. The primary endpoint, i.e. the FVC measured at home, could not be analyzed as planned due to technical difficulties and a small number of outliers.

The median decrease in FVC measured at home was - 87.7 mL at week 26 in the pirfenidone group versus - 157.1 mL in the placebo group (statistically significant difference). The mean decrease in FVC measured during the hospital visits was - 17.8 mL at week 26 in the pirfenidone group versus - 113.0 mL in the placebo group ($p = 0.002$). At week 26, patients treated with pirfenidone less often experienced a 5% decrease in FVC ($p = 0.001$), a 10% decrease in FVC ($p = 0.01$), and a decrease in DLco $>$ 15% ($p = 0.039$). The decline in DLco was - 0.7 +/- 7.1% in the pirfenidone group versus - 2.5 +/- 8.8% in the placebo group. The change in 6MWT distance was - 2.0 +/- 68.1 m in the pirfenidone group versus - 26.7 +/- 79.3

m in the placebo group. The AEs were comparable to those reported in the other trials assessing pirfenidone, mainly gastrointestinal AEs, fatigue, and rash.

The RELIEF study [560] was a phase IIb, randomized, placebo-controlled trial assessing pirfenidone for 48 weeks in patients with unclassifiable ILD with a progressive fibrosing phenotype, meeting criteria for disease progression in the 6 months prior to inclusion (defined by an annualized absolute decline in FVC $\geq 5\%$, based on at least three measurements in 6–24 months, despite conventional treatment) and with a FVC ranging between 40 and 90% of the predicted value and a DLco ranging between 10 and 90% of the predicted value. Inclusion criteria were patients with CTD-ILD, fibrosing NSIP, fibrosing HP, or asbestos-induced pulmonary fibrosis. The trial was terminated early after the randomization of 127 patients (64 in the pirfenidone group and 63 in the placebo group), based on a futility criterion in an interim analysis triggered by a slow enrolment. Nevertheless, the analysis has shown a significantly smaller decrease in the percentage of FVC in the pirfenidone group compared to placebo ($p = 0.043$); the result was similar when the model was stratified according to the diagnosis group ($p = 0.042$). The median difference between the groups was 1.69% of the predicted FVC (95% CI: - 0.65 - 4.03). In the linear analysis of the slope of FVC in the mixed model, the estimated difference between the groups was 3.53% of predicted FVC (95% CI: 0.21–6.86). The difference between the groups was also significant for the DLco. Given the early study termination, the results of this trial should be interpreted with caution.

These trials show the efficacy of nintedanib in ILDs with a progressive fibrosing phenotype, and suggest a comparable efficacy of pirfenidone in unclassifiable ILDs and other ILDs with a progressive fibrosing phenotype. In Europe, nintedanib has been approved for use in ILDs with a progressive fibrosing phenotype on July 15, 2020; the Transparency Committee has voted a moderate actual medical benefit and a level IV improvement in actual medical benefit on December 16, 2020. It is extremely important to make a precise etiological diagnosis when faced with any fibrosing ILD in order to guide the management. Antifibrotic treatment can slow down the worsening in case of progressive fibrosing phenotype despite conventional management.

Guideline 52. In patients with fibrosing interstitial lung disease, it is recommended to follow the evolution longitudinally based on the symptoms, forced vital capacity, diffusing capacity for carbon monoxide, and chest CT scan, in order to identify a progressive fibrosing phenotype.

Guideline 53. In patients with interstitial lung disease with a progressive fibrosing phenotype despite therapeutic management adapted to the etiology, it is recommended to start treatment with nintedanib after a multidisciplinary discussion, and it is proposed to start off-label treatment with pirfenidone if nintedanib is not appropriate due to intolerance, comorbidities or drug interactions.

Declaration of Competing Interest

None.

Acknowledgements

The authors would like to thank Mr. Benoit Bouquillon (Carely, Lille) for his help in coordinating and drafting the guidelines, the French rare diseases Healthcare Network (RespiFil), the “Association pour l’amélioration de la prise en charge des maladies pulmonaires rares” as well as the French learned Society of Pulmonology for the English translation.

Appendix 1. Contact details for reference and expert centers for rare lung diseases

The reference center for rare lung diseases is multi-site. It includes the following centers (full contact details available on www.maladies-pulmonaires-rares.fr and respifil.fr).

Center	Address	Coordinating physician	Phone number of the secretariat
Coordinating reference center	Hospices Civils de Lyon (HCL) Hôpital Louis Pradel 59 Boulevard Pinel, 69,677 LYON Cedex	Prof. Vincent COTTIN	+33 (0)4 27 85 77 00
Constitutive reference centers	Bobigny (AP-HP) Hôpital Avicenne 125 rue de Stalingrad, 93,000 BOBIGNY	Prof. Hilario NUNES	+33 (0)1 48 95 51 29
	Hôpital François Mitterand CHU Dijon - Bourgogne 14 rue Gaffarel, 21,079 DIJON	Pr Philippe BONNIAUD	+33 (0)3 20 44 59 48
Regional Expert centers	Lille Hôpital Calmette Bd du Professeur Jules Leclercq, 59,037 LILLE	Prof. Cécile CHENIVESSE	+33 (0)3 20 44 59 48
	Paris (AP-HP) Hôpital Bichat – Claude Bernard 46 rue Henri Huchard, 75,018 PARIS Hôpital Pitié – Salpêtrière (Syndrome d’Ondine de l’Adulte) 47–83 Boulevard de l’Hôpital, 75,651 PARIS cedex 13 Hôpital Tenon 4 rue de la Chine, 75,970 PARIS Cedex	Prof. Bruno CRESTANI Prof. Christian STRAUS Prof. Jacques CADRANEL	+33 (0)1 40 25 68 00 +33 (0)1 42 17 85 78 +33 (0)1 56 01 61 47
Regional Expert centers	Besançon Hôpital Jean-Minjoz 3 boulevard Alexandre Fleming, 25,030 BESANÇON Cedex	Dr. Anne GONDOUIN	+33 (0)3 81 66 88 02
	Bordeaux Hôpital du Haut Levêque 1 avenue Magellan 33,604 PESSAC Cedex	Dr. Elodie BLANCHARD	+33 (0)5 57 65 63 38
	Caen Hôpital Côte de Nacre Avenue de la Côte de Nacre, 14,033 CAEN Cedex 5	Prof. Emmanuel BERGOT	+33 (0)2 31 06 46 77
Regional Expert centers	Grenoble Hôpital Michallon – Site Nord Boulevard de la Chantourne 38,043 LA TRONCHE Cedex 9	Dr. Sébastien QUETANT	+33 (0)4 76 76 54 67
	Le Kremlin-Bicêtre Hôpital Bicêtre (AP-HP) 78, rue du Général Leclerc, 94,275 LE KREMLIN BICETRE	Prof. David MONTANI	+33 (0)1 45 21 79 76
	Marseille Hôpital Nord (AP-HM)	Prof. Martine REYNAUD-GAUBERT	+33 (0)4 91 96 61 45/46/47

(Continued)

Center	Address	Coordinating physician	Phone number of the secretariat
	Chemin des Bourelly 13,915 MARSEILLE Cedex 20		
Montpellier	Hôpital Arnaud de Villeneuve 371 avenue Doyen Gaston Giraud, 34,295 MONTPELLIER Cedex 5	Prof. Arnaud BOURDIN	+33 (0)4 67 33 60 91
Nancy	Hopitaux de Brabois Rue du Morvan 54,511 VANDOEUVRE-LÈS-NANCY	Dr. Emmanuel GOMEZ	+33 (0)3 83 15 40 21
Nice	Hôpital Pasteur 30, Voie Romaine, 06,001 NICE Cedex 1	Pr Charles-Hugo MARQUETTE	+33 (0)4 92 03 88 83
Paris (AP-HP)	Hôpital européen Georges-Pompidou (HEGP) 20 Rue Leblanc, 75,015 PARIS	Prof. Olivier SANCHEZ	+33 (0)1 56 09 20 00
Reims	Hôpital Maison Blanche 45 rue Cognacq-Jay 51,092 REIMS Cedex	Prof. François LEBARGY	+33 (0)3 26 78 76 14
Rennes	Hôpital Pontchaillou 2 rue Henri Le Guilloux 35,033 RENNES Cedex 09	Prof. Stéphane JOUNEAU	+33 (0)2 99 28 24 78
Rouen	Hôpital Charles Nicolle 1 rue Germont 76,031 ROUEN Cedex	Dr. Mathieu SALAUN	+33 (0)2 32 88 82 47
Strasbourg	Nouvel Hôpital civil 1 place de l'hôpital – BP 426 67,091 STRASBOURG Cedex	Dr. Sandrine HIRSCHI	+33 (0)3 69 55 06 46
Toulouse	Hôpital Larrey 24, chemin de Pouvoirville - TSA 30,030 31,059 TOULOUSE Cedex 9	Dr. Grégoire PREVOT	+33 (0)5 67 77 17 09
Tours	Hôpital Bretonneau 2 boulevard Tonnellé 37,044 TOURS Cedex 9	Prof. Sylvain MARCHAND-ADAM	+33 (0)2 47 47 37 87

Appendix 2. Detail of the ratings of the review group.

Guideline	Number of voters	Number of voters with [5–9] rating	Percentage of voters with [5–9] rating	Status
1	40	40	100	Validated
2	40	40	100	Validated
3	40	40	100	Validated
4	39	39	100	Validated
5	39	39	100	Validated
6	40	40	100	Validated
7	38	37	97	Validated
8	40	40	100	Validated
9	39	37	95	Validated
10	38	38	100	Validated
11	38	38	100	Validated
12	39	39	100	Validated
13	36	36	100	Validated
14	40	39	98	Validated
15	40	40	100	Validated
16	40	40	100	Validated
17	36	34	94	Validated
18	35	35	100	Validated
19	36	35	97	Validated
20	36	36	100	Validated
21	34	34	100	Validated
22	37	37	100	Validated
23	36	36	100	Validated
24	35	35	100	Validated
25	35	35	100	Validated
26	38	38	100	Validated
27	35	35	100	Validated
28	35	34	97	Validated
29	34	34	100	Validated

(continued)

(Continued)

Guideline	Number of voters	Number of voters with [5–9] rating	Percentage of voters with [5–9] rating	Status
30	35	35	100	Validated
31	35	35	100	Validated
32	35	35	100	Validated
33	38	38	100	Validated
34	35	35	100	Validated
35	34	34	100	Validated
36	35	34	97	Validated
37	39	39	100	Validated
38	38	38	100	Validated
39	37	37	100	Validated
40	35	35	100	Validated
41	33	32	97	Validated
42	36	36	100	Validated
43	40	40	100	Validated
44	36	36	100	Validated
45	34	33	97	Validated
46	38	38	100	Validated
47	36	36	100	Validated
48	36	36	100	Validated
49	39	39	100	Validated
50	39	39	100	Validated
51	39	39	100	Validated
52	38	38	100	Validated
53	39	39	100	Validated
54	35	35	100	Validated

A guideline is validated if at least 90% of the voters in the review group have responded in the [5–9] interval.

References

- [1] Duchemann B, Annesi-Maesano I, Jacobe de Naurois C, Sanyal S, Brillet PY, Brauner M, Kambouchner M, Huynh S, Naccache JM, Borie R, Piquet J, Mekinian A, Virally J, Uzunhan Y, Cadranet J, Crestani B, Fain O, Lhote F, Dhote R, Saidenberg- Kermanac'h N, Rosental PA, Valeyre D, Nunes H. Prevalence and incidence of interstitial lung diseases in a multi-ethnic county of Greater Paris. *Eur Respir J* 2017;50:1602419.
- [2] Centre de référence des maladies pulmonaires rares. 2015 10 février 2020]. Available from: <http://www.maladies-pulmonaires-rares.fr/index.asp>.
- [3] Cottin V, Crestani B, Cadranet J, Cordier JF, Marchand-Adam S, Prevot G, Wallaert B, Bergot E, Camus P, Dalphin JC, Dromer C, Gomez E, Israel-Biet D, Jouneau S, Kessler R, Marquette CH, Reynaud-Gaubert M, Aguilaniu B, Bonnet D, Carre P, Danel C, Faivre JB, Ferretti G, Just N, Lebargy F, Philippe B, Terrioux P, Thivolet- Bejui F, Trumbic B, Valeyre D. Recommandations pratiques pour le diagnostic et la prise en charge de la fibrose pulmonaire idiopathique – Actualisation 2017. *Rev Mal Respir* 2017;34:900–68.
- [4] Raghu G, Weycker D, Edelsberg J, Bradford WZ, Oster G. Incidence and prevalence of idiopathic pulmonary fibrosis. *Am J Respir Crit Care Med* 2006;174:810–6.
- [5] Raghu G, Chen SY, Yeh WS, Maroni B, Li Q, Lee YC, Collard HR. Idiopathic pulmonary fibrosis in US Medicare beneficiaries aged 65 years and older: incidence, prevalence, and survival, 2001-11. *Lancet Respir Med* 2014;2:566–72.
- [6] Nadrous HF, Myers JL, Decker PA, Ryu JH. Idiopathic pulmonary fibrosis in patients younger than 50 years. *Mayo Clin Proc* 2005;80:37–40.
- [7] Armanios M. Telomerase and idiopathic pulmonary fibrosis. *Mutation research* 2012;730:52–8.
- [8] Behr J, Kreuter M, Hoepfer MM, Wirtz H, Klotsche J, Koschel D, Andreas S, Claussen M, Grohe C, Wilkens H, Randerath W, Skowasch D, Meyer FJ, Kirschner J, Glaser S, Herth FJ, Welte T, Huber RM, Neurohr C, Schwaiblmair M, Kohlhauf M, Hoffken G, Held M, Koch A, Bahmer T, Pittrow D. Management of patients with idiopathic pulmonary fibrosis in clinical practice: the INSIGHTS-IPF registry. *Eur Respir J* 2015;46:186–96.
- [9] Ley B, Collard HR. Epidemiology of idiopathic pulmonary fibrosis. *Clinical epidemiology* 2013;5:483–92.
- [10] Raghu G, Remy-Jardin M, Myers JL, Richeldi L, Ryerson CJ, Lederer DJ, Behr J, Cottin V, Danoff SK, Morell F, Flaherty KR, Wells A, Martinez FJ, Azuma A, Bice TJ, Bouros D, Brown KK, Collard HR, Duggal A, Galvin L, Inoue Y, Jenkins RG, Johkoh T, Kazerooni EA, Kitaichi M, Knight SL, Mansour G, Nicholson AG, Pipavath SNJ, Buendia-Roldan I, Selman M, Travis WD, Walsh S, Wilson KC, American Thoracic Society ERSJRS. Latin American Thoracic S. Diagnosis of Idiopathic Pulmonary Fibrosis. An Official ATS/ERS/JRS/ALAT Clinical Practice Guideline. *Am J Respir Crit Care Med* 2018;198:e44–68.

- [11] Collard HR, Ryerson CJ, Corte TJ, Jenkins G, Kondoh Y, Lederer DJ, Lee JS, Maher TM, Wells AU, Antoniou KM, Behr J, Brown KK, Cottin V, Flaherty KR, Fukuoka J, Hansell DM, Johkoh T, Kaminski N, Kim DS, Kolb M, Lynch DA, Myers JL, Raghu G, Richeldi L, Taniguchi H, Martinez FJ. Acute Exacerbation of Idiopathic Pulmonary Fibrosis. An International Working Group Report. *Am J Respir Crit Care Med* 2016;194:265–75.
- [12] Cottin V, Crestani B, Valeyre D, Wallaert B, Cadranel J, Dalphin JC, Delaval P, Israel-Biet D, Kessler R, Reynaud-Gaubert M, Cordier JF, Aguilaniu B, Bouquillon B, Carre P, Danel C, Faivre JB, Ferreti G, Just N, Kouzan S, Lebargy F, Marchand Adam S, Philippe B, Prevot G, Stach B, Thivolet-Bejui F. Recommandations pratiques pour le diagnostic et la prise en charge de la fibrose pulmonaire idiopathique. Élaborées par le centre national de référence et les centres de compétence pour les maladies pulmonaires rares sous l'égide de la Société de pneumologie de langue française. *Rev Mal Respir* 2013;30:879–902.
- [13] Haute Autorité de Santé. Méthode « Recommandations pour la pratique clinique ». Saint-Denis: HAS; 2010.
- [14] Gribbin J, Hubbard RB, Le Jeune I, Smith CJP, West J, Tata LJ. Incidence and mortality of idiopathic pulmonary fibrosis and sarcoidosis in the UK. *Thorax* 2006;61:980–5.
- [15] Raghu G, Freudenberger TD, Yang S, Curtis JR, Spada C, Hayes J, Sillery JK, Pope 2nd CE, Pellegrini CA. High prevalence of abnormal acid gastro-oesophageal reflux in idiopathic pulmonary fibrosis. *Eur Respir J* 2006;27:136–42.
- [16] Cottin V, Cordier JF. Velcro crackles: the key for early diagnosis of idiopathic pulmonary fibrosis? *Eur Respir J* 2012;40:519–21.
- [17] Sellarés J, Hernandez-Gonaalez F, Lucena CM, Paradela M, Brito-Zeron P, Prieto-Gonzalez S, Benegas M, Cuerpo S, Espinosa G, Ramírez J, Sanchez M, Xaubet A. Auscultation of Velcro Crackles is Associated With Usual Interstitial Pneumonia. *Medicine (Baltimore)* 2016;95:e2573.
- [18] Sgalla G, Walsh SLF, Sverzellati N, Fletcher S, Cerri S, Dimitrov B, Nikolic D, Barney A, Pancaldi F, Larcher L, Luppi F, Jones MG, Davies D, Richeldi L. Velcro-type" crackles predict specific radiologic features of fibrotic interstitial lung disease. *BMC Pulm Med* 2018;18:103.
- [19] van Manen MJG, Vermeer LC, Moor CC, Vrijenhoef R, Grutters JC, Veltkamp M, Wijsenbeek MS. Clubbing in patients with fibrotic interstitial lung diseases. *Respir Med* 2017;132:226–31.
- [20] Nakatsuka Y, Handa T, Kokosi M, Tanizawa K, Puglisi S, Jacob J, Sokai A, Ikezoe K, Kanatani KT, Kubo T, Tomioka H, Taguchi Y, Nagai S, Chin K, Mishima M, Wells AU, Hirai T. The Clinical Significance of Body Weight Loss in Idiopathic Pulmonary Fibrosis Patients. *Respiration* 2018;96:338–47.

- [21] Raghu G, Collard HR, Egan JJ, Martinez FJ, Behr J, Brown KK, Colby TV, Cordier JF, Flaherty KR, Lasky JA, Lynch DA, Ryu JH, Swigris JJ, Wells AU, Ancochea J, Bouros D, Carvalho C, Costabel U, Ebina M, Hansell DM, Johkoh T, Kim DS, King Jr. TE, Kondoh Y, Myers J, Muller NL, Nicholson AG, Richeldi L, Selman M, Dudden RF, Griss BS, Protzko SL, Schunemann HJ. An Official ATS/ERS/JRS/ALAT statement: idiopathic pulmonary fibrosis: evidence-based guidelines for diagnosis and management. *Am J Respir Crit Care Med* 2011;183:788–824.
- [22] Lynch DA, Sverzellati N, Travis WD, Brown KK, Colby TV, Galvin JR, Goldin JG, Hansell DM, Inoue Y, Johkoh T, Nicholson AG, Knight SL, Raoof S, Richeldi L, Ryerson CJ, Ryu JH, Wells AU. Diagnostic criteria for idiopathic pulmonary fibrosis: a Fleischner Society White Paper. *Lancet Respir Med* 2018;6:138–53.
- [23] Watadani T, Sakai F, Johkoh T, Noma S, Akira M, Fujimoto K, Bankier AA, Lee KS, Muller NL, Song JW, Park JS, Lynch DA, Hansell DM, Remy-Jardin M, Franquet T, Sugiyama Y. Interobserver variability in the CT assessment of honeycombing in the lungs. *Radiology* 2013;266:936–44.
- [24] Walsh SL, Calandriello L, Sverzellati N, Wells AU, Hansell DM. Interobserver agreement for the ATS/ERS/JRS/ALAT criteria for a UIP pattern on CT. *Thorax* 2016;71:45–51.
- [25] Raghu G, Remy-Jardin M, Myers J, Richeldi L, Wilson KC. The 2018 Diagnosis of Idiopathic Pulmonary Fibrosis Guidelines: Surgical Lung Biopsy for Radiological Pattern of Probable Usual Interstitial Pneumonia Is Not Mandatory. *Am J Respir Crit Care Med* 2019;200:1089–92.
- [26] Rémy-Jardin M, Faivre JB, Hutt A, Felloni P, Rémy J. Critères de qualité du scanner thoracique réalisé pour une pneumopathie infiltrante diffuse. *La Lettre du Pneumologue* 2020;23:210–8.
- [27] Hansell DM, Bankier AA, MacMahon H, McLoud TC, Muller NL, Remy J. Fleischner Society: glossary of terms for thoracic imaging. *Radiology* 2008;246:697–722.
- [28] Lynch DA, Godwin JD, Safrin S, Starko KM, Hormel P, Brown KK, Raghu G, King Jr. TE, Bradford WZ, Schwartz DA, Richard Webb W. High-resolution computed tomography in idiopathic pulmonary fibrosis: diagnosis and prognosis. *Am J Respir Crit Care Med* 2005;172:488–93.
- [29] Sundaram B, Gross BH, Martinez FJ, Oh E, Muller NL, Schipper M, Kazerooni EA. Accuracy of high-resolution CT in the diagnosis of diffuse lung disease: effect of predominance and distribution of findings. *AJR Am J Roentgenol* 2008;191:1032–9.
- [30] Walsh SL, Sverzellati N, Devaraj A, Wells AU, Hansell DM. Chronic hypersensitivity pneumonitis: high resolution computed tomography patterns and pulmonary function indices as prognostic determinants. *Eur Radiol* 2012;22:1672–9.
- [31] Walsh SL, Sverzellati N, Devaraj A, Keir GJ, Wells AU, Hansell DM. Connective tissue disease related fibrotic lung disease: high resolution computed tomographic and pulmonary function indices as prognostic determinants. *Thorax* 2014;69:216–22.

[32] Edey AJ, Devaraj AA, Barker RP, Nicholson AG, Wells AU, Hansell DM. Fibrotic idiopathic interstitial pneumonias: HRCT findings that predict mortality. *Eur Radiol* 2011;21:1586–93.

[33] Sumikawa H, Johkoh T, Colby TV, Ichikado K, Suga M, Taniguchi H, Kondoh Y, Ogura T, Arakawa H, Fujimoto K, Inoue A, Mihara N, Honda O, Tomiyama N, Nakamura H, Muller NL. Computed tomography findings in pathological usual interstitial pneumonia: relationship to survival. *Am J Respir Crit Care Med* 2008;177:433–9.

[34] Remy-Jardin M, Giraud F, Remy J, Copin MC, Gosselin B, Duhamel A. Importance of ground-glass attenuation in chronic diffuse infiltrative lung disease: pathologic- CT correlation. *Radiology* 1993;189:693–8.

[35] Akira M, Kozuka T, Yamamoto S, Sakatani M. Computed tomography findings in acute exacerbation of idiopathic pulmonary fibrosis. *Am J Respir Crit Care Med* 2008;178:372–8.

[36] Collard HR, Moore BB, Flaherty KR, Brown KK, Kaner RJ, King Jr. TE, Lasky JA, Loyd JE, Noth I, Olman MA, Raghu G, Roman J, Ryu JH, Zisman DA, Hunninghake GW, Colby TV, Egan JJ, Hansell DM, Johkoh T, Kaminski N, Kim DS, Kondoh Y, Lynch DA, Muller-Quernheim J, Myers JL, Nicholson AG, Selman M, Toews GB, Wells AU, Martinez FJ. Acute exacerbations of idiopathic pulmonary fibrosis. *Am J Respir Crit Care Med* 2007;176:636–43.

[37] Cottin V, Capron F, Grenier P, Cordier JF. Pneumopathies interstitielles diffuses idiopathiques. Classification de Consensus International Multidisciplinaire de l'American Thoracic Society et de l'European Respiratory Society, principales entités anatomo-cliniques, et conduite du diagnostic. *Rev Mal Respir* 2004;21:299–318.

[38] Johkoh T, Muller NL, Cartier Y, Kavanagh PV, Hartman TE, Akira M, Ichikado K, Ando M, Nakamura H. Idiopathic interstitial pneumonias: diagnostic accuracy of thin-section CT in 129 patients. *Radiology* 1999;211:555–60.

[39] Hunninghake GW, Zimmerman MB, Schwartz DA, King Jr. TE, Lynch J, Hegele R, Waldron J, Colby T, Muller N, Lynch D, Galvin J, Gross B, Hogg J, Toews G, Helmers R, Cooper Jr. JA, Baughman R, Strange C, Millard M. Utility of a lung biopsy for the diagnosis of idiopathic pulmonary fibrosis. *Am J Respir Crit Care Med* 2001;164:193–6.

[40] Mathieson JR, Mayo JR, Staples CA, Muller NL. Chronic diffuse infiltrative lung disease: comparison of diagnostic accuracy of CT and chest radiography. *Radiology* 1989;171:111–6.

[41] Swensen SJ, Aughenbaugh GL, Myers JL. Diffuse lung disease: diagnostic accuracy of CT in patients undergoing surgical biopsy of the lung. *Radiology* 1997;205:229–34.

[42] Raghu G, Mageto YN, Lockhart D, Schmidt RA, Wood DE, Godwin JD. The accuracy of the clinical diagnosis of new-onset idiopathic pulmonary fibrosis and other interstitial lung disease: A prospective study. *Chest* 1999;116:1168–74.

- [43] Hunninghake GW, Lynch DA, Galvin JR, Gross BH, Muller N, Schwartz DA, King Jr. TE, Lynch 3rd JP, Hegele R, Waldron J, Colby TV, Hogg JC. Radiologic findings are strongly associated with a pathologic diagnosis of usual interstitial pneumonia. *Chest* 2003;124:1215–23.
- [44] Gruden JF, Panse PM, Leslie KO, Tazelaar HD, Colby TV. UIP diagnosed at surgical lung biopsy, 2000-2009: HRCT patterns and proposed classification system. *AJR Am J Roentgenol* 2013;200:W458–67.
- [45] Tcherakian C, Cottin V, Brillet PY, Freynet O, Naggara N, Carton Z, Cordier JF, Brauner M, Valeyre D, Nunes H. Progression of idiopathic pulmonary fibrosis: lessons from asymmetrical disease. *Thorax* 2011;66:226–31.
- [46] Souza CA, Muller NL, Lee KS, Johkoh T, Mitsuhiro H, Chong S. Idiopathic interstitial pneumonias: prevalence of mediastinal lymph node enlargement in 206 patients. *AJR Am J Roentgenol* 2006;186:995–9.
- [47] Adegunsoye A, Oldham JM, Bonham C, Hrusch C, Nolan P, Klejch W, Bellam S, Mehta U, Thakrar K, Pugashetti JV, Husain AN, Montner SM, Straus CM, Vij R, Sperling AI, Noth I, Strek ME, Chung JH. Prognosticating Outcomes in Interstitial Lung Disease by Mediastinal Lymph Node Assessment. An Observational Cohort Study with Independent Validation. *Am J Respir Crit Care Med* 2019;199:747– 59.
- [48] Egashira R, Jacob J, Kokosi MA, Brun AL, Rice A, Nicholson AG, Wells AU, Hansell DM. Diffuse Pulmonary Ossification in Fibrosing Interstitial Lung Diseases: Prevalence and Associations. *Radiology* 2017;284:255–63.
- [49] Gudmundsson E, Zhao A, Mogulkoc N, Stewart I, Jones MG, Van Moorsel CHM, Savas R, Brereton CJ, Van Es HW, Unat O, Pontoppidan K, Van Beek F, Veltkamp M, Gholipour B, Nair A, Wells AU, Janes SM, Alexander DC, Jacob J. Pleuroparenchymal fibroelastosis in idiopathic pulmonary fibrosis: Survival analysis using visual and computer-based computed tomography assessment. *EClinicalMedicine* 2021;38:101009.
- [50] Chung JH, Chawla A, Peljto AL, Cool CD, Groshong SD, Talbert JL, McKean DF, Brown KK, Fingerlin TE, Schwarz MI, Schwartz DA, Lynch DA. CT scan findings of probable usual interstitial pneumonitis have a high predictive value for histologic usual interstitial pneumonitis. *Chest* 2015;147:450–9.
- [51] Salisbury ML, Xia M, Murray S, Bartholmai BJ, Kazerooni EA, Meldrum CA, Martinez FJ, Flaherty KR. Predictors of idiopathic pulmonary fibrosis in absence of radiologic honeycombing: A cross sectional analysis in ILD patients undergoing lung tissue sampling. *Respir Med* 2016;118:88–95.
- [52] Brownell R, Moua T, Henry TS, Elicker BM, White D, Vittinghoff E, Jones KD, Urisman A, Aravena C, Johannson KA, Golden JA, King Jr. TE, Wolters PJ, Collard HR, Ley B. The use of pretest probability increases the value of high-resolution CT in diagnosing usual interstitial pneumonia. *Thorax* 2017;72:424–9.

- [53] Raghu G, Wells AU, Nicholson AG, Richeldi L, Flaherty KR, Le Maulf F, Stowasser S, Schlenker-Herceg R, Hansell DM. Effect of Nintedanib in Subgroups of Idiopathic Pulmonary Fibrosis by Diagnostic Criteria. *Am J Respir Crit Care Med* 2016.
- [54] Raghu G, Wells AU, Nicholson AG, Richeldi L, Flaherty KR, Le Maulf F, Stowasser S, Schlenker-Herceg R, Hansell DM. Effect of Nintedanib in Subgroups of Idiopathic Pulmonary Fibrosis by Diagnostic Criteria. *Am J Respir Crit Care Med* 2017;195:78–85.
- [55] Yagihashi K, Huckleberry J, Colby TV, Tazelaar HD, Zach J, Sundaram B, Pipavath S, Schwarz MI, Lynch DA. Radiologic-pathologic discordance in biopsy-proven usual interstitial pneumonia. *Eur Respir J* 2016;47:1189–97.
- [56] Barnett J, Molyneaux PL, Rawal B, Abdullah R, Hare SS, Vancheeswaran R, Desai SR, Maher TM, Wells AU, Devaraj A. Variable utility of mosaic attenuation to distinguish fibrotic hypersensitivity pneumonitis from idiopathic pulmonary fibrosis. *Eur Respir J* 2019;54.
- [57] Hutchinson JP, Fogarty AW, McKeever TM, Hubbard RB. In-Hospital Mortality after Surgical Lung Biopsy for Interstitial Lung Disease in the United States. 2000 to 2011. *Am J Respir Crit Care Med* 2016;193:1161–7.
- [58] Hutchinson JP, McKeever TM, Fogarty AW, Navaratnam V, Hubbard RB. Surgical lung biopsy for the diagnosis of interstitial lung disease in England: 1997-2008. *Eur Respir J* 2016;48:1453–61.
- [59] Fisher JH, Shapera S, To T, Marras TK, Gershon A, Dell S. Procedure volume and mortality after surgical lung biopsy in interstitial lung disease. *Eur Respir J* 2019;53:1801164.
- [60] Vaszar LT, Larsen BT, Swanson KL, Ryu JH, Tazelaar HD. Diagnostic utility of surgical lung biopsies in elderly patients with indeterminate interstitial lung disease. *Respirology* 2018;23:507–11.
- [61] Ayed AK. Video-assisted thoracoscopic lung biopsy in the diagnosis of diffuse interstitial lung disease. A prospective study. *J Cardiovasc Surg (Torino)* 2003;44:115–8.
- [62] Morris D, Zamvar V. The efficacy of video-assisted thoracoscopic surgery lung biopsies in patients with Interstitial Lung Disease: a retrospective study of 66 patients. *J Cardiothorac Surg* 2014;9:45.
- [63] Bagheri R, Haghi SZ, Attaran D, Hashem Asnaashari AM, Basiri R, Rajabnejad A. Efficacy of minimally invasive surgery in diagnosis of interstitial lung disease. *Asian Cardiovasc Thorac Ann* 2015;23:851–4.
- [64] Bando M, Ohno S, Hosono T, Yanase K, Sato Y, Sohara Y, Hironaka M, Sugiyama Y. Risk of Acute Exacerbation After Video-assisted Thoracoscopic Lung Biopsy for Interstitial Lung Disease. *J Bronchology Interv Pulmonol* 2009;16:229–35.
- [65] Blackhall V, Asif M, Renieri A, Civitelli S, Kirk A, Jilaihawi A, Granato F. The role of surgical lung biopsy in the management of interstitial lung disease: experience from a single institution in the UK. *Interact Cardiovasc Thorac Surg* 2013;17:253–7.

- [66] Blanco M, Obeso GA, Duran JC, Rivo JE, Garcia-Fontan E, Pena E, Rodriguez M, Albort J, Canizares MA. Surgical lung biopsy for diffuse lung disease. Our experience in the last 15 years. *Rev Port Pneumol* 2013;19:59–64.
- [67] Blewett CJ, Bennett WF, Miller JD, Urschel JD. Open lung biopsy as an outpatient procedure. *Ann Thorac Surg* 2001;71:1113–5.
- [68] Fibla JJ, Brunelli A, Allen MS, Wigle D, Shen R, Nichols F, Deschamps C, Cassivi SD. Do the number and volume of surgical lung biopsies influence the diagnostic yield in interstitial lung disease? A propensity score analysis. *Arch Bronconeumol* 2015;51:76–9.
- [69] Fındıkcıoğlu A, Kılıç D, Karadayı S, Canpolat T, Hatipoğlu A, Cerrahisi G. Is Surgical Biopsy Necessary for Diagnosis of Interstitial Lung Diseases: A Retrospective Clinical Study. *J Clin Anal Med* 2014;5:204–8.
- [70] Guerra M, Miranda JA, Leal F, Vouga L. Interstitial lung disease: diagnostic accuracy and safety of surgical lung biopsy. *Rev Port Pneumol* 2009;15:433–42.
- [71] Ishie RT, Cardoso JJ, Silveira RJ, Stocco L. Video-assisted thoracoscopy for the diagnosis of diffuse parenchymal lung disease. *J Bras Pneumol* 2009;35: 234–41.
- [72] Kayatta MO, Ahmed S, Hammel JA, Fernandez F, Pickens A, Miller D, Staton Jr. G, Veerarghavan S, Force S. Surgical biopsy of suspected interstitial lung disease is superior to radiographic diagnosis. *Ann Thorac Surg* 2013;96:399–401.
- [73] Khalil M, Cowen M, Chaudhry M, Loubani M. Single versus multiple lung biopsies for suspected interstitial lung disease. *Asian Cardiovasc Thorac Ann* 2016;24:788–91.
- [74] Kreider ME, Hansen-Flaschen J, Ahmad NN, Rossmann MD, Kaiser LR, Kucharczuk JC, Shrager JB. Complications of video-assisted thoracoscopic lung biopsy in patients with interstitial lung disease. *Ann Thorac Surg* 2007;83:1140–4.
- [75] Luo Q, Han Q, Chen X, Xie J, Wu L, Chen R. The diagnosis efficacy and safety of video-assisted thoracoscopy surgery (VATS) in undefined interstitial lung diseases: a retrospective study. *J Thorac Dis* 2013;5:283–8.
- [76] Miller JD, Urschel JD, Cox G, Olak J, Young JE, Kay JM, McDonald E. A randomized, controlled trial comparing thoracoscopy and limited thoracotomy for lung biopsy in interstitial lung disease. *Ann Thorac Surg* 2000;70:1647–50.
- [77] Ooi A, Iyenger S, Ferguson J, Ritchie AJ. VATS lung biopsy in suspected, diffuse interstitial lung disease provides diagnosis, and alters management strategies. *Heart Lung Circ* 2005;14:90–2.
- [78] Pompeo E, Rogliani P, Cristino B, Schillaci O, Novelli G, Saltini C. Awake thoracoscopic biopsy of interstitial lung disease. *Ann Thorac Surg* 2013;95:445–52.
- [79] Qureshi RA, Ahmed TA, Grayson AD, Soorae AS, Drakeley MJ, Page RD. Does lung biopsy help patients with interstitial lung disease? *Eur J Cardiothorac Surg* 2002;21:621–6 discussion 626.

- [80] Rotolo N, Imperatori A, Dominioni L, Facchini A, Conti V, Castiglioni M, Spanevello A. Efficacy and safety of surgical lung biopsy for interstitial disease. Experience of 161 consecutive patients from a single institution in Italy. *Sarcoidosis Vasc Diffuse Lung Dis* 2015;32:251–8.
- [81] Samejima J, Tajiri M, Ogura T, Baba T, Omori T, Tsuboi M, Masuda M. Thoracoscopic lung biopsy in 285 patients with diffuse pulmonary disease. *Asian Cardiovasc Thorac Ann* 2015;23:191–7.
- [82] Sigurdsson MI, Isaksson HJ, Gudmundsson G, Gudbjartsson T. Diagnostic surgical lung biopsies for suspected interstitial lung diseases: a retrospective study. *Ann Thorac Surg* 2009;88:227–32.
- [83] Sonobe M, Handa T, Tanizawa K, Sato M, Sato T, Chen F, Omasa M, Bando T, Date H, Mishima M. Videothoracoscopy-assisted surgical lung biopsy for interstitial lung diseases. *Gen Thorac Cardiovasc Surg* 2014;62:376–82.
- [84] Tomassetti S, Wells AU, Costabel U, Cavazza A, Colby TV, Rossi G, Sverzellati N, Carloni A, Carretta E, Buccioli M, Tantalocco P, Ravaglia C, Gurioli C, Dubini A, Piciocchi S, Ryu JH, Poletti V. Bronchoscopic Lung Cryobiopsy Increases Diagnostic Confidence in the Multidisciplinary Diagnosis of Idiopathic Pulmonary Fibrosis. *Am J Respir Crit Care Med* 2016;193:745–52.
- [85] Ravaglia C, Bonifazi M, Wells AU, Tomassetti S, Gurioli C, Piciocchi S, Dubini A, Tantalocco P, Sanna S, Negri E, Tramacere I, Ventura VA, Cavazza A, Rossi A, Chilosi M, La Vecchia C, Gasparini S, Poletti V. Safety and Diagnostic Yield of Transbronchial Lung Cryobiopsy in Diffuse Parenchymal Lung Diseases: A Comparative Study versus Video-Assisted Thoracoscopic Lung Biopsy and a Systematic Review of the Literature. *Respiration* 2016;91:215–27.
- [86] Morell F, Reyes L, Domenech G, De Gracia J, Majo J, Ferrer J. [Diagnoses and diagnostic procedures in 500 consecutive patients with clinical suspicion of interstitial lung disease]. *Arch Bronconeumol* 2008;44:185–91.
- [87] Iftikhar IH, Alghothani L, Sardi A, Berkowitz D, Musani AI. Transbronchial Lung Cryobiopsy and Video-assisted Thoracoscopic Lung Biopsy in the Diagnosis of Diffuse Parenchymal Lung Disease. A Meta-analysis of Diagnostic Test Accuracy. *Ann Am Thorac Soc* 2017;14:1197–211.
- [88] Walsh SLF, Lederer DJ, Ryerson CJ, Kolb M, Maher TM, Nusser R, Poletti V, Richeldi L, Vancheri C, Wilsher ML, Antoniou KM, Behr J, Bendstrup E, Brown KK, Corte TJ, Cottin V, Crestani B, Flaherty KR, Glaspole IN, Grutters J, Inoue Y, Kondoh Y, Kreuter M, Johannson KA, Ley B, Martinez FJ, Molina-Molina M, Morais A, Nunes H, Raghu G, Selman M, Spagnolo P, Taniguchi H, Tomassetti S, Valeyre D, Wijsenbeek M, Wuyts WA, Wells AU. Diagnostic Likelihood Thresholds That Define a Working Diagnosis of Idiopathic Pulmonary Fibrosis. *Am J Respir Crit Care Med* 2019;200:1146–53.

- [89] Hetzel J, Maldonado F, Ravaglia C, Wells AU, Colby TV, Tomassetti S, Ryu JH, Fruchter O, Piciucchi S, Dubini A, Cavazza A, Chilosi M, Sverzellati N, Valeyre D, Leduc D, Walsh SLF, Gasparini S, Hetzel M, Hagemeyer L, Haentschel M, Eberhardt R, Darwiche K, Yarmus LB, Torrego A, Krishna G, Shah PL, Annema JT, Herth FJF, Poletti V. Transbronchial Cryobiopsies for the Diagnosis of Diffuse Parenchymal Lung Diseases: Expert Statement from the Cryobiopsy Working Group on Safety and Utility and a Call for Standardization of the Procedure. *Respiration* 2018;95:188–200.
- [90] Babiak A, Hetzel J, Krishna G, Fritz P, Moeller P, Balli T, Hetzel M. Transbronchial cryobiopsy: a new tool for lung biopsies. *Respiration* 2009;78:203–8.
- [91] Troy LK, Grainge C, Corte T, Williamson JP, Vallely MP, Cooper W, Mahar AM, Lai S, Mulyadi E, Torzillo PJ, Salamonsen M, Don G, Myers J, Raghu G, Lau EMT, Team CI. Cryobiopsy versus open lung biopsy in the diagnosis of interstitial lung disease (COLDICE): protocol of a multicentre study. *BMJ open respiratory research* 2019;6:e000443.
- [92] Ravaglia C, Wells AU, Tomassetti S, Dubini A, Cavazza A, Piciucchi S, Sverzellati N, Gurioli C, Gurioli C, Costabel U, Tantalocco P, Ryu JH, Chilosi M, Poletti V. Transbronchial Lung Cryobiopsy in Diffuse Parenchymal Lung Disease: Comparison between Biopsy from 1 Segment and Biopsy from 2 Segments – Diagnostic Yield and Complications. *Respiration* 2017;93:285–92.
- [93] Colby TV, Tomassetti S, Cavazza A, Dubini A, Poletti V. Transbronchial Cryobiopsy in Diffuse Lung Disease: Update for the Pathologist. *Arch Pathol Lab Med* 2017;141:891–900.
- [94] Sheth JS, Belperio JA, Fishbein MC, Kazerooni EA, Lagstein A, Murray S, Myers JL, Simon RH, Sisson TH, Sundaram B, White ES, Xia M, Zisman D, Flaherty KR. Utility of Transbronchial vs Surgical Lung Biopsy in the Diagnosis of Suspected Fibrotic Interstitial Lung Disease. *Chest* 2017;151:389–99.
- [95] Ramaswamy A, Homer R, Killam J, Pisani MA, Murphy TE, Araujo K, Puchalski J. Comparison of Transbronchial and Cryobiopsies in Evaluation of Diffuse Parenchymal Lung Disease. *J Bronchology Interv Pulmonol* 2016;23:14–21.
- [96] Kim SY, Diggans J, Pankratz D, Huang J, Pagan M, Sindy N, Tom E, Anderson J, Choi Y, Lynch DA, Steele MP, Flaherty KR, Brown KK, Farah H, Bukstein MJ, Pardo A, Selman M, Wolters PJ, Nathan SD, Colby TV, Myers JL, Katzenstein AL, Raghu G, Kennedy GC. Classification of usual interstitial pneumonia in patients with interstitial lung disease: assessment of a machine learning approach using highdimensional transcriptional data. *Lancet Respir Med* 2015;3:473–82.
- [97] Pankratz DG, Choi Y, Imtiaz U, Fedorowicz GM, Anderson JD, Colby TV, Myers JL, Lynch DA, Brown KK, Flaherty KR, Steele MP, Groshong SD, Raghu G, Barth NM, Walsh PS, Huang J, Kennedy GC, Martinez FJ. Usual Interstitial Pneumonia Can Be Detected in Transbronchial Biopsies Using Machine Learning. *Ann Am Thorac Soc* 2017;14:1646–54.
- [98] Cascante JA, Cebollero P, Herrero S, Yague A, Echegoyen A, Elizalde J, Hueto J. Transbronchial Cryobiopsy in Interstitial Lung Disease: Are We on the Right Path? *J Bronchology Interv Pulmonol* 2016;23:204–9.

- [99] Fruchter O, Fridel L, El Raouf BA, Abdel-Rahman N, Rosengarten D, Kramer MR. Histological diagnosis of interstitial lung diseases by cryo-transbronchial biopsy. *Respirology* 2014;19:683–8.
- [100] Griff S, Schonfeld N, Ammenwerth W, Blum TG, Grah C, Bauer TT, Gruning W, Mairinger T, Wurps H. Diagnostic yield of transbronchial cryobiopsy in non-neoplastic lung disease: a retrospective case series. *BMC Pulm Med* 2014;14:171.
- [101] Hagemeyer L, Theegarten D, Treml M, Priegnitz C, Randerath W. Validation of transbronchial cryobiopsy in interstitial lung disease - interim analysis of a prospective trial and critical review of the literature. *Sarcoidosis Vasc Diffuse Lung Dis* 2016;33:2–9.
- [102] Hernandez-Gonzalez F, Lucena CM, Ramirez J, Sanchez M, Jimenez MJ, Xaubet A, Sellares J, Agusti C. Cryobiopsy in the diagnosis of diffuse interstitial lung disease: yield and cost-effectiveness analysis. *Arch Bronconeumol* 2015;51:261–7.
- [103] Kronborg-White S, Folkersen B, Rasmussen TR, Voldby N, Madsen LB, Rasmussen F, Poletti V, Bendstrup E. Introduction of cryobiopsies in the diagnostics of interstitial lung diseases - experiences in a referral center. *Eur Clin Respir J* 2017;4:1274099.
- [104] Kropski JA, Pritchett JM, Mason WR, Sivarajan L, Gleaves LA, Johnson JE, Lancaster LH, Lawson WE, Blackwell TS, Steele MP, Loyd JE, Rickman OB. Bronchoscopic cryobiopsy for the diagnosis of diffuse parenchymal lung disease. *PLoS One* 2013;8:e78674.
- [105] Pourabdollah M, Shamaei M, Karimi S, Karimi M, Kiani A, Jabbari HR. Transbronchial lung biopsy: the pathologist's point of view. *Clin Respir J* 2016;10:211–6.
- [106] Ussavarungsi K, Kern RM, Roden AC, Ryu JH, Edell ES. Transbronchial Cryobiopsy in Diffuse Parenchymal Lung Disease: Retrospective Analysis of 74 Cases. *Chest* 2017;151:400–8.
- [107] Tomassetti S, Wells AU, Costabel U, Cavazza A, Colby TV, Rossi G, Sverzellati N, Carloni A, Carretta E, Buccioli M, Tantalocco P, Ravaglia C, Gurioli C, Dubini A, Piciucchi S, Ryu JH, Poletti V. Bronchoscopic Lung Cryobiopsy Increases Diagnostic Confidence in the Multidisciplinary Diagnosis of Idiopathic Pulmonary Fibrosis. *Am J Respir Crit Care Med* 2015.
- [108] Romagnoli M, Colby TV, Berthet JP, Gamez AS, Mallet JP, Serre I, Cancellieri A, Cavazza A, Solovei L, Dell'Amore A, Dolci G, Guerrieri A, Reynaud P, Bommart S, Zompatori M, Dalpiaz G, Nava S, Trisolini R, Suehs CM, Vachier I, Molinari N, Bourdin A. Poor Concordance between Sequential Transbronchial Lung Cryobiopsy and Surgical Lung Biopsy in the Diagnosis of Diffuse Interstitial Lung Diseases. *Am J Respir Crit Care Med* 2019;199:1249–56.
- [109] Bondue B, Leduc D, Froidure A, Pieters T, Taton O, Heinen V, Alexander P, Hoton D, Dome F, Rimmelink M. Usefulness of surgical lung biopsies after cryobiopsies when pathological results are inconclusive or show a pattern suggestive of a nonspecific interstitial pneumonia. *Respir Res* 2020;21.

[110] Troy LK, Grainge C, Corte TJ, Williamson JP, Vallely MP, Cooper WA, Mahar A, Myers JL, Lai S, Mulyadi E, Torzillo PJ, Phillips MJ, Jo HE, Webster SE, Lin QT, Rhodes JE, Salamonsen M, Wrobel JP, Harris B, Don G, Wu PJC, Ng BJ, Oldmeadow C, Raghu G, Lau EMT. Diagnostic accuracy of transbronchial lung cryobiopsy for interstitial lung disease diagnosis (COLDICE): a prospective, comparative study. *Lancet Respir Med* 2019;8:171–81.

[111] Raghu G, Flaherty KR, Lederer DJ, Lynch DA, Colby TV, Myers JL, Groshong SD, Larsen BT, Chung JH, Steele MP, Benzaquen S, Calero K, Case AH, Criner GJ, Nathan SD, Rai NS, Ramaswamy M, Hagemeyer L, Davis JR, Gauhar UA, Pankratz DG, Choi Y, Huang J, Walsh PS, Neville H, Lofaro LR, Barth NM, Kennedy GC, Brown KK, Martinez FJ. Use of a molecular classifier to identify usual interstitial pneumonia in conventional transbronchial lung biopsy samples: a prospective validation study. *Lancet Respir Med* 2019;7:487–96.

[112] Richeldi L, Scholand MB, Lynch DA, Colby TV, Myers JL, Groshong SD, Chung JH, Benzaquen S, Nathan SD, Davis JR, Schmidt SL, Hagemeyer L, Sonetti D, Hetzel J, Criner GJ, Case AH, Ramaswamy M, Calero K, Gauhar UA, Patel NM, Lancaster L, Choi Y, Pankratz DG, Walsh PS, Lofaro LR, Huang J, Borade SM, Kennedy GC, Martinez FJ, Raghu G. Utility of a Molecular Classifier as a Complement to High-Resolution Computed Tomography to Identify Usual Interstitial Pneumonia. *Am J Respir Crit Care Med* 2021;203:211–20.

[113] Berbescu EA, Katzenstein A-LA, Snow JL, Zisman DA. Transbronchial biopsy in usual interstitial pneumonia. *Chest* 2006;129:1126–31.

[114] Cottin V, Hirani NA, Hotchkiss DL, Nambiar AM, Ogura T, Otaola M, Skowasch D, Park JS, Poonyagariyagorn HK, Wuyts W, Wells AU. Presentation, diagnosis and clinical course of the spectrum of progressive-fibrosing interstitial lung diseases. *Eur Respir Rev* 2018;27:180076.

[115] Cottin V, Valenzuela C. Diagnostic approach of fibrosing interstitial lung diseases of unknown origin. *Presse Med* 2020;49:104021.

[116] Travis WD, Costabel U, Hansell DM, King Jr. TE, Lynch DA, Nicholson AG, Ryerson CJ, Ryu JH, Selman M, Wells AU, Behr J, Bouros D, Brown KK, Colby TV, Collard HR, Cordeiro CR, Cottin V, Crestani B, Drent M, Dudden RF, Egan J, Flaherty K, Hogaboam C, Inoue Y, Johkoh T, Kim DS, Kitaichi M, Loyd J, Martinez FJ, Myers J, Protzko S, Raghu G, Richeldi L, Sverzellati N, Swigris J, Valeyre D. An official American Thoracic Society/European Respiratory Society statement: Update of the international multidisciplinary classification of the idiopathic interstitial pneumonias. *Am J Respir Crit Care Med* 2013;188:733–48.

[117] American Thoracic Society, European Respiratory Society. American Thoracic Society/European Respiratory Society International Multidisciplinary Consensus Classification of the Idiopathic Interstitial Pneumonias. This joint statement of the American Thoracic Society (ATS), and the European Respiratory Society (ERS) was adopted by the ATS board of directors, June 2001 and by the ERS Executive Committee, June 2001. *Am J Respir Crit Care Med* 2002;165:277–304.

- [118] Morell F, Villar A, Montero MA, Munoz X, Colby TV, Pipvath S, Cruz MJ, Raghu G. Chronic hypersensitivity pneumonitis in patients diagnosed with idiopathic pulmonary fibrosis: a prospective case-cohort study. *Lancet Respir Med* 2013;1:685–94.
- [119] Jeong YJ, Lee KS, Chung MP, Han J, Johkoh T, Ichikado K. Chronic hypersensitivity pneumonitis and pulmonary sarcoidosis: differentiation from usual interstitial pneumonia using high-resolution computed tomography. *Semin Ultrasound CT MR* 2014;35:47–58.
- [120] Wuyts WA, Cavazza A, Rossi G, Bonella F, Sverzellati N, Spagnolo P. Differential diagnosis of usual interstitial pneumonia: when is it truly idiopathic? *Eur Respir Rev* 2014;23:308–19.
- [121] Singh S, Collins BF, Sharma BB, Joshi JM, Talwar D, Katiyar S, Singh N, Ho L, Samaria JK, Bhattacharya P, Gupta R, Chaudhari S, Singh T, Moond V, Pipavath S, Ahuja J, Chetambath R, Ghoshal AG, Jain NK, Devi HJ, Kant S, Koul P, Dhar R, Swarnakar R, Sharma SK, Roy DJ, Sarmah KR, Jankharia B, Schmidt R, Katiyar SK, Jindal A, Mangal DK, Singh V, Raghu G. Interstitial Lung Disease in India. Results of a Prospective Registry. *Am J Respir Crit Care Med* 2017;195:801–13.
- [122] Salisbury ML, Myers JL, Belloli EA, Kazerooni EA, Martinez FJ, Flaherty KR. Diagnosis and Treatment of Fibrotic Hypersensitivity Pneumonia. Where We Stand and Where We Need to Go. *Am J Respir Crit Care Med* 2017;196:690–9.
- [123] Vasakova M, Morell F, Walsh S, Leslie K, Raghu G. Hypersensitivity Pneumonitis: Perspectives in Diagnosis and Management. *Am J Respir Crit Care Med* 2017;196:680–9.
- [124] Park JH, Kim DS, Park IN, Jang SJ, Kitaichi M, Nicholson AG, Colby TV. Prognosis of fibrotic interstitial pneumonia: idiopathic versus collagen vascular disease-related subtypes. *Am J Respir Crit Care Med* 2007;175:705–11.
- [125] Cottin V. Interstitial lung disease: are we missing formes frustes of connective tissue disease? *Eur Respir J* 2006;28:893–6.
- [126] Suzuki A, Sakamoto S, Kurosaki A, Kurihara Y, Satoh K, Usui Y, Nanki T, Arimura Y, Makino H, Okada Y, Harigai M, Yamagata K, Sugiyama H, Dobashi H, Ishizu A, Tsuboi N, Usui J, Sada KE, Homma S. Chest High-Resolution CT Findings of Microscopic Polyangiitis: A Japanese First Nationwide Prospective Cohort Study. *AJR Am J Roentgenol* 2019;213:104–14.
- [127] Foulon G, Delaval P, Valeyre D, Wallaert B, Debray MP, Brauner M, Nicaise P, Cadranel J, Cottin V, Tazi A, Aubier M, Crestani B. ANCA-associated lung fibrosis: analysis of 17 patients. *Respir Med* 2008;102:1392–8.
- [128] Fischer A, Antoniou KM, Brown KK, Cadranel J, Corte TJ, du Bois RM, Lee JS, Leslie KO, Lynch DA, Matteson EL, Mosca M, Noth I, Richeldi L, Strek ME, Swigris JJ, Wells AU, West SG, Collard HR, Cottin V. An official European Respiratory Society/American Thoracic Society research statement: interstitial pneumonia with autoimmune features. *Eur Respir J* 2015;46:976–87.

- [129] White ES, Xia M, Murray S, Dyal R, Flaherty CM, Flaherty KR, Moore BB, Cheng L, Doyle TJ, Villalba J, Dellaripa PF, Rosas IO, Kurtis JD, Martinez FJ. Plasma Surfactant Protein-D, Matrix Metalloproteinase-7, and Osteopontin Index Distinguishes Idiopathic Pulmonary Fibrosis from Other Idiopathic Interstitial Pneumonias. *Am J Respir Crit Care Med* 2016;194:1242–51.
- [130] Morais A, Beltrao M, Sokhatska O, Costa D, Melo N, Mota P, Marques A, Delgado L. Serum metalloproteinases 1 and 7 in the diagnosis of idiopathic pulmonary fibrosis and other interstitial pneumonias. *Respir Med* 2015;109:1063–8.
- [131] Maher TM, Oballa E, Simpson JK, Porte J, Habgood A, Fahy WA, Flynn A, Molyneaux PL, Braybrooke R, Divyateja H, Parfrey H, Rassl D, Russell AM, Saini G, Renzoni EA, Duggan AM, Hubbard R, Wells AU, Lukey PT, Marshall RP, Jenkins RG. An epithelial biomarker signature for idiopathic pulmonary fibrosis: an analysis from the multicentre PROFILE cohort study. *Lancet Respir Med* 2017;5:946– 55.
- [132] Meyer KC, Raghu G, Baughman RP, Brown KK, Costabel U, du Bois RM, Drent M, Haslam PL, Kim DS, Nagai S, Rottoli P, Saltini C, Selman M, Strange C, Wood B. An official American Thoracic Society clinical practice guideline: the clinical utility of bronchoalveolar lavage cellular analysis in interstitial lung disease. *Am J Respir Crit Care Med* 2012;185:1004–14.
- [133] Ohshimo S, Bonella F, Cui A, Beume M, Kohno N, Guzman J, Costabel U. Significance of bronchoalveolar lavage for the diagnosis of idiopathic pulmonary fibrosis. *Am J Respir Crit Care Med* 2009;179:1043–7.
- [134] Raghu G, Remy-Jardin M, Ryerson CJ, Myers JL, Kreuter M, Vasakova M, Bargagli E, Chung JH, Collins BF, Bendstrup E, Chami HA, Chua AT, Corte TJ, Dalphin JC, Danoff SK, Diaz-Mendoza J, Duggal A, Egashira R, Ewing T, Gulati M, Inoue Y, Jenkins AR, Johannson KA, Johkoh T, Tamae-Kakazu M, Kitaichi M, Knight SL, Koschel D, Lederer DJ, Mageto Y, Maier LA, Matiz C, Morell F, Nicholson AG, Patolia S, Pereira CA, Renzoni EA, Salisbury ML, Selman M, Walsh SLF, Wuyts WA, Wilson KC. Diagnosis of Hypersensitivity Pneumonitis in Adults. An Official ATS/JRS/ALAT Clinical Practice Guideline. *Am J Respir Crit Care Med* 2020;202:e36– 69.
- [135] Adderley N, Humphreys CJ, Barnes H, Ley B, Premji ZA, Johannson KA. Bronchoalveolar lavage fluid lymphocytosis in chronic hypersensitivity pneumonitis: a systematic review and meta-analysis. *Eur Respir J* 2020;56.
- [136] Tzilas V, Tzouvelekis A, Bouros E, Karampitsakos T, Ntasiou M, Katsaras M, Costabel U, Wells A, Bouros D. Diagnostic value of BAL lymphocytosis in patients with indeterminate for usual interstitial pneumonia imaging pattern. *Eur Respir J* 2019;54:1901144.
- [137] Lee W, Chung WS, Hong KS, Huh J. Clinical usefulness of bronchoalveolar lavage cellular analysis and lymphocyte subsets in diffuse interstitial lung diseases. *Ann Lab Med* 2015;35:220–5.

- [138] Schildge J, Frank J, Klar B. [The Role of Bronchoalveolar Lavage in the Diagnosis of Idiopathic Pulmonary Fibrosis: An Investigation of the Relevance of the Protein Content]. *Pneumologie* 2016;70:435–41.
- [139] Nagai S, Kitaichi M, Itoh H, Nishimura K, Izumi T, Colby TV. Idiopathic nonspecific interstitial pneumonia/fibrosis: comparison with idiopathic pulmonary fibrosis and BOOP. *Eur Respir J* 1998;12:1010–9.
- [140] Efares B, Ebang-Atsame G, Rabiou S, Diarra AS, Tahiri L, Hammas N, Smahi M, Amara B, Benjelloun MC, Serraj M, Chbani L, El Fatemi H. The diagnostic value of the bronchoalveolar lavage in interstitial lung diseases. *J Negat Results Biomed* 2017;16:4.
- [141] Welker L, Jorres RA, Costabel U, Magnussen H. Predictive value of BAL cell differentials in the diagnosis of interstitial lung diseases. *Eur Respir J* 2004;24:1000– 6.
- [142] Ryu YJ, Chung MP, Han J, Kim TS, Lee KS, Chun EM, Kyung SY, Jeong SH, Colby TV, Kim H, Kwon OJ. Bronchoalveolar lavage in fibrotic idiopathic interstitial pneumonias. *Respir Med* 2007;101:655–60.
- [143] Veeraraghavan S, Latsi PI, Wells AU, Pantelidis P, Nicholson AG, Colby TV, Haslam PL, Renzoni EA, du Bois RM. BAL findings in idiopathic nonspecific interstitial pneumonia and usual interstitial pneumonia. *Eur Respir J* 2003;22:239–44.
- [144] Abe M, Tsushima K, Ishii D, Shikano K, Yoshioka K, Sakayori M, Suzuki M, Hirasawa Y, Ishiwata T, Kawasaki T, Ikari J, Terada J, Tatsumi K. Risk factors for acute exacerbation following bronchoalveolar lavage in patients with suspected idiopathic pulmonary fibrosis: A retrospective cohort study. *Adv Respir Med* 2021;89:101–9.
- [145] Fingerlin TE, Murphy E, Zhang W, Peljto AL, Brown KK, Steele MP, Loyd JE, Cosgrove GP, Lynch D, Groshong S, Collard HR, Wolters PJ, Bradford WZ, Kossen K, Seiwert SD, du Bois RM, Garcia CK, Devine MS, Gudmundsson G, Isaksson HJ, Kaminski N, Zhang Y, Gibson KF, Lancaster LH, Cogan JD, Mason WR, Maher TM, Molyneaux PL, Wells AU, Moffatt MF, Selman M, Pardo A, Kim DS, Crapo JD, Make BJ, Regan EA, Walek DS, Daniel JJ, Kamatani Y, Zelenika D, Smith K, McKean D, Pedersen BS, Talbert J, Kidd RN, Markin CR, Beckman KB, Lathrop M, Schwarz MI, Schwartz DA. Genome-wide association study identifies multiple susceptibility loci for pulmonary fibrosis. *Nat Genet* 2013;45:613–20.
- [146] Peljto AL, Zhang Y, Fingerlin TE, Ma SF, Garcia JG, Richards TJ, Silveira LJ, Lindell KO, Steele MP, Loyd JE, Gibson KF, Seibold MA, Brown KK, Talbert JL, Markin C, Kossen K, Seiwert SD, Murphy E, Noth I, Schwarz MI, Kaminski N, Schwartz DA. Association between the MUC5B promoter polymorphism and survival in patients with idiopathic pulmonary fibrosis. *JAMA* 2013;309:2232–9.

- [147] Allen RJ, Porte J, Braybrooke R, Flores C, Fingerlin TE, Oldham JM, Guillen-Guio B, Ma SF, Okamoto T, John AE, Obeidat M, Yang IV, Henry A, Hubbard RB, Navaratnam V, Saini G, Thompson N, Booth HL, Hart SP, Hill MR, Hirani N, Maher TM, McAnulty RJ, Millar AB, Molyneaux PL, Parfrey H, Rassel DM, Whyte MKB, Fahy WA, Marshall RP, Oballa E, Bosse Y, Nickle DC, Sin DD, Timens W, Shrine N, Sayers I, Hall IP, Noth I, Schwartz DA, Tobin MD, Wain LV, Jenkins RG. Genetic variants associated with susceptibility to idiopathic pulmonary fibrosis in people of European ancestry: a genome-wide association study. *Lancet Respir Med* 2017;5:869–80.
- [148] Newton CA, Batra K, Torrealba J, Kozlitina J, Glazer CS, Aravena C, Meyer K, Raghu G, Collard HR, Garcia CK. Telomere-related lung fibrosis is diagnostically heterogeneous but uniformly progressive. *Eur Respir J* 2016;48:1710–20.
- [149] Borie R, Tabeze L, Thabut G, Nunes H, Cottin V, Marchand-Adam S, Prevot G, Tazi A, Cadranet J, Mal H, Wemeau-Stervinou L, Bergeron Lafaurie A, Israel-Biet D, Picard C, Reynaud Gaubert M, Jouneau S, Nacache JM, Mankikian J, Menard C, Cordier JF, Valeyre D, Reocreux M, Grandchamp B, Revy P, Kannengiesser C, Crestani B. Prevalence and characteristics of TERT and TERC mutations in suspected genetic pulmonary fibrosis. *Eur Respir J* 2016;48:1721–31.
- [150] Ley B, Newton CA, Arnould I, Elicker BM, Henry TS, Vittinghoff E, Golden JA, Jones KD, Batra K, Torrealba J, Garcia CK, Wolters PJ. The MUC5B promoter polymorphism and telomere length in patients with chronic hypersensitivity pneumonitis: an observational cohort-control study. *Lancet Respir Med* 2017;5:639–47.
- [151] Armanios MY, Chen JJ, Cogan JD, Alder JK, Ingersoll RG, Markin C, Lawson WE, Xie M, Vulto I, Phillips 3rd JA, Lansdorp PM, Greider CW, Loyd JE. Telomerase mutations in families with idiopathic pulmonary fibrosis. *N Engl J Med* 2007;356:1317–26.
- [152] Steele MP, Speer MC, Loyd JE, Brown KK, Herron A, Slifer SH, Burch LH, Wahidi MM, Phillips 3rd JA, Sporn TA, McAdams HP, Schwarz MI, Schwartz DA. Clinical and pathologic features of familial interstitial pneumonia. *Am J Respir Crit Care Med* 2005;172:1146–52.
- [153] Lee HY, Seo JB, Steele MP, Schwarz MI, Brown KK, Loyd JE, Talbert JL, Schwartz DA, Lynch DA. High-resolution CT scan findings in familial interstitial pneumonia do not conform to those of idiopathic interstitial pneumonia. *Chest* 2012;142:1577–83.
- [154] Lee HL, Ryu JH, Wittmer MH, Hartman TE, Lymp JF, Tazelaar HD, Limper AH. Familial idiopathic pulmonary fibrosis: clinical features and outcome. *Chest* 2005;127:2034–41.
- [155] Borie R, Kannengiesser C, Nathan N, Tabeze L, Pradere P, Crestani B. Fibroses pulmonaires familiales. *Rev Mal Respir* 2015;32:413–34.
- [156] Diaz de Leon A, Cronkhite JT, Katzenstein AL, Godwin JD, Raghu G, Glazer CS, Rosenblatt RL, Girod CE, Garrity ER, Xing C, Garcia CK. Telomere lengths, pulmonary fibrosis and telomerase (TERT) mutations. *PLoS One* 2010;5:e10680.

- [157] Cronkhite JT, Xing C, Raghu G, Chin KM, Torres F, Rosenblatt RL, Garcia CK. Telomere shortening in familial and sporadic pulmonary fibrosis. *Am J Respir Crit Care Med* 2008;178:729–37.
- [158] Borie R, Kannengiesser C, Hirschi S, Le Pavec J, Mal H, Bergot E, Jouneau S, Naccache JM, Revy P, Boutboul D, Peffault de la Tour R, Wemeau-Stervinou L, Philit F, Cordier JF, Thabut G, Crestani B, Cottin V. Severe hematologic complications after lung transplantation in patients with telomerase complex mutations. *J Heart Lung Transplant* 2015;34:538–46.
- [159] Stuart BD, Lee JS, Kozlitina J, Noth I, Devine MS, Glazer CS, Torres F, Kaza V, Girod CE, Jones KD, Elicker BM, Ma SF, Vij R, Collard HR, Wolters PJ, Garcia CK. Effect of telomere length on survival in patients with idiopathic pulmonary fibrosis: an observational cohort study with independent validation. *Lancet Respir Med* 2014;2:557–65.
- [160] Garcia CK. Running short on time: lung transplant evaluation for telomere-related pulmonary fibrosis. *Chest* 2015;147:1450–2.
- [161] van Moorsel CH, van Oosterhout MF, Barlo NP, de Jong PA, van der Vis JJ, Ruven HJ, van Es HW, van den Bosch JM, Grutters JC. Surfactant protein C mutations are the basis of a significant portion of adult familial pulmonary fibrosis in a dutch cohort. *Am J Respir Crit Care Med* 2010;182:1419–25.
- [162] Spagnolo P, Cottin V. Genetics of idiopathic pulmonary fibrosis: from mechanistic pathways to personalised medicine. *J Med Genet* 2017;54:93–9.
- [163] Diaz de Leon A, Cronkhite JT, Yilmaz C, Brewington C, Wang R, Xing C, Hsia CC, Garcia CK. Subclinical lung disease, macrocytosis, and premature graying in kindreds with telomerase (TERT) mutations. *Chest* 2011;140:753–63.
- [164] Chaudhuri N, Spencer L, Greaves M, Bishop P, Chaturvedi A, Leonard C. A Review of the Multidisciplinary Diagnosis of Interstitial Lung Diseases: A Retrospective Analysis in a Single UK Specialist Centre. *J Clin Med* 2016;5.
- [165] Thomeer M, Demedts M, Behr J, Buhl R, Costabel U, Flower CD, Verschakelen J, Laurent F, Nicholson AG, Verbeken EK, Capron F, Sardina M, Corvasce G, Lankhorst I. Multidisciplinary interobserver agreement in the diagnosis of idiopathic pulmonary fibrosis. *Eur Respir J* 2008;31:585–91.
- [166] Jo HE, Glaspole IN, Levin KC, McCormack SR, Mahar AM, Cooper WA, Cameron R, Ellis SJ, Cottee AM, Webster SE, Troy LK, Torzillo PJ, Corte P, Symons KM, Taylor N, Corte TJ. Clinical impact of the interstitial lung disease multidisciplinary service. *Respirology* 2016;21:1438–44.
- [167] Theegarten D, Muller HM, Bonella F, Wohlschlaeger J, Costabel U. Diagnostic approach to interstitial pneumonias in a single centre: report on 88 cases. *Diagn Pathol* 2012;7:160.

- [168] Walsh SL, Wells AU, Desai SR, Poletti V, Piciucchi S, Dubini A, Nunes H, Valeyre D, Brillet PY, Kambouchner M, Morais A, Pereira JM, Moura CS, Grutters JC, van den Heuvel DA, van Es HW, van Oosterhout MF, Seldenrijk CA, Bendstrup E, Rasmussen F, Madsen LB, Goptu B, Pomplun S, Taniguchi H, Fukuoka J, Johkoh T, Nicholson AG, Sayer C, Edmunds L, Jacob J, Kokosi MA, Myers JL, Flaherty KR, Hansell DM. Multicentre evaluation of multidisciplinary team meeting agreement on diagnosis in diffuse parenchymal lung disease: a case-cohort study. *Lancet Respir Med* 2016;4:557–65.
- [169] De Sadeleer LJ, Meert C, Yserbyt J, Slabbynck H, Verschakelen JA, Verbeken EK, Weynand B, De Langhe E, Lenaerts JL, Nemery B, Van Raemdonck D, Verleden GM, Wells AU, Wuyts WA. Diagnostic Ability of a Dynamic Multidisciplinary Discussion in Interstitial Lung Diseases: A Retrospective Observational Study of 938 Cases. *Chest* 2018;153:1416–23.
- [170] Lamas DJ, Kawut SM, Bagiella E, Philip N, Arcasoy SM, Lederer DJ. Delayed access and survival in idiopathic pulmonary fibrosis: a cohort study. *Am J Respir Crit Care Med* 2011;184:842–7.
- [171] Jo HE, Corte TJ, Moodley Y, Levin K, Westall G, Hopkins P, Chambers D, Glaspole I. Evaluating the interstitial lung disease multidisciplinary meeting: a survey of expert centres. *BMC Pulm Med* 2016;16:22.
- [172] Cottin V, Castillo D, Poletti V, Kreuter M, Corte TJ, Spagnolo P. Should Patients With Interstitial Lung Disease Be Seen by Experts? *Chest* 2018;154:713–4.
- [173] Wells AU. Any fool can make a rule and any fool will mind it. *BMC medicine* 2016;14:23.
- [174] Skolnik K, Ryerson CJ. Unclassifiable interstitial lung disease: A review. *Respirology* 2016;21:51–6.
- [175] Guler SA, Ryerson CJ. Unclassifiable interstitial lung disease: from phenotyping to possible treatments. *Curr Opin Pulm Med* 2018;24:461–8.
- [176] Guler SA, Ellison K, Algamdi M, Collard HR, Ryerson CJ. Heterogeneity in Unclassifiable Interstitial Lung Disease. A Systematic Review and Meta-Analysis. *Ann Am Thorac Soc* 2018;15:854–63.
- [177] Ryerson CJ, Urbania TH, Richeldi L, Mooney JJ, Lee JS, Jones KD, Elicker BM, Koth LL, King Jr. TE, Wolters PJ, Collard HR. Prevalence and prognosis of unclassifiable interstitial lung disease. *Eur Respir J* 2013;42:750–7.
- [178] Hyldgaard C, Bendstrup E, Wells AU, Hilberg O. Unclassifiable interstitial lung diseases: Clinical characteristics and survival. *Respirology* 2017;22:494–500.
- [179] Ryerson CJ, Corte TJ, Lee JS, Richeldi L, Walsh SLF, Myers JL, Behr J, Cottin V, Danoff SK, Flaherty KR, Lederer DJ, Lynch DA, Martinez FJ, Raghu G, Travis WD, Udwadia Z, Wells AU, Collard HR. A Standardized Diagnostic Ontology for Fibrotic Interstitial Lung Disease. An International Working Group Perspective. *Am J Respir Crit Care Med* 2017;196:1249–54.

- [180] Thomeer MJ, Vansteenkiste J, Verbeken EK, Demedts M. Interstitial lung diseases: characteristics at diagnosis and mortality risk assessment. *Respir Med* 2004;98:567–73.
- [181] Jacob J, Bartholmai BJ, Rajagopalan S, Egashira R, Brun AL, Kokosi M, Nair A, Walsh SLF, Karwoski R, Nicholson AG, Hansell DM, Wells AU. Unclassifiable interstitial lung disease: Outcome prediction using CT and functional indices. *Respir Med* 2017;130:43–51.
- [182] Ley B, Collard HR, King Jr. TE. Clinical course and prediction of survival in idiopathic pulmonary fibrosis. *Am J Respir Crit Care Med* 2011;183:431–40.
- [183] Raghu G, Ley B, Brown KK, Cottin V, Gibson KF, Kaner RJ, Lederer DJ, Noble PW, Song JW, Wells AU, Whelan TP, Lynch DA, Humphries SM, Moreau E, Goodman K, Patterson SD, Smith V, Gong Q, Sundry JS, O’Riordan TG, Martinez FJ. Risk factors for disease progression in idiopathic pulmonary fibrosis. *Thorax* 2019;75:78–80.
- [184] du Bois RM, Weycker D, Albera C, Bradford WZ, Costabel U, Kartashov A, Lancaster L, Noble PW, Raghu G, Sahn SA, Szwarzberg J, Thomeer M, Valeyre D, King Jr TE. Ascertainment of individual risk of mortality for patients with idiopathic pulmonary fibrosis. *Am J Respir Crit Care Med* 2011;184:459–66.
- [185] Jouneau S, Gamez AS, Tracllet J, Nunes H, Marchand-Adam S, Kessler R, Israel-Biet D, Borie R, Strombom I, Scalori A, Crestani B, Valeyre D, Cottin V. A 2-Year Observational Study in Patients Suffering from Idiopathic Pulmonary Fibrosis and Treated with Pirfenidone: A French Ancillary Study of PASSPORT. *Respiration* 2019;98:19–28.
- [186] Jouneau S, Kerjouan M, Rousseau C, Lederlin M, Llamas-Gutierrez F, De Latour B, Guillot S, Vernhet L, Desrues B, Thibault R. What are the best indicators to assess malnutrition in idiopathic pulmonary fibrosis patients? A cross-sectional study in a referral center. *Nutrition* 2019;62:115–21.
- [187] Jouneau S, Crestani B, Thibault R, Lederlin M, Vernhet L, Valenzuela C, Wijsenbeek M, Kreuter M, Stansen W, Quaresma M, Cottin V. Analysis of body mass index, weight loss and progression of idiopathic pulmonary fibrosis. *Respir Res* 2020;21:312.
- [188] Ley B, Ryerson CJ, Vittinghoff E, Ryu JH, Tomassetti S, Lee JS, Poletti V, Buccioli M, Elicker BM, Jones KD, King Jr. TE, Collard HR. A multidimensional index and staging system for idiopathic pulmonary fibrosis. *Ann Intern Med* 2012;156:684–91.
- [189] Ley B, Bradford WZ, Weycker D, Vittinghoff E, du Bois RM, Collard HR. Unified baseline and longitudinal mortality prediction in idiopathic pulmonary fibrosis. *Eur Respir J* 2015;45:1374–81.
- [190] Salisbury ML, Xia M, Zhou Y, Murray S, Tayob N, Brown KK, Wells AU, Schmidt SL, Martinez FJ, Flaherty KR. Idiopathic Pulmonary Fibrosis: Gender-Age-Physiology Index Stage for Predicting Future Lung Function Decline. *Chest* 2015;149:491–8.

[191] Ley B, Elicker BM, Hartman TE, Ryerson CJ, Vittinghoff E, Ryu JH, Lee JS, Jones KD, Richeldi L, King Jr. TE, Collard HR. Idiopathic pulmonary fibrosis: CT and risk of death. *Radiology* 2014;273:570–9.

[192] Wells AU, Desai SR, Rubens MB, Goh NS, Cramer D, Nicholson AG, Colby TV, du Bois RM, Hansell DM. Idiopathic pulmonary fibrosis: a composite physiologic index derived from disease extent observed by computed tomography. *Am J Respir Crit Care Med* 2003;167:962–9.

[193] Schmidt SL, Tayob N, Han MK, Zappala C, Kervitsky D, Murray S, Wells AU, Brown KK, Martinez FJ, Flaherty KR. Predicting pulmonary fibrosis disease course from past trends in pulmonary function. *Chest* 2014;145:579–85.

[194] Zappala CJ, Latsi PI, Nicholson AG, Colby TV, Cramer D, Renzoni EA, Hansell DM, du Bois RM, Wells AU. Marginal decline in forced vital capacity is associated with a poor outcome in idiopathic pulmonary fibrosis. *European Respiratory Journal* 2010;35:830–6.

[195] du Bois RM, Weycker D, Albera C, Bradford WZ, Costabel U, Kartashov A, King Jr. TE, Lancaster L, Noble PW, Sahn SA, Thomeer M, Valeyre D, Wells AU. Forced vital capacity in patients with idiopathic pulmonary fibrosis: test properties and minimal clinically important difference. *Am J Respir Crit Care Med* 2011;184:1382–9.

[196] Richeldi L, Ryerson CJ, Lee JS, Wolters PJ, Koth LL, Ley B, Elicker BM, Jones KD, King TE, Ryu JH, Collard HR. Relative versus absolute change in forced vital capacity in idiopathic pulmonary fibrosis. *Thorax* 2012;67:407–11.

[197] Wells AU. Forced vital capacity as a primary end point in idiopathic pulmonary fibrosis treatment trials: making a silk purse from a sow's ear. *Thorax* 2012.

[198] Aguilaniu B. EFX et pneumopathies interstitielles diffuses: qu'en attendre et quelle place dans la prise en charge ? *La Lettre du Pneumologue* 2016;19:17–20.

[199] Holland AE. Exercise limitation in interstitial lung disease - mechanisms, significance and therapeutic options. *Chron Respir Dis* 2010;7:101–11.

[200] Brown SW, Dobelle M, Padilla M, Agovino M, Wisnivesky JP, Hashim D, Boffetta P. Idiopathic Pulmonary Fibrosis and Lung Cancer. A Systematic Review and Meta-analysis. *Ann Am Thorac Soc* 2019;16:1041–51.

[201] O'Brien EC, Hellkamp AS, Neely ML, Swaminathan A, Bender S, Snyder LD, Culver DA, Conoscenti CS, Todd JL, Palmer SM, Leonard TB. Disease Severity and Quality of Life in Patients With Idiopathic Pulmonary Fibrosis: A Cross-Sectional Analysis of the IPF-PRO Registry. *Chest* 2020;157:1188–98.

[202] Wapenaar M, Patel AS, Biring SS, Domburg RTV, Bakker EW, Vindigni V, Skold CM, Cottin V, Vancheri C, Wijzenbeek MS. Translation and validation of the King's Brief Interstitial Lung Disease (K-BILD) questionnaire in French, Italian, Swedish, and Dutch. *Chronic respiratory disease* 2017;14:140–50.

- [203] Nolan CM, Birring SS, Maddocks M, Maher TM, Patel S, Barker RE, Jones SE, Walsh JA, Wynne SC, George PM, Man WD. King's Brief Interstitial Lung Disease questionnaire: responsiveness and minimum clinically important difference. *Eur Respir J* 2019;54:1900281.
- [204] Ruwanpura SM, Thomas BJ, Bardin PG. Pirfenidone: Molecular Mechanisms and Potential Clinical Applications in Lung Disease. *Am J Respir Cell Mol Biol* 2020;62:413–22.
- [205] Carter NJ. Pirfenidone: in idiopathic pulmonary fibrosis. *Drugs* 2011;71: 1721–32.
- [206] Raghu G, Johnson WC, Lockhart D, Mageto Y. Treatment of idiopathic pulmonary fibrosis with a new antifibrotic agent, pirfenidone: results of a prospective, open-label Phase II study. *Am J Respir Crit Care Med* 1999;159:1061–9.
- [207] Azuma A, Nukiwa T, Tsuboi E, Suga M, Abe S, Nakata K, Taguchi Y, Nagai S, Itoh H, Ohi M, Sato A, Kudoh S. Double-blind, placebo-controlled trial of pirfenidone in patients with idiopathic pulmonary fibrosis. *Am J Respir Crit Care Med* 2005;171:1040–7.
- [208] Taniguchi H, Ebina M, Kondoh Y, Ogura T, Azuma A, Suga M, Taguchi Y, Takahashi H, Nakata K, Sato A, Takeuchi M, Raghu G, Kudoh S, Nukiwa T. Pirfenidone in idiopathic pulmonary fibrosis. *Eur Respir J* 2010;35:821–9.
- [209] Noble PW, Albera C, Bradford WZ, Costabel U, Glassberg MK, Kardatzke D, King Jr. TE, Lancaster L, Sahn SA, Swarcberg J, Valeyre D, du Bois RM. Pirfenidone in patients with idiopathic pulmonary fibrosis (CAPACITY): two randomised trials. *Lancet* 2011;377:1760–9.
- [210] King Jr. TE, Bradford WZ, Castro-Bernardini S, Fagan EA, Glaspole I, Glassberg MK, Gorina E, Hopkins PM, Kardatzke D, Lancaster L, Lederer DJ, Nathan SD, Pereira CA, Sahn SA, Sussman R, Swigris JJ, Noble PW. A phase 3 trial of pirfenidone in patients with idiopathic pulmonary fibrosis. *N Engl J Med* 2014;370:2083–92.
- [211] Vancheri C, du Bois RM. A progression-free end-point for idiopathic pulmonary fibrosis trials: lessons from cancer. *Eur Respir J* 2013;41:262–9.
- [212] du Bois RM, Weycker D, Albera C, Bradford WZ, Costabel U, Kartashov A, Lancaster L, Noble PW, Sahn SA, Swarcberg J, Thomeer M, Valeyre D, King Jr. TE. Sixminute-walk test in idiopathic pulmonary fibrosis: test validation and minimal clinically important difference. *Am J Respir Crit Care Med* 2011;183:1231–7.
- [213] Spagnolo P, Del Giovane C, Luppi F, Cerri S, Balduzzi S, Walters EH, D'Amico R, Richeldi L. Non-steroid agents for idiopathic pulmonary fibrosis. *Cochrane Database Syst Rev* 2010:CD003134.
- [214] Lederer DJ, Bradford WZ, Fagan EA, Glaspole I, Glassberg MK, Glasscock KF, Kardatzke D, King Jr. TE, Lancaster LH, Nathan SD, Pereira CA, Sahn SA, Swigris JJ, Noble PW. Sensitivity Analyses of the Change in FVC in a Phase 3 Trial of Pirfenidone for Idiopathic Pulmonary Fibrosis. *Chest* 2015;148:196–201.

[215] Noble PW, Albera C, Bradford WZ, Costabel U, du Bois RM, Fagan EA, Fishman RS, Glaspole I, Glassberg MK, Lancaster L, Lederer DJ, Leff JA, Nathan SD, Pereira CA, Swigris JJ, Valeyre D, King Jr. TE. Pirfenidone for idiopathic pulmonary fibrosis: analysis of pooled data from three multinational phase 3 trials. *Eur Respir J* 2016;47:243–53.

[216] Ley B, Swigris J, Day BM, Stauffer JL, Raimundo K, Chou W, Collard HR. Pirfenidone Reduces Respiratory-related Hospitalizations in Idiopathic Pulmonary Fibrosis. *Am J Respir Crit Care Med* 2017;196:756–61.

[217] Nathan SD, Costabel U, Glaspole I, Glassberg MK, Lancaster LH, Lederer DJ, Pereira CA, Trzaskoma B, Morgenthien EA, Limb SL, Wells AU. Efficacy of Pirfenidone in the Context of Multiple Disease Progression Events in Patients With Idiopathic Pulmonary Fibrosis. *Chest* 2019;155:712–9.

[218] Glassberg MK, Wijsenbeek MS, Gilberg F, Petzinger U, Kirchgaessler KU, Albera C. Effect of pirfenidone on breathlessness in patients with idiopathic pulmonary fibrosis. *Eur Respir J* 2019;54:1900399.

[219] Nathan SD, Costabel U, Albera C, Behr J, Wuyts WA, Kirchgaessler KU, Stauffer JL, Morgenthien E, Chou W, Limb SL, Noble PW. Pirfenidone in patients with idiopathic pulmonary fibrosis and more advanced lung function impairment. *Respir Med* 2019;153:44–51.

[220] Costabel U, Albera C, Lancaster LH, Lin CY, Hormel P, Hulter HN, Noble PW. An Open-Label Study of the Long-Term Safety of Pirfenidone in Patients with Idiopathic Pulmonary Fibrosis (RECAP). *Respiration* 2017;94:408–15.

[221] Costabel U, Albera C, Bradford WZ, Hormel P, King Jr. TE, Noble PW, Sahn SA, Valeyre D, du Bois RM. Analysis of lung function and survival in RECAP: An open-label extension study of pirfenidone in patients with idiopathic pulmonary fibrosis. *Sarcoidosis Vasc Diffuse Lung Dis* 2014;31:198–205.

[222] Sugino K, Ishida F, Kikuchi N, Hirota N, Sano G, Sato K, Isobe K, Sakamoto S, Takai Y, Homma S. Comparison of clinical characteristics and prognostic factors of combined pulmonary fibrosis and emphysema versus idiopathic pulmonary fibrosis alone. *Respirology* 2014;19:239–45.

[223] Iwasawa T, Ogura T, Sakai F, Kanauchi T, Komagata T, Baba T, Gotoh T, Morita S, Yazawa T, Inoue T. CT analysis of the effect of pirfenidone in patients with idiopathic pulmonary fibrosis. *Eur J Radiol* 2014;83:32–8.

[224] Loeh B, Drakopanagiotakis F, Bandelli GP, von der Beck D, Tello S, Cordani E, Rizza E, Barrocu L, Markart P, Seeger W, Guenther A, Albera C. Intraindividual response to treatment with pirfenidone in idiopathic pulmonary fibrosis. *Am J Respir Crit Care Med* 2015;191:110–3.

- [225] Harari S, Caminati A, Albera C, Vancheri C, Poletti V, Pesci A, Luppi F, Saltini C, Agostini C, Bargagli E, Sebastiani A, Sanduzzi A, Giunta V, Della Porta R, Bandelli GP, Puglisi S, Tomassetti S, Biffi A, Cerri S, Mari A, Cinetto F, Tirelli F, Farinelli G, Bocchino M, Specchia C, Confalonieri M. Efficacy of pirfenidone for idiopathic pulmonary fibrosis: An Italian real life study. *Respir Med* 2015;109:904–13.
- [226] Oltmanns U, Kahn N, Palmowski K, Trager A, Wenz H, Heussel CP, Schnabel PA, Puderbach M, Wiebel M, Ehlers-Tenenbaum S, Warth A, Herth FJ, Kreuter M. Pirfenidone in idiopathic pulmonary fibrosis: real-life experience from a German tertiary referral center for interstitial lung diseases. *Respiration* 2014;88:199–207.
- [227] Kreuter M. Pirfenidone: an update on clinical trial data and insights from everyday practice. *Eur Respir Rev* 2014;23:111–7.
- [228] Fang C, Huang H, Guo J, Ferianc M, Xu Z. Real-world experiences: Efficacy and tolerability of pirfenidone in clinical practice. *PLoS One* 2020;15:e0228390.
- [229] Eaden JA, Barber CM, Renshaw SA, Chaudhuri N, Bianchi SM. Real world experience of response to pirfenidone in patients with idiopathic pulmonary fibrosis: a two centre retrospective study. *Sarcoidosis Vasc Diffuse Lung Dis* 2020;37:218–24.
- [230] Vancheri C, Sebastiani A, Tomassetti S, Pesci A, Rogliani P, Tavanti L, Luppi F, Harari S, Rottoli P, Ghirardini A, Kirchgaessler KU, Albera C. Pirfenidone in real life: A retrospective observational multicentre study in Italian patients with idiopathic pulmonary fibrosis. *Respir Med* 2019;156:78–84.
- [231] Cottin V, Koschel D, Gunther A, Albera C, Azuma A, Skold CM, Tomassetti S, Hormel P, Stauffer JL, Strombom I, Kirchgaessler KU, Maher TM. Long-term safety of pirfenidone: results of the prospective, observational PASSPORT study. *ERJ Open Res* 2018;4.
- [232] Tzouveleakis A, Karampitsakos T, Ntolios P, Tzilas V, Bouros E, Markozannes E, Malliou I, Anagnostopoulos A, Granitsas A, Steiropoulos P, Dimakou K, Chrysikos S, Koulouris N, Bouros D. Longitudinal "Real-World" Outcomes of Pirfenidone in Idiopathic Pulmonary Fibrosis in Greece. *Frontiers in medicine* 2017;4:213.
- [233] Ogawa K, Miyamoto A, Hanada S, Takahashi Y, Murase K, Mochizuki S, Uruga H, Takaya H, Morokawa N, Kishi K. The Efficacy and Safety of Long-term Pirfenidone Therapy in Patients with Idiopathic Pulmonary Fibrosis. *Intern Med* 2018;57:2813–8.
- [234] Fisher M, Nathan SD, Hill C, Marshall J, Dejonckheere F, Thuresson PO, Maher TM. Predicting Life Expectancy for Pirfenidone in Idiopathic Pulmonary Fibrosis. *J Manag Care Spec Pharm* 2017;23:S17–24.
- [235] Birring SS, Fleming T, Matos S, Raj AA, Evans DH, Pavord ID. The Leicester Cough Monitor: preliminary validation of an automated cough detection system in chronic cough. *Eur Respir J* 2008;31:1013–8.

- [236] van Manen MJG, Birring SS, Vancheri C, Vindigni V, Renzoni E, Russell AM, Wapenaar M, Cottin V, Wijsenbeek MS. Effect of pirfenidone on cough in patients with idiopathic pulmonary fibrosis. *Eur Respir J* 2017;50:1701157.
- [237] Valeyre D, Albera C, Bradford WZ, Costabel U, King Jr. TE, Leff JA, Noble PW, Sahn SA, du Bois RM. Comprehensive assessment of the long-term safety of pirfenidone in patients with idiopathic pulmonary fibrosis. *Respirology* 2014;19:740–7.
- [238] Jiang C, Huang H, Liu J, Wang Y, Lu Z, Xu Z. Adverse events of pirfenidone for the treatment of pulmonary fibrosis: a meta-analysis of randomized controlled trials. *PLoS One* 2012;7:e47024.
- [239] Margaritopoulos GA, Trachalaki A, Wells AU, Vasarmidi E, Bibaki E, Papastratigakis G, Detorakis S, Tzanakis N, Antoniou KM. Pirfenidone improves survival in IPF: results from a real-life study. *BMC Pulm Med* 2018;18:177.
- [240] Glassberg MK, Nathan SD, Lin CY, Morgenthien EA, Stauffer JL, Chou W, Noble PW. Cardiovascular Risks, Bleeding Risks, and Clinical Events from 3 Phase III Trials of Pirfenidone in Patients with Idiopathic Pulmonary Fibrosis. *Advances in therapy* 2019;36:2910–26.
- [241] Costabel U, Bendstrup E, Cottin V, Dewint P, Egan JJ, Ferguson J, Groves R, Hellstrom PM, Kreuter M, Maher TM, Molina-Molina M, Nordlind K, Sarafidis A, Vancheri C. Pirfenidone in idiopathic pulmonary fibrosis: expert panel discussion on the management of drug-related adverse events. *Advances in therapy* 2014;31:375–91.
- [242] Song MJ, Moon SW, Choi JS, Lee SH, Lee SH, Chung KS, Jung JY, Kang YA, Park MS, Kim YS, Chang J, Kim SY. Efficacy of low dose pirfenidone in idiopathic pulmonary fibrosis: real world experience from a tertiary university hospital. *Sci Rep* 2020;10:21218.
- [243] Uehara M, Enomoto N, Oyama Y, Suzuki Y, Kono M, Furuhashi K, Fujisawa T, Inui N, Nakamura Y, Suda T. Body size-adjusted dose analysis of pirfenidone in patients with interstitial pneumonia. *Respirology* 2018;23:318–24.
- [244] Agence française de sécurité sanitaire des produits de santé. ESBRIET (pirféridone): Mise à jour Importante de sécurité et nouvelles recommandations concernant les risques d'atteintes hépatiques d'origine médicamenteuse - Lettre aux professionnels de santé. 2020 March 22]. Available from <https://ansm.sante.fr/S-informer/Informations-de-securite-Lettres-aux-professionnels-desante/ESBRIET-pirfenidone-Mise-a-jour-Importante-de-securite-et-nouvellesrecommandations-concernant-les-risques-d-atteintes-hepatiques-d-origine-medicamenteuse-Lettre-aux-professionnels-de-sante>.
- [245] Grimminger F, Gunther A, Vancheri C. The role of tyrosine kinases in the pathogenesis of idiopathic pulmonary fibrosis. *Eur Respir J* 2015;45:1426–33.
- [246] Wollin L, Wex E, Pautsch A, Schnapp G, Hostettler KE, Stowasser S, Kolb M. Mode of action of nintedanib in the treatment of idiopathic pulmonary fibrosis. *Eur Respir J* 2015;45:1434–45.

- [247] Wollin L, Maillet I, Quesniaux V, Holweg A, Ryffel B. Antifibrotic and anti-inflammatory activity of the tyrosine kinase inhibitor nintedanib in experimental models of lung fibrosis. *J Pharmacol Exp Ther* 2014;349:209–20.
- [248] Hostettler KE, Zhong J, Papakonstantinou E, Karakiulakis G, Tamm M, Seidel P, Sun Q, Mandal J, Lardinois D, Lambers C, Roth M. Anti-fibrotic effects of nintedanib in lung fibroblasts derived from patients with idiopathic pulmonary fibrosis. *Respir Res* 2014;15:157.
- [249] Rangarajan S, Kurundkar A, Kurundkar D, Bernard K, Sanders YY, Ding Q, Antony VB, Zhang J, Zmijewski J, Thannickal VJ. Novel Mechanisms for the Antifibrotic Action of Nintedanib. *Am J Respir Cell Mol Biol* 2016;54:51–9.
- [250] Richeldi L, Costabel U, Selman M, Kim DS, Hansell DM, Nicholson AG, Brown KK, Flaherty KR, Noble PW, Raghu G, Brun M, Gupta A, Juhel N, Kluglich M, du Bois RM. Efficacy of a tyrosine kinase inhibitor in idiopathic pulmonary fibrosis. *N Engl J Med* 2011;365:1079–87.
- [251] Richeldi L, Cottin V, Flaherty KR, Kolb M, Inoue Y, Raghu G, Taniguchi H, Hansell DM, Nicholson AG, Le Maulf F, Stowasser S, Collard HR. Design of the INPULSIS trials: two phase 3 trials of nintedanib in patients with idiopathic pulmonary fibrosis. *Respir Med* 2014;108:1023–30.
- [252] Richeldi L, du Bois RM, Raghu G, Azuma A, Brown KK, Costabel U, Cottin V, Flaherty KR, Hansell DM, Inoue Y, Kim DS, Kolb M, Nicholson AG, Noble PW, Selman M, Taniguchi H, Brun M, Le Maulf F, Girard M, Stowasser S, Schlenker-Herceg R, Disse B, Collard HR. Efficacy and safety of nintedanib in idiopathic pulmonary fibrosis. *N Engl J Med* 2014;370:2071–82.
- [253] Costabel U, Inoue Y, Richeldi L, Collard HR, Tschöepe I, Stowasser S, Azuma A. Efficacy of Nintedanib in Idiopathic Pulmonary Fibrosis across Prespecified Subgroups in INPULSIS. *Am J Respir Crit Care Med* 2016;193:178–85.
- [254] Kolb M, Richeldi L, Behr J, Maher TM, Tang W, Stowasser S, Hallmann C, du Bois RM. Nintedanib in patients with idiopathic pulmonary fibrosis and preserved lung volume. *Thorax* 2016;72:340–6.
- [255] Cottin V. Nintedanib: a new treatment for idiopathic pulmonary fibrosis. *Clinical Investigation* 2015;5:621–32.
- [256] Richeldi L, Cottin V, du Bois RM, Selman M, Kimura T, Bailes Z, Schlenker-Herceg R, Stowasser S, Brown KK. Nintedanib in patients with idiopathic pulmonary fibrosis: combined evidence from the TOMORROW and INPULSIS trials. *Respiratory Medicine* 2016.
- [257] Crestani B, Huggins JT, Kaye M, Costabel U, Glaspole I, Ogura T, Song JW, Stansen W, Quaresma M, Stowasser S, Kreuter M. Long-term safety and tolerability of nintedanib in patients with idiopathic pulmonary fibrosis: results from the open-label extension study, INPULSIS-ON. *Lancet Respir Med* 2019;7:60–8.

- [258] Lancaster L, Goldin J, Trampisch M, Kim GH, Ilowite J, Homik L, Hotchkin DL, Kaye M, Ryerson CJ, Mogulkoc N, Conoscenti CS. Effects of Nintedanib on Quantitative Lung Fibrosis Score in Idiopathic Pulmonary Fibrosis. *The open respiratory medicine journal* 2020;14:22–31.
- [259] Goldin J, Kim G, Lu P, Porter S, Gorina E, Brown M. Short term Quantitative Lung Fibrosis (QLF) change predicts rapid rate of FVC decline in patients with IPF. *Eur Respir J* 2017;50:PA853.
- [260] Kim G, Brown M, Goldin J, Lu P, Gorina E, Porter S. Automatic quantitative fibrosis scores at baseline is a predictor of progression in patients with IPF. *Eur Respir J* 2017;50:OA1957.
- [261] Brown KK, Flaherty KR, Cottin V, Raghu G, Inoue Y, Azuma A, Huggins JT, Richeldi L, Stowasser S, Stansen W, Schlenker-Herceg R, Maher TM, Wells AU. Lung function outcomes in the INPULSIS() trials of nintedanib in idiopathic pulmonary fibrosis. *Respir Med* 2019;146:42–8.
- [262] Kreuter M, Wuyts WA, Wijsenbeek M, Bajwah S, Maher TM, Stowasser S, Male N, Stansen W, Schoof N, Orsatti L, Swigris J. Health-related quality of life and symptoms in patients with IPF treated with nintedanib: analyses of patient-reported outcomes from the INPULSIS_ trials. *Respir Res* 2020;21:36.
- [263] Toellner H, Hughes G, Beswick W, Crooks MG, Donaldson C, Forrest I, Hart SP, Leonard C, Major M, Simpson AJ, Chaudhuri N. Early clinical experiences with nintedanib in three UK tertiary interstitial lung disease centres. *Clinical and translational medicine* 2017;6:41.
- [264] Bargagli E, Piccioli C, Rosi E, Torricelli E, Turi L, Piccioli E, Pistolesi M, Ferrari K, Voltolini L. Pirfenidone and Nintedanib in idiopathic pulmonary fibrosis: Reallife experience in an Italian referral centre. *Pulmonology* 2019;25:149–53.
- [265] Brunnemer E, Walscher J, Tenenbaum S, Hausmanns J, Schulze K, Seiter M, Heussel CP, Warth A, Herth FJF, Kreuter M. Real-World Experience with Nintedanib in Patients with Idiopathic Pulmonary Fibrosis. *Respiration* 2018;95:301–9.
- [266] Fletcher SV, Jones MG, Renzoni EA, Parfrey H, Hoyles RK, Spinks K, Kokosi M, Kwok A, Warburton C, Titmuss V, Thillai M, Simler N, Maher TM, Brereton CJ, Chua F, Wells AU, Richeldi L, Spencer LG. Safety and tolerability of nintedanib for the treatment of idiopathic pulmonary fibrosis in routine UK clinical practice. *ERJ Open Res* 2018;4:00049–2018.
- [267] Noth I, Oelberg D, Kaul M, Conoscenti CS, Raghu G. Safety and tolerability of nintedanib in patients with idiopathic pulmonary fibrosis in the USA. *Eur Respir J* 2018;52:1702106.
- [268] Rivera-Ortega P, Hayton C, Blaikley J, Leonard C, Chaudhuri N. Nintedanib in the management of idiopathic pulmonary fibrosis: clinical trial evidence and realworld experience. *Ther Adv Respir Dis* 2018;12:1753466618800618.

[269] Tzouvelekis A, Karampitsakos T, Kontou M, Granitsas A, Malliou I, Anagnostopoulos A, Ntoliou P, Tzilas V, Bouros E, Steiropoulos P, Chrysikos S, Dimakou K, Koulouris N, Bouros D. Safety and efficacy of nintedanib in idiopathic pulmonary fibrosis: A real-life observational study in Greece. *Pulmonary pharmacology & therapeutics* 2018;49:61–6.

[270] Antoniou K, Markopoulou K, Tzouvelekis A, Trachalaki A, Vasarmidi E, Organtzis J, Tzilas V, Bouros E, Kounti G, Rampiadou C, Kotoulas SC, Bardaka F, Bibaki E, Fouka E, Meletis G, Tryfon S, Daniil Z, Papakosta D, Bouros D. Efficacy and safety of nintedanib in a Greek multicentre idiopathic pulmonary fibrosis registry: a retrospective, observational, cohort study. *ERJ Open Res* 2020;6:00172–2019.

[271] Kato M, Sasaki S, Nakamura T, Kurokawa K, Yamada T, Ochi Y, Ihara H, Takahashi F, Takahashi K. Gastrointestinal adverse effects of nintedanib and the associated risk factors in patients with idiopathic pulmonary fibrosis. *Sci Rep* 2019;9:12062.

[272] Lancaster L, Crestani B, Hernandez P, Inoue Y, Wachtlin D, Loaiza L, Quaresma M, Stowasser S, Richeldi L. Safety and survival data in patients with idiopathic pulmonary fibrosis treated with nintedanib: pooled data from six clinical trials. *BMJ open respiratory research* 2019;6:e000397.

[273] Noth I, Wijsenbeek M, Kolb M, Bonella F, Moros L, Wachtlin D, Corte TJ. Cardiovascular safety of nintedanib in subgroups by cardiovascular risk at baseline in the TOMORROW and INPULSIS trials. *Eur Respir J* 2019;54:1801797.

[274] Corte T, Bonella F, Crestani B, Demedts MG, Richeldi L, Coeck C, Pelling K, Quaresma M, Lasky JA. Safety, tolerability and appropriate use of nintedanib in idiopathic pulmonary fibrosis. *Respir Res* 2015;16:116.

[275] Toi Y, Kimura Y, Domeki Y, Kawana S, Aiba T, Ono H, Aso M, Tsurumi K, Suzuki K, Shimizu H, Sugisaka J, Saito R, Terayama K, Kawashima Y, Nakamura A, Yamanda S, Honda Y, Sugawara S. Association of low body surface area with dose reduction and/or discontinuation of nintedanib in patients with idiopathic pulmonary fibrosis: a pilot study. *Sarcoidosis Vasc Diffuse Lung Dis* 2019;36:74–8.

[276] Jo HE, Glaspole I, Grainge C, Goh N, Hopkins PM, Moodley Y, Reynolds PN, Chapman S, Walters EH, Zappala C, Allan H, Keir GJ, Hayen A, Cooper WA, Mahar AM, Ellis S, Macansh S, Corte TJ. Baseline characteristics of idiopathic pulmonary fibrosis: analysis from the Australian Idiopathic Pulmonary Fibrosis Registry. *Eur Respir J* 2017;49:1601592.

[277] Guenther A, Krauss E, Tello S, Wagner J, Paul B, Kuhn S, Maurer O, Heinemann S, Costabel U, Barbero MAN, Muller V, Bonniaud P, Vancheri C, Wells A, Vasakova M, Pesci A, Sofia M, Klepetko W, Seeger W, Drakopanagiotakis F, Crestani B. The European IPF registry (eurIPFreg): baseline characteristics and survival of patients with idiopathic pulmonary fibrosis. *Respir Res* 2018;19:141.

[278] Dempsey TM, Sangaralingham LR, Yao X, Sanghavi D, Shah ND, Limper AH. Clinical Effectiveness of Antifibrotic Medications for Idiopathic Pulmonary Fibrosis. *Am J Respir Crit Care Med* 2019;200:168–74.

[279] Behr J, Prasse A, Wirtz H, Koschel D, Pittrow D, Held M, Klotsche J, Andreas S, Claussen M, Groh_e C, Wilkens H, Hagemeyer L, Skowasch D, Meyer JF, Kirschner J, Gl€aser S, Kahn N, Welte T, Neurohr C, Schwaiblmair M, Bahmer T, Oqueka T, Frankenberger M, Kreuter M. Survival and course of lung function in the presence or absence of antifibrotic treatment in patients with idiopathic pulmonary fibrosis: long-term results of the INSIGHTS-IPF registry. *Eur Respir J* 2020;56.

[280] Kang J, Han M, Song JW. Antifibrotic treatment improves clinical outcomes in patients with idiopathic pulmonary fibrosis: a propensity score matching analysis. *Scientific reports* 2020;10:15620.

[281] Delanote I, Wuyts WA, Yserbyt J, Verbeken EK, Verleden GM, Vos R. Safety and efficacy of bridging to lung transplantation with antifibrotic drugs in idiopathic pulmonary fibrosis: a case series. *BMC Pulm Med* 2016;16:156.

[282] Yanagihara T, Sato S, Upagupta C, Kolb M. What have we learned from basic science studies on idiopathic pulmonary fibrosis? *Eur Respir Rev* 2019;28:190029.

[283] Spagnolo P, Kropski JA, Jones MG, Lee JS, Rossi G, Karampitsakos T, Maher TM, Tzouveleakis A, Ryerson CJ. Idiopathic pulmonary fibrosis: Disease mechanisms and drug development. *Pharmacol Ther* 2020;222:107798.

[284] Albera C, Costabel U, Fagan EA, Glassberg MK, Gorina E, Lancaster L, Lederer DJ, Nathan SD, Spirig D, Swigris JJ. Efficacy of pirfenidone in patients with idiopathic pulmonary fibrosis with more preserved lung function. *Eur Respir J* 2016;48:843–51.

[285] Maher TM, Stowasser S, Nishioka Y, White ES, Cottin V, Noth I, Selman M, Rohr KB, Michael A, Ittrich C, Diefenbach C, Jenkins RG, It investigators. Biomarkers of extracellular matrix turnover in patients with idiopathic pulmonary fibrosis given nintedanib (INMARK study): a randomised, placebo-controlled study. *Lancet Respir Med* 2019;7:771–9.

[286] Wuyts WA, Kolb M, Stowasser S, Stansen W, Huggins JT, Raghu G. First Data on Efficacy and Safety of Nintedanib in Patients with Idiopathic Pulmonary Fibrosis and Forced Vital Capacity of ≤ 50 % of Predicted Value. *Lung* 2016;194:739–43.

[287] Caminati A, Cassandro R, Torre O, Harari S. Severe idiopathic pulmonary fibrosis: what can be done? *Eur Respir Rev* 2017;26.

[288] Abe M, Tsushima K, Sakayori M, Suzuki K, Ikari J, Terada J, Tatsumi K. Utility of nintedanib for severe idiopathic pulmonary fibrosis: a single-center retrospective study. *Drug Des Devel Ther* 2018;12:3369–75.

- [289] Harari S, Caminati A, Poletti V, Confalonieri M, Gasparini S, Lacedonia D, Luppi F, Pesci A, Sebastiani A, Spagnolo P, Vancheri C, Balestro E, Bonifazi M, Cerri S, De Giacomo F, Della Porta R, Foschino Barbaro MP, Fui A, Pasquinelli P, Rosso R, Tomassetti S, Specchia C, Rottoli P. A Real-Life Multicenter National Study on Nintedanib in Severe Idiopathic Pulmonary Fibrosis. *Respiration* 2018;95:433–40.
- [290] Tzouvelekis A, Bouros D. Nintedanib in Severe Idiopathic Pulmonary Fibrosis: Effectiveness through Compassion. *Respiration* 2018;95:401–2.
- [291] Yoon HY, Park S, Kim DS, Song JW. Efficacy and safety of nintedanib in advanced idiopathic pulmonary fibrosis. *Respir Res* 2018;19:203.
- [292] Barczy E, Starobinski L, Kolonics-Farkas A, Eszes N, Bohacs A, Vasakova M, Hejduk K, M€uller V. Long-Term Effects and Adverse Events of Nintedanib Therapy in Idiopathic Pulmonary Fibrosis Patients with Functionally Advanced Disease. *Adv Ther* 2019;36:1221–32.
- [293] Nakamura M, Okamoto M, Fujimoto K, Ebata T, Tominaga M, Nouno T, Zaizen Y, Kaieda S, Tsuda T, Kawayama T, Hoshino T. A retrospective study of the tolerability of nintedanib for severe idiopathic pulmonary fibrosis in the real world. *Annals of translational medicine* 2019;7:262.
- [294] Nathan SD. Nintedanib and Sildenafil in Patients with Idiopathic Pulmonary Fibrosis. Echoes of the Past, Lessons for the Future. *Am J Respir Crit Care Med* 2019;200:1459–61.
- [295] Chung MP, Park MS, Oh IJ, Lee HB, Kim YW, Park JS, Uh ST, Kim YS, Jegal Y, Song JW. Safety and Efficacy of Pirfenidone in Advanced Idiopathic Pulmonary Fibrosis: A Nationwide Post-Marketing Surveillance Study in Korean Patients. *Adv Ther* 2020;37:2303–16.
- [296] Richeldi L, Kolb M, Jouneau S, Wuyts WA, Schinzel B, Stowasser S, Quaresma M, Raghu G. Efficacy and safety of nintedanib in patients with advanced idiopathic pulmonary fibrosis. *BMC Pulm Med* 2020;20:3.
- [297] Senoo S, Miyahara N, Taniguchi A, Oda N, Itano J, Higo H, Hara N, Watanabe H, Kano H, Suwaki T, Fuchimoto Y, Kajimoto K, Ichikawa H, Kudo K, Shibayama T, Tanimoto Y, Kuyama S, Kanehiro A, Maeda Y, Kiura K. Nintedanib can be used safely and effectively for idiopathic pulmonary fibrosis with predicted forced vital capacity $\leq 50\%$: A multi-center retrospective analysis. *PLoS One* 2020;15: e0236935.
- [298] Wuyts WA, Antoniou KM, Borensztajn K, Costabel U, Cottin V, Crestani B, Grutters JC, Maher TM, Poletti V, Richeldi L, Vancheri C, Wells AU. Combination therapy: the future of management for idiopathic pulmonary fibrosis? *Lancet Respir Med* 2014;2:933–42.
- [299] Ogura T, Taniguchi H, Azuma A, Inoue Y, Kondoh Y, Hasegawa Y, Bando M, Abe S, Mochizuki Y, Chida K, Kluglich M, Fujimoto T, Okazaki K, Tadayasu Y, Sakamoto W, Sugiyama Y. Safety and pharmacokinetics of nintedanib and pirfenidone in idiopathic pulmonary fibrosis. *Eur Respir J* 2015;45:1382–92.

- [300] Richeldi L, Fletcher S, Adamali H, Chaudhuri N, Wiebe S, Wind S, Hohl K, Baker A, Schlenker-Herceg R, Stowasser S, Maher TM. No relevant pharmacokinetic drugdrug interaction between nintedanib and pirfenidone. *Eur Respir J* 2019;53:1801060.
- [301] Vancheri C, Kreuter M, Richeldi L, Ryerson CJ, Valeyre D, Grutters JC, Wiebe S, Stansen W, Quaresma M, Stowasser S, Wuyts WA, Investigators IT. Nintedanib with Add-on Pirfenidone in Idiopathic Pulmonary Fibrosis. Results of the INJOURNEY Trial. *Am J Respir Crit Care Med* 2018;197:356–63.
- [302] Flaherty KR, Fell CD, Huggins JT, Nunes H, Sussman R, Valenzuela C, Petzinger U, Stauffer JL, Gilberg F, Bengus M, Wijsenbeek M. Safety of nintedanib added to pirfenidone treatment for idiopathic pulmonary fibrosis. *Eur Respir J* 2018;52:1800230.
- [303] Cottin V, Hospices Civils de Lyon. Pragmatic Management of Progressive Disease in Idiopathic Pulmonary Fibrosis: a Randomized Trial. 2020 April 7, 2021]. Available from: <https://clinicaltrials.gov/ct2/show/study/NCT03939520>.
- [304] King Jr. TE, Behr J, Brown KK, du Bois RM, Lancaster L, de Andrade JA, Stahler G, Leconte I, Roux S, Raghu G. BUILD-1: a randomized placebo-controlled trial of bosentan in idiopathic pulmonary fibrosis. *Am J Respir Crit Care Med* 2008;177:75–81.
- [305] King Jr. TE, Brown KK, Raghu G, du Bois RM, Lynch DA, Martinez F, Valeyre D, Leconte I, Morganti A, Roux S, Behr J. BUILD-3: a randomized, controlled trial of bosentan in idiopathic pulmonary fibrosis. *Am J Respir Crit Care Med* 2011;184:92–9.
- [306] Raghu G, Million-Rousseau R, Morganti A, Perchenet L, Behr J. Efficacy and safety of macitentan in idiopathic pulmonary fibrosis: results of a prospective, randomized, double-blind, placebo-controlled trial. *Am J Respir Crit Care Med* 2012;185:A3631.
- [307] Behr J, Bendstrup E, Crestani B, Gunther A, Olschewski H, Skold CM, Wells A, Wuyts W, Koschel D, Kreuter M, Wallaert B, Lin CY, Beck J, Albera C. Safety and tolerability of acetylcysteine and pirfenidone combination therapy in idiopathic pulmonary fibrosis: a randomised, double-blind, placebo-controlled, phase 2 trial. *Lancet Respir Med* 2016;4:445–53.
- [308] Kolb M, Raghu G, Wells AU, Behr J, Richeldi L, Schinzel B, Quaresma M, Stowasser S, Martinez FJ. Nintedanib plus Sildenafil in Patients with Idiopathic Pulmonary Fibrosis. *N Engl J Med* 2018;379:1722–31.
- [309] Douglas WW, Ryu JH, Schroeder DR. Idiopathic pulmonary fibrosis: Impact of oxygen and colchicine, prednisone, or no therapy on survival. *Am J Respir Crit Care Med* 2000;161:1172–8.
- [310] Nagai S, Kitaichi M, Hamada K, Nagao T, Hoshino Y, Miki H, Izumi T. Hospitalbased historical cohort study of 234 histologically proven Japanese patients with IPF. *Sarcoidosis Vasc Diffuse Lung Dis* 1999;16:209–14.

- [311] Gay SE, Kazerooni EA, Toews GB, Lynch 3rd JP, Gross BH, Cascade PN, Spizarny DL, Flint A, Schork MA, Whyte RI, Popovich J, Hyzy R, Martinez FJ. Idiopathic pulmonary fibrosis: predicting response to therapy and survival. *Am J Respir Crit Care Med* 1998;157:1063–72.
- [312] Collard HR, Ryu JH, Douglas WW, Schwarz MI, Curran-Everett D, King Jr. TE, Brown KK. Combined corticosteroid and cyclophosphamide therapy does not alter survival in idiopathic pulmonary fibrosis. *Chest* 2004;125:2169–74.
- [313] Pereira CA, Malheiros T, Coletta EM, Ferreira RG, Rubin AS, Otta JS, Rocha NS. Survival in idiopathic pulmonary fibrosis-cytotoxic agents compared to corticosteroids. *Respir Med* 2006;100:340–7.
- [314] Grgic A, Lausberg H, Heinrich M, Koenig J, Uder M, Sybrecht GW, Wilkens H. Progression of fibrosis in usual interstitial pneumonia: serial evaluation of the native lung after single lung transplantation. *Respiration* 2008;76:139–45.
- [315] Wahidi MM, Ravenel J, Palmer SM, McAdams HP. Progression of idiopathic pulmonary fibrosis in native lungs after single lung transplantation. *Chest* 2002;121:2072–6.
- [316] Fiorucci E, Lucantoni G, Paone G, Zotti M, Li BE, Serpilli M, Regimenti P, Cammarella I, Puglisi G, Schmid G. Colchicine, cyclophosphamide and prednisone in the treatment of mild-moderate idiopathic pulmonary fibrosis: comparison of three currently available therapeutic regimens. *Eur Rev Med Pharmacol Sci* 2008;12:105–11.
- [317] Antoniou KM, Nicholson AG, Dimadi M, Malagari K, Latsi P, Rapti A, Tzanakis N, Trigidou R, Polychronopoulos V, Bouros D. Long-term clinical effects of interferon gamma-1b and colchicine in idiopathic pulmonary fibrosis. *Eur Respir J* 2006;28:496–504.
- [318] Douglas WW, Ryu JH, Swensen SJ, Offord KP, Schroeder DR, Caron GM, DeRemee RA. Colchicine versus prednisone in the treatment of idiopathic pulmonary fibrosis. A randomized prospective study. Members of the Lung Study Group. *Am J Respir Crit Care Med* 1998;158:220–5.
- [319] Shulgina L, Cahn AP, Chilvers ER, Parfrey H, Clark AB, Wilson EC, Twentyman OP, Davison AG, Curtin JJ, Crawford MB, Wilson AM. Treating idiopathic pulmonary fibrosis with the addition of co-trimoxazole: a randomised controlled trial. *Thorax* 2013;68:155–62.
- [320] Wilson AM, Clark AB, Cahn T, Chilvers ER, Fraser W, Hammond M, Livermore DM, Maher TM, Parfrey H, Swart AM, Stirling S, Thickett DR, Whyte M. Effect of Co-trimoxazole (Trimethoprim-Sulfamethoxazole) vs Placebo on Death, Lung Transplant, or Hospital Admission in Patients With Moderate and Severe Idiopathic Pulmonary Fibrosis: The EME-TIPAC Randomized Clinical Trial. *Jama* 2020;324:2282–91.
- [321] Martinez FJ, Yow E, Flaherty KR, Snyder LD, Durham MT, Wisniewski SR, Sciruba FC, Raghu G, Brooks MM, Kim DY, Dilling DF, Criner GJ, Kim H, Belloli EA, Nambiar AM, Scholand MB, Anstrom KJ, Noth I. Effect of Antimicrobial Therapy on Respiratory Hospitalization or Death in Adults With Idiopathic Pulmonary Fibrosis: The CleanUP-IPF Randomized Clinical Trial. *Jama* 2021;325:1841–51.

- [322] Raghu G, Brown KK, Costabel U, Cottin V, du Bois RM, Lasky JA, Thomeer M, Utz JP, Khandker RK, McDermott L, Fatenejad S. Treatment of idiopathic pulmonary fibrosis with etanercept: an exploratory, placebo-controlled trial. *Am J Respir Crit Care Med* 2008;178:948–55.
- [323] Kreuter M, Lederer DJ, Molina-Molina M, Noth I, Valenzuela C, Frankenstein L, Weycker D, Atwood M, Kirchgaessler KU, Cottin V. Association of Angiotensin Modulators With the Course of Idiopathic Pulmonary Fibrosis. *Chest* 2019;156:706–14.
- [324] Raghu G, Brown KK, Bradford WZ, Starko K, Noble PW, Schwartz DA, King Jr. TE. A placebo-controlled trial of interferon gamma-1b in patients with idiopathic pulmonary fibrosis. *N Engl J Med* 2004;350:125–33.
- [325] King Jr. TE, Albera C, Bradford WZ, Costabel U, Hormel P, Lancaster L, Noble PW, Sahn SA, Szwarzberg J, Thomeer M, Valeyre D, du Bois RM. Effect of interferon gamma-1b on survival in patients with idiopathic pulmonary fibrosis (INSPIRE): a multicentre, randomised, placebo-controlled trial. *Lancet* 2009;374:222–8.
- [326] Raghu G, Anstrom KJ, King Jr. TE, Lasky JA, Martinez FJ. Prednisone, azathioprine, and N-acetylcysteine for pulmonary fibrosis. *N Engl J Med* 2012;366:1968–77.
- [327] Oldham JM, Ma SF, Martinez FJ, Anstrom KJ, Raghu G, Schwartz DA, Valenzi E, Witt L, Lee C, Vij R, Huang Y, Strek ME, Noth I. TOLLIP, MUC5B, and the Response to N-Acetylcysteine among Individuals with Idiopathic Pulmonary Fibrosis. *Am J Respir Crit Care Med* 2015;192:1475–82.
- [328] Raghu G, Behr J, Brown KK, Egan J, Kawut SM, Flaherty KR, Martinez FJ, Nathan SD, Wells AU, Pedersen P, Shao L, Chien J, O'Riordan T. ARTEMIS-IPF: a placebo-controlled trial of ambrisentan in idiopathic pulmonary fibrosis. *Am J Respir Crit Care Med* 2012;185:A3632.
- [329] Noth I, Anstrom KJ, Calvert SB, de Andrade J, Flaherty KR, Glazer C, Kaner RJ, Olan MA. A placebo-controlled randomized trial of warfarin in idiopathic pulmonary fibrosis. *Am J Respir Crit Care Med* 2012;186:88–95.
- [330] Kreuter M, Wijsenbeek MS, Vasakova M, Spagnolo P, Kolb M, Costabel U, Weycker D, Kirchgaessler KU, Maher TM. Unfavourable effects of medically indicated oral anticoagulants on survival in idiopathic pulmonary fibrosis. *Eur Respir J* 2016;47:1776–84.
- [331] Hope-Gill BD, Hilldrup S, Davies C, Newton RP, Harrison NK. A study of the cough reflex in idiopathic pulmonary fibrosis. *Am J Respir Crit Care Med* 2003;168:995–1002.
- [332] Raghu G, Behr JB, KK Egan J, Kawut SM, Flaherty KR, Martinez FJN, S D, Wells AU, Pedersen P, Shao L, Chien J, O'Riordan T. ARTEMIS-IPF: a placebo-controlled trial of ambrisentan in idiopathic pulmonary fibrosis. *Am J Respir Crit Care Med* 2012;185:A3632.

- [333] Mason DP, Brizzio ME, Alster JM, McNeill AM, Murthy SC, Budev MM, Mehta AC, Minai OA, Pettersson GB, Blackstone EH. Lung transplantation for idiopathic pulmonary fibrosis. *Ann Thorac Surg* 2007;84:1121–8.
- [334] Keating D, Levvey B, Kotsimbos T, Whitford H, Westall G, Williams T, Snell G. Lung transplantation in pulmonary fibrosis: challenging early outcomes counterbalanced by surprisingly good outcomes beyond 15 years. *Transplant Proc* 2009;41:289–91.
- [335] Thabut G, Mal H, Castier Y, Groussard O, Brugiére O, Marrash-Chahla R, Leseche G, Fournier M. Survival benefit of lung transplantation for patients with idiopathic pulmonary fibrosis. *J Thorac Cardiovasc Surg* 2003;126:469–75.
- [336] The International Society for Heart and Lung Transplantation. Adult Lung Transplantation Statistics. 2015 26 Mai 2016]. Available from: <https://www.ishlt.org/registries/slides.asp?slides=heartLungRegistry>.
- [337] Weill D, Benden C, Corris PA, Dark JH, Davis RD, Keshavjee S, Lederer DJ, Mulligan MJ, Patterson GA, Singer LG, Snell GI, Verleden GM, Zamora MR, Glanville AR. A consensus document for the selection of lung transplant candidates: 2014—an update from the Pulmonary Transplantation Council of the International Society for Heart and Lung Transplantation. *J Heart Lung Transplant* 2015;34:1–15.
- [338] Li D, Liu Y, Wang B. Single versus bilateral lung transplantation in idiopathic pulmonary fibrosis: A systematic review and meta-analysis. *PLoS One* 2020;15: e0233732.
- [339] Nathan SD, Shlobin OA, Ahmad S, Koch J, Barnett SD, Ad N, Burton N, Leslie K. Serial development of pulmonary hypertension in patients with idiopathic pulmonary fibrosis. *Respiration* 2008;76:288–94.
- [340] Hayes Jr. D, Higgins RS, Black SM, Wehr AM, Lehman AM, Kirkby S, Whitson BA. Effect of pulmonary hypertension on survival in patients with idiopathic pulmonary fibrosis after lung transplantation: an analysis of the United Network of Organ Sharing registry. *J Heart Lung Transplant* 2015;34:430–7.
- [341] Mortensen A, Cherrier L, Walia R. Effect of pirfenidone on wound healing in lung transplant patients. *Multidiscip Respir Med* 2018;13:16.
- [342] Balestro E, Solidoro P, Parigi P, Boffini M, Lucianetti A, Rea F. Safety of nintedanib before lung transplant: an Italian case series. *Respirology case reports* 2018;6: e00312.
- [343] Esposito AJ, Menon AA, Ghosh AJ, Putman RK, Fredenburgh LE, El-Chemaly SY, Goldberg HJ, Baron RM, Hunninghake GM, Doyle TJ. Increased Odds of Death for Patients with Interstitial Lung Disease and COVID-19: A Case-Control Study. *Am J Respir Crit Care Med* 2020;202:1710–3.
- [344] Drake TM, Docherty AB, Harrison EM, Quint JK, Adamali H, Agnew S, Babu S, Barber CM, Barratt S, Bendstrup E, Bianchi S, Villegas DC, Chaudhuri N, Chua F, Coker R, Chang W, Crawshaw A, Crowley LE, Dosanjh D, Fiddler CA, Forrest IA, George PM, Gibbons MA, Groom K, Haney S, Hart SP, Heiden E, Henry M, Ho LP,

Hoyles RK, Hutchinson J, Hurley K, Jones M, Jones S, Kokosi M, Kreuter M, MacKay LS, Mahendran S, Margaritopoulos G, Molina-Molina M, Molyneaux PL, O'Brien A, O'Reilly K, Packham A, Parfrey H, Poletti V, Porter JC, Renzoni E, Rivera-Ortega P, Russell AM, Saini G, Spencer LG, Stella GM, Stone H, Sturney S, Thickett D, Thillai M, Wallis T, Ward K, Wells AU, West A, Wickremasinghe M, Woodhead F, Hearson G, Howard L, Baillie JK, Openshaw PJM, Semple MG, Stewart I, Jenkins RG. Outcome of Hospitalization for COVID-19 in Patients with Interstitial Lung Disease. An International Multicenter Study. *Am J Respir Crit Care Med* 2020;202:1656–65.

[345] Gallay L, Uzunhan Y, Borie R, Lazor R, Rigaud P, Marchand-Adam S, Hirschi S, Israel-Biet D, Valentin V, Cottin V. Risk Factors for Mortality after COVID-19 in Patients with Preexisting Interstitial Lung Disease. *Am J Respir Crit Care Med* 2021;203:245–9.

[346] Birring SS, Kavanagh JE, Irwin RS, Keogh KA, Lim KG, Ryu JH. Treatment of Interstitial Lung Disease Associated Cough: CHEST Guideline and Expert Panel Report. *Chest* 2018;154:904–17.

[347] Martinez FJ, Afzal AS, Smith JA, Ford AP, Li JJ, Li Y, Kitt MM. Treatment of Persistent Cough in Subjects with Idiopathic Pulmonary Fibrosis (IPF) with Gefapixant, a P2_U 3 Antagonist, in a Randomized, Placebo-Controlled Clinical Trial. *Pulmonary therapy* 2021;7:471–86.

[348] Horton MR, Danoff SK, Lechtzin N. Thalidomide inhibits the intractable cough of idiopathic pulmonary fibrosis. *Thorax* 2008;63:749.

[349] Horton MR, Santopietro V, Mathew L, Horton KM, Polito AJ, Liu MC, Danoff SK, Lechtzin N. Thalidomide for the treatment of cough in idiopathic pulmonary fibrosis: a randomized trial. *Ann Intern Med* 2012;157:398–406.

[350] Kilduff CE, Counter MJ, Thomas GA, Harrison NK, Hope-Gill BD. Effect of acid suppression therapy on gastroesophageal reflux and cough in idiopathic pulmonary fibrosis: an intervention study. *Cough* 2014;10:4.

[351] Dutta P, Funston W, Mossop H, Ryan V, Jones R, Forbes R, Sen S, Pearson J, Griffin SM, Smith JA, Ward C, Forrest IA, Simpson AJ. Randomised, double-blind, placebo-controlled pilot trial of omeprazole in idiopathic pulmonary fibrosis. *Thorax* 2019;74:346–53.

[352] Ryan NM, Birring SS, Gibson PG. Gabapentin for refractory chronic cough: a randomised, double-blind, placebo-controlled trial. *Lancet* 2012;380:1583–9.

[353] Glaspole IN, Chapman SA, Cooper WA, Ellis SJ, Goh NS, Hopkins PM, Macansh S, Mahar A, Moodley YP, Paul E, Reynolds PN, Walters EH, Zappala CJ, Corte TJ. Health-related quality of life in idiopathic pulmonary fibrosis: Data from the Australian IPF Registry. *Respirology* 2017;22:950–6.

- [354] Kreuter M, Swigris J, Pittrow D, Geier S, Klotsche J, Prasse A, Wirtz H, Koschel D, Andreas S, Claussen M, Grohe C, Wilkens H, Hagemeyer L, Skowasch D, Meyer JF, Kirschner J, Glaser S, Herth FJF, Welte T, Neurohr C, Schwaiblmair M, Held M, Bahmer T, Frankenberger M, Behr J. Health related quality of life in patients with idiopathic pulmonary fibrosis in clinical practice: insights-IPF registry. *Respir Res* 2017;18:139.
- [355] Khadawardi H, Mura M. A simple dyspnoea scale as part of the assessment to predict outcome across chronic interstitial lung disease. *Respirology* 2017;22:501–7.
- [356] Bajwah S, Ross JR, Peacock JL, Higginson IJ, Wells AU, Patel AS, Koffman J, Riley J. Interventions to improve symptoms and quality of life of patients with fibrotic interstitial lung disease: a systematic review of the literature. *Thorax* 2013;68:867–79.
- [357] Carvajalino S, Reigada C, Johnson MJ, Dzingina M, Bajwah S. Symptom prevalence of patients with fibrotic interstitial lung disease: a systematic literature review. *BMC Pulm Med* 2018;18:78.
- [358] Seppälä S, Rajala K, Lehto JT, Sutinen E, Mäkitalo L, Kautiainen H, Kankaanranta H, Ainola M, Saarto T, Myllärniemi M. Factor analysis identifies three separate symptom clusters in idiopathic pulmonary fibrosis. *ERJ Open Res* 2020;6:00347–2020.
- [359] Vainshelboim B, Oliveira J, Fox BD, Soreck Y, Fruchter O, Kramer MR. Long-term effects of a 12-week exercise training program on clinical outcomes in idiopathic pulmonary fibrosis. *Lung* 2015;193:345–54.
- [360] Vainshelboim B, Oliveira J, Yehoshua L, Weiss I, Fox BD, Fruchter O, Kramer MR. Exercise training-based pulmonary rehabilitation program is clinically beneficial for idiopathic pulmonary fibrosis. *Respiration* 2014;88:378–88.
- [361] Kenn K, Gloeckl R, Behr J. Pulmonary rehabilitation in patients with idiopathic pulmonary fibrosis—a review. *Respiration* 2013;86:89–99.
- [362] Dowman L, Hill CJ, Holland AE. Pulmonary rehabilitation for interstitial lung disease. *Cochrane Database Syst Rev* 2014;10:CD006322.
- [363] Wallaert B, Duthoit L, Drumez E, Behal H, Wemeau L, Chenivesse C, Grosbois JM. Long-term evaluation of home-based pulmonary rehabilitation in patients with fibrotic idiopathic interstitial pneumonias. *ERJ Open Res* 2019;5:00045–2019.
- [364] Tonelli R, Cocconcelli E, Lanini B, Romagnoli I, Florini F, Castaniere I, Andrisani D, Cerri S, Luppi F, Fantini R, Marchioni A, Begh_e B, Gigliotti F, Clini EM. Effectiveness of pulmonary rehabilitation in patients with interstitial lung disease of different etiology: a multicenter prospective study. *BMC Pulm Med* 2017;17:130.
- [365] Jennings AL, Davies AN, Higgins JP, Gibbs JS, Broadley KE. A systematic review of the use of opioids in the management of dyspnoea. *Thorax* 2002;57:939–44.
- [366] Kohberg C, Andersen CU, Bendstrup E. Opioids: an unexplored option for treatment of dyspnea in IPF. *Eur Clin Respir J* 2016;3:30629.

[367] Allen S, Raut S, Woollard J, Vassallo M. Low dose diamorphine reduces breathlessness without causing a fall in oxygen saturation in elderly patients with end-stage idiopathic pulmonary fibrosis. *Palliat Med* 2005;19:128–30.

[368] Bajwah S, Davies JM, Tanash H, Currow DC, Oluyase AO, Ekström M. Safety of benzodiazepines and opioids in interstitial lung disease: a national prospective study. *Eur Respir J* 2018;52.

[369] Nocturnal Oxygen Therapy Trial Group. Continuous or nocturnal oxygen therapy in hypoxemic chronic obstructive lung disease: a clinical trial. *Ann Intern Med* 1980;93:391–8.

[370] Medical Research Council Working Party. Long term domiciliary oxygen therapy in chronic hypoxic cor pulmonale complicating chronic bronchitis and emphysema. Report of the Medical Research Council Working Party. *Lancet* 1981;1:681–6.

[371] Jacobs SS, Krishnan JA, Lederer DJ, Ghazipura M, Hossain T, Tan AM, Carlin B, Drummond MB, Ekström M, Garvey C, Graney BA, Jackson B, Kallstrom T, Knight SL, Lindell K, Prieto-Centurion V, Renzoni EA, Ryerson CJ, Schneidman A, Swigris J, Upson D, Holland AE. Home Oxygen Therapy for Adults with Chronic Lung Disease. An Official American Thoracic Society Clinical Practice Guideline. *Am J Respir Crit Care Med* 2020;202:e121–41.

[372] Morrison DA, Stovall JR. Increased exercise capacity in hypoxemic patients after long-term oxygen therapy. *Chest* 1992;102:542–50.

[373] Visca D, Montgomery A, de Lauretis A, Sestini P, Soteriou H, Maher TM, Wells AU, Renzoni EA. Ambulatory oxygen in interstitial lung disease. *Eur Respir J* 2011;38:987–90.

[374] Frank RC, Hicks S, Duck AM, Spencer L, Leonard CT, Barnett E. Ambulatory oxygen in idiopathic pulmonary fibrosis: of what benefit? *Eur Respir J* 2012;40:269–70.

[375] Arizono S, Furukawa T, Taniguchi H, Sakamoto K, Kimura T, Kataoka K, Ogawa T, Watanabe F, Kondoh Y. Supplemental oxygen improves exercise capacity in IPF patients with exertional desaturation. *Respirology* 2020;25:1152–9.

[376] Nishiyama O, Miyajima H, Fukai Y, Yamazaki R, Satoh R, Yamagata T, Sano H, Iwanaga T, Higashimoto Y, Nakajima H, Kume H, Tohda Y. Effect of ambulatory oxygen on exertional dyspnea in IPF patients without resting hypoxemia. *Respir Med* 2013;107:1241–6.

[377] Visca D, Mori L, Tsipouri V, Fleming S, Firouzi A, Bonini M, Pavitt MJ, Alfieri V, Canu S, Bonifazi M, Boccabella C, De Lauretis A, Stock CJW, Saunders P, Montgomery A, Hogben C, Stockford A, Pittet M, Brown J, Chua F, George PM, Molyneaux PL, Margaritopoulos GA, Kokosi M, Kouranos V, Russell AM, Birring SS, Chetta A, Maher TM, Cullinan P, Hopkinson NS, Banya W, Whitty JA, Adamali H, Spencer LG, Farquhar M, Sestini P, Wells AU, Renzoni EA. Effect of ambulatory oxygen on quality of life for patients with fibrotic lung disease (AmbOx): a prospective, open-label, mixed-method, crossover randomised controlled trial. *Lancet Respir Med* 2018;6:759–70.

- [378] Lim RK, Humphreys C, Morisset J, Holland AE, Johannson KA. Oxygen in patients with fibrotic interstitial lung disease: an international Delphi survey. *Eur Respir J* 2019;54:1900421.
- [379] Khor YH, Harrison A, Robinson J, Goh NSL, Glaspole I, McDonald CF. Moderate resting hypoxaemia in fibrotic interstitial lung disease. *Eur Respir J* 2021;57:2001563.
- [380] Khor YH, Holland AE, Goh NSL, Miller BR, Vlahos R, Bozinovski S, Lahham A, Glaspole I, McDonald CF. Ambulatory Oxygen in Fibrotic Interstitial Lung Disease: A Pilot, Randomized, Triple-Blinded, Sham-Controlled Trial. *Chest* 2020;158:234–44.
- [381] Ramadurai D, Riordan M, Graney B, Churney T, Olson AL, Swigris JJ. The impact of carrying supplemental oxygen on exercise capacity and dyspnea in patients with interstitial lung disease. *Respir Med* 2018;138:32–7.
- [382] Holland AE, Hill CJ, Conron M, Munro P, McDonald CF. Short term improvement in exercise capacity and symptoms following exercise training in interstitial lung disease. *Thorax* 2008;63:549–54.
- [383] Nishiyama O, Kondoh Y, Kimura T, Kato K, Kataoka K, Ogawa T, Watanabe F, Arizono S, Nishimura K, Taniguchi H. Effects of pulmonary rehabilitation in patients with idiopathic pulmonary fibrosis. *Respirology* 2008;13:394–9.
- [384] Gaunard IA, Gomez-Marín OW, Ramos CF, Sol CM, Cohen MI, Cahalin LP, Cardenas DD, Jackson RM. Physical activity and quality of life improvements of patients with idiopathic pulmonary fibrosis completing a pulmonary rehabilitation program. *Respir Care* 2014;59:1872–9.
- [385] Dowman LM, McDonald CF, Hill CJ, Lee AL, Barker K, Boote C, Glaspole I, Goh NSL, Southcott AM, Burge AT, Gillies R, Martin A, Holland AE. The evidence of benefits of exercise training in interstitial lung disease: a randomised controlled trial. *Thorax* 2017;72:610–9.
- [386] Vainshelboim B. Clinical Improvement and Effectiveness of Exercise-Based Pulmonary Rehabilitation in Patients With Idiopathic Pulmonary Fibrosis: A BRIEF ANALYTICAL REVIEW. *Journal of cardiopulmonary rehabilitation and prevention* 2021;41:52–7.
- [387] Ryerson CJ, Cayou C, Topp F, Hilling L, Camp PG, Wilcox PG, Khalil N, Collard HR, Garvey C. Pulmonary rehabilitation improves long-term outcomes in interstitial lung disease: a prospective cohort study. *Respir Med* 2014;108:203–10.
- [388] Ferreira A, Garvey C, Connors GL, Hilling L, Rigler J, Farrell S, Cayou C, Shariat C, Collard HR. Pulmonary rehabilitation in interstitial lung disease: benefits and predictors of response. *Chest* 2009;135:442–7.
- [389] Holland AE, Hill CJ, Glaspole I, Goh N, McDonald CF. Predictors of benefit following pulmonary rehabilitation for interstitial lung disease. *Respir Med* 2012;106:429–35.

- [390] Kozu R, Senjyu H, Jenkins SC, Mukae H, Sakamoto N, Kohno S. Differences in response to pulmonary rehabilitation in idiopathic pulmonary fibrosis and chronic obstructive pulmonary disease. *Respiration* 2011;81:196–205.
- [391] Huppmann P, Szczepanski B, Boensch M, Winterkamp S, Schonheit-Kenn U, Neurohr C, Behr J, Kenn K. Effects of in-patient pulmonary rehabilitation in patients with interstitial lung disease. *Eur Respir J* 2012.
- [392] Rammaert B, Leroy S, Cavestri B, Wallaert B, Grosbois JM. [Home-based pulmonary rehabilitation in idiopathic pulmonary fibrosis]. *Rev Mal Respir* 2009;26:275–82.
- [393] Organisation Mondiale de la Santé. Classification internationale du fonctionnement, du handicap et de la santé. CIF; 2021. 2001 April 7]. Available from <https://apps.who.int/iris/handle/10665/42418>.
- [394] Yu X, Li X, Wang L, Liu R, Xie Y, Li S, Li J. Pulmonary Rehabilitation for Exercise Tolerance and Quality of Life in IPF Patients: A Systematic Review and Meta-Analysis. *BioMed research international* 2019;2019:8498603.
- [395] Sampson C, Gill BH, Harrison NK, Nelson A, Byrne A. The care needs of patients with idiopathic pulmonary fibrosis and their carers (CaNoPy): results of a qualitative study. *BMC Pulm Med* 2015;15:155.
- [396] Russell AM, Ripamonti E, Vancheri C. Qualitative European survey of patients with idiopathic pulmonary fibrosis: patients' perspectives of the disease and treatment. *BMC Pulm Med* 2016;16:10.
- [397] Overgaard D, Kaldan G, Marsaa K, Nielsen TL, Shaker SB, Egerod I. The lived experience with idiopathic pulmonary fibrosis: a qualitative study. *Eur Respir J* 2016;47:1472–80.
- [398] Taillé C. Où meurent les patients atteints de fibrose pulmonaire idiopathique ? *Info Respiration* 2015:26.
- [399] Ahmadi Z, Wysham NG, Lundstrom S, Janson C, Currow DC, Ekstrom M. End-of-life care in oxygen-dependent ILD compared with lung cancer: a national population-based study. *Thorax* 2016;71:510–6.
- [400] Rajala K, Lehto JT, Saarinen M, Sutinen E, Saarto T, Myllärniemi M. End-of-life care of patients with idiopathic pulmonary fibrosis. *BMC palliative care* 2016;15:85.
- [401] Bajwah S, Ross JR, Wells AU, Mohammed K, Oyebode C, Birring SS, Patel AS, Koffman J, Higginson IJ, Riley J. Palliative care for patients with advanced fibrotic lung disease: a randomised controlled phase II and feasibility trial of a community case conference intervention. *Thorax* 2015;70:830–9.

- [402] Abernethy AP, McDonald CF, Frith PA, Clark K, Herndon 2nd JE, Marcello J, Young IH, Bull J, Wilcock A, Booth S, Wheeler JL, Tulsy JA, Crockett AJ, Currow DC. Effect of palliative oxygen versus room air in relief of breathlessness in patients with refractory dyspnoea: a double-blind, randomised controlled trial. *Lancet* 2010;376:784–93.
- [403] Lindell KO, Kavalieratos D, Gibson KF, Tycon L, Rosenzweig M. The palliative care needs of patients with idiopathic pulmonary fibrosis: A qualitative study of patients and family caregivers. *Heart Lung* 2017;46:24–9.
- [404] Lindell KO, Nouraie M, Klesen MJ, Klein S, Gibson KF, Kass DJ, Rosenzweig MQ. Randomised clinical trial of an early palliative care intervention (SUPPORT) for patients with idiopathic pulmonary fibrosis (IPF) and their caregivers: protocol and key design considerations. *BMJ Open Respir Res* 2018;5:e000272.
- [405] Duchemann B, Assistance Publique - Hôpitaux de Paris. Impact des soins palliatifs systématiques sur la qualité de vie, dans la fibrose pulmonaire idiopathique avancée. 2017 19 mai 2021]. Available from: <https://ichgcp.net/fr/clinical-trialsregistry/NCT03229343>.
- [406] Collard HR, Ryerson CJ, Corte TJ, Jenkins G, Kondoh Y, Lederer DJ, Lee JS, Maher TM, Wells AU, Antoniou KM, Behr J, Brown KK, Cottin V, Flaherty KR, Fukuoka J, Hansell DM, Johkoh T, Kaminski N, Kim DS, Kolb M, Lynch DA, Myers JL, Raghu G, Richeldi L, Taniguchi H, Martinez FJ. Acute Exacerbation of Idiopathic Pulmonary Fibrosis: An International Working Group Report. *Am J Respir Crit Care Med* 2016;194:265–75.
- [407] Brown AW, Fischer CP, Shlobin OA, Buhr RG, Ahmad S, Weir NA, Nathan SD. Outcomes after hospitalization in idiopathic pulmonary fibrosis: a cohort study. *Chest* 2015;147:173–9.
- [408] Zhuang Y, Zhou Y, Qiu X, Xiao Y, Cai H, Dai J. Incidence and impact of extra-pulmonary organ failures on hospital mortality in acute exacerbation of idiopathic pulmonary fibrosis. *Sci Rep* 2020;10:10742.
- [409] Kondoh Y, Cottin V, Brown KK. Recent lessons learned in the management of acute exacerbation of idiopathic pulmonary fibrosis. *Eur Respir Rev* 2017;26:170050.
- [410] Kakugawa T, Sakamoto N, Sato S, Yura H, Harada T, Nakashima S, Hara A, Oda K, Ishimoto H, Yatera K, Ishimatsu Y, Obase Y, Kohno S, Mukae H. Risk factors for an acute exacerbation of idiopathic pulmonary fibrosis. *Respir Res* 2016;17:79.
- [411] Kawamura K, Ichikado K, Ichiyasu H, Anan K, Yasuda Y, Suga M, Sakagami T. Acute exacerbation of chronic fibrosing interstitial pneumonia in patients receiving antifibrotic agents: incidence and risk factors from real-world experience. *BMC Pulm Med* 2019;19:113.
- [412] Kishaba T, Hozumi H, Fujisawa T, Nei Y, Enomoto N, Sugiura H, Kitani M, Suda T. Predictors of acute exacerbation in biopsy-proven idiopathic pulmonary fibrosis. *Respir Investig* 2020;58:177–84.

- [413] Johannson KA, Vittinghoff E, Lee K, Balmes JR, Ji W, Kaplan GG, Kim DS, Collard HR. Acute exacerbation of idiopathic pulmonary fibrosis associated with air pollution exposure. *Eur Respir J* 2014;43:1124–31.
- [414] Sese L, Nunes H, Cottin V, Sanyal S, Didier M, Carton Z, Israel-Biet D, Crestani B, Cadranel J, Wallaert B, Tazi A, Maitre B, Prevot G, Marchand-Adam S, Guillot-Dudoret S, Nardi A, Dury S, Giraud V, Gondouin A, Juvin K, Borie R, Wislez M, Valeyre D, Annesi-Maesano I. Role of atmospheric pollution on the natural history of idiopathic pulmonary fibrosis. *Thorax* 2018;73:145–50.
- [415] Morawiec E, Tillie-Leblond I, Pansini V, Salleron J, Remy-Jardin M, Wallaert B. Exacerbations of idiopathic pulmonary fibrosis treated with corticosteroids and cyclophosphamide pulses. *Eur Respir J* 2011;38:1487–9.
- [416] Naccache JM, Montil M, Cadranel J, Cachanado M, Cottin V, Crestani B, Valeyre D, Wallaert B, Simon T, Nunes H. Study protocol: exploring the efficacy of cyclophosphamide added to corticosteroids for treating acute exacerbation of idiopathic pulmonary fibrosis; a randomized double-blind, placebo-controlled, multi-center phase III trial (EXAFIP). *BMC Pulm Med* 2019;19:75.
- [417] Raghu G. Idiopathic pulmonary fibrosis: increased survival with "gastroesophageal reflux therapy": fact or fallacy? *Am J Respir Crit Care Med* 2011;184:1330–2.
- [418] Kondoh Y, Azuma A, Inoue Y, Ogura T, Sakamoto S, Tsushima K, Johkoh T, Fujimoto K, Ichikado K, Matsuzawa Y, Saito T, Kishi K, Tomii K, Sakamoto N, Aoshima M, Araya J, Izumi S, Arita M, Abe M, Yamauchi H, Shindoh J, Suda T, Okamoto M, Ebina M, Yamada Y, Tohda Y, Kawamura T, Taguchi Y, Ishii H, Hashimoto N, Abe S, Taniguchi H, Tagawa J, Bessho K, Yamamori N, Homma S. Thrombomodulin Alfa for Acute Exacerbation of Idiopathic Pulmonary Fibrosis. A Randomized, Double-Blind Placebo-controlled Trial. *Am J Respir Crit Care Med* 2020;201:1110–9.
- [419] Kubo H, Nakayama K, Yanai M, Suzuki T, Yamaya M, Watanabe M, Sasaki H. Anticoagulant therapy for idiopathic pulmonary fibrosis. *Chest* 2005;128:1475–82.
- [420] Vianello A, Molena B, Turato C, Braccioni F, Arcaro G, Paladini L, Andretta M, Saetta M. Pirfenidone improves the survival of patients with idiopathic pulmonary fibrosis hospitalized for acute exacerbation. *Curr Med Res Opin* 2019;35:1187–90.
- [421] Furuya K, Sakamoto S, Shimizu H, Sekiya M, Kinoshita A, Isshiki T, Sugino K, Matsumoto K, Homma S. Pirfenidone for acute exacerbation of idiopathic pulmonary fibrosis: A retrospective study. *Respir Med* 2017;126:93–9.
- [422] Richeldi L. Time for Prevention of Idiopathic Pulmonary Fibrosis Exacerbation. *Ann Am Thorac Soc* 2015;12 Suppl 2:S181–5.
- [423] Kawamura K, Ichikado K, Yasuda Y, Anan K, Suga M. Azithromycin for idiopathic acute exacerbation of idiopathic pulmonary fibrosis: a retrospective single-center study. *BMC Pulm Med* 2017;17:94.

[424] Trudzinski FC, Kaestner F, Schafers HJ, Fahndrich S, Seiler F, Bohmer P, Linn O, Kaiser R, Haake H, Langer F, Bals R, Wilkens H, Lepper PM. Outcome of Patients with Interstitial Lung Disease Treated with Extracorporeal Membrane Oxygenation for Acute Respiratory Failure. *Am J Respir Crit Care Med* 2015;93:527–33.

[425] Kreuter M, Polke M, Walsh SLF, Krisam J, Collard HR, Chaudhuri N, Avdeev S, Behr J, Calligaro G, Corte T, Flaherty K, Funke-Chambour M, Kolb M, Kondoh Y, Maher TM, Molina Molina M, Morais A, Moor CC, Morisset J, Pereira C, Quadrelli S, Selman M, Tzouveleki A, Valenzuela C, Vancheri C, Vicens-Zygmunt V, Wealscher J, Wuyts W, Wijsenbeek M, Cottin V, Bendstrup E. Acute exacerbation of idiopathic pulmonary fibrosis: international survey and call for harmonisation. *Eur Respir J* 2020;55:1901760.

[426] Marcelli C. *Ost_eoporose cortisonique*. EMC Appareil locomoteur 2011.

[427] Blivet S, Philit F, Sab JM, Langevin B, Paret M, Guerin C, Robert D. Outcome of patients with idiopathic pulmonary fibrosis admitted to the ICU for respiratory failure. *Chest* 2001;120:209–12.

[428] Kim DS, Park JH, Park BK, Lee JS, Nicholson AG, Colby T. Acute exacerbation of idiopathic pulmonary fibrosis: frequency and clinical features. *Eur Respir J* 2006;27:143–50.

[429] Molina-Molina M, Badia JR, Marin-Arguedas A, Xaubet A, Santos MJ, Nicolas JM, Ferrer M, Torres A. [Outcomes and clinical characteristics of patients with pulmonary fibrosis and respiratory failure admitted to an intensive care unit. A study of 20 cases]. *Med Clin (Barc)* 2003;121:63–7.

[430] Saydain G, Islam A, Afessa B, Ryu JH, Scott JP, Peters SG. Outcome of patients with idiopathic pulmonary fibrosis admitted to the intensive care unit. *Am J Respir Crit Care Med* 2002;166:839–42.

[431] Nava S, Rubini F. Lung and chest wall mechanics in ventilated patients with end stage idiopathic pulmonary fibrosis. *Thorax* 1999;54:390–5.

[432] Stern JB, Mal H, Groussard O, Brugiere O, Marceau A, Jebrak G, Fournier M. Prognosis of patients with advanced idiopathic pulmonary fibrosis requiring mechanical ventilation for acute respiratory failure. *Chest* 2001;120:213–9.

[433] Al-Hameed FM, Sharma S. Outcome of patients admitted to the intensive care unit for acute exacerbation of idiopathic pulmonary fibrosis. *Can Respir J* 2004;11:117–22.

[434] Fumeaux T, Rothmeier C, Jolliet P. Outcome of mechanical ventilation for acute respiratory failure in patients with pulmonary fibrosis. *Intensive Care Med* 2001;27:1868–74.

[435] Mollica C, Paone G, Conti V, Ceccarelli D, Schmid G, Mattia P, Perrone N, Petroianni A, Sebastiani A, Cecchini L, Orsetti R, Terzano C. Mechanical ventilation in patients with end-stage idiopathic pulmonary fibrosis. *Respiration* 2010;79:209–15.

- [436] Rangappa P, Moran JL. Outcomes of patients admitted to the intensive care unit with idiopathic pulmonary fibrosis. *Crit Care Resusc* 2009;11:102–9.
- [437] Mallick S. Outcome of patients with idiopathic pulmonary fibrosis (IPF) ventilated in intensive care unit. *Respir Med* 2008;102:1355–9.
- [438] Rush B, Wiskar K, Berger L, Griesdale D. The use of mechanical ventilation in patients with idiopathic pulmonary fibrosis in the United States: A nationwide retrospective cohort analysis. *Respir Med* 2016;111:72–6.
- [439] Gaudry S, Vincent F, Rabbat A, Nunes H, Crestani B, Naccache JM, Wolff M, Thabut G, Valeyre D, Cohen Y, Mal H. Invasive mechanical ventilation in patients with fibrosing interstitial pneumonia. *J Thorac Cardiovasc Surg* 2014;147:47–53.
- [440] Yokoyama T, Kondoh Y, Taniguchi H, Kataoka K, Kato K, Nishiyama O, Kimura T, Hasegawa R, Kubo K. Noninvasive ventilation in acute exacerbation of idiopathic pulmonary fibrosis. *Intern Med* 2010;49:1509–14.
- [441] Mullier A, Cottin V, Richard J-C, Guérin C. Fibrose pulmonaire: dans quels cas et sur quels critères envisager une admission en réanimation? *R »animation* 2013:45–53.
- [442] Simonneau G, Montani D, Celermajer DS, Denton CP, Gatzoulis MA, Krowka M, Williams PG, Souza R. Haemodynamic definitions and updated clinical classification of pulmonary hypertension. *Eur Respir J* 2019;53:1801913.
- [443] Nathan SD, Cottin V. Pulmonary hypertension in patients with idiopathic pulmonary fibrosis. *Eur Respir Mon* 2012;57:148–60.
- [444] Shorr AF, Wainright JL, Cors CS, Lettieri CJ, Nathan SD. Pulmonary hypertension in patients with pulmonary fibrosis awaiting lung transplant. *Eur Respir J* 2007;30:715–21.
- [445] Lettieri CJ, Nathan SD, Barnett SD, Ahmad S, Shorr AF. Prevalence and outcomes of pulmonary arterial hypertension in advanced idiopathic pulmonary fibrosis. *Chest* 2006;129:746–52.
- [446] Judge EP, Fabre A, Adamali HI, Egan JJ. Acute exacerbations and pulmonary hypertension in advanced idiopathic pulmonary fibrosis. *Eur Respir J* 2012;40:93–100.
- [447] Nathan SD, Shlobin OA, Barnett SD, Sagar R, Belperio JA, Ross DJ, Ahmad S, Sagar R, Libre E, Lynch 3rd JP, Zisman DA. Right ventricular systolic pressure by echocardiography as a predictor of pulmonary hypertension in idiopathic pulmonary fibrosis. *Respir Med* 2008;102:1305–10.
- [448] Swanson KL, Utz JP, Krowka MJ. Doppler echocardiography-right heart catheterization relationships in patients with idiopathic pulmonary fibrosis and suspected pulmonary hypertension. *Med Sci Monit* 2008;14:CR177–82.

- [449] Arcasoy SM, Christie JD, Ferrari VA, Sutton MS, Zisman DA, Blumenthal NP, Pochettino A, Kotloff RM. Echocardiographic assessment of pulmonary hypertension in patients with advanced lung disease. *Am J Respir Crit Care Med* 2003;167:735–40.
- [450] Devaraj A, Wells AU, Meister MG, Corte TJ, Hansell DM. The effect of diffuse pulmonary fibrosis on the reliability of CT signs of pulmonary hypertension. *Radiology* 2008;249:1042–9.
- [451] Leuchte HH, Baumgartner RA, Nounou ME, Vogeser M, Neurohr C, Trautnitz M, Behr J. Brain natriuretic peptide is a prognostic parameter in chronic lung disease. *Am J Respir Crit Care Med* 2006;173:744–50.
- [452] Zisman DA, Karlamangla AS, Kawut SM, Shlobin OA, Sagar R, Ross DJ, Schwarz MI, Belperio JA, Ardehali A, Lynch 3rd JP, Nathan SD. Validation of a method to screen for pulmonary hypertension in advanced idiopathic pulmonary fibrosis. *Chest* 2008;133:640–5.
- [453] Galie N, Humbert M, Vachiery JL, Gibbs S, Lang I, Torbicki A, Simonneau G, Peacock A, Vonk Noordegraaf A, Beghetti M, Ghofrani A, Gomez Sanchez MA, Hansmann G, Klepetko W, Lancellotti P, Matucci M, McDonagh T, Pierard LA, Trindade PT, Zompatori M, Hoeper M. 2015 ESC/ERS Guidelines for the diagnosis and treatment of pulmonary hypertension: The Joint Task Force for the Diagnosis and Treatment of Pulmonary Hypertension of the European Society of Cardiology (ESC) and the European Respiratory Society (ERS): Endorsed by: Association for European Paediatric and Congenital Cardiology (AEPC), International Society for Heart and Lung Transplantation (ISHLT). *Eur Respir J* 2015;46:903–75.
- [454] Nathan SD, Barbera JA, Gaine SP, Harari S, Martinez FJ, Olschewski H, Olsson KM, Peacock AJ, Pepke-Zaba J, Provencher S, Weissmann N, Seeger W. Pulmonary hypertension in chronic lung disease and hypoxia. *Eur Respir J* 2019;53:1801914.
- [455] Corte TJ, Keir GJ, Dimopoulos K, Howard L, Corris PA, Parfitt L, Foley C, Yanez-Lopez M, Babalis D, Marino P, Maher TM, Renzoni EA, Spencer L, Elliot CA, Birring SS, O'Reilly K, Gatzoulis MA, Wells AU, Wort SJ. Bosentan in pulmonary hypertension associated with fibrotic idiopathic interstitial pneumonia. *Am J Respir Crit Care Med* 2014;190:208–17.
- [456] Raghu G, Million-Rousseau R, Morganti A, Perchenet L, Behr J. Macitentan for the treatment of idiopathic pulmonary fibrosis: the randomised controlled MUSIC trial. *Eur Respir J* 2013;42:1622–32.
- [457] Nathan SD, Behr J, Cottin V, Collard HR, Hoeper MM, Martinez FJ, Wells AU. Idiopathic interstitial pneumonia-associated pulmonary hypertension: A target for therapy? *Respir Med* 2017;122 Suppl 1:S10–3.

[458] Nathan SD, Behr J, Collard HR, Cottin V, Hoeper MM, Martinez FJ, Corte TJ, Keogh AM, Leuchte H, Mogulkoc N, Ulrich S, Wuyts WA, Yao Z, Boateng F, Wells AU. Riociguat for idiopathic interstitial pneumonia-associated pulmonary hypertension (RISE-IIP): a randomised, placebo-controlled phase 2b study. *Lancet Respir Med* 2019;7:780–90.

[459] Ghofrani HA, Wiedemann R, Rose F, Schermuly RT, Olschewski H, Weissmann N, Gunther A, Walmrath D, Seeger W, Grimminger F. Sildenafil for treatment of lung fibrosis and pulmonary hypertension: a randomised controlled trial. *Lancet* 2002;360:895–900.

[460] Madden BP, Allenby M, Loke TK, Sheth A. A potential role for sildenafil in the management of pulmonary hypertension in patients with parenchymal lung disease. *Vascul Pharmacol* 2006;44:372–6.

[461] Collard HR, Anstrom KJ, Schwarz MI, Zisman DA. Sildenafil improves walk distance in idiopathic pulmonary fibrosis. *Chest* 2007;131:897–9.

[462] Zisman DA, Schwarz M, Anstrom KJ, Collard HR, Flaherty KR, Hunninghake GW. A controlled trial of sildenafil in advanced idiopathic pulmonary fibrosis. *N Engl J Med* 2010;363:620–8.

[463] Han MK, Bach DS, Hagan PG, Yow E, Flaherty KR, Toews GB, Anstrom KJ, Martinez FJ. Sildenafil preserves exercise capacity in patients with idiopathic pulmonary fibrosis and right-sided ventricular dysfunction. *Chest* 2013;143:1699–708.

[464] Hoeper MM, Behr J, Held M, Grunig E, Vizza CD, Vonk-Noordegraaf A, Lange TJ, Claussen M, Grohe C, Klose H, Olsson KM, Zelniker T, Neurohr C, Distler O, Wirtz H, Opitz C, Huscher D, Pittrow D, Gibbs JS. Pulmonary Hypertension in Patients with Chronic Fibrosing Idiopathic Interstitial Pneumonias. *PLoS One* 2015;10:e0141911.

[465] Behr J, Nathan SD, Wuyts WA, Mogulkoc Bishop N, Bouros DE, Antoniou K, Guiot J, Kramer MR, Kirchgaessler KU, Bengus M, Gilberg F, Perjesi A, Harari S, Wells AU. Efficacy and safety of sildenafil added to pirfenidone in patients with advanced idiopathic pulmonary fibrosis and risk of pulmonary hypertension: a double-blind, randomised, placebo-controlled, phase 2b trial. *Lancet Respir Med* 2021;9:85–95.

[466] Nathan SD, Flaherty KR, Glassberg MK, Raghu G, Swigris J, Alvarez R, Ettinger N, Loyd J, Fernandes P, Gillies H, Kim B, Shah P, Lancaster L. A Randomized, Double-Blind, Placebo-Controlled Study of Pulsed, Inhaled Nitric Oxide in Subjects at Risk of Pulmonary Hypertension Associated With Pulmonary Fibrosis. *Chest* 2020;158:637–45.

[467] Waxman A, Restrepo-Jaramillo R, Thenappan T, Ravichandran A, Engel P, Bajwa A, Allen R, Feldman J, Argula R, Smith P, Rollins K, Deng C, Peterson L, Bell H, Tapson V, Nathan SD. Inhaled Treprostinil in Pulmonary Hypertension Due to Interstitial Lung Disease. *N Engl J Med* 2021;384:325–34.

[468] Savarino E, Carbone R, Marabotto E, Furnari M, Sconfienza L, Ghio M, Zentilin P, Savarino V. Gastro-oesophageal reflux and gastric aspiration in idiopathic pulmonary fibrosis patients. *Eur Respir J* 2013;42:1322–31.

- [469] Noth I, Zangan SM, Soares RV, Forsythe A, Demchuk C, Takahashi SM, Patel SB, Streck ME, Krishnan JA, Patti MG, Macmahon H. Prevalence of hiatal hernia by blinded multidetector CT in patients with idiopathic pulmonary fibrosis. *Eur Respir J* 2012;39:344–51.
- [470] Tossier C, Dupin C, Plantier L, Leger J, Flament T, Favelle O, Lecomte T, Diot P, Marchand-Adam S. Hiatal hernia on thoracic computed tomography in pulmonary fibrosis. *Eur Respir J* 2016;48:833–42.
- [471] Mackintosh JA, Desai SR, Adamali H, Patel K, Chua F, Devaraj A, Kouranos V, Kokosi M, Margaritopoulos G, Renzoni EA, Wells AU, Molyneaux PL, Kumar S, Maher TM, George PM. In patients with idiopathic pulmonary fibrosis the presence of hiatus hernia is associated with disease progression and mortality. *Eur Respir J* 2019;53:1802412.
- [472] Corrao S, Natoli G, Argano C, Scichilone N. Gastroesophageal Reflux Disease and Idiopathic Pulmonary Fibrosis: No Data for Supporting a Relationship After a Systematic Review. *Chest* 2019;156:190–2.
- [473] Tobin RW, Pope CE, Pellegrini CA, Emond MJ, Sillery J, Raghu G. Increased prevalence of gastroesophageal reflux in patients with idiopathic pulmonary fibrosis. *Am J Respir Crit Care Med* 1998;158:1804–8.
- [474] Sweet MP, Patti MG, Leard LE, Golden JA, Hays SR, Hoopes C, Theodore PR. Gastroesophageal reflux in patients with idiopathic pulmonary fibrosis referred for lung transplantation. *J Thorac Cardiovasc Surg* 2007;133:1078–84.
- [475] Bedard Methot D, Leblanc E, Lacasse Y. Meta-analysis of Gastroesophageal Reflux Disease and Idiopathic Pulmonary Fibrosis. *Chest* 2019;155:33–43.
- [476] Lacasse Y, Leblanc E, Bedard Methot D. Response. *Chest* 2019;156:192–3.
- [477] Lee JS, Collard HR, Raghu G, Sweet MP, Hays SR, Campos GM, Golden JA, King Jr. TE. Does chronic microaspiration cause idiopathic pulmonary fibrosis? *Am J Med* 2010;123:304–11.
- [478] Linden PA, Gilbert RJ, Yeap BY, Boyle K, Deykin A, Jaklitsch MT, Sugarbaker DJ, Bueno R. Laparoscopic fundoplication in patients with end-stage lung disease awaiting transplantation. *J Thorac Cardiovasc Surg* 2006;131:438–46.
- [479] Raghu G, Pellegrini CA, Yow E, Flaherty KR, Meyer K, Noth I, Scholand MB, Cello J, Ho LA, Pipavath S, Lee JS, Lin J, Maloney J, Martinez FJ, Morrow E, Patti MG, Rogers S, Wolters PJ, Yates R, Anstrom KJ, Collard HR. Laparoscopic anti-reflux surgery for the treatment of idiopathic pulmonary fibrosis (WRAP-IPF): a multicentre, randomised, controlled phase 2 trial. *Lancet Respir Med* 2018;6:707–14.
- [480] Lee JS, Ryu JH, Elicker BM, Lydell CP, Jones KD, Wolters PJ, King Jr. TE, Collard HR. Gastroesophageal reflux therapy is associated with longer survival in patients with idiopathic pulmonary fibrosis. *Am J Respir Crit Care Med* 2011;184:1390–4.

- [481] Kreuter M, Spagnolo P, Wuyts W, Renzoni E, Koschel D, Bonella F, Maher TM, Kolb M, Weycker D, Kirchgassler KU, Costabel U. Antacid Therapy and Disease Progression in Patients with Idiopathic Pulmonary Fibrosis Who Received Pirfenidone. *Respiration* 2017;93:415–23.
- [482] Costabel U, Behr J, Crestani B, Stansen W, Schlenker-Herceg R, Stowasser S, Raghu G. Anti-acid therapy in idiopathic pulmonary fibrosis: insights from the INPULSIS(R) trials. *Respir Res* 2018;19:167.
- [483] Tran T, Suissa S. The effect of anti-acid therapy on survival in idiopathic pulmonary fibrosis: a methodological review of observational studies. *Eur Respir J* 2018;51:1800376.
- [484] Tran T, Assayag D, Ernst P, Suissa S. Effectiveness of Proton Pump Inhibitors in Idiopathic Pulmonary Fibrosis: A Population-Based Cohort Study. *Chest* 2021;159:673–82.
- [485] Lee JS, Collard HR, Anstrom KJ, Martinez FJ, Noth I, Roberts RS, Yow E, Raghu G. Anti-acid treatment and disease progression in idiopathic pulmonary fibrosis: an analysis of data from three randomised controlled trials. *Lancet Respir Med* 2013;1:369–76.
- [486] Kreuter M, Wuyts W, Renzoni E, Koschel D, Maher TM, Kolb M, Weycker D, Spagnolo P, Kirchgassler KU, Herth FJ, Costabel U. Antacid therapy and disease outcomes in idiopathic pulmonary fibrosis: a pooled analysis. *Lancet Respir Med* 2016;4:381–9.
- [487] DeVault KR, Castell DO. Updated guidelines for the diagnosis and treatment of gastroesophageal reflux disease. *Am J Gastroenterol* 2005;100:190–200.
- [488] Arai T, Inoue Y, Sasaki Y, Tachibana K, Nakao K, Sugimoto C, Okuma T, Akira M, Kitaichi M, Hayashi S. Predictors of the clinical effects of pirfenidone on idiopathic pulmonary fibrosis. *Respir Investig* 2014;52:136–43.
- [489] Cottin V, Hansell DM, Sverzellati N, Weycker D, Antoniou KM, Atwood M, Oster G, Kirchgassler KU, Collard HR, Wells AU. Effect of Emphysema Extent on Serial Lung Function in Patients with Idiopathic Pulmonary Fibrosis. *Am J Respir Crit Care Med* 2017;196:1162–71.
- [490] Akira M, Inoue Y, Kitaichi M, Yamamoto S, Arai T, Toyokawa K. Usual interstitial pneumonia and nonspecific interstitial pneumonia with and without concurrent emphysema: thin-section CT findings. *Radiology* 2009;251:271–9.
- [491] Inomata M, Ikushima S, Awano N, Kondoh K, Satake K, Masuo M, Kusunoki Y, Moriya A, Kamiya H, Ando T, Yanagawa N, Kumasaka T, Ogura T, Sakai F, Azuma A, Gemma A, Takemura T. An autopsy study of combined pulmonary fibrosis and emphysema: correlations among clinical, radiological, and pathological features. *BMC Pulm Med* 2014;14:104.
- [492] Watanabe Y, Kawabata Y, Kanauchi T, Hoshi E, Kurashima K, Koyama S, Colby TV. Multiple, thin-walled cysts are one of the HRCT features of airspace enlargement with fibrosis. *Eur J Radiol* 2015;84:986–92.

- [493] Katzenstein AL. Smoking-related interstitial fibrosis (SRIF): pathologic findings and distinction from other chronic fibrosing lung diseases. *J Clin Pathol* 2013;66:882–7.
- [494] Mejia M, Carrillo G, Rojas-Serrano J, Estrada A, Suarez T, Alonso D, Barrientos E, Gaxiola M, Navarro C, Selman M. Idiopathic pulmonary fibrosis and emphysema: decreased survival associated with severe pulmonary arterial hypertension. *Chest* 2009;136:10–5.
- [495] Cottin V, Nunes H, Brillet PY, Delaval P, Devouassoux G, Tillie-Leblond I, Israel-Biet D, Court-Fortune I, Valeyre D, Cordier JF. Combined pulmonary fibrosis and emphysema: a distinct underrecognised entity. *Eur Respir J* 2005;26:586–93.
- [496] Jacob J, Bartholmai BJ, Rajagopalan S, Karwoski R, Nair A, Walsh SLF, Barnett J, Cross G, Judge EP, Kokosi M, Renzoni E, Maher TM, Wells AU. Likelihood of pulmonary hypertension in patients with idiopathic pulmonary fibrosis and emphysema. *Respirology* 2018;23:593–9.
- [497] Jacob J, Bartholmai BJ, Rajagopalan S, Kokosi M, Maher TM, Nair A, Karwoski R, Renzoni E, Walsh SLF, Hansell DM, Wells AU. Functional and prognostic effects when emphysema complicates idiopathic pulmonary fibrosis. *Eur Respir J* 2017;50:1700379.
- [498] Cottin V, Le Pavec J, Prevot G, Mal H, Humbert M, Simonneau G, Cordier JF. Pulmonary hypertension in patients with combined pulmonary fibrosis and emphysema syndrome. *Eur Respir J* 2010;35:105–11.
- [499] Akagi T, Matsumoto T, Harada T, Tanaka M, Kuraki T, Fujita M, Watanabe K. Coexistent emphysema delays the decrease of vital capacity in idiopathic pulmonary fibrosis. *Respiratory Medicine* 2009;103:1209–15.
- [500] Schmidt SL, Nambiar AM, Tayob N, Sundaram B, Han MK, Gross BH, Kazerooni EA, Chughtai AR, Lagstein A, Myers JL, Murray S, Toews GB, Martinez FJ, Flaherty KR. Pulmonary function measures predict mortality differently in IPF versus combined pulmonary fibrosis and emphysema. *Eur Respir J* 2011;38:176–83.
- [501] Cottin V, Azuma A, Raghu G, Stansen W, Stowasser S, Schlenker-Herceg R, Kolb M. Therapeutic effects of nintedanib are not influenced by emphysema in the INPULSIS trials. *Eur Respir J* 2019;53.
- [502] Clark M, Cooper B, Singh S, Cooper M, Carr A, Hubbard R. A survey of nocturnal hypoxaemia and health related quality of life in patients with cryptogenic fibrosing alveolitis. *Thorax* 2001;56:482–6.
- [503] Aydogdu M, Ciftci B, Firat Guven S, Ulukavak Ciftci T, Erdogan Y. [Assessment of sleep with polysomnography in patients with interstitial lung disease]. *Tuberk Toraks* 2006;54:213–21.
- [504] Mermigkis C, Chapman J, Golish J, Mermigkis D, Budur K, Kopanakis A, Polychronopoulos V, Burgess R, Foldvary-Schaefer N. Sleep-related breathing disorders in patients with idiopathic pulmonary fibrosis. *Lung* 2007;185:173–8.

- [505] Bosi M, Milioli G, Parrino L, Fanfulla F, Tomassetti S, Melpignano A, Trippi I, Vaudano AE, Ravaglia C, Mascetti S, Poletti V. Quality of life in idiopathic pulmonary fibrosis: The impact of sleep disordered breathing. *Respir Med* 2019;147:51–7.
- [506] Gille T, Didier M, Boubaya M, Moya L, Sutton A, Carton Z, Baran-Marszak F, Sadoun-Danino D, Israël-Biet D, Cottin V, Gagnadoux F, Crestani B, d'Ortho MP, Brillet PY, Valeyre D, Nunes H, Planes C. Obstructive sleep apnoea and related comorbidities in incident idiopathic pulmonary fibrosis. *Eur Respir J* 2017;49:1601934.
- [507] Lancaster LH, Mason WR, Parnell JA, Rice TW, Loyd JE, Milstone AP, Collard HR, Malow BA. Obstructive sleep apnea is common in idiopathic pulmonary fibrosis. *Chest* 2009;136:772–8.
- [508] Bosi M, Milioli G, Fanfulla F, Tomassetti S, Ryu JH, Parrino L, Riccardi S, Melpignano A, Vaudano AE, Ravaglia C, Tantalocco P, Rossi A, Poletti V. OSA and Prolonged Oxygen Desaturation During Sleep are Strong Predictors of Poor Outcome in IPF. *Lung* 2017;195:643–51.
- [509] Troy LK, Young IH, Lau EMT, Wong KKH, Yee BJ, Torzillo PJ, Corte TJ. Nocturnal hypoxaemia is associated with adverse outcomes in interstitial lung disease. *Respirology* 2019;24:996–1004.
- [510] Adegunsoye A, Neborak JM, Zhu D, Cantrill B, Garcia N, Oldham JM, Noth I, Vij R, Kuzniar TJ, Bellam SK, Streck ME, Mokhlesi B. CPAP Adherence, Mortality, and Progression-Free Survival in Interstitial Lung Disease and OSA. *Chest* 2020;158:1701–12.
- [511] Société de Pneumologie de Langue Française. Société Française d'Anesthésie Réanimation. Société Française de Cardiologie SFdMdT. Société Française d'ORL. Société de Physiologie. Société Française de Recherche et de Médecine du Sommeil. Recommandations pour la Pratique Clinique. Syndrome d'apnées hypopnées obstructives du sommeil de l'adulte. *Rev Mal Respir* 2010;27:806–33.
- [512] Mermigkis C, Bouloukaki I, Antoniou K, Papadogiannis G, Giannarakis I, Varouchakis G, Siafakas N, Schiza SE. Obstructive sleep apnea should be treated in patients with idiopathic pulmonary fibrosis. *Sleep Breath* 2015;19:385–91.
- [513] Hubbard R, Venn A, Lewis S, Britton J. Lung cancer and cryptogenic fibrosing alveolitis. A population-based cohort study. *American Journal of Respiratory & Critical Care Medicine* 2000;161:5–8.
- [514] Song MJ, Kim SY, Park MS, Kang MJ, Lee SH, Park SC. A nationwide populationbased study of incidence and mortality of lung cancer in idiopathic pulmonary fibrosis. *Sci Rep* 2021;11:2596.
- [515] Whittaker Brown SA, Padilla M, Mhango G, Taioli E, Powell C, Wisnivesky J. Outcomes of Older Patients with Pulmonary Fibrosis and Non-Small Cell Lung Cancer. *Ann Am Thorac Soc* 2019;16:1034–40.

- [516] Guyard A, Danel C, Theou-Anton N, Debray MP, Gibault L, Mordant P, Castier Y, Crestani B, Zalcman G, Blons H, Cazes A. Morphologic and molecular study of lung cancers associated with idiopathic pulmonary fibrosis and other pulmonary fibroses. *Respir Res* 2017;18:120.
- [517] Girard N, Marchand-Adam S, Naccache JM, Borie R, Urban T, Jouneau S, Marchand E, Ravel AC, Kiakouama L, Etienne-Mastroianni B, Cadranet J, Cottin V, Cordier JF. Lung cancer in combined pulmonary fibrosis and emphysema: a series of 47 Western patients. *J Thorac Oncol* 2014;9:1162–70.
- [518] Ogura T, Takigawa N, Tomii K, Kishi K, Inoue Y, Ichihara E, Homma S, Takahashi K, Akamatsu H, Ikeda S, Inase N, Iwasawa T, Ohe Y, Ohta H, Onishi H, Okamoto I, Ogawa K, Kasahara K, Karata H, Kishimoto T, Kitamura Y, Gemma A, Kenmotsu H, Sakashita H, Sakamoto S, Sekine K, Takiguchi Y, Tada Y, Toyooka S, Nakayama Y, Nishioka Y, Hagiwara K, Hanibuchi M, Fukuoka J, Minegishi Y, Yanagihara T, Yamamoto N, Yamamoto H, Gaga M, Fong KM, Powell CA, Kiura K. Summary of the Japanese Respiratory Society statement for the treatment of lung cancer with comorbid interstitial pneumonia. *Respir Investig* 2019;57:512–33.
- [519] Fell CD. Idiopathic pulmonary fibrosis: phenotypes and comorbidities. *Clin Chest Med* 2012;33:51–7.
- [520] Iwata T, Yoshida S, Fujiwara T, Wada H, Nakajima T, Suzuki H, Yoshino I. Effect of Perioperative Pirfenidone Treatment in Lung Cancer Patients With Idiopathic Pulmonary Fibrosis. *Ann Thorac Surg* 2016;102:1905–10.
- [521] Iwata T, Yoshino I, Yoshida S, Ikeda N, Tsuboi M, Asato Y, Katakami N, Sakamoto K, Yamashita Y, Okami J, Mitsudomi T, Yamashita M, Yokouchi H, Okubo K, Okada M, Takenoyama M, Chida M, Tomii K, Matsuura M, Azuma A, Iwasawa T, Kuwano K, Sakai S, Hiroshima K, Fukuoka J, Yoshimura K, Tada H, Nakagawa K, Nakanishi Y. A phase II trial evaluating the efficacy and safety of perioperative pirfenidone for prevention of acute exacerbation of idiopathic pulmonary fibrosis in lung cancer patients undergoing pulmonary resection: West Japan Oncology Group 6711 L (PEOPLE Study). *Respir Res* 2016;17:90.
- [522] Sekihara K, Aokage K, Miyoshi T, Tane K, Ishii G, Tsuboi M. Perioperative pirfenidone treatment as prophylaxis against acute exacerbation of idiopathic pulmonary fibrosis: a single-center analysis. *Surg Today* 2020;50:905–11.
- [523] Kanayama M, Mori M, Matsumiya H, Taira A, Shinohara S, Kuwata T, Imanishi N, Yoneda K, Kuroda K, Tanaka F. Perioperative pirfenidone treatment for lung cancer patients with idiopathic pulmonary fibrosis. *Surg Today* 2020;50:469–74.
- [524] Yamamoto Y, Yano Y, Kuge T, Okabe F, Ishijima M, Uenami T, Kanazu M, Akazawa Y, Yamaguchi T, Mori M. Safety and effectiveness of pirfenidone combined with carboplatin-based chemotherapy in patients with idiopathic pulmonary fibrosis and non-small cell lung cancer: A retrospective cohort study. *Thoracic cancer* 2020;11:3317–25.

- [525] Sato T, Teramukai S, Kondo H, Watanabe A, Ebina M, Kishi K, Fujii Y, Mitsudomi T, Yoshimura M, Maniwa T, Suzuki K, Kataoka K, Sugiyama Y, Kondo T, Date H. Impact and predictors of acute exacerbation of interstitial lung diseases after pulmonary resection for lung cancer. *J Thorac Cardiovasc Surg* 2014;147:1604–11 e1603.
- [526] Yamaguchi S, Ohguri T, Ide S, Aoki T, Imada H, Yahara K, Narisada H, Korogi Y. Stereotactic body radiotherapy for lung tumors in patients with subclinical interstitial lung disease: the potential risk of extensive radiation pneumonitis. *Lung Cancer* 2013;82:260–5.
- [527] Goodman CD, Nijman SFM, Senan S, Nossent EJ, Ryerson CJ, Dhaliwal I, Qu XM, Laba J, Rodrigues GB, Palma DA. A Primer on Interstitial Lung Disease and Thoracic Radiation. *J Thorac Oncol* 2020;15:902–13.
- [528] Minegishi Y, Sudoh J, Kuribayashi H, Mizutani H, Seike M, Azuma A, Yoshimura A, Kudoh S, Gemma A. The safety and efficacy of weekly paclitaxel in combination with carboplatin for advanced non-small cell lung cancer with idiopathic interstitial pneumonias. *Lung Cancer* 2011;71:70–4.
- [529] Asahina H, Oizumi S, Takamura K, Harada T, Harada M, Yokouchi H, Kanazawa K, Fujita Y, Kojima T, Sugaya F, Tanaka H, Honda R, Kikuchi E, Ikari T, Ogi T, Shimizu K, Suzuki M, Konno S, Dosaka-Akita H, Isobe H, Nishimura M. A prospective phase II study of carboplatin and nab-paclitaxel in patients with advanced nonsmall cell lung cancer and concomitant interstitial lung disease (HOT1302). *Lung Cancer* 2019;138:65–71.
- [530] Kenmotsu H, Yoh K, Mori K, Ono A, Baba T, Fujiwara Y, Yamaguchi O, Ko R, Okamoto H, Yamamoto N, Ninomiya T, Ogura T, Kato T. Phase II study of nab-paclitaxel + carboplatin for patients with non-small-cell lung cancer and interstitial lung disease. *Cancer science* 2019;110:3738–45.
- [531] Shimizu R, Fujimoto D, Kato R, Otoshi T, Kawamura T, Tamai K, Matsumoto T, Nagata K, Otsuka K, Nakagawa A, Katakami N, Tomii K. The safety and efficacy of paclitaxel and carboplatin with or without bevacizumab for treating patients with advanced nonsquamous non-small cell lung cancer with interstitial lung disease. *Cancer Chemother Pharmacol* 2014;74:1159–66.
- [532] Fujimoto D, Morimoto T, Ito J, Sato Y, Ito M, Teraoka S, Otsuka K, Nagata K, Nakagawa A, Tomii K. A pilot trial of nivolumab treatment for advanced non-small cell lung cancer patients with mild idiopathic interstitial pneumonia. *Lung Cancer* 2017;111:1–5.
- [533] Fujimoto D, Yomota M, Sekine A, Morita M, Morimoto T, Hosomi Y, Ogura T, Tomioka H, Tomii K. Nivolumab for advanced non-small cell lung cancer patients with mild idiopathic interstitial pneumonia: A multicenter, open-label single-arm phase II trial. *Lung Cancer* 2019;134:274–8.
- [534] Ikeda S, Kato T, Kenmotsu H, Ogura T, Iwasawa S, Iwasawa T, Kasajima R, Miyagi Y, Misumi T, Yamanaka T, Okamoto H. A phase II study of atezolizumab for pretreated advanced/recurrent non-small cell lung cancer with idiopathic interstitial pneumonias: rationale and design for the TORG1936/AMBITIOUS study. *Ther Adv Med Oncol* 2020;12:1758835920922022.

- [535] Minegishi Y, Kuribayashi H, Kitamura K, Mizutani H, Kosaihiira S, Okano T, Seike M, Azuma A, Yoshimura A, Kudoh S, Gemma A. The feasibility study of Carboplatin plus Etoposide for advanced small cell lung cancer with idiopathic interstitial pneumonias. *J Thorac Oncol* 2011;6:801–7.
- [536] Yoshida T, Yoh K, Goto K, Niho S, Umemura S, Ohmatsu H, Ohe Y. Safety and efficacy of platinum agents plus etoposide for patients with small cell lung cancer with interstitial lung disease. *Anticancer Res* 2013;33:1175–9.
- [537] Watanabe N, Taniguchi H, Kondoh Y, Kimura T, Kataoka K, Nishiyama O, Kondo M, Hasegawa Y. Chemotherapy for extensive-stage small-cell lung cancer with idiopathic pulmonary fibrosis. *Int J Clin Oncol* 2014;19:260–5.
- [538] Miyazaki K, Satoh H, Kurishima K, Nakamura R, Ishikawa H, Kagohashi K, Hizawa N. Interstitial lung disease in patients with small cell lung cancer. *Med Oncol* 2010;27:763–7.
- [539] Togashi Y, Masago K, Handa T, Tanizawa K, Okuda C, Sakamori Y, Nagai H, Kim YH, Mishima M. Prognostic significance of preexisting interstitial lung disease in Japanese patients with small-cell lung cancer. *Clin Lung Cancer* 2012;13:304–11.
- [540] Raghu G, Amatto VC, Behr J, Stowasser S. Comorbidities in idiopathic pulmonary fibrosis patients: a systematic literature review. *Eur Respir J* 2015;46:1113–30.
- [541] Vancheri C, Cottin V, Kreuter M, Hilberg O. IPF, comorbidities and management implications. *Sarcoidosis Vasc Diffuse Lung Dis* 2015;32 Suppl 1:17–23.
- [542] Hyldgaard C, Hilberg O, Bendstrup E. How does comorbidity influence survival in idiopathic pulmonary fibrosis? *Respir Med* 2014;108:647–53.
- [543] Navaratnam V, Fogarty AW, McKeever T, Thompson N, Jenkins G, Johnson SR, Dolan G, Kumaran M, Pointon K, Hubbard RB. Presence of a prothrombotic state in people with idiopathic pulmonary fibrosis: a population-based case-control study. *Thorax* 2014;69:207–15.
- [544] Yalınz E, Polat G, Demirci F, Deniz S, Karadeniz G, Aydınlı E, Vayisoglu G, Ayrancı A. Are idiopathic pulmonary fibrosis patients more anxious and depressive than patient's with other interstitial lung disease? *Sarcoidosis Vasc Diffuse Lung Dis* 2019;36:294–301.
- [545] Holland AE, Fiore Jr. JF, Bell EC, Goh N, Westall G, Symons K, Dowman L, Glaspole I. Dyspnoea and comorbidity contribute to anxiety and depression in interstitial lung disease. *Respirology* 2014;19:1215–21.
- [546] Lee YJ, Choi SM, Lee YJ, Cho YJ, Yoon HI, Lee JH, Lee CT, Park JS. Clinical impact of depression and anxiety in patients with idiopathic pulmonary fibrosis. *PLoS One* 2017;12:e0184300.
- [547] Matsuda T, Taniguchi H, Ando M, Kondoh Y, Kimura T, Kataoka K, Nishimura K, Nishiyama O, Sakamoto K, Hasegawa Y. Depression Is Significantly Associated with the Health Status in Patients with Idiopathic Pulmonary Fibrosis. *Intern Med* 2017;56:1637–44.

- [548] Dent E, Martin FC, Bergman H, Woo J, Romero-Ortuno R, Walston JD. Management of frailty: opportunities, challenges, and future directions. *Lancet* 2019;394:1376–86.
- [549] Guler SA, Kwan JM, Leung JM, Khalil N, Wilcox PG, Ryerson CJ. Functional ageing in fibrotic interstitial lung disease: the impact of frailty on adverse health outcomes. *Eur Respir J* 2020;55:1900647.
- [550] Collard HR, Ward AJ, Lanes S, Courtney Hayflinger D, Rosenberg DM, Hunsche E. Burden of illness in idiopathic pulmonary fibrosis. *J Med Econ* 2012;15:829–35.
- [551] Wijsenbeek M, Cottin V. Spectrum of Fibrotic Lung Diseases. *N Engl J Med* 2020;383:958–68.
- [552] Cottin V, Wollin L, Fischer A, Quaresma M, Stowasser S, Harari S. Fibrosing interstitial lung diseases: knowns and unknowns. *Eur Respir Rev* 2019;28:180100.
- [553] Nasser M, Larrieu S, Si-Mohamed S, Ahmad K, Boussel L, Brevet M, Chalabreysse L, Fabre C, Marque S, Revel D, Thivolet-Bejui F, Traclet J, Zeghmar S, Maucourt- Boulch D, Cottin V. Progressive fibrosing interstitial lung disease: a clinical cohort (the PROGRESS study). *Eur Respir J* 2021;57:2002718.
- [554] Faverio P, Piluso M, De Giacomi F, Della Zoppa M, Cassandro R, Harari S, Luppi F, Pesci A. Progressive Fibrosing Interstitial Lung Diseases: Prevalence and Characterization in Two Italian Referral Centers. *Respiration* 2020;99:838–45.
- [555] Olson A, Hartmann N, Patnaik P, Wallace L, Schlenker-Herceg R, Nasser M, Richeldi L, Hoffmann-Vold AM, Cottin V. Estimation of the Prevalence of Progressive Fibrosing Interstitial Lung Diseases: Systematic Literature Review and Data from a Physician Survey. *Advances in therapy* 2021;38:854–67.
- [556] Brown KK, Martinez FJ, Walsh SLF, Thannickal VJ, Prasse A, Schlenker-Herceg R, Goeldner RG, Clerisme-Beaty E, Tetzlaff K, Cottin V, Wells AU. The natural history of progressive fibrosing interstitial lung diseases. *Eur Respir J* 2020;55.
- [557] Wells AU, Brown KK, Flaherty KR, Kolb M, Thannickal VJ, Group IPFCW. What's in a name? That which we call IPF, by any other name would act the same. *Eur Respir J* 2018;51.
- [558] Flaherty KR, Wells AU, Cottin V, Devaraj A, Walsh SLF, Inoue Y, Richeldi L, Kolb M, Tetzlaff K, Stowasser S, Coeck C, Clerisme-Beaty E, Rosenstock B, Quaresma M, Haeufel T, Goeldner RG, Schlenker-Herceg R, Brown KK, Investigators IT. Nintedanib in Progressive Fibrosing Interstitial Lung Diseases. *N Engl J Med* 2019;381:1718–27.
- [559] George PM, Spagnolo P, Kreuter M, Altinisik G, Bonifazi M, Martinez FJ, Molyneaux PL, Renzoni EA, Richeldi L, Tomassetti S, Valenzuela C, Vancheri C, Varone F, Cottin V, Costabel U. Progressive fibrosing interstitial lung disease: clinical uncertainties, consensus recommendations, and research priorities. *Lancet Respir Med* 2020;8:925–34.

[560] Maher TM, Corte TJ, Fischer A, Kreuter M, Lederer DJ, Molina-Molina M, Axmann J, Kirchgaessler KU, Samara K, Gilberg F, Cottin V. Pirfenidone in patients with unclassifiable progressive fibrosing interstitial lung disease: a double-blind, randomised, placebo-controlled, phase 2 trial. *Lancet Respir Med* 2020;8:147–57.

[561] Behr J, Prasse A, Kreuter M, Johow J, Rabe KF, Bonella F, Bonnet R, Grohe C, Held M, Wilkens H, Hammerl P, Koschel D, Blaas S, Wirtz H, Ficker JH, Neumeister W, Schönfeld N, Claussen M, Kneidinger N, Frankenberger M, Hummler S, Kahn N, Tello S, Freise J, Welte T, Neuser P, Günther A. Pirfenidone in patients with progressive fibrotic interstitial lung diseases other than idiopathic pulmonary fibrosis (RELIEF): a double-blind, randomised, placebo-controlled, phase 2b trial. *Lancet Respir Med* 2021;9:476–86.

[562] Maher TM, Brown KK, Kreuter M, Devaraj A, Walsh SLF, Lancaster LH, Belloli EA, Padilla M, Behr J, Goeldner RG, Tetzlaff K, Schlenker-Herceg R, Flaherty KR. Effects of nintedanib by inclusion criteria for progression of interstitial lung disease. *Eur Respir J* 2021:2004587.

[563] Flaherty KR, Wells AU, Cottin V, Devaraj A, Inoue Y, Richeldi L, Walsh SLF, Kolb M, Koschel D, Moua T, Stowasser S, Goeldner RG, Schlenker-Herceg R, Brown KK. Nintedanib in progressive interstitial lung diseases: data from the whole INBUILD trial. *Eur Respir J* 2021:2004538.

[564] Armanios M, Price C. Telomeres and disease: an overview. *Mutat Res* 2012;730:1–2.

[565] Stanley SE, Gable DL, Wagner CL, Carlile TM, Hanumanthu VS, Podlevsky JD, Khalil SE, DeZern AE, Rojas-Duran MF, Applegate CD, Alder JK, Parry EM, Gilbert WV, Armanios M. Loss-of-function mutations in the RNA biogenesis factor NAF predispose to pulmonary fibrosis-emphysema. *Sci Transl Med* 2016;8:351ra107.

[566] Stuart BD, Choi J, Zaidi S, Xing C, Holohan B, Chen R, Choi M, Dharwadkar P, Torres F, Girod CE, Weessler J, Fitzgerald J, Kershaw C, Klesney-Tait J, Mageto Y, Shay JW, Ji W, Bilguvar K, Mane S, Lifton RP, Garcia CK. Exome sequencing links mutations in PARN and RTEL1 with familial pulmonary fibrosis and telomere shortening. *Nat Genet* 2015;47:512–7.

[567] Kannengiesser C, Borie R, Menard C, Reocreux M, Nitschke P, Gazal S, Mal H, Taille C, Cadranet J, Nunes H, Valeyre D, Cordier JF, Callebaut I, Boileau C, Cottin V, Grandchamp B, Revy P, Crestani B. Heterozygous RTEL1 mutations are associated with familial pulmonary fibrosis. *Eur Respir J* 2015;46:474–85.

[568] Hodgson U, Pulkkinen V, Dixon M, Peyrard-Janvid M, Rehn M, Lahermo P, Ollikainen V, Salmenkivi K, Kinnula V, Kere J, Tukiainen P, Laitinen T. ELMOD2 is a candidate gene for familial idiopathic pulmonary fibrosis. *Am J Hum Genet* 2006;79:149–54.

[569] Zamora AC, Collard HR, Wolters PJ, Webb WR, King TE. Neurofibromatosis-associated lung disease: a case series and literature review. *Eur Respir J* 2007;29:210–4.

[570] Hamvas A, Deterding RR, Wert SE, White FV, Dishop MK, Alfano DN, Halbower AC, Planer B, Stephan MJ, Uchida DA, Williams LD, Rosenfeld JA, Lebel RR, Young LR, Cole

FS, Noguee LM. Heterogeneous pulmonary phenotypes associated with mutations in the thyroid transcription factor gene NKX2-1. *Chest* 2013;144:794–804.

[571] Dell'Angelica EC, Shotelersuk V, Aguilar RC, Gahl WA, Bonifacino JS. Altered trafficking of lysosomal proteins in Hermansky-Pudlak syndrome due to mutations in the beta 3A subunit of the AP-3 adaptor. *Mol Cell* 1999;3:11–21.

[572] Mercier S, Kury S, Shaboodien G, Houniet DT, Khumalo NP, Bou-Hanna C, Bodak N, Cormier-Daire V, David A, Faivre L, Figarella-Branger D, Gherardi RK, Glen E, Hamel A, Laboissee C, Le Caignec C, Lindenbaum P, Magot A, Munnich A, Mussini JM, Pillay K, Rahman T, Redon R, Salort-Campana E, Santibanez-Koref M, Thauvin C, Barbarot S, Keavney B, Bezieau S, Mayosi BM. Mutations in FAM111B cause hereditary fibrosing poikiloderma with tendon contracture, myopathy, and pulmonary fibrosis. *Am J Hum Genet* 2013;93:1100–7.