



HAL
open science

How May a Brief Seizure Lead to Prolonged Epileptic Amnesia?

Simela Chatzikonstantinou, Aude Jegou, Sacha Brohée, Rinki Singh, Christian Bénar, Stanislas Lagarde, Fabrice Bartolomei

► To cite this version:

Simela Chatzikonstantinou, Aude Jegou, Sacha Brohée, Rinki Singh, Christian Bénar, et al.. How May a Brief Seizure Lead to Prolonged Epileptic Amnesia?. *Brain Topography: a Journal of Cerebral Function and Dynamics*, 2023, 36 (2), pp.129-134. <10.1007/s10548-022-00930-z>. <hal-04086436>

HAL Id: hal-04086436

<https://hal.science/hal-04086436v1>

Submitted on 2 May 2023

HAL is a multi-disciplinary open access archive for the deposit and dissemination of scientific research documents, whether they are published or not. The documents may come from teaching and research institutions in France or abroad, or from public or private research centers.

L'archive ouverte pluridisciplinaire **HAL**, est destinée au dépôt et à la diffusion de documents scientifiques de niveau recherche, publiés ou non, émanant des établissements d'enseignement et de recherche français ou étrangers, des laboratoires publics ou privés.



HAL Authorization

TITLE PAGE

How may a brief seizure lead to prolonged epileptic amnesia?

Authors : Simela Chatzikonstantinou^{1,2}, Aude Jegou³, Sacha Brohée¹, Rinki Singh⁴, Christian Bénar³, Stanislas Lagarde^{1,3}, Fabrice Bartolomei^{1,3}

Affiliations:

¹ APHM, Timone Hospital, Epileptology and Cerebral Rhythmology, Marseille, France

² Third Department of Neurology, Aristotle University of Thessaloniki, Thessaloniki, Greece

³ Aix Marseille Univ, INSERM, INS, Inst Neurosci Syst, Marseille, France.

⁴ Department of Clinical Neurophysiology, King's College Hospital, London, United Kingdom

Corresponding Authors:

Dr Stanislas LAGARDE (stanislas.lagarde@ap-hm.fr)

or Pr Fabrice Bartolomei (fabrice.bartolomei@ap-hm.fr)

Service D'Epileptologie et de Rythmologie Cérébrale, Hôpitaux de la Timone, 264 Rue Saint-Pierre, 13005, Marseille, France

Abstract

Pure amnesic seizures are defined as self-limited episodes with isolated, anterograde memory loss and have been attributed to bilateral dysfunction of mesial temporal structures. This type of seizure can occur in patients with different forms of temporal lobe epilepsy and has been more recently associated with a late-onset epileptic syndrome, called transient epileptic amnesia (TEA). The mechanisms of such prolonged manifestations are not well known and notably its ictal or post-ictal origin remains poorly understood. We report a case of prolonged anterograde amnesia (lasting several hours) following a brief seizure induced by stimulation of the left entorhinal cortex, recorded during stereo-EEG (SEEG). This episode was associated with prolonged changes in the intracerebral EEG signal complexity (entropy) within bilateral mesial temporal structure, particularly the entorhinal cortices, with a progressive normalization paralleling the clinical recovery. Our case shows that long-lasting (hours) memory impairment may follow brief seizure that led to prolonged electrophysiological signals alterations in bilateral mesial temporal structures

Key words: drug-resistant epilepsy, partial epilepsy, SEEG, memory, stimulation

Competing Interests: The authors have no competing interests to declare that are relevant to the content of this article.

Acknowledgements: we thank Dr Romain Carron for the implantation of SEEG electrodes and Prof Didier Scavarda for the resective surgery of the patient.

Funding: The research leading to these results received funding from Agence Nationale de la Recherche, under Grant/ Award Number: ANR- 11- IDEX- 0001- 02 and ANR- 13- PRTS- 0011-

01

TEXT

Introduction

Pure amnesic seizures (Palmini et al. 1992) are defined as self-limited episodes with isolated, anterograde memory loss and have been attributed to bilateral dysfunction of mesial temporal structures. This seizure can occur in patients with different forms of temporal lobe epilepsy and has been more recently associated with a late-onset epileptic syndrome, called transient epileptic amnesia (TEA) (Kapur 1993; Butler et al. 2007; Mosbah et al. 2014). It usually begins in later life, most commonly in the seventh decade (Zeman et al. 1998) and is generally responsive to antiepileptic therapy (Gallassi 2006; Butler et al. 2007). In this form of epilepsy, the seizures are typically purely amnesic and often associated with interictal memory impairment. In most cases, the episodes are brief, lasting less than 10 minutes, but cases with longer duration, ranging from 30 minutes to several hours can occur (Tassinari et al. 1991; Mosbah et al. 2014). The mechanisms of such prolonged manifestations are not well known. Few cases have been documented using video-EEG (Palmini et al. 1992; Mosbah et al. 2014; Jensen et al. 2020) and the ictal or post ictal origin remains poorly understood. Cases of amnesic seizures recorded during intracerebral EEG exploration are rare (Palmini et al. 1992).

In this work we report a case of prolonged anterograde amnesia (lasting several hours) following a brief seizure induced by stimulation of the left entorhinal cortex, recorded during stereo-EEG (SEEG). To gain insight into the mechanisms of the prolonged amnesia, we applied an entropy-based method of signal complexity analysis. It has been argued that a certain degree of complexity in brain signals is associated with healthy cognition, whereas low complexity may be a sign of pathological states (Mateos et al. 2018).

Case Study

A 40-year-old, left-handed woman, with an history of focal pharmaco-resistant epilepsy, post-head trauma, was referred for presurgical evaluation.

Seizures were characterised by behavioural arrest followed by head version to the left, dystonic right-hand posturing, chewing automatic movements and loss of consciousness. Occasionally, the seizures were preceded by an ascending warm epigastric sensation or “déjà-vu” feeling. Some of the seizures were followed by prolonged periods (hours) during which her memory “was not functioning properly”, she had difficulty remembering events and names and she would usually fully recover the next day after the seizure. Video-scalp-EEG found left temporal ictal discharges. Magnetic resonance imaging (MRI) revealed gliotic scar within temporal edge of the left insula. 18-FDG-PET showed moderate hypometabolism in the left insulo-opercular region extending to the left inferior parietal region. Interictal magnetoencephalography (MEG) showed predominant localisation of interictal spikes in the left temporal anterior areas. The neuropsychological assessment showed: 1) normal global intellectual efficiency without visuo-verbal dissociation (WAIS-IV), 2) normal memory performance (immediate and differed, without dissociation, MEM III), 3) normal denomination (DO80) .

Given the possible dissociation between anatomical lesion and putative epileptogenic zone (EZ), a stereo-EEG (SEEG) was undertaken. A signed consent was obtained from the patient and her relatives, who were informed that her data could be used for research purposes. 17 electrodes were implanted (*Figure 1*). The decision on electrode placement was guided by the assumptions about the location of the EZ. High-frequency stimulation at 50 Hz (pulse duration 1 ms, intensity 0.5-2mA) was applied in a bipolar fashion to each of the contact pairs in the grey matter for a period of 3-5 s (see *Supplementary Material*). Direct electrical stimulation

of the left entorhinal cortex triggered a habitual seizure (Trébuchon and Chauvel 2016). Pre-surgical evaluation concluded to a left mesio-temporal EZ and a left anterior temporal lobectomy made the patient seizure free for 6 months until now.

During stimulation of the right rhinal cortex (50 Hz, 1.5 mA, 5 s), the patient experienced a sensation of "déjà vu" together with nausea, which she did not recognize as a typical seizure. After this first stimulation associated with a SEEG unilateral mesio-temporal discharge (duration 55 seconds), there was no obvious memory impairment (normal episodic retrograde memory, no formal testing of anterograde memory). However, there was some persistent slowing of SEEG background activity in the right rhinal cortex. Five minutes later, during stimulation of the left rhinal cortex (50 Hz, 1.5 mA, 5 s), there was a clinically asymptomatic electrical discharge in the left mesio-temporal, left insular, and left posterior cingulate regions (sparing the right rhinal cortex) during 32 sec. At the end of this discharge, the patient presented a mixed retrograde-anterograde amnesic state that gradually subsided over the next 3 hours. Specifically, she was unaware of the reason for her hospitalization and could not recall the discussions that had taken place between her and the medical staff in the preceding minutes. In addition, she was unable to encode new information, as tested repeatedly by medical staff using a three-word recall test. Older memories and other aspects of memory remained intact throughout. On SEEG traces, there was a slowing of background activity in the bilateral mesiotemporal regions with progressive recovery (*Figure 1*).

In this study, we chose permutation entropy (PE) to characterize the level of disorganization of the signals and to correlate with the amnesic state (see *Supplementary Material*). We compute PE in 6 regions of interest (left amygdala, left hippocampus, left entorhinal cortex, left para-hippocampal gyrus, left temporal pole and right entorhinal cortex). These regions were chosen because of the implication of mesial temporal regions in memory processing.

Particularly, the hippocampus is thought to be critical for long-term detailed episodic memories (Vargha-Khadem et al. 1997), and the perirhinal region has been implicated in recognition memory and in context-free memory in general (Mishkin et al. 1997; Barbeau 2011). We analysed five distinct periods of interest:

1. Seizure: period with ictal discharge
2. Post-seizure: the 225 seconds just after this ictal discharge
3. Period of Interest (POI) 1 = early amnesia: the first 500 seconds of amnesia, characterised by a marked amnesia with anterograde encoding and with major retrograde autobiographical amnesia
4. POI2 = persistent anterograde amnesic state: 1 hour after the onset of amnesia characterised by the recovery of retrograde memory but persistence of an anterograde amnesia
5. POI3 = complete recovery: the day after the episode when the patient has completely recovered her usual memory (in the morning, first period with certainty of memory recovery because of clinical testing)

We compared these periods of interest with a 10 mn baseline taken on the same afternoon but preceding electrical seizure stimulation (see *Supplementary Material*).

During the seizure induced by the second stimulation of left rhinal cortex we observed a significant and marked decrease of entropy within the mesial temporal region (amygdala, hippocampus, entorhinal, temporal pole, and para-hippocampal) whereas the right entorhinal cortex (involved in the previous stimulus-induced seizure) showed non-significant increase of entropy. The immediate post-seizure period and POI1, when the patient had marked global amnesia, was both characterised by significant increased entropy (compared to baseline) within left amygdala, hippocampus and temporal pole, and also right entorhinal

cortex (with rather unchanged entropy within left entorhinal and para-hippocampal cortices). Furthermore, we observed a higher entropy during immediate post seizure than during POI 1 (probably reflecting the beginning of the PE decrease process) POI 2, clinically characterised by a chronic state of anterograde amnesia, was characterised by a decreased of entropy within left amygdala, temporal pole, entorhinal, and para-hippocampal cortices, also affecting right entorhinal cortex (with unchanged entropy within left hippocampus). Finally, POI 3, clinically characterised by complete recovery of the memory functioning, showed a normalisation of the entropy value across areas, at the exception of the left temporal pole (Figure 2 and *Supplementary Material*). Noteworthy, the right entorhinal stimulation induced first a decrease of entropy during the seizure followed by an increase of entropy during post-seizure period, both limited to the right entorhinal cortex (*Supplementary Material*).

Discussion

We studied a case of transient amnesia induced by direct electrical stimulation of the rhinal cortices in a patient with refractory focal structural epilepsy explored by SEEG. This report shows that a stimulated seizure, even of short duration, involving the mesial temporal structures, particularly the hippocampi and rhinal cortices, is able to induce a transient but prolonged post-ictal amnesia associated with prolonged changes in the SEEG signal and entropy. The dynamics of these modifications are correlated with the clinical evolution, the recovery of a normal entropy corresponding to a return to a normal memory state. In the original paper by Palmieri et al, which introduced the entity of pure amnesic seizures, amnesia was attributed to epileptic discharge limited to uni- or bilateral mesio-temporal structures also depending on the underlying structural damage (Palmieri et al. 1992). Interestingly, our results are in agreement with these observations, although in our case the amnesia was

essentially a post-ictal manifestation. Moreover, the left insular scar of our patient may have weakened her memory system and favoured her post-ictal memory deficit, as left insular infarction demonstrated poorer verbal memory performance (Manes et al. 1999).

The question of whether amnesic seizures reflect ictal activity, or a postictal state has been posed since the early years of their description of the TEA syndrome or more generally in temporal lobe epilepsies (Tassinari et al. 1991). It has been hypothesized by various clinical descriptions that both scenarios could possibly occur, depending on the patient and the underlying pathology (Zeman et al. 1998). Interestingly, in a study of 30 patients with episodic memory dysfunction, interictal memory impairment, and a diagnosis of epilepsy (defined as epileptic amnesia syndrome, by the authors), 76.7% of them exhibited transient anterograde amnesia after the seizures (sometimes clinically subtle: short loss of contact and automatisms). Therefore, postictal amnesia was the most notable symptom leading patients to seek medical attention (Gallassi 2006). Long term amnesic seizures with anterograde amnesia lasting more than 1 hour have been reported in this syndrome (Butler et al. 2007; Mosbah et al. 2014). We show here that these probably relate to prolonged post-ictal alteration of entropy within mesio-temporal structures. An underlying structural pathology may favour this type of manifestation (cf. post-traumatic lesions in our patient). In TEA syndrome, chronic alterations of hippocampal regions have been suggested by morphometric studies (Butler et al. 2009) and PET metabolic imaging (Mosbah et al. 2014).

The interpretation of the entropy changes in post ictal phases remains hypothetical. The seizure is accompanied by a marked drop in entropy which probably corresponds to a massive decrease in signal complexity (Yang et al. 2018). To our knowledge, no specific study has investigated the correlation between entropy change and post-ictal recovery. The immediate post-ictal phase ("Post seizure") and the "POI1" period (persistence of a fairly global amnesia)

are mainly characterized by an increase in entropy within the SEEG signal in the bilateral mesio-temporal structures.

This apparent paradoxical entropy increase could be interpreted either as a compensatory and recuperative phenomenon or as an abnormal entropy too close to a stochastic random signal. It is likely that the information contained in the EEG signal to be informative requires an equilibrium in the entropy values. The post-ictal phase with pure anterograde amnesia (POI2,) corresponds to a decrease in entropy observed in the entorhinal cortex on both sides. This decrease in entropy corresponds classically to a decrease in signal complexification and information depletion (Bandt and Pompe 2002).

In conclusion, we report a case with prolonged post ictal amnesia associated with alteration of signal complexity within bilateral mesio-temporal structures. It could be a process involved in the semiology of prolonged amnestic seizures particularly observed in the transient epileptic amnesia syndrome.

DATA AVAILABILITY STATEMENT

The datasets generated during and/or analysed during the current study are available from the corresponding author on reasonable request.

REFERENCES

- Bandt C, Pompe B (2002) Permutation entropy: a natural complexity measure for time series. *Phys Rev Lett* 88:4. <https://doi.org/10.1103/PHYSREVLETT.88.174102>
- Barbeau EJ (2011) Les modèles de la mémoire : approches anatomo-fonctionnelle et représentationnelle-hiérarchique. *Rev Neuropsychol* 3:104. <https://doi.org/10.3917/rne.032.0104>
- Butler CR, Bhaduri A, Acosta-Cabronero J, et al (2009) Transient epileptic amnesia: regional brain atrophy and its relationship to memory deficits. *Brain* 132:357–368. <https://doi.org/10.1093/brain/awn336>
- Butler CR, Graham KS, Hodges JR, et al (2007) The syndrome of transient epileptic amnesia. *Ann Neurol* 61:587–598. <https://doi.org/10.1002/ana.21111>
- Gallassi R (2006) Epileptic Amnesic Syndrome: An Update and Further Considerations. *Epilepsia* 47:103–105. <https://doi.org/10.1111/j.1528-1167.2006.00704.x>
- Jensen CD, Krøigård T, Beier CP (2020) Transient epileptic amnesia diagnosed using long-term electroencephalography. *Epileptic Disord* 22:225–228. <https://doi.org/10.1684/epd.2020.1148>
- Kapur N (1993) Transient epileptic amnesia a clinical update and a reformulation. *J Neurol Neurosurg Psychiatry* 56:1184–1190. <https://doi.org/10.1136/jnnp.56.11.1184>
- Manes F, Springer J, Jorge R, Robinson RG (1999) Verbal memory impairment after left insular cortex infarction. *J Neurol Neurosurg Psychiatry* 67:532–534. <https://doi.org/10.1136/jnnp.67.4.532>
- Mateos DM, Guevara Erra R, Wennberg R, Perez Velazquez JL (2018) Measures of entropy and complexity in altered states of consciousness. *Cogn Neurodyn* 12:73–84.

<https://doi.org/10.1007/s11571-017-9459-8>

Mishkin M, Suzuki WA, Gadian DG, Vargha-Khadem F (1997) Hierarchical organization of cognitive memory. *Philos Trans R Soc London Ser B Biol Sci* 352:1461–1467.

<https://doi.org/10.1098/rstb.1997.0132>

Mosbah A, Tramoni E, Guedj E, et al (2014) Clinical, neuropsychological, and metabolic characteristics of transient epileptic amnesia syndrome. *Epilepsia* 55:699–706.

<https://doi.org/10.1111/epi.12565>

Palmini AL, Gloor P, Jones-Gotman M (1992) Pure amnestic seizures in temporal lobe epilepsy. *Brain* 115:749–769

Tassinari CA, Ciarmatori C, Alesi C, et al (1991) Transient Global Amnesia as a Postictal State from Recurrent Partial Seizures. *Epilepsia* 32:882–885. <https://doi.org/10.1111/j.1528-1157.1991.tb05545.x>

Trébuchon A, Chauvel P (2016) Electrical Stimulation for Seizure Induction and Functional Mapping in Stereoelectroencephalography. *J Clin Neurophysiol* 33:511–521.

<https://doi.org/10.1097/WNP.0000000000000313>

Vargha-Khadem F, Gadian DG, Watkins KE, et al (1997) Differential Effects of Early Hippocampal Pathology on Episodic and Semantic Memory. *Science* (80-) 277:376–380.

<https://doi.org/10.1126/science.277.5324.376>

Yang Y, Zhou M, Niu Y, et al (2018) Epileptic Seizure Prediction Based on Permutation Entropy. *Front Comput Neurosci* 12:. <https://doi.org/10.3389/fncom.2018.00055>

Zeman AZJ, Boniface SJ, Hodges JR (1998) Transient epileptic amnesia: a description of the clinical and neuropsychological features in 10 cases and a review of the literature. *J Neurol Neurosurg Psychiatry* 64:435–443. <https://doi.org/10.1136/jnnp.64.4.435>

FIGURES LEGENDS

Figure 1

A. Axial and coronal slice views of the electrodes of interest (post-operative CT and pre-operative MRI fusion). The contacts are numbered in ascending order from the most mesial part (i.e. contact number 1 is the most medial contact of the electrode). 3D representations of the electrodes of the patients.

B. SEEG traces during the TEA showing:

Upper part: First stimulation in the right rhinal cortex followed by limited ictal discharge in this area (sparing the contralateral side). The right part shows a slowing of background activity in the right rhinal cortex following the first stimulation (persistence of IEDs in the left mesio-temporal structures / absence of amnesia at this time)

Lower part: Second stimulation in the left rhinal cortex responsible for ictal discharge in all left mesio-temporal regions (sparing the right rhinal cortex which retains a slowed background activity). On the right part: Bilateral slowing of background activity in mesio-temporal structures concomitant with the amnesia observed after the second stimulation (no persistence of ictal discharge)

Timescale: 30 seconds per page

A' left amygdala; B' left hippocampus; TB' left rhinal cortex; GPH' left para-hippocampal cortex; TP' left temporal pole; TB right Rhinal cortex

Stimulation parameters: Intensity 1,5 mA Pulse Width 1000 μ s Frequency 50 Hz Duration 5 seconds

Figure 2

A) Time course of entropy values per region over the different time periods of interest. The entropy values are represented in z-score in comparison to the baseline.

The 5 seconds of stimulation were not analysed.

A' left amygdala; B' left hippocampus; TB' left rhinal cortex; GPH' left para-hippocampal cortex; TP' left temporal pole; TB right rhinal cortex

B) Boxplot showing the entropy values per region over the different time periods of interest.

The entropy values are represented in z-score in comparison to the baseline.

The 5 seconds of stimulation were not analysed.

A' left amygdala; B' left hippocampus; TB' left rhinal cortex; GPH' left para-hippocampal cortex; TP' left temporal pole; TB right rhinal cortex

Figure 1

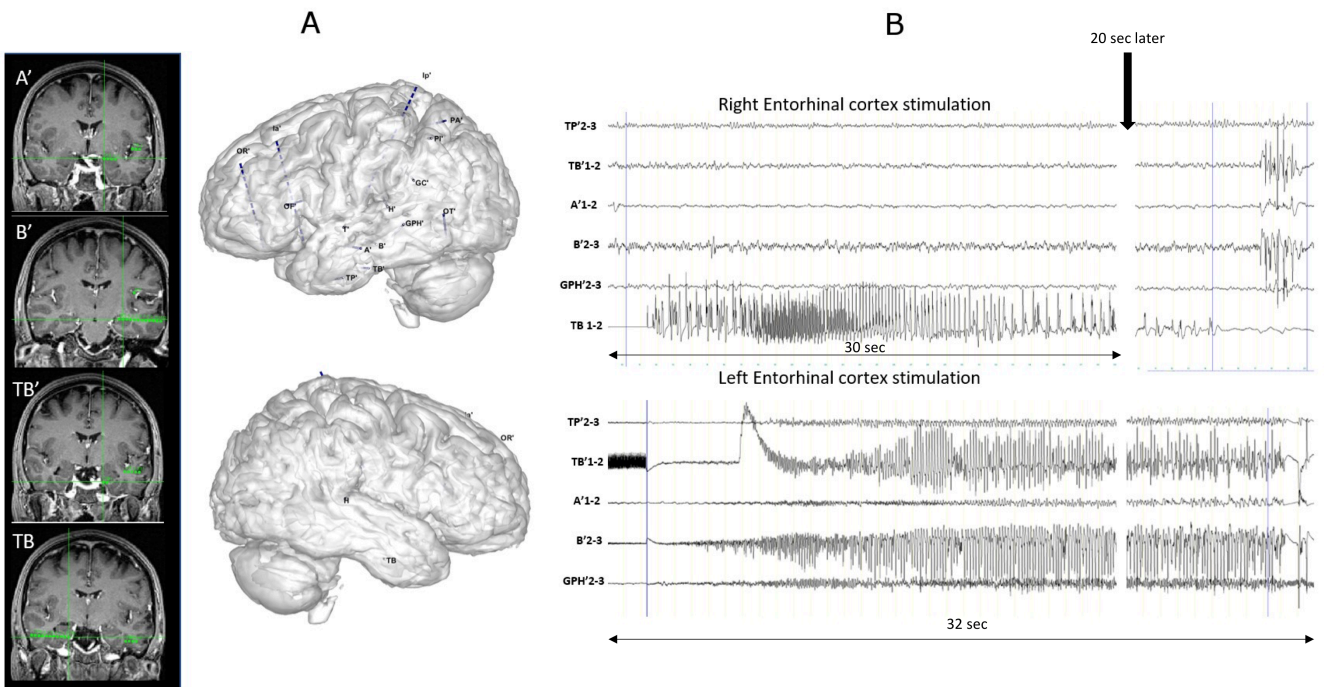
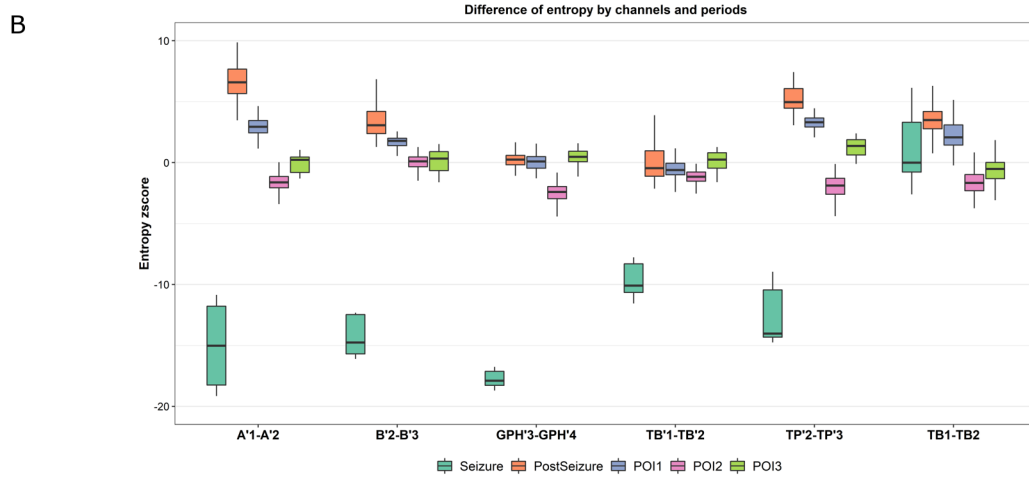
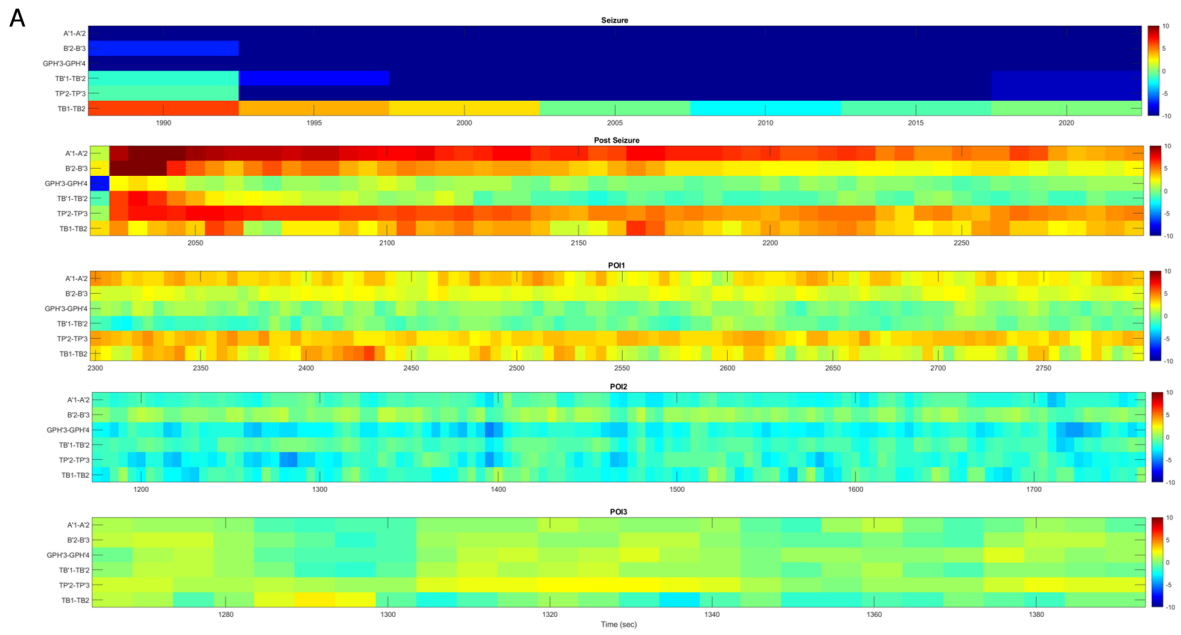
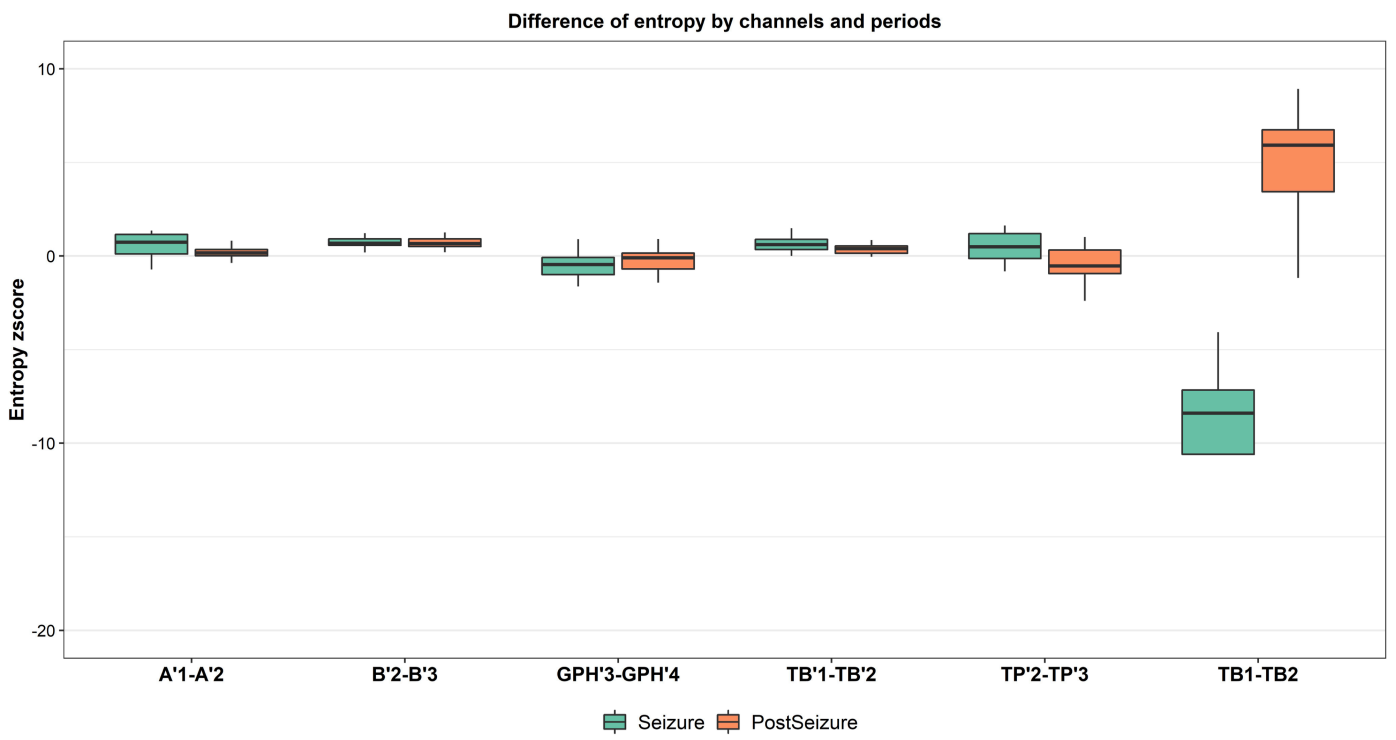


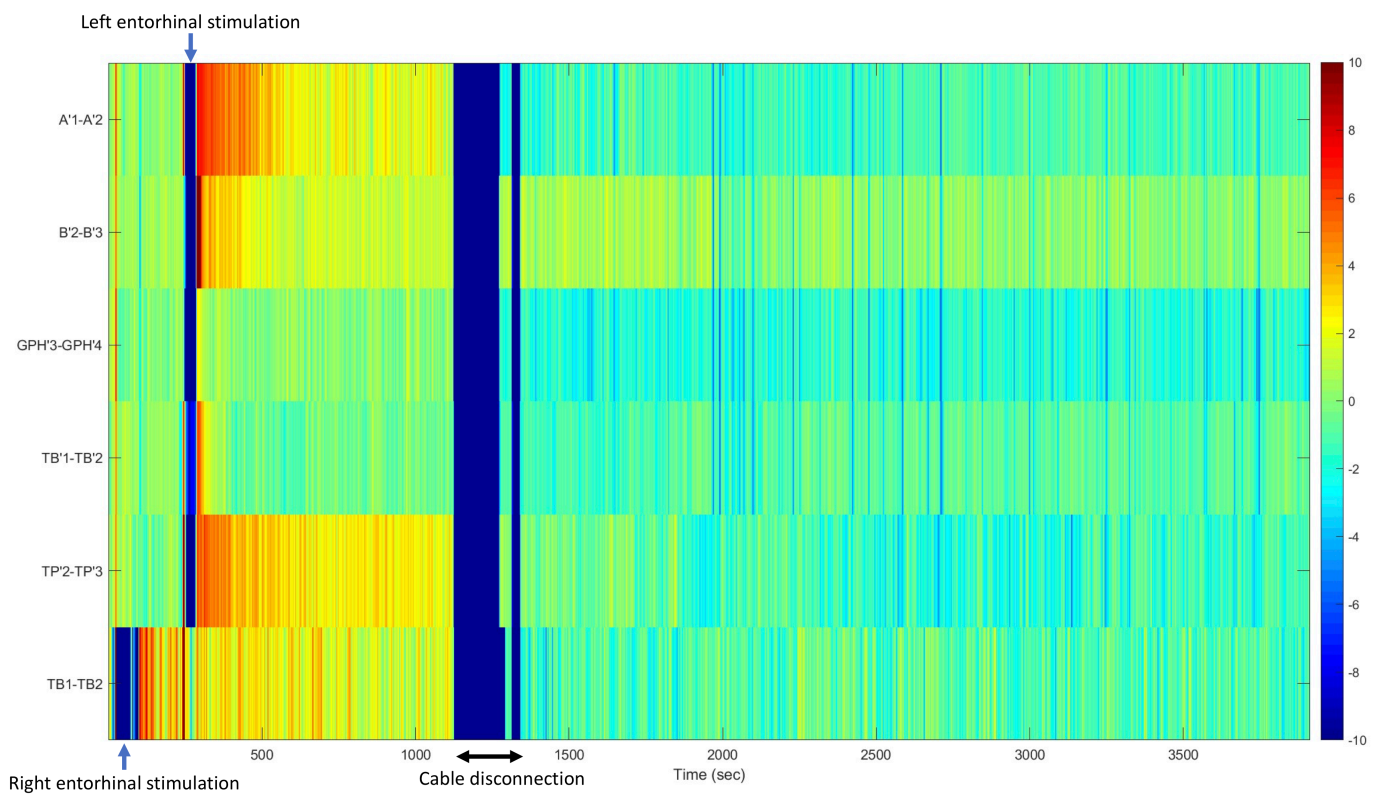
Figure 2



Supplementary Figure 1



Supplementary Figure 2



SUPPLEMENTARY MATERIAL

Material and Methods

SEEG electrodes: Alcis, Besançon, France; 10-15 contacts; length: 2 mm, diameter: 0.8 mm, spaced 1.5 mm apart.

A postoperative computerized tomography (CT) scan was performed to verify the absence of bleeding and the position of each recording lead. Then, a fusion of CT/MRI data was performed to identify and locate precisely each contact along the electrode trajectory using a specific in-house software (Gardel, available at: <http://meg.univ-amu.fr/wiki/GARDEL:presentation>) (Medina Villalon et al. 2018). The signals were recorded on a 256-channel Deltamed™ system and were sampled at 1024 Hz. Signal analysis was performed with Anywave software (available at: <https://meg.univ-amu.fr/wiki/AnyWave>) (Colombet et al. 2015). Electrical stimulation was produced by a regulated neurostimulator designed for safe diagnostic stimulation of the human brain (Inomed®).

The specific entropy method chosen was the “Permutation Entropy” (PE) (Bandt and Pompe 2002) which considers the complexity of the electrophysiological signals. PE is based on a measure of Shannon entropy of the relationships between neighbouring values of the time series. The method is rendered more robust than standard information-based method by calculating the entropy for n “embedding dimensions” in the range of 3 to 7, (i.e., different number of neighbours or samples). We used a fixed delay τ which indicates the distance between neighbours ($\tau = 1$ for consecutive samples).

$$H(n) = - \sum p(\pi) \log \log p(\pi)$$

$$h_n = \frac{H(n)}{(n-1)}$$

With π describing the dynamics between the neighbour values (e.g., $x_t < x_{t+1}$), $p(\pi)$ probability of this order and n embedding dimensions. h_n gives a value between 0 and 1, 0 meaning that the signal is perfectly organized (for example in the case of a pure sine wave) and 1 completely disorganized (completely random noise). The algorithm used to apply permutation entropy on our data is the one developed by Unakafova (Unakafova and Keller 2013) due to its algorithmic performance. The efficiency of this method stems from the use of pre-filled tables to describe the order relation between neighbouring values. Before applying permutation entropy on a given seizure signal, we performed careful selection of channels by keeping those in the grey matter and removing the white matter channels. A bipolar montage was used (i.e., difference of consecutive channels). Permutation entropy was computed on each channel, on a sliding window of 10s with an overlap of 5s, an order of 3 and a delay of 1 sample.

Statistically we evaluated the z-score of the PE value by period and region and the p-value determined by using Wilcoxon test was corrected by applying a Bonferroni correction to account for multiple comparisons.

Supplementary Table

Table showing the variation of entropy values across periods of interest and regions, relative to the baseline. Numerical values are z-score values relative to the baseline. Statistically significant values after Bonferroni correction for multiple comparisons are marked in red for entropy increases and in blue for decreases (non-statistically significant values remain in white).

	Seizure	Post-seizure	POI1	POI2	POI3
Left amygdala (A'1-2)	-17.6	6.6	2.9	-1.6	0
Left Hippocampus (B'1-2)	-13.5	3.9	1.7	0	0.2
Left entorhinal cortex (TB'1-2)	-8.8	0.3	-0.6	-1.2	0.2
Left Para hippocampal gyrus (GPH'3-4)	-17.2	0.2	0	-2.5	0.4
Left temporal Pole (TP'2-3)	-11.4	5.2	3.3	-1.9	1.2
Right entorhinal cortex (TB1-2)	1.2	3.5	2.3	-1.6	-0.4