



HAL
open science

An impossible biliary drainage? Fistulization of a degenerated intraductal papillary mucinous pancreatic neoplasm to the common bile duct.

Pierre Mayer, Lucile Héroin, Leonardo Sosa-Valencia, Flavien Dautrecque, Patrick Pessaux, Antonio Saviano, Francois Habersetzer

► To cite this version:

Pierre Mayer, Lucile Héroin, Leonardo Sosa-Valencia, Flavien Dautrecque, Patrick Pessaux, et al.. An impossible biliary drainage? Fistulization of a degenerated intraductal papillary mucinous pancreatic neoplasm to the common bile duct.. *Endoscopy*, 2023, 55 (S 01), 10.1055/a-1930-5917 . hal-04080455

HAL Id: hal-04080455

<https://hal.science/hal-04080455v1>

Submitted on 24 Apr 2023

HAL is a multi-disciplinary open access archive for the deposit and dissemination of scientific research documents, whether they are published or not. The documents may come from teaching and research institutions in France or abroad, or from public or private research centers.

L'archive ouverte pluridisciplinaire **HAL**, est destinée au dépôt et à la diffusion de documents scientifiques de niveau recherche, publiés ou non, émanant des établissements d'enseignement et de recherche français ou étrangers, des laboratoires publics ou privés.

An impossible biliary drainage? Fistulization of a degenerated intraductal papillary mucinous pancreatic neoplasm to the common bile duct



Intraductal papillary mucinous pancreatic neoplasms (IPMNs) are very common lesions. International guidelines recommend surveillance or more invasive management according to precise criteria [1]. A very rare complication of these lesions is the fistulization to an adjacent structure of the pancreas [2, 3].

We report the case of a 90-year-old man with jaundice in the context of metastatic prostatic adenocarcinoma. A cephalic cystic lesion of the pancreas was known and stable during his oncologic follow-up. An abdominal-pelvic computed tomography scan found major dilation of the common bile duct (measuring 27 mm) and of the main pancreatic duct (12 mm). A cephalic multiloculated cystic

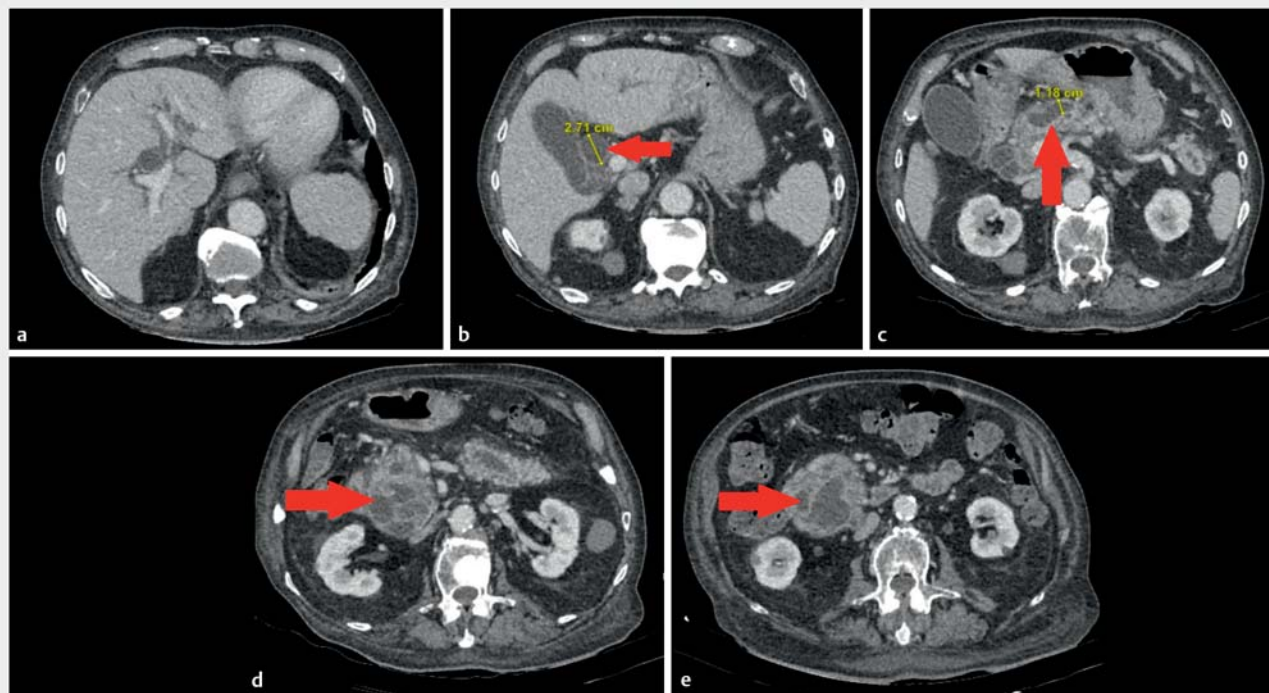
mass was also described, measuring 77×78 mm with irregular parietal nodular contrast, compatible with IPMNs (► Fig. 1, ► Fig. 2).

Endoscopic ultrasonography confirmed the diagnosis of IPMN with high-risk stigmata (main pancreatic duct >10 mm and enhancing mural nodule >5 mm). Endoscopic retrograde cholangiopancreatography (ERCP) was performed and revealed major dilation of the major and minor papillary orifices owing to presence of mucinous material. Sphincterotomy and use of a balloon inflated to 15 mm resulted in the clearance of the mucinous material. Cholangiography did not clearly identify a fistula between the bile duct and IPMN (► Video 1). The

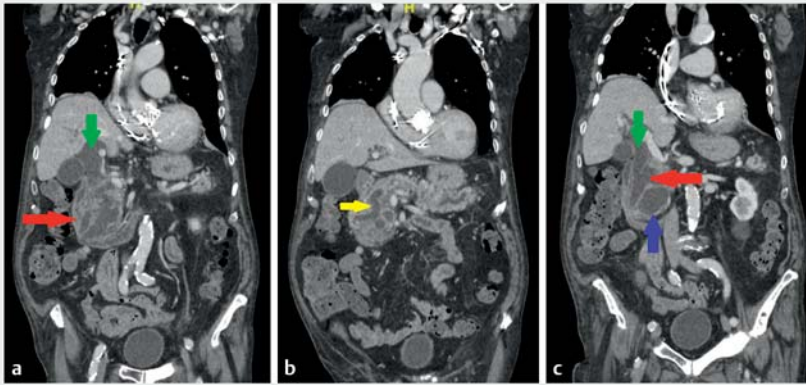
jaundice did not improve following this first procedure. A second ERCP was performed to extract mucinous material and to place two double-pigtail plastic stents (10Fr×7 cm) to provide biliary drainage (► Fig. 3).

Fistulization of IPMNs is a very rare complication, with only a few cases reported in the literature [2–5]. In practice, this type of fistula is untreatable by endoscopic means, mainly due to the continuous production of mucinous material. Endoscopic drainage appears to be a bridge to surgery or a palliative treatment. Surgery, when it is possible, appears to be the best treatment.

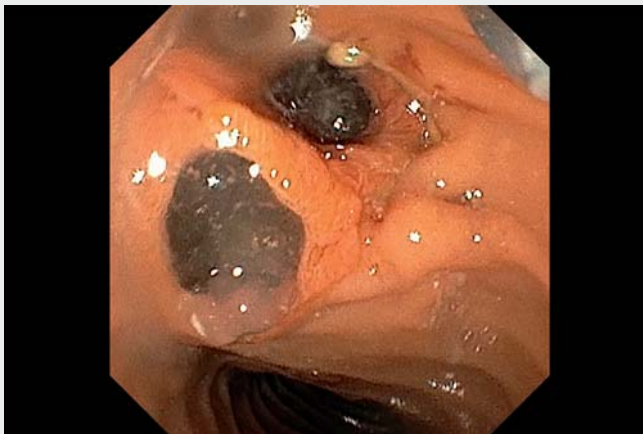
Endoscopy_UCTN_Code_CCL_1AZ_2AM



► **Fig. 1** Abdominal-pelvic computed tomography scan showing dilation of the common bile duct and main pancreatic duct due to an intraductal papillary mucinous pancreatic neoplasm (IPMPN) located at the lower part of the pancreatic head and uncus. **a** Dilation of the intrahepatic bile ducts and biliary convergence. **b** Dilation of the main bile duct (red arrow) measuring 27.1 mm. **c** Dilation of the main pancreatic duct (red arrow) measuring 11.8 mm. **d, e** IPMN with heterogeneous appearance (red arrow) with presence of septum.



► **Fig. 2** Abdominal-pelvic computed tomography scan (coronal section) showing degenerated intraductal papillary mucinous pancreatic neoplasm (IPMN), biliary dilation, and possible fistula between the IPMN and main bile duct. **a** Degenerated IPMN (red arrow) and dilation of the main bile duct (green arrow). **b** Dilation of the main pancreatic duct (yellow arrow) due to the IPMN. **c** Probable fistula between the main bile duct and IPMN (red arrow), with dilation of the common bile duct (green arrow) and involvement of the pancreatic uncus by IPMN (blue arrow).



► **Video 1** Endoscopic ultrasound and endoscopic retrograde cholangiopancreatography, showing dilation of the bile and pancreatic ducts by mucinous material, initial drainage, and subsequent placement of two double-pigtail plastic stents.

The authors

Pierre Mayer^{1,2}, Lucile Héroin^{1,2}, Leonardo Sosa-Valencia², Flavien Dautrecque³, Patrick Pessaux^{2,4,5}, Antonio Saviano^{1,2,5}, François Habersetzer^{1,2,5}

- 1 Department of Hepatology and Gastroenterology, Pôle Hépatodigestif, Nouvel Hôpital Civil, Hôpitaux Universitaires de Strasbourg, Strasbourg, France
- 2 Institut Hospitalo Universitaire Strasbourg, Strasbourg, France
- 3 Department of Hepatology and Gastroenterology, Centre Hospitalier de Lens, Lens, France
- 4 Department of Visceral and Digestive Surgery Pôle Hépatodigestif, Nouvel Hôpital Civil, Hôpitaux Universitaires de Strasbourg, Strasbourg, France
- 5 Inserm U1110, Institute for Viral and Liver Diseases, LabEx HepSYS, University of Strasbourg, Faculty of Medicine, Strasbourg, France

Corresponding author

Pierre Mayer, MD

Department of Hepatology and Gastroenterology, Pôle Hépatodigestif, Nouvel Hôpital Civil, Hôpitaux Universitaires de Strasbourg (HUS), 1, place de l'Hôpital, 67000 Strasbourg, France
 pierre-emmanuel.mayer@chru-strasbourg.fr

References

- [1] Tanaka M, Fernández-Del Castillo C, Kamisawa T et al. Revisions of international consensus Fukuoka guidelines for the management of IPMN of the pancreas. *Pancreatology* 2017; 17: 738–753
- [2] Bong JJ, Wang J, Spalding DR. Pancreatobiliary and pancreatoduodenal fistulae in intraductal papillary mucinous neoplasm of the pancreas: report of a case. *Surg Today* 2011; 41: 281–284
- [3] Brown NG, Camilo J, McCarter M et al. Refractory jaundice from intraductal papillary mucinous neoplasm treated with cholangioscopy-guided radiofrequency ablation. *ACG Case Rep J* 2016; 3: 202–204
- [4] Ravaud S, Laurent V, Jausset F et al. CT and MR imaging features of fistulas from intraductal papillary mucinous neoplasms of the pancreas to adjacent organs: a retrospective study of 423 patients. *Eur J Radiol* 2015; 84: 2080–2088
- [5] Rosenberger LH, Stein LH, Witkiewicz AK et al. Intraductal papillary mucinous neoplasm (IPMN) with extra-pancreatic mucin: a case series and review of the literature. *J Gastrointest Surg* 2012; 16: 762–770

Acknowledgment

This work was supported by French state funds managed within the “Plan Investissements d’Avenir” and by the ANR (reference ANR-10-IAHU-02).

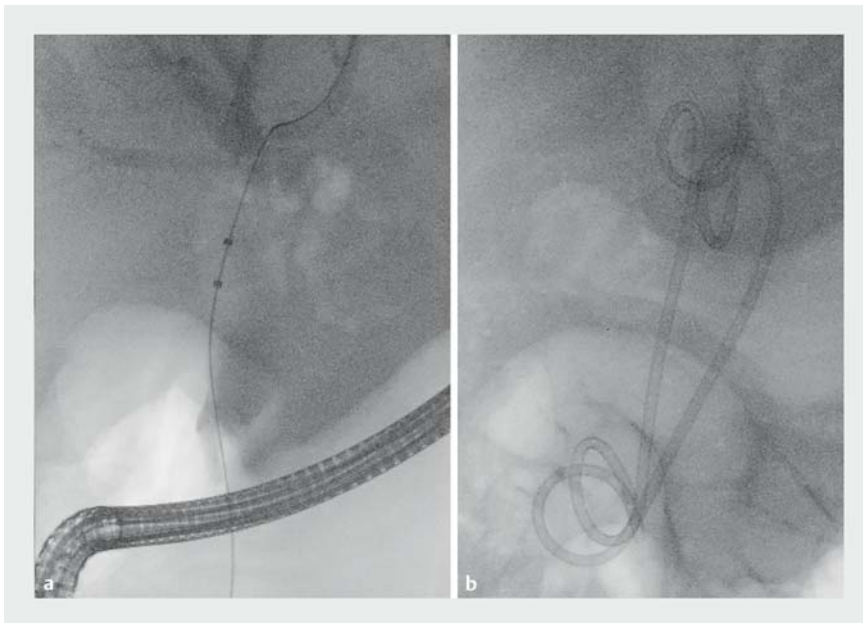This work has been published under the framework of the LABEX ANR-10-LABX-0028_HEPSYS and Inserm Plan Cancer and benefits from funding from the state managed by the French National Research Agency as part of the Investments for the future program.

Funding

Agence Nationale de la Recherche
<http://dx.doi.org/10.13039/501100001665>
 ANR-10-IAHU-02

Competing interests

The authors declare that they have no conflict of interest.



► **Fig. 3** Endoscopic retrograde cholangiopancreatography. **a** Dilatation of the intrahepatic bile ducts. **b** Two double-pigtail plastic stents were placed to provide biliary drainage.

Bibliography

Endoscopy 2023; 55: E39–E41

DOI 10.1055/a-1930-5917

ISSN 0013-726X

published online 22.9.2022

© 2022. The Author(s).

This is an open access article published by Thieme under the terms of the Creative Commons Attribution-NonDerivative-NonCommercial License, permitting copying and reproduction so long as the original work is given appropriate credit. Contents may not be used for commercial purposes, or adapted, remixed, transformed or built upon. (<https://creativecommons.org/licenses/by-nc-nd/4.0/>)

Georg Thieme Verlag KG, Rüdigerstraße 14, 70469 Stuttgart, Germany



ENDOSCOPY E-VIDEOS

<https://eref.thieme.de/e-videos>



Endoscopy E-Videos is an open access online section, reporting on interesting cases and new techniques in gastroenterological endoscopy. All papers include a high quality video and all contributions are freely accessible online. Processing charges apply (currently EUR 375), discounts and waivers acc. to HINARI are available.

This section has its own submission website at <https://mc.manuscriptcentral.com/e-videos>