



HAL
open science

Muscle damage after neuromuscular electrostimulation assessed by multimodal magnetic resonance imaging

Alexandre Fouré, Arnaud Le Troter, Guillaume Duhamel, Christophe Vilmen,
Marc Jubeau, Jennifer Wegrzyk, Jean-Pierre Mattei, Kazunori Nosaka,
Bendahan David, Julien Gondin

► To cite this version:

Alexandre Fouré, Arnaud Le Troter, Guillaume Duhamel, Christophe Vilmen, Marc Jubeau, et al..
Muscle damage after neuromuscular electrostimulation assessed by multimodal magnetic resonance
imaging. 42nd European Muscle Conference (EMC), Sep 2013, Amsterdam, Netherlands. hal-
04080389

HAL Id: hal-04080389

<https://hal.science/hal-04080389>

Submitted on 27 Apr 2023

HAL is a multi-disciplinary open access archive for the deposit and dissemination of scientific research documents, whether they are published or not. The documents may come from teaching and research institutions in France or abroad, or from public or private research centers.

L'archive ouverte pluridisciplinaire **HAL**, est destinée au dépôt et à la diffusion de documents scientifiques de niveau recherche, publiés ou non, émanant des établissements d'enseignement et de recherche français ou étrangers, des laboratoires publics ou privés.

Fouré A¹, Le Troter A¹, Duhamel G¹, Vilmen C¹, Jubeau M², Wegrzyk J¹, Mattei JP^{1,3}, Nosaka K⁴, Bendahan D¹, Gondin J¹

¹Aix-Marseille University, CNRS, CRMBM UMR CNRS 7339, 13385, Marseille, France

²University of Nantes, Laboratory "Motricité, Interactions, Performance" (EA 4334), UFR STAPS, 44000, Nantes, FRANCE

³APHM, Hôpitaux de la Timone, CEMEREM, 13385, Marseille, France

⁴Edith Cowan University, School of Exercise and Health Sciences, WA 6027, Joondalup, AUSTRALIA

Introduction

Neuromuscular electrostimulation (NMES) is useful for improving muscle function. However, it has been reported that NMES-induced muscle damage is mainly due to the specificity of motor unit recruitment (i.e., non-selective, spatially fixed, synchronous and mainly superficial). Moreover, it is documented that NMES results in a preferential activation of muscle fibers beneath and close to the stimulating electrodes (1), so that one could expect heterogeneous damage between directly and indirectly stimulated muscles.

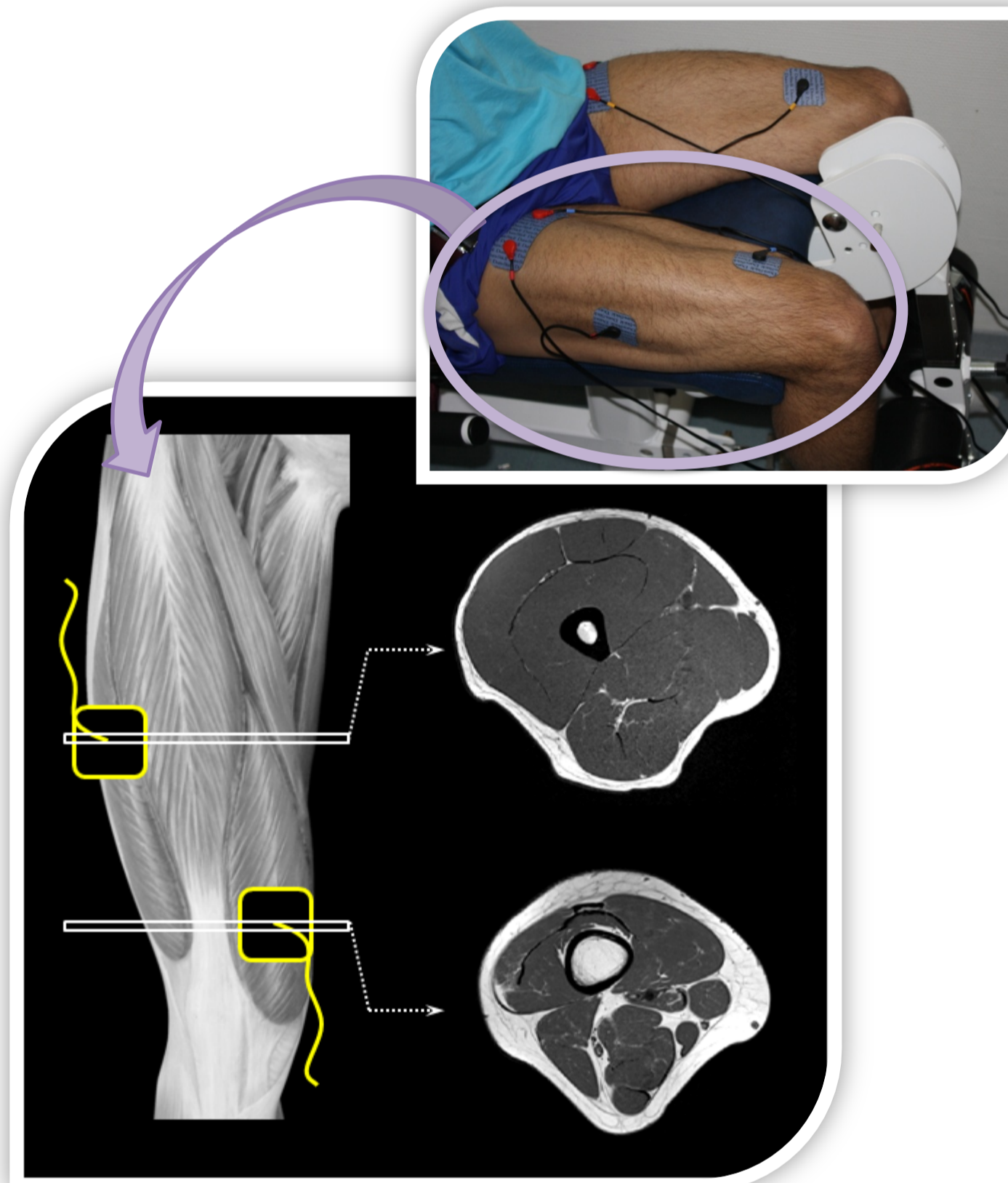
The present study aimed to test the hypothesis that NMES-induced muscle damage would be different between directly and indirectly stimulated muscles of the knee extensors using multimodal magnetic resonance imaging (MRI) including T₂ mapping and diffusion tensor imaging (DTI).

Methods

Twenty-five young male subjects took part in a single bout of NMES with the electrodes being placed over the belly of *vastus lateralis* (VL) and *vastus medialis* (VM, Figure 1).

NMES session consisted in 40 isometric contractions (5s on and 15s off) evoked with pulses delivered at 75Hz (pulse duration of 400μs). Intensity was increased until maximally tolerable level.

Figure 1: Subject position during the NMES session (Top) with electrodes (in black and yellow) placed on vastus lateralis and medialis (Bottom). Axial slices were obtained for proximal and distal part of thigh muscles corresponding to the electrodes' placement.



MRI parameters were assessed before and 4 days after the NMES session using a 1.5T scanner (Siemens® Avanto, Erlangen).

T₂ mapping: TR = 4800ms; TE = 15/25/35/45/55ms; 20 slices; thickness = 6mm.

DTI : TR = 5000ms; TE = 53ms; 12 directions; b-values = 0 and 500s/mm².

Mean T₂ values, radial diffusion (λ_3) and fractional anisotropy (FA) were determined in VL, VM, *vastus intermedius* (VI) and *rectus femoris* (RF) muscles.

Results

Mean increases in T₂ (Figure 2-A) were larger for the VL (+19.5%) and VM (+6.7%) when compared with the VI (+4.3%) and RF (+2.9%).

Significant increases in λ_3 for VL, VM and VI (+7.3%, +3.7% and +2.3% respectively, Figure 2-B) and a decrease in FA only for VL (-7.0%, Figure 2-C) were observed (P < 0.05).

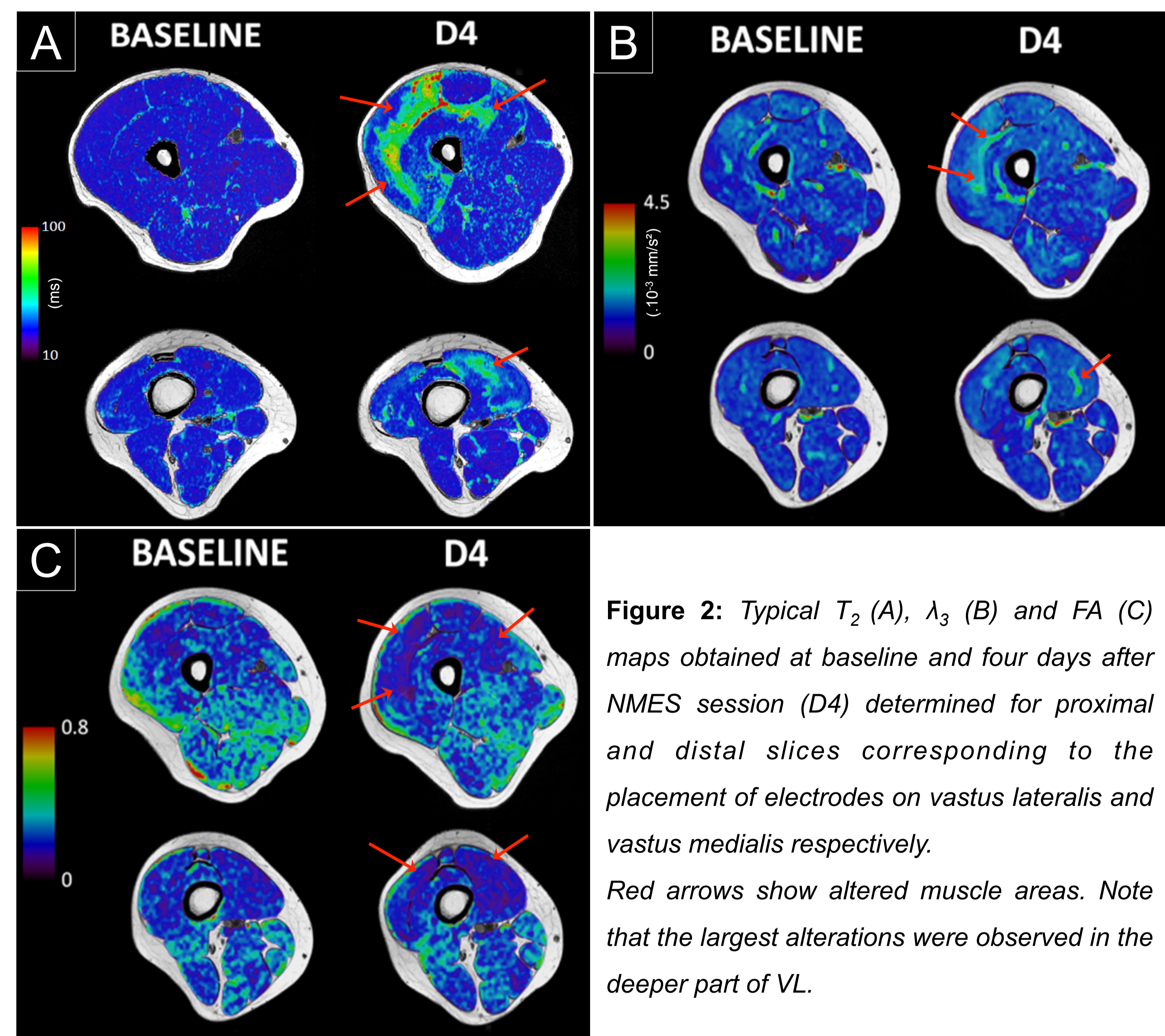


Figure 2: Typical T₂ (A), λ_3 (B) and FA (C) maps obtained at baseline and four days after NMES session (D4) determined for proximal and distal slices corresponding to the placement of electrodes on vastus lateralis and vastus medialis respectively. Red arrows show altered muscle areas. Note that the largest alterations were observed in the deeper part of VL.

Conclusion

MRI parameters were largely and heterogeneously affected as a result of a single NMES session, thereby clearly illustrating major muscle alterations. The extent of muscle damage was greater for muscles beneath stimulation electrodes which is consistent with the spatial distribution of blood flow in directly stimulated muscles (3).

Interestingly, the largest alterations were found in the deeper part of VL. This unexpected result might be related to the activation of deep intramuscular nerve branches and/or shear stress between muscles leading to inflammation of connective tissues (4).

Finally, the extent of changes varied between T₂ and DTI metrics, indicating that the corresponding indices likely reflect different physiological processes and highlighting the relevance of multimodal MRI for monitoring *in vivo* skeletal muscle injury.

(1)Maffiuletti NA (2010). Eur J Appl Physiol, 110:223-234.

(2)Heemskerk AM et al. (2006). Magn Reson Med, 56:272-281.

(3)Vanderthommen M et al. (2000). Muscle Nerve, 23:482-489.

(4)Mackey AL et al. (2011). FASEB J, 25:1943-1959.