



**HAL**  
open science

## Inferior mesenteric artery embolization ahead of rectal cancer surgery: AMIREMBOL pilot study

Julien Frandon, Laure Berny, Michel Prudhomme, H el ene de Forges, Chris Serrand, Fabien de Oliveira, Jean-Paul Beregi, Martin Bertrand

### ► To cite this version:

Julien Frandon, Laure Berny, Michel Prudhomme, H el ene de Forges, Chris Serrand, et al.. Inferior mesenteric artery embolization ahead of rectal cancer surgery: AMIREMBOL pilot study. *British Journal of Surgery*, 2022, 10.1093/bjs/znac071 . hal-04079880

**HAL Id: hal-04079880**

**<https://hal.science/hal-04079880v1>**

Submitted on 24 Apr 2023

**HAL** is a multi-disciplinary open access archive for the deposit and dissemination of scientific research documents, whether they are published or not. The documents may come from teaching and research institutions in France or abroad, or from public or private research centers.

L'archive ouverte pluridisciplinaire **HAL**, est destin ee au d ep ot et  a la diffusion de documents scientifiques de niveau recherche, publi es ou non,  emanant des  tablissements d'enseignement et de recherche franais ou  trangers, des laboratoires publics ou priv es.



Distributed under a Creative Commons Attribution 4.0 International License

# Inferior mesenteric artery embolization ahead of rectal cancer surgery: AMIREMBOL pilot study

Julien Frandon<sup>1,\*</sup>, Laure Berny<sup>1</sup>, Michel Prudhomme<sup>2</sup>, H el ene de Forges<sup>1</sup>, Chris Serrand<sup>3</sup>, Fabien de Oliveira<sup>1</sup>, Jean-Paul Beregi<sup>1</sup> and Martin M. Bertrand<sup>2</sup>

<sup>1</sup>Department of Medical Imaging, N imes University Hospital, University of Montpellier, Medical Imaging Group N imes (IMAGINE), N imes, France

<sup>2</sup>Surgery Department, N imes University Hospital, University of Montpellier, N imes, France

<sup>3</sup>Department of Biostatistics, Clinical Epidemiology, Public Health, and Innovation in Methodology (BESPIM), CHU N imes, N imes, France

\*Correspondence to: Julien Frandon, CHU de N imes, Medical Imaging Group N imes, IMAGINE team, Place du Professeur Robert Debr e, 30029 N imes Cedex 9, France (e-mail: jfrandon38@gmail.com)

## Introduction

Anastomotic leak is a common and feared complication of rectal cancer surgery<sup>1</sup>. It is recognized that good perfusion of the colonic conduit used for the anastomosis is important to reduce the risk of leakage<sup>2,3</sup>. Undertaken a few days before surgery, ischaemic conditioning involves embolizing the vessels planned for ligation during the operation, thereby promoting arterial collateral vessel formation. It has been shown to reduce anastomotic leak rates in oesophageal cancer surgery<sup>4–6</sup>. Advances in endovascular surgery mean that embolization of the inferior mesenteric artery (IMA) to prevent aneurysm endoleaks is feasible and safe<sup>7,8</sup>. The aims of this study were, therefore, to assess the feasibility and safety of IMA ischaemic preconditioning in patients with rectal or sigmoid cancer undergoing surgery, and to evaluate its effect on colonic perfusion.

## Methods

### Patients and study design

Patients aged over 18 years undergoing surgery for rectal or sigmoid cancer were included in this prospective single-centre study. The exclusion criteria were contraindications to surgery or arteriography, superior mesenteric artery (SMA) abnormality or IMA occlusion. The study was approved by an ethical review board (ID RCB 2017-A03527-46, CPP Sud-M editerran ee II) and registered at ClinicalTrials.gov (NCT0362824). All patients provided signed informed consent. Patients were randomized into two groups to receive either plain arteriography (control group) or endovascular IMA embolization (embolization group). Randomization in a 1 : 1 ratio was performed using SAS<sup> </sup> software version 9.2 (SAS Institute, Cary, NC, USA). Patients and surgeons were blinded to the procedure.

## Technical description

### Arteriography and embolization

Arteriography was performed 3 weeks before surgery by an interventional radiologist with a classical femoral common 4-Fr puncture under local anaesthesia. SMA and IMA diagnostic arteriography was carried out. In the embolization group, the

proximal IMA was embolized using coils or plugs to obtain complete IMA occlusion; details are provided in the [supplementary material](#).

## Surgery

All patients underwent low anterior resection or sigmoid resection with high-tie IMA ligation by a laparoscopic or robot-assisted approach. The resistive index (RI) was used to assess tissue hypoperfusion<sup>9</sup>, and was measured during surgery with an ultrasound probe placed directly on the mesocolon (LA3-16 AD transducer with a Samsung Medison HM70A<sup>TM</sup> ultrasound system, Seoul, Korea). Systemic arterial BP was recorded before and after IMA ligation.

## Endpoints

The primary endpoint was intraoperative colonic perfusion measured by the RI ((peak systolic velocity – end diastolic velocity)/peak systolic velocity) of the arc of Riolan in the mesocolon, before, immediately after, and 5 min after ligation. After visualization of the arc, several RI measurements were taken until a stable and reproducible tracing was obtained before ligation of the artery. Secondary endpoints were early postembolization complications, assessed during a telephone call on day 5, and surgical complications until hospital discharge graded according to the Clavien–Dindo classification.

## Statistical analysis

Continuous variables are presented as median (range). Values were compared using the Fisher's exact or Mann–Whitney *U* test. *P* < 0.050 was considered significant.

## Results

### Patients and procedure

From March 2020 to March 2021, 10 patients, of median age 72 (range 53–79) years, were included, with five patients in each group ([Table 1](#)). Embolization was successful in all five patients, with complete IMA occlusion achieved.

Received: November 02, 2021. Revised: December 22, 2021. Accepted: February 19, 2022

  The Author(s) 2022. Published by Oxford University Press on behalf of BJS Society Ltd.

This is an Open Access article distributed under the terms of the Creative Commons Attribution License (<https://creativecommons.org/licenses/by/4.0/>), which permits unrestricted reuse, distribution, and reproduction in any medium, provided the original work is properly cited.

Table 1 Patient characteristics and resistive index results

	Embolization group (n = 5)	Control group (n = 5)	P§
Age (years)*	70 (53–71)	74 (63–79)	
Sex			
M	2	4	
F	3	1	
BMI (kg/m <sup>2</sup> )*	26 (19–31)	23 (21–28)	
Cardiovascular risk factors†	4	4	
Tumour location			
Rectum	5	4	
Sigmoid	0	1	
Preoperative CRT	4	3	
Procedure duration (min)*	37 (26–72)	13 (4–19)	
Radiation dose (DAP) (mGy/cm <sup>2</sup> )*	281 (120–833)	347 (139–660)	
Duration of hospital stay (nights)*	10 (5–17)	6 (4–25)	
Resistive index*			
Before ligation	0.87 (0.48–0.89)	0.83 (0.71–0.84)	0.53
Immediately after ligation	0.84 (0.37–0.9)	0.5 (0.42–0.75)	0.22
Drop immediately after ligation (%)‡	5.6 (3.4–22.9)	39.0 (9.6–47.0)	0.03
5 min after ligation	0.85 (0.43–0.9)	0.5 (0.45–0.76)	0.22
Drop at 5 min (%)‡	4.5 (1.15–16.7)	36.6 (8.4–42.7)	0.03
Systemic arterial BP (mmHg)*			
Before ligation	76.33 (70.67–87.33)	72.33 (65.00–102.00)	0.83
Immediately after ligation	87.67 (79.33–99.67)	96.67 (69.33–99.67)	0.92
5 min after ligation	75.00 (71.67–90.67)	90.00 (67.00–90.67)	0.83

BMI: Body Mass Index; RI: Resistive Index.

\*Values are median (range). †Arterial hypertension, diabetes, active tobacco use, hypercholesterolaemia, dyslipidaemia, sedentary lifestyle, personal cardiovascular history, family history of cardiovascular disease. ‡Compared with baseline, before ligation. CRT, chemoradiotherapy; DAP, dose area product. §Mann-Whitney U test.

## Colonic perfusion

RI measurement was feasible in all patients. There was a drop in RI immediately after IMA ligation of 39.0 (range 9.6–47.0) per cent in the control group versus 5.6 (3.4–22.9) per cent in the embolization group ( $P=0.032$ ) (Table 1 and Fig 1). This decrease was maintained 5 min after ligation. The arterial BP was similar in the two groups at all times.

## Complications

After arteriography and embolization, no major complications were reported. Minor complications occurred after arteriography in one patient, who developed a localized haematoma at the puncture site. Two patients reported abdominal pain (Clavien-Dindo grade I) 2 days after embolization; both required an analgesia

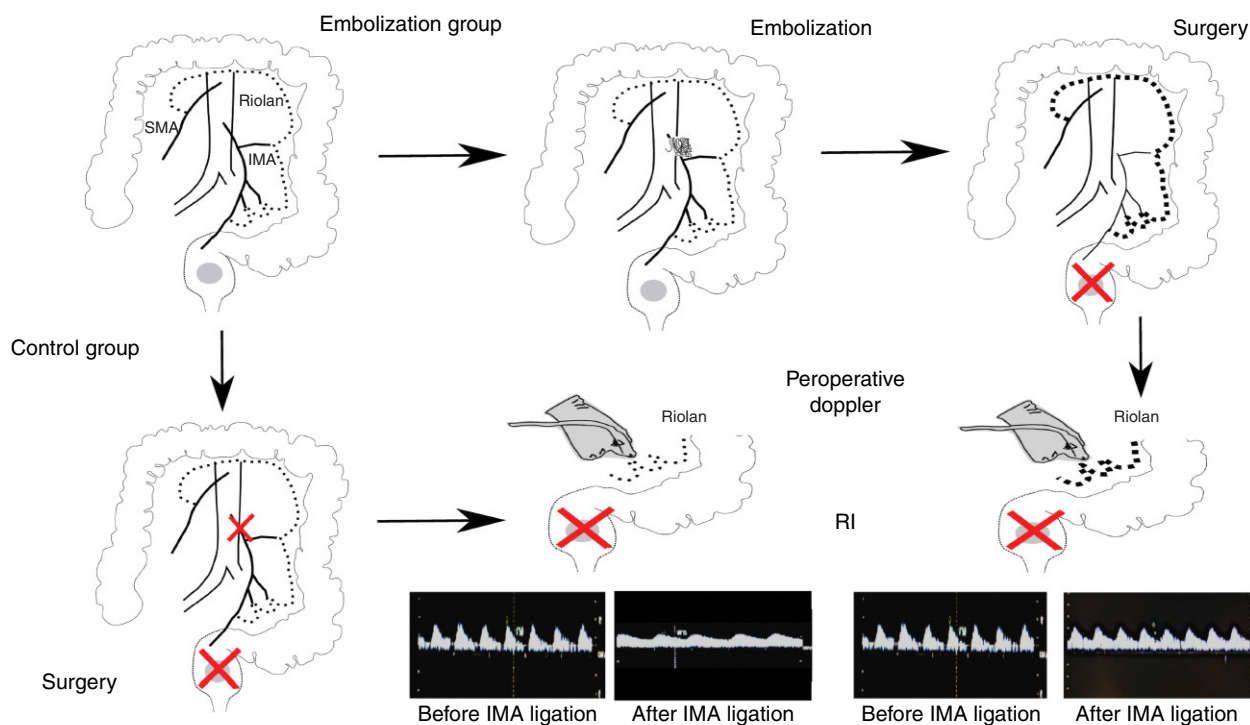


Fig. 1 Study protocol

In the embolization group, proximal embolization of the inferior mesenteric artery (IMA) (centre top, with the coil in the proximal part of the IMA) was performed 3 weeks before surgery to potentially allow the arc of Riolan (Riolan) to promote arterial collateral vessel formation (bold dotted line). In the control group, plain arteriography was performed but without IMA embolization. Intraoperative Doppler imaging was undertaken directly on the mesocolon and on the arc of Riolan in both groups, and the resistive index (RI) was measured just before surgical ligation (red cross) of the IMA, and at 1 and 5 min after ligation. SMA, superior mesenteric artery.

prescription but did not require radiological or surgical intervention and the pain settled spontaneously. After surgery, one patient in the control group sustained an anastomotic leak on day 4 which required a second procedure and longer hospital stay (25 days).

## Discussion

This single-centre randomized study has demonstrated that ischaemic conditioning by preoperative IMA embolization in patients scheduled for surgery to treat rectal or sigmoid cancer is feasible and safe. Improved perfusion in the colonic conduit used for anastomosis was seen in patients who underwent IMA embolization.

The RI is a sonographic index that indicates arterial resistance to flow. It is a common non-invasive tool used to evaluate hepatic<sup>10</sup> and renal<sup>11</sup> perfusion. A decrease in RI indicates hypoperfusion in relation to a significant vascular stenosis or occlusion. In this study, the absence of a decrease in RI values in the embolized group reflected the development of vascular collaterality. Other techniques, such as laser Doppler flowmetry<sup>12</sup> and transanal pulse oximetry<sup>13</sup>, have revealed a similar decrease in colonic blood flow after IMA ligation.

Whether to perform high or low tie of the IMA during left-sided/rectal cancer surgery is debated<sup>14</sup>. In the present study, a high tie was chosen according to the surgical team's usual clinical practice. Embolization was carried out 3 weeks ahead of surgery; this interval was thought to allow effective preconditioning as previous clinical and experimental studies<sup>15,16</sup> have shown poorer results with a shorter delay.

The present study has some limitations, including its single-centre pilot design and small size. In addition, follow-up was short and oncological efficacy was not assessed. However, these promising early results should be evaluated in larger multicentre studies that assess the impact of ischaemic preconditioning on the occurrence of postoperative anastomotic leakage.

## Funding

The study was funded by a Nîmes University Hospital internal call for projects funding.

**Disclosure.** The authors declare no conflict of interest.

## Supplementary material

[Supplementary material](#) is available at *BJS Open* online.

## References

- Snijders HS, Wouters MWJM, van Leersum NJ, Kolfschoten NE, Henneman D, de Vries AC *et al.* Meta-analysis of the risk for anastomotic leakage, the postoperative mortality caused by leakage in relation to the overall postoperative mortality. *Eur J Surg Oncol* 2012;**38**:1013–1019
- Sciuto A, Merola G, De Palma GD, Sodo M, Pirozzi F, Bracale UM *et al.* Predictive factors for anastomotic leakage after laparoscopic colorectal surgery. *World J Gastroenterol* 2018;**24**:2247–2260
- Li Z, Zhou Y, Tian G, Liu Y, Jiang Y, Li X *et al.* Meta-analysis on the efficacy of indocyanine green fluorescence angiography for reduction of anastomotic leakage after rectal cancer surgery. *Am Surg* 2021;**87**:1910–1919
- Ghelfi J, Brichon PY, Frandon J, Boussat B, Bricault I, Ferretti G *et al.* Ischemic gastric conditioning by preoperative arterial embolization before oncologic esophagectomy: a single-center experience. *Cardiovasc Intervent Radiol* 2017;**40**:712–720
- Michalinos A, Antoniou SA, Ntourakis D, Schizas D, Ekmektzoglou K, Angouridis A *et al.* Gastric ischemic preconditioning may reduce the incidence and severity of anastomotic leakage after oesophagectomy: a systematic review and meta-analysis. *Dis Esophagus* 2020;**33**:doaa010
- Pham TH, Melton SD, McLaren PJ, Mokdad AA, Huerta S, Wang DH *et al.* Laparoscopic ischemic conditioning of the stomach increases neovascularization of the gastric conduit in patients undergoing esophagectomy for cancer. *J Surg Oncol* 2017;**116**:391–397
- Petit P, Hertault A, Mesnard T, Bianchini A, Lopez B, Patterson BO *et al.* Outcomes of Preventive embolization of the inferior mesenteric artery during endovascular abdominal aortic aneurysm repair. *J Vasc Interv Radiol* 2021;**32**:1360.e2–1370.e2
- Etz CD, Debus ES, Mohr FW, Kölbl T. First-in-man endovascular preconditioning of the paraspinal collateral network by segmental artery coil embolization to prevent ischemic spinal cord injury. *J Thorac Cardiovasc Surg* 2015;**149**:1074–1079
- Anile A, Ferrario S, Campanello L, Orban MA, Castiglione G. Renal resistive index: a new reversible tool for the early diagnosis and evaluation of organ perfusion in critically ill patients: a case report. *Ultrasound J* 2019;**11**:23
- Dodd GD, Memel DS, Zajko AB, Baron RL, Santaguida LA. Hepatic artery stenosis and thrombosis in transplant recipients: Doppler diagnosis with resistive index and systolic acceleration time. *Radiology* 1994;**192**:657–661
- Radermacher J, Mengel M, Ellis S, Stuhrt S, Hiss M, Schwarz A *et al.* The renal arterial resistance index and renal allograft survival. *N Engl J Med* 2003;**349**:115–124
- Seike K, Koda K, Saito N, Oda K, Kosugi C, Shimizu K *et al.* Laser Doppler assessment of the influence of division at the root of the inferior mesenteric artery on anastomotic blood flow in recto-sigmoid cancer surgery. *Int J Colorectal Dis* 2007;**22**:689–697
- Gardner GP, LaMorte WW, Obi-Tabot ET, Menzoian JO. Transanal intracolonic pulse oximetry as a means of monitoring the adequacy of colonic perfusion. *J Surg Res* 1994;**57**:537–540
- Hajibandeh S, Hajibandeh S, Maw A. Meta-analysis and trial sequential analysis of randomized controlled trials comparing high and low ligation of the inferior mesenteric artery in rectal cancer surgery. *Dis Colon Rectum* 2020;**63**:988–999
- Prochazka V, Marek F, Kunovsky L, Svaton R, Grolich T, Moravcik P *et al.* Comparison of cervical anastomotic leak and stenosis after oesophagectomy for carcinoma according to the interval of the stomach ischaemic conditioning. *Ann R Coll Surg Engl* 2018;**100**:509–514
- Perry KA, Banarjee A, Liu J, Shah N, Wendling MR, Melvin WS. Gastric ischemic conditioning increases neovascularization and reduces inflammation and fibrosis during gastroesophageal anastomotic healing. *Surg Endosc* 2013;**27**:753–760