



**HAL**  
open science

## Case Report on Ectopic Third Molar in Maxillary Sinus

sghaier jihed, Abdellatif Chokri, Hend Ouertani, Hela Jegham, Mohamed Bassem Khattech, Jamil Selmi

► **To cite this version:**

sghaier jihed, Abdellatif Chokri, Hend Ouertani, Hela Jegham, Mohamed Bassem Khattech, et al.. Case Report on Ectopic Third Molar in Maxillary Sinus. international journal of research and reports in dentistry, 2023, 6 (2), pp.39-43. <hal-04078460>

**HAL Id: hal-04078460**

**<https://hal.science/hal-04078460v1>**

Submitted on 23 Apr 2023

**HAL** is a multi-disciplinary open access archive for the deposit and dissemination of scientific research documents, whether they are published or not. The documents may come from teaching and research institutions in France or abroad, or from public or private research centers.

L'archive ouverte pluridisciplinaire **HAL**, est destinée au dépôt et à la diffusion de documents scientifiques de niveau recherche, publiés ou non, émanant des établissements d'enseignement et de recherche français ou étrangers, des laboratoires publics ou privés.



HAL Authorization



# Case Report on Ectopic Third Molar in Maxillary Sinus

**Sghaier Jihed<sup>a\*</sup>, Abdellatif Chokri<sup>b</sup>, Hend Ouertani<sup>a</sup>,  
Hela Jegham<sup>a</sup>, Mohamed Bassem Khattech<sup>a</sup>  
and Jamil Selmi<sup>b</sup>**

<sup>a</sup> *Military Hospital of Tunisia, Mont-Fleury 1008 Tunis, Tunisia.*

<sup>b</sup> *Department of Medicine and Oral Surgery, University Dental Clinic, Monastir, Tunisia.*

## **Authors' contributions**

*All authors have read and agreed to the final version of this manuscript and have equally contributed to its content and to the management of the cases.*

## **Article Information**

### **Open Peer Review History:**

This journal follows the Advanced Open Peer Review policy. Identity of the Reviewers, Editor(s) and additional Reviewers, peer review comments, different versions of the manuscript, comments of the editors, etc are available here: <https://www.sdiarticle5.com/review-history/98885>

**Case Report**

**Received: 12/02/2023**

**Accepted: 15/04/2023**

**Published: 22/04/2023**

## **ABSTRACT**

Ectopic tooth in the maxillary sinus is a rare occurrence. There are multiple etiologies of this condition, including developmental disruption, pathological process, iatrogenic, and in rare cases no recognized reason.

Ectopic teeth in the maxillary sinus are noticed by accident during routine radiological examinations. A 38-year-old married female reported to the Department of oral medicine and oral surgery at the University Dental Clinic of Monastir-Tunisia. She has been experiencing pain in the left side of the face and a chronic headache for two months.

Orthopantomography and computed tomography are used to identify the existence of an ectopic tooth within the left maxillary sinus.

The Modified Caldwell-Luc Technique was executed to remove the tooth.

The patient remained free of the presenting symptoms three months later.

Although the existence of an ectopic tooth in the maxillary sinus is rare, it should be evaluated and detected as soon as possible. An ectopic tooth in the maxillary sinus needs to be extracted since it might cause cyst development if left untreated. The modified Caldwell-Luc method, which offers a clear view into the maxillary sinus, is the standard approach.

\*Corresponding author: Email: [sghaier.jihed25@gmail.com](mailto:sghaier.jihed25@gmail.com);

**Keywords:** Third tooth; intrasinusal; modified Caldwell-Luc; ectopic; maxilla.

## ABBREVIATIONS

CBCT : Cone Beam Computed Tomography

EMTM : Ectopic Maxillary Third Molars

## 1. INTRODUCTION

Ectopic tooth eruption inside the dentate area of the jaws is common in clinical practice and extensively described in the literature. Nevertheless, ectopic eruptions into the nondentate area are uncommon and infrequently reported [1].

Although a panoramic radiograph is the standard diagnostic radiographic examination for this type of accident, cone beam computed tomography (CBCT) is highly advised for further localization of the ectopic tooth and evaluation of the particulars of any related lesion before operation [2].

Developmental abnormalities such as cleft palate, trauma or odontogenic infection, hereditary variables, and crowding or dentigerous cysts associated with impacted teeth are suggested etiologies [3].

## 2. CASE REPORT

A 38-year-old female reported to the Department of oral medicine and oral surgery at the University Dental Clinic of Monastir-Tunisia. She has been experiencing pain in the left side of her face for the two last months. She had a history of two courses of antibiotics recommended by her doctor, but she had no long-term relief. As a result, she was referred to our center for better management.

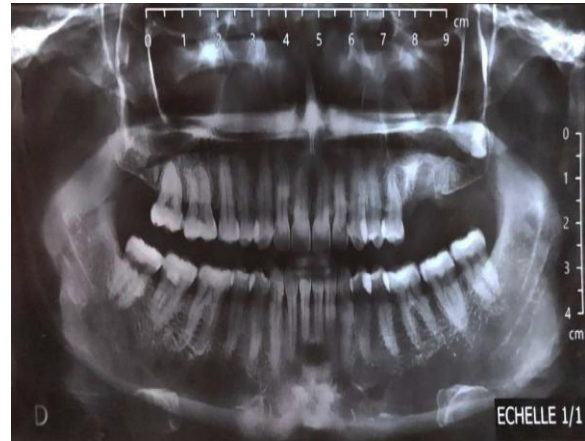On clinical examination, there was no intraoral or extraoral swelling, and there was a partial terminal edentulousness with the absence of the first, second, and third left maxillary molars.

All teeth were vital and free of decay in the left maxillary region.

A panoramic radiograph showed that the left maxillary third tooth was erupting in the maxillary sinus (Fig. 1).

A second radiographic scan, this time using cone beam computed tomography (CBCT), revealed

the precise site of the third maxillary molar. CBCT showed the ectopic third molar located in the posteroinferior aspect of the sinus deported on the palatal side and in a horizontal position with a close approximation to the lateral wall of the sinus (Fig. 2a, Fig. 2b).



**Fig. 1. Preoperative panoramic radiograph of an ectopic eruption of the left maxillary third molar into the left maxillary sinus**

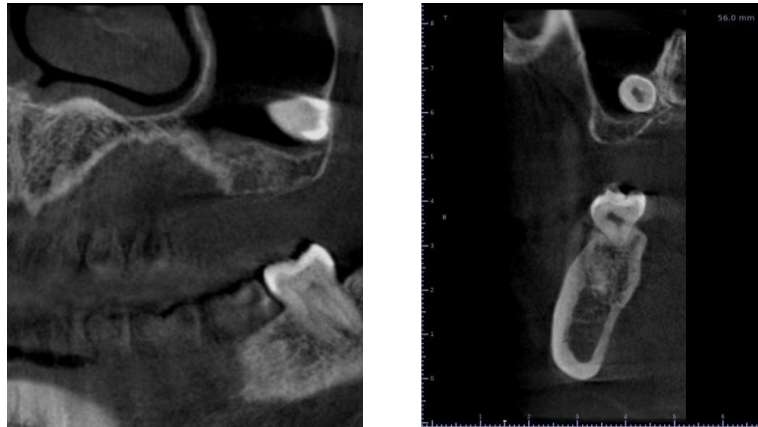
The ectopic tooth morphology indicated a typical shape and size, as well as full root development. There were no radiological or clinical pathologies associated with the tooth. There were no signs of chronic sinusitis like mucosal thickening owing to the impacted tooth.

Based on the clinical and radiographic evaluation, the tooth was removed through the Modified Caldwell-Luc procedure.

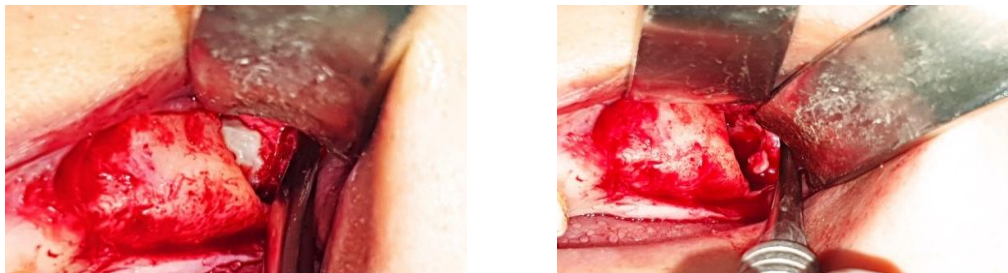
A second-year resident in Oral surgery, and oral medicine under the supervision of a university hospital professor at the Faculty of dental medicine of Monastir, Tunisia, utilizing a modified Caldwell-Luc approach, with a bony window created in the posterolateral wall of the maxillary sinus (Fig. 3a, Fig. 3b).

The surgery begun with the administration of local anesthesia. A crestal incision was made from the distal side of the second premolar to the tuberosity region followed by a mesial discharge incision and a mucoperiosteal flap was elevated.

A bone window was created by a round bur with intense irrigation.



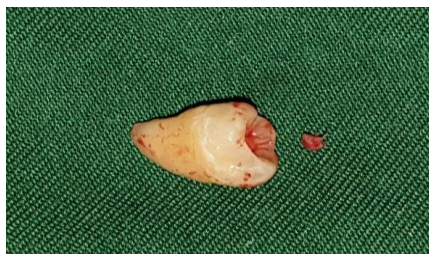**Fig. 2. Multiplanar Cone beam computed tomography (CBCT) sections: (a) coronal slices; (b) sagittal: illustrating the posteroinferior location of the ectopic left third maxillary molar inside the maxillary sinus**



**Fig. 3. Perioperative view of the bony window created in the sinus's anterior wall**

The ectopic tooth was found and extracted after light milling around the tooth (Fig. 4).

The left maxillary sinus was thoroughly irrigated with normal saline. The mucoperiosteal flap was repositioned and sutured.



**Fig. 4. Tooth after the operation**

The patient was given postoperative antibiotics in the form of 1000 mg of amoxicillin 2 times daily for seven days with an analgesic (500 mg of paracetamol every four hours per day), Nasonex spray 4 times daily, chlorohexidine mouthwash, as well as two doses of Dexamethasone 8 mg to prevent postoperative edema, and she was warned not to blow her nose for ten days.

Sutures were removed 10 days after surgery, and the surgical site was completely healed without any issues.

Three months following the procedure, a panoramic radiograph and CBCT were taken. The patient remained free of the presenting symptoms.

### 3. DISCUSSION

Tooth formation is the consequence of an interaction between the oral epithelium and the underlying mesenchymal tissue [4]. The formation of maxillary and mandibular dental lamina in the area of the future alveolar process begins in the sixth week of pregnancy. During the 5th and 10th months, the ectodermal derivative mostly undergoes proliferation to produce permanent dentition [5]. Ectopic tooth growth and eruption can originate from any aberrant tissue contact during odontogenesis [6].

According to the most recent analysis of the literature, 51 patients were observed to have ectopic teeth in the maxillary sinus, with third

molars having the highest frequency of ectopic teeth (21 cases) [6].

The ectopic eruption in the maxillary sinus can induce sinonasal symptoms, most commonly due to recurrent or chronic sinusitis, or it can cause ocular problems [7]. A headache, face discomfort, edema, nasal blockage, nasal discharge, epiphora, rhinorrhea, hyposmia, and orbital proptosis are among the symptoms. On the other hand, some asymptomatic instances may be identified by chance without any symptoms [8].

The CBCT which was intended for implant dentistry is beneficial for detecting jaw abnormality and pathology.

It allows you to see the maxilla and mandible in three planes: panoramic, axial, and cross-sectional [9].

Additionally, the closeness of the tooth to the sinus wall may be recognized and properly measured. If there is already a ruptured cortical bone in the sinus wall, it should be taken into surgical consideration to minimize needless bone loss [8].

With a lower patient dosage than a CT scan, CBCT allows a three-dimensional examination of the maxillary sinus. As a result, it can be an effective replacement for detecting and treating ectopic tooth eruptions in the maxillary sinus.

If an ectopic tooth in the maxillary sinus is not removed surgically, it will most likely develop into a cyst or tumor if left untreated [10].

There are presently two effective surgical treatments for EMTM: the Caldwell-Luc method and nasal endoscopy. Patients who are symptomatic or asymptomatic with an accompanying cyst are candidates for EMTM avulsion.

But, the standard Caldwell-Luc method was established for removing a foreign body from the maxillary sinus; the most common problems related to this procedure include facial edema, infraorbital paraesthesia, and loss of tooth vitality [11].

An inferior meatal antrostomy is done in the usual Caldwell-Luc technique to improve sinus drainage. Nevertheless, inferior meatal antrostomy has significant disadvantages, including increased operating time, the danger of

nasolacrimal duct injury, and early closure of the orifice [12].

That's why, the modified Caldwell-Luc procedure without inferior meatal antrostomy was favored over the usual technique in this patient.

The modified Caldwell-Luc technique is used effectively in the retrieval of an ectopic tooth from the maxillary sinus. It is related to less postoperative pain and fewer complications [13].

Alternative surgical techniques, including endoscopic surgery, enucleation, and marsupialization, are employed less frequently for this problem. Regular follow-ups have been suggested in certain asymptomatic instances [14].

#### **4. CONCLUSION**

A third molar eruption in the maxillary sinus is highly uncommon. CBCT is quite useful for visualizing and managing teeth in the maxillary sinus.

The cause of ectopic eruption is still undetermined and several theories have been proposed including trauma, infection, crowding, and developmental anomalies.

The most common treatment for ectopic teeth in the maxillary sinus is surgical extraction. Close radiological follow-up is recommended if the tooth is not extracted.

#### **CONSENT**

As per international standards or university standards, patient written consent has been collected and preserved by the authors.

#### **ETHICAL APPROVAL**

As per international standards or university standards written ethical approval has been collected and preserved by the authors.

#### **ACKNOWLEDGEMENTS**

Authors are grateful to the patients for their collaborations.

#### **COMPETING INTERESTS**

Authors have declared that no competing interests exist.

## REFERENCES

1. Ramanojam S, Halli R, Hebbale M, Bhardwaj S. Ectopic tooth sinus: In maxillary case series. *Ann. Maxillofac. Surg.* 2013;3(1):89–92.
2. Elmorsy K, Elsayed LK, El Khateeb SM. Case Report: Ectopic third molar in the maxillary sinus with infected dentigerous cyst assessed by cone beam CT. 2020; 9:209.  
Available: <https://f1000research.com/article/s/9-209-v2>  
Accessed on 25 March 2020.
3. Lombroni LG, Farronato G, Santamaria G, Lombroni DM, Gatti P, Capelli M. Ectopic teeth in the maxillary sinus: case report and literature review. *Indian Journal of Dental Research.* 2018;29(5):667.
4. Kayabasoglu G, Karaman M, Kaymaz R, Nacar A. A Rare entity causing chronic sinusitis: ectopic tooth in maxillary sinus. *European Journal of General Medicine.* 2015;12(1).
5. Bello SA, Oketade IO, Osunde OD. Ectopic 3rd molar tooth in the maxillary antrum. *Case Rep Dent.* 2014;2014: 620741.  
DOI: 10.1155/2014/620741  
PMID: 25132999 PMCID: PMC4123483  
Epub 2014 Jul 15.
6. Avery JK. Oral development and histology. 2nd ed. New York. Thieme Medical Publisher Inc.1994;70:92.
7. Findik Y, Baykul T. ECTOPIC third molar in the mandibular sigmoid notch: Report of a case and literature review. *J Clin Exp Dent.* 2015;7(1):133–137.
8. Mitra K, Mahnaz S. Ectopic third molar in maxillary sinus: An asymptomatic accidental finding. *The Egyptian Journal of Otolaryngology.* 2019;35:219–221.
9. Bodner L, Tovi F, Bar Ziv J. Teeth in the maxillary sinus – imaging and management. *The Journal of Laryngology & Otology.* 1997; 111(9):820-824  
DOI: 10.1017/S0022215100138721
10. Sheikhi M, Samandari M, Karbasi Kheir M, Moaddabi A. Multiple dentigerous cysts with a complex odontoma: an unusual case report. *Avicenna J Dent Res.* 2016;8(2): e26050.
11. Low WK. Complications of caldwell luc and how to avoid them. *Aus NZJ Surg.* 1995; 65:582–584.
12. Huang YC, Chen WH. Caldwell-Luc operation without inferior meatal antrostomy: a retrospective study of 50 cases. *J Oral Maxillofac Surg.* 2012;70: 2080–2084.
13. Asmael HM. The modified caldwell-luc approach in retrieval of accidentally displaced root into the maxillary sinus. *J Craniofac Surg.* 2018;29(2):e130-e131.  
DOI: 10.1097/SCS.0000000000004189  
PMID: 29194255
14. Kaan Beriat G, Çelebi Beriat C, Yalçinkaya E. Ectopic molar tooth in the maxillary sinus: A case report. *Clin Dent Res.* 2011;35:35–40.

© 2023 Jihed et al.; This is an Open Access article distributed under the terms of the Creative Commons Attribution License (<http://creativecommons.org/licenses/by/4.0>), which permits unrestricted use, distribution, and reproduction in any medium, provided the original work is properly cited.

*Peer-review history:*

*The peer review history for this paper can be accessed here:*  
<https://www.sdiarticle5.com/review-history/98885>