



HAL
open science

Liraglutide 3 mg as a weight-loss strategy after failed bariatric surgery in a patient with hypothalamic obesity following craniopharyngioma

M. Bretault, C. Carette, R. Zaharia, K. Vychnevskaja, J.-L. Bouillot, S. Czernichow, M.-L. Raffin-Sanson

► To cite this version:

M. Bretault, C. Carette, R. Zaharia, K. Vychnevskaja, J.-L. Bouillot, et al.. Liraglutide 3 mg as a weight-loss strategy after failed bariatric surgery in a patient with hypothalamic obesity following craniopharyngioma. *Diabetes & Metabolism*, 2020, 46 (6), pp.514-515. 10.1016/j.diabet.2019.07.004 . hal-04074618

HAL Id: hal-04074618

<https://hal.science/hal-04074618>

Submitted on 19 Apr 2023

HAL is a multi-disciplinary open access archive for the deposit and dissemination of scientific research documents, whether they are published or not. The documents may come from teaching and research institutions in France or abroad, or from public or private research centers.

L'archive ouverte pluridisciplinaire **HAL**, est destinée au dépôt et à la diffusion de documents scientifiques de niveau recherche, publiés ou non, émanant des établissements d'enseignement et de recherche français ou étrangers, des laboratoires publics ou privés.



Distributed under a Creative Commons Attribution - NonCommercial - NoDerivatives 4.0 International License

Liraglutide 3 mg as a weight-loss strategy after failed bariatric surgery in a patient with hypothalamic obesity following craniopharyngioma



ARTICLE INFO

Keywords:

Craniopharyngioma
Gastric bypass
Hypothalamic obesity
Glucagon-like peptide-1 analogue
Liraglutide

Hypothalamic obesity is a devastating consequence of craniopharyngioma that is frequently found to be worsened after neurosurgery and sometimes after radiotherapy, even when experienced neurosurgery teams have limited resection to preserve the hypothalamus. As the impact of lifestyle interventions is reported to be limited, bariatric surgery has been proposed as a therapeutic option, resulting in noticeable weight loss, although this is more modest than seen with the common causes of obesity [1]. However, the use of glucagon-like peptide (GLP)-1 analogues was recently reported in patients with hypothalamic obesity (HO) and type 2 diabetes mellitus (T2DM), with promising results on weight loss at dosages recommended for glycaemic control [2]. Here, we report on a patient with severe HO following craniopharyngioma who regained all lost weight 4 years after Roux-en-Y gastric bypass (RYGB) surgery, but who then lost > 30 kg under 3-mg liraglutide therapy.

A 19-year-old boy was referred to our adult nutrition university department. He had been diagnosed with craniopharyngioma at the age of 9 years. Cerebral magnetic resonance imaging (MRI) showed an intra- and suprasellar lesion compressing the optic nerves. The lesion was totally removed surgically although, subsequently, the patient suffered from bitemporal hemianopsia and panhypopituitarism requiring hormone substitution therapy. Also, shortly after the surgery, abnormal eating behaviours were observed, including binge-eating disorders and complete loss of satiety, leading to dramatic

weight gain: +30 kg within the first year of the neurosurgery, resulting in a body mass index (BMI) above the 97th percentile for his age (10 years). Despite regular nutritional follow-up, he reached a maximum weight of 179 kg (BMI: 57.7 kg/m²) at age 19 years.

After a multidisciplinary discussion, RYGB surgery was performed with no complications, following which he lost 42.8 kg after 6 months, corresponding to 24% of his preoperative weight, although he gradually regained all of the weight lost after 4 years (Fig. 1). Comorbidities included non-alcoholic steatohepatitis (NASH), obstructive sleep apnoea syndrome and severe bilateral coxarthrosis, but no T2DM.

Considering the severity of this patient's situation, treatment with a daily dose of 3 mg of liraglutide was proposed (using Victoza®, as Saxenda® is not marketed in France). Liraglutide was started at 0.6 mg once daily, and the dose was gradually increased to 3 mg daily with no side-effects. After 8 months of therapy, a significant weight loss of 29 kg was observed, corresponding to a 16% reduction of his initial body weight, with concomitant improvement in metabolic parameters such as triglyceride levels, hepatic cytolysis, systolic blood pressure and fat mass percentage. Over the following months, his weight remained stable until the patient spontaneously discontinued the treatment.

GLP-1 agonists were initially used as glucose-lowering drugs for the treatment of T2DM, but the results of clinical trials repeatedly demonstrated their ability to also induce weight loss. Thus, in 2014, the US Food and Drug Administration (FDA) approved the use of a higher-dose (3 mg daily) version of liraglutide for the treatment of severe obesity. The European Medicines Agency (EMA) then authorized its use in 2015. At this dose, the mean weight loss obtained in patients with common obesity was 7.2 kg after 20 weeks, 4.4 kg [95% confidence interval (CI): 2.9–6.0] greater than that seen with placebo [3] and considerably less than was observed in our patient. In HO, only small series and case reports of the use of exenatide therapy have been published, and these show conflicting results: average weight loss ranged from no significant loss [4] to –29 kg after 2.5 years of treatment [5]. One study described two T2DM patients with HO who were given liraglutide 0.9 mg daily and showed modest weight loss (–3 and –11 kg, respectively) [2]. A multicentre randomized trial testing exenatide is now underway in

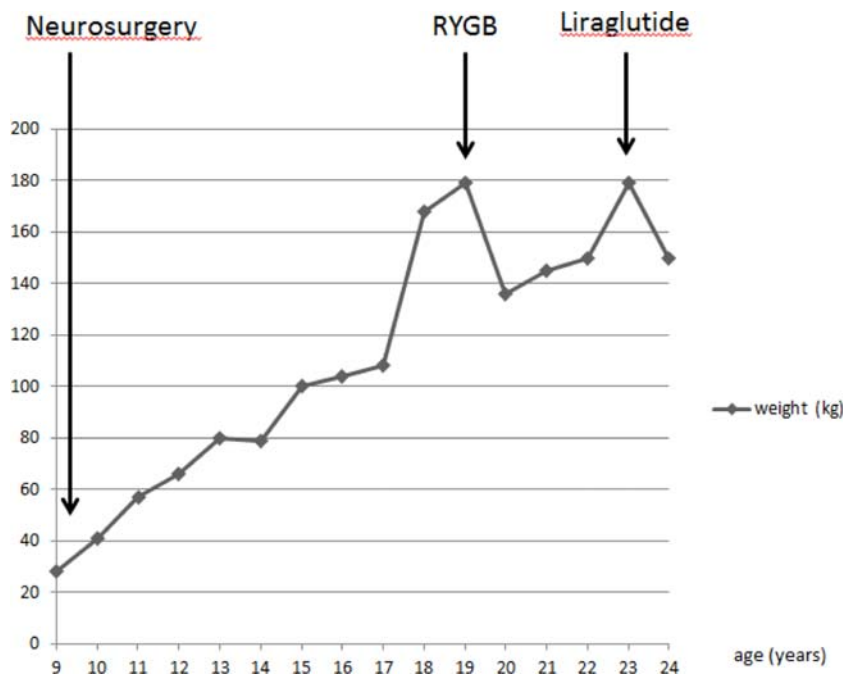


Fig. 1. Evolution of the patient's weight during follow-up. RYGB: Roux-en-Y gastric bypass (surgery).

France (ClinicalTrials.gov: NCT02860923). However, to our knowledge, our report here is the first to describe the use of 3-mg liraglutide in a patient with HO following craniopharyngioma.

The spectacular impact of this treatment in our patient raises speculation as to the possible mechanisms underlying liraglutide efficacy for achieving and maintaining such significant weight loss in a patient with HO and ineffective RYGB. Liraglutide significantly delays gastric-emptying, but as our patient underwent surgical gastric reduction with loss of the pyloric valve, this effect of liraglutide was probably weak in this case. It is known that induced weight loss is mediated by reduced appetite and energy intakes rather than increased energy expenditures. GLP-1 agonists act on central satiety centres, particularly the ventromedian hypothalamic nuclei. These structures are damaged during craniopharyngioma tumor development and by extensive surgery. In fact, we recently demonstrated the abolition of postprandial GLP-1 secretion in patients with HO following craniopharyngioma, but with restoration of a prandial surge of GLP-1 in some patients after gastric-bypass surgery [6]. Interestingly, the restoration of postprandial GLP-1 secretion in these patients correlated with weight loss and reduced energy intakes, further suggesting that the central effect of GLP-1 is not lost in HO. During GLP-1 treatment in our patient, we observed a significant reduction of food intake even during bouts of compulsive eating, with no changes in energy expenditure. This further suggests that the central effect of GLP-1 is maintained in some patients with HO and craniopharyngioma. Thus, GLP-1 receptors that allow control of appetite may be located outside of the hypothalamus in other regions of the central nervous system.

Although the mechanisms of liraglutide effectiveness in HO are still not completely understood, the metabolic improvement observed in our young patient must be highlighted. The prevalence of NASH and cardiovascular disease is higher in patients with HO, while hypopituitarism and diabetes insipidus are negative prognostic factors for mortality and morbidity. Yet, the effects of liraglutide on NASH resolution in diabetic and non-diabetic patients, and the decreases in cardiovascular morbidity and mortality that were recently demonstrated, could be additional arguments for the use of liraglutide in this rare patient population [7].

Thus, we demonstrate here, for the first time, the beneficial effects of liraglutide 3 mg on excess weight and metabolic complications in a young man with HO and an increased metabolic and cardiovascular risk following craniopharyngioma. In this case, the presence of hypothalamic lesions and the previous failure of RYGB did not prevent the effectiveness of the treatment, although prolonged monitoring and follow-up are nonetheless essential.

Funding

This research did not receive any specific grant from funding agencies in the public, commercial or not-for-profit sectors.

Disclosure of interest

M. Bretault: Novo Nordisk, clinical formation.
 C. Carette: Novo Nordisk, meeting/clinical research.
 R. Zaharia: Novo Nordisk, meeting/consultant/clinical formation.
 Karina Vychnevskaja: no conflict of interest.
 Jean-Luc Bouillot: no conflict of interest.
 S. Czernichow: holds shares in MyGoodLife; has coordinated a semaglutide trial for Novo Nordisk in 2018–2019.
 Marie-Laure Raffin-Sanson: Novo Nordisk, clinical formation.

References

- [1] Bretault M, Bouillot A, Muzard L, Poitou C, Oppert JM, Barsamian C, et al. Clinical review: Bariatric surgery following treatment for craniopharyngioma: a sys-

tematic review and individual-level data meta-analysis. *J Clin Endocrinol Metab* 2013;98:2239–46.

- [2] Ando T, Haraguchi A, Matsunaga T, Natsuda S, Yamasaki H, Usa T, et al. Liraglutide as a potentially useful agent for regulating appetite in diabetic patients with hypothalamic hyperphagia and obesity. *Intern Med* 2014;53:1791–5.
- [3] Astrup A, Rössner S, Van Gaal L, Rissanen A, Niskanen L, Al Hakim M, et al. Effects of liraglutide in the treatment of obesity: a randomised, double-blind, placebo-controlled study. *Lancet* 2009;374:1606–16.
- [4] Lomenick JP, Buchowski MS, Shoemaker AH. A 52-week pilot study of the effects of exenatide on body weight in patients with hypothalamic obesity. *Obesity (Silver Spring)* 2016;24:1222–5.
- [5] Simmons JH, Shoemaker AH, Roth CL. Treatment with glucagon-like peptide-1 agonist exenatide-4 in a patient with hypothalamic obesity secondary to intracranial tumor. *Horm Res Paediatr* 2012;78:54–8.
- [6] Bretault M, Laroche S, Lacorte JM, Barsamian C, Polak M, Raffin-Sanson ML, et al. Postprandial GLP-1 secretion after bariatric surgery in three cases of severe obesity related to craniopharyngiomas. *Obes Surg* 2016;26:1133–7.
- [7] Marso SP, Daniels GH, Brown-Frandsen K, Mann JF, Nauck MA, Nissen SE, et al. Liraglutide and Cardiovascular Outcomes in Type 2 Diabetes. *N Engl J Med* 2016;375:311–22.

M. Bretault^{a,*}, C. Carette^b, R. Zaharia^a, K. Vychnevskaja^c, J.-L. Bouillot^c, S. Czernichow^b, M.-L. Raffin-Sanson^a

^aDepartment of Endocrinology-Nutrition, Ambroise-Paré Hospital, AP-HP, 9, avenue Charles de-Gaulle, 92100 Boulogne-Billancourt, France

^bDepartment of Nutrition, Georges-Pompidou Hospital, AP-HP, 20, rue Leblanc, 75015 Paris, France

^cDepartment of Visceral and Metabolic Surgery, Ambroise-Paré Hospital, AP-HP, 9, avenue Charles de-Gaulle, 92100 Boulogne-Billancourt, France

*Corresponding author at: Department of Endocrinology-Nutrition, Ambroise-Paré Hospital, AP-HP, Université de Versailles Saint-Quentin en Yvelines, 92100 Boulogne-Billancourt, France
 E-mail address: marion.bretault@aphp.fr (M. Bretault).

Received 14 June 2019

Received in revised form 5 July 2019

Accepted 21 July 2019

Available online 27 July 2019

<https://doi.org/10.1016/j.diabet.2019.07.004>

1262-3636/© 2019 Elsevier Masson SAS. All rights reserved.

Efficacy of semaglutide versus liraglutide in clinical practice



ARTICLE INFO

Keywords:

Glycaemic control
 Glucagon-like peptide-1
 Receptor agonist
 Liraglutide
 Semaglutide
 Type 2 diabetes

In the recent issue of *Diabetes & Metabolism* semaglutide and liraglutide are compared head-to-head in previously GLP-1 naïve patients [1]. Once weekly GLP-1 agonist semaglutide at maximum approved doses was superior to liraglutide 1.2 mg daily in reducing HbA1c and body weight. This study confirms previous comparisons between various GLP-1 agonists showing that semaglutide is the most potent drug in the class as far as HbA1c and weight