



HAL
open science

Fluocinolone Acetonide implant injected 1 month after Dexamethasone implant for diabetic macular oedema: the ILUVI1MOIS study

Nicolas Rousseau, Olivier Lebreton, H el ene Masse, Yann Maucourant,
Valentin Pipelart, Manon Clement, Marie Laure Le Lez, Raoul K Khanna,
Maxime Pepin, Yannick Eude, et al.

► **To cite this version:**

Nicolas Rousseau, Olivier Lebreton, H el ene Masse, Yann Maucourant, Valentin Pipelart, et al.. Fluocinolone Acetonide implant injected 1 month after Dexamethasone implant for diabetic macular oedema: the ILUVI1MOIS study. 2023. hal-04073664

HAL Id: hal-04073664

<https://hal.science/hal-04073664>

Preprint submitted on 19 Apr 2023

HAL is a multi-disciplinary open access archive for the deposit and dissemination of scientific research documents, whether they are published or not. The documents may come from teaching and research institutions in France or abroad, or from public or private research centers.

L'archive ouverte pluridisciplinaire **HAL**, est destin ee au d ep ot et  a la diffusion de documents scientifiques de niveau recherche, publi es ou non,  emanant des  tablissements d'enseignement et de recherche fran ais ou  trangers, des laboratoires publics ou priv es.



Distributed under a Creative Commons Attribution 4.0 International License

1 **PREPRINT: this is a working paper**

2 **Fluocinolone Acetonide implant injected 1 month after Dexamethasone**
3 **implant for diabetic macular oedema: the ILUVI1MOIS study**

4 Nicolas ROUSSEAU¹, Olivier LEBRETON¹, Hélène MASSE¹, Yann MAUCOURANT², Valentin
5 PIPELART³, Manon CLEMENT¹, Marie Laure LE LEZ⁴, Raoul K KHANNA⁵, Maxime PEPIN⁶,
6 Yannick EUDE¹, Guylène LE MEUR¹, Michel WEBER¹, Jean-Baptiste DUCLOYER¹

7 ¹Nantes Université, CHU Nantes, service d'ophtalmologie, Nantes, France

8 ²Centre Hospitalier Universitaire de Rennes, service d'ophtalmologie, Rennes, France

9 ³Centre Hospitalier Le Mans, service d'ophtalmologie, Le Mans, France

10 ⁴Hôpital Universitaire Bretonneau, service d'ophtalmologie, Tours, France

11 ⁵Hôpital Universitaire Bretonneau, service d'ophtalmologie, UMR 1253, iBrain, Tours, France

12 ⁶Centre Hospitalier Universitaire d'Angers, service d'ophtalmologie, Angers, France

13

14 Correspondence should be addressed to the corresponding author:

15 Dr. Jean-Baptiste DUCLOYER

16 CHU Nantes, service d'Ophtalmologie

17 1 place Alexis Ricordeau

18 44093 Nantes France

19 Tel: 0033 2 40 08 36 56

20 Fax: 0033 2 40 08 46 50

21 jeanbaptiste.ducloyer@chu-nantes.fr

22

23

24 **Keywords**

25 Diabetes complications; diabetic macular oedema; DME; retinal diseases; intravitreal injection;
26 fluocinolone acetonide; dexamethasone; corticosteroid implant

27

28

29 **Abbreviations**

30 BCVA: Best-corrected visual acuity

31 CMT: Central macular thickness

32 DEXi: 700 µg dexamethasone implant

33 DME: Diabetic macular oedema

34 FAci: 0.19 mg fluocinolone acetonide implant

35 TELCAPS: Telangiectatic capillaries

36 **Synopsis (35 words)**

37 Fluocinolone Acetonide implant (FAci) is effective/safe in pseudophakic eyes with chronic diabetic
38 macular oedema requiring frequent dexamethasone implants (DEXi) without ocular hypertension. The
39 first FAci may be injected one month after the last DEXi.

40

41 **(3 – 5 sentences)**

42 **(What is already known on this topic?):**

43 Fluocinolone Acetonide intravitreal implant (FAci) is effective to treat chronic diabetic macular oedema
44 (DME), and its effect lasts longer than that of dexamethasone implant (DEXi) (24-36 months *versus* 3-
45 6 months, respectively). A FAci is therefore a relevant option in pseudophakic eyes with chronic DME
46 requiring frequent DEXi in the absence of ocular hypertension, but the best time to switch implants
47 needs to be investigated since waiting for the end of the effect of DEXi could result in a visual loss and
48 injecting both FAci and DEXi could increase the risk of ocular hypertension.

49 **(What this study adds?):**

50 In this retrospective multicentric study including pseudophakic patients with chronic DME treated with
51 frequent DEXi, switching to FAci injection 1 month after the last DEXi allowed maintaining control of
52 the DME and best-corrected visual acuity, while limiting the use of additional therapies, without
53 increasing significantly the intraocular pressure.

54 **(How this study might affect research, practice or policy?):**

55 This study provides reassuring data allowing ophthalmologists to switch from DEXi to FAci during the
56 DEXi efficacy peak in selected patients. It highlights a favourable risk-benefit ratio associated with the
57 use of FAci to decrease the burden of care in patients with chronic DME and enhance patients'
58 adherence to treatment. Finally, it paves the way for further randomized controlled studies to
59 determine the best interval between the last DEXi and the first FAci.

60 **ABSTRACT**

61 **OBJECTIVE**

62 The aim of this study was to assess the efficacy and safety of fluocinolone acetonide implant (FAci)
63 injected 1 month after the last dexamethasone intravitreal implant (DEXi) in chronic diabetic macular
64 oedema (DME) patients.

65 **METHODS**

66 Retrospective multicentric study conducted in pseudophakic patients with chronic DME frequently
67 treated with DEXi (time to DME recurrence ≤ 6 months), receiving FAci 1 month after the last DEXi, with
68 at least a 6-month follow-up. Best-corrected visual acuity (BCVA), central macular thickness (CMT) on
69 optical coherence tomography, intraocular pressure (IOP) and additional treatments were assessed on
70 the day of FAci injection (M0), one (M1) and 3 months (M3) later and then every 3 months.

71 **RESULTS**

72 Forty-one eyes of 34 patients were included. At M0, patients' mean age was 68.7 ± 9.8 years, the mean
73 DME duration was 63.9 ± 22.9 months, the mean interval between two DEXi was 14.2 ± 3.3 weeks.
74 M12 data were available for 71% of patients. At baseline, the mean BCVA, CMT and IOP were $63.2 \pm$
75 16.6 letters, 299.4 ± 103.3 μm , and 16.2 ± 4.5 mmHg, respectively, and remained stable during the
76 follow-up. At M12, 14% of patients required additional intravitreal treatments.

77 **CONCLUSION**

78 In pseudophakic patients with chronic DME showing good response to DEXi but requiring repeated
79 injections every < 6 months, switching to FAci 1 month after the last DEXi was effective and safe.
80 Further prospective randomized controlled studies are needed to confirm these findings, and to
81 determine the best interval between the last DEXi and the first FAci.

82 INTRODUCTION

83 The number of diabetic patients is expected to reach 700 million in 2050 [1]. Diabetes is the
84 fourth cause of visual impairment in the world and the leading cause in the active population [2].
85 Diabetic macular oedema (DME) affects the central vision and leads to a heavy medico-economic
86 impact due to the burden of care, especially in working populations [3]. The pathophysiology of DME
87 is complex and involves vascular [4] and inflammatory [5] mechanisms.

88 Repeated intravitreal injections of anti-VEGF is the gold standard treatment for decreased
89 vision associated with DME [6]. Intraocular dexamethasone implant (DEXi) also plays an important role
90 in the management of DME due to its longer duration of action (3-6 months) [7] compared to anti-
91 VEGFs (1-2 months) [6], allowing reducing the burden of care [8]. In addition, DEXi allows achieving a
92 complete DME regression in almost half of the patients 2 months after the first injection [9]. However,
93 the use of DEXi is associated with the occurrence of ocular hypertension (OHT) in 20% of cases [10],
94 cataracts requiring surgery in 67% of cases [6], a lack of effect on the activity of peripheral diabetic
95 retinopathy, as well as a need for repeated injections to maintain its efficacy on DME [11]. Overall,
96 DEXi is used as a second-line therapy in the absence of response to anti-VEGF therapy, or as a first-line
97 therapy in patients with a significant cardiovascular history or in pseudophakic patients, especially in
98 the absence of peripheral diabetic retinopathy.

99 The 0.19 mg fluocinolone acetonide implant (FAci) is a newest corticosteroid implant. This
100 polymer device is inserted into the vitreous cavity using a 25-gauge needle where it releases 0.2 µg/day
101 of FAc for up to 36 months [12,13]. As with the DEXi, the use of a FAci is associated with the occurrence
102 of OHT in 20% of cases [14,15], cataracts requiring surgery in 80% of cases 12-18 months after the
103 injection [12] and an absence of effect on diabetic retinopathy activity. According to its French
104 Marketing Authorization, FAci is currently indicated for treatment of chronic DME as a third-line
105 therapy [16]. In clinical practice, and in line with expert opinions [17], this indication is extended to
106 cases treated with effective, well-tolerated DEXi injections but for which a too short injection interval
107 is needed for three reasons: (a) the risk of OHT associated with FAci is limited in patients who did not
108 experience OHT with DEXi [18], (b) patients with DME well controlled with DEXi (good responders) are
109 likely to well respond to FAci [19,20], and (c) the efficacy of FAci lasts much longer than that of DEXi
110 and allows less frequent intravitreal injections [21].

111 However, the modalities for switching from DEXi to FAci are poorly described in the literature
112 and it remains unknown whether FAci should be injected during or after the end of the efficacy period
113 of DEXi (6 months after the injection). It is important to study this transition phase because the kinetics
114 of action of FAci is slower than that of DEXi, with complete anatomical and functional efficacy reached

115 11 months after the injection [14]. Indeed, the visual improvement may be delayed with FAci and 30%
116 of patients require additional treatment during their follow-up [14], mainly during the first year
117 [17,18,22]. It appears essential to optimize this transition to minimize DME variation because: (a) a
118 visual discomfort in daily life (decreased visual acuity and metamorphopsia) directly correlates with
119 the presence of DME, (b) the shorter the duration of DME progression is, the better the response to
120 treatment is [14], and (c) the long-term visual acuity is worse in case of longer progression and greater
121 DME variations [23].

122 The aim of this study was to assess the efficacy and safety of a FAci injection on chronic DME,
123 when the FAci was injected 1 month after the last DEXi injection in patients adequately controlled with
124 frequent DEXi injections and to confirm if an early switch allowed maintaining control of the DME and
125 visual acuity, without increasing the risk of OHT.

126

127 **METHODS**

128 The ILUVI1MOIS study was a regional, multicentric, open-label, non-randomized, retrospective
129 phase IV study involving ophthalmology departments in five French centres: the university hospitals
130 (CHU) of Nantes, Tours, Angers, and Rennes, and the hospital of Le Mans.

131 The study population included patients injected with a FAci in the participating centres
132 between March 2019 and September 2021. Inclusion criteria were: patients with chronic DME, injected
133 with a FAci 1 month after the last DEXi injection, in whom DME recurrence was delayed after DEXi
134 injections, with a minimum follow-up ≥ 6 months, and not opposing to participate in the study after
135 oral and written information.

136 Data collected were: age, gender, type of diabetes, DME duration, history of panretinal
137 photocoagulation (PRP), history of focal macular laser, number of anti-VEGF and DEXi injections
138 received before inclusion, mean time to DME recurrence after DEXi (in weeks), previous intraocular
139 pressure (IOP) lowering therapy. The following data were collected at each standardized follow-up
140 visit: best-corrected visual acuity (BCVA, ETDRS scale), central macular thickness (CMT) (1000- μm
141 diameter) measured on Optical Coherence Tomography (OCT), IOP and IOP-lowering therapy,
142 additional treatment. For eyes requiring additional treatment during the follow-up, OCT and
143 indocyanine green angiography (ICGA) performed prior to FAci injection were analysed, if available, to
144 detect telangiectatic capillaries (TELCAPS) responsible for a focal component of DME. TELCAPS were
145 considered accessible to focal argon laser treatment if they were collocated with a focal component of
146 DME and located outside an area centred on the fovea and measuring 1500- μm in diameter.

147 As part of the follow-up protocol standardized in our 5 centres, patients treated with FAci
148 attended the following consultations: on the day of the FAci injection (M0), 1 month (M1) and 3
149 months (M3) after the injection, and then every 3 months.

150 The study was approved by a regional ethics committee (Groupe Nantais d'Ethique dans le
151 Domaine de la Santé - GNEDS) and was conducted in compliance with the Declaration of Helsinki.
152 According to the French law for retrospective studies, patients' non-opposition is sufficient to process
153 retrospective data. All patients received information and gave oral consent to participate in the study.
154 Quantitative data were compared using a Student's t-test or a Mann-Whitney U test (for parametric
155 and non-parametric data, respectively).

156 **RESULTS**

157 Among the 47 patients (55 eyes) injected with FAci during the study period, 34 patients (41
158 eyes) were included and analysed (figure 1). The mean follow-up duration after the FAci injection was
159 13.1 ± 4.4 months (range: 6-22 months): 29/41 eyes had a 12-month follow-up and 9/41 eyes had an
160 18-month follow-up (Table 1).

161 ***Visual acuity (BCVA)***

162 The mean BCVA was 63.2 ± 16.6 letters at M0 and was not significantly different at M1 ($63.0 \pm$
163 17.5 letters), M9 (65.2 ± 14.8 letters) and M12 (62.1 ± 20.3 letters). The BCVA was significantly higher
164 at M3 (64.3 ± 14.7 letters) and M6 (64.6 ± 15.7 letters) compared to M0 ($p=0.0208$ and $p=0.0377$,
165 respectively) (figure 2A).

166 ***Central Macular Thickness (CMT)***

167 The change in mean CMT between M0 ($299.4 \pm 103.3 \mu\text{m}$), M1 ($283.1 \pm 101.6 \mu\text{m}$), M3 (319.3
168 $\pm 125.8 \mu\text{m}$), M6 ($328.9 \pm 131.7 \mu\text{m}$), M9 ($300.9 \pm 79.9 \mu\text{m}$) and M12 ($322.9 \pm 123.1 \mu\text{m}$) was always
169 less than 10% and was never significant (figure 2B).

170 ***Additional treatments***

171 In our cohort, 29 eyes had a complete follow-up of at least 12 months. Among them, 6 eyes
172 (20.6%) received additional treatment during this period: a DEXi injection at M6 ($n=3$), focal laser for
173 TELCAPS at M6 ($n=2$), or combined focal laser and DEXi injection at M9 ($n=1$) (figure 3). Thus, 4 eyes
174 (13.8%) followed for at least 12 months required additional pharmacological treatment during the first
175 year: recent ICGA findings were available for 3 eyes, showing TELCAPS centering a focal component of
176 the DME, accessible to focal laser treatment (at least at $750 \mu\text{m}$ from the fovea). Among the 6 eyes
177 that required early additional treatment, 5 had TELCAPS that maintained a focal component of DME
178 visible on ICGA prior to FAci injection; 4 of them had TELCAPS at a distance of at least $750 \mu\text{m}$ from the
179 fovea and 1 had TELCAPS between 500 and $750 \mu\text{m}$ from the fovea.

180 ***Intraocular pressure (IOP)***

181 At M0, 24 eyes (58%) were not treated with IOP-lowering therapy. The mean IOP at M1 (17.05
182 mmHg), M3 (16.7 mmHg), M6 (16.3 mmHg), M9 (15.9 mmHg) and M12 (15.6 mmHg) did not
183 significantly differ from that measured at M0 ($16.2 \pm 4.5 \text{ mmHg}$) (figure 2C). During the follow-up, 10
184 eyes (23%) had transient OHT at M1 ($n=4$), M3 ($n=2$), M9 ($n=1$), M12 ($n=2$) or M14 ($n=1$) that was
185 effectively treated with local IOP-lowering therapy. No eye had OHT $>30 \text{ mmHg}$ during the follow-up.
186 No eye required additional triple therapy or incisional surgery. No patient already treated with any
187 type of IOP-lowering therapy at M0 required additional therapy during the follow-up.

188 **Table 1. Baseline demographics and ocular characteristics.**

189 BCVA, best-corrected visual acuity; CMT, central macular thickness; ETDRS, early treatment diabetic
 190 retinopathy study; IOP, intraocular pressure; SD, standard deviation

<i>Patients characteristics</i>	
Number of eyes (number of patients)	41 (34)
Sex :	
- Male	20
- Female	14
Age in years, mean \pm SD [range]	68,7 \pm 9,8 [44 ; 85]
Type of diabetes	
- Type 1, n (%)	2 (4,8)
- Type 2, n (%)	39 (95,2)
<i>Ocular characteristics</i>	
Pseudophakic, n (%)	41 (100)
Diabetic macular oedema duration (months)	63,9 \pm 22,9 [18 ; 120]
Panretinal photocoagulation	28 (68,3)
Macular laser therapy	9 (21,9)
Number of anti VEGF injections per eye	7,6 \pm 5,8 [0 ; 21]
Number of DEXi injections per eye	6,1 \pm 4,5 [2 ; 21]
Time between two DEX injections (weeks)	14,2 \pm 3,3 [8 ; 24]
CMT (μ m)	299,4 \pm 103,3
BCVA (ETDRS letters)	63,2 \pm 16,6
IOP (mmHg)	16,2 \pm 4,5
IOP-lowering medications	17 (41,4)
- Monotherapy	7 (17,0)
- Dual Therapy	7 (17,0)
- Triple Therapy	1 (2,4)
- Incisional surgery	2 (4,8)
Follow-up duration after FAci (months)	13,1 \pm 4,4 [6 ; 22]

191

192

193 **Table 2. Distribution of eyes with ocular hypertension during follow-up.**

194 Intra ocular pressure (IOP)

IOP [21 – 25 mmHg]	6/41 (14,6%)
IOP [25 – 30 mmHg]	4/41 (9,7%)
IOP > 30 mmHg	0/41 (0%)

195

196 **DISCUSSION**

197 In patients with chronic DME requiring frequent DEXi injections, we found that injecting a FAci
198 1 month after the last DEXi effectively maintained stable BCVA and CMT, with a low rate of additional
199 treatments required and minimal OHT concerns. To our knowledge, this was the first study to
200 investigate the switch interval of 1 month between a DEXi and a FAci. Indeed, in most published large,
201 real-life studies, the last molecule injected prior to FAci injection is usually not reported
202 [14,18,21,24,25]. Similarly, the time between the last treatment and the injection of FAci is usually not
203 mentioned. However, in these studies, the injection was mostly performed at the time of a recurrence
204 of DME.

205 ***Anatomical and functional efficacy***

206 Since our patients were injected with a FAci during the efficacy period of the DEXi, in the
207 absence of DME recurrence, their BCVA and CMT were already improved at M0 and thus evolved very
208 differently from those observed in previous studies in which the FAci was injected at the time of a
209 recurrence of DME. The MEDISOFT study has shown a mean CMT reduction of 97 μm during the follow-
210 up and a mean BCVA improvement of 5.3 letters at 24 months [21]. A meta-analysis has shown a mean
211 BCVA improvement of 8.7 letters at 11.3 months and a mean CMT reduction of 184 μm (34.3%) at 16.6
212 months [14]. This meta-analysis has also shown a good anatomical and functional correlation (CMT
213 reduction of at least 20% associated with a BCVA gain of at least 5 letters) in 77.0% of analysed studies.
214 In our study, the mean BCVA gain was 1.1 letter and the mean CMT change was <10% after a 12-month
215 follow-up. Our results are consistent with other studies if we consider the stability period following the
216 FAci ramp-up. Indeed, the MEDISOFT study has found a mean BCVA change of only 1.0 letter between
217 6 and 24 months. Similarly, the PALADIN study has found a mean BCVA change of 2.1 letters and a
218 mean CMT change <5.0% between 6 and 18 months [18].

219 ***Additional treatments***

220 The data available in the literature on additional treatments have shown that about 30% of
221 patients require additional treatment during their follow-up with a mean time to retreatment of 15.4
222 months [14]. In the IRISS study [26], 22.4% of eyes were treated with anti-VEGF, 6.6% with DEXi and
223 9.6% with focal laser during the follow-up. In the MEDISOFT study [21], a retreatment rate of 35.7%
224 has been reported during the follow-up, and 32.2% of eyes were retreated with intravitreal injections
225 (DEXi or anti-VEGF) and 6.4% with focal laser. The PALADIN study [18] has investigated the likelihood
226 of using additional early treatment and has found that 48.1% of patients received additional treatment
227 during the first 12 months. This is a relatively high proportion of patients, although this study has
228 clearly shown a decrease in the number of treatments per year required after FAci compared to before

229 FAci. In their study, Baillif *et al.* have found a rate of additional treatments of 32.7% during the first 12
230 months with a mean time to retreatment of 113.27 days [22]. In our study, only 6 out of the 29 eyes
231 (20.9%) with a complete follow-up at 12 months required additional treatment during the first year,
232 and only 4 eyes required additional pharmacological treatment (13.8%). A retrospective analysis of
233 pre-FAci angiograms has found that 4 out of the 6 retreated eyes had visible TELCAPS easily accessible
234 to laser treatment (at least at 750 μm from the fovea) and 1 had visible TELCAPS relatively close to the
235 fovea (between 500 and 750 μm from the fovea). This finding suggests that many patients could have
236 benefited from macular focal laser earlier. Further studies are needed to confirm that diagnosing and
237 treating TELCAPS before FAci injection could decrease the need for additional treatment. Other
238 publications support the need to diagnose and treat TELCAPS as part of the management of DME. A
239 study has found that 63% of eyes with DME had TELCAPS on ICGA, at a median distance of 2,700 μm
240 from the fovea, and thus accessible to laser treatment in most cases [27]. Another study of chronic
241 macular oedema (secondary to diabetes and vein occlusion) has found that 66.3% of patients had
242 macular TELCAPS [28]. Furthermore, treating these TELCAPS allowed reducing the interval between
243 intravitreal injections [29].

244 ***Intraocular pressure (IOP)***

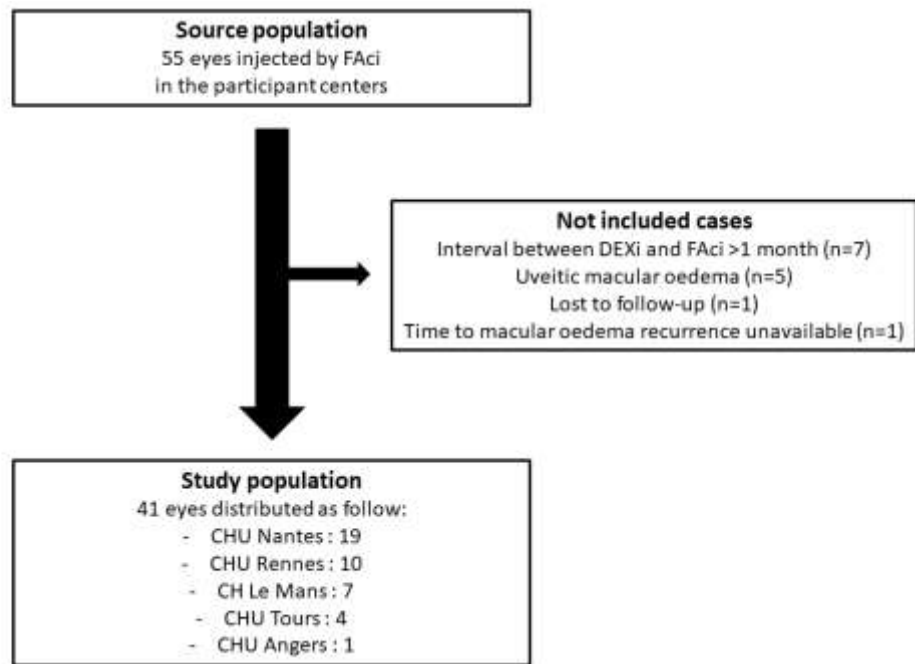
245 OHT concerns were remarkably low in our study. As mentioned above, no patient had OHT >30
246 mmHg, no patient required triple IOP-lowering therapy nor incisional surgery. The 24% of eyes that
247 required IOP-lowering therapy were all well controlled thereafter. Baillif *et al.* have found similar
248 results [22]. Conversely, in the RETRO IDEAL study [24] conducted in 81 eyes, 12.3% of patients had an
249 IOP peak >30 mmHg at some point during the follow-up and 3.7% of them required filtering surgery.
250 In the MEDISOFT study [21], 7.2% of eyes had an IOP peak >30 mmHg. A major difference between
251 these two studies and our study is that a minority of patients had received a DEXi injection before
252 injecting a FAci. Indeed, in the RETRO IDEAL study [24], only 24.1% of eyes had received a DEXi injection
253 within the year before FAci injection. In the MEDISOFT study [21], only 32.8% of eyes had received a
254 corticosteroid intravitreal injection before FAci injection, and the authors have pointed out that eyes
255 that did not experience any increase in IOP under DEX, did not experience a severe increase (>30
256 mmHg) in IOP under FAc. These data suggest that it is more prudent to inject DEXi to identify patients
257 at risk of OHT before considering injecting a FAci. Indeed, the PALADIN study [18] has shown that
258 patients who do not experience OHT related to corticosteroids are at low risk of OHT under FAc, unlike
259 those with a history of OHT with corticosteroids (positive predictive value of 79.6% of having an IOP
260 <25 mmHg after FAci injection in the absence of a history of IOP rise under corticosteroids).

261 Our study has several limitations. First, the retrospective collection of data which does not give
262 our conclusions the same strength as a prospective study. However, the robustness of our study relies
263 on the common decision to apply a systematized care and follow-up protocol for all patients. Similarly,
264 the absence of a control group with a different injection interval is explained by the retrospective
265 design of the study, the relatively small number of eligible patients, and the collegiate care protocol
266 implemented given the scientific findings presented above. The follow-up duration was relatively short
267 and heterogeneous, but the inclusion criterion requiring a follow-up of at least 6 months for all patients
268 allowed properly investigating the transition period of interest. Furthermore, a 12-month follow-up
269 was available for 71% of cases (29/41 eyes) and allowed obtaining relevant secondary results.

270 In conclusion, in pseudophakic patients with chronic DME showing a good response to DEXi in
271 the absence of OHT but requiring repeated injections every <6 months, we showed the efficacy and
272 safety of injecting a FAci 1 month after the last DEXi injection. Further prospective randomized studies
273 are needed to confirm this result, to determine the best interval between the DEXi and FAci injections,
274 and to confirm that diagnosing and treating TELCAPS before initiating FAci injection could further
275 reduce the need for additional treatment.

276

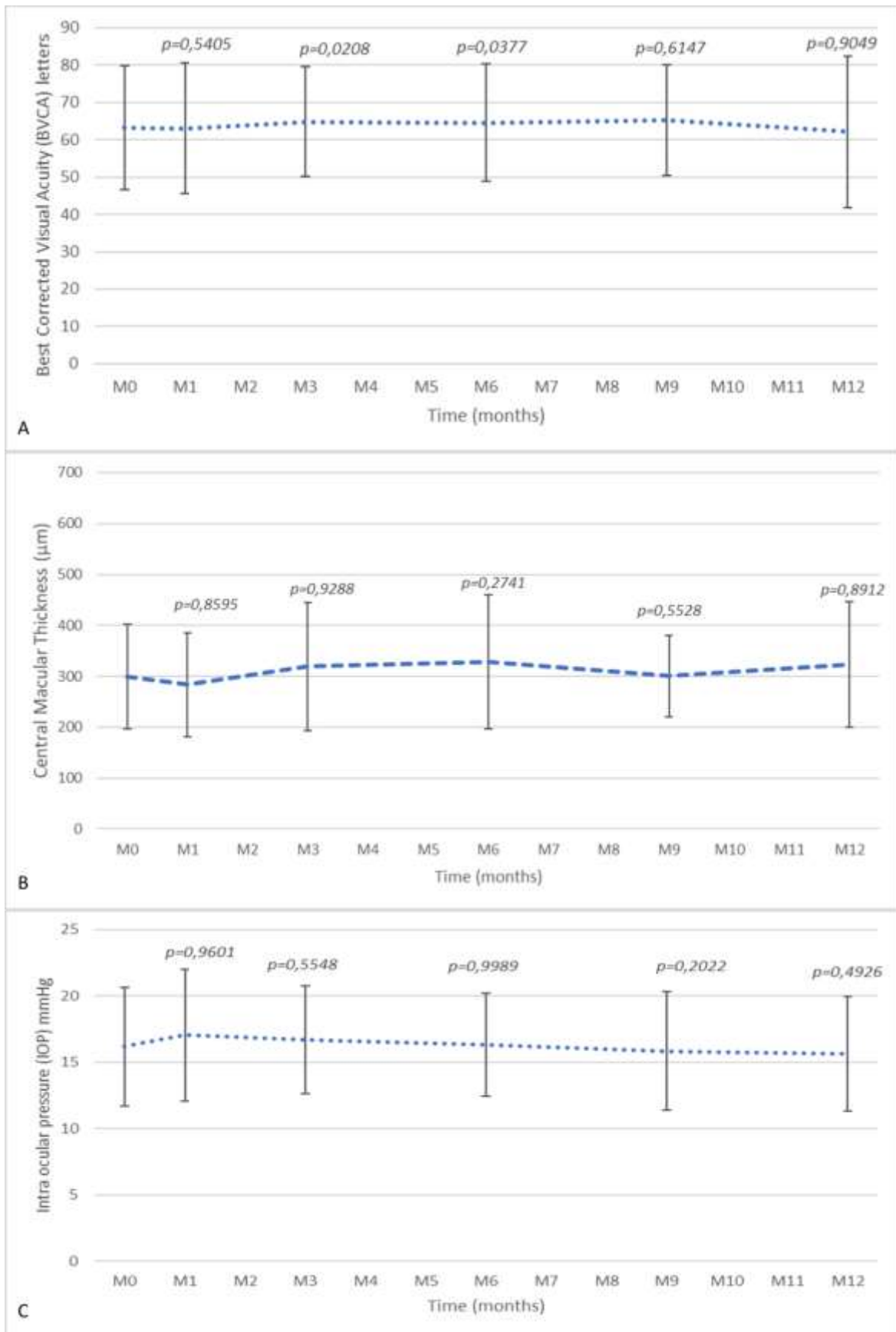
277 **Figure 1. Flow diagram**



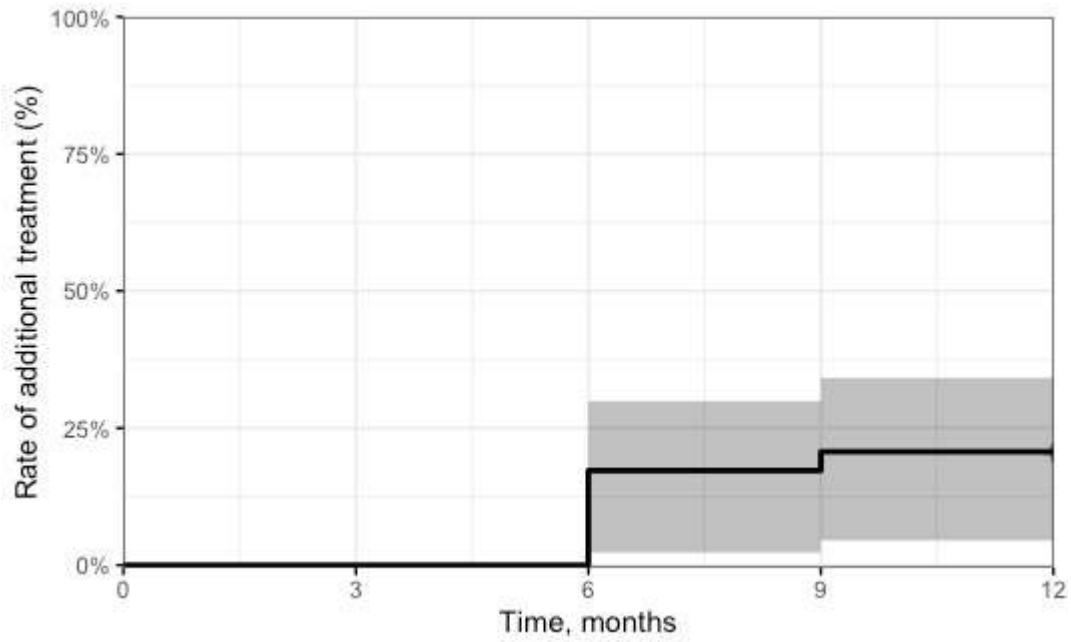
278

279

280 **Figure 2. Mean best-corrected visual acuity, central macular thickness, intraocular pressure during**
 281 **the 12-month follow-up after fluocinolone acetonide implant injection.**



282 **Figure 3. Rate of additional treatment during the 12-month follow-up after fluocinolone acetonide**
283 **implant injection.** In grey, the 95% confidence interval. Edited with R version 1.2.5019 with the
284 survmine package



285
286
287

288 **Competing interests**

289 Horus pharma[®] funded the English proofreading of the manuscript and the publication fees.

290

291 **Acknowledgments**

292 We thank the ophthalmologists who performed the injections and followed the patients in accordance
293 with the standardized care protocol. We thank the patients who consented to participate. We thank
294 Horus Pharma[®] who funded the proofreading and publication fees.

295

296 **Author Contributions**

297 NR, OL, HM, MC, MW and JBD contributed to the study conception and design. Material preparation
298 and data collection were performed by NR, OL, HM, MC, YM, VP, ML, KK, MP, MW and JBD. Data
299 analysis was performed by NR, OL, HM, YE, GLM, MW and JBD. The first draft of the manuscript was
300 written by NR and all authors reviewed the previous versions of the manuscript. All authors read and
301 approved the final manuscript.

302

303 **REFERENCES**

- 304 1 Home, Resources, diabetes L with, *et al.* 9th edition | IDF Diabetes Atlas.
305 <https://diabetesatlas.org/atlas/ninth-edition/> (accessed 20 Jun 2022).
- 306 2 GBD 2019 Blindness and Vision Impairment Collaborators, Vision Loss Expert Group of
307 the Global Burden of Disease Study. Causes of blindness and vision impairment in 2020
308 and trends over 30 years, and prevalence of avoidable blindness in relation to VISION
309 2020: the Right to Sight: an analysis for the Global Burden of Disease Study. *Lancet Glob*
310 *Health* 2021;**9**:e144–60. doi:10.1016/S2214-109X(20)30489-7
- 311 3 Cooper O a. E, Taylor DJ, Crabb DP, *et al.* Psychological, social and everyday visual impact
312 of diabetic macular oedema and diabetic retinopathy: a systematic review. *Diabet Med J*
313 *Br Diabet Assoc* 2020;**37**:924–33. doi:10.1111/dme.14125
- 314 4 Haritoglou C, Neubauer AS, Kernt M. Fluocinolone acetonide and its potential in the
315 treatment of chronic diabetic macular edema. *Clin Ophthalmol Auckl NZ* 2013;**7**:503–9.
316 doi:10.2147/OPHTH.S34057
- 317 5 X Z, H Z, S B, *et al.* Diabetic macular edema: new concepts in patho-physiology and
318 treatment. *Cell Biosci* 2014;**4**. doi:10.1186/2045-3701-4-27
- 319 6 Schmidt-Erfurth U, Garcia-Arumi J, Bandello F, *et al.* Guidelines for the Management of
320 Diabetic Macular Edema by the European Society of Retina Specialists (EURETINA).
321 *Ophthalmol J Int Ophthalmol Int J Ophthalmol Z Augenheilkd* 2017;**237**:185–222.
322 doi:10.1159/000458539
- 323 7 Boyer DS, Yoon YH, Belfort R, *et al.* Three-year, randomized, sham-controlled trial of
324 dexamethasone intravitreal implant in patients with diabetic macular edema.
325 *Ophthalmology* 2014;**121**:1904–14. doi:10.1016/j.ophtha.2014.04.024
- 326 8 Weiss M, Sim DA, Herold T, *et al.* COMPLIANCE AND ADHERENCE OF PATIENTS WITH
327 DIABETIC MACULAR EDEMA TO INTRAVITREAL ANTI-VASCULAR ENDOTHELIAL GROWTH
328 FACTOR THERAPY IN DAILY PRACTICE. *Retina Phila Pa* 2018;**38**:2293–300.
329 doi:10.1097/IAE.0000000000001892
- 330 9 Bonnin S, Dupas B, Sanharawi ME, *et al.* Efficacy of dexamethasone intravitreal implant
331 for the treatment of diabetic macular edema. *Eur J Ophthalmol* 2015;**25**:448–53.
332 doi:10.5301/ejo.5000581
- 333 10 Malclès A, Dot C, Voirin N, *et al.* SAFETY OF INTRAVITREAL DEXAMETHASONE IMPLANT
334 (OZURDEX): The SAFODEX study. Incidence and Risk Factors of Ocular Hypertension.
335 *Retina Phila Pa* 2017;**37**:1352–9. doi:10.1097/IAE.0000000000001369
- 336 11 Bellocq D, Akeshi J, Matonti F, *et al.* The Pattern of Recurrence in Diabetic Macular
337 Edema Treated by Dexamethasone Implant: The PREDIAMEX Study. *Ophthalmol Retina*
338 2018;**2**:567–73. doi:10.1016/j.oret.2017.10.016

- 339 12 Campochiaro PA, Brown DM, Pearson A, *et al.* Sustained delivery fluocinolone acetonide
340 vitreous inserts provide benefit for at least 3 years in patients with diabetic macular
341 edema. *Ophthalmology* 2012;**119**:2125–32. doi:10.1016/j.ophtha.2012.04.030
- 342 13 Campochiaro PA, Brown DM, Pearson A, *et al.* Long-term benefit of sustained-delivery
343 fluocinolone acetonide vitreous inserts for diabetic macular edema. *Ophthalmology*
344 2011;**118**:626-635.e2. doi:10.1016/j.ophtha.2010.12.028
- 345 14 Kodjikian L, Baillif S, Creuzot-Garcher C, *et al.* Real-World Efficacy and Safety of
346 Fluocinolone Acetonide Implant for Diabetic Macular Edema: A Systematic Review.
347 *Pharmaceutics* 2021;**13**:72. doi:10.3390/pharmaceutics13010072
- 348 15 Parrish RK, Campochiaro PA, Pearson PA, *et al.* Characterization of Intraocular Pressure
349 Increases and Management Strategies Following Treatment With Fluocinolone
350 Acetonide Intravitreal Implants in the FAME Trials. *Ophthalmic Surg Lasers Imaging*
351 *Retina* 2016;**47**:426–35. doi:10.3928/23258160-20160419-05
- 352 16 ILUVIEN (acétonide de fluocinolone), corticoïde en implant intravitréen. Haute Aut.
353 Santé. [https://www.has-sante.fr/jcms/c_1622369/fr/iluvien-acetonide-de-fluocinolone-](https://www.has-sante.fr/jcms/c_1622369/fr/iluvien-acetonide-de-fluocinolone-corticoide-en-implant-intravitreem)
354 [corticoide-en-implant-intravitreem](https://www.has-sante.fr/jcms/c_1622369/fr/iluvien-acetonide-de-fluocinolone-corticoide-en-implant-intravitreem) (accessed 2 Aug 2022).
- 355 17 Kodjikian L, Bandello F, de Smet M, *et al.* Fluocinolone acetonide implant in diabetic
356 macular edema: International experts' panel consensus guidelines and treatment
357 algorithm. *Eur J Ophthalmol* 2022;**32**:1890–9. doi:10.1177/11206721221080288
- 358 18 Mansour SE, Kiernan DF, Roth DB, *et al.* Two-year interim safety results of the 0.2 µg/day
359 fluocinolone acetonide intravitreal implant for the treatment of diabetic macular
360 oedema: the observational PALADIN study. *Br J Ophthalmol* 2021;**105**:414–9.
361 doi:10.1136/bjophthalmol-2020-315984
- 362 19 Cicinelli MV, Rosenblatt A, Grosso D, *et al.* The outcome of fluocinolone acetonide
363 intravitreal implant is predicted by the response to dexamethasone implant in diabetic
364 macular oedema. *Eye Lond Engl* 2021;**35**:3232–42. doi:10.1038/s41433-020-01373-1
- 365 20 Adán A, Cabrera F, Figueroa MS, *et al.* Clinical-Decision Criteria to Identify Recurrent
366 Diabetic Macular Edema Patients Suitable for Fluocinolone Acetonide Implant Therapy
367 (ILUVIEN®) and Follow-Up Considerations/Recommendations. *Clin Ophthalmol Auckl NZ*
368 2020;**14**:2091–107. doi:10.2147/OPHTH.S252359
- 369 21 Bailey C, Chakravarthy U, Lotery A, *et al.* Real-world experience with 0.2 µg/day
370 fluocinolone acetonide intravitreal implant (ILUVIEN) in the United Kingdom. *Eye Lond*
371 *Engl* 2017;**31**:1707–15. doi:10.1038/eye.2017.125
- 372 22 Baillif S, Staccini P, Weber M, *et al.* Management of Patients with Diabetic Macular
373 Edema Switched from Dexamethasone Intravitreal Implant to Fluocinolone Acetonide
374 Intravitreal Implant. *Pharmaceutics* 2022;**14**:2391. doi:10.3390/pharmaceutics14112391
- 375 23 Sadda SR, Campbell J, Dugel PU, *et al.* Relationship between duration and extent of
376 oedema and visual acuity outcome with ranibizumab in diabetic macular oedema: A post

- 377 hoc analysis of Protocol I data. *Eye Lond Engl* 2020;**34**:480–90. doi:10.1038/s41433-019-
378 0522-z
- 379 24 Augustin AJ, Bopp S, Fechner M, *et al.* Three-year results from the Retro-IDEAL study:
380 Real-world data from diabetic macular edema (DME) patients treated with ILUVIEN®
381 (0.19 mg fluocinolone acetonide implant). *Eur J Ophthalmol* 2020;**30**:382–91.
382 doi:10.1177/1120672119834474
- 383 25 Holden SE, Kapik B, Beiderbeck AB, *et al.* Comparison of data characterizing the clinical
384 effectiveness of the fluocinolone intravitreal implant (ILUVIEN) in patients with diabetic
385 macular edema from the real world, non-interventional ICE-UK study and the FAME
386 randomized controlled trials. *Curr Med Res Opin* 2019;**35**:1165–76.
387 doi:10.1080/03007995.2018.1560779
- 388 26 Chakravarthy U, Taylor SR, Koch FHJ, *et al.* Changes in intraocular pressure after
389 intravitreal fluocinolone acetonide (ILUVIEN): real-world experience in three European
390 countries. *Br J Ophthalmol* 2019;**103**:1072–7. doi:10.1136/bjophthalmol-2018-312284
- 391 27 Castro Farías D, Matsui Serrano R, Bianchi Gancharov J, *et al.* Indocyanine green
392 angiography for identifying telangiectatic capillaries in diabetic macular oedema. *Br J*
393 *Ophthalmol* 2020;**104**:509–13. doi:10.1136/bjophthalmol-2019-314355
- 394 28 Chaperon M, Kodjikian L, Agard E, *et al.* Screening of telangiectatic capillaries in chronic
395 macular edema based on multimodal imaging: a study of 101 eyes. LyoMAC1 study.
396 *Graefes Arch Clin Exp Ophthalmol Albrecht Von Graefes Arch Klin Exp Ophthalmol*
397 2022;**260**:2501–8. doi:10.1007/s00417-022-05592-y
- 398 29 Séjournet L, Kodjikian L, Elbany S, *et al.* Focal Photocoagulation as an Adjunctive Therapy
399 to Reduce the Burden of Intravitreal Injections in Macula Edema Patients, the LyoMAC2
400 Study. *Pharmaceutics* 2023;**15**:308. doi:10.3390/pharmaceutics15020308
- 401