



HAL
open science

Can Patella Instability After Total Knee Arthroplasty be Treated With Medial Patellofemoral Ligament Reconstruction?

Jobe Shatrov, Antoine Colas, Gaspard Fournier, Cécile Batailler, Elvire Servien, Sebastien Lustig

► To cite this version:

Jobe Shatrov, Antoine Colas, Gaspard Fournier, Cécile Batailler, Elvire Servien, et al.. Can Patella Instability After Total Knee Arthroplasty be Treated With Medial Patellofemoral Ligament Reconstruction?. *Arthroplasty Today*, 2022, 16, p 130-139. 10.1016/j.artd.2022.04.006 . hal-04071159


HAL Id: hal-04071159

<https://hal.science/hal-04071159>

Submitted on 17 Apr 2023

HAL is a multi-disciplinary open access archive for the deposit and dissemination of scientific research documents, whether they are published or not. The documents may come from teaching and research institutions in France or abroad, or from public or private research centers.

L'archive ouverte pluridisciplinaire **HAL**, est destinée au dépôt et à la diffusion de documents scientifiques de niveau recherche, publiés ou non, émanant des établissements d'enseignement et de recherche français ou étrangers, des laboratoires publics ou privés.



Original Research

Can Patella Instability After Total Knee Arthroplasty be Treated With Medial Patellofemoral Ligament Reconstruction?

Jobe Shatrov, MBBS (Hons), Bsc ^{a, b, *}, Antoine Colas, MD ^a, Gaspard Fournier, MD ^a,
Cécile Batailler, PhD, MD ^{a, c}, Elvire Servien, PhD, MD ^{a, d}, Sébastien Lustig, PhD, MD ^{a, c}

^a Orthopaedics Surgery and Sports Medicine Department, FIFA Medical Center of Excellence, Croix-Rousse Hospital, Lyon University Hospital, Lyon, France

^b Sydney Orthopaedic Research Institute (SORI) – St. Leonards, Sydney, Australia

^c Univ Lyon, Claude Bernard Lyon 1 University, IFSSTAR, LBMC UMR_T9406, F69622, Lyon, France

^d LIBM – EA 7424, Interuniversity Laboratory of Biology of Mobility, Claude Bernard Lyon 1 University, Lyon, France

ARTICLE INFO

Article history:

Received 10 April 2022

Accepted 12 April 2022

Available online xxx

Keywords:

Patellofemoral instability

Total knee arthroplasty

MPFL reconstruction

Tibial tubercle osteotomy

Suspensory fixation

ABSTRACT

Background: The aim of this study was to describe outcomes of patients who had undergone medial patellofemoral ligament reconstruction (MPFLr) to treat patellofemoral instability (PFI) following total knee arthroplasty (TKA).

Material and methods: This is a retrospective case series of consecutive patients treated for PFI after TKA. Patients were included if they had radiographic documentation of patella dislocation or subluxation and component position was adequate. MPFLr was performed using a quadriceps tendon autograft. The graft was fixed with either an interference or additional suspensory fixation. A tibial tubercle osteotomy was performed in select indications. Patients were assessed with Kujala and International Knee Score (IKS) at a minimum 12-month follow-up and radiographically with plain radiographs.

Results: A total of 22 patients (23 procedures) were included. The mean follow-up period was 38 months (range 12–72). Average preoperative femoral component rotation on computed tomography was 0.10° external rotation (range 3° internal rotation to 3° external rotation). All patients had improved clinical and radiographic outcomes postoperatively. At the last follow-up, the mean IKS knee score was 77.6 ± 13.1, mean IKS function score was 75.2 ± 23.3, and mean Kujala score was 60.2/100 ± 10.9. There was 1 mechanical failure, which occurred following MPFLr with interference fixation. There were 6 complications (28.1%) postoperatively. Patients receiving double fixation of the MPFLr graft had higher clinical and radiographic scores; however, this difference was not statistically significant. MPFLr had a patella-lowering effect, 0.97 preoperatively to 0.74 postoperatively ($P = .069$).

Conclusion: MPFLr in appropriately selected patients is a satisfactory option to treat PFI following TKA. © 2022 The Authors. Published by Elsevier Inc. on behalf of The American Association of Hip and Knee Surgeons. This is an open access article under the CC BY-NC-ND license (<http://creativecommons.org/licenses/by-nc-nd/4.0/>).

Introduction

Patellofemoral instability (PFI) following total knee arthroplasty (TKA) is an uncommon but devastating complication with incidence ranging from 0.5% to 0.8% [1,2]. Aetiology of PFI following TKA is either implant-related, soft-tissue-related, or a combination of the 2. The most frequently cited cause is femoral or tibial component internal rotation (IR) [3–5], and when present, revision

arthroplasty is recommended [5,6]. What defines the threshold for malrotation has not been clearly defined. Furthermore, revision of components that are well fixed is a morbid procedure.

When implant position is satisfactory, addressing the soft-tissue imbalance is required. The medial patellofemoral ligament (MPFL) prevents the patella from subluxing laterally in early flexion [7]. Reconstruction of the MPFL (MPFLr) has been used successfully in the treatment of lateral patella instability in the native knee [8–10]. However, patients experiencing patella instability after arthroplasty are comparatively older and may have poor bone quality [11,12]. Only a small number of studies with low numbers of patients have reported outcomes of patients with PFI after TKA treated using MPFLr [13,14]. Furthermore, the indications for

* Corresponding author. Department of Orthopaedic Surgery, Hôpital de la Croix Rousse - Lyon University, 103 Grande Rue de la Croix Rousse, 69004 Lyon, France. Tel.: +33 646873300.

E-mail address: jobeshatrov1@gmail.com

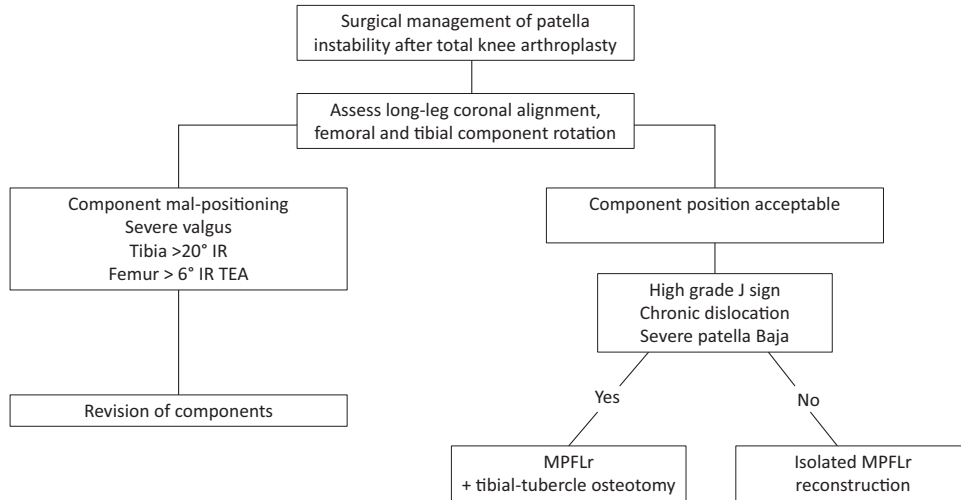


Figure 1. Algorithm for management of patella instability after total knee arthroplasty.

performing MPFLr with or without a tibial tubercle osteotomy (TTO) in a TKA have not been well described previously.

The purpose of this study was to report the clinical and radiological outcomes and the complications at midterm of the surgical management of PFI in patients who had previously undergone TKA using an algorithm that consisted of isolated MPFLr using a double fixation technique, with the addition of a TTO in select indications. The hypothesis was that this strategy could be used successfully to manage PFI after TKA.

Material and methods

Patients

This is a single-center retrospective case-series study of consecutive patients treated for PFI after TKA with MPFLr who had a minimum 12-month follow-up. The technique and algorithm evolved over a 10-year period in this institution to manage PFI after TKA (Fig. 1). Inclusion criteria were radiographic evidence of patella subluxation or dislocation, previous TKA, and no evidence of femoral or tibial component malrotation. Patients were excluded if they had evidence of implant loosening, femoral or tibial malrotation of more than 6° IR, combined femoral-tibial rotation of more than 3°, a hip-knee angle of more than 5° valgus, a preoperative extensor lag, history of quadriceps tendon rupture, and had a prosthesis preventing tunnel creation such as a distal femoral or total femoral replacement. A strict criterion of patella thickness with this technique is not required as the quadriceps tendon autograft is left attached to its insertion point on the patella. Twenty-five patients underwent surgery for PFI after TKA in the study period. Two patients were treated with isolated TTO. One patient who underwent MPFLr suffered repeat dislocation and subsequently underwent revision using a TTO and repeat MPFLr using a double fixation that was an evolved variant of our technique during the study period (Fig. 2).

Rational for implant boundaries

Determining the threshold for femoral and tibial malrotation is difficult. Postoperatively, the posterior condylar axis (PCA) is no longer available for femoral referencing, and so most studies have described using the transepicondylar axis (TEA) as a landmark to measure femoral component positioning on computed tomography

(CT) scans [15,16]. In the current study, the threshold to define malrotation of the femoral component TEA was more than 6° of IR. This is based on the observation that the posterior condylar axis is 3.5° to 0.3° IR to the TEA in a normal population [16]. This is also a limitation set out by the Food and Drug administration [17], and 85% of the normal population falls within this limitation [18]. Tibial rotation malrotation is also not well defined, with variations in definitions and thresholds. Typically, the most prominent point or medial third of the tibial tuberosity is used as a reference point; however, it has previously been shown that the interobserver measurement disagreement is more than 3° in 70% of cases [19]. In the current study, tibial rotation was measured, and the threshold

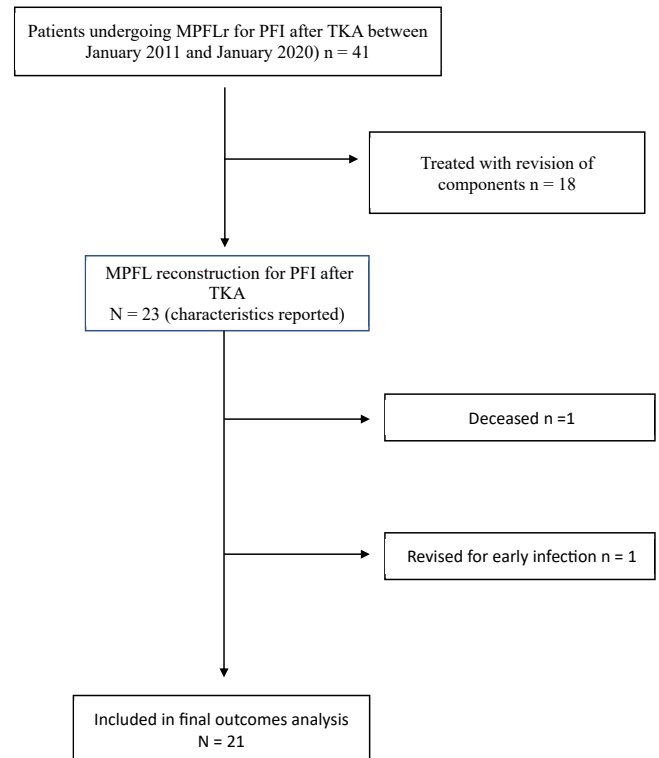


Figure 2. Study flowchart of patella instability after TKA cohort selection.

was set at 20° according to the technique described by Berger et al. which utilizes the most prominent point of the tibial tuberosity [16]. Using this technique, a range of $18^\circ \pm 2.6^\circ$ was described as a limit. An inherent issue with measuring tibial rotation, however, is the wide variation in the position of the tibial tuberosity which has previously been described [20]. In the current study, combined femoral-tibial malrotation of more than 3° was used as a threshold. Previously, it has been observed that 3°–8° of combined IR was associated with PFI in TKA [21]. The coronal limitation of 5° valgus is based on the observation of Bellemans et al. who did not observe any native knees outside this range [18].

Surgery

In all cases, MPFLr was performed using a quadriceps tendon autograft taken from the medial one-third of the quadriceps tendon, leaving the patella attachment undisturbed. The graft is whip-stitched and passed beneath the vastus medialis muscle (Fig. 3). A femoral tunnel is drilled starting from the femoral footprint of the MPFL [22] aiming for the meta-diaphyseal junction laterally. Initially, the quadriceps tendon autograft was fixed by interference screws only. However, due to the observation of poor bone quality in the supracondylar region of the femur, an additional cortical fixation was added with the use of an endobutton in later cases. The graft is tensioned with the knee flexed to approximately 30°–45° and fixed with an interference screw, but a cortical button is added laterally to avoid graft slippage (Fig. 2).

TTO was performed if the patient exhibited a grade-3 J-sign during the examination under anaesthesia, if the quadriceps mechanism was deemed to be shortened (eg, chronic dislocations [>3 months]), or in cases of severe patella baja. Briefly, the J-sign evaluation was performed by estimating the lateral translation of

the patella throughout the knee motion. A grade 3 J-sign was defined as lateral dislocation of the patellar in terminal extension [23,24].

TTO was performed (Fig. 4) using an oscillating saw to create an osteotomy that was 6 cm in length, 1.5 cm deep proximally, tapered distally, and hinged open laterally. All TTOs were fixed using two 3.5-mm cortical screws. Medialisation was performed up to 10 mm or until correction of the J-sign, and proximalization in cases of quadriceps shortening or severe patella baja. A 1-cm bone bridge was preserved proximally to avoid conflict with the tibial tray. If a TTO was performed, it was done prior to the MPFLr for all cases. Patient outcomes were described for the entire cohort, and a further subgroup analysis was performed based on surgery type; isolated MPFLr using an interference screw only (group 1), MPFLr with an interference screw only and TTO (group 2), and MPFLr with double fixation and TTO (group 3.)

Clinical and radiological outcomes

Patients were assessed clinically with Kujala [25] and International Knee Score (IKS) scores at a minimum 12-month follow-up and radiographically to measure Caton-Deschamps index [26], patella tilt (PT), and patella shift (Figs. 4 and 5). All CT and radiographic measurements were independently performed by 2 orthopaedic surgeons who were blinded to the patient outcomes, using a commercially available software program (Picture Archiving Communication System; Carestream Health, Rochester, NY). Femoral and femoral-tibial rotation were measured using techniques previously described [15,16,21]. Patella height measured using the Caton-Deschamps index [26] and patella skyline views were taken at an angle of 45°, and from this, PT and PS were measured as described by Merchant et al. [27].

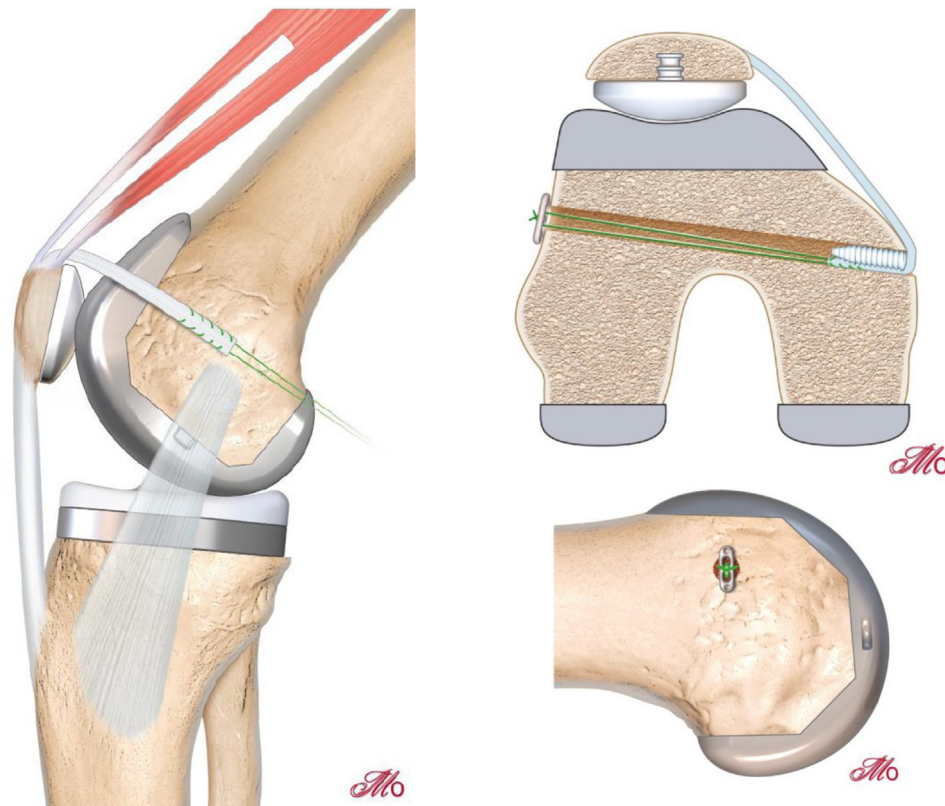


Figure 3. Medial one-third of the quadriceps tendon is used as an autograft for MPFLr and attached using double fixation with an interference screw and a cortical button.

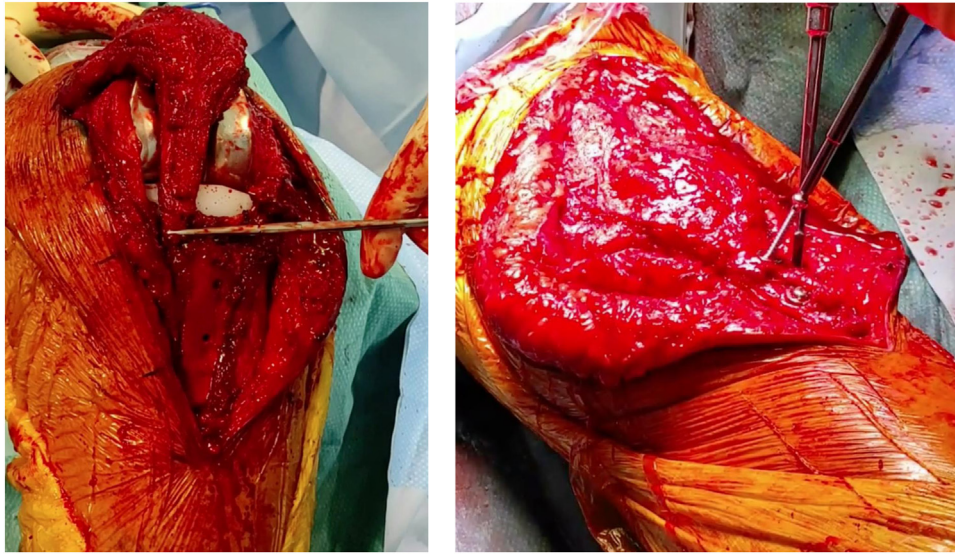


Figure 4. When indicated, a tibial tubercle osteotomy (TTO) was performed that was 6 cm in length, 1.5 cm deep proximally, tapered distally, and hinged open laterally. All TTOs were fixed using two 3.5-mm cortical screws.

Statistical analysis

The statistical analysis was performed using SPSS version 21.0 (SPSS Inc., Chicago, IL). Descriptive statistic was used to report all collected data; continuous parameters were presented as mean values with standard deviation. Shapiro-Wilk test was used to assess the normal distribution for all the evaluated data. Baseline characteristics were reported using mean and standard deviations. Means between surgical technique groups were compared using the Fisher-exact test and Kruskal-Wallis tests. A *P* value < .05 was considered significant.

Ethical approval

All procedures were performed in accordance with the ethical standards of the institutional and/or national research committee, the 1964 Helsinki declaration, and its later amendments, or comparable ethical standards.

Results

A total of 22 patients (23 knees) were included in the final analysis. Patient characteristics are summarized in [Table 1](#). PFI occurred in posterior-stabilized implants in 18 cases (78.2%) and in hinge implants in 5 cases (21.8%). Sixty-five percent of patients previously had at least 2 operations to their knee, indicating the often-complex nature of this surgery. One patient underwent early revision for deep infection, and another died within 3 months of surgery.

Clinical outcomes

Outcomes are reported for the remaining 21 knees and are summarized in [Tables 2](#) and [3](#). The mean follow-up period was 51.4 months (range 12-72). Preoperative and postoperative comparisons demonstrated significant improvements in the IKS scores, PT, and patella shift ([Table 3](#)).

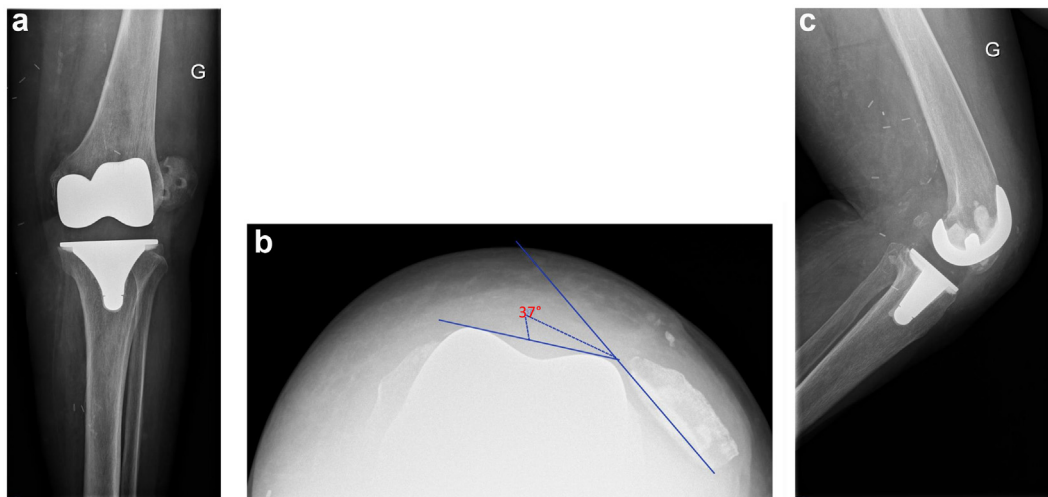


Figure 5. Left total knee arthroplasty with patella dislocation preoperatively. (a) Anteroposterior view. (b) Skyline view showing 37° tilt. (c) Lateral view.

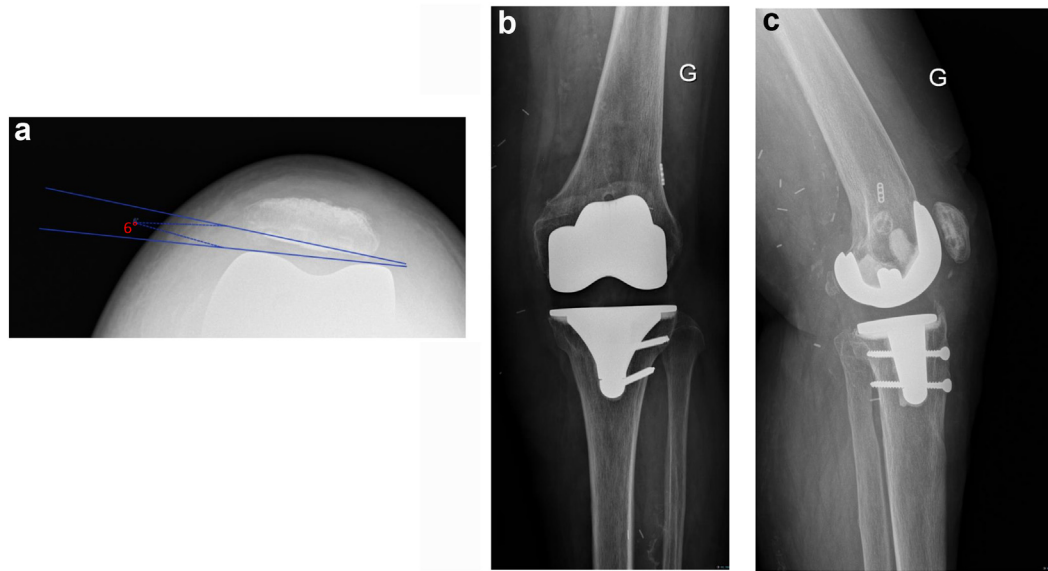


Figure 6. Postoperative radiographs (12 weeks) of the patient from Figure 5 with MPFLr using double fixation and tibial tubercle osteotomy. (a) Skyline view demonstrating patella now centered with a patella tilt of 6°. (b) Anteroposterior radiograph, the endobutton can be seen sitting flush on the lateral cortex. (c) Lateral profile demonstrating the tibial tubercle osteotomy and tunnel position. The osteotomy is united at 3 months after the surgery.

Table 1
Patient characteristics (n = 23).

Characteristics	N	Mean	Std. deviation	Maximum	Minimum
Age at MPFL surgery	23	68.14	8.88	83	49
BMI	23	31.14	6.25	44	22
Time from primary	23	12.95	16.93	60	0.5
Preop. flexion	23	116.67	18.46	140	70
IKS knee preop	23	59.30	15.56	92	35
IKS function preop	23	49.20	13.46	70	15
IKS total preop	23	108.65	24.54	162	55
Hip-knee-ankle angle	23	178.07	2.52	184	174
CDI preop	23	0.96	0.47	2.8	0.45
Tibial rotation	19	7.68	3.62	13	-3
Femoral-tibial rotation	19	-0.05	1.27	2	-3
Femoral rotation	19	-0.16	1.49	2	-3
Patella thickness	19	12.66	2.32	18	10
American Society of Anesthesiologists (ASA) score					
				N	%
1				1	4.3
2				13	56.5
3				9	39.1
Side					
Left				12	52.2
Right				11	47.8
Gender					
F				15	65.2
M				8	34.8
Operations prior to MPFL					
1				8	34.8
2				5	21.7
3				4	17.4
4				5	21.7
6				1	4.3
Indication for prosthesis					
High tibial osteotomy (HTO)				1	4.3
Idiopathic				12	52.2
Posttraumatic				3	13
Revision (aseptic)				1	4.3
Revision (stiffness)				1	4.3
Revision (pain)				1	4.3
Revision (sepsis)				3	13
Rickets				1	4.3
Prosthesis type					
Hinge				5	21.7
Posterior stabilized				18	78.3

BMI, body mass index; CDI, Caton-Deschamps Index.

Femoral rotation, negative value = external rotational.

Femoral tibial rotation, negative rotation = external rotation.

Table 2
Postoperative outcomes (n = 21).

Outcome	N	Mean	Std. deviation	Minimum	Maximum
Follow-up (mo)	21	51.48	23.67	12.00	72.00
Postoperative flexion (°)	21	112.86	15.70	75.00	140.00
Preoperative to postoperative flexion change (°)	21	3.10	19.52	-20.00	55.00
IKS score postop.	21	77.67	13.18	55.00	96.00
IKS function score postop.	21	75.29	23.30	15.00	100.00
IKS total score postop.	21	153.62	32.45	85.00	195.00
Kujala score postop.	21	60.29	10.97	37.00	77.00
PS postop. (mm)	21	0.93	1.19	0.00	3.00
PT postop. (°)	21	7.49	7.43	1.00	30.00
CDI postop.	21	0.75	0.20	0.30	1.10
TTO union time (wk)	10	14.86	4.88	10.00	20.00

CDI, Caton-Deschamps Index; PS, patella shift (+ve value indicates lateral translation); PT, patella tilt (+ve value indicates lateral tilt).

In a subgroup analysis (Table 4), 11 patients received an isolated MPFLr using an interference screw fixation, 4 had had a TTO with the MPFLr fixed using an interference screw, and 6 had a TTO plus MPFLr with a double fixation with an endobutton and a screw. While Kujala and IKS scores were higher in patients receiving double fixation of the MPFLr graft and a TTO than those in patients receiving MPFLr with interference fixation, these differences were not significant ($P = .081$). There was no significant difference between the 3 groups when comparing flexion range change. A further analysis comparing outcomes and alignment by prosthesis type (hinge vs posterior-stabilized [PS]) was performed and found significant results between groups (Table 5); however, the PS group did have a wider range of clinical outcome scores as evidenced by the greater standard deviations.

Radiographic outcomes

Preoperative CT analysis was available for 19 patients and revealed an average femoral component rotation of 0.16° external rotation in relation to the TEA (range 2° IR to 3° external rotation).

Radiographic outcomes revealed superior results with additional endobutton fixation (Fig. 6); however, this difference was not statistically significant. The mean PT and patella shift following isolated MPFLr using interference fixation was 9.53° and 1.35 cm, respectively, compared to 3.25° ($P = .111$) and 0.27 cm ($P = .433$) with additional endobutton fixation. MPFLr had a patella-lowering effect, 0.97 preoperatively to 0.74 postoperatively ($P = .069$).

Complications

There were 6 (26.1%) complications consisting of 1 deep infection, 1 superficial infection, 1 tibial fracture, 1 osteonecrosis of the

patella, 1 tendinopathy of the patellar tendon, and 1 implant revision because of pain. The patient with the superficial infection was successfully treated with a wound debridement and antibiotics but had a delayed union of their TTO (20 weeks). The tibial fracture occurred following a TTO and was managed successfully with plate fixation. The osteonecrosis was diagnosed using radiographs and scintigraphy. The patient was managed conservatively in a brace and did not experience fracture or develop an extensor lag. There was 1 mechanical failure which occurred in the isolated MPFL with a screw fixation group. The patient subsequently underwent revision MPFLr with additional endobutton fixation for the graft, and at 24-month follow-up, the patient was walking independently and had no evidence of recurrent instability.

Discussion

The most important finding of this study was that isolated MPFLr is a satisfactory option to treat PFI after TKA in the appropriately selected patients. The addition of cortical fixation in the surgical technique yielded modestly superior clinical and radiological results to graft fixation with an interference screw alone. MPFLr with the addition of a TTO in select cases demonstrated this approach can achieve good clinical results, as evidenced by a number of recurrences and an improvement in patient function following the surgery.

Surgical management of patella instability after TKA broadly follows 1 of 2 pathways (Fig. 1), consisting of either a revision of components or a patella stabilization with soft-tissue, bony, or combined procedures. The results of patients treated with revision arthroplasty of the tibial and femoral components for PFI after TKA were recently described by Warschawski et al. [5]. In this study, patients underwent revision based on an intraoperative

Table 3
Comparison of preoperative and postoperative outcomes.

Outcome	Mean	Std. deviation	95% confidence interval of the difference		P
Preoperative flexion (°)	110.48	26.17			
Postoperative flexion (°)	112.86	15.70	-11.44547	6.68357	.590
IKS score preop.	57.90	16.46			
IKS score postop.	77.67	13.18	-27.29383	-12.22998	<.0001
IKS function score preop.	49.24	14.48			
IKS function score postop.	75.29	23.30	-38.04048	-14.05475	<.0001
IKS total score preop.	107.29	26.43			
IKS total score postop.	153.62	32.45	-63.96196	-28.7047	<.0001
CDI preop.	0.98	0.48			
CDI postop.	0.75	0.20	-0.02117	0.48726	.070

CDI, Caton-Deschamps Index.
 $P > .05 =$ significant.

Table 4
Outcomes between surgery groups.

Outcome	Surgery	N	Mean	Std. deviation	95% confidence interval for mean		Minimum	Maximum	<i>P</i> ^b
					Lower bound	Upper bound			
Age at MPFL surgery (y)	1	11	69.00	9.78	62.43	75.57	53	79	
	2	4	68.25	4.43	61.21	75.29	64	73	
	3	6	72.17	5.78	66.10	78.23	66	83	
BMI (kg/m ²)	1	11	29.27	6.07	25.20	33.35	22	44	.648
	2	4	35.50	5.07	27.44	43.56	31	42	
	3	6	33.67	4.37	29.08	38.25	29	40	
Flexion change (°)	1	11	9.09	19.85	-4.25	22.43	-20	55	.072
	2	4	-7.50	22.17	-42.78	27.78	-30	20	
	3	6	-0.83	15.94	-17.56	15.90	-20	25	
Hip-knee-ankle angle (°)	1	11	177.68	1.85	176.44	178.92	174	180	.262
	2	4	180.50	3.87	174.34	186.66	175	184	
	3	6	178.17	1.72	176.36	179.97	176	181	
PS postoperatively (°)	1	11	1.35	1.42	0.40	2.31	0	3	.433
	2	4	0.75	0.96	-0.77	2.27	0	2	
	3	6	0.27	0.32	-0.07	0.60	0	0.7	
PT postoperatively (°)	1	11	9.53	9.20	3.34	15.71	2	30	.133
	2	4	8.25	4.99	0.31	16.19	3	13	
	3	6	3.25	2.32	0.82	5.68	1	7	
CDI postoperatively	1	11	0.77	0.15	0.67	0.88	0.6	1.05	.997
	2	4	0.77	0.11	0.59	0.94	0.63	0.9	
	3	6	0.70	0.33	0.36	1.04	0.3	1.1	
Tibial rotation ^a (°)	1	11	7.45	4.32	4.55	10.36	-3	12	.923
	2	2	8.50	0.71	2.15	14.85	8	9	
	3	4	8.75	3.40	3.33	14.17	6	13	
Femoral-tibial rotation ^a (°)	1	11	0.00	1.55	-1.04	1.04	-3	2	.736
	2	2	0.50	0.71	-5.85	6.85	0	1	
	3	4	-0.25	0.96	-1.77	1.27	-1	1	
Femoral rotation ^a (°)	1	11	0.29	1.66	-0.83	1.41	-3	2	.203
	2	2	-0.70	0.14	-1.97	0.57	-0.8	-0.6	
	3	4	-0.75	1.50	-3.14	1.64	-3	0	
Patella thickness (mm)	1	11	12.68	2.26	11.16	14.20	10	18	.953
	2	2	14.00	4.24	-24.12	52.12	11	17	
	3	4	12.75	2.50	8.77	16.73	10	16	
IKS knee score postoperatively	1	11	72.45	13.92	63.10	81.81	55	95	.174
	2	4	84.50	13.96	62.28	106.72	65	96	
	3	6	82.67	7.97	74.31	91.03	70	92	
IKS function score postoperatively	1	11	69.00	27.53	50.50	87.50	15	100	.326
	2	4	75.00	21.98	40.02	109.98	50	100	
	3	6	87.00	10.71	75.76	98.24	68	100	
IKS total score postoperatively	1	11	141.45	35.27	117.76	165.15	85	195	.262
	2	4	159.50	35.00	103.81	215.19	115	193	
	3	6	172.00	15.18	156.07	187.93	148	192	
Kujala score postoperatively	1	11	55.45	11.02	48.05	62.86	37	71	.081
	2	4	64.75	11.79	46.00	83.50	49	77	
	3	6	66.17	6.79	59.04	73.30	57	76	

BMI, body mass index; CDI, Caton-Deschamps Index; PS, patella shift (+ve value indicates lateral translation); PT, patella tilt (+ve value indicates lateral tilt).
Surgery groups: 1 = isolated MPFL (screw fixation) (N = 11); 2 = MPFL + TTA (screw fixation) (N = 4); 3 = MPFL (endobutton + screw) + TTA (N = 6).

Flexion change, preoperatively to postoperatively.

^a Positive value indicates internal rotation.

^b Kruskal-Wallis test. *P* < .05 = significance.

assessment of component positioning. Revision was performed if malrotation according to anatomical landmarks was deemed to be present. The authors reported over 80% of cases had tibial IR requiring revision arthroplasty. In most cases, patients required a condylar-constrained implant used as the revision prosthesis. Several problems exist with this approach. Primarily, the anatomical landmarks used are not precise. Second, a decision to revise well-fixed implants cannot be made until after the exposure is performed. Third, revision of well-fixed implants invariably is a morbid procedure that causes bone loss and soft-tissue damage as indicated by the high rate of need for a condylar-constrained implant with this approach, and finally, highly constrained implants in registry studies have twice the failure rate of primary implants at 10-year follow-up [28]. While revision arthroplasty may be required in certain cases of PFI, the approach in the current study describes an alternative surgical management in select

indications that allows for retention of the prosthesis and demonstrates satisfactory results.

Previously published outcomes of MPFLr in this population are limited to small case series or case reports [13,14,29–31] (Table 6). In the largest previous series published on this topic, van Gennip et al. treated 9 patients with a mean follow-up of 33 months [14]. In this study, patients had an MPFLr using interference fixation of a quadriceps graft combined with either a lateral release or TTO. The authors reported a median postoperative tilt of 15° and 1 recurrence of instability [14]. Lamotte et al. treated 6 patients using gracilis autograft for MPFLr with a combination of anchor fixation in the patella and endobutton for the femoral tunnel [13]. One patient had ongoing instability [13]. Endobutton fixation using a hamstring autograft has been reported in several case reports in combination with a lateral release to correct patella instability after TKA [29,32]. The technique we describe to have evolved during this

Table 5
Comparison between prosthesis types.

Outcome	Prosthesis	N	Mean	Std. deviation	P value ^a
IKS preop.	1	6	61.5	15.4	0.569
	2	15	56.5	17.2	
IKS function preop.	1	6	51.7	13.3	0.733
	2	15	48.3	15.3	
IKS total preop.	1	6	113.2	22.5	0.470
	2	15	104.9	28.2	
IKS knee postop.	1	6	79.8	9.9	0.622
	2	15	76.8	14.5	
IKS function postop.	1	6	74.5	9.5	0.340
	2	15	75.6	27.3	
IKS total postop.	1	6	156.7	18.5	0.340
	2	15	152.4	37.1	
Kujala	1	6	63.3	7.5	0.970
	2	15	59.1	12.1	
HKA	1	6	179.8	2.9	0.424
	2	15	177.8	2.0	
PS	1	6	0.7	1.0	0.132
	2	15	1.0	1.3	
PT	1	6	5.6	3.6	0.910
	2	15	8.3	8.5	
CDI postop.	1	6	0.7	0.2	0.922
	2	15	0.8	0.2	

CDI, Caton-Deschamps Index; HKA, hip-knee-ankle angle; PS, patella shift (+ve value indicates lateral translation); PT, patella tilt (+ve value indicates lateral tilt). Group 1, posterior-stabilized; group 2, hinge prosthesis. Flexion change, preoperatively to postoperatively.

^a Kruskal-Wallis test. *P* < .05 = significance.

study period differs in a way that the graft is fixed using both an interference screw and an endobutton to gain cortical fixation. The current study is the largest series of patients with the longest follow-up using MPFLr to treat PFI after TKA and demonstrates it is a valuable method of surgical treatment for a difficult problem.

The current study demonstrated improvement in clinical outcomes using MPFLr to manage PFI after TKA. All patients had increased IKS scores postoperatively. It should be noted, however, that the mean preoperative IKS score was very low, reflecting the devastating effect of PFI after TKA. Only 1 other study [13] has reported Kujala scores albeit in 6 patients for PFI after TKA, with a mean of 53.5 (32-74). In the current study, the mean Kujala score achieved was 60.3, with a wide range of 37-77. The results show

that while patients will improve following this surgery, expectations of the final function should be tempered to understand that the final result will, in most cases, be inferior to those achieved following primary TKA. Furthermore, no significant differences were found between groups when analyzing patients by surgery type (TTO + MPFLr compared to MPFLr alone) or prosthesis type (PS vs hinge). However, the strength of any conclusions is limited by the small sample size in this study despite it being the largest of its type in the literature.

Careful consideration should be given to the addition of a TTO in the management of a PFI after TKA. In our institution, patients having surgery for PFI after TKA prior to any incision being performed have an examination under anaesthesia (EUA), and the presence of a grade 3 J-sign is an indication for TTO. Additional indications include severe patella baja or sever quadriceps shortening as is the case in chronic patella dislocations. High-grade J-signs in native PFI have been associated with abnormal patella height [33], muscle imbalance [34], genu valgum [35], and torsional abnormalities [36]. The rationale for the addition of a TTO is based on understanding the role of the MPFL, which is to entrain the patella into the trochlear groove in the first 30° of flexion and is not robust enough to withstand the forces that result in a grade 3 J-sign. This approach has not been described previously in TKA but is supported by the observation that a positive J-sign has been shown to be an independent predictor following isolated MPFLr failure in native patella dislocations [37] and leads to MPFLr graft laxity if an associated TTO is not performed [24].

The double fixation is a critical step of this procedure, as it provides additional stability to the graft. Furthermore, it addresses the challenge of poor bone quality that can affect graft stability and is frequently encountered in this region following TKA. Bone mineral density in the supracondylar region of the femur following TKA has been observed to decrease by 20%-45% following TKA [11,12]. Most studies that have reported on MPFLr to treat patella instability after TKA to date have used an interference screw fixation method [13,14] which relies on compressing the graft against bone to prevent slippage. The load to failure of grafts using interference screw fixation has been shown to be directly related to bone mineral density, with lower density bone showing graft slippage and failure at significantly lower forces during biomechanical testing [38]. Reliance on interference fixation in this scenario may lead to recurrence of instability.

Table 6
Published outcomes following MPFLr or tibial tubercle osteotomy to treat patella instability after total knee arthroplasty.

Study	Year	Cases	Technique	Follow-up	Outcomes	Radiographic outcomes
Current study	2021	21	Quads tendon autograft fixed with endobutton (n = 6) or interference fixation (n = 15)	Mean 51 mo (min. 12)	Kujala, 60 (37-77); IKS total score, 153.63 (85-195); ROM 113° (75°-140°) 1 recurrence	CDI, 0.75; patella tilt, 7.5; patella shift, 0.93
van Gennip et al. [14]	2012	9	7 MPFLr + lateral release 2 – Additional TTO Semitendinosus - 2 Quadriceps tendon – 6 Allograft – 1 Either interference or anchor fixation	Mean 33 mo (10-48)	Bartlett score “displayed a diverse picture”	ROM not reported. No complications. One recurrence of instability. Patella tilt 15
Lamotte et al. [13]	2016	6	Double bundle gracilis autograft, 2 anchors for patella fixation Interference femoral fixation	Mean 23 (6-46)	Kujala, mean 52.6 (32-69); IKDC, 38.2 (23-47)	No recurrence. Patella tilt 13
Kirk et al. [30]	1992	14	TTO ± lateral release	Mean 2 y (1-4)	HSS score, 82 (range 61-95); ROM 112	1 Nonunion. No recurrence
Nakajima et al. [31]	2010	1	TTO + lateral release	12 mo	ROM, patella tilt, patella height	Patella height 1.19 (Insall-Salvati); patella tilt 14.7; ROM 120
Goto et al. [29]	2014	1	MPFL + lateral release (semi-tendinosus with endobutton)	12 mo	ROM	10-110 No complication

CDI, Caton-Deschamps Index; ROM, range of motion; HSS, hospital for special surgery knee rating scale; IKDC, international knee documentation committee.

The complication rate in the current study was high (26.1%). Some studies have previously reported a complication rate of 0% albeit a shorter follow-up following MPFLr for PFI after TKA [14]. The complications experienced in this study are heterogeneous, including patella osteonecrosis, quadriceps tendinopathy, superficial and deep infection, and pain requiring revision. The nature and incidence of the complications reflect the complex nature of patients presenting with this problem. In the current study, most patients had already undergone more than 2 operations prior to receiving MPFLr, and both the clinician and patient should be mindful of the risks associated with undertaking surgery for PFI after TKA.

This study had several weaknesses. First, the number of patients in this study was small, owing to the rare nature of this complication. Despite this, the current study is the largest published series of patients treated for PFI after TKA in the literature. Second, this study was retrospective in nature and is thus subject to the biases that effect such study designs. Finally, this was an observational study with no comparison group, and thus, superiority of this technique for managing PFI in TKA cannot be proven from this study. Nonetheless, the purpose of this study was to determine if MPFLr could provide satisfactory outcomes in this population, and the incidence of this complication is very low, limiting the ability to perform comparative studies.

The findings of the current study provide important data to inform orthopaedic surgeons management algorithm for a rare but devastating problem after TKA (Fig. 1). MPFLr can provide satisfactory outcomes in appropriately select patients. The addition of suspensory fixation, and when indicated a TTO, should be considered due to the unique challenges posed in this patient population.

Conclusion

MPFLr in appropriately selected patients is a satisfactory option to treat PFI following TKA. Accommodating for the variable bone quality in this specific population, suspensory fixation in addition to an interference screw showed improved functional and radiological outcomes compared with fixation with an interference screw alone.

Funding

This research did not receive any specific grant from funding agencies in the public, commercial, or not-for-profit sectors.

Conflicts of interest

The authors declare the following financial interests/personal relationships which may be considered as potential competing interests:

E. Servien is a consultant for Corin and receives institutional research support from Corin and Amplitude. S. Lustig receives royalties from Smith & Nephew and Stryker; is a consultant for Stryker, Smith & Nephew, Heraeus, DePuy Synthes, and Groupe Lepine; receives institutional research support from Corin and Amplitude; and is in the editorial board of the *Journal of Bone and Joint Surgery* (American). All the other authors declare that they have no conflict of interest.

For full disclosure statements refer to <https://doi.org/10.1016/j.artd.2022.04.006>.

Ethical approval

All procedures were performed in accordance with the ethical standards of the institutional and/or national research committee,

the 1964 Helsinki declaration, and its later amendments, or comparable ethical standards.

References

- [1] Scuderi GR, Insall JN, Scott NW. Patellofemoral pain after total knee arthroplasty. *J Am Acad Orthop Surg* 1994;2:239–246. <https://doi.org/10.5435/00124635-199409000-00001>.
- [2] Rand JA. The patellofemoral joint in total knee arthroplasty. *J Bone Joint Surg Am* 1994;76:612–620. <https://doi.org/10.2106/00004623-199404000-00019>.
- [3] Anouchi YS, Whiteside LA, Kaiser AD, Milliano MT. The effects of axial rotational alignment of the femoral component on knee stability and patellar tracking in total knee arthroplasty demonstrated on autopsy specimens. *Clin Orthop Relat Res* 1993;287:170–177.
- [4] Akagi M, Matsusue Y, Mata T, Asada Y, Horiguchi M, Iida H, et al. Effect of rotational alignment on patellar tracking in total knee arthroplasty. *Clin Orthop Relat Res* 1999;366:155–163. <https://doi.org/10.1097/00003086-199909000-00019>.
- [5] Warschawski Y, Garceau S, Frenkel Rutenberg T, Dahduli O, Wolfstadt J, Backstein D. Revision total knee arthroplasty for patellar dislocation in patients with malrotated TKA components. *Arch Orthop Trauma Surg* 2020;140:777–783. <https://doi.org/10.1007/s00402-020-03468-6>.
- [6] Malo M, Vince KG. The unstable patella after total knee arthroplasty: etiology, prevention, and management. *J Am Acad Orthop Surg* 2003;11:364–371. <https://doi.org/10.5435/00124635-200309000-00009>.
- [7] Dandy DJ. Chronic patellofemoral instability. *J Bone Joint Surg Br* 1996;78:328–335.
- [8] Astur DC, Gouveia GB, Borges JH, Astur N, Ariani GG, Kaleka CC, et al. Medial patellofemoral ligament reconstruction: a longitudinal study comparison of 2 techniques with 2 and 5-years follow-up. *Open Orthop J* 2015;9:198–203. <https://doi.org/10.2174/1874325001509010198>.
- [9] Bouras T, Edmond U, Brown A, Gallacher P, Barnett A. Isolated medial patellofemoral ligament reconstruction significantly improved quality of life in patients with recurrent patella dislocation. *Knee Surg Sports Traumatol Arthrosc* 2019;27:3513–3517. <https://doi.org/10.1007/s00167-019-05447-w>.
- [10] Deie M, Ochi M, Sumen Y, Adachi N, Kobayashi K, Yasumoto M. A long-term follow-up study after medial patellofemoral ligament reconstruction using the transferred semitendinosus tendon for patellar dislocation. *Knee Surg Sports Traumatol Arthrosc* 2005;13:522–528. <https://doi.org/10.1007/s00167-005-0641-x>.
- [11] Andersen MR, Winther NS, Lind T, Schroder HM, Mork Petersen M. Bone remodeling of the distal femur after uncemented total knee arthroplasty-A 2-year prospective DXA study. *J Clin Densitom* 2018;21:236–243. <https://doi.org/10.1016/j.jocd.2017.05.001>.
- [12] Petersen MM, Lauritzen JB, Pedersen JG, Lund B. Decreased bone density of the distal femur after uncemented knee arthroplasty. A 1-year follow-up of 29 knees. *Acta Orthop Scand* 1996;67:339–344. <https://doi.org/10.3109/17453679609002327>.
- [13] Lamotte A, Neri T, Kawaye A, Boyer B, Farizon F, Philippot R. Medial patellofemoral ligament reconstruction for patellar instability following total knee arthroplasty: a review of 6 cases. *Orthop Traumatol Surg Res* 2016;102:607–610. <https://doi.org/10.1016/j.otsr.2016.03.018>.
- [14] van Gennip S, Schimmel JJ, van Hellemond GG, Defoort KC, Wymenga AB. Medial patellofemoral ligament reconstruction for patellar maltracking following total knee arthroplasty is effective. *Knee Surg Sports Traumatol Arthrosc* 2014;22:2569–2573. <https://doi.org/10.1007/s00167-012-2269-y>.
- [15] Chauhan SK, Clark GW, Lloyd S, Scott RG, Bredahl W, Sikorski JM. Computer-assisted total knee replacement. A controlled cadaver study using a multi-parameter quantitative CT assessment of alignment (the Perth CT Protocol). *J Bone Joint Surg Br* 2004;86:818–823. <https://doi.org/10.1302/0301-620x.86b6.15456>.
- [16] Berger RA, Rubash HE, Seel MJ, Thompson WH, Crossett LS. Determining the rotational alignment of the femoral component in total knee arthroplasty using the epicondylar axis. *Clin Orthop Relat Res* 1993;286:40–47.
- [17] MacDessi SJ. Restricted kinematic alignment in total knee arthroplasty: scientific exploration involving detailed planning, precise execution, and knowledge of when to abort. *Arthroplast Today* 2021;10:24–26. <https://doi.org/10.1016/j.artd.2021.05.024>.
- [18] Bellemans J, Colyn W, Vandenuecker H, Victor J. The Chitranjan Ranawat award: is neutral mechanical alignment normal for all patients? The concept of constitutional varus. *Clin Orthop Relat Res* 2012;470:45–53. <https://doi.org/10.1007/s11999-011-1936-5>.
- [19] Indelli PF, Graceffa A, Marcucci M, Baldini A. Rotational alignment of the tibial component in total knee arthroplasty. *Ann Transl Med* 2016;4:3. <https://doi.org/10.3978/j.issn.2305-5839.2015.12.03>.
- [20] Cobb JP, Dixon H, Dandachli W, Iranpour F. The anatomical tibial axis: reliable rotational orientation in knee replacement. *J Bone Joint Surg Br* 2008;90:1032–1038. <https://doi.org/10.1302/0301-620X.90B8.19905>.
- [21] Berger RA, Crossett LS, Jacobs JJ, Rubash HE. Malrotation causing patellofemoral complications after total knee arthroplasty. *Clin Orthop Relat Res* 1998;356:144–153. <https://doi.org/10.1097/00003086-199811000-00021>.
- [22] Servien E, Fritsch B, Lustig S, Demey G, Debarge R, Lapra C, et al. In vivo positioning analysis of medial patellofemoral ligament reconstruction. *Am*

- J Sports Med 2011;39:134–139. <https://doi.org/10.1177/0363546510381362>.
- [23] Franciozi CE, Ambra LF, Albertoni LJ, Debieux P, Rezende FC, Oliveira MA, et al. Increased femoral anteversion influence over surgically treated recurrent patellar instability patients. *Arthroscopy* 2017;33:633–640. <https://doi.org/10.1016/j.arthro.2016.09.015>.
- [24] Zhang Z, Zhang H, Song G, Zheng T, Feng H. A pre-operative grade 3 J-sign adversely affects short-term clinical outcome and is more likely to yield MPFL residual graft laxity in recurrent patellar dislocation. *Knee Surg Sports Traumatol Arthrosc* 2020;28:2147–2156. <https://doi.org/10.1007/s00167-019-05736-4>.
- [25] Kujala UM, Jaakkola LH, Koskinen SK, Taimela S, Hurme M, Nelimarkka O. Scoring of patellofemoral disorders. *Arthroscopy* 1993;9:159–163. [https://doi.org/10.1016/s0749-8063\(05\)80366-4](https://doi.org/10.1016/s0749-8063(05)80366-4).
- [26] Caton J, Deschamps G, Chambat P, Lerat JL, Dejourn H. [Patella infera. Apropos of 128 cases]. *Rev Chir Orthop Reparatrice Appar Mot* 1982;68:317–325.
- [27] Merchant AC, Mercer RL, Jacobsen RH, Cool CR. Roentgenographic analysis of patellofemoral congruence. *J Bone Joint Surg Am* 1974;56:1391–1396.
- [28] Registry. A.N.J. Australia National Joint registry report: 2019. <https://aoanjrr.sahmri.com/documents/10180/668596/Hip%2C+Knee+%26+Shoulder+Arthroplasty/c287d2a3-22df-a3bb-37a2-91e6c00bfcf0>; 2019. [Accessed 26 December 2021].
- [29] Goto T, Hamada D, Iwame T, Suzue N, Takeuchi M, Egawa H, et al. Medial patellofemoral ligament reconstruction for patellar dislocation due to rupture of the medial structures after total knee arthroplasty: a case report and review of the literature. *J Med Invest* 2014;61:409–412. <https://doi.org/10.2152/jmi.61.409>.
- [30] Kirk P, Rorabeck CH, Bourne RB, Burkart B, Nott L. Management of recurrent dislocation of the patella following total knee arthroplasty. *J Arthroplasty* 1992;7:229–233. [https://doi.org/10.1016/0883-5403\(92\)90041-n](https://doi.org/10.1016/0883-5403(92)90041-n).
- [31] Nakajima A, Watanabe H, Rokkaku T, Koda M, Yamada T, Murakami M. The Elmslie-Trillat procedure for recurrent patellar subluxation after total knee arthroplasty. *J Arthroplasty* 2010;25:1170.e1–1170.e5. <https://doi.org/10.1016/j.arth.2009.09.008>.
- [32] Asada S, Akagi M, Mori S, Hamanishi C. Medial patellofemoral ligament reconstruction for recurrent patellar dislocation after total knee arthroplasty. *J Orthop Sci* 2008;13:255–258. <https://doi.org/10.1007/s00776-007-1219-x>.
- [33] Ward SR, Terk MR, Powers CM. Patella alta: association with patellofemoral alignment and changes in contact area during weight-bearing. *J Bone Joint Surg Am* 2007;89:1749–1755. <https://doi.org/10.2106/JBJS.F.00508>.
- [34] Pal S, Draper CE, Fredericson M, Gold GE, Dejp SL, Beaupre GS, et al. Patellar maltracking correlates with vastus medialis activation delay in patellofemoral pain patients. *Am J Sports Med* 2011;39:590–598. <https://doi.org/10.1177/0363546510384233>.
- [35] Frosch KH, Schmeling A. A new classification system of patellar instability and patellar maltracking. *Arch Orthop Trauma Surg* 2016;136:485–497. <https://doi.org/10.1007/s00402-015-2381-9>.
- [36] Dickschas J, Harrer J, Pfefferkorn R, Strecker W. Operative treatment of patellofemoral maltracking with torsional osteotomy. *Arch Orthop Trauma Surg* 2012;132:289–298. <https://doi.org/10.1007/s00402-011-1303-8>.
- [37] Sappey-Mariniere E, Sonnery-Cottet B, O'Loughlin P, Ouanezar H, Reina Fernandes L, Kouevidjin B, et al. Clinical outcomes and predictive factors for failure with isolated MPFL reconstruction for recurrent patellar instability: a series of 211 reconstructions with a minimum follow-up of 3 years. *Am J Sports Med* 2019;47:1323–1330. <https://doi.org/10.1177/0363546519838405>.
- [38] Nyland J, Kocabey Y, Caborn DN. Insertion torque pullout strength relationship of soft tissue tendon graft tibia tunnel fixation with a bioabsorbable interference screw. *Arthroscopy* 2004;20:379–384. <https://doi.org/10.1016/j.arthro.2004.01.026>.