



HAL
open science

The Pandemic and Your Skin-Direct and Indirect Impact of COVID-19

Mohammad Imran, Xuping Jin, Masood Ali, Pronalis Tapfumaneyi, Pauline Lelasseur, Laure Carlo, Axelle Jude, Alice Le Bourg, Bhavesh Panchal, Arianna Dick, et al.

► **To cite this version:**

Mohammad Imran, Xuping Jin, Masood Ali, Pronalis Tapfumaneyi, Pauline Lelasseur, et al.. The Pandemic and Your Skin-Direct and Indirect Impact of COVID-19. *Cosmetics*, 2023, 10 (1), pp.34. 10.3390/cosmetics10010034 . hal-04069022

HAL Id: hal-04069022

<https://hal.science/hal-04069022v1>

Submitted on 14 Apr 2023

HAL is a multi-disciplinary open access archive for the deposit and dissemination of scientific research documents, whether they are published or not. The documents may come from teaching and research institutions in France or abroad, or from public or private research centers.

L'archive ouverte pluridisciplinaire **HAL**, est destinée au dépôt et à la diffusion de documents scientifiques de niveau recherche, publiés ou non, émanant des établissements d'enseignement et de recherche français ou étrangers, des laboratoires publics ou privés.



Distributed under a Creative Commons Attribution 4.0 International License

Review

The Pandemic and Your Skin—Direct and Indirect Impact of COVID-19

Mohammad Imran ¹, Xuping Jin ^{1,2}, Masood Ali ¹, Pronalis Tapfumaneyi ³, Pauline Lelasseur ⁴, Laure Carlo ⁴, Axelle Jude ⁴, Alice Le Bourg ⁴, Bhavesh Panchal ¹, Arianna Dick ^{1,5}, Keshav Raj Paudel ⁶, Philip M. Hansbro ⁶ and Yousuf Mohammed ^{1,2,*}

¹ Therapeutics Research Group, Frazer Institute, Faculty of Medicine, University of Queensland, Brisbane, QLD 4102, Australia

² School of Pharmacy, University of Queensland, Brisbane, QLD 4102, Australia

³ School of Pharmacy, Rhodes University, Grahamstown, Makhanda 6139, South Africa

⁴ Faculty of Pharmacy, The University of Rennes, 35000 Rennes, France

⁵ Biosciences and Food Technology, School of Science, RMIT University, Melbourne, VIC 3000, Australia

⁶ Centre for Inflammation, Faculty of Science, School of Life Science, Centenary Institute and University of Technology Sydney, Sydney 2007, Australia

* Correspondence: y.mohammed@uq.edu.au; Tel.: +61-433-853-534

Abstract: Apart from well-known respiratory symptoms, less frequent symptoms also appear as a direct result of COVID-19 infection, or as indirect effects of the recommended quarantine and related lifestyle changes. The impact of the COVID-19 pandemic on human skin is predominantly focused on in this article. Cutaneous manifestations, including redness, chilblain-like symptoms (COVID toes), hives or urticaria rash, water blisters, and fishing net-like red-blue patterns on the skin, may appear as accompanying or as systemic COVID-19 symptoms with potential lesions at different skin sites. These symptoms were related to skin phototypes and vitamin D deficiency. Moreover, Black, Asian, and minority ethnic origin patients are found to be more sensitive to COVID-19 infection than Caucasians because of vitamin D deficiency. The region of population with lighter skin phototypes have a significantly higher chance to develop cutaneous manifestations than population with dark skin. In addition, adverse effects, such as skin barrier damage and irritation, may also occur due to extensive personal protective equipment usage (e.g., masks, protective suits, and a few others) and predominately alcohol-based sanitizers. This manuscript covers various aspects of COVID-19 and its clinical skin manifestations.

Keywords: COVID-19; skin manifestations; immunological response; PPEs



Citation: Imran, M.; Jin, X.; Ali, M.; Tapfumaneyi, P.; Lelasseur, P.; Carlo, L.; Jude, A.; Bourg, A.L.; Panchal, B.; Dick, A.; et al. The Pandemic and Your Skin—Direct and Indirect Impact of COVID-19. *Cosmetics* **2023**, *10*, 34. <https://doi.org/10.3390/cosmetics10010034>

Academic Editor: Enzo Berardesca

Received: 21 December 2022

Revised: 8 February 2023

Accepted: 9 February 2023

Published: 15 February 2023



Copyright: © 2023 by the authors. Licensee MDPI, Basel, Switzerland. This article is an open access article distributed under the terms and conditions of the Creative Commons Attribution (CC BY) license (<https://creativecommons.org/licenses/by/4.0/>).

1. Introduction

Since the beginning of the COVID-19 pandemic, millions of people have lost their lives due to the lethal and contagious nature of the virus. The statistical data showed that the virus killed nearly 6.4 million people worldwide, including 1 million people in the United States alone [1]. The effect of the virus was so significant that it drastically affected all age groups of the population. Specifically, the geriatric and pediatric populations were highly affected by the severity of the COVID-19 virus compared to the younger generation [2]. The pandemic waves occurred at different times in different parts of the world, and this contagious virus gripped the world. The severity of the pandemic significantly increased over time and caused a range of manifestations, including skin-related manifestations. Due to the contagious and lethal nature of the virus, people were restricted to staying at their homes without traveling. Consequently, these restrictions on people's lives showed various effects in the forms of physical, mental, and emotional health [3].

People spent several months inside their homes without exposure to enough sunlight to meet a minimum requirement for normal human body homeostasis to prevent various

disease complications. This causes multiple skin manifestations due to the deficiency of sunlight uptake, i.e., synthesis of vitamin D is reduced in the skin, affecting the multiple molecular pathways responsible for normal metabolism and processes [4]. It has been reported that the COVID-19 virus attacks human cells by targeting angiotensin-converting enzyme-2 (ACE-2), and ACE-2 is abundantly expressed in keratinocytes, epidermis, and dermis, which is mainly responsible for the COVID-induced skin manifestations [5]. ACE-2 is not restricted to a specific part of the skin, as it is also expressed in sweat glands and other body tissues. In the case of skin-related disorders, the deteriorated skin allows the entrance and creates an opportunity to penetrate the epidermis and other skin parts. Qiannan Xu et al. demonstrated that the SARS-CoV-2 protein binds with the ACE-2 receptor in the stratum basale and dermis, which pose a higher risk of skin infection for the patient. Apart from skin infection, the most vulnerable organ to this virus was the lungs. The skin diseases such as psoriasis, atopic dermatitis, and any other inflamed skin diseases leave the skin in a more deteriorated condition if left untreated, which becomes an easy target for the virus and enables its transmission [6,7]. In addition, the current therapy of inflammatory disease mediated by COVID-19 has significant effects [1]. Several studies have shown that COVID-19-exposed and non-exposed patients have different therapeutic regimes for skin-related disorders such as pemphigus vulgaris, psoriasis, atopic dermatitis, and acute dermatomyositis [2]. Therefore, the risk–benefit ratio should be considered before initiating any therapy for skin disorders due to the compromised immune system of the patients.

Yuka et al. examined and demonstrated the impact of COVID-19 on skin cancer diagnosis. The findings revealed that the pandemic delayed skin cancer diagnosis due to restricted resources. However, preventive steps could be considered to stop the delay in diagnosis and avoid the comorbidities of illness associated with skin cancer and COVID-19 [8]. In another case-control study in Europe, the impact of COVID-19 on the treatment delay of skin cancer was investigated, and that study showed the negative impact of COVID-19 on the treatment of skin cancer, which resulted in an increase in the incidence of SCC [9]. Therefore, considering these scientific shreds of evidence, it can be said that the impact of the COVID-19 pandemic has enormously affected people across all age groups.

Hence, we extensively reviewed the literature to study the impact of COVID-19 on the skin. We have covered a range of skin-related topics and the impact of COVID-19 on them. The symptoms associated with the skin manifestations due to COVID-19 have been widely described, including the physiological burden on the skin. The impact on the most vulnerable strata of the population, the effect of sanitizers, gloves, and personal protective equipment, and the impact on different skin colors due to COVID-19 exposure have been highlighted. In addition, the correlation between vitamin D deficiency and COVID-19, and the application of sunscreens during the pandemic times and their usage decreasing significantly has also been covered in the manuscript. It is a first-of-its-kind review article that has extensively covered the impact of the COVID-19 pandemic on the skin.

2. Skin Manifestations Related to COVID-19

There are various skin manifestations that have been caused by COVID-19 protective measures directly and indirectly. We have incorporated and summarized the clinical evidence of cutaneous manifestations associated with SARS-CoV in the sections below. In addition, we provide a thorough discussion of clinical evidence on the most vulnerable population.

2.1. Cutaneous Manifestations Associated with COVID-19

The cutaneous symptoms associated with COVID-19 infection are diverse, with some symptoms common to other diseases, e.g., Kawasaki disease, and others appearing in the absence of systemic COVID-19 symptoms, e.g., vesicular lesions [10–12]. It has posed challenges in their identification and classification and whether these symptoms indicate direct infection or an association with systemic illness [12]. According to a review compiling

information from 46 articles involving 998 patients from nine countries with COVID-19-related skin manifestations, chilblain-like lesions were the most reported dermatologic COVID-19 symptom, with 40.2%. Maculopapular lesions followed this with 22.7%, urticarial lesions with 8.9%, vesicular lesions with 6.4%, livedoid and necrotic lesions with 2.8%, and other skin lesions and rashes with 19.8% [13]. Although the exact mechanism of the skin manifestations is still unknown, hypotheses allude to the role of the immune response and microvascular injury [14]. The predominant cutaneous COVID-19 manifestations are shown in Figure 1. Chilblain-like acral lesions, also known as COVID-19 toes, appear days after systemic COVID-19 symptoms, commonly in young adults and children, as red/purple blisters or vesicles predominantly on toes and, to a lesser extent, on fingers. Children often remain asymptomatic with negative COVID-19 tests at the initial cutaneous manifestation, and the appearance of lesions is attributed to a possible late indication of the infection [11,14]. Maculopapular lesions generally accompany COVID-19 symptoms, commonly appearing on the trunk of the body and are associated with itching, scaling, and a purpuric component. The lesions typically subside within ten days [10,15]. Urticaria appears concurrently with systemic COVID-19 symptoms lasting about seven days and is associated with a medium-high COVID-19 severity. They appear as itchy red welts or plaques with associated purpura, mainly on the trunk and limbs [11,16]. Vesicular eruptions typically appear before other COVID-19 symptoms, appearing on the trunk and limbs as small vesicles accompanied by itching [10,17]. Acral ischemia (livedo/necrosis) lesions often appear as purpuric, necrotic, and hemorrhagic bullae that commonly affect fingers and toes [18]. It is an occlusive vascular disease that primarily develops simultaneously with systemic symptoms. Livedoid and necrotic lesions are often seen in the aged population with severe COVID-19 symptoms [10].

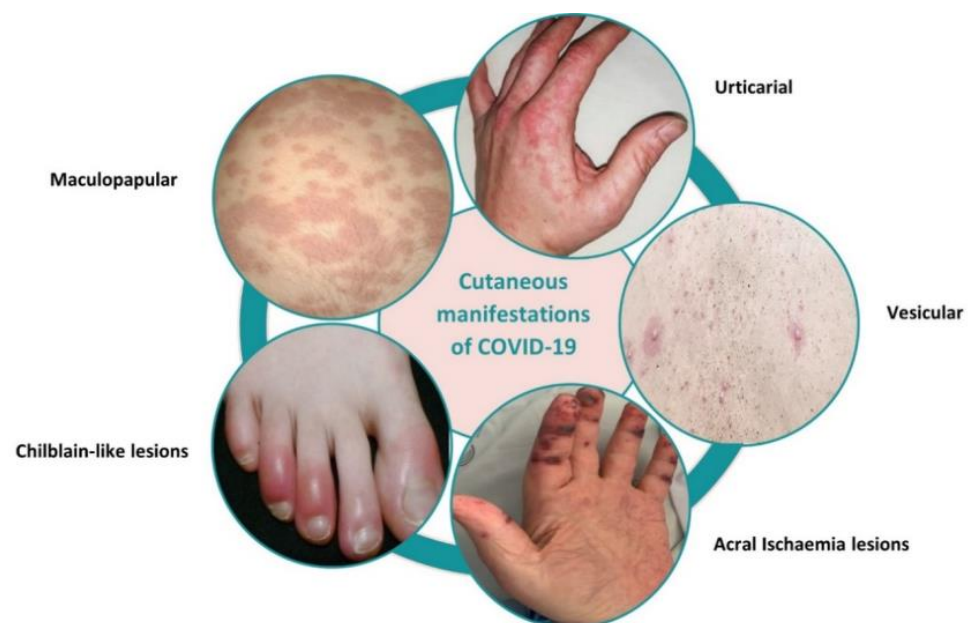

Figure 1. Cutaneous manifestations associated with COVID-19. Adapted with permission from [14,15,18–20].

To confirm this, Cazzato et al. performed a study to investigate the possible association between SARS-CoV-2, ACE2, and skin manifestations. They performed immunohistochemical investigation from nine different skin samples procured from COVID patients. This study presented ambiguous findings in which some authors agreed that clinical manifestations are linked with COVID-19, and some are not linked with COVID-19. However, they provided broad aspects from other literature to get an overview of the impact of COVID-19 on skin manifestations [21].

2.2. Cutaneous Manifestations in Children and Pregnant Women

In the pediatric population, if present, the cutaneous symptoms of COVID-19 are often the first signs of infection before fever and cough [22]. These skin manifestations can differ between adults and children [23]. According to the Dr. Lloyd, approximately 15% of children infected with the omicron variant showed rashes on the skin [24]. A significant number of frostbite cases were reported during the first wave in March 2020, especially in children, but also more in adolescents and young adults, especially on the feet. Still, the link with COVID-19 remains to be proven [23]. A study on elderly subjects in France reported that no elderly patient presented skin symptoms such as frostbite or painful, persistent redness [25]. However, most COVID-19 symptoms developed on the skin, including periocular inflammation, ischemia, livedo reticularis and petechiae, and purpura, are more frequently reported in severe cases, compared to other manifestations, including vesiculobullous, ecchymosis, and maculopapular exanthema. During pregnancy, there is a higher risk of complications from COVID-19, and the hormonal and immune changes during this period would also impact the skin manifestations of COVID [26,27]. Such data allude to a link between COVID-19 and its effect on the skin. Figure 2 is illustrating cutaneous manifestations associated with COVID-19 infection in children (foot) and pregnant women (belly).

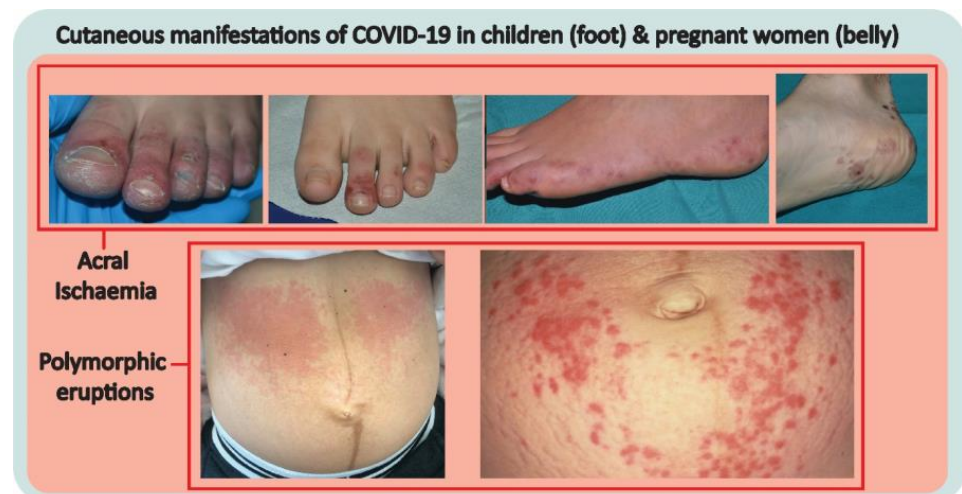

Figure 2. Cutaneous manifestations associated with COVID-19 infection in children (foot) and pregnant women (belly). Adapted with permission from [23,26].

3. Role of Vitamin D Deficiency and Skin Demographics with COVID-19

Various research groups have investigated the role of vitamin D in combating COVID-19 with its unique mechanism, and as an adjuvant therapy for COVID-19. In addition, the effect of vitamin D on skin pigmentation and skin demographics is widely described in the sections below.

3.1. Understanding the Molecular Mechanisms behind Vitamin D Deficiency

Vitamin D is an immunomodulator and a steroidal hormone produced in the human skin by exposure to ultraviolet (UV) B rays [28]. It is particularly known for its impact on various upper respiratory tract infections by stopping hyperinflammatory responses with activation of the dimerization cascade, releasing nitric oxide, or inhibiting nuclear factor kappa-light chain-enhancer of activated B cells (NFκB) [29]. COVID-19 is considered to be an acute respiratory syndrome, and by using the angiotensin-2 converting enzyme receptor, it triggers a cascade that activates macrophages, interleukins, and the cytokine storm, consequently responsible for acute respiratory distress syndrome (ARDS) [29]. A recent study found more than 50% vitamin D deficiency in 40 different countries, mainly in the elderly. However, in some countries with COVID-19, the rate of vitamin D deficiency

continues to increase (>70%), especially in the Indian population, which may be due to dietary phytates and phosphates or a lack of sun exposure [29]. For this reason, a comparison was performed between patients with and without COVID-19 related to the level of vitamin D measured in the six months preceding the infection. Different parameters were measured, such as D-dimer involved in the detection of coagulation and fibrinolysis, C-reactive protein (CRP)—a protein playing a role in cytokine storm and inflammation—and length of hospital stay. The multiplication factor between COVID-19 patients with vitamin D deficiency and those with vitamin D sufficiency was 1.77 [30]. To highlight the association between vitamin D level and COVID-19 infection, four groups were formed according to vitamin D level (0–10, 10–20, 20–30, >30 ng/mL). For high vitamin D levels (>30 ng/mL), D-dimer levels and length of hospitalization decreased. CRP also decreased, suggesting that vitamin D might have an impact on preventing the progression of inflammation to acute respiratory distress syndrome (ARDS) [30].

In parallel, the study of Lippi et al. compared vitamin D levels during 2018, 2019, and 2020, when the pandemic began. Vitamin D concentration was not different over the three years, and no increase in the prevalence of vitamin D deficiency was found during and after the confinement period. No clinically significant effects on vitamin D levels were found during the lockdown [31]. In contrast, vitamin D may play a role in ARDS, and COVID-19 [30]; vitamin D levels were found to be not significantly different during the COVID-19 period [31], suggesting the need for further investigation into the link between vitamin D and COVID-19.

3.2. Role of Vitamin D: Skin Pigmentation and Skin Color Demographics

With the spread of the pandemic worldwide, it was found in multiple studies that severe symptom development because of COVID-19 infection is more constantly reported in individuals sharing a BAME (Black, Asian, and Minority Ethnic or non-white ethnicity) origin than in Caucasians [32–37]. A recent study in the UK also reported that over 30% of COVID-19-affected patients requiring intensive care are of BAME background [33]. Currently, available data attribute poor prognosis of COVID-19 in a colored race to vitamin D deficiency [38]. People with darker complexion have high levels of melanin, which protects their skin from the harmful effects of UV exposure [39]. On the other hand, an increase in melanin levels in the skin reduces the production of vitamin D₃, especially affecting people living in higher altitude geographical locations [40]. When melanin absorbs UV-B photons, it competes with enzyme 7-dehydrocholesterol's ability to absorb UV-B photons to synthesize vitamin D₃ [41]. This is especially important since vitamin D₃ has been shown to have immunomodulatory effects [42]. As such, vitamin D₃ deficiency has been linked to an increased risk of viral upper and lower respiratory tract infections, wheezing, and asthma-related hospitalizations in infants and children [43,44].

The manifestation and appearance of cutaneous pathology also vary widely with different ethnic backgrounds and skin colors. As previously described in Section 2, common skin manifestations associated with COVID-19 include redness, chilblain-like symptoms (COVID toes), hives or urticaria rash, water blisters, the fishing net-like red-blue pattern on the skin, and rashes associated with multisystem inflammatory syndrome in children. These cutaneous manifestations have been mostly reported in countries with populations with lighter skin phototypes, with a paucity of data from the populations with darker skin phototypes [45]. Inflammatory skin conditions are easily noticeable and typically present as erythema in lighter skin, whereas in darker skin, they could be more subtle and present with pigmentary changes [46,47]. There are minor differences in COVID-19 skin manifestations for patients; while, more subtle dermatoses can present in patients with darker skin.

Urticaria has been reported to be a common skin manifestation in Caucasian patients with COVID-19, while the manifestation is not apparent in darker skin [48]. The appearance of hives on the skin of colored patients could be the same color as the skin and the surrounding erythema which may be difficult to distinguish. Batarseh, Kersten, Pinelo,

Nadler, Schwartz [49] reported several cases of COVID-19-induced angioedema of the face, lips, mouth, and tongue, but without urticaria, in hospitalized African American patients. A study on chilblain-like lesions associated with 318 COVID-19 patients and close contacts (from eight countries) reported 0.7% of the cases to be black or African and 10.7% of cases to be non-white people [50]. Similarly, an electronic survey in Brazil involving 1429 COVID-19 patients with mucocutaneous manifestations reported that chilblain-like and urticaria-like symptoms were rare in the non-white demographic population compared to white skin patients [51]. In the skin of patients of color, the appearance of the chilblain-like eruption is more subtle with less apparent red to pink discoloration when present [52]. In the case of livedo reticularis, the manifestation is characterized by reddish-blue discoloration. However, hyperpigmented patches with discoloration have been reported in darker skin due to uneven distribution of melanin [53]. Figure 3 is depicting the illustration of the interplay between vitamin D synthesis and pigmentation biology within the skin strata. Therefore, it is crucial to comprehend and recognize how the existence of cutaneous symptoms of COVID-19 may vary with varied skin color demographics, especially considering the variety of skin manifestations associated with COVID-19.

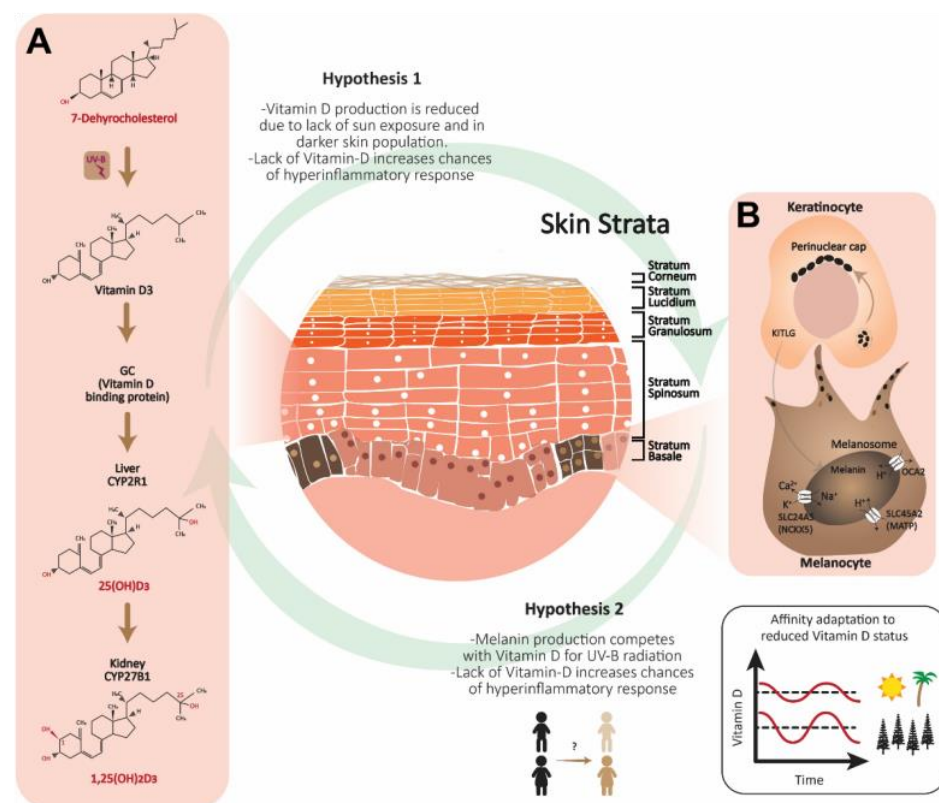


Figure 3. Diagrammatic illustration of the interplay between vitamin D synthesis and pigmentation biology within the skin strata. (A) Vitamin D₃ is synthesized when cholesterol precursor 7-dehydrocholesterol is exposed to UV-B radiation in a non-enzymatic conversion, which then initially synthesizes pre-vitamin D that eventually isomerizes to vitamin D₃. Vitamin D₃ and associated metabolites in serum are bound to GC protein and transported to the liver. The liver enzyme CYP2R1 converts vitamin D₃ to 25(OH)D₃. In the kidneys, CYP27B1 synthesizes 1,25(OH)₂D₃, which has a high affinity towards vitamin D cell surface receptors. (B) Melanocyte cells residing in the basal layer of the epidermis provide keratinocyte cells with melanosomes. Keratinocyte cells phagocytose melanosomes and reorganize in the supranuclear area to form melanin caps. Under the process of melanogenesis, melanin is synthesized in melanosomes under the control of the proteins KITLG, SLC24A5, and SLC45A2. The complete hypothesis of the figure explains the interplay between vitamin D production with melanin.

4. The Health of the Skin

The international health community has historically underprioritized the field of dermatology. However, the interest in dermatology for global health has increased significantly during the past few years [54]. Dermatologists also increasingly occupy a unique position in global health [55]. Indeed, skin conditions often indicate serious illnesses, such as neglected tropical diseases (NTDs) and COVID-19 [54]. An international registry to collect cases of skin manifestations related to COVID-19 was created at the start of the pandemic. This collected data could help to recognize early infection. Dermatologists demonstrated leadership during the COVID-19 pandemic by recognizing that skin manifestations can be part of long COVID-19 [54]. In order to limit the spread of the virus, people use hand sanitizer and wear a face mask. However, frequent handwashing may produce dermatitis and favor bacterial skin infections [56]. Moreover, the skin of the geriatric population is more permeable to chemicals because of the weaker barrier function. Thus, intensive handwashing can potentially trigger xerosis and irritant contact dermatitis [57].

4.1. The Consequences of Excess Hygiene Measures

To prevent transmission of COVID-19, the Centre for Disease Control and Prevention (CDC) and WHO recommend maintaining proper hand hygiene by washing hands with soap and water for at least 20 s, or using a hand sanitizer that contains at least 60% alcohol if soap and water are not readily available [58]. Interestingly, hand sanitizers make it much easier to clean your hands, but they can affect the skin's microbiota and produce adverse effects on the skin. In addition, excessive hand washing (~10 times per day) followed by the applying hydro alcoholic gel can also affect the hands [59].

Commonly reported adverse reactions to skin disinfectants are irritant contact dermatitis and allergic contact dermatitis [60,61]. The symptoms of both types of adverse reactions can overlap and show similarities which usually include manifestations such as skin dryness, erythema, pruritus, and bleeding [62]. In a recent descriptive analysis of 1090 participants, approximately 76%, 41%, and 35% of participants reported skin dryness, skin itching, and hand redness, respectively, as the most common disorders as a consequence of disinfectant use [63]. The use of soap, water, and sanitizers has also been reported as the biggest culprit among personal protective measures causing adverse cutaneous effects with common symptoms such as pruritus, erythema, and papules [64]. The common reasons causing adverse effects usually involve improper preparation and use of disinfectants in unconventional concentrations and the excessive use of these materials [63]. Among the alcohol-based formulations, the ethanol ingredient is relatively less skin-irritant compared to isopropanol and n-propanol [65]. Alcohol-containing sanitizer also has a drying effect on hands which can further cause the skin to crack or peel [66–68]. Apart from alcohol, there are, however, other factors contributing to the increase in the risk of contact dermatitis, such as a lack of or low concentrations of supplementary emollients in the sanitizer, friction due to wearing and removal of gloves, and low relative humidity elevating the dryness [69–71]. Figure 4 showing the cutaneous manifestations related to preventative measures implemented for COVID-19 pandemic.

Moreover, following much stricter hygienic practices was normal during the COVID pandemic. However, it came with a huge microbial cost by reducing microbial acquisition and reinoculation, followed by loss [72]. These hygienic practices proved to be very effective in reducing the transmission of COVID-19. In addition, physical distancing and isolation demonstrated a drastic reduction in virus spread [73]. Therefore, to implement these good hygienic practices, various infection control policies were developed. In addition, the awareness among the population to practice implemented measures was a crucial parameter to restrict the spread of the virus [74].

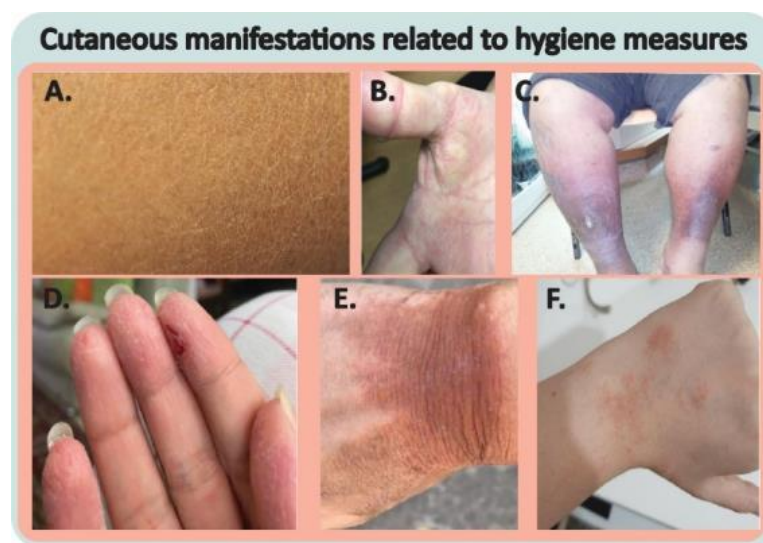

Figure 4. Cutaneous manifestations related to preventative measures implemented for COVID-19 pandemic. Xerosis (A) and irritant contact dermatitis (B) due to frequent handwashing/alcohol-based sanitizers, (C) stasis dermatitis due to sedentary behavior mandates, (D,F) eczematous contact dermatitis, (E) post-inflammatory hyperpigmentation related to severe disinfectant-related dermatitis. Images adapted from [57,75].

4.2. PPE-Associated Cutaneous Manifestations

Various factors related to the COVID-19 pandemic, such as the viral infection, use of PPE (masks, goggles, gowns, and gloves), and personal hygiene measures, have been demonstrated to impose a physiological burden (changes in the normal functioning of the body) on the skin [10]. Environmental factors such as humidity and temperature have been shown to play a significant role in altering the normal functioning of the skin. In the case of the COVID-19 pandemic, these changes in the physiological function of the skin often result from prolonged occlusion and different types of contact from PPE use, which can induce skin barrier damage, skin irritation, and changes in skin characteristics, i.e., hydration, water evaporation, percutaneous absorption, and skin microflora [76,77]. An important element of the skin's barrier is its inherent biomechanical and viscoelastic properties provided by the skin's uppermost layer, the stratum corneum, and the strain-rate dependent viscoelastic viable epidermal layer [78–80]. Excess moisture from prolonged occlusion and changes in temperature reduce the stratum corneum's strength, which alters the skin's mechanical loading capacity and underlying soft tissues [81]. Furthermore, associated skin barrier damage from PPE use can result in dermatoses such as urticaria, acne vulgaris, and contact dermatitis [82]. A study by Kim et al. noted significant changes in the temperature, redness, transepidermal water loss (TEWL), and skin pH after 6 h of mask use. In contrast, changes in skin elasticity, pore size, and an increase in acne lesions were noted after a 2 weeks of mask use. The changes in skin temperature were linked to exhalation, while changes in skin redness were associated with direct mask-to-skin contact [77]. Further, Abiakam and associates reported various skin adverse reactions, including redness, itchiness, pressure damage, and rashes associated with friction, moisture, and pressure from the PPE devices [83]. Several studies have attributed the development of some dermatoses directly to the COVID infection from a possible immune response or microvascular injury [14], with 20.4% (18/88) reporting cutaneous manifestations in an Italian study [84] and 4.9% (5/103) reporting an incidence of skin lesions in China following viral infection [85]. These studies demonstrate the inherent effects associated with the pandemic on the physiological functioning of the skin and the associated dermatologic implication. Figure 5 is illustrating the cases of personal protective equipment (PPE) associated skin rashes during the pandemic.

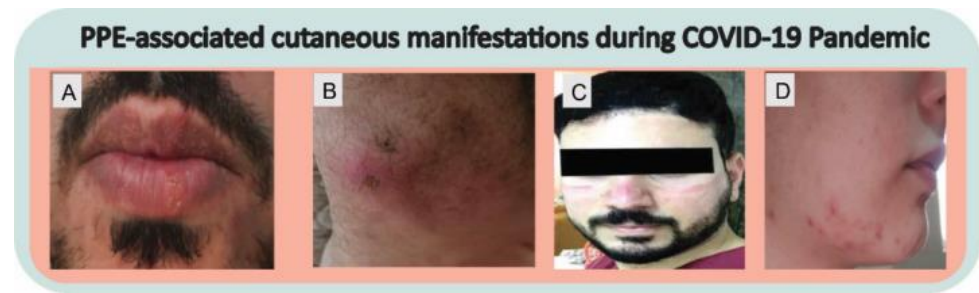

Figure 5. Documented cases of personal protective equipment (PPE) associated skin rashes during the pandemic; (A) Herpes simplex reactivation triggered by friction caused by wearing a surgical mask, (B) gown-related contact urticaria, (C) impressions on the face, (D) mask-related frictional acne. Adapted with permission from [75,86].

5. Protection of Skin from Harmful UV Radiation

As the skin is the largest organ of the body, it is the one that gets exposed to any harsh exogenous environment. Applying a broad range of sunscreens, hats, sunglasses, and many other methods can prevent the skin from getting burned quickly. However, the application of these methods has drastically reduced during the pandemic. Therefore, we discuss the impact of COVID-19 on using these materials to prevent skin exposure to harmful UV radiation. In addition, using the section below imparts some light on skin exposure protective measures.

5.1. Sunscreens

COVID-19 pandemic lockdowns or stay-at-home orders affected people's direct exposure to solar UV radiation, UVA and UVB. However, it is widely known that direct exposure is not the only mechanism by which solar radiation can reach an individual, as it can also be scattered from the open sky or reflected from the environment, including ground and building surfaces, such as white paint, light-colored concrete, and metallic surfaces [87]. UVB radiation is related to sunburn and skin cancer and is typically blocked by the glass (e.g., a window). In contrast, UVA radiation contributes to skin aging and can be reduced or eliminated by certain types of glass, such as laminated glass. In this way, solar UV radiation reaching indoor settings presents minimal risk. However, chores carried out outside during lockdown, such as gardening, may increase exposure when the UV level is 3 or higher, which justifies the use of sunscreen when indoors [88]. In addition, some UV radiation from artificial sources, such as interior lighting of general use (e.g., fluorescent, quartz halogen, and incandescent sources), can also be found at home at very low levels, which can still represent a risk for patients with cutaneous photosensitivity disorders [89]. A study by Bhakti reported similar sunscreen usage before (91.7%) and during (90.7%) the COVID-19 pandemic among adult women in Nepal [90].

On the other hand, Korrapati et al. reported a decrease in sunscreen usage in the skincare routines of participants residing primarily in India (67.1%) and Georgia (22.9%). Sunscreen was used in 20.9% of participants before the pandemic versus 13.3% after the pandemic. The different findings between studies may be the result of consumer awareness and access to skin health information across different countries, varying temperatures, lockdown periods, sun exposure, and location [91].

5.2. Other Methods to Protect the Skin from Harmful UV Radiation

Lockdowns during the pandemic impacted our regular sun exposure and, thus, our biological mechanisms for adapting to sunlight [91]. In this way, UV protection after lockdowns becomes even more imperative, considering the potential increased exposure to UV radiation. The Australia Radiation Protection and Nuclear Safety Agency recommends a combination of five protective measures: slip, slop, slap, seek, and slide [87]. Slip-on ultraviolet protection factor (UPF) rated clothing.

- Slop a broad-spectrum and water-resistant sunscreen labeled SPF30 or higher 20 min before going outdoors and reapplying every two hours;
- Slap on a hat that provides shade to the head, ears, face, and neck (high protection factor);
- Seek shade coverage.
- Slide on direct, scattered, and reflected solar UVR glasses tested to Australian standards and labeled as “sunglasses or as special purposes sunglasses.”

6. Conclusions

This review focused on the impacts of the COVID-19 pandemic on human skin. Since the pandemic, millions of people worldwide have been affected, directly or indirectly, and to varying degrees, due to the highly contagious nature of the virus. Besides well-known respiratory symptoms, COVID-19 has shown various clinical manifestations such as cardiac, physiological, psychological, and dermal. The disease progress of COVID-19 skin manifestations was also found to be related to skin color demographics. The potential mechanisms for these adverse effects can be attributed to the composition of skin barrier function due to the alteration of skin characteristics such as hydration status of the stratum corneum, skin pH buffering capacity, and changes in microbiota on skin. Overall, this manuscript thoroughly reviews COVID-19's clinical manifestations on the skin.

Funding: MI is supported by the Research Training Program Scholarship, The University of Queensland, and PMH is funded by a Fellowship and grants from the National Health and Medical Research Council (NHMRC) of Australia (1175134) and by UTS.

Institutional Review Board Statement: Not applicable.

Informed Consent Statement: Not applicable.

Data Availability Statement: The data presented in this study are openly available in PubMed, Scopus, google scholar and other repositories.

Acknowledgments: Authors would like to thank Translational Research Institute for providing the facilities.

Conflicts of Interest: The authors declare no conflict of interest.

References

1. Li, H.; Liu, Z.; Ge, J. Scientific research progress of COVID-19/SARS-CoV-2 in the first five months. *J. Cell. Mol. Med.* **2020**, *24*, 6558–6570. [[CrossRef](#)]
2. Criado, P.R.; Ianhez, M.; Silva de Castro, C.C.; Talhari, C.; Ramos, P.M.; Miot, H.A. COVID-19 and skin diseases: Results from a survey of 843 patients with atopic dermatitis, psoriasis, vitiligo and chronic urticaria. *J. Eur. Acad. Dermatol. Venereol.* **2022**, *36*, e1–e3. [[CrossRef](#)] [[PubMed](#)]
3. Dellino, M.; Cascardi, E.; Vinciguerra, M.; Lamanna, B.; Malvasi, A.; Scacco, S.; Acquaviva, S.; Pinto, V.; Di Vagno, G.; Cormio, G.; et al. Nutrition as Personalized Medicine against SARS-CoV-2 Infections: Clinical and Oncological Options with a Specific Female Groups Overview. *Int. J. Mol. Sci.* **2022**, *23*, 9136. [[CrossRef](#)] [[PubMed](#)]
4. Novak, N.; Peng, W.; Naegeli, M.C.; Galvan, C.; Kolm-Djamei, I.; Brügggen, C.; Cabanillas, B.; Schmid-Grendelmeier, P.; Catala, A. SARS-CoV-2, COVID-19, skin and immunology—What do we know so far? *Allergy* **2021**, *76*, 698–713. [[CrossRef](#)] [[PubMed](#)]
5. Swarnkar, B.; Bhari, N. Skin amidst COVID-19 pandemic. *Dermatol. Ther.* **2020**, *33*, e13789. [[CrossRef](#)]
6. Xu, Q.; Zhang, L.; Chen, L.; Zhao, X.; Wang, X.; Hu, M.; Le, Y.; Xue, F.; Li, X.; Zheng, J. SARS-CoV-2 might transmit through the skin while the skin barrier function could be the mediator. *Med. Hypotheses* **2022**, *159*, 110752. [[CrossRef](#)]
7. Imran, M.; Iqbal, M.K.; Imtiyaz, K.; Saleem, S.; Mittal, S.; Rizvi, M.M.A.; Ali, J.; Baboota, S. Topical nanostructured lipid carrier gel of quercetin and resveratrol: Formulation, optimization, in vitro and ex vivo study for the treatment of skin cancer. *Int. J. Pharm.* **2020**, *587*, 119705. [[CrossRef](#)]
8. Asai, Y.; Nguyen, P.; Hanna, T.P. Impact of the COVID-19 pandemic on skin cancer diagnosis: A population-based study. *PLoS ONE* **2021**, *16*, e0248492. [[CrossRef](#)]
9. Seretis, K.; Boptsi, E.; Boptsi, A.; Lykoudis, E.G. The impact of treatment delay on skin cancer in COVID-19 era: A case-control study. *World J. Surg. Oncol.* **2021**, *19*, 350. [[CrossRef](#)]
10. Gül, Ü. COVID-19 and dermatology. *Turk. J. Med. Sci.* **2020**, *50*, 1751–1759. [[CrossRef](#)]
11. Genovese, G.; Moltrasio, C.; Berti, E.; Marzano, A.V. Skin Manifestations Associated with COVID-19: Current Knowledge and Future Perspectives. *Dermatology* **2021**, *237*, 1–12. [[CrossRef](#)]
12. Shinkai, K.; Bruckner, A.L. Dermatology and COVID-19. *JAMA* **2020**, *324*, 1133–1134. [[CrossRef](#)]

13. Jia, J.L.; Kamceva, M.; Rao, S.A.; Linos, E. Cutaneous manifestations of COVID-19: A preliminary review. *J. Am. Acad. Dermatol.* **2020**, *83*, 687–690. [[CrossRef](#)]
14. Athwani, V.; Gothwal, S. Dermatological Manifestations of COVID-19 in Children. *J. Ski. Stem Cell* **2020**, *7*, e106890. [[CrossRef](#)]
15. Mariyath, O.K.R.; Samad, K.A.; Devi, K.; Surya, V.S.; Effeena, M.D.; Ajina, M.; Diseases, S.T. Atypical maculopapular rash as the initial sign of COVID-19: A case report from a COVID hospital. *J. Ski. Sex. Transm. Dis.* **2021**, *3*, 87–90. [[CrossRef](#)]
16. Polly, S.; Fernandez, A.P. Common skin signs of COVID-19 in adults: An update. *Cleve. Clin. J. Med.* **2022**, *89*, 161–167. [[CrossRef](#)]
17. Galván Casas, C.; Català, A.; Carretero Hernández, G.; Rodríguez-Jiménez, P.; Fernández-Nieto, D.; Rodríguez-Villa Lario, A.; Navarro Fernández, I.; Ruiz-Villaverde, R.; Falkenhain-López, D.; Llamas Velasco, M.; et al. Classification of the cutaneous manifestations of COVID-19: A rapid prospective nationwide consensus study in Spain with 375 cases. *Br. J. Dermatol.* **2020**, *183*, 71–77. [[CrossRef](#)]
18. Calvão, J.; Relvas, M.; Pinho, A.; Brinca, A.; Cardoso, J.C. Acro-ischæmia and COVID-19 infection: Clinical and histopathological features. *J. Eur. Acad. Dermatol. Venereol.* **2020**, *34*, e653–e754. [[CrossRef](#)]
19. Henry, D.; Ackerman, M.; Sancelme, E.; Finon, A.; Esteve, E. Urticarial eruption in COVID-19 infection. *J. Eur. Acad. Dermatol. Venereol.* **2020**, *34*, e244–e245. [[CrossRef](#)]
20. Palaniappan, V.; Subramaniam, K.; Karthikeyan, K. Papular-Vesicular Rash in COVID-19. *Am. J. Trop. Med. Hyg.* **2021**, *105*, 551–552. [[CrossRef](#)]
21. Cazzato, G.; Cascardi, E.; Colagrande, A.; Foti, C.; Stellacci, A.; Marrone, M.; Ingravallo, G.; Arezzo, F.; Loizzi, V.; Solimando, A.G.; et al. SARS-CoV-2 and Skin: New Insights and Perspectives. *Biomolecules* **2022**, *12*, 1212. [[CrossRef](#)] [[PubMed](#)]
22. Lavery, M.J.; Bouvier, C.A.; Thompson, B. Cutaneous manifestations of COVID-19 in children (and adults): A virus that does not discriminate. *Clin. Dermatol.* **2021**, *39*, 323–328. [[CrossRef](#)] [[PubMed](#)]
23. Andina, D.; Belloni-Fortina, A.; Bodemer, C.; Bonifazi, E.; Chiriach, A.; Colmenero, I.; Diociaiuti, A.; El-Hachem, M.; Fertitta, L.; van Gysel, D.; et al. Skin manifestations of COVID-19 in children: Part 1. *Clin. Exp. Dermatol.* **2021**, *46*, 444–450. [[CrossRef](#)] [[PubMed](#)]
24. Visconti, A.; Murray, B.; Rossi, N.; Wolf, J.; Ourselin, S.; Spector, T.D.; Freeman, E.E.; Bataille, V.; Falchi, M. Cutaneous Manifestations of SARS-CoV-2 infection during the Delta and Omicron waves in 348,691 UK users of the UK ZOE COVID Study App. *Br. J. Dermatol.* **2022**, *187*, 900–908. [[CrossRef](#)]
25. Zulfiqar, A.-A.; Lorenzo Villalba, N.; Severac, F.; Andrès, E. Infection liée à la COVID-19 chez une série de sujets âgés: Résultats d’une étude préliminaire COVID-19 infection in a cohort of elderly patients in France: Results of a preliminary study. *La Presse Médicale Form.* **2020**, *1*, 460–463. [[CrossRef](#)]
26. Proietti, I.; Bernardini, N.; Tolino, E.; Mambrin, A.; Balduzzi, V.; Marchesiello, A.; Michelini, S.; Skroza, N.; Potenza, C. Polymorphic eruption of pregnancy as a possible COVID-19 manifestation. *Dermatol. Ther.* **2020**, *33*, e14117. [[CrossRef](#)]
27. Lim, R.K.; Kalagara, S.; Chen, K.K.; Mylonakis, E.; Kroumpouzos, G. Dermatology in a multidisciplinary approach with infectious disease and obstetric medicine against COVID-19. *Int. J. Womens Dermatol.* **2021**, *7*, 640–646. [[CrossRef](#)]
28. Jan, Y.; Malik, M.; Yaseen, M.; Ahmad, S.; Imran, M.; Rasool, S.; Haq, A. Vitamin D fortification of foods in India: Present and past scenario. *J. Steroid Biochem. Mol. Biol.* **2019**, *193*, 105417. [[CrossRef](#)]
29. Mohan, M.; Cherian, J.J.; Sharma, A. Exploring links between vitamin D deficiency and COVID-19. *PLoS Pathog.* **2020**, *16*, e1008874. [[CrossRef](#)]
30. Demir, M.; Demir, F.; Aygun, H. Vitamin D deficiency is associated with COVID-19 positivity and severity of the disease. *J. Med. Virol.* **2021**, *93*, 2992–2999. [[CrossRef](#)]
31. Lippi, G.; Ferrari, A.; Targher, G. Is COVID-19 lockdown associated with vitamin D deficiency? *Eur. J. Public Health* **2021**, *31*, 278–279. [[CrossRef](#)]
32. Patel, P.; Hiam, L.; Sowemimo, A.; Devakumar, D.; McKee, M. Ethnicity and COVID-19. *BMJ* **2020**, *369*, 1–2. [[CrossRef](#)]
33. Pareek, M.; Bangash, M.N.; Pareek, N.; Pan, D.; Sze, S.; Minhas, J.S.; Hanif, W.; Khunti, K. Ethnicity and COVID-19: An urgent public health research priority. *Lancet* **2020**, *395*, 1421–1422. [[CrossRef](#)]
34. Aldridge, R.W.; Lewer, D.; Katikireddi, S.V.; Mathur, R.; Pathak, N.; Burns, R.; Fragaszy, E.B.; Johnson, A.M.; Devakumar, D.; Abubakar, I. Black, Asian and Minority Ethnic groups in England are at increased risk of death from COVID-19: Indirect standardisation of NHS mortality data. *Wellcome Open Res.* **2020**, *5*, 88. [[CrossRef](#)]
35. Khunti, K.; Singh, A.K.; Pareek, M.; Hanif, W. Is ethnicity linked to incidence or outcomes of COVID-19? *BMJ* **2020**, *369*, 1–2. [[CrossRef](#)]
36. Pan, D.; Sze, S.; Minhas, J.S.; Bangash, M.N.; Pareek, N.; Divall, P.; Williams, C.M.; Oggioni, M.R.; Squire, I.B.; Nellums, L.B. The impact of ethnicity on clinical outcomes in COVID-19: A systematic review. *EClinicalMedicine* **2020**, *23*, 100404. [[CrossRef](#)]
37. Sze, S.; Pan, D.; Nevill, C.R.; Gray, L.J.; Martin, C.A.; Nazareth, J.; Minhas, J.S.; Divall, P.; Khunti, K.; Abrams, K.R. Ethnicity and clinical outcomes in COVID-19: A systematic review and meta-analysis. *EClinicalMedicine* **2020**, *29*, 100630. [[CrossRef](#)]
38. Darling, A.L.; Ahmadi, K.R.; Ward, K.A.; Harvey, N.C.; Alves, A.C.; Dunn-Walters, D.K.; Lanham-New, S.A.; Cooper, C.; Blackburn, D.J. Vitamin D status, body mass index, ethnicity and COVID-19: Initial analysis of the first-reported UK Biobank COVID-19 positive cases (n 580) compared with negative controls (n 723). *MedRxiv* **2020**, *4*. [[CrossRef](#)]
39. Herrling, T.; Jung, K.; Fuchs, J. The role of melanin as protector against free radicals in skin and its role as free radical indicator in hair. *Spectrochim. Acta Part A Mol. Biomol. Spectrosc.* **2008**, *69*, 1429–1435. [[CrossRef](#)]

40. Islam, M.T.; Salehi, B.; Karampelas, O.; Sharifi-Rad, J.; Docea, A.O.; Martorell, M.; Calina, D. High skin melanin content, vitamin D deficiency and immunity: Potential interference for severity of COVID-19. *Farmacia* **2020**, *68*, 970–983. [[CrossRef](#)]
41. Chen, T.C.; Chimeh, F.; Lu, Z.; Mathieu, J.; Person, K.S.; Zhang, A.; Kohn, N.; Martinello, S.; Berkowitz, R.; Holick, M.F. Factors that influence the cutaneous synthesis and dietary sources of vitamin D. *Arch. Biochem. Biophys.* **2007**, *460*, 213–217. [[CrossRef](#)] [[PubMed](#)]
42. Jagannath, V.A.; Filippini, G.; Di Pietrantonj, C.; Asokan, G.; Robak, E.W.; Whamond, L.; Robinson, S.A. Vitamin D for the management of multiple sclerosis. *Cochrane Database Syst. Rev.* **2018**, *24*, 9. [[CrossRef](#)] [[PubMed](#)]
43. Aglipay, M.; Birken, C.S.; Parkin, P.C.; Loeb, M.B.; Thorpe, K.; Chen, Y.; Laupacis, A.; Mamdani, M.; Macarthur, C.; Hoch, J.S. Effect of high-dose vs standard-dose wintertime vitamin D supplementation on viral upper respiratory tract infections in young healthy children. *JAMA* **2017**, *318*, 245–254. [[CrossRef](#)] [[PubMed](#)]
44. Esposito, S.; Lelii, M. Vitamin D and respiratory tract infections in childhood. *BMC Infect. Dis.* **2015**, *15*, 1–10. [[CrossRef](#)] [[PubMed](#)]
45. Lester, J.; Jia, J.; Zhang, L.; Okoye, G.; Linos, E. Absence of images of skin of colour in publications of COVID-19 skin manifestations. *Br. J. Dermatol.* **2020**, *183*, 593–595. [[CrossRef](#)]
46. Sangha, A.M. Dermatological Conditions in SKIN OF COLOR—: Managing Atopic Dermatitis. *J. Clin. Aesthetic Dermatol.* **2021**, *14*, S20.
47. Kaufman, B.P.; Guttman-Yassky, E.; Alexis, A.F. Atopic dermatitis in diverse racial and ethnic groups—Variations in epidemiology, genetics, clinical presentation and treatment. *Exp. Dermatol.* **2018**, *27*, 340–357. [[CrossRef](#)]
48. Akuffo-Addo, E.; Nicholas, M.N.; Joseph, M. COVID-19 Skin Manifestations in Skin of Colour. *J. Cutan. Med. Surg.* **2022**, *26*, 189–197. [[CrossRef](#)]
49. Batarseh, E.; Kersten, B.P.; Pinelo, A.C.; Nadler, J.N.; Schwartz, S.A. Angioedema in African American patients hospitalized for COVID-19. *Am. J. Respir. Crit. Care Med.* **2020**, *202*, 1581–1584. [[CrossRef](#)]
50. Freeman, E.E.; McMahan, D.E.; Lipoff, J.B.; Rosenbach, M.; Kovarik, C.; Takeshita, J.; French, L.E.; Thiers, B.H.; Hruza, G.J.; Fox, L.P. Pernio-like skin lesions associated with COVID-19: A case series of 318 patients from 8 countries. *J. Am. Acad. Dermatol.* **2020**, *83*, 486–492. [[CrossRef](#)]
51. Miot, H.; Ianhez, M.; Ramos, P.M. Self-reported cutaneous manifestations in 1429 Brazilian COVID-19 patients. *J. Eur. Acad. Dermatol. Venereol.* **2021**, *35*, e172–e173. [[CrossRef](#)]
52. Daneshjou, R.; Rana, J.; Dickman, M.; Yost, J.M.; Chiou, A.; Ko, J. Pernio-like eruption associated with COVID-19 in skin of color. *JAAD Case Rep.* **2020**, *6*, 892–897. [[CrossRef](#)]
53. Strom, M.A.; Trager, M.H.; Timerman, D.; Coromilas, A.J.; Burriss, K.; Belsito, D.V.; Eber, A.; Greenberg, S.; Husain, S.; Lewin, J.M. Cutaneous findings in hospitalized and critically ill patients with COVID-19: A case series of 15 patients. *J. Am. Acad. Dermatol.* **2021**, *84*, 510–511. [[CrossRef](#)]
54. Prasad, S.; Bassett, I.V.; Freeman, E.E. Dermatology on the global stage: The role of dermatologists in international health advocacy and COVID-19 research. *Int. J. Womens Dermatol.* **2021**, *7*, 653–659. [[CrossRef](#)]
55. Hasan, N.; Imran, M.; Nadeem, M.; Jain, D.; Haider, K.; Moshahid Alam Rizvi, M.; Sheikh, A.; Kesharwani, P.; Kumar Jain, G.; Jalees Ahmad, F. Formulation and development of novel lipid-based combinatorial advanced nanoformulation for effective treatment of non-melanoma skin cancer. *Int. J. Pharm.* **2023**, *632*, 122580. [[CrossRef](#)]
56. Schwartz, R.A.; Lambert, W.C. COVID-19-specific skin changes related to SARS-CoV-2: Visualizing a monumental public health challenge. *Clin. Dermatol.* **2021**, *39*, 374–379. [[CrossRef](#)]
57. Golpanian, R.S.; Yosipovitch, G. Geriatric Skin Care in the Era of COVID-19. *J. Am. Geriatr. Soc.* **2020**, *68*, 1680–1682. [[CrossRef](#)]
58. Hadaway, A. Handwashing: Clean hands save lives. *J. Consum. Health Internet* **2020**, *24*, 43–49. [[CrossRef](#)]
59. Lin, P.; Zhu, S.; Huang, Y.; Li, L.; Tao, J.; Lei, T.; Song, J.; Liu, D.; Chen, L.; Shi, Y. Adverse skin reactions among healthcare workers during the coronavirus disease 2019 outbreak: A survey in Wuhan and its surrounding regions. *Br. J. Dermatol.* **2020**, *183*, 190–192. [[CrossRef](#)]
60. Ale, I.S.; Maibach, H.I. Irritant contact dermatitis. *Rev. Environ. Health* **2014**, *29*, 195–206. [[CrossRef](#)]
61. Wilhelm, K.-P. Prevention of surfactant-induced irritant contact dermatitis. *Prev. Contact Dermat.* **1996**, *25*, 78–85.
62. Jing, J.L.J.; Pei Yi, T.; Bose, R.J.; McCarthy, J.R.; Tharmalingam, N.; Madheswaran, T. Hand sanitizers: A review on formulation aspects, adverse effects, and regulations. *Int. J. Environ. Res. Public Health* **2020**, *17*, 3326. [[CrossRef](#)] [[PubMed](#)]
63. Dindarloo, K.; Aghamolaei, T.; Ghanbarnejad, A.; Turki, H.; Hoseinvandtabar, S.; Pasalari, H.; Ghaffari, H.R. Pattern of disinfectants use and their adverse effects on the consumers after COVID-19 outbreak. *J. Environ. Health Sci. Eng.* **2020**, *18*, 1301–1310. [[CrossRef](#)] [[PubMed](#)]
64. Mushtaq, S.; Terzi, E.; Recalcati, S.; Salas-Alanis, J.C.; Amin, S.; Faizi, N. Cutaneous adverse effects due to personal protective measures during COVID-19 pandemic: A study of 101 patients. *Int. J. Dermatol.* **2021**, *60*, 327–331. [[CrossRef](#)]
65. Erasmus, V.; Daha, T.J.; Brug, H.; Richardus, J.H.; Behrendt, M.D.; Vos, M.C.; van Beeck, E.F. Systematic review of studies on compliance with hand hygiene guidelines in hospital care. *Infect. Control. Hosp. Epidemiol.* **2010**, *31*, 283–294. [[CrossRef](#)]
66. Guin, J.D.; Goodman, J. Contact urticaria from benzyl alcohol presenting as intolerance to saline soaks. *Contact Dermat.* **2001**, *45*, 182–183. [[CrossRef](#)]
67. de Groot, A.C. Contact allergy to cosmetics: Causative ingredients. *Contact Dermat.* **1987**, *17*, 26–34. [[CrossRef](#)]

68. Podda, M.; Zollner, T.; Grundmann-Kollmann, M.; Kaufmann, R.; Boehncke, W.-H. Allergic contact dermatitis from benzyl alcohol during topical antimycotic treatment. *Contact Dermat.* **1999**, *41*, 302–303. [CrossRef]
69. Cimiotti, J.P.; Marmur, E.S.; Nesin, M.; Hamlin-Cook, P.; Larson, E.L. Adverse reactions associated with an alcohol-based hand antiseptic among nurses in a neonatal intensive care unit. *Am. J. Infect. Control* **2003**, *31*, 43–48. [CrossRef]
70. Ophaswongse, S.; Maibach, H.I. Alcohol dermatitis: Allergic contact dermatitis and contact urticaria syndrome: A review. *Contact Dermat.* **1994**, *30*, 1–6. [CrossRef]
71. Rosenberg, A.; Alatary, S.; Peterson, A. Safety and efficacy of the antiseptic chlorhexidine gluconate. *Surg. Gynecol. Obstet.* **1976**, *143*, 789–792.
72. Finlay, B.B.; Amato, K.R.; Azad, M.; Blaser, M.J.; Bosch, T.C.G.; Chu, H.; Dominguez-Bello, M.G.; Ehrlich, S.D.; Elinav, E.; Geva-Zatorsky, N.; et al. The hygiene hypothesis, the COVID pandemic, and consequences for the human microbiome. *Proc. Natl. Acad. Sci. USA* **2021**, *118*, e2010217118. [CrossRef]
73. Dzator, J.; Acheampong, A.O.; Dzator, M.; Paolucci, F.; Yawe, B.L.; Asmah, E.E.; Andoh, F.K.; Kabagenyi, A.; Gillespie, J. Policy Stringency, Handwashing and COVID-19 cases: Evidence from Global dataset. *Health Policy Technol.* **2022**, *11*, 100574. [CrossRef]
74. Guner, R.; Hasanoglu, I.; Aktas, F. Evaluating the efficiency of public policy measures against COVID-19. *Turk. J. Med. Sci.* **2021**, *51*, 3229–3237. [CrossRef]
75. Shanshal, M.; Ahmed, H.S.; Asfoor, H.; Salih, R.I.; Ali, S.A.; Aldabouni, Y.K. Impact of COVID-19 on medical practice: A nationwide survey of dermatologists and health care providers in Iraq. *Clin. Dermatol.* **2021**, *39*, 500–509. [CrossRef]
76. Lan, J.; Song, Z.; Miao, X.; Li, H.; Li, Y.; Dong, L.; Yang, J.; An, X.; Zhang, Y.; Yang, L.; et al. Skin damage among health care workers managing coronavirus disease-2019. *J. Am. Acad. Dermatol.* **2020**, *82*, 1215–1216. [CrossRef]
77. Kim, J.; Yoo, S.; Kwon, O.S.; Jeong, E.T.; Lim, J.M.; Park, S.G. Influence of quarantine mask use on skin characteristics: One of the changes in our life caused by the COVID-19 pandemic. *Skin Res. Technol.* **2021**, *27*, 599–606. [CrossRef]
78. Masood, A.; Sarika, N.; Heather, A.E.B.; Tushar, K.; Yousuf, M. Skin biomechanics: Breaking the dermal barriers with microneedles. *Nano TransMed* **2022**, *1*, e9130002. [CrossRef]
79. Ali, M.; Namjoshi, S.; Benson, H.A.E.; Mohammed, Y.; Kumeria, T. Dissolvable polymer microneedles for drug delivery and diagnostics. *J. Control Release* **2022**, *347*, 561–589. [CrossRef]
80. Mohammed, Y.; Holmes, A.; Kwok, P.C.L.; Kumeria, T.; Namjoshi, S.; Imran, M.; Matteucci, L.; Ali, M.; Tai, W.; Benson, H.A. Advances and future perspectives in epithelial drug delivery. *Adv. Drug Deliv. Rev.* **2022**, *186*, 114293. [CrossRef]
81. Kottner, J.; Black, J.; Call, E.; Gefen, A.; Santamaria, N. Microclimate: A critical review in the context of pressure ulcer prevention. *Clin. Biomech.* **2018**, *59*, 62–70. [CrossRef] [PubMed]
82. Yan, Y.; Chen, H.; Chen, L.; Cheng, B.; Diao, P.; Dong, L.; Gao, X.; Gu, H.; He, L.; Ji, C.; et al. Consensus of Chinese experts on protection of skin and mucous membrane barrier for health-care workers fighting against coronavirus disease 2019. *Dermatol. Ther.* **2020**, *33*, e13310. [CrossRef] [PubMed]
83. Abiakam, N.; Worsley, P.; Jayabal, H.; Mitchell, K.; Jones, M.; Fletcher, J.; Spratt, F.; Bader, D. Personal protective equipment related skin reactions in healthcare professionals during COVID-19. *Int. Wound J.* **2021**, *18*, 312–322. [CrossRef] [PubMed]
84. Recalcati, S. Cutaneous manifestations in COVID-19: A first perspective. *J. Eur. Acad. Dermatol. Venereol.* **2020**, *34*, e212–e213. [CrossRef]
85. Hedou, M.; Carsuzaa, F.; Chary, E.; Hainaut, E.; Cazenave-Roblot, F.; Masson Regnault, M. Comment on ‘Cutaneous manifestations in COVID-19: A first perspective’ by Recalcati S. *J. Eur. Acad. Dermatol. Venereol.* **2020**, *34*, e299–e300. [CrossRef]
86. Singh, H.; Kaur, H.; Singh, K.; Sen, C.K. Cutaneous Manifestations of COVID-19: A Systematic Review. *Adv. Wound Care* **2021**, *10*, 51–80. [CrossRef]
87. Australia Radiation Protection and Nuclear Safety Agency (ARPANSA). Ultraviolet Radiation. Available online: <https://www.arpansa.gov.au/understanding-radiation/what-is-radiation/non-ionising-radiation/ultraviolet-radiation> (accessed on 29 July 2022).
88. Cancer Council. Should I Wear Sunscreen When Indoors? Available online: <https://www.cancer.org.au/iheard/should-i-wear-sunscreen-when-indoors> (accessed on 29 July 2022).
89. Sayre, R.M.; Dowdy, J.C.; Poh-Fitzpatrick, M. Dermatological risk of indoor ultraviolet exposure from contemporary lighting sources. *Photochem. Photobiol.* **2004**, *80*, 47–51. [CrossRef]
90. Bakhati, D.; Agrawal, S. COVID-19 pandemic lockdown—Is it affecting our skin hygiene and cosmetic practice? *J. Cosmet. Dermatol.* **2022**, *21*, 1830–1836. [CrossRef]
91. Korrapati, N.H.; Perera, M.H.; K Swamy, P.; Ranganath, P.A.; Ankireddy, K.; Thomas, S.A.; Bathala, R.P. Skin-care Routine During The COVID-19 Pandemic: An Online Survey. *Int. J. Progress. Sci. Technol.* **2021**, *25*, 12. [CrossRef]

Disclaimer/Publisher’s Note: The statements, opinions and data contained in all publications are solely those of the individual author(s) and contributor(s) and not of MDPI and/or the editor(s). MDPI and/or the editor(s) disclaim responsibility for any injury to people or property resulting from any ideas, methods, instructions or products referred to in the content.