



HAL
open science

Intraoperative functional remapping unveils evolving patterns of cortical plasticity

Sam Ng, Pablo Valdes, Sylvie Moritz-Gasser, Anne-Laure Lemaitre, Hugues Duffau, Guillaume Herbet

► **To cite this version:**

Sam Ng, Pablo Valdes, Sylvie Moritz-Gasser, Anne-Laure Lemaitre, Hugues Duffau, et al.. Intraoperative functional remapping unveils evolving patterns of cortical plasticity. *Brain - A Journal of Neurology*, In press, 146 (7), pp.3088-3100. 10.1093/brain/awad116 . hal-04068731

HAL Id: hal-04068731

<https://hal.science/hal-04068731>

Submitted on 14 Apr 2023

HAL is a multi-disciplinary open access archive for the deposit and dissemination of scientific research documents, whether they are published or not. The documents may come from teaching and research institutions in France or abroad, or from public or private research centers.

L'archive ouverte pluridisciplinaire **HAL**, est destinée au dépôt et à la diffusion de documents scientifiques de niveau recherche, publiés ou non, émanant des établissements d'enseignement et de recherche français ou étrangers, des laboratoires publics ou privés.

Intraoperative functional remapping unveils evolving patterns of cortical plasticity

Sam Ng,^{1,2,†} Pablo A. Valdes,^{3,†} Sylvie Moritz-Gasser,^{1,2} Anne-Laure Lemaitre,^{1,2} Hugues Duffau^{1,2} and Guillaume Herbet^{1,2,4}

[†]These authors contributed equally to this work.

Abstract

The efficiency with which the brain reorganizes following injury not only depends on the extent and the severity of the lesion, but also on its temporal features. It is established that diffuse low-grade gliomas (DLGG), brain tumours with a slow-growth rate, induce a compensatory modulation of the anatomo-functional architecture, making this kind of tumours an ideal lesion model to study the dynamics of neuroplasticity. Direct electrostimulation (DES) mapping is a well-tried procedure used during awake resection surgeries to identify and spare cortical epicenters which are critical for a range of functions. Because DLGG is a chronic disease, it inevitably relapses years after the initial surgery, and thus requires a second surgery to reduce tumour volume again. In this context, contrasting the cortical mappings obtained during two sequential neurosurgeries offers a unique opportunity to both identify and characterize the dynamic (*i.e.* re-evolving) patterns of cortical re-arrangements.

Here, we capitalized on an unprecedented series of 101 DLGG patients who benefited from two DES-guided neurosurgeries usually spaced several years apart, resulting in a large DES dataset of 2082 cortical sites. All sites (either non-functional or associated with language, speech, motor, somatosensory and semantic processing) were recorded in the Montreal Neurological Institute (MNI) space. Next, we used a multi-step approach to generate probabilistic neuroplasticity maps that reflected the dynamic rearrangements of cortical mappings from one surgery to another, both at the population and individual-level.

Voxel-wise neuroplasticity maps revealed regions with a relatively high potential of evolving reorganizations at the population level, including the supplementary motor area (SMA, $p_{max} = 0.63$), the dorsolateral prefrontal cortex (dlPFC, $p_{max} = 0.61$), the anterior ventral premotor cortex (vPMC, $p_{max}=0.43$) and the middle superior temporal gyrus (STG $p_{max}= 0.36$). Parcel-wise neuroplasticity maps confirmed this potential for the dlPFC (Fisher's exact test, $p_{FDR-corrected} = 6.6 \times 10^{-5}$), the anterior ($p_{FDR-corrected} = 0.0039$) and the ventral precentral gyrus ($p_{FDR-corrected}$

© The Author(s) 2023. Published by Oxford University Press on behalf of the Guarantors of Brain. All rights reserved. For permissions, please e-mail: journals.permissions@oup.com This article is published and distributed under the terms of the Oxford University Press, Standard Journals Publication Model (<https://academic.oup.com/pages/standard-publication-reuse-rights>)

1 = 0.0058). A series of clustering analyses revealed a topological migration of clusters,
2 especially within the left dlPFC and STG (language sites); the left vPMC (speech
3 arrest/dysarthria sites) and the right SMA (negative motor response sites). At the individual
4 level, these dynamic changes were confirmed for the dlPFC (bilateral), the left vPMC and the
5 anterior left STG (threshold free cluster enhancement, 5000 permutations, family-wise-error-
6 corrected).

7 Taken as a whole, our results provide a critical insight into the dynamic potential of DLGG-
8 induced continuing rearrangements of the cerebral cortex, with considerable implications for
9 re-operations.

10

11 **Author affiliations:**

12 1 Department of Neurosurgery, Gui de Chauliac hospital, Montpellier University Medical
13 Center, Montpellier, France

14 2 Institute of Functional Genomics, University of Montpellier, CNRS, INSERM, Montpellier,
15 France

16 3 Department of Neurosurgery, University of Texas Medical Branch, Galveston, Texas, USA

17 4 Praxiling laboratory, UMR 5267, CNRS, UPVM, Montpellier, France

18

19 Correspondence to: Guillaume Herbet

20 Bâtiment Marc Bloch (BRED) Université Paul-Valéry, Route de Mende, 34199 Montpellier
21 cedex, France

22 E-mail: guillaume.herbet@umontpellier.fr

23

24 **Running title:** Cortical remodelling in recurrent gliomas

25 **Keywords:** plasticity; recurrent glioma; direct electrostimulation mapping; awake surgery;
26 cognitive mapping; cortical rearrangement

27

28

1 Introduction

2 Neuroplasticity refers to the unique capacity of the brain to adapt its networks in response to
3 experience or cognitive demands to maintain an optimal level of interactions with the ever-
4 evolving internal or external environment.^{1,2} Neuroplasticity can occur at multiple
5 spatiotemporal scales, from fast remodelling of neurosynaptic maps to long-term rewiring of
6 long-range white matter connections.³ From a behavioural standpoint, this neural malleability
7 is mirrored in the human's capacity to learn an impressive array of new skills and to produce
8 creative behaviours. For example, it is established that acquiring a new language⁴ or learning a
9 new musical instrument⁵ causes measurable structural and functional brain variations.⁶

10 In the pathophysiological domain, neuroplasticity refers to the brain's ability to
11 reorganize following structural damage (*e.g.* stroke, tumour, traumatic brain injury) in an
12 attempt to maintain or re-establish normal function. Postlesional neuroplasticity has been the
13 subject of numerous studies, especially in the context of acute lesions such as stroke or
14 traumatic brain injury, with the objective of identifying the different strategies that the brain
15 deploys to compensate for neuronal losses and the factors predictive of functional recovery.⁷⁻⁹
16 Over different lesion models, diffuse low-grade gliomas (WHO grade II diffuse glioma¹⁰,
17 DLGG), a subgroup of primary brain tumours with a slow-growth rate, have been highlighted
18 as an exemplary model for studying neuroplasticity.^{11,12} At the cellular level, the dynamic
19 interplay between glioma cells and their local microenvironment results in complex electrical
20 and synaptic integration into neural circuits^{13,14} that promotes long-range modulations of neural
21 signalling and activities.¹⁵ At the macroscale level, there is increasing evidence that the slow-
22 growth kinetics of DLGG favour a dynamic network re-organization,¹⁶⁻¹⁸ whose mechanistic
23 principles remain to be characterised. These whole brain neuroplastic modulations may account
24 for the common but remarkable observation that cognitive impairments in DLGG patients are
25 relatively low both before and after neurosurgery,¹⁹ despite sometimes large resections of
26 cortical areas ordinarily considered as "eloquent".²⁰

27 As DLGG is a chronic disease, it will inevitably relapse years or even decades after the
28 initial resection, requiring a second surgery to be performed in an attempt to again reduce
29 tumour volume and prevent malignant transformation.^{21,22} Currently, wide-awake surgery
30 assisted with direct electrostimulation (DES) mapping is the gold standard treatment at
31 diagnosis, as it has been shown to enhance both the extent of resection and life expectancy
32 while drastically decreasing the likelihood of postoperative permanent, debilitating

1 neurological and neuropsychological deficits.^{19,23} DES mapping is increasingly used at the time
2 of reoperation in the event of DLGG recurrence, as it allows surgical resection to be extended
3 beyond the functional limits identified with DES mapping during the first surgery.²⁴⁻²⁶ The
4 observation that reoperations are possible supports the hypothesis whereby tumour-induced
5 plasticity may continue in a constant-evolving manner, in a co-dependent manner with tumour
6 expansion, resulting in evolving patterns of cortical rearrangements.¹² In this context,
7 contrasting the cortical mappings obtained between two sequential surgeries offers a unique
8 opportunity to characterise the dynamics of cortical reorganisation and to identify the anatomic
9 factors that constrain them.

10 Here, we took advantage of a unique DES cortical mapping dataset (2082 exploitable
11 stimulation sites) gained from a cohort of 101 patients having undergone two distinct awake
12 surgical procedures usually spaced several years apart. In contrast to alternate methods that can
13 be used to study the dynamics of neuroplasticity, DES offers the clear advantage of causally
14 linking human behaviors and neuroanatomy with a high reproducibility and spatiotemporal
15 resolution.²⁷⁻²⁹

16 The main objectives of this study were threefold: (i) to investigate the potential of
17 cortical structures to functionally evolve and remodel from one surgery to another under the
18 form of gradients (from lowest to highest potential); (ii) to categorize the topological features
19 of cortical rearrangements as a result of functional responses; (iii) to provide clinically relevant
20 maps that account for the evolving capability of cortical structures to compensate over time.

21

22 **Materials and methods**

23 **Study population**

24 Data processed in this study were obtained in a clinical context and the procedures detailed
25 below follow our standard clinical approach. All patients gave informed consent. Approval for
26 the study was granted by the Institution Review Board of Montpellier University Medical
27 Center (No.202000557).

28 The population screened for inclusion included all patients operated in our institution
29 by a single surgeon (H.D.) between 2007 and 2021. The inclusion criteria were: (1) a diagnosis
30 of DLGG, confirmed by histopathological and/or molecular analysis, (2) two surgical
31 procedures spaced at least 6 months apart, (3) the use of cortical DES mapping under awake

1 conditions in both procedures. Intraoperative reports, photographs, camera recordings and
2 neuroimaging data were consecutively collected and subjected to a retrospective analysis. Of
3 note, only patients who remained free of radiation therapy (a treatment that may diminish the
4 propensity for neuroplastic reorganization)³⁰ were included in the study.

6 **In vivo electrostimulation procedure and behavioural paradigms**

7 The surgical procedure was extensively described elsewhere^{31,32} and the technique remained
8 unchanged from Surg.1 to Surg.2. Briefly, patients systematically underwent an asleep-awake-
9 asleep procedure. DES cortical mapping was performed during the awake phase, after
10 craniotomy and dura (re-)opening. Electrical mapping was performed with a bipolar probe
11 (inter-tip spacing: 5mm, NIMBUS stimulator, Newmedic, France) delivering a biphasic current
12 (1ms pulse width, 60Hz, amplitude from 1.50mA to 3.50mA). DES never exceeded 4s to limit
13 electrical spreading and to maintain anatomo-functional specificity. The amplitude was
14 gradually increased up until functional responses (*i.e.*, transient speech disorders) were elicited
15 within the ventral premotor cortex (vPMc). Then, the same amplitude was maintained constant
16 during the whole procedure. Cortical sites were considered as positive ones if they elicited an
17 inability to perform at least one of the intraoperative tasks within the 4s time delay, in a
18 reproducible way, during at least three non-consecutive stimulations (see Figure 1A). Cortical
19 sites that did not fulfil the criteria for a positive response were considered as negative ones.
20 After completion of DES cortical mapping, the tumour removal was performed using subpial
21 dissection. The resection was achieved until DES subcortical responses were obtained
22 (following the principle of functionally guided tumour removal).²⁹

23 Intraoperative tasks included upper limb movements, number counting (1-10), a picture
24 naming task, a non-verbal semantic association task when tumours involved the right
25 hemisphere (Pyramids and Palm Trees test).^{33,34} Other cognitive tasks (e.g., line bisection task)
26 were occasionally used³⁵⁻³⁷ depending on the location of the tumour and the date of the surgery
27 but were not considered in this study. Intraoperative cognitive monitoring was performed by a
28 senior speech therapist (S.M.G.) or neuropsychologist (A.L.L., G.H.) who remained blind to
29 the application of DES during the procedure. Note that each task was administered before
30 surgery in order to decrease the likelihood of false positive responses during intraoperative
31 mapping. The neuropsychologist and/or speech therapist checked whether movement disorders

1 were due to contraction/inhibition during each task (or dual tasking). This assessment was
2 performed systematically for the face and the upper limbs.

3 The following positive (*i.e.* functional) responses were considered: (1) language
4 impairments (including anomia and paraphasia), (2) speech disorders (including speech arrest
5 and dysarthria), (3) negative motor responses of the upper limb, (4) positive motor responses
6 of the face and upper limb, (5) dysesthesia and (6) semantic association disorders.

7 The above-mentioned intraoperative manifestations were determined as follows: a
8 negative motor response was defined as a complete inhibition of movement without the loss of
9 muscle tone or consciousness;^{38,39} a positive motor response was defined as the contraction of
10 a muscle or muscle group causing an involuntary movement;⁴⁰ speech arrest was defined as a
11 complete discontinuation of the ongoing number counting or continuous speaking, without oral,
12 facial, jaw, or tongue positive movements^{32,39} (of note, it was not possible to perform a
13 concomitant movement task of the face and thus to strictly distinguish a facial negative motor
14 response from a speech arrest); anomia was defined as an inability to name an object, while still
15 being able to pronounce the words “this is a [picture]” (naming task)⁴¹, thus allowing to rule
16 out a speech arrest manifestation; paraphasia was specifically defined by a misnaming of an
17 object, using the same paradigm; dysarthria was defined as a disorder of articulatory planning
18 and/or speech sound production (word groping, sound distortion, prosodic abnormalities),
19 without oral, facial, jaw, or tongue positive movements; a semantic association disorder was
20 defined as an incorrect response or an inability to respond during the Pyramid and Palm Tree
21 task.

22 Functional responses in one of these categories at Surg.1 were only considered if the
23 same task(s) were applied at Surg.2. Note that some stimulations could produce concomitant
24 disorders and were further considered in both disorder categories in further analyses (*e.g.*,
25 speech arrest plus negative motor response of the upper limb). Two photographs were done:
26 one at the end of the cortical mapping, and one at the end of the resection. In addition,
27 procedures were recorded with a built-in camera attached to the operating lights.

28

29 **Neuroimaging processing**

30 T1-weighted and fluid-attenuated inversion recovery (FLAIR) preoperative and postoperative
31 MRI were systematically acquired the day before and at 3-months after both surgeries. MRIs
32 were co-registered to the Montreal Neurological Institute (MNI) space using enantiomorphic

1 normalization⁴² with SPM12 (Statistical Parametric Mapping,
2 <https://www.fil.ion.ucl.ac.uk/spm/software/spm12>) and the Clinical toolbox
3 (<https://www.nitrc.org/projects/clinicaltbx>) implemented in MATLAB environment (Release
4 2018a, The MathWorks Inc., Natick, NA, USA).

5

6 **Spatial positioning of DES sites**

7 The MNI coordinates for each stimulation site were determined after inspection of operative
8 reports, intraoperative photographs (positive stimulations) and intraoperative videos (negative
9 sites), as illustrated in Figure 1B and 1C. This method was previously demonstrated to provide
10 an high inter-observer reliability.^{27,43} The MRI obtained 3 months after Surg.1 was
11 systematically used as the reference image for spatial positioning, since it allowed a comparison
12 between the post-resection photograph obtained during Surg.1 and the pre-resection photograph
13 obtained during Surg.2. In addition, 3-dimensional pial-mesh reconstructions of the MRI
14 obtained 3 months after Surg.1 were generated with BrainVISA/Anatomist software (Version
15 5.0, CEA I2BM, CATI Neuroimaging, Inserm IFR49, and CNRS, France) to allow a 3D
16 visualization of individual cortical structures and a semi-automated MNI coordinate-surface
17 matching of the model (Figure 1D). To demonstrate the reproducibility of the procedure used
18 to position cortical sites despite a more challenging identification of gyro-sulcal anatomy at
19 reoperation,⁴⁴ intra- and inter-observer correlation coefficients were computed. More
20 specifically, the first observer positioned two times consecutively 100 stimulation sites
21 randomly selected within the left hemisphere. Pearson correlations were performed between
22 each set of coordinates to derive measures of intra-observer agreement (one for each axis).
23 Likewise, a second observer also positioned the same 100 sites to derive this time measures of
24 inter-observer agreement. We also used simple two-tailed *t*-tests to check for differences
25 between each coordinate dataset. Note that the procedure was performed by two experts in
26 neuroanatomy. Overall, we found a high degree of intra and inter-observer agreement (see
27 Supplementary Figure 1).

28

29 **Probabilistic distributions of functional sites**

30 **Voxel-wise density maps**

1 For each DES site, we assumed that the associated functional response f_i (where i corresponds
 2 to a given stimulation with $i=1, \dots, n$ for n stimulations) is maximal at the centre of the
 3 stimulated area. Furthermore, to account for the spread of the electrical current nearby this
 4 central position, we approximated f_i in all surrounding voxels (from 1 at the centre to 0 in all
 5 voxels sufficiently distant from this centre) with a standard kernel regression technique. Using
 6 the function “fslmaths” in FMRIB Software Library program (FSL, version 6.0,
 7 <https://fsl.fmrib.ox.ac.uk/fsl>), we applied a full width at half maximum (FWHM) of 8mm
 8 (bandwidth ≈ 3.4 mm) for each DES site, which is more conservative than previous studies
 9 pointing out that bandwidth values were acceptable until 4-5mm in the same experimental
 10 settings.^{28,45} In order to represent the spatial distribution of all stimulation sites, we then
 11 computed a voxel-wise overlap map by summing individual kernel-transformed maps.
 12 Consequently, for each voxel x of the brain, we obtained a density overlap map with $Density_x =$
 13 $\sum_{i=1}^n f_i$

14

15 **Voxel-wise probability maps**

16 To map the potential of cortical areas to be associated with positive or negative responses, we
 17 computed voxel-wise probability maps by calculating the ratio of positive responses and
 18 negative responses in each voxel. In particular, we defined the probability that a given voxel x
 19 of the brain is implicated in a functional response as a positive probability, and the probability
 20 that a given voxel x of the brain is implicated in a negative response as a negative probability.
 21 Thus, we calculated positive and negative probability maps at Surg.1 and Surg.2 with the
 22 following formula:

23

$$24 \text{ Positive_Probability}_x = \frac{\sum_{i=1}^v f_{\text{positive}_i}}{(\sum_{i=1}^v f_{\text{positive}_i} + \sum_{k=1}^w f_{\text{negative}_k})}$$

$$25 \text{ Negative_Probability}_x = \frac{\sum_{k=1}^w f_{\text{negative}_k}}{(\sum_{i=1}^v f_{\text{positive}_i} + \sum_{k=1}^w f_{\text{negative}_k})}$$

26 where f_{positive_i} and f_{negative_j} are the functional responses of v positive stimulation(s) (with
 27 $i=1, \dots, v$) and w negative stimulation(s) (with $k=1, \dots, w$).

28

29 **Voxel-wise plastic probability maps**

1 To capture the propensity of cortical areas to be functional at Surg.1, while becoming non-
 2 functional at Surg.2, which can be interpreted as a marker of cortical remodelling, we further
 3 computed a probability map representing the intersection between positive probability maps at
 4 Surg.1 and negative probability maps at Surg.2 as follows (*i.e.* a plasticity probability map):

$$5 \text{ Plasticity_Probability}_x = \text{Surg.1_positive_probability}_x * \text{Surg.2_negative_probability}_x$$

7 **Parcel-wise probability map**

8 Next, we used predefined cortical parcels to contextualize the ratio between positive and
 9 negative responses in terms of anatomical location. Our goal was to allow an explicit
 10 assignment of DES effects in specific anatomical structures. This approach also permits a
 11 substantial reduction of the dimensionality of the stimulation dataset in comparison to voxel-
 12 based analyses. To estimate the probability of obtaining a positive response within *a priori*
 13 anatomical parcellations, we used the Brainnetome atlas (<https://atlas.brainnetome.org/bntatlas>,
 14 composed of 123 labelled parcels, see Supplementary materials for a list of all cortical parcels).
 15 More specifically, we divided the number of positive DES by the total number of DES (positive
 16 and negative) in a given parcel. For instance, the probability of observing a positive response
 17 during Surg.1 within the region 6_1 of the left Precentral gyrus (left PrG_6_1) was 0.973 (*i.e.*,
 18 215 positive DES/ 221 positive and negative DES). Each stimulation site was generated as an
 19 MNI-registered sphere using Marsbar Toolbox (radius=5mm), implemented in the MATLAB
 20 environment (<https://marsbar-toolbox.github.io>). To determine the location of each sphere in
 21 terms of anatomical parcels, we used the Lesion Quantification Toolkit
 22 (<https://wustl.app.box.com/v/LesionQuantificationToolkit>)⁴⁶. The function
 23 “util_get_parcel_damage” was applied for each stimulation point (see Supplementary Figure 2
 24 and Supplementary materials for more details and links to custom MATLAB codes). The ratio
 25 of positive and negative DES was then compared between Surg.1 and Surg.2, within each
 26 anatomical parcel with >3 DES, using Fisher’s exact tests. Benjamini-Hochberg’s false
 27 discovery rate (FDR) correction for multiple comparisons was used in each hemisphere
 28 separately, with a threshold set at $P < 0.05$ (*Rstudio*, 2021.09.1 Build 372, www.r-project.org).

29

30 **Clustering analyses**

31 **K-mean clustering**

1 Clustering analyses were performed to assess the extent to which the distribution pattern of
2 functional sites was changing from Surg.1 to Surg.2. In this analysis, only positive stimulations
3 were considered. Clustering analyses were performed separately at Surg.1 and Surg.2. For a
4 given behaviour response of interest (*i.e.* language disorders, speech arrest and dysarthria,
5 positive motor responses and negative motor responses), the MNI coordinates of all stimulation
6 sites were analysed with *R* software using the Flexible Procedures for Clustering package (fpc,
7 version 2.2-9). Note that somatosensorial responses were not considered here, because of the
8 limited amount of available data per hemisphere during Surg.2. A Duda-Hart statistic was used
9 to determine whether a given dataset should be clustered. Datasets with a Duda-Hart statistic
10 >1.645 were further subjected to a *k*-mean clustering; the remaining ones were represented as
11 single clusters. The optimal number of clusters (range: 2-10) was determined using the most
12 conservative result (*i.e.* the smallest number of suggested clusters) obtained from the average
13 silhouette width method and the Calinski Harabasz index method. Stimulation sites and their
14 related centroids were further plotted in a z/y MNI graph representation to allow an easier
15 visualization of their locations.

16

17 **Cluster comparisons**

18 Based on a qualitative analysis, we next identified: (i) Clusters presenting with spatial
19 similarities but potential shifts of their coordinates from Surg.1 to Surg.2. To provide a
20 quantitative overview of cluster shifts, the MNI coordinates of stimulations sites forming
21 similar clusters were analysed with two-tailed *t*-tests. FDR correction for multiple comparisons
22 was used for each hemisphere separately, with a threshold set at $P < 0.05$; (ii) Clusters that
23 disappeared from Surg.1 to Surg.2 and their related centroids; (iii) Clusters that appeared from
24 Surg.1 to Surg.2 and their related centroids.

25

26 **Dynamic remodelling of individual functional cortical maps**

27 **Individual functional cortical maps**

28 To better highlight the neuroplasticity potential outlined in previous analyses, we directly
29 contrasted the changes in the distribution of functional responses from one surgery to another
30 at the individual level. First, we identified cortical areas that were uniformly covered by DES
31 from one surgery to another in each patient by generating a reference binarized map

1 corresponding to the intersection map between the sum of all stimulations at Surg.1 and Surg.2.
2 By doing so, areas eliciting positive (or negative) response during only one of the two
3 electrostimulation sessions were not considered in further statistical analyses.

4 Second, we computed an individual functional cortical map accounting for positive
5 responses at Surg.1 and Surg.2 in each patient. Briefly, we computed functional responses in
6 each patient using a standard kernel regression technique to approximate a cortical functional
7 map (with each voxel having a value between 0 and 1) exclusively within the previously
8 generated intersection map (*i.e.* within voxels covered by DES during both Surg.1 and Surg.2).

9 Individual functional cortical maps were computed to investigate plasticity in general
10 (*i.e.* all positive functional responses were selected), or in the different functional responses
11 taken separately. It should be mentioned that non-responsive DES sites for a given function of
12 interest were considered as non-functional DES (*e.g.* in language mapping, DES eliciting
13 positive motor responses without associated language disorders were considered negative for
14 language). More details and links to custom MATLAB codes are provided in Supplementary
15 figure 3 and Supplementary materials).

17 **Surg.1 and Surg.2 statistical comparisons**

18 Each patient's functional cortical maps (FCMs) at Surg.1 and Surg.2 were then used to study
19 the cortical neuroplastic changes from one surgery to another. To do so, non-parametric
20 statistics were performed, using the "randomise" function from FSL with 5000 permutations
21 and threshold free cluster enhancement. To achieve a paired comparison analysis, we calculated
22 the difference between Surg.1 and Surg.2 FCMs within-subjects ($FCM_{Surg.1} - FCM_{Surg.2}$, using
23 "fslmaths" function) and then performed a one sample *t*-test across subjects, which is equivalent
24 to a paired *t*-test (<https://fsl.fmrib.ox.ac.uk/fsl/fslwiki/Randomise/UserGuide>). We corrected
25 for multiple comparisons with a family-wise error (FWE) threshold set at $P < 0.05$. Since we
26 assumed a prior hypothesis that individual FCMs were more restricted at Surg.2 compared to
27 Surg.1 ($FCM_{Surg.1} - FCM_{Surg.2} > 0$) due to higher neuroplastic compensations, we only provide the
28 results of one sample *t*-tests. Of note, we also performed the same analysis with the opposite
29 contrast (difference between Surg.2 and Surg.1.) but found no significant results.

30 To mitigate the potential effect of clinical or biological factors that may modulate
31 cortical plasticity, we next repeated the same analysis using 'stimulation intensity changes from
32 Surg.1 to Surg.2', 'histomolecular classification', 'the use of chemotherapy between Surg.1 and

1 Surg.2' and the 'time interval between Surg.1 and Surg.2' as nuisance covariates. Briefly, we
2 independently tested the effect of these covariates with both a 1/0 and a 0/1 contrasts within the
3 corresponding design matrix (FEAT interface, <https://fsl.fmrib.ox.ac.uk/fsl/fslwiki/GLM>)
4 before running "randomise" function from FSL.

5

6 **Residual functional cortical map, regrowth functional cortical map and** 7 **extra-lesional functional cortical map**

8 To assess whether the spatial patterns of tumour regrowth modulated cortical plasticity, we next
9 confronted the individual FCMs to each patient's tumoral infiltration pattern, based on FLAIR
10 images obtained 3 months after Surg.1 and immediately before Surg.2. As a result, in each
11 patient we were able to discriminate (1) a residual functional cortical map (changes of FCM
12 only within post-Surg.1 tumour residual), (2) a regrowth functional cortical map (changes of
13 FCM only within changes of FLAIR signal observed between post-Surg.1 and pre-Surg.2
14 MRIs) and (3) an extra-lesional functional cortical map (changes of FCM only outside pre-
15 Surg.2 tumour signal). Non-parametric statistics were then performed to compare each patient's
16 FCM, using the "randomise" function from FSL with 5000 permutations and threshold free
17 cluster enhancement (see above). Methodological details are illustrated in **Supplementary**
18 **Figure 4.**

19

20 **Data availability**

21 Data will be made available upon reasonable request to the corresponding author.

22 Exhaustive datasets are provided in the Supplementary materials, including custom MATLAB
23 codes. Visualization of the results were made with MRICroGL
24 (<https://www.nitrc.org/projects/microgl>) and SurfIce (<https://www.nitrc.org/projects/surfice>).

25

26 **Results**

27 **Participants**

1 Overall, 101 patients underwent repeat awake-guided surgical resections for a DLGG (49
2 female [48.5%], mean age at first surgery: 34.5 ± 9.1). Details about mean tumour volumes
3 before/after surgeries and the extent of resections are provided in the Supplementary materials.
4 Pre-surgical, post-surgical and tumour regrowth infiltration maps are displayed in
5 Supplementary Figure 5. The mean time interval between Surg.1 and Surg.2 was 53.52 ± 27.59
6 months (range: 7-125 months). Histopathological features at Surg.1 and Surg.2 are detailed in
7 the Supplementary materials. Note that 3 patients had a change of histomolecular classification
8 from Surg.1 to Surg.2 due to the absence of 1p19q codeletion and/or IDH1/2 mutation at the
9 first surgery. In addition, 13 patients (12.9%) presented with a change of grade according to the
10 WHO classification at Surg.2. Details about seizure control and the use of antiepileptic drugs
11 before Surg.1/Surg.2 are reported in the Supplementary materials. No patients received
12 radiation therapy before Surg.2. Thirty patients (29.7%) received chemotherapy between Surg.1
13 and Surg.2 (Temolozomide alone: 24 patients; Procarbazine/Lomustine/Vincristine: 3 patients;
14 a combination of both at different time points: 3 patients).

15 The total number of eligible cortical DES was 2082, including 1291 during Surg.1 (485
16 positive stimulations, 806 negative stimulations) and 791 during Surg.2 (351 positive
17 stimulations, 440 negative stimulations). The mean DES amplitude was 2.31 ± 0.58 mA. There
18 were no significant changes of stimulation intensities from Surg.1 to Surg.2 (mean intensity at
19 Surg1: 2.29 ± 0.60 mA, mean intensity at Surg2: 2.33 ± 0.56 mA, two-tailed paired t-test: $t_{(100)}$
20 = 0.64, $p = 0.52$). The locations of all stimulation sites are displayed in Figure 1E and 1F.
21 Among positive stimulations, 91 elicited language disorders (45 during Surg.1 and 46 during
22 Surg.2), 406 elicited speech production disorders (237 during Surg.1 and 169 during Surg.2),
23 164 elicited negative motor responses (65 during Surg.1 and 99 during surg.2), 230 elicited
24 positive motor responses (134 during Surg.1 and 96 during Surg.2), 73 elicited somatosensory
25 disorders (52 during Surg.1 and 21 during Surg.2) and 38 elicited semantic association disorders
26 (19 during Surg.1 and 19 during Surg.2, all within the right hemisphere).

27

28 **Probability maps**

29 **Voxel-wise probability maps**

30 Density maps and left and right voxel-wise positive probability maps are displayed in Figure
31 2A. Additional negative density maps are detailed in Supplementary figure 6. Voxel-wise

1 probabilistic neuroplasticity maps are displayed in Figure 2B. The maximal probabilities p_{max}
 2 (from 0, lowest neuroplasticity, to 1, highest neuroplasticity) were observed within the right
 3 SMA ($p_{max} = 0.63$), the right dlPFC ($p_{max} = 0.61$), the left supramarginalis gyrus (SMG, $p_{max} =$
 4 0.49), the left anterior part of the ventral PMC ($p_{max} = 0.43$), the left dlPFC ($p_{max} = 0.39$) and
 5 the middle portion of the left STG (STG, $p_{max} = 0.36$).

7 Parcel-wise probability maps

8 Parcel-wise probabilistic maps and related significant statistical comparisons are illustrated in
 9 Figure 2C-F. The number of stimulations (positive and negative) in each parcel is detailed in
 10 Supplementary materials.

11 The analyses indicated significant changes in probability distributions between positive
 12 and negative DES in the following parcels: left PrG6_1 parcel (*Fisher's exact test*, $p_{FDR-corrected}$
 13 $= 2.6 \times 10^{-5}$) the left PrG6_2 ($p_{FDR-corrected} = 0.046$), the left PrG6_6 ($p_{FDR-corrected} = 0.046$), the right
 14 MFG7_2 ($p_{FDR-corrected} = 6.6 \times 10^{-5}$), the right PrG6_1 ($p_{FDR-corrected} = 0.0058$) and the right PrG6_6
 15 ($p_{FDR-corrected} = 0.0039$). In all above-mentioned parcels, the ratio of positive/negative
 16 stimulations consistently decreased at Surg.2, with the exception of the left supramarginal gyrus
 17 (left IPL6_4, $p_{FDR-corrected} = 0.046$).

18 Clustering analyses

19 Clustering analysis results, locations of cluster centroids and significant shifts of cluster MNI
 20 coordinates between Surg.1 and Surg.2 are provided in Figure 3.

21 Within the left hemisphere, significant cluster migrations were found for language
 22 responses ($n_{Surg.1} = 45$ stimulations [4 clusters], $n_{Surg.2} = 46$ stimulations [3 clusters], see Figure
 23 3A), with a significant antero-posterior shift of paired centroids within the dlPFC (mean MNI_y-
 24 coordinates change = -10.4 ± 3.0 $t_{(32)} = 3.46$, $p_{FDR-corrected} = 0.007$). In addition, a language
 25 cluster located within the left STG during Surg.1 (centroid MNI coordinates [-65.1; -22.3; 7.7])
 26 disappeared at Surg.2. Cluster shifts were also found in speech arrest/dysarthria ($n_{Surg.1} = 167$
 27 stimulations [2 clusters], $n_{Surg.2} = 115$ stimulations [2 clusters], see Figure 3C) with a ventro-
 28 dorsal shift of a cluster located within the medio-dorsal part of the precentral gyrus (mean
 29 MNI_x-coordinates change = 8.3 ± 2.0 , $t_{(87)} = 4.23$ $p_{FDR-corrected} < 0.0001$; mean MNI_z-coordinates
 30 change = 9.1 ± 2.0 , $t_{(87)} = 4.49$, $p_{FDR-corrected} < 0.0001$). An additional cluster was identified at
 31 Surg.2 regarding stimulations eliciting negative motor responses (left precentral gyrus, centroid

1 MNI coordinates [-35.9; -5.6; 61.6], see Figure 3E). No cluster change was observed for
2 stimulations provoking positive motor responses (Figure 3G).

3
4 Within the right hemisphere, cluster locations were also comparable regarding DES-
5 induced non-verbal semantic disorders ($n_{\text{Surg.1}} = 9$ stimulations [1 cluster], $n_{\text{Surg.2}} = 12$
6 stimulations [1 cluster], see Figure 3B). Additional clusters were identified at Surg.2, especially
7 regarding stimulations eliciting speech arrest/dysarthria (right SMG, centroid MNI coordinates
8 [64.2; -24; 32], see Figure 3D) and negative motor responses (right precentral gyrus, centroid
9 MNI coordinates [49.6; 0.88; 50.7], see Figure 3F). Interestingly an antero-posterior shift of a
10 cluster located within the right upper precentral gyrus/right SMA toward the right upper
11 precentral gyrus was observed (mean MNI_y -coordinates change = -13.8 ± 3.0 , $t_{(28)} = 4.55$, $p_{\text{FDR-}}$
12 $\text{corrected} < 0.0001$, Figure 3F). No significant changes in cluster coordinate positioning were
13 observed between the two surgeries for stimulations provoking positive motor responses within
14 the right hemisphere ($n_{\text{Surg.1}} = 64$ stimulations [2 clusters], $n_{\text{Surg.2}} = 54$ stimulations [2 clusters],
15 see Figure 3H).

17 **Dynamic reorganizations of individual functional cortical maps**

18 The overlap of cortical areas being stimulated both at Surg.1 and Surg.2 at the individual level
19 is displayed in Figure 4A. Statistically significant differences between both functional cortical
20 maps are provided as $1-p$ maps (FWE-corrected, threshold free cluster enhancement, 5000
21 permutations). The results of FCM comparisons when adjusted for each covariate
22 independently (*i.e.* stimulation intensity changes, histomolecular classification, the use of
23 chemotherapy and the time interval between Surg.1 and Surg.2) still remained significant, with
24 only modulations in terms of cluster size. In addition, no linear significant relationships were
25 observed between FCM measures and each covariate taken separately (see Supplementary
26 Materials). Results by behavioural response (Figure 4B) indicate significant reorganizations (i)
27 for language responses within both the left dlPFC and the left anterior STG, (ii) for speech
28 arrest/dysarthria within the left vPMC and to some extent at the junction between the right
29 dorsal PMC and the precentral gyrus (iii) for semantic response within the right dlPFC and (iv)
30 for negative motor responses within the right vPMC. Cortical areas eliciting positive motor
31 responses (left and right hemispheres) and negative motor responses (left hemisphere) remained
32 unchanged from Surg.1 to Surg.2. Overall, high neuroplastic reorganizations occurred in the

1 left dlPFC, the left vPMC, the posterior part of the inferior frontal gyrus (IFG), the anterior part
2 of the left STG and the right dlPFC (Figure 4C).

3 Significant voxels were found both within the residual functional cortical map, the regrowth
4 functional cortical map and the extra-lesional functional cortical map, highlighting cortical
5 plasticity potential both within and directly around the cortical tumoral infiltration (see
6 Supplementary Figure 7).

8 **Discussion**

9 The unique ability of the cerebral cortex to rearrange the topological organization of its cortical
10 networks has been highlighted in response to various pathological settings, including peripheral
11 lesions (*e.g.* in case of deprivation of normal sensory inputs),^{2,47} congenital or brain injuries
12 such as brain tumours and stroke.^{48,49} It is widely acknowledged that lesion-induced plasticity
13 is a time-dependent process, though it has been rarely investigated longitudinally, especially in
14 the context of slow-growing tumours where neuroplastic changes are widespread. In other
15 words, the longitudinal study of DLGG patients may help address fundamental questions about
16 the properties of tumour-induced plasticity: Is postlesional plasticity a time-limited process? Is
17 the potential for cortical remodelling equivalent across brain areas?

18 In the present study, we capitalized on a large and longitudinal electrostimulation dataset
19 acquired from patients with DLGG to test the hypothesis that lesion-induced plasticity follows
20 an evolving and spatially constrained scheme across the human cortex. Overall, our results
21 show that (i) cortical areas have a potential for evolving rearrangements which is however
22 graded across the cortex; (ii) this dynamic potential appears to be constrained by the underlying
23 functional neuroanatomy (*e.g.*, primary sensorimotor cortices) and (iii) the efficiency of cortical
24 rearrangements might be domain-specific, with higher plastic potentials in cortical circuits
25 underpinning language and speech production.

26 The temporal pattern of tumour expansion is believed to be a key mechanistic principle
27 governing the efficiency with which neuroplasticity deploys in DLGG patients.¹⁶ However,
28 there is only a handful of studies that have investigated the longitudinal features of glioma-
29 induced neuroplasticity in general^{50,51} – those using DES mapping being based on small
30 datasets.^{24,25} Here we showed that the potential of cortical areas to undergo glioma-induced
31 rearrangement evolves from one surgery to another, albeit with an important variability across

1 the cerebral cortex. Furthermore, we demonstrated that cortical plasticity evolves not only
2 within the lesion, but also around the cortical infiltration. This confirms that important spatial
3 cortical rearrangements occur as a consequence of a dynamic interplay between the brain and
4 the tumour, as reported in previous case series.^{25,52} In addition, the present study suggests a
5 marked heterogeneity in the plasticity potential across cortical structures. Such differing
6 potential can be conceived as a gradient, the value of which varies as a function of cortical
7 areas. Low gradients of plasticity were mainly found within unimodal cortical structures, those
8 which belong to what have been previously called the “minimal common brain” (*i.e.* a universal
9 trunk formed by cortico-subcortical structures that is essential for basic cerebral functions, with
10 low interindividual variability),⁵³ including the primary somatosensory and motor cortices.
11 This result aligns with that of a recent MEG study showing only subtle ipsilesional longitudinal
12 changes of motor activations in patients with recurrent gliomas.⁵⁰ Admittedly however, the
13 restricted plasticity potential observed in the primary motor areas at reoperation has to be
14 interpreted in the light of a limited tumoral regrowth within cortical areas of the precentral gyrus
15 (in particular, the primary hand area), while adjacent connective tracts were generally more
16 infiltrated compared to the initial surgery. Increasing sample size in future studies may help
17 capture a more in-depth picture of the potential of all cortical motor areas to be rewired
18 following glioma relapse, an important point considering that plasticity of the primary
19 sensorimotor cortex at first operation has been sometimes described.^{52,54–56}

20 Remarkably, cluster analyses confirmed that positive language sites within the middle
21 portion of the STG tended to turn negative during the second surgery, thus supporting the results
22 of a recent MEG study indicating that the neural network underpinning language may be
23 especially plastic in recurrent glioma patients, the mechanism of which would be a laterality
24 shift in hemispheric specialization.⁵¹

25 Interestingly, we observed higher gradients of neuroplasticity within the vPMC, a result
26 that was not particularly expected given the role of this region in speech production and its
27 topologically-constrained neuroplasticity potential at initial surgery.⁵⁷ Indeed, the speech-
28 related lateral part of the precentral gyrus was substantially rearranged between two surgeries,
29 with a migration of sites from the ventral to the dorsal premotor cortex. This intragyral
30 reorganisation may be explained by the fact that the third branch of the superior longitudinal
31 fasciculus, which is known to convey speech articulatory related information from the
32 supramarginal gyrus to the vPMC,⁵⁸ also projects more dorsally in the precentral gyrus. In other
33 words, one can speculate that the dorsal trajectory of cortical rearrangements might depend on

1 the connective properties of the superior longitudinal fasciculus III. Likewise, the high potential
2 for evolving neuroplastic compensation within the posterior dlPFC appears to be challenging
3 given its topological positioning into the anatomo-functional architecture. Indeed, the dlPFC
4 acts as a high-centrality cortical hub, and is thought to support transmodal integration.⁵⁹ Yet,
5 our findings might be sustained by further functional compensation within the contralateral
6 dlPFC, given the expected contribution of both dlPFC especially in semantic processing.³³

7 Our results may have important clinical implications in at least two directions. First,
8 DLGG are diffuse neoplasms showing a recurrent infiltration within the brain parenchyma. In
9 the context of multistage surgical management,⁶⁰ a better understanding of the mechanistic
10 principles of cortical reallocation over time is of major importance to assess re-operability in
11 patients for whom the glioma recurs (*e.g.* earlier reoperation might be suggested in the event of
12 dlPFC, vPMc, or STG infiltration). Second, our results pave the way for future interventional
13 therapies aimed at fostering individual dynamics of plasticity or “meta-plasticity” (a term
14 recently reappraised to account for the susceptibility of brain plasticity to adapt its learning
15 rules in an ever changing context).⁶¹ For example, cortical areas associated with a high potential
16 of continuous plasticity may be potential targets for non-invasive neuromodulation therapy.
17 Such a proactive approach coupled with cognitive stimulation may help accelerate cortical
18 redistributions and thus allows earlier reoperation and greater extent of resection while
19 minimizing the likelihood of postoperative deficits.⁶²

21 **Limitations**

22 Our main findings must be interpreted in light of several limitations. First, the cerebral cortex
23 was not uniformly covered by cortical electrostimulations given that the topological distribution
24 of DES sites was conditional to that of tumour (re)infiltration. Second, due to the clinical
25 context of the study, some biological and therapeutical variables with a potential influence on
26 neuroplasticity could not be directly controlled between the two surgeries (*e.g.* time interval
27 between Surg.1 and Surg.2, switch of antiepileptic drugs, use of adjuvant chemotherapy),
28 although adjusted statistical analyses did not suggest critical a determinant effect of these
29 variables on plasticity changes. Third, thirteen patients (12.9%) presented with a shift of their
30 histomolecular grade toward higher-grade gliomas, which may impact our results. In these
31 patients, it is possible that the dynamic potential for cortical reorganization between both
32 surgeries might have been lowered.¹⁶ Fourth, we considered negative stimulation sites as

1 cortical areas free of function, which is a necessary reductionist (but clinically relevant)
2 approach given the fact that these areas are not stimulated for the large array of existing
3 cognitive and fine-grained motor functions. For example, all aspects of motor control are not
4 assessed,^{63,64} meaning that the neuroplasticity potential of motor regions might have been
5 underestimated. This potential shortcoming is however mitigated by the clinical observation
6 that surgical removal of negative sites is not associated with a postoperative decline of
7 intraoperatively unassessed functions.^{19,26} Last, the probability of observing a loss of functional
8 sites at Surg.2 (*i.e.* a functional area at Surg.1 turning negative at Surg.2) was higher than the
9 probability of observing a displacement of positive sites (*i.e.* the migration of one positive
10 stimulation at Surg.1 to another area at Surg.2). This suggests that remote, nonlocal
11 compensatory cortical sites are potentially recruited (either in the ipsilateral or contralateral
12 hemisphere), beyond the cortical surface exposed during surgery which is necessarily limited.

13

14 **Conclusions**

15 Overall, our findings indicate that the slow re-growth of DLGGs favours a gradual and evolving
16 remodelling of the cerebral cortex from one surgery to another. This dynamic potential can be
17 expressed as a gradient to the extent that some cortical areas (the dorsolateral prefrontal cortex,
18 the ventral premotor cortex, the superior temporal gyrus) display a higher propensity to
19 reorganize than others (primary sensorimotor cortices). Furthermore, the efficiency of cortical
20 reorganization may be domain-specific, with a higher potential for cortical circuits
21 underpinning language and speech production. Taken together, these novel findings provide a
22 new insight into the neuroplastic properties of cortical networks and are of immense interest for
23 the clinical management of patients, especially in case of tumour recurrence.

24

25 **Funding**

26 No funding was received towards this work.

27

28 **Competing interests**

29 The authors report no competing interests.

30

1 **Supplementary material**

2 Supplementary material is available at *Brain* online.

4 **References**

- 6 1. Mesulam M. From sensation to cognition. *Brain*. 1998;121(6):1013-1052.
7 doi:10.1093/brain/121.6.1013
- 8 2. Buonomano DV, Merzenich MM. Cortical plasticity: From Synapses to Maps. *Annu Rev*
9 *Neurosci*. 1998;21(1):149-186. doi:10.1146/annurev.neuro.21.1.149
- 10 3. Sampaio-Baptista C, Johansen-Berg H. White Matter Plasticity in the Adult Brain. *Neuron*.
11 2017;96(6):1239-1251. doi:10.1016/j.neuron.2017.11.026
- 12 4. Li P, Legault J, Litcofsky KA. Neuroplasticity as a function of second language learning:
13 Anatomical changes in the human brain. *Cortex*. 2014;58:301-324.
14 doi:10.1016/j.cortex.2014.05.001
- 15 5. Herholz SC, Zatorre RJ. Musical Training as a Framework for Brain Plasticity: Behavior,
16 Function, and Structure. *Neuron*. 2012;76(3):486-502. doi:10.1016/j.neuron.2012.10.011
- 17 6. Zatorre RJ, Fields RD, Johansen-Berg H. Plasticity in gray and white: neuroimaging
18 changes in brain structure during learning. *Nat Neurosci*. 2012;15(4):528-536.
19 doi:10.1038/nn.3045
- 20 7. Rocha RP, Koçillari L, Suweis S, et al. Recovery of neural dynamics criticality in
21 personalized whole-brain models of stroke. *Nat Commun*. 2022;13(1):3683.
22 doi:10.1038/s41467-022-30892-6
- 23 8. Salvalaggio A, De Filippo De Grazia M, Zorzi M, Thiebaut de Schotten M, Corbetta M.
24 Post-stroke deficit prediction from lesion and indirect structural and functional
25 disconnection. *Brain*. 2020;143(7):2173-2188. doi:10.1093/brain/awaa156
- 26 9. Stockert A, Wawrzyniak M, Klingbeil J, et al. Dynamics of language reorganization after
27 left temporo-parietal and frontal stroke. *Brain*. 2020;143(3):844-861.
28 doi:10.1093/brain/awaa023

- 1 10. Louis DN, Perry A, Wesseling P, et al. The 2021 WHO Classification of Tumors of the
2 Central Nervous System: a summary. *Neuro-Oncology*. 2021;23(8):1231-1251.
3 doi:10.1093/neuonc/noab106
- 4 11. Duffau H. Lessons from brain mapping in surgery for low-grade glioma: insights into
5 associations between tumour and brain plasticity. *The Lancet Neurology*. 2005;4(8):476-
6 486. doi:10.1016/S1474-4422(05)70140-X
- 7 12. Duffau H. The huge plastic potential of adult brain and the role of connectomics: New
8 insights provided by serial mappings in glioma surgery. *Cortex*. 2014;58:325-337.
9 doi:10.1016/j.cortex.2013.08.005
- 10 13. Venkataramani V, Tanev DI, Strahle C, et al. Glutamatergic synaptic input to glioma cells
11 drives brain tumour progression. *Nature*. 2019;573(7775):532-538. doi:10.1038/s41586-
12 019-1564-x
- 13 14. Venkatesh HS, Morishita W, Geraghty AC, et al. Electrical and synaptic integration of
14 glioma into neural circuits. *Nature*. 2019;573(7775):539-545. doi:10.1038/s41586-019-
15 1563-y
- 16 15. Jung E, Alfonso J, Osswald M, Monyer H, Wick W, Winkler F. Emerging intersections
17 between neuroscience and glioma biology. *Nat Neurosci*. 2019;22(12):1951-1960.
18 doi:10.1038/s41593-019-0540-y
- 19 16. Desmurget M, Bonnetblanc F, Duffau H. Contrasting acute and slow-growing lesions: a
20 new door to brain plasticity. *Brain*. 2006;130(4):898-914. doi:10.1093/brain/awl300
- 21 17. Almairac F, Deverdun J, Cochereau J, et al. Homotopic redistribution of functional
22 connectivity in insula-centered diffuse low-grade glioma. *NeuroImage: Clinical*.
23 2021;29:102571. doi:10.1016/j.nicl.2021.102571
- 24 18. Ng S, Deverdun, Jeremy, Lemaitre, Anne-Laure, et al. Precuneal gliomas promote
25 behaviorally relevant remodeling of the functional connectome. *J Neurosurg*. Published
26 online 2022. doi:10.3171/2022.9.JNS221723
- 27 19. Lemaitre AL, Herbet G, Ng S, Moritz-Gasser S, Duffau H. Cognitive preservation
28 following awake mapping-based neurosurgery for low-grade gliomas: A longitudinal,
29 within-patient design study. *Neuro-Oncology*. 2022;24(5):781-793.
30 doi:10.1093/neuonc/noab275

- 1 20. Herbet G, Maheu M, Costi E, Lafargue G, Duffau H. Mapping neuroplastic potential in
2 brain-damaged patients. *Brain*. 2016;139(3):829-844. doi:10.1093/brain/awv394
- 3 21. Ramakrishna R, Hebb A, Barber J, Rostomily R, Silbergeld D. Outcomes in Reoperated
4 Low-Grade Gliomas. *Neurosurgery*. 2015;77(2):175-184.
5 doi:10.1227/NEU.0000000000000753
- 6 22. Shofty B, Haim O, Costa M, et al. Impact of repeated operations for progressive low-grade
7 gliomas. *European Journal of Surgical Oncology*. 2020;46(12):2331-2337.
8 doi:10.1016/j.ejso.2020.07.013
- 9 23. De Witt Hamer PC, Robles SG, Zwinderman AH, Duffau H, Berger MS. Impact of
10 Intraoperative Stimulation Brain Mapping on Glioma Surgery Outcome: A Meta-Analysis.
11 *JCO*. 2012;30(20):2559-2565. doi:10.1200/JCO.2011.38.4818
- 12 24. Picart T, Herbet G, Moritz-Gasser S, Duffau H. Iterative Surgical Resections of Diffuse
13 Glioma With Awake Mapping: How to Deal With Cortical Plasticity and Connectomal
14 Constraints? *Neurosurgery*. 2019;85(1):105-116. doi:10.1093/neuros/nyy218
- 15 25. Southwell DG, Hervey-Jumper SL, Perry DW, Berger MS. Intraoperative mapping during
16 repeat awake craniotomy reveals the functional plasticity of adult cortex. *JNS*.
17 2016;124(5):1460-1469. doi:10.3171/2015.5.JNS142833
- 18 26. Ng S, Lemaitre AL, Moritz-Gasser S, Herbet G, Duffau H. Recurrent Low-Grade Gliomas:
19 Does Reoperation Affect Neurocognitive Functioning? *Neurosurgery*. 2022;90(2):221-
20 232. doi:10.1227/NEU.0000000000001784
- 21 27. Lu J, Zhao Z, Zhang J, et al. Functional maps of direct electrical stimulation-induced speech
22 arrest and anomia: a multicentre retrospective study. *Brain*. 2021;144(8):2541-2553.
23 doi:10.1093/brain/awab125
- 24 28. Sarubbo S, Tate M, De Benedictis A, et al. Mapping critical cortical hubs and white matter
25 pathways by direct electrical stimulation: an original functional atlas of the human brain.
26 *NeuroImage*. 2020;205:116237. doi:10.1016/j.neuroimage.2019.116237
- 27 29. Tate MC, Herbet G, Moritz-Gasser S, Tate JE, Duffau H. Probabilistic map of critical
28 functional regions of the human cerebral cortex: Broca's area revisited. *Brain*.
29 2014;137(10):2773-2782. doi:10.1093/brain/awu168

- 1 30. Makale MT, McDonald CR, Hattangadi-Gluth JA, Kesari S. Mechanisms of radiotherapy-
2 associated cognitive disability in patients with brain tumours. *Nat Rev Neurol*.
3 2017;13(1):52-64. doi:10.1038/nrneuro.2016.185
- 4 31. Duffau H. New Philosophy, Clinical Pearls, and Methods for Intraoperative Cognition
5 Mapping and Monitoring “à la carte” in Brain Tumor Patients. *Neurosurgery*. Published
6 online January 19, 2021:nyaa363. doi:10.1093/neuros/nyaa363
- 7 32. Sanai N, Mirzadeh Z, Berger MS. Functional Outcome after Language Mapping for Glioma
8 Resection. *N Engl J Med*. 2008;358(1):18-27. doi:10.1056/NEJMoa067819
- 9 33. Herbet G, Moritz-Gasser S, Duffau H. Electrical stimulation of the dorsolateral prefrontal
10 cortex impairs semantic cognition. *Neurology*. 2018;90(12):e1077-e1084.
11 doi:10.1212/WNL.0000000000005174
- 12 34. Moritz-Gasser S, Herbet G, Duffau H. Mapping the connectivity underlying multimodal
13 (verbal and non-verbal) semantic processing: A brain electrostimulation study.
14 *Neuropsychologia*. 2013;51(10):1814-1822. doi:10.1016/j.neuropsychologia.2013.06.007
- 15 35. Duffau H, Ng S, Lemaitre AL, Moritz-Gasser S, Herbet G. Constant Multi-Tasking With
16 Time Constraint to Preserve Across-Network Dynamics Throughout Awake Surgery for
17 Low-Grade Glioma: A Necessary Step to Enable Patients Resuming an Active Life. *Front*
18 *Oncol*. 2022;12:924762. doi:10.3389/fonc.2022.924762
- 19 36. Ng S, Moritz-Gasser S, Lemaitre AL, Duffau H, Herbet G. White matter disconnectivity
20 fingerprints causally linked to dissociated forms of alexia. *Commun Biol*. 2021;4(1):1413.
21 doi:10.1038/s42003-021-02943-z
- 22 37. Yordanova YN, Cochereau J, Duffau H, Herbet G. Combining resting state functional MRI
23 with intraoperative cortical stimulation to map the mentalizing network. *NeuroImage*.
24 2019;186:628-636. doi:10.1016/j.neuroimage.2018.11.046
- 25 38. Lüders HO, Dinner DS, Morris HH, Wyllie E, Comair YG. Cortical electrical stimulation
26 in humans. The negative motor areas. *Adv Neurol*. 1995;67:115-129.
- 27 39. Rech F, Herbet G, Gaudeau Y, et al. A probabilistic map of negative motor areas of the
28 upper limb and face: a brain stimulation study. *Brain*. 2019;142(4):952-965.
29 doi:10.1093/brain/awz021

- 1 40. Penfield W, Boldrey E. Somatic Motor and Sensory representation in the Cerebral Cortex
2 of man as studied by Electrical Stimulation. *Brain*. 1937;60(4):389-443.
3 doi:10.1093/brain/60.4.389
- 4 41. Metz-Lutz MN, Kremin H, Deloche G, Hannequin D, Ferrand L, Perrier D, et al.
5 Standardisation d'un test de dénomination orale: contrôle des effets de l'âge, du sexe et du
6 niveau de scolarité chez les sujets adultes normaux. *Revue de Neuropsychologie* 1991; 1(1):
7 73-95.
- 8 42. Nachev P, Coulthard E, Jäger HR, Kennard C, Husain M. Enantiomorphic normalization
9 of focally lesioned brains. *NeuroImage*. 2008;39(3):1215-1226.
10 doi:10.1016/j.neuroimage.2007.10.002
- 11 43. Roux A, Lemaitre AL, Deverdun J, Ng S, Duffau H, Herbet G. Combining
12 Electrostimulation With Fiber Tracking to Stratify the Inferior Fronto-Occipital Fasciculus.
13 *Front Neurosci*. 2021;15:683348. doi:10.3389/fnins.2021.683348
- 14 44. Morshed RA, Young JS, Gogos AJ, et al. Reducing complication rates for repeat
15 craniotomies in glioma patients: a single-surgeon experience and comparison with the
16 literature. *Acta Neurochir*. 2022;164(2):405-417. doi:10.1007/s00701-021-05067-9
- 17 45. Sarubbo S, De Benedictis A, Merler S, et al. Towards a functional atlas of human white
18 matter: Functional Atlas of White Matter. *Hum Brain Mapp*. 2015;36(8):3117-3136.
19 doi:10.1002/hbm.22832
- 20 46. Griffis JC, Metcalf NV, Corbetta M, Shulman GL. Lesion Quantification Toolkit: A
21 MATLAB software tool for estimating grey matter damage and white matter
22 disconnections in patients with focal brain lesions. *NeuroImage: Clinical*. 2021;30:102639.
23 doi:10.1016/j.nicl.2021.102639
- 24 47. Feldman DE, Brecht M. Map Plasticity in Somatosensory Cortex. *Science*.
25 2005;310(5749):810-815. doi:10.1126/science.1115807
- 26 48. Hartwigsen G, Saur D. Neuroimaging of stroke recovery from aphasia – Insights into
27 plasticity of the human language network. *NeuroImage*. 2019;190:14-31.
28 doi:10.1016/j.neuroimage.2017.11.056
- 29 49. Saur D. Dynamics of language reorganization after stroke. *Brain*. 2006;129(6):1371-1384.
30 doi:10.1093/brain/awl090

- 1 50. Bulubas L, Sardesh N, Traut T, et al. Motor Cortical Network Plasticity in Patients With
2 Recurrent Brain Tumors. *Front Hum Neurosci.* 2020;14:118.
3 doi:10.3389/fnhum.2020.00118
- 4 51. Traut T, Sardesh N, Bulubas L, et al. MEG imaging of recurrent gliomas reveals functional
5 plasticity of hemispheric language specialization. *Hum Brain Mapp.* 2019;40(4):1082-
6 1092. doi:10.1002/hbm.24430
- 7 52. Duffau H, Denvil D, Capelle L. Long term reshaping of language, sensory, and motor maps
8 after glioma resection: a new parameter to integrate in the surgical strategy. *J Neurol*
9 *Neurosurg Psychiatry.* 2002;72(4):511-516. doi:10.1136/jnnp.72.4.511
- 10 53. Ius T, Angelini E, Thiebaut de Schotten M, Mandonnet E, Duffau H. Evidence for potentials
11 and limitations of brain plasticity using an atlas of functional resectability of WHO grade
12 II gliomas: Towards a “minimal common brain.” *NeuroImage.* 2011;56(3):992-1000.
13 doi:10.1016/j.neuroimage.2011.03.022
- 14 54. Schucht P, Ghareeb F, Duffau H. Surgery for low-grade glioma infiltrating the central
15 cerebral region: location as a predictive factor for neurological deficit, epileptological
16 outcome, and quality of life: Clinical article. *JNS.* 2013;119(2):318-323.
17 doi:10.3171/2013.5.JNS122235
- 18 55. Rossi M, Viganò L, Puglisi G, et al. Targeting Primary Motor Cortex (M1) Functional
19 Components in M1 Gliomas Enhances Safe Resection and Reveals M1 Plasticity Potentials.
20 *Cancers.* 2021;13(15):3808. doi:10.3390/cancers13153808
- 21 56. Nakajima R, Kinoshita M, Nakada M. Motor Functional Reorganization Is Triggered by
22 Tumor Infiltration Into the Primary Motor Area and Repeated Surgery. *Front Hum*
23 *Neurosci.* 2020;14:327. doi:10.3389/fnhum.2020.00327
- 24 57. van Geemen K, Herbet G, Moritz-Gasser S, Duffau H. Limited plastic potential of the left
25 ventral premotor cortex in speech articulation: Evidence From intraoperative awake
26 mapping in glioma patients: Ventral Premotor Cortex and Speech. *Hum Brain Mapp.*
27 2014;35(4):1587-1596. doi:10.1002/hbm.22275
- 28 58. Giampiccolo D, Duffau H. Controversy over the temporal cortical terminations of the left
29 arcuate fasciculus: a reappraisal. *Brain.* 2022;145(4):1242-1256.
30 doi:10.1093/brain/awac057

- 1 59. Margulies DS, Ghosh SS, Goulas A, et al. Situating the default-mode network along a
2 principal gradient of macroscale cortical organization. *Proc Natl Acad Sci USA*.
3 2016;113(44):12574-12579. doi:10.1073/pnas.1608282113
- 4 60. Duffau H, Taillandier L. New concepts in the management of diffuse low-grade glioma:
5 Proposal of a multistage and individualized therapeutic approach. *Neuro-Oncology*.
6 Published online August 2, 2014:nou153. doi:10.1093/neuonc/nou153
- 7 61. Duffau H. Introducing the concept of brain metaplasticity in glioma: how to reorient the
8 pattern of neural reconfiguration to optimize the therapeutic strategy. *Journal of*
9 *Neurosurgery*. 2022;136(2):613-617. doi:10.3171/2021.5.JNS211214
- 10 62. Ille S, Kelm A, Schroeder A, et al. Navigated repetitive transcranial magnetic stimulation
11 improves the outcome of postsurgical paresis in glioma patients – A randomized, double-
12 blinded trial. *Brain Stimulation*. 2021;14(4):780-787. doi:10.1016/j.brs.2021.04.026
- 13 63. Viganò L, Howells H, Fornia L, et al. Negative motor responses to direct electrical
14 stimulation: Behavioral assessment hides different effects on muscles. *Cortex*.
15 2021;137:194-204. doi:10.1016/j.cortex.2021.01.005
- 16 64. Fornia L, Rossi M, Rabuffetti M, et al. Direct Electrical Stimulation of Premotor Areas:
17 Different Effects on Hand Muscle Activity during Object Manipulation. *Cerebral Cortex*.
18 2020;30(1):391-405. doi:10.1093/cercor/bhz139

19
20

1 **Figure legends**

2 **Figure 1 Methodological framework for intraoperative stimulation and acquisition of**
 3 **normalized stimulation sites.** (A) Intraoperative protocol during wide-awake surgery with
 4 cognitive monitoring. (B and C) Illustration of intraoperative cortical mapping at Surg.1 and
 5 Surg.2, based on intraoperative photographs and camera recordings. (D) Positioning of
 6 stimulation sites (Surg.2, left hemisphere) onto a 3-dimensional pial mesh reconstruction
 7 normalized in the Montreal Neurological Institute space (BrainVISA/Anatomist software
 8 [Version 5.0, CEA I2BM, CATI Neuroimaging, Inserm IFR49, and CNRS, France]). (E)
 9 Eligible cortical stimulation sites during Surg.1 (485 positive stimulations, 806 negative
 10 stimulations) (F) Eligible cortical stimulation sites during Surg.2 (351 positive stimulations,
 11 440 negative stimulations). The same colour legends apply for the whole figure. DES: Direct
 12 electrostimulation, LH: left hemisphere, RH: right hemisphere, Surg.: Surgery

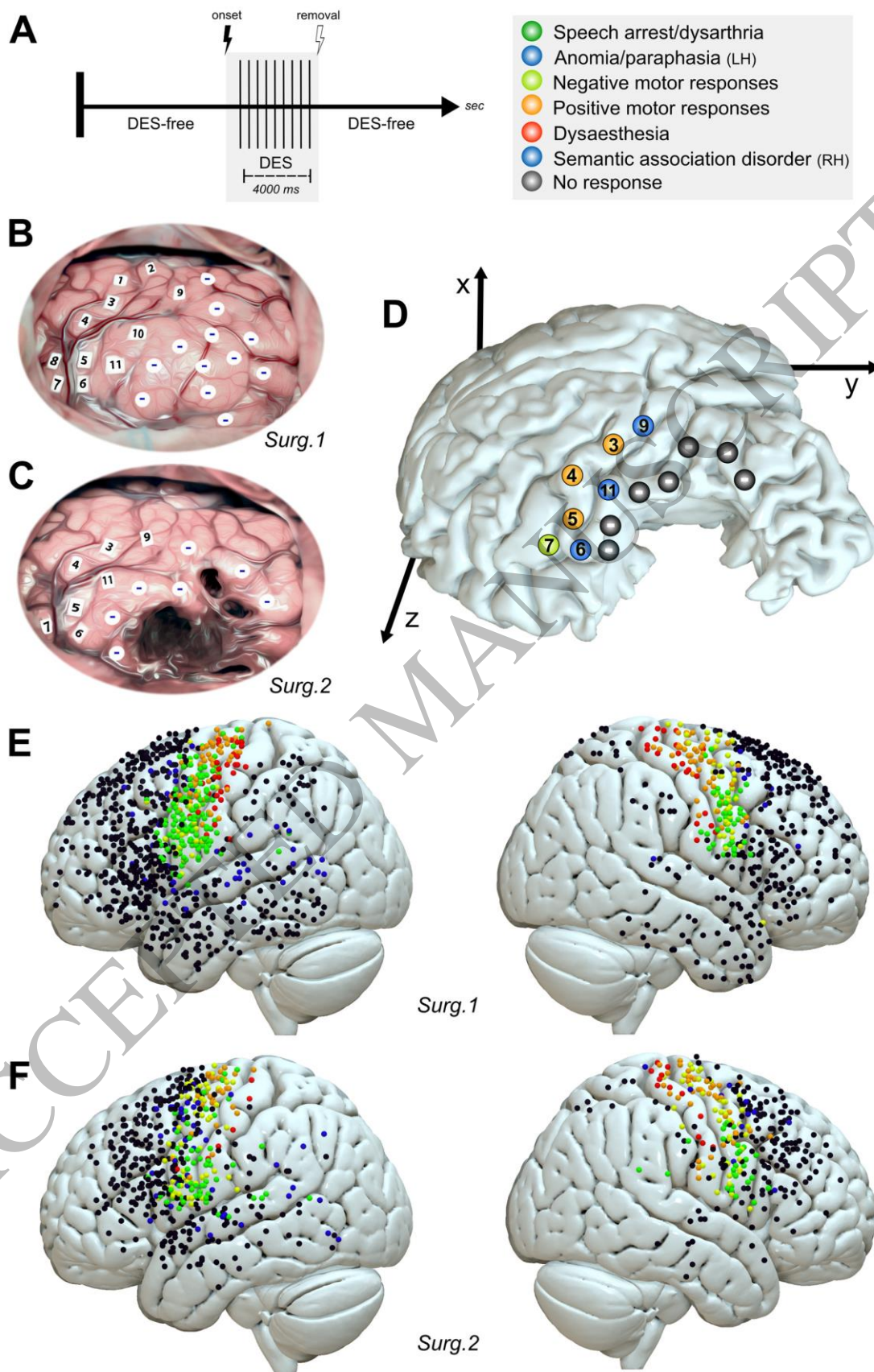
13
 14 **Figure 2 Voxelwise and parcelwise probability maps.** (A) Voxelwise positive probability
 15 maps (right panel), based on positive and negative stimulation density maps (left panel, here
 16 illustrating density maps within the left hemisphere at Surg.1). (B) Voxel-wise probabilistic
 17 neuroplasticity maps, illustrating the probability to obtain a positive (*i.e.* functional) response
 18 during Surg.1 cortical mapping while obtaining a negative (*i.e.* non-functional) response during
 19 Surg.2 cortical re-mapping. (C) Parcelwise probability results within the left hemisphere, based
 20 on the parcels of the Brainnetome atlas (<https://atlas.brainnetome.org/bntatlas>). (D) Significant
 21 results of parcelwise positive probability comparisons within the left hemisphere (*Fisher's*
 22 *exact test, FDR-correction*). (E) Parcelwise probability results within the right hemisphere,
 23 based on the parcels of the Brainnetome atlas. (F) Significant results of parcelwise positive
 24 probability comparisons within the right hemisphere. IPL: inferior parietal lobule, MFG: middle
 25 frontal gyrus, PrG: precentral gyrus, Stim.: stimulation, Surg.: surgery. , * indicates $p < 0.05$;
 26 ** indicates $p < 0.01$; *** indicates $p < 0.001$

27
 28 **Figure 3 Results of clustering analyses by functional response.** (A) Direct electrostimulation
 29 (DES) sites eliciting anomia and paraphasia and their related cluster centroids (orange mark at
 30 surgery 1, red mark at surgery 2) within the left hemisphere. The upper left panel indicates the
 31 location of DES sites at surgery 1. The bottom left panel indicates the location of DES sites at
 32 surgery 2. The right panel indicates cluster centroids at surgery 1 and surgery 2. (B) DES sites

1 eliciting non-verbal semantic disorders and their related cluster centroids (orange mark at
2 surgery 1, red mark at surgery 2) within the right hemisphere. (C) DES sites eliciting speech
3 arrest and dysarthria and their related cluster centroids within the left hemisphere. (D) DES
4 sites eliciting speech arrest and dysarthria and their related cluster centroids within the right
5 hemisphere. (E) DES sites eliciting negative motor responses and their related cluster centroids
6 within the left hemisphere. (F) DES sites eliciting negative motor responses and their related
7 cluster centroids within the right hemisphere. (G) DES sites eliciting positive motor responses
8 and their related cluster centroids (white mark at surgery 1, black mark at surgery 2) within the
9 left hemisphere. (H) DES sites eliciting positive motor responses and their related cluster
10 centroids (white mark at surgery 1, black mark at surgery 2) within the right hemisphere.
11 Significant displacements of cluster centroids are represented with a black arrow. Significant
12 modifications in Montreal Neurological Institute coordinates are illustrated with a * (*t-test*,
13 *FDR-correction*). Onsets of new clusters at surgery 2 are indicated with a red circle.
14 Disappearances of clusters at surgery 2 are indicated with an orange circle. Surg.: surgery

15
16 **Figure 4 Comparisons of individual functional cortical maps.** (A) Overlap of individual
17 cortical areas being stimulated both at surgery 1 and surgery 2. (B) Results of comparisons
18 between surgery 1 and surgery 2 functional cortical maps, illustrated as a 1 minus p-value map
19 considering only selected functional responses and (C) all intraoperative functional responses.
20 Statistical analyses were computed with a family-wise error (FWE) threshold set at $P < 0.05$.
21 Significant cortical areas are indicated with a white arrow.

22
23



1
2
3

Figure 1
180x263 mm (x DPI)

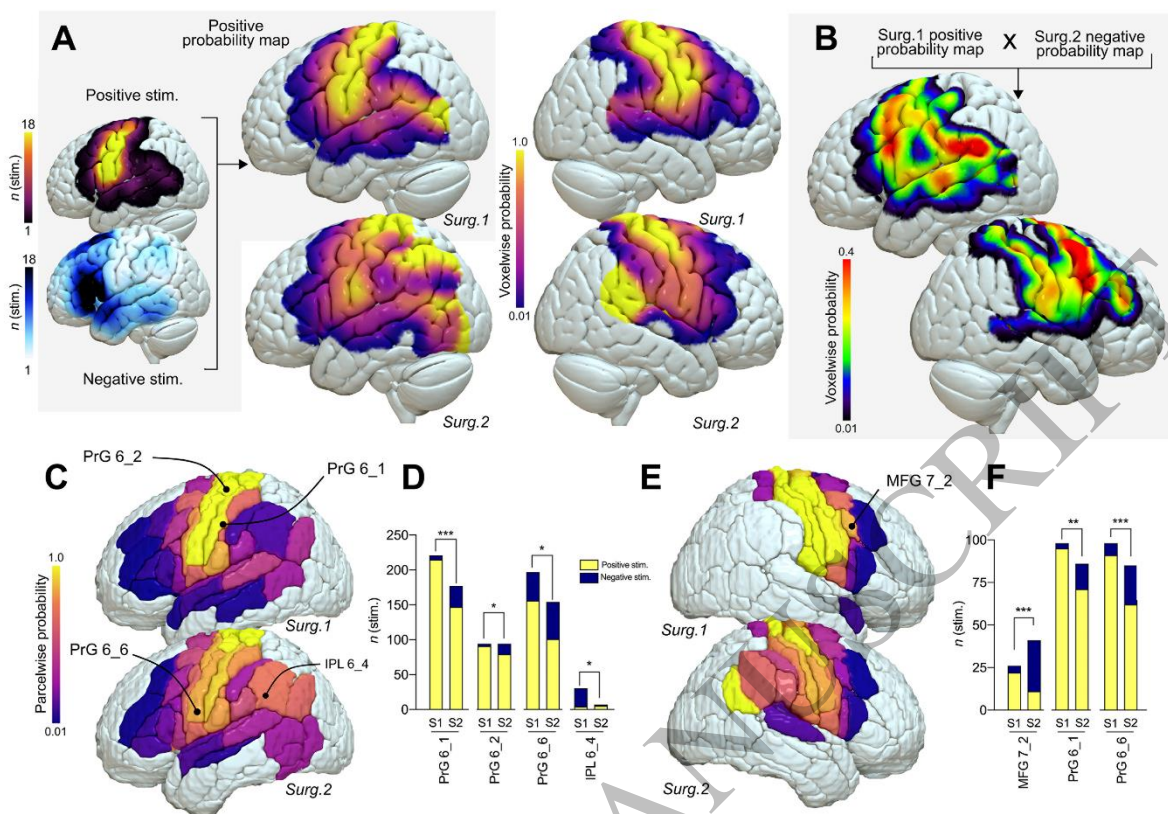


Figure 2
180x124 mm (x DPI)

1
2
3
4

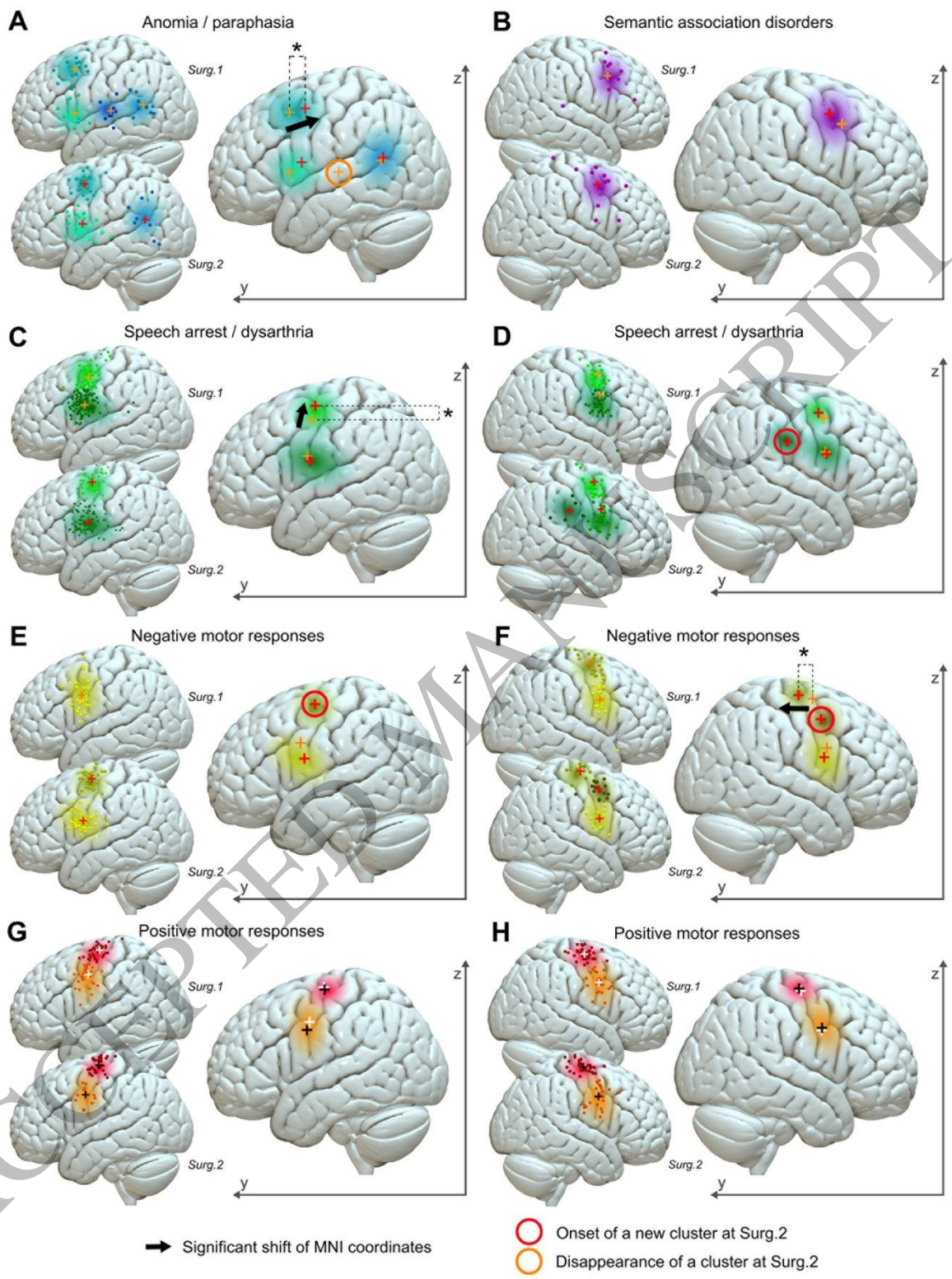


Figure 3
180x233 mm (x DPI)

1
2
3
4

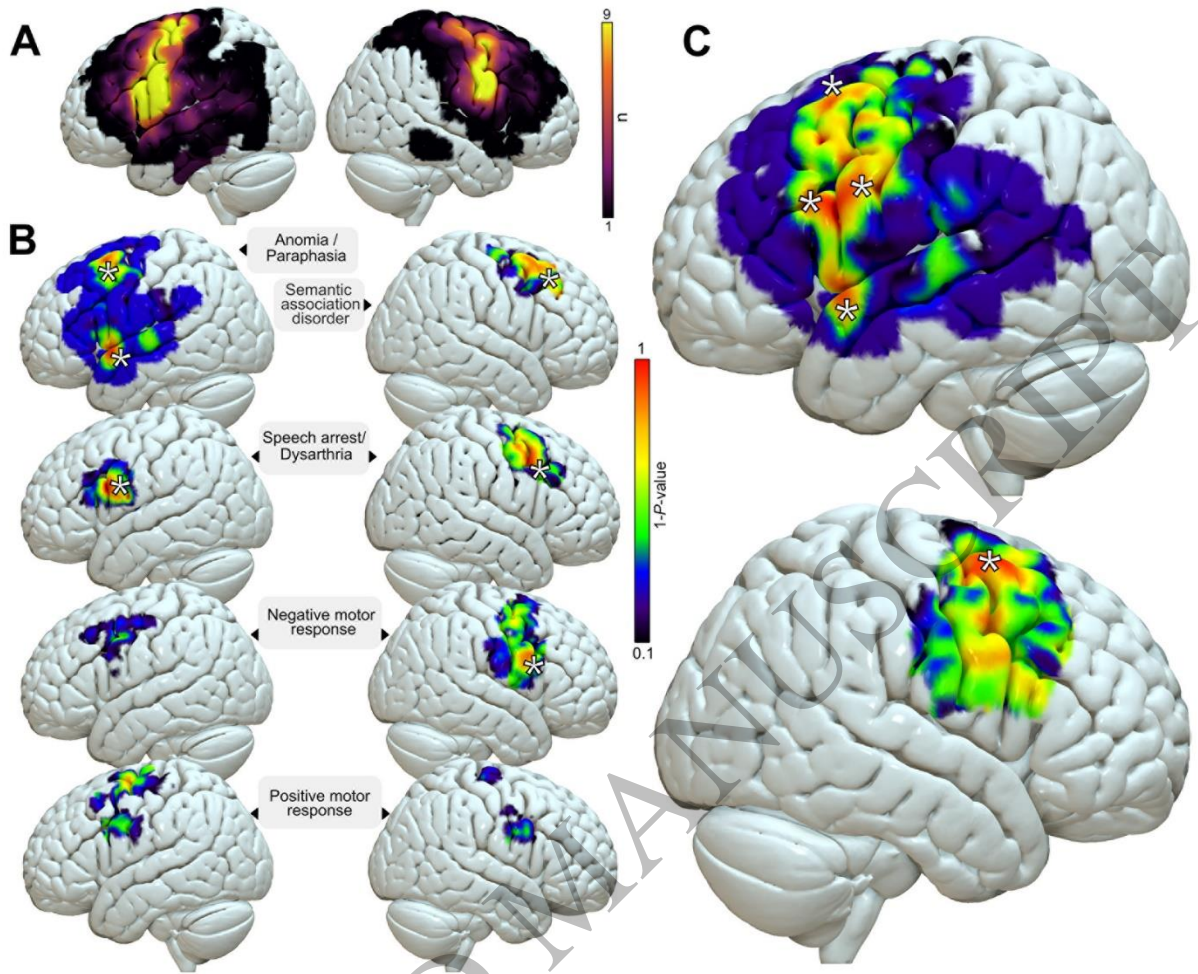


Figure 4
180x152 mm (x DPI)

1
2
3