



**HAL**  
open science

## Sagittal Balance Using Position and Orientation of Each Vertebra in an Asymptomatic Population

Olivier Gille, Wafa Skalli, Paul Mathio, Pascal Kouyoumdjian, Alice Boishardy, Laurent Gajny, Cecile Roscop

► **To cite this version:**

Olivier Gille, Wafa Skalli, Paul Mathio, Pascal Kouyoumdjian, Alice Boishardy, et al.. Sagittal Balance Using Position and Orientation of Each Vertebra in an Asymptomatic Population. *Spine*, 2022, 47 (16), pp.E551-E559. 10.1097/BRS.0000000000004366 . hal-04065908

**HAL Id: hal-04065908**

**<https://hal.science/hal-04065908v1>**

Submitted on 12 Apr 2023

**HAL** is a multi-disciplinary open access archive for the deposit and dissemination of scientific research documents, whether they are published or not. The documents may come from teaching and research institutions in France or abroad, or from public or private research centers.

L'archive ouverte pluridisciplinaire **HAL**, est destinée au dépôt et à la diffusion de documents scientifiques de niveau recherche, publiés ou non, émanant des établissements d'enseignement et de recherche français ou étrangers, des laboratoires publics ou privés.



Distributed under a Creative Commons Attribution 4.0 International License

# Sagittal Balance Using Position and Orientation of Each Vertebra in an Asymptomatic Population

Olivier Gille, MD, PhD,<sup>a</sup> Wafa Skalli, PhD,<sup>b</sup> Paul Mathio, MD,<sup>a</sup> Pascal Kouyoumdjian, MD, PhD,<sup>c</sup>  
Alice Boishardy, MD,<sup>a</sup> Laurent Gajny, PhD,<sup>c</sup> and Cecile Roscop, MD<sup>a</sup>

**Study Design.** A monocentric, retrospective radiographic study with 99 asymptomatic volunteers.

**Objective.** The authors performed the postural analysis commonly scheduled when evaluating sagittal balance in a vertebra-by-vertebra manner by enrolling an asymptomatic population. They measured the position and angulation of each vertebra to reveal those for which the spatial positioning could be relevant during spinal surgeries.

**Summary of Background Data.** Several recent publications detailed the sagittal alignment parameters and focus on global analysis parameters. Some patients with identical commonly evaluated spinal parameters have exhibited very different profiles, with notable differences in vertebral positions and orientations. Therefore, a fine segmental analysis of position of each vertebra could be interest to gain understanding of spine alignment.

**Materials and Methods.** The authors obtained full-spine EOS x-rays of 99 volunteers in the standard free-standing position. We used a validated three-dimensional reconstruction technique to extract current spinal parameters and the positions and angulations of all vertebrae and lumbar discs. Particular attention was paid to the positions and angulations of the apical and transitional vertebrae in the general population and in subgroups according to pelvic incidence (PI).

**Results.** T1 was the most common transitional cervicothoracic vertebra (in 89.9% of subjects) and was oriented downwards by an

average of 22.0° (SD = 7.3°, minimum = 2.3°, maximum = 40.1°). The thoracic apex trio of T5 (22.2%), T6 (28.3%), and T7 (36.4%) were equally found. The transitional thoracolumbar vertebrae were L1 (39.4%) and T12 (33.3%). The lumbar apex was usually the L3-L4 disc (36.4%). T1 seemed to be the transitional vertebra (90%) irrespective of the PI. For the other relevant vertebrae, the greater the PI, the more cranial the vertebra.

**Conclusions.** We performed a detailed three-dimensional assessment of overall spinal balance using positional and rotational parameters. The positions and orientations of all vertebrae were specified, particularly the apical and transitional vertebrae.

**Key words:** the key points are postural balance, spinal alignment, 2D/3D EOS, vertebral angulation, and pelvic incidence

**Level of Evidence.** 3

**Spine 2022;47:E551–E559**

Deterioration of sagittal alignment caused by spinal degeneration reduces the quality of life and worsens low back pain, often creating a requirement for surgery,<sup>1</sup> which can fail if fusion is performed at an inappropriate position, thus increasing and triggering postoperative mechanical complications.<sup>2,3</sup> Restoration of sagittal balance is essential to improve postoperative outcomes.<sup>4,5</sup>

However, restoration of a “normal” sagittal profile is difficult, as individual “normality” is poorly defined in the general population.<sup>6</sup> Assessment of coronal alignment is simpler; namely, the coronal plane is approximately a straight line along the axis of gravity. Assessment of sagittal alignment is more difficult, requiring analysis of curvatures<sup>7</sup> and spinopelvic parameters.<sup>8</sup> Recently, many global measurements from sagittal or biplanar x-rays have been published<sup>9–13</sup>; these radiologic parameters aid the planning of deformation-correcting surgery and the evaluation of surgical outcomes.

The cervicothoracic, thoracolumbar and lumbosacral transitional vertebrae have been well-studied. For example, the planning and restoration of lumbosacral lordosis at L4-S1 has become essential during lumbosacral arthrodesis.<sup>4,14</sup> Measurement of T10-L2 thoracolumbar kyphosis is used by some surgeons to determine the optimal superior vertebra for instrumentation during extended

From the <sup>a</sup>Spine Surgery Department, University Hospital, Bordeaux, France; <sup>b</sup>Biomechanical Laboratory, ENSAM-CNRS UMR 8005, Paris, France; and <sup>c</sup>Spine Surgery Department, University Hospital, Nîmes, France.

Acknowledgment date: May 27, 2021. First revision date: November 29, 2021. Acceptance date: February 26, 2022.

The English in this document has been checked by at least two professional editors, both native speakers of English. For a certificate, please see: <http://www.textcheck.com/certificate/XNRcm>

The authors report no conflicts of interest.

Address correspondence and reprint requests to Cecile Roscop, MD, Unité de Pathologie Rachidienne, CHU Bordeaux, Place Raba Amélie Léon, Bordeaux 33000, France; Email: [roscop.cecile@gmail.com](mailto:roscop.cecile@gmail.com)

Supplemental Digital Content is available for this article. Direct URL citations appear in the printed text and are provided in the HTML and PDF versions of this article on the journal's website, [www.spinejournal.com](http://www.spinejournal.com).

DOI: 10.1097/BRS.0000000000004366

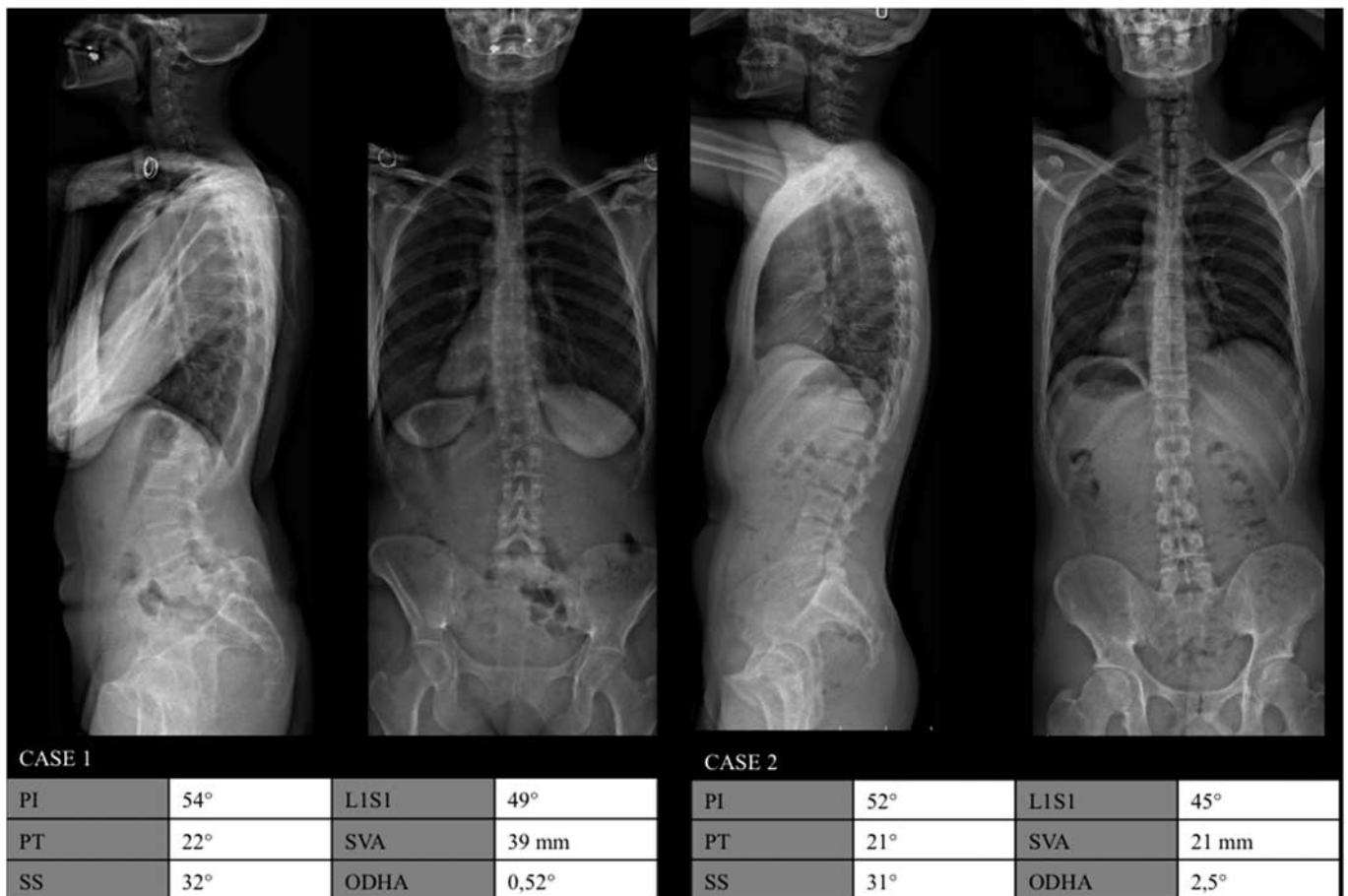
lumbar fusion.<sup>15</sup> Some authors have shown that the T1 slope is strongly correlated with cervical lordosis and must be considered during long thoracolumbar fixation.<sup>16</sup> Others have shown that the orientation of the upper instrumented vertebra in long fusions affects the risk of proximal junctional disease.<sup>17</sup> This is why several recent publications detail the sagittal alignment parameters: however, studies mainly focus on global analysis parameters, while position of each vertebra of the spine construct could be interest to gain understanding of spine alignment. Some patients with identical commonly evaluated spinal parameters have exhibited very different profiles, with notable differences in vertebral positions and orientations (Figure 1).<sup>18</sup> Therefore, a fine segmental analysis of the spine is still lacking.

The authors thus complemented common postural analysis (employing pelvic parameters, spinal curvatures, and global sagittal parameters) with a vertebra-by-vertebra sagittal alignment analysis in an asymptomatic population. They describe the positions and angulations of all vertebrae according to the pelvic incidence (PI) and identify those for which the spatial positions could be of interest during pre-operative planning, spinal surgery and the follow-up to understand and prevent proximal junctional disease.

## MATERIALS AND METHODS

### Population and Study Design

We retrospectively selected 119 asymptomatic subjects (62 males and 57 females). The exclusion criteria were previous spinal surgery, poor visibility of the external auditory canal and the upper part of the cervical spine, and any abnormality in the number of vertebrae (such as a transitional lumbosacral vertebra or a supernumerary lumbar vertebra) or spine disorders symptoms. Lack of symptoms was confirmed in two ways: an Oswestry score <20 (17) and a visual analogue pain and radiculalgia score <2/10. Low-dose EOS x-rays (with simultaneous acquisition of the sagittal and coronal planes) were obtained from head to toe<sup>19</sup> with all subjects in the standardized free standing position, adapted from Faro: fists on clavicles.<sup>20</sup> This position is more representative of a subject's functional balance while still allowing adequate lateral radiographic visualization of the spine. Three-dimensional (3D) reconstruction was performed for the spine (from C3 to L5) and pelvis using a validated software developed at Institut de Biomécanique Humaine Georges Charpak (ENSAM Paris).<sup>21</sup>



**Figure 1.** Full spinal EOS x-rays of two subjects with the same pelvic and global parameters. Case 1: a patient with L5-S1 spondylolisthesis and severe lumbosacral kyphosis. Case 2: a volunteer without vertebral abnormalities.

Downloaded from http://journals.lww.com/spinejournal by BHDMSepHKav1ZcumYtQAN4akLhEzZq5siHo4XM10h on 04/12/2023

### Radiographic Parameters

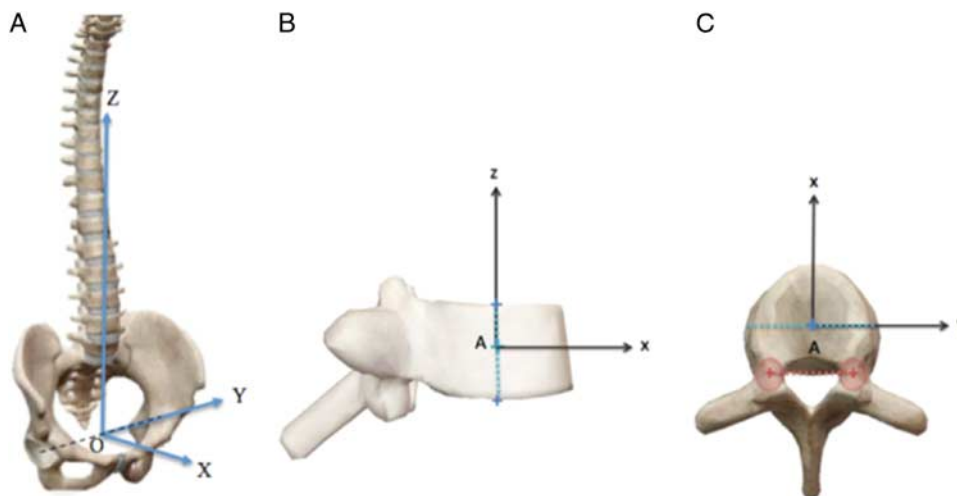
From the 3D reconstructions, various parameters were automatically computed: the PI, pelvic tilt (PT), sacral slope, spinal curvatures (C3-C7, T4-T12, and L1-S1) and global postural parameters including the sagittal vertical axis, spinosacral angle, T1 pelvic angle, global tilt, and odontoid-hip axis angle. Subjects were next divided into three groups according to PI (24): *low PI* (PI <45°), *mid PI* (PI 45–60°), and *high PI* (PI >60°).

### Position and Orientation

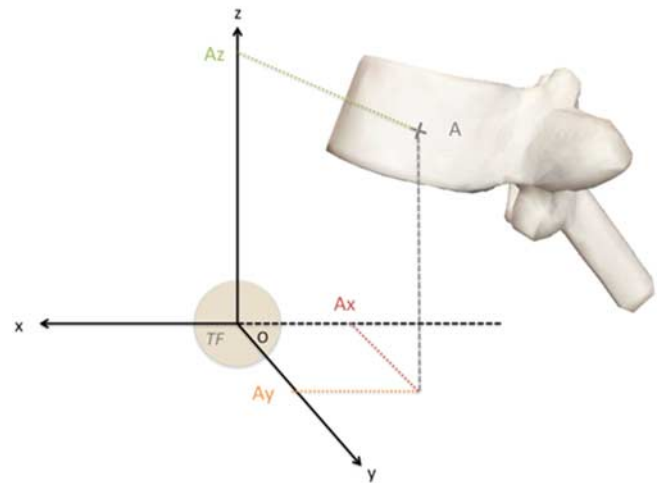
To obtain linear position and angulation of each vertebra, we defined an anato-gravity spinal frame, defined by the vertical axis passing by the middle of the two acetabula centers, and the horizontal axis perpendicular to the acetabula centers line, as detailed in Figure 2A. A local vertebral co-ordinate system (Figures 2B, C).

The *x*, *y*, and *z* co-ordinates of point A (the center of the vertebral body in the spinal frame) are *Ax*, *Ay*, and *Az*, respectively (Figure 3). When *Ax* is positive, the vertebral body center projects in front of the femoral heads, but backwards if *Ax* is negative. When *Ay* is positive, the vertebra is located on the left, and on the right if *Ay* is negative. *Az* is the height of the vertebra with regard to the femoral heads. *Az* is dependent on subject height and is always positive. To limit interindividual variability, we also normalised this parameter using a “min/max” method (C3 height being 100%).

The second set of parameters included orientation parameters (Figure 4). We obtained angular position as routinely computed from spine 3D reconstruction using rotation matrices and the lateral-sagittal-axial (L-S-A) angles.<sup>22</sup> VCT is the vertebral coronal tilt, VSA represents the vertebral sagittal angulation, and VAR is the vertebral axial rotation.



**Figure 2.** A, The anato-gravity frame. The frontal plane is the vertical plane that passes through the centers of both acetabula; the sagittal and transverse planes are orthogonal to each other and to the frontal plane. The origin of the frame is the center of the segment with the two acetabula. B and C, The vertebral co-ordinate system. B, Profile view; the center of the vertebral body (A) is in the middle of the line between the midpoints of the vertebral endplates. The vertebral *z* axis is on this line, being oriented upwards with A as the origin. C, Axial view; the *y* axis lies parallel to the line connecting the centroids of the two pedicles. The *x* axis is orthogonal to the *z* and *y* axes (figure adapted from “visible body”).



**Figure 3.** Linear and positional parameters (adapted from “visible body”).

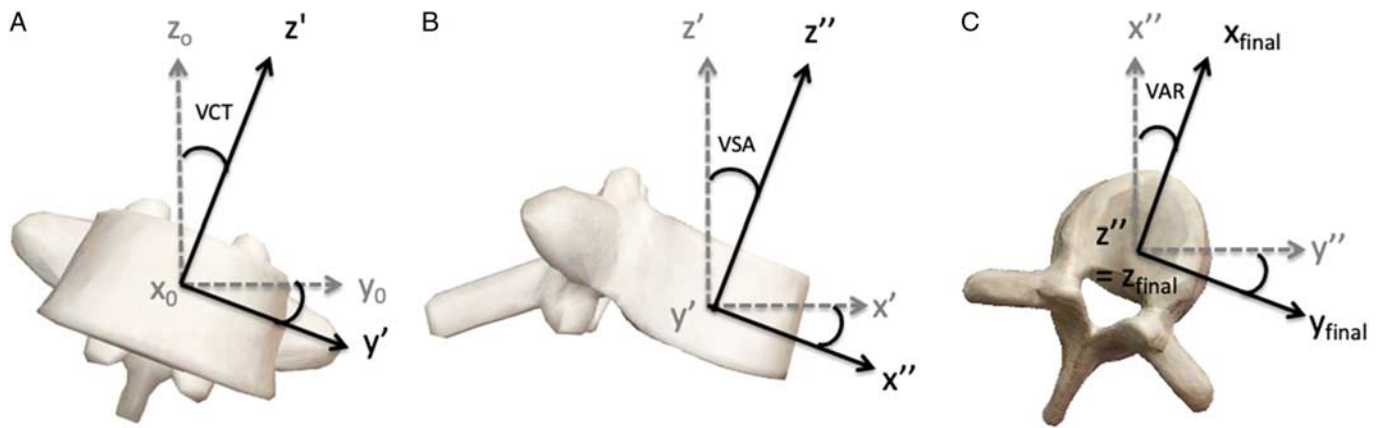
### Definitions of Apical and Transitional Vertebrae

The lumbar apex was the vertebra closest to the Z gravity axis, with minimal *Ax* value, and with a sagittal angulation that was closest to the horizontal, with minimal VSA value. Conversely, the thoracic apex was the vertebra furthest from the *z*-axis (largest *Ax*) with an angulation closest to the horizontal (minimal VSA). The cervicothoracic and thoracolumbar transitional vertebrae were, respectively, the most downward-oriented vertebra with the most negative VSA and the most upward-oriented vertebra with the most positive VSA. Because lumbar transitions can occur at disc levels, the orientation of each lumbar disc was also computed.

### Statistical Analysis

We compared the radiological data using the online software EasyMedStat ([www.easymedstat.com](http://www.easymedstat.com); Neuilly-Sur-Seine;

Downloaded from <http://journals.lww.com/spinejournal> by BIRD/MSF/HK/AVI/ZE/UM/TIQ/N/4+K/LHE/Zq5h04XM10H CymcX1AW/nYop/IIQH/D3I3D00D/RV/TT/SF14C13V/C4/OA/PD/8K/KGK/V0Ym/+78= on 04/12/2023



**Figure 4.** Angular vertebral rotation parameters: VCT, VSA, and VAR. A, Coronal view; rotation around the  $x$  axis. B, Sagittal view; rotation around the  $Y'$  axis. C, Axial view; rotation around the  $Z''$  axis (adapted from Skalli et al<sup>22</sup>). Adaptations are themselves works protected by copyright. So in order to publish this adaptation, authorization must be obtained both from the owner of the copyright in the original work and from the owner of copyright in the translation or adaptation. VAR indicates vertebral axial rotation; VCT, vertebral coronal tilt; VSA, vertebral sagittal angulation.

France). Normality was evaluated using the Shapiro-Wilk test, with an alpha risk threshold of  $<5\%$  ( $\alpha=0.05$ ). Correlations between parameters were derived using the Pearson test, with  $P < 0.05$  denoting significance.

**RESULTS**

**Subject Characteristics**

Ninety-nine of 119 subjects originally enrolled were included. Eleven exhibited evidence of a transitional lumbosacral anomaly or an additional lumbar vertebra. The data of nine subjects were not reconstructed because they did not respect the standard position. The 99 subjects included 47 females and 52 males with a mean age of 31 years (range, 18–47 y). All were asymptomatic; the mean questionnaire scores were 9.0% on the Oswestry scale (range, 0–16%, SD = 3.23) and 0.08 on the visual analogue scale (VAS) for pain (range, 0–2, SD = 0.24). Subject characteristics are summarized in Table 1.

For the entire population, the means (SD) of the pelvic parameters were 48.9° (9.9°) for PI, 9.4° (6.9°) for PT, and 39.5° (7.6°) for sacral slope. The mean (SD) spinal curvatures were 0.5° (11.1°) for C3–C7, 33.5° (8.9°) for T4–T12 and 57.5° (9.3°) for L1–S1. All parameters were normally distributed ( $P > 0.05$ ).

**Positional Parameters**

The average  $A_y$  (lateral position) value for each vertebra ranged from -0.4 to 6 mm in the frontal plane (overall range, -18.2 to 13.0 mm) (Table 2). The  $A_x$  values were negative from C3 to S1; all vertebral centers projected behind the femoral heads in the sagittal plane. The vertebral center closest to the  $z$ -axis was L4 (mean = 5.9 mm, SD = 14.7 mm). The most distant vertebra was T6 (mean = 80.8 mm, SD = 18.9 mm). The  $A_z$  values, which depended on subject height, were associated with large SDs (33.8 mm for C3) minimized after standardization.

**Angulation Parameters**

Angular parameters are shown in Figure 5 and listed in Table 3.

The vertebral axial rotation VAR value for each vertebra ranged from -1.2 to 1.6° (overall: mean = -0.8°, min = -9.6°, max = 12.4°). The vertebral coronal tilt VCT value for each vertebra ranged from -3.9° to 4.0° (overall: mean = -0.05°, min = -18.2°, max = 13.0°). For sagittal angulation VSA, L4 was the most horizontal lumbar

**TABLE 1. Demographic and Radiological Sagittal Parameters**

	Mean	Min	Max	SD
Age (yr)	31	18	47	7.3
Oswestry score (%)	9.0	0	16	3.23
VAS (n)	0.08	0	2	0.24
PI (°)	48.9	29.9	80.1	9.9
PT (°)	9.4	-11.0	26.5	6.9
SS (°)	39.5	24.6	59.7	7.6
T4-T12 TK (°)	33.5	8.4	5.6	8.9
L1-S1 LL (°)	57.5	29.9	85.2	9.3
SVA (°)	27.3	2.8	64.2	15.5
SSA (°)	133.4	117.7	155.1	8.0
T1PA (°)	2.8	-21.3	15.5	7.3
GT (°)	15.6	1.5	30.3	6.5
ODHA (°)	3.1	-7.7	3.2	2.1

GT indicates global tilt; ODHA, odontoid-hip axis angle; SS, sacral slope; SSA, spinosacral angle; SVA, sagittal vertical axis; TK, thoracic kyphosis; T1PA, T1 pelvic angle.

Downloaded from http://journals.lww.com/spinejournal by BHDMSepHKavI zEum tIQINa+hKLnEzq5H0dXM10n CwWCX1AWnYop/IIQH3D33D00dR7V7TSF14C3VCA/OA/PD88KKGK/V0YmY+78= on 04/12/2023

**TABLE 2. Values of Parameters Ax, Ay, and Az for Each Vertebra, and Normalized (norm.) Az Values**

Vertebra	Ax (mm)	Ay (mm)	Az (mm)	Az (norm.)
C3	-37.0 (23.3)	4.4 (10.7)	624.5 (33.8)	100% (0)
C4	-40.1 (22.7)	4.5 (10.5)	607.9 (32.6)	97% (0.2)
C5	-43.0 (22.3)	4.8 (10.4)	591.7 (31.5)	94% (0.3)
C6	-44.8 (22.0)	5.0 (10.2)	575.3 (30.4)	91% (0.5)
C7	-48.6 (21.8)	5.5 (10.1)	558.7 (29.5)	87% (0.6)
T1	-56.5 (21.3)	6.1 (9.9)	541.6 (28.6)	84% (0.8)
T2	-62.3 (20.9)	6.0 (9.8)	522.4 (27.5)	80% (0.9)
T3	-69.0 (20.5)	6.1 (9.7)	502.1 (26.4)	76% (0.9)
T4	-74.6 (20.0)	6.2 (9.6)	481.2 (25.1)	72% (0.9)
T5	-78.6 (19.5)	5.9 (9.5)	459.8 (23.8)	68% (0.9)
T6	-80.8 (18.9)	5.6 (9.4)	437.0 (22.4)	64% (0.9)
T7	-80.2 (18.5)	5.1 (9.4)	414.0 (20.8)	59% (0.9)
T8	-76.8 (18.3)	4.7 (9.3)	390.9 (19.4)	55% (0.9)
T9	-71.2 (18.3)	4.7 (9.1)	367.2 (17.9)	50% (0.9)
T10	-63.9 (18.6)	4.6 (8.7)	343.0 (16.7)	46% (0.9)
T11	-55.1 (18.9)	4.2 (8.3)	317.1 (15.2)	41% (0.9)
T12	-45.3 (19.3)	4.2 (8.0)	289.7 (13.9)	35% (0.9)
L1	-34.2 (19.4)	3.4 (8.0)	260.8 (12.7)	30% (0.9)
L2	-21.9 (18.8)	2.1 (7.4)	229.2 (11.8)	24% (0.8)
L3	-11.7 (17.0)	1.7 (6.1)	195.0 (11.0)	17% (0.7)
L4	-5.9 (14.7)	0.5 (4.7)	160.0 (10.3)	10% (0.6)
L5	-10.5 (12.9)	-0.4 (4.2)	125.5 (9.1)	4% (0.4)
S1	-17.4 (12.65)	-0.4 (4.1)	106.1 (8.1)	0% (0)

Data are presented as means or percentages with SDs in parentheses.

vertebra [VSA = -1.2° (6.7°)] and T12 the most upward-oriented vertebra [VSA = 19.5° (4.5°)]. T6 was the most horizontal thoracic vertebra [VSA = -2.4° (6.5°)], and T1 was the most downward-oriented vertebra [VSA = -22.9° (7.2°)].

### Relevant Vertebrae

The thoracic apex was formed by one of three vertebrae: T7 (36%), T6 (28%), and T5 (22%) (Supplemental File 1, <http://links.lww.com/BRS/B886>). The lumbar apex was shared between L4 (59%) and L3 (27%). To better identify the lumbar apex, we integrated the VSA values of the intervertebral discs; the frequencies then became 36% for L3-L4, 27% for L4 and 22% for L4-L5. The most common transitional cervicothoracic vertebra was T1 (89.9%), and

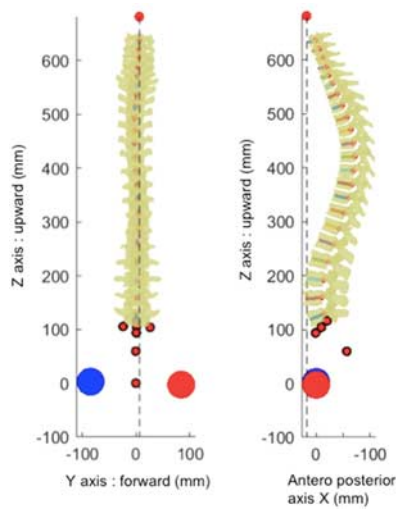
the most common transitional thoracolumbar vertebra was L1 (39.4%) followed by T12 (33.3%).

### Correlations

The VSA and LL values of relevant vertebrae were significantly and positively correlated for the entire population (Table 4). The L4 and L5 VSA values were significantly and positively correlated with the PI, (L5  $r=0.68$ ,  $P < 10^{-4}$ ; L4  $r=0.63$ ,  $P < 10^{-4}$ ). The T1 VSA was not significantly correlated with LL or the PI (LL  $r=0.06$ ,  $P > 0.05$ ; PI  $r=0.02$ ,  $P > 0.05$ ).

### Apical and Transitional Vertebrae According to PI

Thirty-seven subjects were in the *low PI* group, 52 were in the *mid PI* group, and 10 were in the *high PI* group. T1 was



**Figure 5.** Vertebral orientations. Vertebral sagittal angulation values are displayed in the sagittal view.

the transitional cervicothoracic vertebra in all three groups with a frequency approaching 90% (Supplemental Digital File 2, <http://links.lww.com/BRS/B887>). The thoracic apex was T7 in 41% of the subjects in the *low PI* group and 37% of the subjects in the *mid PI* group, and T6 in 80% of the subjects in the *high PI* group. The thoracolumbar transitional vertebra was L1 in 43% of the *low PI* and 37% of the *mid PI* subjects, and T12 in 60% of the *high PI* subjects. The lumbar apex was L4-L5 in 46% of the *low PI* subjects, and L3-L4 in 44% of the *mid PI* subjects and 50% of the *high PI* subjects.

**DISCUSSION**

This study performs a complete analysis of 3D values from a large cohort of asymptomatic subjects. The current parameters averages were similar to those in the literature.<sup>18,23–25</sup>

We assessed all vertebral positions and orientations to obtain a detailed understanding of postural alignment, visualizing the entire spine in 3D space (Figure 5). In our healthy population, the axial rotations (VAR) were low and nonpathological, being slightly oriented to the left without affecting overall alignment. Both the coronal tilt (VCT) and coronal position (Ay) were slightly oriented to the left [VSA (–4°, 4°), Ay (–0.4 mm, 6 mm)], consistent with the literature,<sup>26</sup> possibly reflecting the fact that the aorta runs left of the spine or physiological asymmetric evolution of the vertebral neurocentral cartilage. The normalised Az values confirmed known geometric relationships (34, 35): T9 is located at the absolute middle of the spine (50%), L1 in the first third, and T7 in the second. In the sagittal plane, the vertebral positions values (Ax and Az) and the sagittal angulation at each vertebral level followed those expected from classic spinal curvature.<sup>27</sup>

The particularity of this study is to identify apical and transitional vertebrae in the sagittal plane in a healthy

**TABLE 3.** Angular Vertebral Orientations in the Coronal, Sagittal, and Axial Planes

Vertebra	Coronal Tilt VCT	Sagittal Angulation VSA	Axial Rotation VAR
C3	–0.6° (3.6)	–1.7° (9.3)	1.2° (2.9)
C4	–0.6° (3.5)	–8.9° (9.4)	1.2° (2.9)
C5	–2.8° (3.9)	–15.2° (9.0)	1.6° (3.0)
C6	0.1° (3.6)	–15.1 (8.6)	1.4° (3.0)
C7	0.6° (3.4)	–17.2° (7.3)	1.6° (3.2)
T1	4.0° (3.5)	–22.9° (7.3)	–1.2° (3.4)
T2	1.1° (3.6)	–19.1° (7.1)	–0.5° (3.4)
T3	0.4° (3.6)	–16.0 (7.1)	–0.3° (3.3)
T4	0.2° (3.5)	–12.4° (7.1)	–0.3° (3.2)
T5	–0.4° (3.5)	–8.1° (7.2)	–0.5° (3.0)
T6	–2.3° (3.8)	–2.4° (6.5)	–0.6° (2.9)
T7	–3.0° (2.9)	4.0° (6.7)	–0.7° (3.0)
T8	–2.2° (2.9)	9.4° (6.3)	–0.8° (3.2)
T9	–0.2° (3.2)	13.4° (6.3)	–0.4° (3.3)
T10	–1.4° (3.5)	17.2° (5.9)	–0.7° (3.3)
T11	–1.0° (3.9)	17.9° (5.2)	–0.5° (3.2)
T12	–1.3° (4.0)	19.5° (4.5)	–0.9° (3.3)
L1	–0.9° (3.4)	19.8° (3.9)	–0.4° (3.2)
L2	–1.1° (2.9)	15.9° (4.2)	–0.3° (3.0)
L3	–1.5° (3.3)	9.4° (5.7)	–0.3° (2.8)
L4	–1.0° (3.9)	–1.2° (7.6)	–0.2° (2.8)
L5	–3.9° (4.2)	–19.1° (9.0)	0.3° (3.2)

*Data are presented as means with SDs in parentheses. VAR indicates vertebral axial rotation; VCT, vertebral coronal tilt; VSA, vertebral sagittal angulation.*

population based on PI, which is a shape parameter that rarely change after growth ceases<sup>8</sup>; the vertebrae involved were identified. When we considered the most frequent vertebral trio at each level, the frequency curves tended to move cranially when the PI increased, except in the cervicothoracic region, where T1 prevailed in all spines (Supplemental File 1, <http://links.lww.com/BRS/B886> and 2, <http://links.lww.com/BRS/B887>). The lumbar apex was most frequently the L3-L4 disc (37%). In the *low PI* group, the apex was lower (the L4-L5 disc) (46%). In the *mid PI* and *high PI* groups, the apex was most frequently the L3-L4 disc (44% and 50%, respectively), followed by L3 (40%) in the *high PI* group. The apex was therefore low, confirming

Downloaded from <http://journals.lww.com/spinejournal> by BRIDM5eP7HkavI zEumTtQIN4+hLhEz9jsiH04XM10H CwC0X1AWnYOpIIQH3i3D00D0R7I7TVSF14C13V3C4/OA/PD/DA8KKGK/V0Ym+78= on 04/12/2023

**TABLE 4. Pearson Correlation Coefficients Between Vertebral Sagittal Angulations and Pelvic Parameters in Asymptomatic Subjects**

	L5 VSA	L4 VSA	T12 VSA	T7 VSA	T1 VSA
Pelvic incidence	0.68,*	0.63,*	0.09	0.18	0.06
	$P < 10^{-4}$	$P < 10^{-4}$	NS	NS	NS
Pelvic	0.10	0.13	0.26	0.10	0.23
Tilt	NS	NS	$P = 0.01$	NS	$P = 0.019$
L1-S1 lumbar lordosis	0.69,*	0.58,*	0.66,*	0.25	0.02
	$P < 10^{-4}$	$P < 10^{-4}$	$P < 10^{-4}$	$P = 0.012$	NS

\*Very strongly significant.  
NS indicates not significant; VSA, vertebral sagittal angulation.

that most lordosis lies between the L4-L5 disc and S1 at low PI values (below 45°) and between L3-L4 disc and S1 at higher PI values (above 45°).<sup>14</sup>

In terms of the thoracolumbar inflexion point, L1 was the most frequent (39%) in the entire population. In the *low PI* and *mid PI* groups, the transitional vertebra was most frequently L1 (43% and 37%, respectively). In the *high PI* group, it was T12 (60%). For patients with high PI values, the L1-S1 Lumbar Lordosis underestimates the true extent of lordosis, which must be measured between the most down-tilted vertebra and S1, not just at L1. In addition, for subjects with high PI values (above 60°), long extended physiological restoration of LL and the attainment of a physiological apex at the L3-L4 disc is necessary.<sup>7,28</sup> The thoracic apex was shared among three vertebrae (T5, T6, and T7) in our general population, with T7 being the most frequent (>33%). In terms of the PI, the thoracic apex was most commonly located at T7 in the *low PI* and *mid PI* groups (41% and 37%, respectively). In the *high PI* group, the thoracic apex was higher (at T6; 80%). This is important during long instrumented fusion; in the choice and orientation of the last instrumented thoracic vertebra, one should probably consider the PI and the location of the physiological apex.<sup>17,29</sup>

Finally, the most common cervicothoracic vertebra was T1 (90%), irrespective of the PI, consistent with the literature. Many angular parameters develop at the expense of T1.<sup>30-33</sup> T1 is oriented (on average) at 22.0° downwards (SD=7.3°) but never over 40° (min=2.3°, max=40.1°), and is associated with economical cervical balance.<sup>31</sup> We did not define an apical cervical vertebra because cervical kyphosis is possible even in healthy subjects.<sup>34</sup> No single vertebra exhibited significant interindividual variability in terms of cervical curvature.

Strong correlations were evident between lumbar sagittal angulation values and pelvic parameters (Table 4), suggesting that the former values are influenced by the shape of the pelvis, consistent with the literature.<sup>7,8,18</sup> The linear correlations between pelvic shape and vertebral orientation were very strong in the pelvic and lumbar areas but weak or nonsignificant in the thoracic and cervical

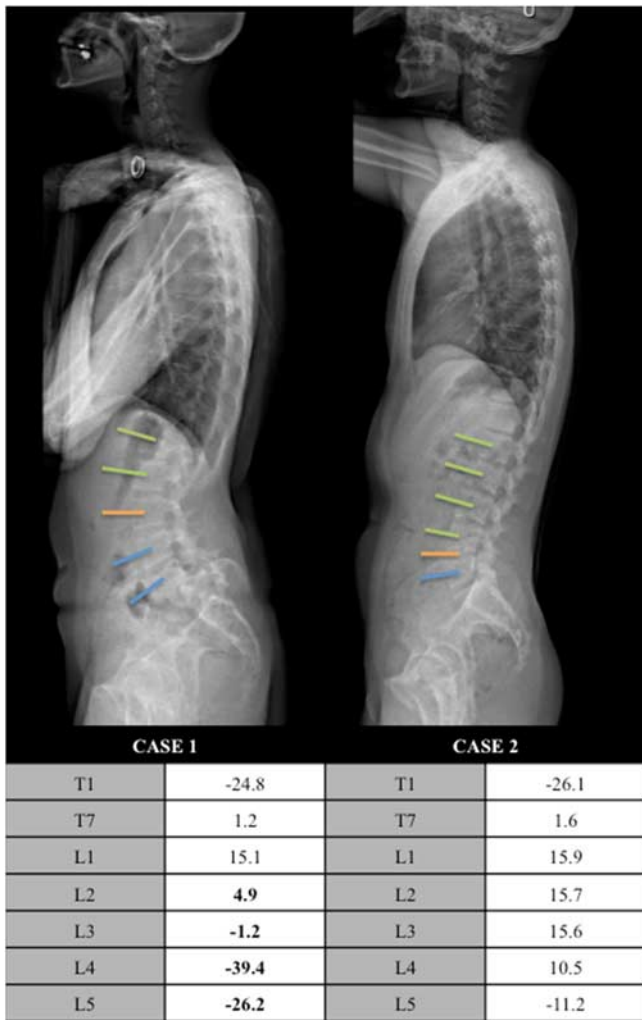
levels. However, each successive anatomical segment is closely related to and influences the adjacent segment.<sup>18</sup>

We applied the parameters to a representative example (Figure 1). Current parameters such as the PI values and LL were similar for the two profiles. However, the cases were not identical in sagittal EOS view; the common parameters did not reveal significant radiological differences (Figure 6). The L5-S1 spondylolisthesis in case 1 had triggered L5-S1 kyphosis, in which the L5 and L4 vertebrae were oriented forward and downward (VSA -26.2° and -39.41°, respectively) and the lumbar apex was high at L3. In case 2, L5 was oriented slightly downward (VSA -11.25°) and the upper adjacent vertebra was oriented upward; the lumbar apex was also lower (at the L4-L5 disc). The cervicothoracic vertebrae are similar in the two cases explaining similar common parameters. Our parameters improve the understanding of overall sagittal balance and appear to be complementary tools.

We suggest that such detailed analysis could be particularly useful when planning spinal surgery (Table 5). The global parameters described in the literature detect postural imbalance and can be used to evaluate surgical outcomes.<sup>15</sup> Normalization of global parameters was correlated with improvement in quality-of-life scores after deformation surgery.<sup>35</sup> However, these global parameters do not completely describe postural alignment. Several studies have sought to remedy lumbosacral lordosis during lumbar spine surgery to limit the risk of adjacent syndrome. Indeed, L4-S1 lordosis constitutes 66% of LL.<sup>14</sup> Theoretically, L4-S1 lordosis is calculated with consideration of the PI, using regression equations in the literature.<sup>23,36,37</sup> However, the goal of lumbosacral lordosis restoration is reconstitution of the physiological lumbar apex. For us, it is important to identify this apex with consideration of the PI, as we have described above.

The literature differs in terms of the last instrumented vertebra<sup>29</sup> that should be chosen to reduce the risk of proximal junction kyphosis. The disparities can be explained by several factors, including the vertebral





**Figure 6.** Vertebral sagittal angulation (VSA) values of key and the lumbar vertebrae. Blue, orange, and green represent negative lumbar, apical and positive VSA values, respectively.

orientation.<sup>17</sup> The physiological thoracolumbar transitional vertebra must be considered during long lumbar fusion or fusion bridging the thoracolumbar transition. The

physiological angular and linear position is well described by VSA and Ax. Indeed, a more superior instrumented vertebra could increase the proximal junction kyphosis risk if the position is nonphysiological: thus, with a more positive VSA (upwardly oriented) or a more negative Ax value (further from the vertical).

Finally, long thoracolumbar or thoracolumbopelvic fusions must also restore the T1 physiological position in space with respect to the pelvis. The T1 position is quantitatively described in the present study, as are those of all vertebrae. The T1 VSA represents the T1 slope and the T1 Ax the T1 cantilever with respect to the femoral heads.

The use of classic literature parameters does not allow the correct positioning of key vertebrae (apical and transitional) relative to the pelvis. Therefore, a combination of global parameters and our local parameters seems necessary during surgical planning.

**Limitations of the Study**

Our study had certain limitations. First, our population was relatively young; hence, the data may not be fully representative. However, all values correlated strongly with PI, which does not change after adolescence, suggesting that the findings apply to all normal individuals. Second, our study does not report body mass index values. It would be interesting to continue this analysis on a larger cohort and evaluate the influence of obesity on studied parameters. Third, our values do not consider compensations such as an augmented PT or knee flexion. During surgical planning, knee flexion and PT are routinely corrected via simulation. Finally, clinical studies are needed to determine the effects of the orientations and positions of relevant vertebrae on the outcomes of arthrodesis.

**CONCLUSION**

We performed a detailed 3D assessment of overall spinal balance using positional and rotational parameters. We specified the positions and orientations of all vertebrae and paid particular attention to the apical and transitional vertebrae.

**TABLE 5. Summary of Positions and Rotations of Relevant Vertebrae According to the PI**

	PI <45°	45° <PI <60°	PI > 60°
Cervicothoracic vertebra	T1	T1	T1
VSA (°)/Ax (mm)	-23.3 (8.4)/-69.8 (28.7)	-22.0 (6.5)/-66.6 (21.0)	25.9 (6.0)/-52.3 (28.5)
Thoracic apex	T7	T7	T6
VSA (°)/Ax (mm)	2.7 (7.1)/-93.0 (17.6)	4.5 (6,5) /-91.7 (17.7)	1.4 (4.4)/-86.1 (19.3)
Thoracolumbar vertebra	L1	L1	T12
VSA (°)/Ax (mm)	20.7 (4.1)/-53.6 (18.9)	19.2 (3.7)/-41.9 (11.5)	20.5 (5.1)/-45.6 (19.3)
Lumbar apex	L4-L5	L4	L3-L4
VSA (°)/Ax (mm)	4.0 (7.0)/-9.4 (11.0)	3.1 (5.0)/-11.1 (8.9)	2.9 (4.8)/-12.8 (17.9)

*PI indicates pelvic incidence; VSA, vertebral sagittal angulation.*

Downloaded from http://journals.lww.com/spinejournal by BHDMSepHKavI zEum tIQN4+hkLhEzqjsho4XM10H CwC0X1AWnYopI/QHhD3i3D00dRy/TV/SF14C13VCA/OAVpDda8KKGK/V0Ym+78= on 04/12/2023

The English in this document has been checked by at least two professional editors, both native speakers of English. For a certificate, please see: <http://www.textcheck.com/certificate/XNRCrn>.

## ➤ Key Points

- Postural balance.
- Spinal alignment.
- 2D/3D EOS.
- Vertebral angulation.
- Pelvic incidence

## References

1. Glassman SD, Bridwell K, Dimar JR, et al. The impact of positive sagittal balance in adult spinal deformity. *Spine*. 2005;30:2024–9.
2. Lazenec JY, Ramaré S, Arafati N, et al. Sagittal alignment in lumbosacral fusion: relations between radiological parameters and pain. *Eur Spine J*. 2000;9:47–55.
3. Tribus CB, Belanger TA, Zdeblick TA. The effect of operative position and short-segment fusion on maintenance of sagittal alignment of the lumbar spine. *Spine*. 1999;24:58–61.
4. Bourghli A, Aunoble S, Reebye O, et al. Correlation of clinical outcome and spinopelvic sagittal alignment after surgical treatment of low-grade isthmic spondylolisthesis. *Eur Spine J*. 2011;20:663–8.
5. Kawakami M, Tamaki T, Ando M, et al. Lumbar sagittal balance influences the clinical outcome after decompression and posterolateral spinal fusion for degenerative lumbar spondylolisthesis. *Spine*. 2002;27:59–64.
6. Glassman SD, Berven S, Bridwell K, et al. Correlation of radiographic parameters and clinical symptoms in adult scoliosis. *Spine*. 2005;30:682–8.
7. Roussouly P, Gollopy S, Berthonnaud E, et al. Classification of the normal variation in the sagittal alignment of the human lumbar spine and pelvis in the standing position. *Spine*. 2005;30:346–53.
8. Legaye J, Duval-Beaupère G, Hecquet J, et al. Pelvic incidence: a fundamental pelvic parameter for three-dimensional regulation of spinal sagittal curves. *Eur Spine J*. 1998;7:99–103.
9. Jackson RP, Hales C. Congruent spinopelvic alignment on standing lateral radiographs of adult volunteers. *Spine*. 2000;25:2808–15.
10. Boissière L, Takemoto M, Bourghli A, et al. Global tilt and lumbar lordosis index: two parameters correlating with health-related quality of life scores—but how do they truly impact disability? *Spine J*. 2017;17:480–8.
11. Qiao J, Zhu F, Xu L, et al. T1 pelvic angle: a new predictor for postoperative sagittal balance and clinical outcomes in adult scoliosis. *Spine*. 2014;39:2103–7.
12. Roussouly P, Gollopy S, Nosedo O, et al. The vertical projection of the sum of the ground reactive forces of a standing patient is not the same as the C7 plumb line: a radiographic study of the sagittal alignment of 153 asymptomatic volunteers. *Spine*. 2006;31:E320–5.
13. Amabile C, Pillet H, Lafage V, et al. A new quasi-invariant parameter characterizing the postural alignment of young asymptomatic adults. *Eur Spine J*. 2016;25:3666–74.
14. Roussouly P, Pinheiro-Franco JL. Biomechanical analysis of the spino-pelvic organization and adaptation in pathology. *Eur Spine J*. 2011;20(suppl 5):609–18.
15. Schwab F, Ungar B, Blondel B, et al. Scoliosis Research Society-Schwab adult spinal deformity classification: a validation study. *Spine*. 2012;37:1077–82.
16. Boissière L, Bernard J, Vital J-M, et al. Cervical spine balance: postoperative radiologic changes in adult scoliosis surgery. *Eur Spine J*. 2015;24:1356–61.
17. Lafage R, Line BG, Gupta S, et al. Orientation of the upper-most instrumented segment influences proximal junctional disease following adult spinal deformity surgery. *Spine*. 2017;42:1570–7.
18. Berthonnaud E, Dimnet J, Roussouly P, et al. Analysis of the sagittal balance of the spine and pelvis using shape and orientation parameters. *J Spinal Disord Tech*. 2005;18:40–7.
19. Dubousset J, Charpak G, Skalli W, et al. EOS stereo-radiography system: whole-body simultaneous anteroposterior and lateral radiographs with very low radiation dose. *Rev Chir Orthop Reparatrice Appar Mot*. 2007;93:141–3.
20. Faro FD, Marks MC, Pawelek J, et al. Evaluation of a functional position for lateral radiograph acquisition in adolescent idiopathic scoliosis. *Spine*. 2004;29:2284–9.
21. Gajny L, Ebrahimi S, Vergari C, et al. Quasi-automatic 3D reconstruction of the full spine from low-dose biplanar x-rays based on statistical inferences and image analysis. *Eur Spine J*. 2019;28:658–4.
22. Skalli W, Lavaste F, Descrimes JL. Quantification of three-dimensional vertebral rotations in scoliosis: what are the true values? *Spine*. 1995;20:546–3.
23. Le Huec JC, Hasegawa K. Normative values for the spine shape parameters using 3D standing analysis from a database of 268 asymptomatic Caucasian and Japanese subjects. *Eur Spine J*. 2016;25:3630–7.
24. Iyer S, Lenke LG, Nemani VM, et al. Variations in sagittal alignment parameters based on age: a prospective study of asymptomatic volunteers using full-body radiographs. *Spine*. 2016;41:1826–36.
25. Mac-Thiong J-M, Roussouly P, Berthonnaud E, et al. Sagittal parameters of global spinal balance: normative values from a prospective cohort of seven hundred nine Caucasian asymptomatic adults. *Spine*. 2010;35:E1193–8.
26. Gangnet N, Dumas R, Pomeroy V, et al. Three-dimensional spinal and pelvic alignment in an asymptomatic population. *Spine*. 2006;31:E507–12.
27. Roussouly P, Pinheiro-Franco JL. Sagittal parameters of the spine: biomechanical approach. *Eur Spine J*. 2011;20(suppl 5):578–85.
28. Roscop C, Mathio P, Gajny L, et al. Analysis of apex and transitional vertebra of the spine according to pelvic incidence using orientation and position parameters. *Eur Spine J*. 2021;30:2514–9.
29. Tono O, Hasegawa K, Okamoto M, et al. Lumbar lordosis does not correlate with pelvic incidence in the cases with the lordosis apex located at L3 or above. *Eur Spine J*. 2019;28:1948–54.
30. Sebaaly A, Riouallon G, Obeid I, et al. Proximal junctional kyphosis in adult scoliosis: comparison of four radiological predictor models. *Eur Spine J*. 2018;27:613–21.
31. Lee S-H, Son E-S, Seo E-M, et al. Factors determining cervical spine sagittal balance in asymptomatic adults: correlation with spinopelvic balance and thoracic inlet alignment. *Spine J*. 2015;15:705–12.
32. Ling FP, Chevillotte T, Leglise A, et al. Which parameters are relevant in sagittal balance analysis of the cervical spine? A literature review. *Eur Spine J*. 2018;27:8–15.
33. Protosaltis T, Schwab F, Bronsard N, et al. The T1 pelvic angle, a novel radiographic measure of global sagittal deformity, accounts for both spinal inclination and pelvic tilt and correlates with health-related quality of life. *J Bone Joint Surg Am*. 2014;96:1631–40.
34. Schwab F, Lafage V, Boyce R, et al. Gravity line analysis in adult volunteers: age-related correlation with spinal parameters, pelvic parameters, and foot position. *Spine*. 2006;31:E959–67.
35. Kim SW, Kim T-H, Bok DH, et al. Analysis of cervical spine alignment in currently asymptomatic individuals: prevalence of kyphotic posture and its relationship with other spinopelvic parameters. *Spine J*. 2018;18:797–810.
36. Schwab F, Lafage V, Patel A, et al. Sagittal plane considerations and the pelvis in the adult patient. *Spine*. 2009;34:1828–33.
37. Legaye J, Duval-Beaupère G. Sagittal plane alignment of the spine and gravity: a radiological and clinical evaluation. *Acta Orthop Belg*. 2005;71:213–0.