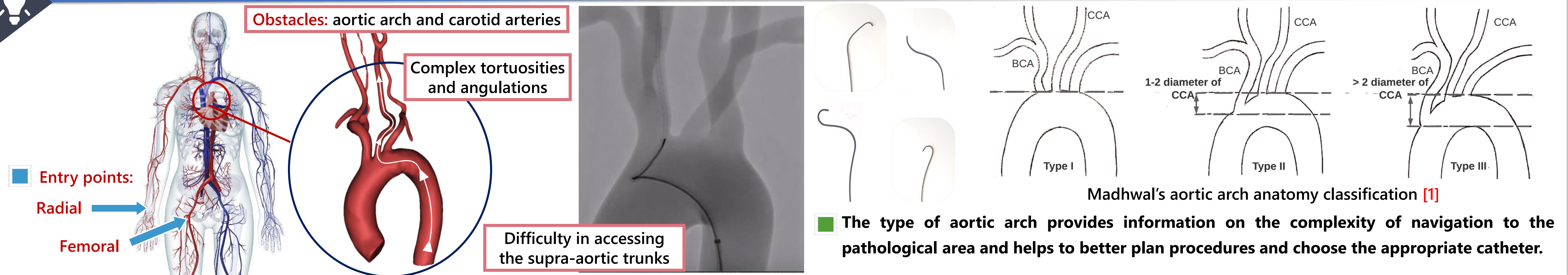


1. Clinical Background



Obstacles: aortic arch and carotid arteries

Complex tortuosities and angulations

Entry points: Radial, Femoral

Difficulty in accessing the supra-aortic trunks

Madhwal's aortic arch anatomy classification [1]

- Type I: 1-2 diameter of CCA
- Type II: 1-2 diameter of CCA
- Type III: > 2 diameter of CCA

The type of aortic arch provides information on the complexity of navigation to the pathological area and helps to better plan procedures and choose the appropriate catheter.

2. Technical Background

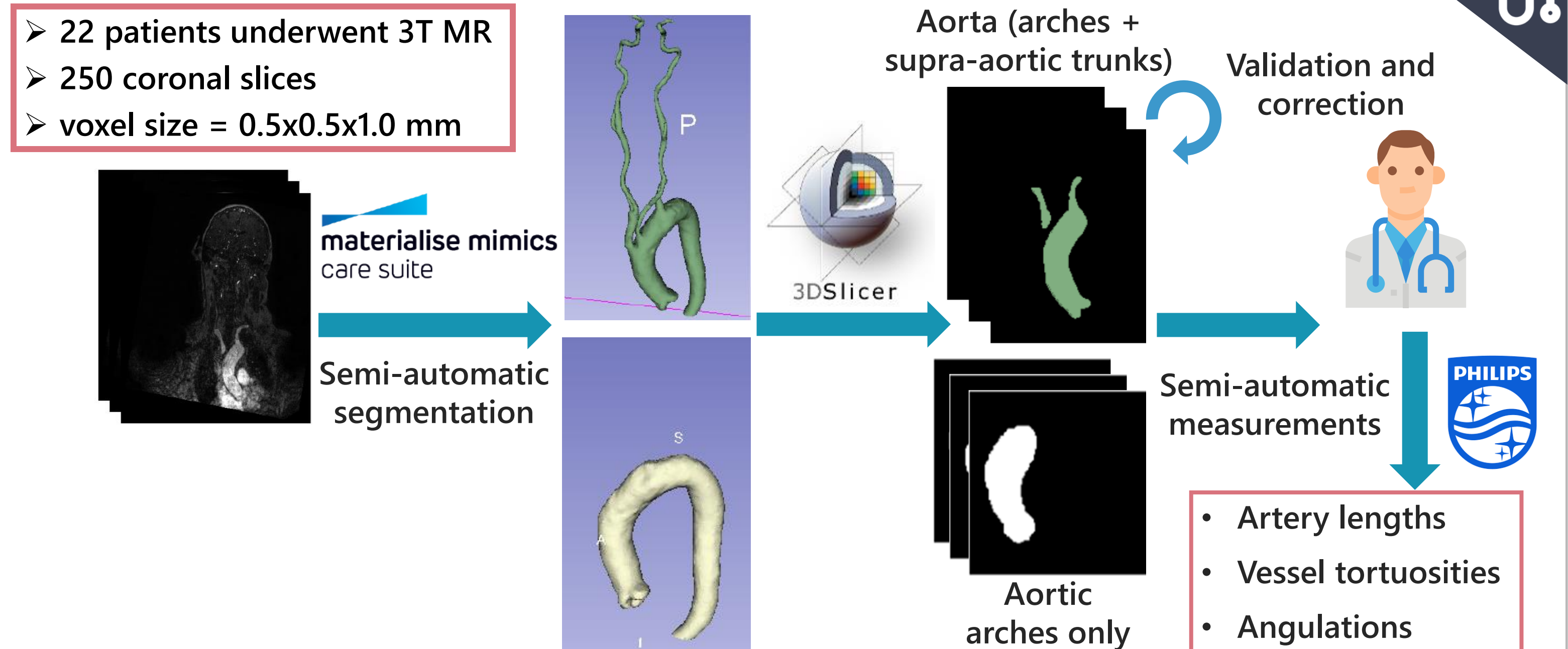
Deep learning pipelines

- Segmentation and extraction of morphological features, such as aortic arch type, supra-aortic trunks diameters, take-off angles, and tortuosity, in stroke cases [2].
- Detection of angles below 90° in the internal carotid artery using a deep learning model in patients undergoing endovascular thrombectomy [3].

General frameworks / Libraries

- Generic frameworks with sets of functions for geometric quantification of anatomical features and vessel characterization [4, 5]. These frameworks are suitable for engineers for research but not relevant for clinicians to use in a medical setting.

3. Data



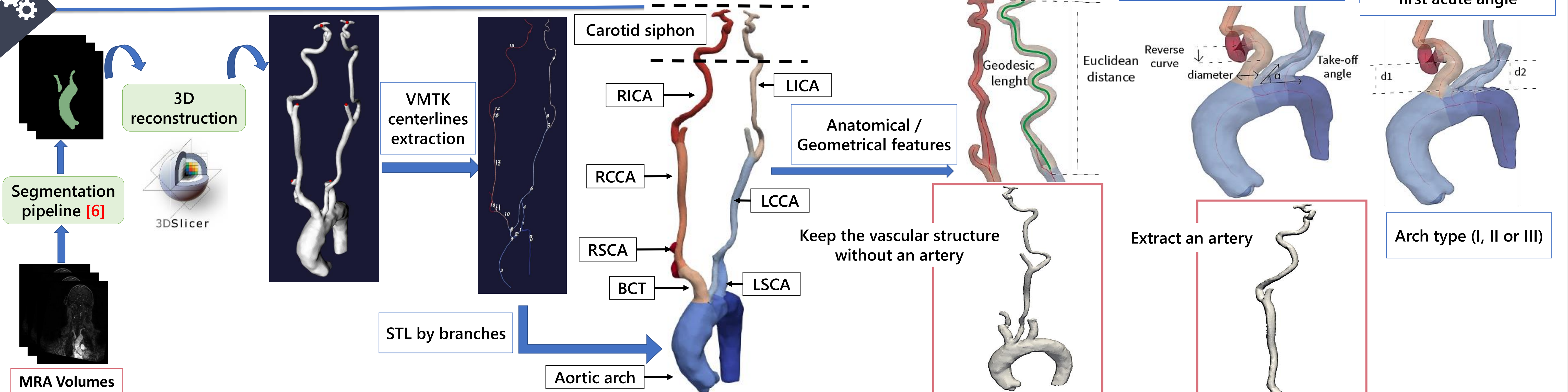
- 22 patients underwent 3T MR
- 250 coronal slices
- voxel size = 0.5x0.5x1.0 mm

materialise mimics care suite → Semi-automatic segmentation → 3DSlicer → Aorta (arches + supra-aortic trunks) → Validation and correction → Philips → Semi-automatic measurements

Aortic arches only

- Artery lengths
- Vessel tortuosities
- Angulations

4. Segmentation and Characterization Pipeline



MRA Volumes → Segmentation pipeline [6] → 3D reconstruction → VMTK centerlines extraction → Anatomical / Geometrical features

Carotid siphon

RICA, LICA, RCCA, LCCA, RSCA, LSCA, BCT

STL by branches → Aortic arch

Lengths and tortuosities: Geodesic length, Euclidean distance

Radii, take-off angles and reverse curves: Reverse curve diameter, Take-off angle

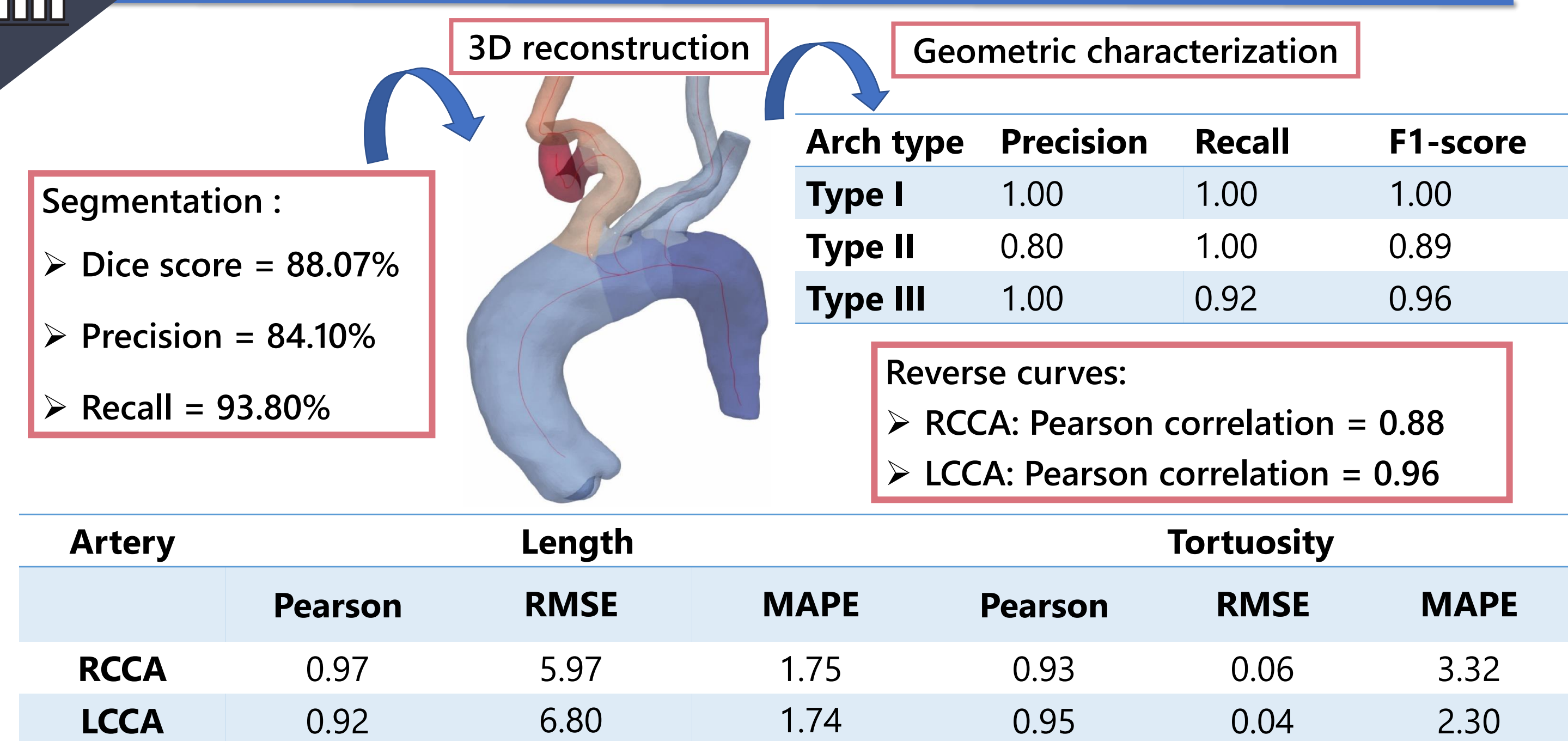
Vertical distance to the first acute angle: d1, d2

Arch type (I, II or III)

Keep the vascular structure without an artery

Extract an artery

5. Results



3D reconstruction

Geometric characterization

Segmentation:

- Dice score = 88.07%
- Precision = 84.10%
- Recall = 93.80%

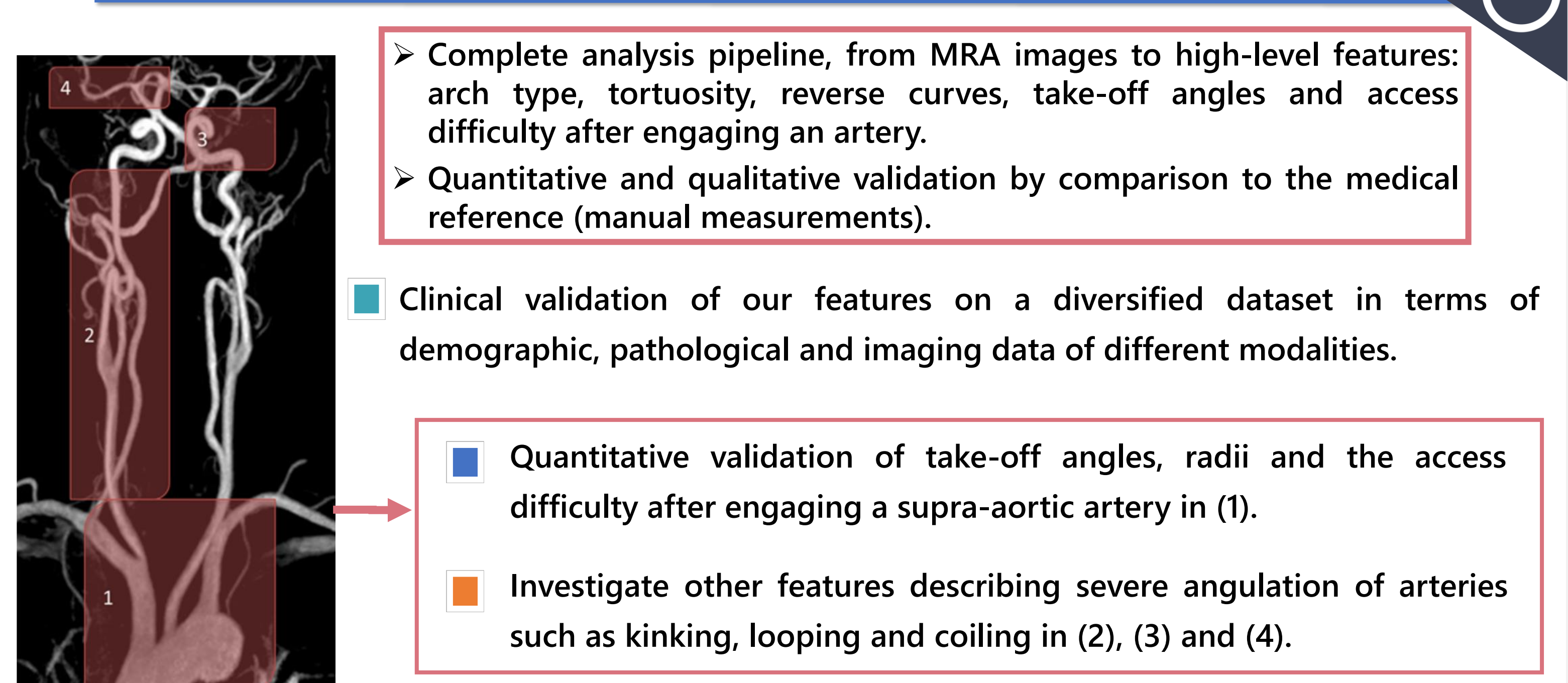
Arch type	Precision	Recall	F1-score
	Type I	1.00	1.00
Type II	0.80	1.00	0.89
Type III	1.00	0.92	0.96

Reverse curves:

- RCCA: Pearson correlation = 0.88
- LCCA: Pearson correlation = 0.96

Artery	Length			Tortuosity		
	Pearson	RMSE	MAPE	Pearson	RMSE	MAPE
RCCA	0.97	5.97	1.75	0.93	0.06	3.32
LCCA	0.92	6.80	1.74	0.95	0.04	2.30

6. Conclusion and Perspectives



- Complete analysis pipeline, from MRA images to high-level features: arch type, tortuosity, reverse curves, take-off angles and access difficulty after engaging an artery.
- Quantitative and qualitative validation by comparison to the medical reference (manual measurements).

Clinical validation of our features on a diversified dataset in terms of demographic, pathological and imaging data of different modalities.

- Quantitative validation of take-off angles, radii and the access difficulty after engaging a supra-aortic artery in (1).
- Investigate other features describing severe angulation of arteries such as kinking, looping and coiling in (2), (3) and (4).

[1] S. Madhwal, V. Rajagopal, D. L. Bhatt, C. T. Bajzer, P. Whitlow, and S. R. Kapadia, "Predictors of difficult carotid stenting as determined by aortic arch angiography," *J Invasive Cardiol*, vol. 20, pp. 200-204, 2008.

[2] P. Canals et al., "A fully automatic method for vascular tortuosity feature extraction in the supra-aortic region: unraveling possibilities in stroke treatment planning," *Comput. Med. Imaging Graph.*, p. 102170, 2022.

[3] G. Nageler et al., "Deep Learning-based Assessment of Internal Carotid Artery Anatomy to Predict Difficult Intracranial Access in Endovascular Recanalization of Acute Ischemic Stroke," *Clin. Neuroradiol.*, pp. 1-10, 2023.

[4] M. Piccinelli, A. Veneziani, D. A. Steinman, A. Remuzzi, and L. Antiga, "A framework for geometric analysis of vascular structures: Application to cerebral aneurysms," *IEEE Trans Med Imaging*, vol.28, pp. 1141-1155, 2009.

[5] H. A. Kjeldsberg, A. W. Bergersen, and K. Valen-Sendstad, "morphMan: Automated manipulation of vascular geometries," *J Open Source Soft.*, vol. 4, pp. 1065, 2019.

[6] M. Lahlouh, Y. Chenoune, R. Blanc, J. Szewczyk, and N. Passat, "Aortic arch anatomy characterization from MRA: A CNN-based segmentation approach," in *IEEE ISBI. IEEE*, 2022, pp. 1-5.