



**HAL**  
open science

## De novo posttransplant membranous nephropathy following BNT162b2 mRNA COVID-19 vaccine in a kidney transplant recipient

Nathalie Chavarot, Michael Padden, Lucile Amrouche, Stéphanie Malard, Anne Scemla, Rebecca Sberro-Soussan, Juliette Léon, Christophe Legendre, Jean Paul Duong, Julien Zuber, et al.

### ► To cite this version:

Nathalie Chavarot, Michael Padden, Lucile Amrouche, Stéphanie Malard, Anne Scemla, et al.. De novo posttransplant membranous nephropathy following BNT162b2 mRNA COVID-19 vaccine in a kidney transplant recipient. *American Journal of Transplantation*, 2022, 22 (12), pp.3188-3189. 10.1111/ajt.17166 . hal-04052551

**HAL Id: hal-04052551**

**<https://hal.science/hal-04052551>**

Submitted on 31 Mar 2023

**HAL** is a multi-disciplinary open access archive for the deposit and dissemination of scientific research documents, whether they are published or not. The documents may come from teaching and research institutions in France or abroad, or from public or private research centers.

L'archive ouverte pluridisciplinaire **HAL**, est destinée au dépôt et à la diffusion de documents scientifiques de niveau recherche, publiés ou non, émanant des établissements d'enseignement et de recherche français ou étrangers, des laboratoires publics ou privés.



Distributed under a Creative Commons Attribution 4.0 International License



Since January 2020 Elsevier has created a COVID-19 resource centre with free information in English and Mandarin on the novel coronavirus COVID-19. The COVID-19 resource centre is hosted on Elsevier Connect, the company's public news and information website.

Elsevier hereby grants permission to make all its COVID-19-related research that is available on the COVID-19 resource centre - including this research content - immediately available in PubMed Central and other publicly funded repositories, such as the WHO COVID database with rights for unrestricted research re-use and analyses in any form or by any means with acknowledgement of the original source. These permissions are granted for free by Elsevier for as long as the COVID-19 resource centre remains active.

## LETTER TO THE EDITOR

## De novo posttransplant membranous nephropathy following BNT162b2 mRNA COVID-19 vaccine in a kidney transplant recipient

### To the Editor:

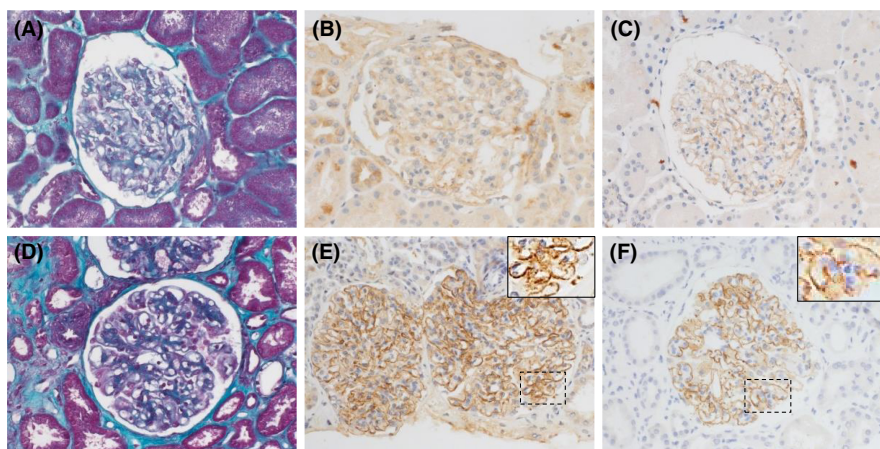
Mass COVID-19 vaccination programs in kidney transplant patients (KTRs) have demonstrated an excellent safety profile, without increased rates of ensuing alloimmune events. However, autoimmune diseases may seldom occur after vaccination. We report the case of a KTR who presented de novo posttransplant membranous nephropathy (MN) following administration of COVID-19 vaccine.

A 66-year-old patient underwent first kidney transplantation for autosomal-dominant polycystic-kidney-disease-related end-stage kidney disease in June 2020. His medical history included hypertension and left nephrectomy in 2016. After basiliximab induction, the maintenance regimen consisted of tacrolimus, mycophenolic acid, and steroids. His baseline creatinine level was 100  $\mu\text{mol/L}$ , and he remained free of proteinuria during the posttransplant course. A 3-month protocol graft biopsy was unremarkable. Immunohistochemistry (IHC) C4d staining was negative (Figure 1A,B).

The patient received the second injection of the BNT162b2 mRNA COVID-19 vaccine (Pfizer-BioNTech) in March 2021.

Subsequent serology tests showed negative results, consistent with a blunted antibody response to the vaccine, as widely reported in KTRs.

Eight weeks after the second vaccine dose, the patient underwent a 1-year protocol graft biopsy. Concurrent creatinine level and proteinuria were 120  $\mu\text{mol/L}$  and negative, respectively. Light microscopy showed normal glomeruli and ruled out subclinical rejection (Figure 1D). However, C4d staining revealed the presence of granular staining along the glomerular basement membrane consistent with stage 1 MN (Figure 1E). Anti-phospholipase-A2-receptor (PLA2R) immunochemistry analysis showed strong positive staining on the glomerular capillary walls (Figure 1F). Circulating PLA2R antibodies were negative. Notably, IHC staining for PLA2R and C4d was retrospectively negative in the 3-month protocol graft biopsy (Figure 1E) and in the native kidney specimen (nephrectomy). The residual renal parenchyma on the native kidney contained non-sclerotic glomeruli. We retrospectively performed Jones staining which did not show irregularities of the glomerular basement membrane suggestive of membranous nephropathy. There was no available frozen sample



**FIGURE 1** Protocol allograft kidney biopsies on month 3 and month 12. (A–C) Month 3 allograft kidney biopsy showing normal glomeruli on Masson Trichrome staining (A,  $\times 200$ ), negative C4d on peritubular capillaries and glomerular basement membrane (B,  $\times 200$ ) by immunohistochemistry, and negative PLA2R on glomerular basement membrane by immunohistochemistry (C,  $\times 200$ ). (D–F) Month 12 allograft kidney biopsy showing normal glomeruli on Masson Trichrome staining (D,  $\times 200$ ) but C4d immunohistochemistry revealed positive granular deposits along the glomerular basement membrane consistent with membranous nephropathy. Anti-PLA2R immunohistochemistry showed a positive staining of the extramembranous deposits. [Color figure can be viewed at [wileyonlinelibrary.com](http://wileyonlinelibrary.com)]

on the renal parenchyma. Hence, the diagnosis of de novo post-transplant MN was firmly established. Screening for malignancy and infections remained negative, excluding secondary causes of MN. COVID-19 tests remained also negative (SARS-CoV-2 PCR was negative at MN diagnosis and 3 months after the diagnosis. Anti-Spike IgG were negative 1 and 2 months after the diagnosis).

This is the first case of de novo posttransplant MN following mRNA COVID-19 vaccine. Interestingly, cases of de novo or relapsing MN after COVID-19 vaccine have recently been reported.<sup>1-3</sup> Additionally, rare cases of MN (including one PLA2R+ case) have been described after COVID-19 infection.<sup>4</sup>

The temporality between COVID-19 vaccination and PLA2R+ MN in a patient without history of MN and in whom the etiological workup has remained otherwise negative, supports a causal link. However, we must acknowledge that a coincidental association could not be ruled out.

Given the lack of proteinuria, no specific treatment was introduced. The subclinical presentation of MN may be related to the mitigating effects of maintenance immunosuppressive therapy.

In conclusion, auto-immune reactivity and MN may occur after mRNA COVID-19 vaccine. This report will raise awareness of nephrologists for the need to closely monitor patients with primary MN, following COVID-19 vaccination, including KTRs. If proteinuria occurs after vaccination, a graft biopsy should be promptly performed to firmly establish the diagnosis.

#### ACKNOWLEDGMENTS

We would like to thank Ms. Roberta Velve for the English language review.

#### DISCLOSURE

The authors of this manuscript have no conflicts of interest to disclose as described by the *American Journal of Transplantation*.

Nathalie Chavarot<sup>1,2,3</sup>   
 Michael Padden<sup>1,2,3</sup>  
 Lucile Amrouche<sup>1,2,3</sup>   
 Stéphanie Malard<sup>4</sup>  
 Anne Scemla<sup>1,2,3</sup>  
 Rebecca Sberro-Soussan<sup>1,2,3</sup>  
 Juliette Léon<sup>1,2,3</sup>   
 Christophe Legendre<sup>1,2,3</sup>  
 Jean Paul Duong<sup>3,5</sup>   
 Julien Zuber<sup>1,2,3</sup>   
 Dany Anglicheau<sup>1,2,3</sup> 

Marion Rabant<sup>3,5</sup> 

Pierre Isnard<sup>3,5</sup>

<sup>1</sup>Department of Kidney and Metabolic diseases, Transplantation, and Clinical Immunology, Necker-Enfants Malades Hospital, Assistance Publique-Hôpitaux de Paris, Paris, France

<sup>2</sup>Department of Immunology, Harvard Medical School, Boston, Massachusetts, USA

<sup>3</sup>Université de Paris, Paris, France

<sup>4</sup>Laboratoire Régional d'Histocompatibilité, Saint-Louis Hospital, Assistance Publique-Hôpitaux de Paris, Paris, France

<sup>5</sup>Department of Pathology, Necker-Enfants Malades Hospital, Assistance Publique-Hôpitaux de Paris, Paris, France

#### Correspondence

Nathalie Chavarot, Service de Néphrologie et Transplantation Rénale Adulte, Hôpital Necker-Enfants Malades, 149, Rue de Sèvres, 75015 Paris, France.

Email: [nathalie.chavarot@aphp.fr](mailto:nathalie.chavarot@aphp.fr)

#### ORCID

Nathalie Chavarot  <https://orcid.org/0000-0001-6361-1392>

Lucile Amrouche  <https://orcid.org/0000-0003-1314-0312>

Juliette Léon  <https://orcid.org/0000-0001-5314-8154>

Jean Paul Duong  <https://orcid.org/0000-0002-3051-2141>

Julien Zuber  <https://orcid.org/0000-0001-6741-9330>

Dany Anglicheau  <https://orcid.org/0000-0001-5793-6174>

Marion Rabant  <https://orcid.org/0000-0001-5696-6478>

#### REFERENCES

1. Aydin MF, Yildiz A, Oruc A, et al. Relapse of primary membranous nephropathy after inactivated SARS-CoV-2 virus vaccination. *Kidney Int.* 2021;100:464-465. doi:10.1016/j.kint.2021.05.001
2. Da Y, Goh GH, Khatri P. A case of membranous nephropathy following Pfizer-BioNTech mRNA vaccination against COVID-19. *Kidney Int.* 2021;100(4):938-939. doi:10.1016/j.kint.2021.07.016
3. Gueguen L, Loheac C, Saidani N, Khatchatourian L. Membranous nephropathy following anti-COVID-19 mRNA vaccination. *Kidney Int.* 2021;S0085-2538(21):00757-00752. doi:10.1016/j.kint.2021.08.006
4. Nasr SH, Alexander MP, Cornell LD, et al. Kidney biopsy findings in patients with COVID-19, kidney injury, and proteinuria. *Am J Kidney Dis.* 2021;77(3):465-468. doi:10.1053/j.ajkd.2020.11.002

#### SUPPORTING INFORMATION

Additional supporting information can be found online in the Supporting Information section at the end of this article.