



HAL
open science

Feasibility of Imaging-Guided Adrenalectomy in Young Patients With Primary Aldosteronism

Gian Paolo Rossi, Filippo Crimì, Giacomo Rossitto, Laurence Amar, Michel Azizi, Anna Riestler, Martin Reincke, Christoph Degenhart, Jiri Widimsky, Mitsuhide Naruse, et al.

► **To cite this version:**

Gian Paolo Rossi, Filippo Crimì, Giacomo Rossitto, Laurence Amar, Michel Azizi, et al.. Feasibility of Imaging-Guided Adrenalectomy in Young Patients With Primary Aldosteronism. *Hypertension*, 2022, 79 (1), pp.187-195. 10.1161/HYPERTENSIONAHA.121.18284. hal-04052100

HAL Id: hal-04052100

<https://hal.science/hal-04052100v1>

Submitted on 11 Apr 2023

HAL is a multi-disciplinary open access archive for the deposit and dissemination of scientific research documents, whether they are published or not. The documents may come from teaching and research institutions in France or abroad, or from public or private research centers.

L'archive ouverte pluridisciplinaire **HAL**, est destinée au dépôt et à la diffusion de documents scientifiques de niveau recherche, publiés ou non, émanant des établissements d'enseignement et de recherche français ou étrangers, des laboratoires publics ou privés.



Distributed under a Creative Commons Attribution 4.0 International License

ORIGINAL ARTICLE

Feasibility of Imaging-Guided Adrenalectomy in Young Patients With Primary Aldosteronism

Gian Paolo Rossi¹, Filippo Crimi¹, Giacomo Rossitto¹, Laurence Amar, Michel Azizi, Anna Riester, Martin Reincke, Christoph Degenhart, Jiri Widimsky², Mitsuhide Naruse³, Jaap Deinum, Leo Schultze Kool, Tomaz Kocjan, Aurelio Negro, Ermanno Rossi⁴, Gregory Kline⁵, Akiyo Tanabe, Fumitoshi Satoh, Lars Christian Rump, Oliver Vonend, Holger S. Willenberg⁶, Peter J. Fuller, Jun Yang, Nicholas Yong Nian Chee, Steven B. Magill, Zulfiya Shafigullina⁷, Marcus Quinkler, Anna Oliveras⁸, Vin Cent Wu, Zuzana Kratka⁹, Giulio Barbiero, Michele Battistel, Teresa Maria Seccia¹⁰

ABSTRACT: Many of the patients with primary aldosteronism (PA) are denied curative adrenalectomy because of limited availability or failure of adrenal vein sampling. It has been suggested that adrenal vein sampling can be omitted in young patients with a unilateral adrenal nodule, who show a florid biochemical PA phenotype. As this suggestion was based on a very low quality of evidence, we tested the applicability and accuracy of imaging, performed by computed tomography and/or magnetic resonance, for identification of unilateral PA, as determined by biochemical and/or clinical cure after unilateral adrenalectomy. Among 1625 patients with PA submitted to adrenal vein sampling in a multicenter multiethnic international study, 473 were ≤ 45 years of age; 231 of them had exhaustive imaging and follow-up data. Fifty-three percentage had a unilateral adrenal nodule, 43% had no nodules, and 4% bilateral nodules. Fifty-six percentage ($n=131$) received adrenalectomy and 128 were unambiguously diagnosed as unilateral PA. A unilateral adrenal nodule on imaging and hypokalemia were the strongest predictors of unilateral PA at regression analysis. Accordingly, imaging allowed correct identification of the responsible adrenal in 95% of the adrenalectomized patients with a unilateral nodule. The rate raised to 100% in the patients with hypokalemia, who comprised 29% of the total, but fell to 88% in those without hypokalemia. Therefore, a unilateral nodule and hypokalemia could be used to identify unilateral PA in patients ≤ 45 years of age if adrenal vein sampling is not easily available. However, adrenal vein sampling remains indispensable in 71% of the young patients, who showed no nodules/bilateral nodules at imaging and/or no hypokalemia.

REGISTRATION: URL: <https://www.clinicaltrials.gov>; Unique identifier: NCT01234220. (*Hypertension*. 2022;79:187–195. DOI: 10.1161/HYPERTENSIONAHA.121.18284.) • **Supplemental Material**

Key Words: aldosterone ■ diagnosis ■ hypertension ■ hypokalemia ■ phenotype

Adrenal vein sampling (AVS) is the key test recommended by experts and guidelines^{1–4} for the subtyping of patients with primary aldosteronism (PA) but is not available in many centers and countries, because it is technically challenging and difficult to interpret. Alternative strategies for identifying unilateral PA, such as functional imaging with C¹¹-metomidate and imaging-based clinical scores, have proven to be either unfeasible on a large scale, or hampered by inconsistent results,^{5–10} even in patients aged ≤ 40 years,¹¹ which is a matter of

concern because many patients with PA, who could be cured with surgery, are denied this opportunity.

Based on the premise that nonfunctioning adrenal nodules are uncommon in young patients,^{12,13} it has been suggested that patients with PA with a unilateral hypodense adrenal nodule and a contralateral normal appearing adrenal gland on computed tomography (CT), who are <40 ,¹⁴ or 35 years of age,¹⁵ could be referred for surgery without undergoing AVS. Accordingly, the Endocrine Society guidelines suggested that AVS can

Correspondence to: Gian Paolo Rossi, Internal & Emergency Unit - Specialized Hypertension Center, Department of Medicine-DIMED, University Hospital via Giustiniani, 2 35126 Padova, Italy. Email gianpaolo.rossi@unipd.it

The Supplemental Material is available with this article at <https://www.ahajournals.org/doi/suppl/10.1161/HYPERTENSIONAHA.121.18284>.

For Sources of Funding and Disclosures, see page 194.

© 2021 American Heart Association, Inc.

Hypertension is available at www.ahajournals.org/journal/hyp

Novelty and Significance

What Is New?

- Imaging correctly identified the responsible adrenal in 95% of adrenalectomized ≤ 45 -year-old patients in an international observational study that involved patients submitted to adrenal vein sampling.
- This rate rose to 100% in patients with hypokalemia, but fell to 88% in patients without hypokalemia.

What Is Relevant?

- Imaging could be used to guide surgery in patients with primary aldosteronism ≤ 45 years old who show hypokalemia.

Summary

- Patients ≤ 45 years old with hypokalemia and a unilateral adrenal nodule at imaging could be referred directly to surgery in centers where adrenal vein sampling is not available.
- Adrenal vein sampling remains, however, indispensable in those showing no nodules or bilateral nodules at imaging and in those without hypokalemia.

Nonstandard Abbreviations and Acronyms

AVIS-2	Adrenal Vein Sampling International Study
AVS	adrenal vein sampling
CT	computed tomography
PA	primary aldosteronism
PAC	plasma aldosterone concentration
ROC	receiver operating characteristic

be omitted in patients younger than 35 years, with a unilateral hypodense adrenal nodule between 10 and 20 mm of size on CT, only if the patient has a florid PA phenotype defined by hypokalemia and a markedly elevated plasma aldosterone concentration (PAC), that is, ≥ 30 ng/dL.¹ However, this suggestion was based on a very low quality of evidence (2 \oplus 000) by the GRADE score system¹⁶ and remains somewhat contentious, because it was, thereafter, supported by results of 2 retrospective studies by Umakoshi et al¹⁷ and Williams et al¹⁸ but challenged by a more recent retrospective Swedish study.¹⁹ Moreover, it remained to be supported by large real-life studies involving multiple centers and multiethnic cohorts of PA patients.¹⁵ Furthermore, the proportion of PA where this strategy can be exploited and whether it could apply also to young patients with PA without such a florid biochemical phenotype remained altogether uncertain.

The AVIS-2 (Adrenal Vein Sampling International Study) recruited patients with PA over a wide range of age, who underwent AVS in major referral centers in 4 continents, because of their wish to achieve surgical cure. Of note, around one-third of them were younger than 45 years, and the majority received an unambiguous diagnosis regarding the presence or absence of unilateral PA based on biochemical cure after unilateral adrenalectomy.²⁰ It was, therefore, possible to assess

the performance of imaging in the diagnostic work-up of young patients with PA, following the Standards for the Reporting of Diagnostic accuracy studies recommendations.²¹ In this AVIS-2-Young Study, we, therefore, investigated the hypothesis that detection of a unilateral hypodense adrenal nodule with a contralateral normal appearing adrenal gland at imaging can permit an accurate identification of unilateral surgically curable PA in young patients.

METHODS

The data that support the findings of this study are available from the corresponding author upon reasonable request.

The AVIS-2 study was conceived as an observational multicenter study to depict current practice in the work-up of patients with PA undergoing AVS worldwide.²⁰ The study was approved by the Institutional Ethics Committees and followed the principles of the Helsinki Declaration.

The study protocol has been registered <https://www.clinicaltrials.gov/> (registration number NCT01234220).

Participating centers were selected based on participation in the AVIS-1 study,²² as described.²⁰

Inclusion criteria were (1) age ≥ 18 years; (2) center's agreement to participate in the data collection; and (3) approval of the Ethics Committee.

Details of the study methodology, outcome, assessment of selectivity, rate of drug-resistant hypertension, and the overall diagnostic accuracy of imaging in the entire cohort have been previously reported in detail.^{20,23}

Imaging

Imaging was performed by CT and/or MRI. CT was performed with contrast medium to rule out an aldosterone-producing carcinoma and to ascertain the pattern of adrenal vein drainage as per guidelines recommendations.¹ Standard CT protocols included unenhanced, arterial, venous, and delayed phases, all at 1.5-mm slice thickness. The arterial phase was performed 10 seconds after the achievement of 100 Hounsfield Unit (HU) in the aortic lumen, the venous phase was acquired 60

seconds after contrast injection and delayed phase 15 minutes after contrast injection. Multiplanar reconstructions in sagittal and coronal planes were performed for all image sets.

MRI protocols included in-phase/out-of-phase, diffusion-weighted imaging and contrast-enhanced sequences. All the sequences had at least a slice thickness of 3 mm. Arterial acquisition was performed 35 seconds after contrast injection, venous phase 60 seconds after contrast administration, and delayed phase 15 minutes after the contrast injection.

The CT and MR results were assessed at each participating center to capture real-life practice. They were entered in the database as presence or absence, and size, of detected nodules.

Based on the result of a pilot study, which showed that, when examined independently by different experienced radiologists, nodules <5 mm maximum diameter could not be consistently detected with current imaging technologies (Supplemental Material), adrenal nodules were defined as lesions with a largest diameter ≥ 5 mm on imaging for the purpose of this analysis.

Definitions and Assignment to Treatment

Per protocol, allocation of the patients to surgery or medical treatment was left to the decision of the investigators at participating centers.²⁰ However, a rigorous definition of unilateral PA, as the gold-standard diagnostic reference for assessing the diagnostic accuracy of imaging, was adopted. Unilateral PA was diagnosed if the patients showed full biochemical cure and/or complete cure of the high blood pressure at follow-up undertaken at least 4 months after unilateral laparoscopic adrenalectomy.

Biochemical cure was defined as normalization of PAC, aldosterone-renin ratio, and serum K⁺ level post-adrenalectomy,²⁴ following the PASO criteria.²⁵

Cure of arterial hypertension was defined as seated office blood pressure values <140 mmHg systolic and <90 mmHg diastolic without any antihypertensive treatment.²⁵ The patients who were not cured biochemically after unilateral adrenalectomy and exclusion of wrong adrenalectomy were considered not to have unilateral PA.

Inappropriate adrenalectomy was defined as adrenalectomy undertaken based on imaging regardless of AVS results when patients did not show biochemical cure. The removal of the adrenal gland contralateral to that overproducing aldosterone at AVS in patients, who showed no biochemical cure post-adrenalectomy, and thus likely had contralateral unilateral PA, was defined as wrong adrenalectomy.

Study Cohort

The flow chart of AVIS-2-Young study is shown in Figure 1. Age was calculated as difference between the date of imaging and the birthdate in 1580 of the 1625 patients recruited in the AVIS-2 study: 30% (n=473) were ≤ 45 years of age; 16%, and 6% were ≤ 40 , and 35 years of age, respectively. Considering the issue of applicability of the imaging-based strategy, the fact that the prevalence of nonfunctioning adrenal nodule increases after age 45 years, and that the largest proportion of the young patients with PA recruited in the AVIS-2 registry were ≤ 45 years of age, we focused our analysis on this age cohort, in which 231 patients had both imaging and follow-up data.

Data Collection and Harmonization

On-line data collection was performed with an ad hoc web-based platform created, as described²⁰ using appropriate filters to prevent input of values that were not biologically plausible and/or were in the wrong unit of measure. Data were stored securely in a server protected by firewalls at the coordinating center. The PI had full access to the dataset; each local PI had access to his/her center's database to allow for revision and corrections.

Data Handling and Statistical Analysis

After locking the database, the data were checked for internal consistency; emerging queries were clarified with each center's lead investigator. Data harmonization to a standard format was carried out before undertaking statistical analysis, as described.²⁰ Univariate and multivariate outlier values were identified following the procedure of Tabachnick and Fidell²⁶; those that could not be resolved by the center's lead investigator were excluded from the analysis.

A linear stepwise regression analysis, using 0.05 and 0.10 as inclusion and exclusion criterion, respectively, was used to identify the predictors of unilateral surgically cured PA. The variables included in the initial model were the presence of a unilateral adrenocortical nodule with a contralateral normal appearing gland at imaging, age, sex, systolic blood pressure, diastolic blood pressure PAC, plasma renin activity, and serum K⁺ levels measured at AVS. The backward (Wald) technique was used to minimize the chances of overlooking relevant variables.²⁷

Results are expressed as mean \pm SD, or median and interquartile range, as appropriate. Continuous variables were tested for normal distribution with the Kolmogorov-Smirnov test; in the case of a skewed distribution, log-transformed data were used. Comparisons were performed with parametric or nonparametric tests (Wilcoxon), as appropriate. Pearson χ^2 test was used for analysis of categorical variables. Significance was set at $P < 0.05$.

Receiver operating characteristic (ROC) curves were drawn using the de Long technique; Youden index was used to identify the value corresponding to the best trade-off between sensitivity and specificity.

SPSS for Mac (version 27 for Mac, IBM-SPSS Bologna, Italy), Prism (version 9.0 for Mac, GraphPad Software, La Jolla, CA), and MedCalc (MedCalc Software Ostend Belgium, version 15.8) were used for the statistical analysis.

RESULTS

The clinical features of the 231 patients in the AVIS-2 registry, who were ≤ 45 years of age and had both imaging and follow-up data are shown in Table 1. Of them, 57% were adrenalectomized based on AVS results and/or clinical indication: 128, who were surgically cured, were classified as unilateral PA; 3 patients could not be unambiguously classified as unilateral PA, because they showed partial biochemical and/or hypertension cure. The remaining 100 patients were not operated, because they were judged to have a bilateral aldosterone secretion at AVS.

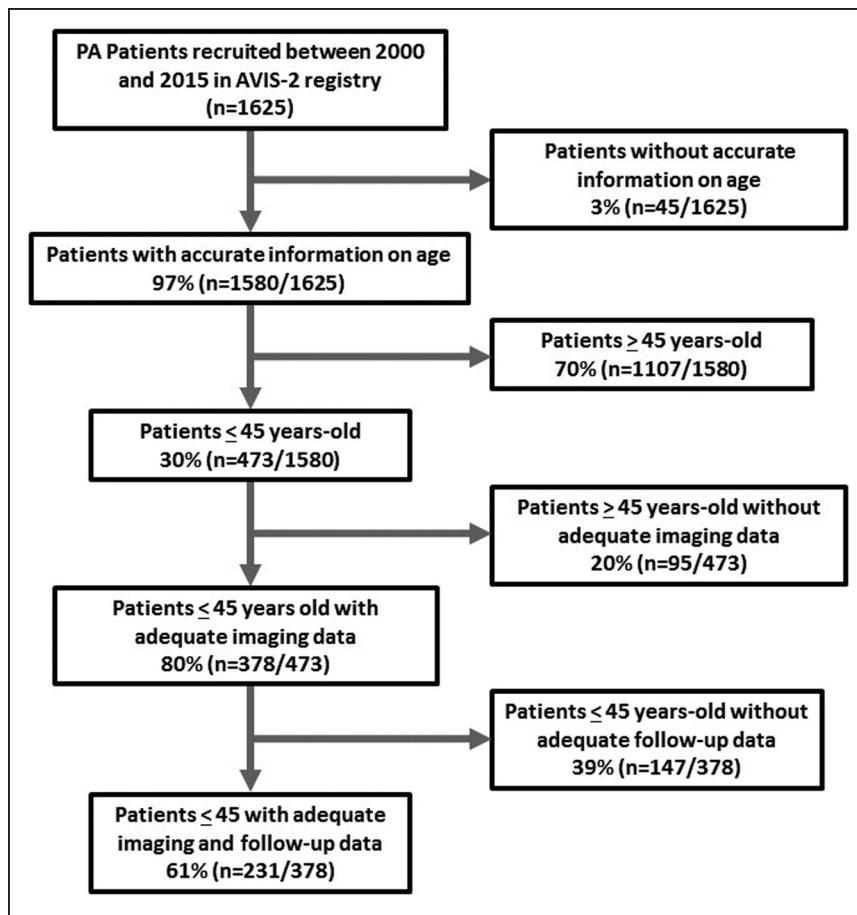


Figure 1. Flow-chart of selection of the patients for the AVIS-2 (Adrenal Vein Sampling International Study) Young study.

Predictors of Surgically Cured Unilateral PA

We investigated the prognosticators of cure after unilateral adrenalectomy using a stepwise backward regression

Table 1. Baseline Demographic, Clinical, and Biochemical Features of Patients Younger Than 45 years of Age With Imaging and Follow-Up Data Available

Variable	Value in patients ≤45 y (n=231)
Age, y	38.5±5.4
Sex (M/F), n (%)	106 (46%)/125 (54%)
Body mass index, kg/m ²	27.6±5.8
Systolic BP, mmHg	150±20
Diastolic BP, mmHg	95±13
Heart rate, beats/min	74±14
Serum K ⁺ , mmol/L	3.6±0.5
PRA, ng/mL per h	0.3 (0.2–0.6)
PAC, ng/dL	24.9 (17.4–39.6)
ARR, ng/dL/ng/mL/h	88.1 (40.5–184.2)
Ethnicity, %	
White participant	75.5%
Asians	21.0%
Africans	3.5%

M±SD or median and IQ range. ARR indicates aldosterone renin ratio; BP, blood pressure; PAC, plasma aldosterone concentration; and PRA, plasma renin activity.

analysis by including in the initial model all the most plausible predictors, besides the presence of unilateral nodule at imaging. We found that only a unilateral nodule at imaging, serum K⁺ measured at AVS, and age, remained in the regression model. Collectively the presence of unilateral nodule at imaging, serum K⁺, and age, predicted 29% of the variance of the outcome variable ($F=32.4$; $P<0.001$, adjusted $R^2=0.290$, Table S2 in the [Supplemental Material](#)), but age was the weakest of the predictors. Of note, systolic ($P=0.075$) and diastolic blood pressure ($P=0.061$), PAC ($P=0.021$), and plasma renin activity ($P=0.032$) showed only weak borderline significant correlation with the outcome variable at bivariate analysis.

Imaging Criteria As a Guide to Surgically Correctable Disease

Of the 231 patients with both imaging and follow-up data, 53% had a unilateral nodule, whose mean size was 15±6 mm (median: 15 mm; range 5–35 mm) and whose size distribution is shown in the Results in the [Supplemental Material](#) (Table S1 and Figure S4). However, 43% of the patients had no detectable nodules, and 4% bilateral nodules. Thus, on the whole, imaging could not guide the referral for surgery in 47% of the patients. Twenty-four percent of those adrenalectomized based on AVS results in spite of uncertain imaging results (21% had no

nodules and 3% bilateral nodules) (Table 2) were cured at follow-up after unilateral adrenalectomy.

Figure 2 shows a scatter plot of nodule size in the adrenalectomized PA patients with a unilateral hypodense adrenal nodule and a contralateral normal appearing adrenal gland as a function of age. Ninety-five of the 98 cases would have been correctly referred for adrenalectomy based on imaging; 3% would have received wrong adrenalectomies and further 2% an inappropriate adrenalectomy.

Hypokalemia As a Guide to Surgically Curable Disease

As the serum K^+ level measured at AVS was identified as an independent predictor of surgically cured unilateral PA, we performed a ROC curve analysis to identify the usefulness the electrolyte level for diagnosing surgically cured unilateral PA. We also sought for the cutoff value that furnished the best combination of sensitivity and specificity, both in the entire cohort and in those with a unilateral nodule.

The ROC curve AUC, a measure of overall diagnostic accuracy, of serum K^+ level was 0.669 (95% CI, 0.605–0.730), which differed ($P < 0.001$) from the AUC under the identity line. At Youden's index analysis, the optimal serum K^+ level cutoff was 3.6 mEq/L, which corresponded to a moderate sensitivity (72%) and low specificity of 60% (Figure 3A; Table S3).

The results were similar when ROC analysis was applied only to the patients with a unilateral nodule at imaging: AUC, 0.644 (95% CI, 0.552–0.729; $P = 0.013$ versus the AUC under the identity line). At Youden's index analysis, the optimal serum K^+ level cutoff was identical and corresponded to a similar sensitivity (71%), but a lower specificity of 50% (Figure 3B; Table S4).

Based on results of the ROC curves and regression analyses, we focused on the proportion of patients with PA with serum K^+ level < 3.6 mmol/L: 55% of the 473 ≤ 45 years of age, 50% of the 231 patients with adequate imaging and follow-up data, and 62% of those who underwent adrenalectomy.

Among the adrenalectomized patients with a unilateral nodule and a contralateral normal appearing adrenal gland

at imaging, the rate of hypokalemia was 58% (57/98); in the adrenalectomized patients without nodules it was 75% and in those with bilateral nodules it was 60%.

The diagnostic accuracy of coexisting hypokalemia and a unilateral nodule was 100%; it fell by 12% (to 88%) in the patients without hypokalemia.

Applicability of the Imaging/Hypokalemia Criterion

We explored the applicability of using a unilateral nodule at imaging and serum $K^+ < 3.6$ mEq/L in the cohort of 231 patients younger than 45 years, who had both imaging and follow-up data. As mentioned above, overall 47% showed no detectable nodules or bilateral nodules; moreover, among those with a unilateral nodule in 44% (54/122) were normokalemic. Hence, the proportion of young patients with PA in whom AVS could be omitted because of the concomitant presence of a unilateral nodule and hypokalemia was 29% (68/231) of the entire cohort (Figure 4).

DISCUSSION

Despite being the most common curable form of arterial hypertension, PA is mostly diagnosed after the fifth or sixth decade.^{28,29} Therefore, patients younger than 45 years of age, and particularly those below 35 years, represent a minority of the reported cases.¹⁵ Therefore, at variance with the guidelines recommendation to screen patients early,^{1,3,4} the diagnosis, and consequently the implementation of the specific treatment, are often delayed, or neglected, in young patients.

Considering the cardiovascular harm of untreated PA,³⁰ and the accumulating evidences that young age and short history of high blood pressure are strong predictors of complete cure of PA with surgery,³¹ the importance of early screening and targeted treatment for PA cannot be overlooked.³¹

Unfortunately, AVS, the key test for assigning patients to adrenalectomy, is not consistently available even in many medically developed countries, so that referral for curative adrenalectomy is not an option to many young patients with PA.

Table 2. Concordance Between Imaging Findings and Final Diagnosis of Surgically Cured Unilateral PA in Patients ≤ 45 y

Findings at cross-sectional imaging in patients ≤ 45 y old	Final diagnosis, n (%)			
	Right unilateral PA	Left unilateral PA	Bilateral PA	Total
Right nodule, n (%)	34 (26%)*	0 (0%)	0 (0%)	34 (26%)
Left nodule, n (%)	3 (2%)	59 (45%)*	2 (1%)	64 (49%)
Bilateral nodules, n (%)	0 (0%)	4 (3%)	1 (1%)*	5 (4%)
No nodules, n (%)	10 (8%)	18 (14%)	0 (0%)	28 (21%)
Total, n (%)	47 (36%)	81 (62%)	3 (2%)	131 (100)%

PA indicates primary aldosteronism.

*Concordance between imaging and final diagnosis in patients ≤ 45 y.

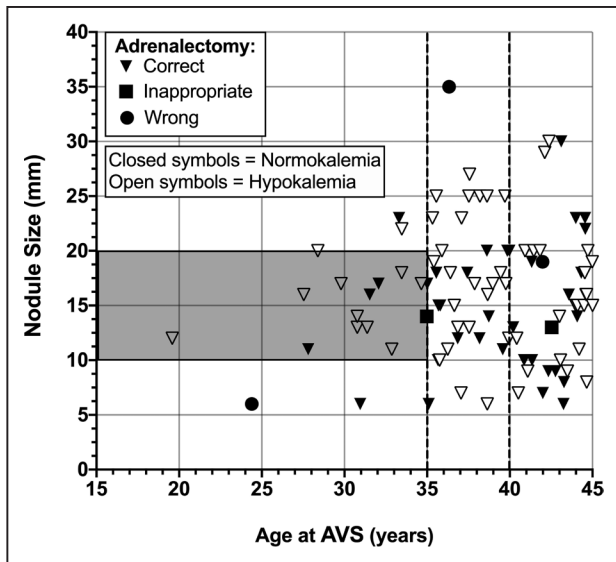


Figure 2. The scatter plot shows the distribution of age and unilateral nodule size, as identified by imaging in the patients who were 45-years-old or younger and showed a unilateral nodule at imaging and a contralateral normally appearing adrenal gland (n=98 ≤45 y; n=58 ≤40 y; n=18 ≤35 y).

The triangles are the patients where the side of the nodule identified with imaging agreed with final diagnosis, and, therefore, who would have undergone correct adrenalectomy based on imaging diagnosis; the square are the patients with bilateral primary aldosteronism (PA) at final diagnosis, who would have undergone inappropriate adrenalectomy based on imaging. The circles identify the patients with imaging nodule side contralateral to the side of unilateral PA at final diagnosis, who would have undergone wrong adrenalectomy based on imaging. Open and close symbols represent patients hypokalemic and normokalemic patients, respectively. The gray area shows the range of nodules ≥10 and <20 mm in size suggested by Lim et al.¹⁵ AVS indicates adrenal vein sampling.

In an attempt to overcome this bottle-neck, it was proposed that AVS can be spared in patients with PA, if they are young and have a unilateral nodule and contralateral normal appearing adrenal gland on imaging.¹⁴ The age cutoff for applying the imaging alone criterion was initially set at 40 years¹⁴ and subsequently lowered to 35

years,³² based on a 100% concordance between detection of an adrenal nodule at imaging and AVS results showing unilateral PA in a small cohort of 6 patients.¹⁵

Since the quality of evidence supporting this contention was judged to be very low, ie, 2⊕000 by the GRADE scoring,¹⁶ the Endocrine Society Clinical Practice guidelines suggested omitting AVS in young patients only if they show a florid biochemical PA, defined as PAC >30 ng/dL and hypokalemia.¹ However, data supporting this contention are limited to a Japanese population¹⁷ and were contradicted by results of a recent retrospective Swedish study.¹⁹ Moreover, in 28 patients aged <40 years, a prediction score based on finding a unilateral typical adenoma on imaging, hypokalemia, and glomerular hyperfiltration had a sensitivity of only 59% and a specificity of 83% in predicting unilateral PA.¹¹

Owing to its wide age inclusion criteria, the AVIS-2 study²⁰ recruited a sizable cohort of young patients with PA, thus offering a unique opportunity to evaluate the diagnostic performance of imaging in young patients. This by no means is a trivial issue, as patients aged 45 years or less comprised a significant proportion, that is, about one-third, of the entire PA population of the AVIS-2 Study. Moreover, the number of young patients with PA will likely increase steadily in the future with widening of the screening strategies and lowering of the minimum size of nodules detected at imaging.

We found that the criterion of a unilateral nodule plus a contralateral normal appearing adrenal at imaging would have allowed correct identification of the responsible side in approximately 95% of the patients aged 45 years or younger and also 40 years or younger, and 89% of those 35 years or younger (Supplemental Material). Using this criterion, assignment to adrenalectomy would have been wrong in 3%, 3%, and 5.5% of the patients aged 45, 40, and 35 years of age or younger, respectively, and inappropriate in 2%, 2%, and 5.5% of them.

Our regression analysis showed that besides a unilateral adrenal nodule on imaging, hypokalemia, defined

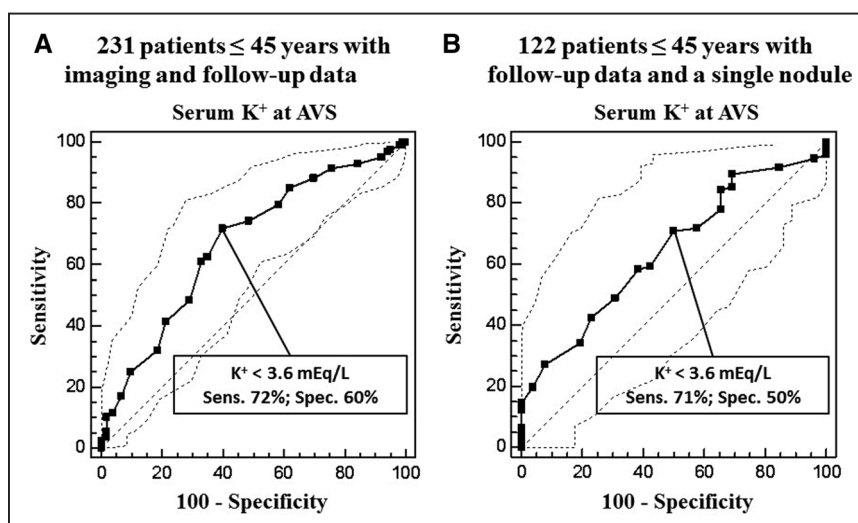


Figure 3. Receiver operating characteristic curves analyses performed using the serum K⁺ for the identification of unilateral primary aldosteronism. (A) Receiver operating characteristic curve analysis performed in 231 patients 45 years of age or younger with imaging and follow-up data. (B) Receiver operating characteristic curve analysis performed in 122 patients 45 years of age or younger with follow-up data available and only a single nodule at imaging.

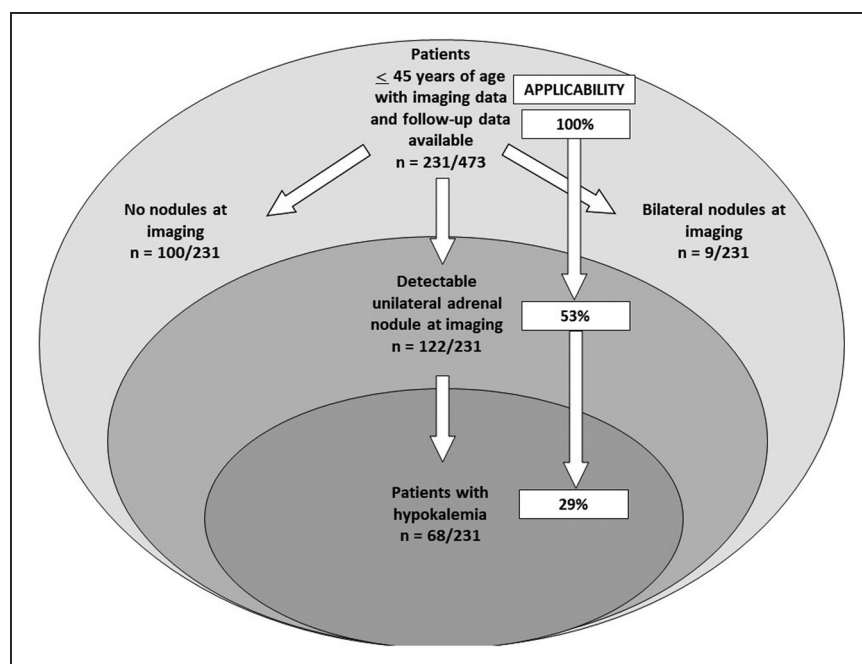


Figure 4. Applicability of the imaging/hypokalemia criteria in the subgroup of patients ≤ 45 years with imaging and follow-up data available of the AVIS-2 (Adrenal Vein Sampling International Study) Young study.

as serum $K^+ < 3.6$ mEq/L, was the strongest predictor of unilateral surgically curable PA. At variance with the suggestion of the Endocrine Society guidelines,¹ we could not confirm that PAC and renin were useful predictors of surgical cure, as they did not remain in the final model at backward stepwise regression. The reasons why they did not contribute to the prediction over hypokalemia are unclear, but possibly related to the multicenter nature of the AVIS-2 study where hormonal measurements were not centralized and used different methods (RIA, ELISA, LC-MSMS), which can generate different results as, for example, LC-MSMS is known to provide lower values than ELISA or RIA.

By exploring the accuracy of finding a unilateral nodule for identifying the responsible adrenal alongside hypokalemia, we found that this combination provided a 100% rate of correct diagnosis, which fell to only a 88% rate when hypokalemia was absent.

Hence, the conclusion can be drawn that in centers where AVS is not available adrenalectomy is feasible in patients who show a unilateral adrenal nodule and spontaneous hypokalemia. These results not only confirm the importance of hypokalemia as predictor of unilateral disease found in the Japanese study,¹⁷ but extend the feasibility of performing adrenalectomy to a multiethnic cohort of PA patients up to 45 years of age.

These important novel findings raise the obvious question of the applicability to young patients with PA of the concurrence of a unilateral nodule and hypokalemia. In AVIS-2-Young, hypokalemia was found in 50% of the patients ≤ 45 years who had imaging and follow-up data available. Moreover, only 53% had an unilateral nodule, a rate slightly lower than the 59% detected in the whole population of the AVIS-2 study.³³ As in these patients the rate of hypokalemia was

44%, the proportion of those with both conditions was 29% of the total, which lowered the applicability of a selection strategy based on imaging and hypokalemia (Figure 4). However, the importance of this approach should not be disregarded because of the high (100%) accuracy that it provided in addition to imaging for identification of the responsible nodule, and of the fact that all patients who received either inappropriate or wrong adrenalectomy were normokalemic (Figure 2).

We also analyzed the AVIS-2-young patients who were aged ≤ 35 years,^{1,15} following the contention of using imaging alone to select patients for surgery in this age cohort. Among these younger patients, who had unambiguously confirmed unilateral PA at follow-up post-adrenalectomy, 29% (7/24) showed no nodules at imaging. Thus, if imaging had been the only diagnostic criterion, a substantial proportion of them would have been denied curative surgery and would have been wrongly assigned to life-long medical treatment (Supplemental Material).

It is worth pointing out that the algorithm originally proposed for patients younger than 35 years included only nodules between 10 and 20 mm in size.¹⁵ Because current imaging technology with standard protocols allows an accurate and consistent identification of smaller nodules (Results in the Supplemental Material), in AVIS-2-Young we used a lower size cutoff threshold of 5 mm for nodule identification, to widen the applicability of the imaging criterion. Of the 2 patients younger than 35 years with solitary unilateral nodules smaller than 10 mm (Figure 2), one was confirmed to have ipsilateral unilateral PA; the other had unilateral PA caused by the contralateral normal appearing adrenal gland. Moreover, considering only nodules sized between 10 and 20 mm,¹⁵ all but one patient < 35 years would have received a correct adrenalectomy.

In spite of the wealth of novel information furnished by the AVIS-2-Young study, some limitations have to be acknowledged. First, it recruited a cohort of highly selected patients with PA, who underwent AVS, and thus comprised the tip of the iceberg of PA phenotypes, likely comprising a more florid disease. Second, in AVIS-2-Young, White patients were over-represented compared with the other ethnicities. Hence, whether these results can be generalized to the entire population of patients with PA remains to be investigated. It should also be acknowledged that some variability could affect the K⁺ measurements since unapparent mild hemolysis can increase (by as much as 0.8 mEq/L) the serum K⁺ values. Hence, our definition of hypokalemia could have underestimated the proportion of patients with PA with this feature. Finally, the lack of centralization for the imaging assessment, the hormonal measurements, and the heterogeneity of AVS interpretation might be perceived as limitations. However, we would suggest that this is a strength of the study, because it provided a snapshot of current clinical practice on the work-up of PA.

In summary, with the strength of the large sample size provided by an international multicenter multiethnic registry, AVIS-2-Young provided the following novel information that is relevant for the assignment to surgical or medical treatment of young patients with an unequivocal diagnosis of PA: 47% of the patients aged 45 years or younger and 25% of those with unambiguously diagnosed unilateral PA, had negative or bilateral findings at imaging.

These patients would have been precluded the possibility of long-term surgical cure if the clinical decision-making were based only on imaging. In patients aged 45 years or younger, who had an adrenal nodule ≥ 5 mm in size, and a contralateral normal appearing adrenal, non AVS-guided unilateral adrenalectomy can be offered if they are willing to accept a 3% chance of a wrong adrenalectomy and a 2% chance of inappropriate adrenalectomy, which could be considered as an acceptable risk in regions where AVS is not easily available and should be presented to the patient. However, the concurrence of hypokalemia raised the diagnostic accuracy to 100%, thus supporting the Endocrine Society guidelines suggestion¹ that in patients with PA aged 45 years or younger, who show a unilateral adrenal nodule, AVS can be omitted if they show a florid PA phenotype revealed by concurrent hypokalemia. AVS is, however, mandatory in the 71% of the patients either because of no or bilateral nodules on imaging or the lack of hypokalemia.

PERSPECTIVES

These results can widen considerably the number of young patients with PA, who can be assigned to unilateral adrenalectomy without undergoing AVS. Whether

the unilateral nodule+hypokalemia can be applied also to patients with PA older 45 years remains to be investigated. Considering the high risk of PA during pregnancy, these women are often advised to avoid pregnancy. We would like to contend that these results could be particularly relevant for young women, who could not be referred for curative adrenalectomy, because of either unfeasible or failed AVS. We recently cured with unilateral adrenalectomy one such patient with a 12 years history of unilateral PA. Unfortunately, this was too late because she was already in menopause.

ARTICLE INFORMATION

Received August 30, 2021; accepted October 10, 2021.

Affiliations

Department of Medicine-DIMED, International PhD Program in Arterial Hypertension and Vascular Biology (ARHYVAB), University of Padova, University Hospital, Italy (G.P.R., G.R., T.M.S.). Department of Medicine-DIMED, University of Padova, Institute of Radiology, University Hospital, Italy (F.C., G.B., M.B.). Institute of Cardiovascular and Medical Sciences, University of Glasgow, United Kingdom (G.R.). AP-HP, Hôpital Européen Georges-Pompidou, Hypertension Department and DMU CARTE, Paris, France (L.A., M.A.). Université de Paris, INSERM, CIC1418 and UMR 970, Paris, France (L.A., M.A.). Medizinische Klinik und Poliklinik IV, Klinikum der Universität München, LMU München, Germany (A.R., M.R., C.D.). 3rd Department of Medicine, Charles University Prague, General Hospital, Czech Republic (J.W., Z.K.). Department of Endocrinology, Clinical Research Institute, NHO Kyoto Medical Center and Endocrine Center, Ijinkai Takeda General Hospital, Japan (M.N.). Department of Internal Medicine, Radboud University Medical Center, Nijmegen, The Netherlands (J.D.). Department of Radiology, Radboud University Medical Center, Nijmegen, The Netherlands (L.S.K.). Department of Endocrinology, Diabetes and Metabolic Diseases, University Medical Centre Ljubljana, Zaloska, Slovenia (T.K.). Faculty of Medicine, University of Ljubljana, Slovenia (T.K.). Department of Internal Medicine, Azienda Unità Sanitaria Locale, IRCCS Arcispedale S. Maria Nuova, Hypertension Unit, Reggio Emilia, Italy (A.N., E.R.). Foothills Medical Centre, University of Calgary, Canada (G.K.). Department of Diabetes, Endocrinology and Metabolism, National Center for Global Health and Medicine, Tokyo, Japan (A.T.). Division of Nephrology, Endocrinology, and Vascular Medicine, Tohoku University Hospital, Sendai, Japan (F.S.). Heinrich Heine University Düsseldorf, Nephrologie, Germany (L.C.R., O.V.). Division of Endocrinology and Metabolism, Rostock University Medical Center, Rostock, Germany (H.S.W.). Endocrinology Unit, Monash Health, Clayton, Victoria, Australia (P.J.F., J.Y., N.Y.N.C.). Hudson Institute of Medical Research, Clayton, Victoria, Australia (P.J.F., J.Y.). Department of Medicine, Monash University, Clayton, Victoria, Australia (J.Y.). Medical College of Wisconsin, Endocrinology Center, North Hills Health Center, Menomonee Falls (S.B.M.). Department of Endocrinology, North-Western Medical University named after I.I. Mechnikov, Russia (Z.S.). Department of Endocrinology in Charlottenburg, Berlin, Germany (M.Q.). Department of Nephrology, Hypertension Unit, Hosp. del Mar Universitat Autònoma de Barcelona, Spain (A.O.). Department of Internal Medicine, National Taiwan University Hospital, Taipei (V.C.W.).

Acknowledgments

G.P. Rossi and F. Crimi conceived the study, managed the data, and performed the statistical analysis. G.P. Rossi drafted the article. All other coauthors collaborated in data collection, interpretation of the results, and revision of the article by providing sound criticisms and feedbacks.

Sources of Funding

This study was supported in part by research grants to G.P. Rossi from FORICA (The Foundation for advanced Research In Hypertension and Cardiovascular diseases) and from the Else Kröner-Fresenius-Stiftung to M. Reincke. A. Riester, M. Reincke, and J. Deinum received support from the Deutsche Forschungsgemeinschaft (DFG, German Research Foundation, Projektnummer 314061271-TRR 205); from the Japan Agency for Medical Research and Development (AMED) (JP20ek0109352) to M. Naruse; from the National Center for Global Health and Medicine, Japan (27-1402, 30-1008) to A. Tanabe.

Disclosures

None.

REFERENCES

- Funder JW, Carey RM, Mantero F, Murad MH, Reincke M, Shibata H, Stowasser M, Young WF Jr. The management of primary aldosteronism: case detection, diagnosis, and treatment: an endocrine society clinical practice guideline. *J Clin Endocrinol Metab.* 2016;101:1889–1916. doi: 10.1210/jc.2015-4061
- Rossi GP, Auchus RJ, Brown M, Lenders JW, Naruse M, Plouin PF, Satoh F, Young WF Jr. An expert consensus statement on use of adrenal vein sampling for the subtyping of primary aldosteronism. *Hypertension.* 2014;63:151–160. doi: 10.1161/HYPERTENSIONAHA.113.02097
- Nishikawa T, Omura M, Satoh F, Shibata H, Takahashi K, Tamura N, Tanabe A; Task Force Committee on Primary Aldosteronism, The Japan Endocrine Society. Guidelines for the diagnosis and treatment of primary aldosteronism—the Japan Endocrine Society 2009. *Endocr J.* 2011;58:711–721. doi: 10.1507/endocrj.11-0133
- Rossi GP, Bisogni V, Bacca AV, Belfiore A, Cesari M, Concistrè A, Del Pinto R, Fabris B, Fallo F, Fava C, et al. The 2020 Italian Society of Arterial Hypertension (SIIA) practical guidelines for the management of primary aldosteronism. *Int J Cardiol Hypertens.* 2020;5:100029. doi: 10.1016/j.ijchy.2020.100029
- Küpers EM, Amar L, Raynaud A, Plouin PF, Steichen O. A clinical prediction score to diagnose unilateral primary aldosteronism. *J Clin Endocrinol Metab.* 2012;97:3530–3537. doi: 10.1210/jc.2012-1917
- Burton TJ, Mackenzie IS, Balan K, Koo B, Bird N, Soloviev DV, Azizan EA, Aigbirhio F, Gurnell M, Brown MJ. Evaluation of the sensitivity and specificity of (11C)-metomidate positron emission tomography (PET)-CT for lateralizing aldosterone secretion by Conn's adenomas. *J Clin Endocrinol Metab.* 2012;97:100–109. doi: 10.1210/jc.2011-1537
- Bongarzone S, Basagni F, Sementa T, Singh N, Gakpetor C, Faugeras V, Bordoloi J, Gee AD. Development of [18 F]FAMTO: a novel fluorine-18 labelled positron emission tomography (PET) radiotracer for imaging CYP11B1 and CYP11B2 enzymes in adrenal glands. *Nucl Med Biol.* 2019;68–69:14–21. <http://www.ncbi.nlm.nih.gov/pubmed/30578137>.
- O'Shea PM, O'Donoghue D, Bashari W, Senanayake R, Joyce MB, Powlson AS, Browne D, O'Sullivan GJ, Cheow H, Mendichovszky I, et al. ¹¹C-Metomidate PET/CT is a useful adjunct for lateralization of primary aldosteronism in routine clinical practice. *Clin Endocrinol (Oxf).* 2019;90:670–679. doi: 10.1111/cen.13942
- Umakoshi H, Tsuiji M, Takeda Y, Kurihara I, Itoh H, Katabami T, Ichijo T, Wada N, Yoshimoto T, Ogawa Y, et al; JPAS Study Group. Significance of computed tomography and serum potassium in predicting subtype diagnosis of primary aldosteronism. *J Clin Endocrinol Metab.* 2018;103:900–908. doi: 10.1210/jc.2017-01774
- Soinio M, Luukkonen AK, Seppänen M, Kemppainen J, Seppänen J, Pienimäki JP, Leijon H, Vesterinen T, Arola J, Lantto E, et al. Functional imaging with ¹¹C-metomidate PET for subtype diagnosis in primary aldosteronism. *Eur J Endocrinol.* 2020;183:539–550. doi: 10.1530/EJE-20-0532
- Riester A, Fischer E, Degenhart C, Reiser MF, Bidlingmaier M, Beuschlein F, Reincke M, Quinkler M. Age below 40 or a recently proposed clinical prediction score cannot bypass adrenal venous sampling in primary aldosteronism. *J Clin Endocrinol Metab.* 2014;99:E1035–E1039. doi: 10.1210/jc.2013-3789
- Podbregar A, Janez A, Gorcar K, Jensterle M. The prevalence and characteristics of non-functioning and autonomous cortisol secreting adrenal incidentaloma after patients' stratification by body mass index and age. *BMC Endocr Disord.* 2020;20:118. doi: 10.1186/s12902-020-00599-0
- Sherlock M, Scarsbrook A, Abbas A, Fraser S, Limumpornpetch P, Dineen R, Stewart PM. Adrenal Incidentaloma. *Endocr Rev.* 2020;41:bnaa008. doi: 10.1210/edrv/bnaa008
- Young WF. Primary aldosteronism: renaissance of a syndrome. *Clin Endocrinol (Oxf).* 2007;66:607–618. doi: 10.1111/j.1365-2265.2007.02775.x
- Lim V, Guo Q, Grant CS, Thompson GB, Richards ML, Farley DR, Young WF Jr. Accuracy of adrenal imaging and adrenal venous sampling in predicting surgical cure of primary aldosteronism. *J Clin Endocrinol Metab.* 2014;99:2712–2719. doi: 10.1210/jc.2013-4146
- Balslem H, Helfand M, Schünemann HJ, Oxman AD, Kunz R, Brozek J, Vist GE, Falck-Ytter Y, Meerpohl J, Norris S, et al. GRADE guidelines: 3. Rating the quality of evidence. *J Clin Epidemiol.* 2011;64:401–406. doi: 10.1016/j.jclinepi.2010.07.015
- Umakoshi H, Ogasawara T, Takeda Y, Kurihara I, Itoh H, Katabami T, Ichijo T, Wada N, Shibayama Y, Yoshimoto T, et al. Accuracy of adrenal computed tomography in predicting the unilateral subtype in young patients with hypokalaemia and elevation of aldosterone in primary aldosteronism. *Clin Endocrinol (Oxf).* 2018;88:645–651. doi: 10.1111/cen.13582
- Williams TA, Burrello J, Sechi LA, Fardella CE, Matrozoza J, Adolf C, Baudrand R, Bernardi S, Beuschlein F, Catena C, et al. Computed tomography and adrenal venous sampling in the diagnosis of unilateral primary aldosteronism. *Hypertension.* 2018;72:641–649. doi: 10.1161/HYPERTENSIONAHA.118.11382
- Gkaniatsa E, Sakinis A, Palmér M, Muth A, Trimpou P, Ragnarsson O. Adrenal venous sampling in young patients with primary aldosteronism. Extravagance or irreplaceable? *J Clin Endocrinol Metab.* 2021;106:e2087–e2095. doi: 10.1210/clinem/dgab047
- Rossi GP, Rossitto G, Amar L, Azizi M, Riester A, Reincke M, Degenhart C, Widimsky J Jr, Naruse M, Deinum J, et al. Clinical outcomes of 1625 patients with primary aldosteronism subtyped with adrenal vein sampling. *Hypertension.* 2019;74:800–808. doi: 10.1161/HYPERTENSIONAHA.119.13463
- Bossuyt PM, Reitsma JB, Bruns DE, Gatsonis CA, Glasziou PP, Irwig L, Lijmer JG, Moher D, Rennie D, de Vet HC, et al; STARD Group. STARD 2015: an updated list of essential items for reporting diagnostic accuracy studies. *BMJ.* 2015;351:h5527. doi: 10.1136/bmj.h5527
- Rossi GP, Barisa M, Allolio B, Auchus RJ, Amar L, Cohen D, Degenhart C, Deinum J, Fischer E, Gordon R, et al. The Adrenal Vein Sampling International Study (AVIS) for identifying the major subtypes of primary aldosteronism. *J Clin Endocrinol Metab.* 2012;97:1606–1614. doi: 10.1210/jc.2011-2830
- Rossitto G, Amar L, Azizi M, Riester A, Reincke M, Degenhart C, Widimsky JJ, Mitsuhide N, Deinum J, Schultze Kool L, et al. Subtyping of primary aldosteronism in the AVIS-2 Study: assessment of selectivity and lateralisation. *J Clin Endocrinol Metab.* 2020;105:2042–2052.
- Seccia TM, Caroccia B, Gomez-Sanchez EP, Gomez-Sanchez CE, Rossi GP. The Biology of normal zona glomerulosa and aldosterone-producing adenoma: pathological implications. *Endocr Rev.* 2018;39:1029–1056. doi: 10.1210/er.2018-00060
- Williams TA, Lenders JWM, Mulatero P, Burrello J, Rottenkolber M, Adolf C, Satoh F, Amar L, Quinkler M, Deinum J, Beuschlein F, et al; Investigators PASO (PASO). Outcomes after adrenalectomy for unilateral primary aldosteronism: An international consensus on outcome measures and analysis of remission rates in an international cohort. *Lancet Diabetes Endocrinol.* 2017;8:587:689–699. doi: 10.1016/S2213-8587(17)30135-3
- Tabachnick BG, Fidell LS. *Using Multivariate Statistics.* Allyn Bacon; 2001.
- Menard S. *Applied Logistic Regression Analysis.* 2nd ed. SAGE Publications, Inc; 2002.
- Rossi GP, Bernini G, Caliumi C, Desideri G, Fabris B, Ferri C, Ganzaroli C, Giacchetti G, Letizia C, Maccario M, et al; PAPY Study Investigators. A prospective study of the prevalence of primary aldosteronism in 1,125 hypertensive patients. *J Am Coll Cardiol.* 2006;48:2293–2300. doi: 10.1016/j.jacc.2006.07.059
- Rossi GP. Prevalence and diagnosis of primary aldosteronism. *Curr Hypertens Rep.* 2010;12:342–348. doi: 10.1007/s11906-010-0134-2
- Baudrand R, Guarda FJ, Fardella C, Hundemer G, Brown J, Williams G, Vaidya A. Continuum of renin-independent aldosteronism in normotension. *Hypertension.* 2017;69:950–956. doi: 10.1161/HYPERTENSIONAHA.116.08952
- Rossi GP. Primary aldosteronism: JACC state-of-the-art review. *J Am Coll Cardiol.* 2019;74:2799–2811. doi: 10.1016/j.jacc.2019.09.057
- Young WF Jr. Diagnosis and treatment of primary aldosteronism: practical clinical perspectives. *J Intern Med.* 2019;285:126–148. doi: 10.1111/joim.12831
- Rossi GP, Crimi F, Rossitto G, Amar L, Azizi M, Riester A, Reincke M, Degenhart C, Widimsky J, Naruse M, Deinum J, Schultze Kool L, et al. Identification of surgically curable primary aldosteronism by imaging in a large multiethnic international study. *J Clin Endocrinol Metab.* 2021;106:e4340–e4349. doi: 10.1210/clinem/dgab482