



HAL
open science

CMV-related anterior and intermediate uveitis in a kidney transplant recipient treated with belatacept

Antoine Morel, Amina Chahrazed Debieb, David Mrejen, Lucile Amrouche, Anne Scemla, Estelle Vilain, Christophe Legendre, Dany Anglicheau, Julien Zuber, Antoine Brézin, et al.

► To cite this version:

Antoine Morel, Amina Chahrazed Debieb, David Mrejen, Lucile Amrouche, Anne Scemla, et al.. CMV-related anterior and intermediate uveitis in a kidney transplant recipient treated with belatacept. European Journal of Ophthalmology, 2022, pp.112067212211263. 10.1177/11206721221126308. hal-04052046

HAL Id: hal-04052046

<https://hal.science/hal-04052046>

Submitted on 31 Mar 2023

HAL is a multi-disciplinary open access archive for the deposit and dissemination of scientific research documents, whether they are published or not. The documents may come from teaching and research institutions in France or abroad, or from public or private research centers.

L'archive ouverte pluridisciplinaire **HAL**, est destinée au dépôt et à la diffusion de documents scientifiques de niveau recherche, publiés ou non, émanant des établissements d'enseignement et de recherche français ou étrangers, des laboratoires publics ou privés.



Distributed under a Creative Commons Attribution - NonCommercial 4.0 International License

CMV-related anterior and intermediate uveitis in a kidney transplant recipient treated with belatacept

European Journal of Ophthalmology
1–4



© The Author(s) 2022

Article reuse guidelines:

sagepub.com/journals-permissions

DOI: 10.1177/11206721221126308

journals.sagepub.com/home/ejo

Antoine Morel^{1,2}, Amina Chahrazed Debieb^{2,3}, David Mrejen^{2,3},
Lucile Amrouche^{1,2}, Anne Scemla^{1,2}, Estelle Vilain¹,
Christophe Legendre^{1,2}, Dany Anglicheau^{1,2}, Julien Zuber^{1,2},
Antoine Brézin^{2,3}  and Nathalie Chavarot^{1,2} 

Abstract

Introduction: Belatacept is associated with a higher incidence of cytomegalovirus (CMV) disease and atypical presentations. Ocular manifestations are rare, representing up to 5% of disease manifestations and previous cases consisted in isolated retinitis.

Case Description: Herein, we report the case of an 81-year-old kidney transplant recipient who developed an anterior and intermediate uveitis under belatacept therapy. The diagnosis was established using quantitative CMV polymerase chain reaction assays in the aqueous humor. Belatacept was interrupted and oral and topical valganciclovir treatments were instituted. Lesions however extended, leading to intensify the treatment by intra-venous and intra-vitreous ganciclovir injections. Visual acuity stabilized and ocular inflammation was finally controlled after 3 months.

Conclusion: Clinicians should be aware of CMV infection as a cause of anterior uveitis under belatacept-based regimen, even in the absence of symptoms suggestive of systemic CMV replication.

Keywords

Cytomegalovirus, uveitis, belatacept, kidney transplant recipient

Date received: 11 November 2021; accepted: 11 August 2022

Introduction

We and others recently reported a very high incidence of CMV disease in KTRs under belatacept-based regimen, compared to those treated with CNI therapy.¹ Notably, belatacept-associated CMV diseases exhibit 3 unique features, including 1- an overrepresentation of tissue-invasive diseases, 2- a high frequency of late-onset forms, remote in time from the induction therapy (even in CMV seropositive patients), and 3- high relapsing rates.¹ The gastrointestinal tract is the most frequently targeted tissue, whereas CMV ocular manifestations seldom occur, accounting for 5% CMV clinical presentations under belatacept and were isolated CMV retinitis.^{1–3} We herein report the first case of CMV intermediate and AU under belatacept.

Case description

An 81-year-old woman was admitted to the hospital because of sudden blurred vision in her left eye in December 2019. She had undergone a preemptive kidney transplantation (KT) in January 2019 for autosomal

¹Department of Nephrology and Kidney Transplantation, Necker-Enfants Malades Hospital, Assistance Publique-Hôpitaux de Paris, Paris, France

²Université de Paris, Paris, France

³Department of Ophthalmology, Cochin Hospital, Assistance Publique-Hôpitaux de Paris, Paris, France

Corresponding author:

Nathalie Chavarot, Service de Néphrologie et Transplantation Rénale Adulte, Hôpital Necker-Enfants Malades, 149, Rue de Sèvres, 75015 Paris, France.

Email: Nathalie.chavarot@aphp.fr

dominant polycystic kidney disease-related end stage renal disease. Her medical history was otherwise unremarkable with the exception of a breast cancer treated with mastectomy and radiation therapy. Immunosuppressive treatment consisted in antithymocyte globulin induction, followed by a maintenance immunosuppressive regimen including tacrolimus, everolimus and steroids. Cytomegalovirus (CMV) serologic status was donor+ / recipient+. At one-month post-transplant, the patient had been switched from tacrolimus/everolimus to belatacept, mycophenolic acid (MPA) and steroids (10 mg of prednisone), after a diagnosis of biopsy-proven *de novo* thrombotic microangiopathy. The occurrence of neutropenia and CMV viremia in May 2019 had prompted to initiate a 3-week full-dose valganciclovir treatment, along with MPA withdrawal. The patient had been remaining CMV-free and off MPA, with a normal neutrophil cell count, for the six following months.

In December 2019, she complained of an acute decreased visual acuity in the left eye. Clinically, the eye was white and both eyes were painless. Best-corrected decimal visual acuity was 0.7 and 1.0 on the left and right eyes, respectively. Slit-lamp examination of the left eye showed a corneal edema associated with an anterior uveitis (AU) and white granulomatous keratic precipitates with a positive Tyndall effect (+2 in the anterior eye

chamber) but without iris-lens synechiae (Figure 1) associated with vitreous haze and vitreous veils. There was no snowballs or snowbanks. Endotheliitis was observed with coin-shaped lesions at the corneal endothelial surface as clusters of fine precipitates. Anterior chamber flare was of 56.3 photon counts per millisecond in the left eye (while it was of 6.2 photon counts per millisecond in the right eye). The intraocular pressure (IOP) was increased at 40 mmHg. A vitritis was observed, but no retinal lesion was seen. Optical Coherence Tomography imaging showed a normal macular profile and the rest of the ophthalmic examination was otherwise normal. Creatinine level was stable, liver enzymes were normal and complete blood cell count showed a normal leukocyte count with isolated lymphopenia ($905/\text{mm}^3$) associated with a severe CD4 depletion ($92/\text{mm}^3$). CD8 count was at $561/\text{mm}^3$.

The diagnosis of vitreoretinal lymphoma was initially suspected in this highly immunocompromised kidney transplant recipient (KTR), presenting with an isolated vitritis. Therefore, an anterior chamber tap was performed to analyze the IL-10/IL-6 ratio in the aqueous humor (AH). However, a negative Interleukin Score for Intraocular Lymphoma Diagnosis did not support this hypothesis. AH sample was also tested for opportunistic infectious agents. Quantitative polymerase chain reaction (PCR)

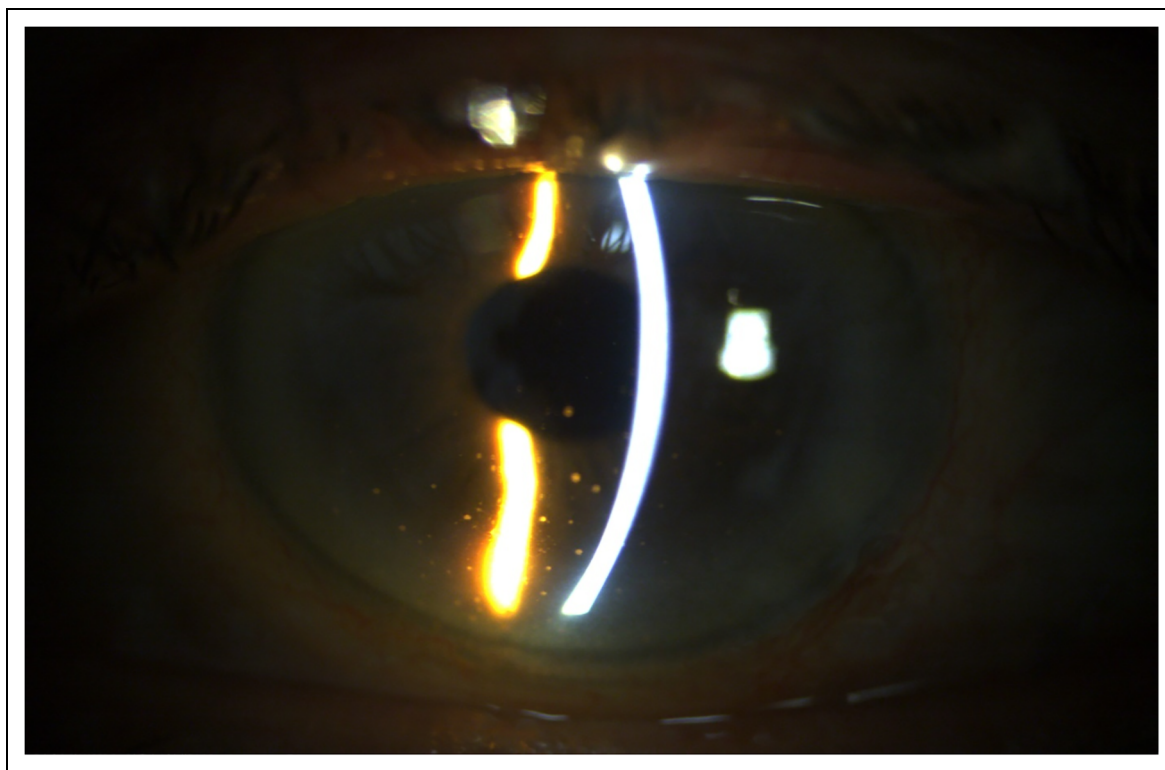


Figure 1. Anterior uveitis.

Slit-lamp photography of the anterior segment of the left eye: anterior uveitis with white granulomatous keratic precipitates.

assays unveiled a CMV replication (4.28 log) in the AH but failed to identify VZV, HSV and *Toxoplasma gondii* DNA. Hence, the diagnosis of CMV-related anterior and intermediate uveitis was established. Concomitant CMV blood testing disclosed a positive viremia at 4 log, while brain MRI was normal. Oral valganciclovir (450 mg every 2 days, dose adjusted to renal function (eGFR: 15 mL/min)) and topical ganciclovir (2% ganciclovir, 1 drop 5 times a day) treatments were instituted, in association with topical steroids and IOP-lowering drops, meanwhile belatacept was interrupted. After one week of treatment, ocular lesions extended (vitreous condensations and vitreous haze increased) leading to start intra-venous (IV) (1.25 mg/kg per day, dose adjusted to renal function) and intra-vitreous ganciclovir (GCV) injections (400 µg). After 3 weeks of treatment, the CMV viral load decreased to 3.18 logs in the AH and was negative in the peripheral blood. Three months later, visual acuity stabilized (0.8)

and ocular inflammation was finally controlled (Figure 2) and IOP was of 12 mmHg.

Discussion and conclusions

To the best of our knowledge, this is the first report of CMV-induced intermediate and anterior uveitis (AU) in the absence of retinitis in a KTR treated with belatacept. The most common ocular CMV manifestation in immunocompromised patients is CMV retinitis and has been mainly described in HIV patients. CMV anterior segment infection has been also recognized in the two last decades in immunocompetent patients.^{4,5} Yet, only a few immunosuppressed patients have been reported with CMV anterior or intermediate uveitis.^{6,7} The clinical presentations include keratic precipitates, iris atrophy, elevated IOP and corneal endotheliitis. Additionally, CMV AU has been reported to be implicated in 25% of

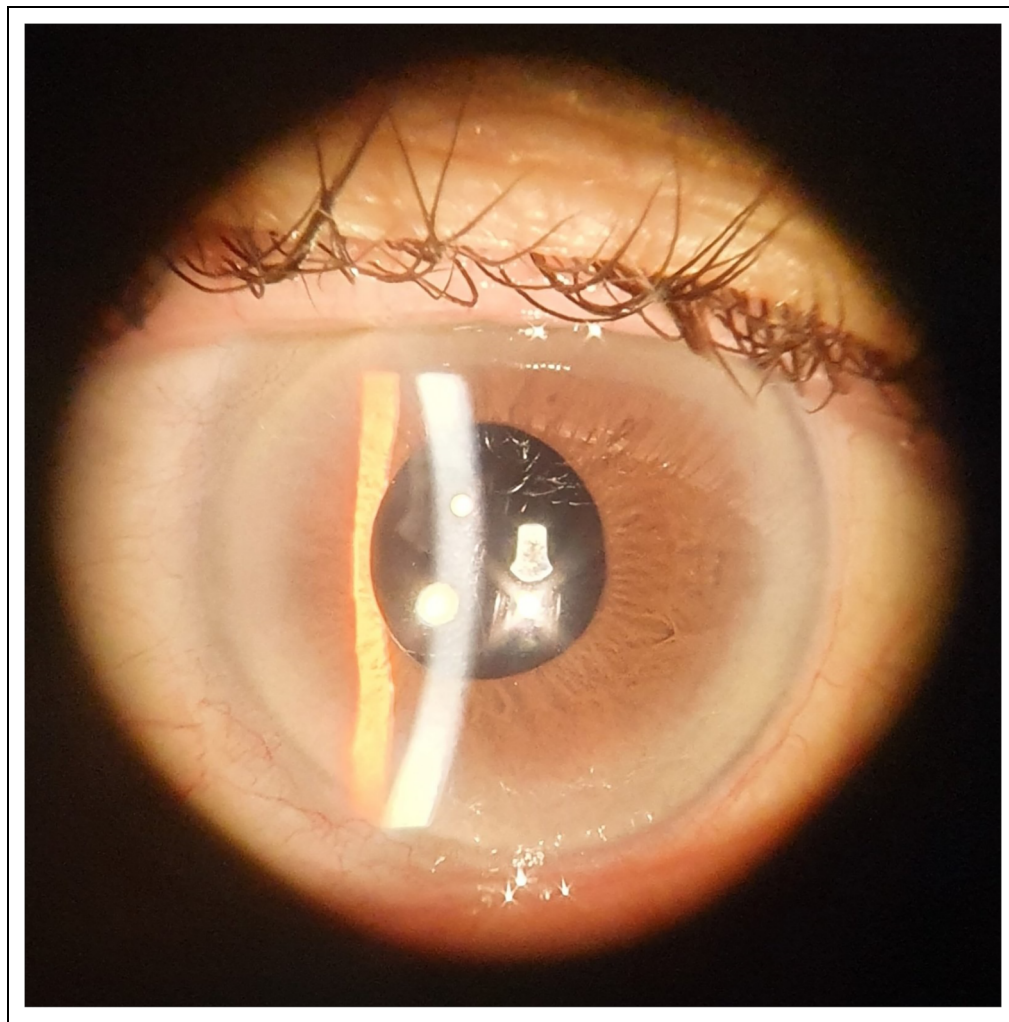


Figure 2. Slit-lamp photography of the anterior segment of the left eye after anti-CMV therapy. The initial lesions resolved following anti-CMV therapy.

cases of hypertensive uveitis. Other manifestations are acute relapsing hypertensive anterior uveitis (Posner Schlossman syndrome) or chronic AU form similar to Fuchs uveitis syndrome.⁸ The main complications in case of uncontrolled disease are cataract formation, corneal decompensation and glaucomatous optic neuropathy, the latter being one of the most common and sight-threatening complications.⁴

Increased incidence of CMV disease is now well characterized in patients treated with belatacept. Ocular manifestations are rare representing 5% of clinical manifestations and consisted in isolated CMV retinitis^{1–3}. No previous case of uveitis had been reported. This case confirms the atypical phenotype of CMV disease under belatacept and the hypothesis that belatacept could weaken a preexisting anti-CMV immune response. Interestingly, this severe opportunistic infection occurred while the immunosuppression had been tapered down for months, limited to a monthly belatacept infusion and steroids. CMV uveitis treatment is based on anti-viral therapy. Several reports, mainly in immunocompetent patients have compared the efficacy of IV vs intravitreal or topical GCV with contrasting results.^{9,10} In our patient, ocular lesions extended under oral and topical GCV but the disease was finally controlled when antiviral therapy was reinforced by IV and intravitreal routes of administration.

In conclusion, a special attention should be paid to CMV infection as a cause of AU in transplant patients under belatacept-based regimen, even in the absence of symptoms suggestive of systemic CMV replication. An ophthalmologic examination should be systematically performed in belatacept-treated patients with CMV replication and/or eye symptoms. In such context, an anterior chamber tap should be promptly undertaken for CMV testing so that appropriate anti-viral therapy could be initiated without undue delay.

Declaration of conflicting interests

The author(s) declared no potential conflicts of interest with respect to the research, authorship, and/or publication of this article.


Funding


The author(s) received no financial support for the research, authorship, and/or publication of this article.

Informed consent

An informed consent was obtained from the patient for publishing the photograph and the case.

ORCID iDs

Antoine Brézin  <https://orcid.org/0000-0001-8461-3119>

Nathalie Chavarot  <https://orcid.org/0000-0001-6361-1392>

References

1. Chavarot N, Divard G, Scemla A, et al. Increased incidence and unusual presentations of CMV disease in kidney transplant recipients after conversion to belatacept. *Am J Transplant* 2021; 21: 2448–2458. Published online January 2, 2021.
2. Deliège PG, Bastien J, Mokri L, et al. Belatacept associated - cytomegalovirus retinitis in a kidney transplant recipient: a case report and review of the literature. *BMC Ophthalmol* 2020; 20: 468.
3. Fan J, Gong D, Truong C, et al. Cytomegalovirus retinitis with belatacept immunosuppression. *Retin Cases Brief Rep*. 2022; 16: 199–203. Publish Ahead of Print.
4. Chan NSW, Chee SP, Caspers L, et al. Clinical features of CMV-associated anterior uveitis. *Ocul Immunol Inflamm* 2018; 26: 107–115.
5. Chee SP, Bacsal K, Jap A, et al. Clinical features of cytomegalovirus anterior uveitis in immunocompetent patients. *Am J Ophthalmol* 2008; 145: 834–840.e1.
6. Hamouda M, Kahloun R, Jaballah L, et al. Cytomegalovirus ocular involvement in a kidney transplant recipient. *Exp Clin Transplant Off J Middle East Soc Organ Transplant* 2018; 16: 495–498.
7. Pathanapitoon K, Tesavibul N, Choopong P, et al. Clinical manifestations of cytomegalovirus-associated posterior uveitis and panuveitis in patients without human immunodeficiency virus infection. *JAMA Ophthalmol* 2013; 131: 638.
8. Relvas LJM, Antoun J, de Groot-Mijnes JDF, et al. Diagnosis of cytomegalovirus anterior uveitis in two European referral centers. *Ocul Immunol Inflamm* 2018; 26: 116–121.
9. Chee SP and Jap A. Cytomegalovirus anterior uveitis: outcome of treatment. *Br J Ophthalmol* 2010; 94: 1648–1652.
10. Touhami S, Qu L, Angi M, et al. Cytomegalovirus anterior uveitis: clinical characteristics and long-term outcomes in a French series. *Am J Ophthalmol* 2018; 194: 134–142.

Abbreviations

AH	aqueous humor
AU	anterior uveitis
CMV	cytomegalovirus
GCV	ganciclovir
IOP	intraocular pressure
KT	kidney transplantation
KTR	kidney transplant recipient
PCR	polymerase chain reaction