



HAL
open science

Silver-Russell Syndrome Synonym: Russell-Silver Syndrome

Howard M Saal, Madeleine D Harbison, Irene Netchine

► **To cite this version:**

Howard M Saal, Madeleine D Harbison, Irene Netchine. Silver-Russell Syndrome Synonym: Russell-Silver Syndrome. GeneReviews, 2019. hal-04027182

HAL Id: hal-04027182

<https://hal.science/hal-04027182>

Submitted on 31 Mar 2023

HAL is a multi-disciplinary open access archive for the deposit and dissemination of scientific research documents, whether they are published or not. The documents may come from teaching and research institutions in France or abroad, or from public or private research centers.

L'archive ouverte pluridisciplinaire **HAL**, est destinée au dépôt et à la diffusion de documents scientifiques de niveau recherche, publiés ou non, émanant des établissements d'enseignement et de recherche français ou étrangers, des laboratoires publics ou privés.



Silver-Russell Syndrome

Synonym: Russell-Silver Syndrome

Howard M Saal, MD,¹ Madeleine D Harbison, MD,² and Irene Netchine, MD, PhD³

Created: November 2, 2002; Updated: October 21, 2019.

Summary

Clinical characteristics

Silver-Russell Syndrome (SRS) is typically characterized by asymmetric gestational growth restriction resulting in affected individuals being born small for gestational age, with relative macrocephaly at birth (head circumference ≥ 1.5 SD above birth weight and/or length), prominent forehead usually with frontal bossing, and frequently body asymmetry. This is followed by postnatal growth failure, and in some cases progressive limb length discrepancy and feeding difficulties. Additional clinical features include triangular facies, fifth-finger clinodactyly, and micrognathia with narrow chin. Except for the limb length asymmetry, the growth failure is proportionate and head growth normal. The average adult height in untreated individuals is $\sim 3.1 \pm 1.4$ SD below the mean. The Netchine-Harbison Clinical Scoring System (NH-CSS) is a sensitive diagnostic scoring system. Clinical diagnosis can be established in an individual who meets at least four of the NH-CSS clinical criteria – prominent forehead/frontal bossing and relative macrocephaly at birth plus two additional findings – and in whom other disorders have been ruled out.

Diagnosis/testing

SRS is a genetically heterogeneous condition. Genetic testing confirms clinical diagnosis in approximately 60% of affected individuals. Hypomethylation of the imprinted control region 1 (ICR1) at 11p15.5 causes SRS in 35%-50% of individuals, and maternal uniparental disomy (mUPD7) causes SRS in 7%-10% of individuals. There are a small number of individuals with SRS who have duplications, deletions or translocations involving the imprinting centers at 11p15.5 or duplications, deletions, or translocations involving chromosome 7. Rarely, affected individuals with pathogenic variants in *CDKN1C*, *IGF2*, *PLAG1*, and *HMGGA2* have been described. However, approximately 40% of individuals who meet NH-CSS clinical criteria for SRS have negative molecular and/or cytogenetic testing.

Author Affiliations: 1 Director of Clinical Genetics, Division of Human Genetics Cincinnati Children's Hospital Medical Center Professor of Pediatrics, University of Cincinnati College of Medicine Cincinnati, Ohio; Email: saalhm@cchmc.org. 2 Icahn School of Medicine at Mount Sinai New York, New York; Email: madeleine.harbison@mssm.edu. 3 Sorbonne Université, INSERM, UMR_S 938 Centre de Recherche Saint Antoine APHP, Hôpital Armand Trousseau Explorations Fonctionnelles Endocriniennes Paris, France; Email: irene.netchine@aphp.fr.

Management

Treatment of manifestations: Multidisciplinary follow up and early, specific intervention are necessary for optimal management of affected individuals. Treatment may include growth hormone therapy. Hypoglycemia should be prevented or aggressively managed. Strategies for feeding disorders include nutritional and caloric supplements, medication for gastroesophageal reflux, therapy for oral motor problems and feeding aversion, cyproheptadine for appetite stimulation, and enteral tube feeding as needed. Lower-limb length discrepancy exceeding 2 cm requires intervention. In older children, distraction osteogenesis is recommended for most individuals. Physical, occupational, speech, and language therapy with an individualized education plan are used to treat delays. Psychological counseling can be used as needed to address psychosocial and body image issues. Severe micrognathia or cleft palate should be managed by a multidisciplinary craniofacial team. Males with cryptorchidism or hypospadias should be referred to a urologist. Males with micropenis and females with internal genitourinary anomalies benefit from referral to a multidisciplinary disorders of sex development center.

Surveillance: Monitoring of: growth velocity; blood glucose concentration and urine ketones for hypoglycemia in infants and as needed in older children; limb length at each well-child visit in early childhood for evidence of asymmetric growth; evaluation for scoliosis, signs of premature central puberty, dental crowding and malocclusion, and speech/language development.

Agents/circumstances to avoid: prolonged fasting in infants and young children because of the risk for hypoglycemia; elective surgery whenever possible due to risk of hypoglycemia, hypothermia, difficult healing, and difficult intubation.

Genetic counseling

SRS has multiple etiologies and typically has a low recurrence risk. In most families, a proband with Silver-Russell syndrome (SRS) represents a simplex case (a single affected family member) and has SRS as the result of an apparent *de novo* epigenetic or genetic alteration (e.g., loss of paternal methylation at the 11p15 ICR1 H19/IGF2 imprinting center 1 or maternal uniparental disomy for chromosome 7). SRS may also occur as the result of a genetic alteration associated with up to a 50% recurrence risk (e.g., a copy number variant on chromosome 7 or 11 or an intragenic pathogenic variant in *CDKN1C*, *IGF2*, *PLAG2*, or *HMGA2*) depending on the nature of the genetic alteration and the sex of the transmitting parent. Accurate assessment of SRS recurrence therefore requires identification of the causative genetic mechanism in the proband.

Diagnosis

Silver-Russell syndrome (SRS) is a genetically heterogeneous disorder; the clinical diagnosis requires fulfillment of specific clinical criteria described in the Netchine-Harbison clinical scoring system (NH-CSS) listed in Suggestive Findings [Azzi et al 2015]. This scoring system has been accepted as the method for identifying those individuals who should have further evaluation for diagnosis of SRS [Wakeling et al 2017].

Suggestive Findings

Silver-Russell syndrome (SRS) **should be suspected in** individuals who meet the NH-CSS clinical criteria [Azzi et al 2015] as follows:

- Small for gestational age (birth weight and/or length ≥ 2 SD below the mean for gestational age)
- Postnatal growth failure (length/height ≥ 1 SD below the mean at 24 months)
- Relative macrocephaly at birth (head circumference > 1.5 SD above birth weight and/or length)
- Frontal bossing or prominent forehead (forehead projecting beyond the facial plane on a side view as a toddler [1–3 years])

- Body asymmetry (limb length discrepancy ≥ 0.5 cm, or < 0.5 cm with ≥ 2 other asymmetric body parts)
- Feeding difficulties or body mass index ≤ 2 SD at 24 months or current use of a feeding tube or cyproheptadine for appetite stimulation

If an individual meets four of the six criteria, the clinical diagnosis is suspected and molecular confirmation testing is warranted. Some rare individuals meeting three of the six criteria have had a positive molecular confirmation for SRS.

Establishing the Diagnosis

The diagnosis of SRS is **established in** a proband who meets four of the six Netchine-Harbison clinical diagnostic criteria and who has findings on molecular genetic testing consistent with either hypomethylation on chromosome 11p15.5 or maternal uniparental disomy (UPD) for chromosome 7 (see Table 1).

Chromosome 11p15.5 imprinting cluster. SRS is associated with abnormal regulation of gene transcription in two imprinted domains on chromosome 11p15.5. Regulation may be disrupted by any one of numerous mechanisms. See Molecular Pathogenesis for a detailed description of the regulation of gene expression in this region.

Maternal UPD7 can occur by different mechanisms. See Molecular Pathogenesis.

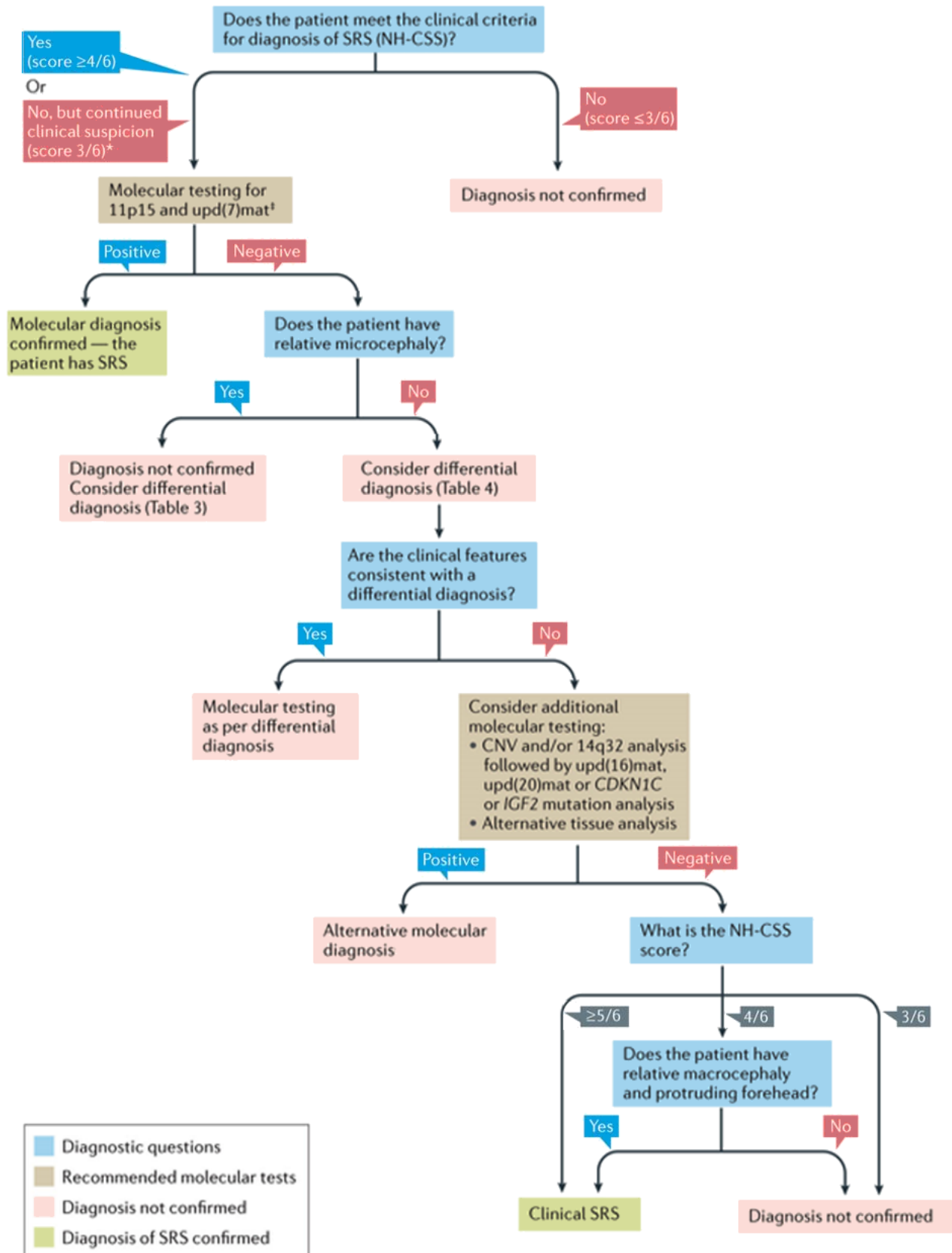
An algorithm for investigation of the diagnosis of SRS was published by the International Expert Consensus [Wakeling et al 2017]. See Figure 1.

The recommended order of testing for SRS is the following:

- Methylation analysis of 11p15.5 ICR1/ICR2 and maternal UPD7 studies may be ordered simultaneously.
Note: (1) Detection of an abnormality is dependent on the mechanism of disease and methodology used (see Table 1). (2) Mosaicism has been reported; therefore, testing of other tissues (e.g., buccal cells or skin fibroblasts) may be considered if leukocyte testing is normal.
- If methylation analysis of 11p15.5 ICR1/ICR2 and maternal UPD7 studies are normal, sequence analysis of *IGF2*, *CDKN1C*, *PLAG1*, and *HMGA2* may be considered.
Note: Some individuals ultimately diagnosed with SRS will have a SNP chromosomal microarray (CMA) based on their significant growth restriction noted at birth or later based on speech or other developmental delays. While this is not a first-tier testing recommendation for someone suspected of having SRS, it can uncover chromosome 7 or 11 abnormalities that establish the diagnosis (see Table 1).

If methylation analysis of 11p15.5 ICR1/ICR2 and UPD7 studies are normal, a multigene panel that includes sequence analysis of *IGF2*, *CDKN1C*, *PLAG1*, *HMGA2*, and other genes of interest (see Differential Diagnosis) may be considered. Note: (1) The genes included in the panel and the diagnostic sensitivity of the testing used for each gene vary by laboratory and are likely to change over time. (2) Some multigene panels may include genes not associated with the condition discussed in this *GeneReview*; thus, clinicians need to determine which multigene panel is most likely to identify the genetic cause of the condition while limiting identification of variants of uncertain significance and pathogenic variants in genes that do not explain the underlying phenotype. (3) In some laboratories, panel options may include a custom laboratory-designed panel and/or custom phenotype-focused exome analysis that includes genes specified by the clinician. (4) Methods used in a panel may include sequence analysis, deletion/duplication analysis, and/or other non-sequencing-based tests.

For an introduction to multigene panels click [here](#). More detailed information for clinicians ordering genetic tests can be found [here](#).



Nature Reviews | Endocrinology

Figure 1. Flow chart for investigation and diagnosis of Silver-Russell Syndrome

This figure was adapted (legends not included) from Wakeling et al [2017], which was published under a Creative Commons Attribution 4.0 International License.

Note

Approximately 40% of individuals who undergo molecular testing after scoring four of six on the Netchine-Harbison scoring system will have nondiagnostic laboratory studies. **For individuals in this group, a clinical diagnosis of SRS can be established if: (a) two of the four clinical findings identified are prominent forehead/frontal bossing and relative macrocephaly at birth; and (b) other disorders have been ruled out** [Wakeling et al 2017] (see Differential Diagnosis).

Table 1. Molecular Genetic Testing Used in Russell-Silver Syndrome

Method	Pathogenic Variants/Alterations Detected		Proportion of SRS Alterations Detected ¹
Methylation analysis ²	Chr11	Loss of methylation at <i>H19/IGF2</i> (paternal) ³	~35%-50% ⁴
		Somatic mosaicism for maternal UPD11 ^{5, 6}	Rare
		Duplication of 11p15.5 (maternal)	Unknown ^{7, 8}
	Chr7	Maternal UPD7 ⁹	~7%-10% ¹⁰
		Microdeletions, microduplications, mosaic trisomy ⁷	Rare ¹¹
Microarray (SNP based)	Chr11	Duplication of 11p15.5 (maternal)	Unknown ^{7, 8}
		Somatic mosaicism for maternal UPD11 ^{5, 6}	Rare ¹²
	Chr7	Microdeletions or microduplications of 7p, mosaic trisomy ⁷	Rare ^{11, 13, 14}
		Maternal UPD7	Maternal isodisomy 7 only ¹⁵
STR marker analysis	Chr11	Somatic mosaicism for maternal UPD11 ^{5, 6}	Rare
	Chr7	Maternal UPD7 ⁹	~7%-10% ¹⁰
Karyotype	Inversion or translocation of 11p15.5		Rare ^{5, 6}
Sequence analysis ¹⁶ / gene-targeted deletion/duplication analysis ¹⁷	<i>CDKN1C</i> (maternal transmission)		1 family reported ¹⁸
	<i>IGF2</i> (paternal transmission)		A few cases reported ¹⁹
	<i>PLAG1</i>		Rare ²⁰
	<i>HMGA2</i>		Rare ²¹

Table 1. continued from previous page.

Method	Pathogenic Variants/Alterations Detected	Proportion of SRS Alterations Detected ¹
Unknown		30%-40% ²²

1. See Molecular Genetics for information on variants/alterations detected.
2. Assays developed to be methylation sensitive such as multiplex ligation probe analysis (MS-MLPA), quantitative PCR (MS-qPCR), or Southern blotting (mainly historical testing) allow detection of epigenetic and genomic alterations of 11p15.5. Methylation-sensitive assays can diagnose RSS resulting from DNA methylation alterations, microdeletions and microduplications, or uniparental disomy (UPD). Interpretation of methylation data should take into account results of copy number testing because copy number variants that alter the relative dosage of parental contributions (e.g., paternal duplication) are associated with abnormal methylation status. Note that MLPA testing may be followed by microarray testing to define breakpoints of deletions or duplications. Other methods to confirm maternal UPD at 11p15.5 include short tandem repeat (STR) analysis or SNP analysis [Keren et al 2013].
3. A small number of individuals have hypomethylation of only *H19* or *IGF2* [Bartholdi et al 2009].
4. False negatives may occur as a result of mosaicism, as 11p15.5 hypomethylation occurs post fertilization. Testing of tissue from a second source (e.g., buccal cells or fibroblasts) should be performed.
5. Bullman et al [2008]
6. Luk et al [2016a]
7. Fisher et al [2002], Eggermann et al [2005], Schönherr et al [2007]
8. Heide et al [2018]
9. Both isodisomy and heterodisomy [Bernard et al 1999, Price et al 1999] as well as segmental maternal UPD [Hannula et al 2001, Eggermann 2008] have been reported. Mosaicism has been observed in cases of maternal UPD7 and other chromosome 7 rearrangements; therefore, testing of an alternate tissue source may be appropriate [Reboul et al 2006].
10. Hannula et al [2001], Kim et al [2005]
11. Courtens et al [2005], Flori et al [2005], Font-Montgomery et al [2005]
12. Luk et al [2016b] described one group of 28 individuals with SRS who had UPD11.
13. A *de novo* duplication of 7p11.2-p13 on the maternal allele containing *GRB10*, *GFBP1*, and *GFBP3* has been reported [Monk et al 2000].
14. A *de novo* deletion of 7q32.2 on the paternal allele including *MEST* has been reported [Carrera et al 2016].
15. Note: SNP array analysis will detect maternal UPD only in cases of isodisomy; 28.8% of maternal UPD7 (2%-3% of all cases of SRS) are a result of isodisomy [Chantot-Bastaraud et al 2017].
16. Sequence analysis detects variants that are benign, likely benign, of uncertain significance, likely pathogenic, or pathogenic. Variants may include small intragenic deletions/insertions and missense, nonsense, and splice site variants; typically, partial-, whole-, or multigene deletions/duplications are not detected. For issues to consider in interpretation of sequence analysis results, click [here](#).
17. Gene-targeted deletion/duplication analysis detects intragenic deletions or duplications. Methods used may include a range of techniques such as quantitative PCR, long-range PCR, multiplex ligation-dependent probe amplification (MLPA), and a gene-targeted microarray designed to detect single-exon deletions or duplications.
18. One four-generation family segregating a *CDKN1C* gain-of-function pathogenic variant has been described [Brioude et al 2013].
19. One family with SRS and a paternally transmitted *IGF2* loss-of-function variant has been reported by Begemann et al [2015] and a few others have been reviewed by Tümer et al [2018].
20. Loss-of-function *PLAG1* variants were identified in two familial and one simplex case [Abi Habib et al 2018].
21. Loss-of-function *HMGA2* variants were identified in two simplex cases [Abi Habib et al 2018].
22. Approximately 40% of individuals who undergo molecular testing after scoring four of six on the Netchine-Harbison scoring system will have nondiagnostic laboratory studies. See **Note**.

Clinical Characteristics

Clinical Description

Silver-Russell Syndrome (SRS) is typically characterized by asymmetric gestational growth restriction resulting in affected individuals being born small for gestational age with relative macrocephaly at birth (head circumference ≥ 1.5 SD above birth weight and/or length), prominent forehead usually with frontal bossing, and frequently body asymmetry. This is followed by postnatal growth failure, and in some cases progressive limb length discrepancy and severe feeding difficulties in the first years of life. Additional clinical features include triangular facies, fifth-finger clinodactyly, and micrognathia with narrow chin. Except for the limb length

asymmetry, the growth failure is proportionate with normal head growth. The average adult height in untreated individuals is $\sim 3.1 \pm 1.4$ SD below the mean.

SRS is an etiologically heterogeneous condition. In the recent international consensus statement for diagnosis and management of SRS [Wakeling et al 2017], the Netchine-Harbison Clinical Scoring System [Netchine et al 2007, Azzi et al 2015] was selected as the most sensitive of the compared diagnostic scoring systems.

Netchine-Harbison Clinical Scoring System (NH-CSS) [Azzi et al 2015]:

- Small for gestational age (birth weight and/or length ≤ 2 SD for gestational age)
- Postnatal growth failure (length/height ≥ 2 SD below the mean at 24 months)
- Relative macrocephaly at birth (head circumference > 1.5 SD above birth weight and/or length)
- Frontal bossing or prominent forehead (Forehead projecting beyond the facial plane on a side view as a toddler [1–3 years])
- Body asymmetry (limb length discrepancy ≥ 0.5 cm, or < 0.5 cm with ≥ 2 other asymmetric body parts)
- Feeding difficulties or BMI ≤ 2 SD at 24 months or current use of a feeding tube or cyproheptadine for appetite stimulation

Clinical diagnosis is made when an infant meets at least four of the clinical criteria, two of which must be relative macrocephaly at birth and frontal bossing. In older children and adults, the facial features can evolve and the prominent forehead can disappear. Therefore, in order to be able to use the NH-CSS in older children and adults, the prominence of the forehead needs to be assessed in childhood and profile photographs taken of the individual at around age two years.

Individuals with SRS typically have additional supportive clinical findings, including the following:

- Delayed closure of anterior fontanelle
- Triangular face
- Micrognathia
- Dental crowding
- Down-turned corners of the mouth
- High pitched voice
- Diminished muscle mass
- Shoulder dimples
- Hypoplastic elbow joints
- Fifth-finger clinodactyly and/or brachydactyly
- Scoliosis
- Excessive sweating
- Fasting hypoglycemia
- Speech delay
- Motor delay
- Genitourinary anomalies

Growth. The earliest manifestation of SRS is abnormal growth. Most children are born small for gestational age with birth weight and/or length ≥ 2 SD below the mean. Although growth velocity may be within the normal range, children with SRS rarely show significant catch-up growth. At age two years, most children with SRS remain > 2 SD below the mean for length unless the parents are tall. Growth charts for European children with SRS have been published [Wollmann et al 1995]. Growth charts for North American children with the Wollmann data superimposed are available from the [MAGIC Foundation](#) (accessed 5-22-20).

In two European series of untreated adults with SRS, height ranged from 3.7 to 3.5 SD below the mean for males and 4.2 to 2.5 SD below the mean for females [Wollmann et al 1995, Binder et al 2013]. Except for the limb

length asymmetry, the growth failure is proportionate, with normal head growth. Most children diagnosed clinically as having SRS who demonstrated catch-up growth in later childhood had conditions other than classic SRS [Saal et al 1985].

See Management for use of growth hormone therapy to influence growth in children with SRS. Note: Many children with SRS do not achieve normal stature even with administration of human growth hormone if rapid bone age advancement during puberty is not managed.

Other endocrinologic issues can include premature adrenarche, early puberty, and insulin resistance, which can contribute to a reduced final height even after treatment with growth hormone.

Skeletal abnormalities may include:

- Limb length asymmetry, caused by hemihypotrophy with diminished growth of the affected side;
- Fifth-finger clinodactyly and/or brachydactyly, among the most frequently described skeletal anomalies (albeit minor) in individuals with SRS;
- Scoliosis, which has been reported in some studies in up to 36% of individuals with SRS [Abraham et al 2004]. A more recent study identified scoliosis or kyphosis in 21% of individuals; 18% required corrective surgery [Yamaguchi et al 2015].

Neurodevelopment. Besides the growth issues, neurodevelopment is of great concern to parents. Evidence shows that children with this condition are at increased risk for developmental delay (both motor and cognitive) and learning disabilities.

In a review of a large cohort of children with SRS with either 11p15 methylation defects or maternal UPD7, developmental delay was seen in 34% of individuals, the majority of whom had mild delays. Developmental delays were more commonly seen in those with maternal UPD7 than in those with 11p15 methylation defects (65% vs 20%). Speech delays were common in both groups [Wakeling et al 2010]. Further studies of individuals with molecularly confirmed SRS and early appropriate clinical management are needed to give a more accurate cognitive prognosis.

Feeding disorders and hypoglycemia. Children with SRS have little subcutaneous fat and often have poor appetites, oral motor problems, and feeding disorders [Fuke et al 2013]. They are at risk for hypoglycemia, especially associated with any prolonged fast [Wakeling et al 2017]. In a study of children with SRS, contributing factors for hypoglycemia included reduced caloric intake, often secondary to poor appetite and feeding; reduced body mass; and, in several children, growth hormone deficiency [Azcona & Stanhope 2005]. While most children had clinical symptoms of hypoglycemia, several were asymptomatic.

Diaphoresis in early childhood may be associated with hypoglycemia, although diaphoresis may often occur in the absence of hypoglycemia in children with SRS [Stanhope et al 1998].

Gastrointestinal disorders are common and problems include gastroesophageal reflux disease, esophagitis, food aversion, vomiting, constipation and failure to thrive. One large study documented gastrointestinal problems in 77% of children, and 55% of children had severe gastroesophageal reflux, which may have an atypical presentation without vomiting in this group of children [Marsaud et al 2015]. Reflux esophagitis should be suspected in children with either food aversion or aspiration.

Craniofacial anomalies are common. Some individuals with SRS have Pierre Robin sequence and cleft palate. Within a group of individuals with SRS, Wakeling et al [2010] found cleft palate or bifid uvula in 7% of those with 11p15.5 methylation defects and in no individuals with maternal UPD7. Those individuals with Pierre Robin sequence should be monitored for obstructive apnea.

Dental and oral abnormalities are common. Microdontia, high-arched palate, and dental crowding secondary to the relative micrognathia and small mouth have been reported [Orbak et al 2005, Wakeling et al 2010]. Overbite and dental crowding appear to be the most common orofacial manifestation [Hodge et al 2015]

Poor oral hygiene in the presence of dental crowding can lead to increased risk for dental caries.

Genitourinary problems have been observed. The most common anomalies are hypospadias and cryptorchidism in males [Bruce et al 2009, Wakeling et al 2017]. Mayer-Rokitansky-Kuster-Hauser syndrome (associated with underdeveloped or absent vagina and uterus with normal appearance of the external genitalia) has been reported in females [Bruce et al 2009, Abraham et al 2015]. Renal anomalies are not common; however, horseshoe kidney and renal dysplasia have been reported [Wakeling et al 2010].

Heart defects are uncommon, but have been reported in larger studies [Wakeling et al 2010] and smaller case series [Ghanim et al 2013]. The prevalence of heart defects may be as high as 5.5% [Ghanim et al 2013].

Genotype-Phenotype Correlations

Using methylation-sensitive restriction enzymes *HpaII* or *NotI* to measure the degree of methylation of *H19*, Bruce et al [2009] developed a scale of extreme *H19* hypomethylation, moderate *H19* hypomethylation, normal *H19* methylation, and maternal UPD7 (normal *H19* methylation). They determined that children with SRS with extreme *H19* hypomethylation (i.e., ≥ 6 SD below the mean or $< 9\%$ methylation) were more likely to have more severe skeletal manifestations (including radiohumeral dislocation, syndactyly, greater limb asymmetry, and scoliosis) than children with SRS with moderate hypomethylation and those with maternal UPD7.

A study by Wakeling et al [2010] compared clinical features of children with SRS caused by 11p15.5 ICR1 IGF2/*H19* methylation defects to those with maternal UPD7. They found fifth-finger clinodactyly and congenital anomalies were more frequent in children with 11p 15.5 ICR1 hypomethylation than in those with maternal UPD7, whereas learning difficulties and speech disorders were more frequent in children with maternal UPD7 than in those with ICR1 hypomethylation.

Children with SRS with maternal UPD7 had more gain in height with growth hormone therapy compared to children with 11p15.5 epimutations, possibly because children with 11p15.5 methylation abnormalities showed elevated levels of insulin-like growth factor I (product of *IGF1*) and therefore a degree of IGF1 resistance; children with SRS with maternal UPD7 had response characteristics similar to other children who were small for gestational age [Binder et al 2008].

Prevalence

The prevalence is unknown and was previously estimated at 1:30,000-1:100,000 (A Toutain, [Orphanet](#)). A recent retrospective study conducted in Estonia estimated the minimum prevalence of SRS at birth as 1:15,886 [Yakoreva et al 2019].

Genetically Related (Allelic) Disorders

Table 2 includes other phenotypes caused by pathogenic variants in the gene(s) associated with Silver-Russell syndrome.

Table 2. Allelic Disorders

Molecular Alteration ¹	Phenotype ¹
Abnormal regulation of gene transcription in the imprinted domain on chr 11p15.5 (i.e., the BWS critical region) or maternally inherited loss-of-function pathogenic variant in <i>CDKN1C</i>	Beckwith-Wiedemann syndrome

Table 2. continued from previous page.

Molecular Alteration ¹	Phenotype ¹
Molecular alterations at chr 11p15 incl loss of methylation at ICR2, gain of methylation at ICR1, ² & 11p15 paternal UPD ³	Isolated hemihyperplasia
Somatic mosaicism for loss of methylation at the paternal ICR1 ⁴	Isolated hemihypoplasia
Constitutional alterations of chr 11p15.5 incl hypermethylation at ICR1, paternal UPD of 11p15.5, & genomic abnormalities incl microdeletion & microinsertion ⁵	Isolated Wilms tumor
Maternally inherited gain-of-function pathogenic variant in <i>CDKN1C</i>	IMAGe syndrome

chr = chromosome; UPD = uniparental disomy

1. See hyperlinked *GeneReview* or cited reference for more information.

2. Martin et al [2005]

3. Shuman et al [2002]

4. Zeschnigk et al [2008], Eggermann et al [2009]

5. Scott et al [2008]

Differential Diagnosis

Intrauterine growth restriction and short stature. The differential diagnosis of Silver-Russell syndrome (SRS) includes any condition that can cause intrauterine growth restriction and short stature. The presence of disproportionate short stature excludes the diagnosis of SRS and suggests a diagnosis of skeletal dysplasia. A skeletal survey can be performed to exclude a skeletal dysplasia that may mimic SRS. Note: Bone age may be delayed in children with SRS; however, delayed bone age is a nonspecific finding frequently seen in children with intrauterine growth restriction of many etiologies.

Chromosome abnormalities. Many conditions caused by a chromosome imbalance can be associated with small size for gestational age and poor postnatal growth, leading to a misdiagnosis of SRS. Chromosome microarray, preferably using a SNP-based platform, can be helpful for identifying microdeletions and microduplications as well as regions of homozygosity, giving potential clues to uniparental chromosomal disomy, and rare recessive disorders in the cases of consanguinity [Grote et al 2014]. Uniparental disomy for several chromosomes have been reported to cause an SRS-like phenotype, including chromosomes 6, 14 (Temple syndrome), 16, and 20 [Sachwitz et al 2016, Wakeling et al 2017, Geoffron et al 2018].

Microcephaly. Individuals with SRS have a normal head circumference or relative macrocephaly. The presence of a significant microcephaly should lead to a search for an alternative etiology.

Table 3 summarizes disorders to consider in the differential diagnosis of Silver-Russell syndrome.

Table 3. Other Disorders with IUGR and Poor Postnatal Growth to Consider in the Differential Diagnosis of Silver-Russell Syndrome

	Disorder	Gene(s)	MOI	Additional Clinical Features of This Disorder	
				Overlapping w/SRS	Distinguishing from SRS
Monogenic disorders	Three M syndrome	<i>CCDC8</i> <i>CUL7</i> <i>OBSL1</i>	AR	<ul style="list-style-type: none"> Clinodactyly Frontal bossing Relative macrocephaly Triangular facies 	<ul style="list-style-type: none"> Pectus excavatum Rib hypoplasia Short neck
	IMAGe syndrome	<i>CDKN1C</i>	AD ¹	<ul style="list-style-type: none"> Frontal bossing Macrocephaly 	<ul style="list-style-type: none"> Adrenal hypoplasia Adrenal insufficiency Metaphyseal dysplasia

Table 3. continued from previous page.

	Disorder	Gene(s)	MOI	Additional Clinical Features of This Disorder	
				Overlapping w/SRS	Distinguishing from SRS
	Bloom syndrome	<i>BLM</i>	AR	<ul style="list-style-type: none"> • Triangular facies • 5th-finger clinodactyly • Café au lait spots 	<ul style="list-style-type: none"> • Abnormal sister chromatid exchange • Dolichocephaly • Microcephaly
	Nijmegen breakage syndrome	<i>NBN</i>	AR	Café au lait spots	<ul style="list-style-type: none"> • Chr instability • Microcephaly • Sloping forehead • Telangiectasia
	Warsaw breakage syndrome (OMIM 613398)	<i>DDX11</i>	AR	5th-finger clinodactyly	<ul style="list-style-type: none"> • Chr instability • Deafness • Microcephaly • Sloping forehead • Epicanthal folds
	Fanconi anemia	>20 genes ²	AR AD XL	Café au lait spots	<ul style="list-style-type: none"> • Chr instability • Absent thumb(s) or thumb hypoplasia • Microcephaly • Radial anomalies • ↑ malignancy risk
	Meier-Gorlin syndrome (OMIM 224690)	<i>CDC45</i> <i>CDC6</i> <i>CDT1</i> <i>GMNN</i> <i>MCM5</i> <i>ORC1</i> <i>ORC4</i> <i>ORC6</i>	AR AD	Frontal bossing	<ul style="list-style-type: none"> • Absent patellae • Microcephaly • Microtia • Small mouth
	Insulin growth factor 1 resistance (incl deletion 15q26.1) ³	<i>IGF1R</i>	AR AD	<ul style="list-style-type: none"> • Clinodactyly • Dental anomalies 	<ul style="list-style-type: none"> • Global DD • Microcephaly • Synophrys
Chromosome abnormalities	Diploid/triploid mixoploidy ⁴			Limb asymmetry	<ul style="list-style-type: none"> • Global DD • Microcephaly
	Temple syndrome (maternal UPD14, paternal chr 14 deletion or loss of methylation at 14q32) (OMIM 616222)			Many features overlap w/ SRS.	<ul style="list-style-type: none"> • Distinguished by genetic testing ⁵ • Similar phenotype

Table 3. continued from previous page.

	Disorder	Gene(s)	MOI	Additional Clinical Features of This Disorder	
				Overlapping w/SRS	Distinguishing from SRS
Teratogenic disorder	Fetal alcohol syndrome			<ul style="list-style-type: none"> • Small for gestational age • Postnatal growth failure • 5th-finger clinodactyly 	<ul style="list-style-type: none"> • Microcephaly • Hypoplastic philtrum • History of in utero exposure to alcohol • Short palpebral fissures

AD = autosomal dominant; AR = autosomal recessive; Chr = chromosome; DD = developmental delay; IUGR = intrauterine growth restriction; MOI = mode of inheritance; XL = X-linked

1. Typically a *CDKN1C* pathogenic variant causing IMAGE syndrome is inherited in an autosomal dominant manner; however, only maternal transmission of the pathogenic variant results in IMAGE syndrome.
2. Fanconi anemia is associated with pathogenic variants involving *BRCA2*, *BRIPI*, *ERCC4*, *FANCA*, *FANCB*, *FANCC*, *FANCD2*, *FANCE*, *FANCF*, *FANCG*, *FANCI*, *FANCL*, *FANCM*, *MAD2L2*, *PALB2*, *RAD51*, *RAD51C*, *RFWD3*, *SLX4*, *UBE2T*, or *XRCC2*.
3. Bruce et al [2009], Ocaranza et al [2017]
4. Graham et al [1981]
5. Ioannides et al [2014], Kagami et al [2015], Geoffron et al [2018]

Management

Evaluations Following Initial Diagnosis

To establish the extent of disease in an individual diagnosed with Silver-Russell syndrome (SRS), the following evaluations are recommended if they have not already been completed:

- Assessment and plotting of growth curves. See the [MAGIC Foundation](#).
- Physical examination for evaluation of possible limb length asymmetry, genitourinary anomalies, scoliosis, precocious or early-onset puberty, and oral and craniofacial abnormalities
- Consultation with a pediatric endocrinologist
- Consultation with a pediatric gastroenterologist and dietician
 - For children suspected of having gastroesophageal reflux disease (GERD), evaluation for esophagitis including video swallow studies, gastric emptying studies pH probe, and endoscopy.
 - Intestinal malrotation has been reported in children with SRS and needs to be ruled out in those who have feeding disorders, constipation and delayed gastric emptying.
- Screening assessment of neurocognitive development, speech and language, and muscle tone
- Consultation with a clinical geneticist and/or genetic counselor

Treatment of Manifestations

SRS leads to a wide spectrum of abnormal physical characteristics and functional abnormalities.

Multidisciplinary follow up and early, specific, interventions are necessary for optimal management of individuals with SRS. The multidisciplinary team should be composed of pediatric subspecialists including an endocrinologist, gastroenterologist, dietician, clinical geneticist and genetic counselor, craniofacial team, orthopedic surgeon, neurologist, speech and language therapist, and psychologist

Growth and use of growth hormone. Children with any condition associated with body differences and/or short stature are often sensitive about body image. These factors can play a significant role in self-image, peer relationships, and socialization. Thus, early referral to a pediatric endocrinologist is essential for children with SRS.

- **Growth hormone therapy** in children with intrauterine growth restriction of all causes has significantly improved growth and final height, especially in those children who do not experience catch-up growth [Dahlgren et al 2005, Jensen et al 2014, Zanelli & Rogol 2018]. Specifically, children with SRS have benefited from growth hormone supplementation [Toumba et al 2010, Binder et al 2013].
 - Smeets et al [2016] found that height gain in children with SRS treated with growth hormone was similar to that in children who did not have SRS, although final heights were less in the SRS population because their heights were lower at the initiation of treatment [Smeets et al 2016].
 - The goals of GH treatment are, of course, to improve growth velocity but also to improve body composition (especially lean body mass), psychomotor development, and appetite; to reduce the risk of hypoglycaemia; and to optimize linear growth [Wakeling et al 2017].
 - A study by Rizzo et al [2001] demonstrated significant increase in height in children with SRS treated with growth hormone, but without a change in body or limb asymmetry
 - Such treatment is best undertaken in a center with experience in managing growth disorders.
- **Growth hormone deficiency.** Treatment with human growth hormone is necessary in the presence of documented growth hormone deficiency. However, growth hormone deficiency is not common in SRS [Wakeling et al 2017].
 - Treatment with growth hormone in SRS is indicated and not altered even in the presence of growth hormone deficiency.
 - Testing for growth hormone deficiency by fasting is contraindicated because of the risk for inducing hypoglycemia [Wakeling et al 2017].
- **Bone age advancement and puberty.** Monitoring for signs of premature adrenarche, fairly early and accelerated central puberty, and insulin resistance is very important in individuals with SRS. Personalized treatment with GnRH analogs for at least two years in children with evidence of central puberty (starting no later than age 12 years in girls and age 13 years in boys) can be considered to preserve adult height potential [Wakeling et al 2017].

Hypoglycemia should be prevented and aggressively managed if present.

- Monitoring for urinary ketones after prolonged fasting (including when infants start sleeping through the night) or excess physical activity or with illness
- Frequent feeding; avoidance of long fasting between feeds (in infants: ≤ 4 hours)
- Use of complex carbohydrates

Gastrointestinal disorders should be treated early and adequately. It is critical that attention to growth and nutrition begin in infancy. Infants with SRS usually have poor muscle mass and often have feeding difficulties in addition to inherent growth disturbance. In one study gastrointestinal issues, feeding disorders, and/or malnutrition were seen in 70% of individuals [Marsaud et al 2015]. Therefore, aggressive feeding measures are often required, but there must be careful monitoring to avoid too rapid a rate of postnatal weight catch up, which has been associated with subsequent increased metabolic risk.

Recommended strategies include:

- Use of nutritional and caloric supplements;
- Treatment of gastroesophageal reflux with appropriate medications, including proton pump inhibitors and H-2 histamine blockers;
- Speech or occupational therapy for oral motor problems and feeding aversion;
- The use of cyproheptadine, an appetite stimulant which has been shown to have a positive effect on weight and growth velocity [Lemoine et al 2018];
- Use of enteral feeding with gastrostomy or jejunostomy to address extreme cases of feeding aversion and/or gastroesophageal reflux with or without fundoplication limited to extreme cases where other

measures have been unsuccessful [Wakeling et al 2017]. With non-volitional feeding, too rapid and excessive weight gain must be avoided.

Skeletal abnormalities. The most common orthopedic problem is limb length discrepancy, which often can be several centimeters and involve upper and/or lower extremities. Functionally, this is most significant for lower extremity asymmetry because of the impact on gait. Lower limb length discrepancy exceeding 2 cm can lead to compensatory scoliosis and thus requires intervention. Initial treatment can include the use of a shoe lift. In older children, limb lengthening with distraction osteogenesis has become a more widely applied procedure. When single segment limb lengthening is sufficient, the limb lengthening is generally done prior to completion of growth but close to final height with femoral internal distracters [Goldman et al 2013]. For young children with leg length discrepancy greater than 4 cm, lengthening is done in the lower segment (tibia) with external fixators [Goldman et al 2013].

Scoliosis and kyphosis are a common problem in SRS [Yamaguchi et al 2015]. The relationship of lower limb length asymmetry to scoliosis is not clear, but many children with limb length asymmetry will develop a compensatory scoliosis. Treatment with monitoring and bracing initially is indicated. Many individuals will need corrective surgery [Yamaguchi et al 2015].

Neurodevelopment

- For infants with hypotonia, referral to an early-intervention program and physical therapy
- For children with evidence of delay, referral for early intervention, speech and language therapy, and occupational and physical therapy as indicated.
- For school-age children, working with the school system to address learning disabilities through appropriate neuropsychological testing and an individualized educational plan, including therapeutic interventions as indicated
- Referral for psychological counseling as needed to address psychosocial and body image issues

Craniofacial anomalies. For those children with severe micrognathia, cleft palate, or complex dental relationships, management by a multidisciplinary cleft palate and craniofacial team is recommended. Early dental care, orthodontia for dental crowding, and maxillofacial surgery may be needed for older children once growth is completed.

Otherwise, dental hygiene and dental crowding can be appropriately managed in a routine manner by pediatric dentists and orthodontists.

Genitourinary abnormalities. Cryptorchidism and hypospadias is best managed by a pediatric urologist.

Males with micropenis and females with internal genitourinary anomalies (some are born with Mayer-Rokitansky-Kuster-Hauser syndrome) benefit from referral to a multidisciplinary disorders of sex development (DSD) center.

Surveillance

Monitoring guidelines of children with SRS has been well outlined in the international consensus statement for diagnosis and management of SRS [Wakeling et al 2017].

The following are appropriate:

- Monitoring of growth with special attention to growth velocity and excessive weight gain
- Monitoring of urine ketones and blood glucose for ketotic hypoglycemia is of major importance especially in infancy and in older children with a large head circumference, lean body habitus, and poor appetite. Monitoring urine ketones to prevent hypoglycemia should be performed in infants when frequency of

feeding is being reduced, in all children who are acutely ill with decreased feeding or have fevers, and in older children at times of increased physical activity.

- At each well-child visit in early childhood, examination and measurement of limb length discrepancy. Infant lengths should be measured for both legs, both lengths recorded, and the longer entered on a growth curve. For measuring height in older children, an appropriate-sized lift sufficient to level the hips should be placed under the foot of the shorter lower extremity.
- Examination for presence or scoliosis at each visit
- Monitoring for early and aggressive adrenarche and early onset of central puberty because of the risk of rapid bone age advancement and reduced final height despite a long course of GH therapy
- Close monitoring for developmental delays, especially motor and speech and language development

Agents/Circumstances to Avoid

Avoid prolonged fasting in infants and young children because of the risk for hypoglycemia.

Avoid elective surgery whenever possible. If surgery is unavoidable, physicians must be aware of the risk for hypoglycemia, hypothermia, difficult healing, and difficult intubation (due to abnormal tooth distribution and small mandible, which affect airway visualization and intubation process).

Evaluation of Relatives at Risk

See Genetic Counseling for issues related to testing of at-risk relatives for genetic counseling purposes.

Therapies Under Investigation

Search [ClinicalTrials.gov](https://clinicaltrials.gov) in the US and [EU Clinical Trials Register](https://clinicaltrialsregister.eu) in Europe for access to information on clinical studies for a wide range of diseases and conditions. Note: There may not be clinical trials for this disorder.

Genetic Counseling

Genetic counseling is the process of providing individuals and families with information on the nature, mode(s) of inheritance, and implications of genetic disorders to help them make informed medical and personal decisions. The following section deals with genetic risk assessment and the use of family history and genetic testing to clarify genetic status for family members; it is not meant to address all personal, cultural, or ethical issues that may arise or to substitute for consultation with a genetics professional. —ED.

Mode of Inheritance

In most families, a proband with Silver-Russell syndrome (SRS) represents a simplex case (a single affected family member) and has SRS as the result of an apparent *de novo* epigenetic or genetic alteration (e.g., loss of paternal methylation at the H19/IGF2 imprinting center 1 or maternal uniparental disomy for chromosome 7). SRS may also occur as the result of a genetic alteration associated with an up to 50% recurrence risk (e.g., a copy number variant on chromosome 7 or 11 or an intragenic pathogenic variant in *CDKN1C*, *IGF2*, *PLAG2*, or *HMGGA2*) depending on the nature of the genetic alteration and the sex of the transmitting parent. Accurate assessment of SRS recurrence therefore requires identification of the causative genetic mechanism in the proband.

Risk to Family Members

Table 4. Recurrence Risk in Sibs of a Proband and Offspring of a Proband

Chromosome / Imprinted Region / Gene	Genetic Alteration	Recurrence Risk	
		Sibs of a proband	Offspring of a proband
11p15.5 ICR1 <i>H19/IGF2</i> regions	Hypomethylation (paternal)	Low ^{1, 2, 3, 4}	Low, but empiric data not available ⁵
Chromosome 11p15.5	Somatic mosaicism for maternal UPD11	<1%	Low, but empiric data not available
	CNV ⁶	≤50% ^{5, 7, 8}	50%
Chromosome 7	Maternal UPD7 ⁹	<1% ¹⁰	Low ¹⁰
	Microdeletions, microduplications	0 to 50% depending on parental carrier status	50% for affected females; 0% for affected males (but may have a different abnormal phenotype)
	Mosaic trisomy 7	Low	Low, but empiric data not available
<i>CDKN1C</i>	Intragenic pathogenic variant ¹¹	0 or 50% ¹²	50% if proband is female; 0% if proband is male
<i>IGF2</i>		0 or 50% ¹³	50% if proband is male; 0% if proband is female
<i>PLAG1</i>		0 or 50% ¹⁴	50%
<i>HMGA2</i>			

Adapted from Eggermann et al [2016], Table 1

ICR1 = imprinting control region 1; UPD = uniparental disomy

1. In 7%-25% of cases of epimutations, multilocus imprinting disturbances (MLID) can be detected and in single MLID cases, monogenic pathogenic variants have been reported.

2. Bartholdi et al [2009] reported a father and daughter with SRS, both of whom have a methylation defect at H19/IGF2 ICR1.

3. Germline mosaicism is presumed to be present in the unaffected fathers in two families in which epigenetic pathogenic variants were identified in sibs [Bartholdi et al 2009].

4. Begemann et al [2015]

5. Depending on the type of chromosomal aberration, the size of the affected fragment, and the sex of the contributing parent, a risk of up to 50% can be delineated.

6. Chromosome anomalies, such as unbalanced translocations involving 11p15.5 as well as paternal microdeletions or maternal microduplications of chromosome 11p15.5 including *CDKN1C*.

7. Abi Habib et al [2017] reported a familial case with hypomethylation caused by paternally transmitted 11p15.5 ICR1 deletion with father and his children affected. They estimated that such deletions are present in approximately 1% of individuals with SRS due to ICR1 hypomethylation.

8. Heide et al [2018] reported a maternally inherited 11p15.5 ICR2 duplication including *CDKN1C*.

9. A karyotype should be performed to rule out a translocation

10. One case with maternal UPD7 based on a familial translocation involving chromosome 7 has been described. The risk for recurrence in sibs and for children of proband is low if a chromosome translocation has been ruled out.

11. Maternally transmitted *CDKN1C* pathogenic variant [Brioude et al 2013]; paternally transmitted *IGF2* pathogenic variant; or *PLAG1* or *HMGA2* pathogenic variant transmitted by either parent [Abi Habib et al 2018].

12. 0% in cases of a *de novo* pathogenic variant or paternal transmission, 50% in cases of a maternal transmission.

13. 0% in cases of a *de novo* pathogenic variant or maternal transmission, 50% in cases of a paternal transmission.

14. 0% in cases of a *de novo* pathogenic variant; 50% in cases of a parental transmission.

Related Genetic Counseling Issues

DNA banking. Because it is likely that testing methodology and our understanding of genes, pathogenic mechanisms, and diseases will improve in the future, consideration should be given to banking DNA from probands in whom a molecular diagnosis has not been confirmed (i.e., the causative pathogenic mechanism is unknown).

Prenatal Testing and Preimplantation Genetic Testing

Loss of paternal methylation at the 11p15.5 *ICR1 H19/IGF2* regions. Reliable testing for loss of paternal methylation at the 11p15.5 *ICR1 H19/IGF2* regions is not possible, since studies show that differentially methylated regions are not firmly established by the gestational age (10-12 weeks) at which chorionic villus sampling (CVS) is performed [Paganini et al 2015]. Additionally, there have been no validated studies establishing reliable testing for differential methylation patterns in amniocytes. Since the majority of epigenetic pathogenic variants can be mosaic, reliable prenatal testing becomes even more challenging [Eggermann et al 2016].

Maternal uniparental disomy (UPD). Maternal UPD7 can be diagnosed prenatally. Maternal isodisomy 7 can be diagnosed with SNP chromosomal microarray (CMA). Maternal heterodisomy 7 can be diagnosed by analyzing fetal SNP CMA and comparing it to SNP CMA of both parents.

Chromosome anomalies. If a causative chromosome anomaly (e.g., an unbalanced translocation involving 11p15.5, a paternal microdeletion, or a maternal microduplication of chromosome 11p15.5 including *CDKN1C*) has been identified in the proband, prenatal testing with SNP CMA on fetal cells obtained by CVS or amniocentesis is possible. Preimplantation genetic testing can also be offered with a known chromosome anomaly depending on the size of the duplication or deletion.

Intragenic pathogenic variants. A known familial maternally inherited *CDKN1C* pathogenic variant, paternally inherited *IGF2* pathogenic variant, or parental pathogenic variant in *PLAG1* or *HMGA2* can be diagnosed using preimplantation genetic testing or prenatally with samples obtained from CVS or amniocentesis [Eggermann et al 2016, Abi Habib et al 2018].

Note: The preimplantation genetic diagnosis or prenatal finding of a genetic alteration consistent with SRS cannot be used to reliably predict clinical outcome [Eggermann et al 2016]; children with SRS demonstrate varying responses to growth hormone, variable late catch-up growth, and variable developmental outcomes.

Differences in perspective may exist among medical professionals and within families regarding the use of prenatal testing, particularly if the testing is being considered for the purpose of pregnancy termination rather than early diagnosis. While most centers would consider use of prenatal testing to be a personal decision, discussion of these issues may be helpful.

Resources

GeneReviews staff has selected the following disease-specific and/or umbrella support organizations and/or registries for the benefit of individuals with this disorder and their families. GeneReviews is not responsible for the information provided by other organizations. For information on selection criteria, click [here](#).

- **Genetic and Rare Diseases Information Center (GARD)**
Phone: 301-251-4925; 888-205-2311
[Russell-Silver syndrome](#)
- **L' AISRS, Associazione Italiana Sindrome di Russell-Silver**

Italy

www.aisrs.it

- **L'ASBL ALICE: Association Libre d'Informations sur la Croissance des Enfants Silver Russell**
Belgium
www.alice.be
- **L'Association Française des Familles touchées par le syndrome de Silver Russell (SSR)**
France
www.silver-russell.fr
- **National Organization for Rare Disorders (NORD)**
Russell Silver Syndrome
- **Silver Russell Syndrome Global Alliance**
www.silverussellsyndrome.org
- **Bundesverband Kleinwüchsige Menschen (BKMF)**
Leinestr. 2
28199 Bremen
Germany
Phone: 49-421-336169-0
Fax: 49-421-336169-18
Email: info@bkmf.de
www.bkmf.de
- **Child Growth Foundation**
United Kingdom
Phone: 0208 995 0257
Email: nfo@childgrowthfoundation.org
www.childgrowthfoundation.org
- **Human Growth Foundation**
www.hgfound.org
- **Little People of America**
Phone: 888-LPA-2001; 714-368-3689
Fax: 707-721-1896
Email: info@lpaonline.org
www.lpaonline.org
- **MAGIC Foundation**
Phone: 800-362-4423; 630-836-8200
Fax: 630-836-8181
Email: contactus@magicfoundation.org
www.magicfoundation.org
- **Silver-Russell Support Group**
c/o Child Growth Foundation
2 Mayfield Avenue
Chiswick WA 1PW
United Kingdom
Phone: 020 8995 0257; 020 8994 7625

Fax: 020 8995 9075

Molecular Genetics

Information in the Molecular Genetics and OMIM tables may differ from that elsewhere in the GeneReview: tables may contain more recent information. —ED.

Table A. Silver-Russell Syndrome: Genes and Databases

Gene	Chromosome Locus	Protein	Locus-Specific Databases	HGMD	ClinVar
<i>CDKN1C</i>		Cyclin-dependent kinase inhibitor 1C	CDKN1C database	CDKN1C	CDKN1C
<i>H19</i>		Unknown	H19 @ LOVD	H19	H19
<i>HMGA2</i>	12q14.3	High mobility group protein HMGI-C	HMGA2 database	HMGA2	HMGA2
<i>IGF2</i>		Insulin-like growth factor II	LOVD - Growth Consortium (IGF2)	IGF2	IGF2
<i>PLAG1</i>	8q12.1	Zinc finger protein PLAG1	PLAG1 database	PLAG1	PLAG1
Unknown	Chromosome 7	Unknown			

Data are compiled from the following standard references: gene from [HGNC](#); chromosome locus from [OMIM](#); protein from [UniProt](#). For a description of databases (Locus Specific, HGMD, ClinVar) to which links are provided, click [here](#).

Table B. OMIM Entries for Silver-Russell Syndrome ([View All in OMIM](#))

103280	H19, IMPRINTED MATERNALLY EXPRESSED NONCODING TRANSCRIPT; H19
147470	INSULIN-LIKE GROWTH FACTOR II; IGF2
180860	SILVER-RUSSELL SYNDROME 1; SRS1
600698	HIGH MOBILITY GROUP AT-HOOK 2; HMGA2
600856	CYCLIN-DEPENDENT KINASE INHIBITOR 1C; CDKN1C
603026	PLAG1 ZINC FINGER PROTEIN; PLAG1
618905	SILVER-RUSSELL SYNDROME 2; SRS2
618907	SILVER-RUSSELL SYNDROME 4; SRS4
618908	SILVER-RUSSELL SYNDROME 5; SRS5

Molecular Pathogenesis

Chromosome 11p15.5-Related Silver-Russell Syndrome (SRS)

The importance of imprinted genes at chromosome 11p15.5 for fetal growth is known [DeChiara et al 1990, Fitzpatrick et al 2002, Eggermann et al 2009].

Imprinted genes often occur in clusters that include a regulatory imprinting control region (ICR). At one of the 11p15.5 imprinted clusters, parent-specific differential methylation of imprinting control region 1 (ICR1) regulates reciprocal expression of *IGF2* – which encodes a growth factor crucial for fetal development – and *H19*, a noncoding transcript. In SRS, hypomethylation of ICR1 leads to biallelic *H19* expression and biallelic silencing

of *IGF2*, resulting in growth restriction, and accounts for approximately 30%-60% of affected individuals [Gicquel et al 2005, Abu-Amero et al 2010, Wakeling et al 2017].

See Figure 2 for a diagram of the molecular changes associated with 11p15.5-related Silver-Russell syndrome. Note that ICR1 is also known as H19/IGF2 IG-DMR (intergenic differentially methylated region).

Abnormal methylation at 11p15.5 can occur through several mechanisms:

- **Hypomethylation** at ICR1 on the paternal chromosome is detected in 30%-60% of individuals with SRS. Because ICR1 regulates methylation of *IGF2* and *H19*, differential analysis showed that in most cases both of these genes are hypomethylated.

Note: (1) Because 11p15.5 hypomethylation at the paternal ICR1 is usually a postzygotic event, most individuals with SRS have a somatic distribution of abnormal methylation patterns (see Table 1 for testing implications). About 1% of the individuals with 11p15.5 ICR1 hypomethylation have a deletion of part of the ICR1. In these rare cases, there is a genetic cause identified for this epigenetic anomaly [Abi Habib et al 2017]. (2) A small number of individuals with SRS have selective hypomethylation of only *H19* or only *IGF2* [Bartholdi et al 2009].

- A small number of individuals with SRS have a duplication involving the maternal 11p15.5 region. Larger duplications, which can involve translocations and inversions, are detectable by cytogenetic analysis [Fisher et al 2002, Eggermann et al 2005], and microdeletions and duplications are detectable by SNP microarray [Begemann et al 2012, Eggermann et al 2012] (Table 1).
- Rare familial cases of SRS have been reported with underlying mechanisms including:
 - Maternally inherited 11p15 duplication;
 - Maternal inherited *CDKN1C* gain-of-function pathogenic variants;
 - Paternally inherited *IGF2* loss-of-function variants;
 - 11p15.5 ICR1 small deletions.

In these families, the risk of recurrence can be as high as 50%. Investigation for underlying CNVs in individuals with 11p15.5 loss of methylation is, therefore, important [Abi Habib et al 2017, Wakeling et al 2017, Heide et al 2018].

Chromosome 7-Related Russell-Silver Syndrome

The genetic loci responsible for maternal UPD7 imprinting appear to include at least *PEG1/MEST*, which is an imprinted gene cluster at 7q32 [Hannula et al 2001, Eggermann et al 2012]. Abnormal methylation at 7q32 can occur through several mechanisms:

- **Maternal UPD7** reported in 7%-10% of SRS, [Moore et al 1999, Hannula et al 2001, Kim et al 2005] can occur by:
 - Maternal isodisomy or heterodisomy [Bernard et al 1999, Price et al 1999]
 - Mosaicism for upd(7)mat [Reboul et al 2006]
 - Segmental upd(7)mat has been reported:
 - One individual with maternal UPD7 for 7q31-qter [Hannula et al 2001]
 - Two individuals with maternal UPD7 of most of the long arm of chromosome 7 (7q11.2-qter) [Eggermann 2008]
- **Rare chromosome 7 anomalies** seen in individuals with SRS include the following:
 - Mosaic trisomy 7 with maternal heterodisomy in two children [Flori et al 2005, Font-Montgomery et al 2005], one of whom was identified prenatally [Font-Montgomery et al 2005]
 - Interstitial deletion of the long arm of chromosome 7 [del(7)(q21.1q21.3)] in one child [Courstens et al 2005]

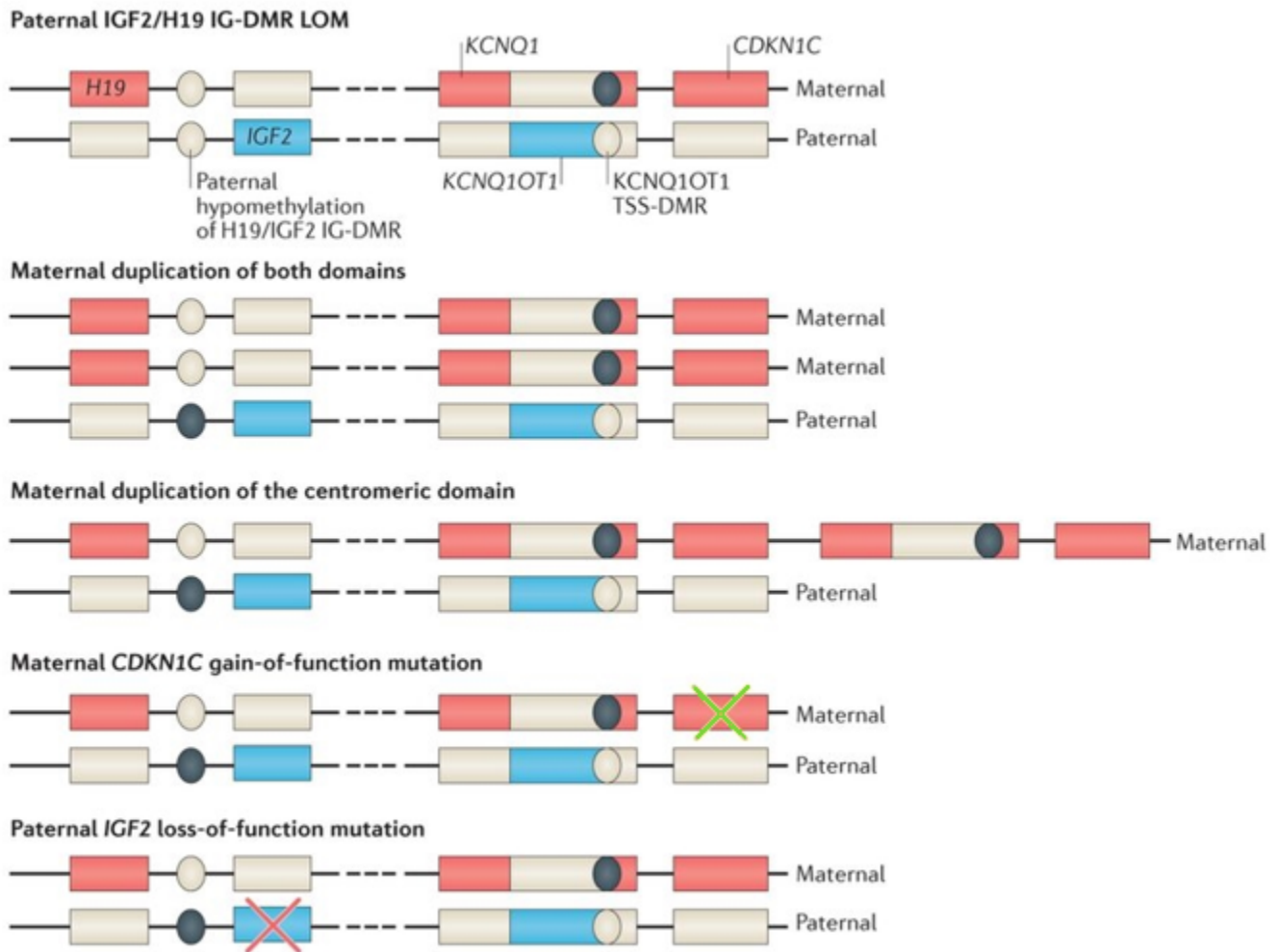


Figure 2. Paternal hypomethylation of H19/IGF2 IG-DMR results in loss of paternal *IGF2* expression and gain of maternal *H19* expression, which leads to a growth restriction phenotype [Gicquel et al 2005, Wakeling et al 2017]. Rarely, maternal duplication of the centromeric or both domains increases dosage of *CDKN1C*. Rare familial cases have been associated with a maternal *CDKN1C* gain-of-function pathogenic variant (green X) [Brioude et al 2013, Wakeling et al 2017] or a paternal *IGF2* loss-of-function pathogenic variant (red X) [Begemann et al 2015, Wakeling et al 2017].

This figure was adapted (legends not included) from Wakeling et al [2017], which was published under a [Creative Commons Attribution 4.0 International License](#).

- Submicroscopic duplication of 7p11.2-p12 identified by fluorescence in situ hybridization (not visible by routine karyotyping) [Joyce et al 1999, Monk et al 2000]

References

Published Guidelines / Consensus Statements

American College of Medical Genetics Statement on diagnostic testing for uniparental disomy. Available [online](#). 2001. Accessed 10-7-21.

Eggermann K, Bliok J, Brioude F, Algar E, Buiting K, Russo S, Tümer Z, Monk D, Moore G, Antoniadis T, Macdonald F, Netchine I, Lombardi P, Soellner L, Begemann M, Prawitt D, Maher ER, Mannens M, Riccio A, Weksberg R, Lapunzina P, Grønskov K, Mackay DJ, Eggermann T. EMQN best practice guidelines for the

molecular genetic testing and reporting of chromosome 11p15 imprinting disorders: Silver-Russell and Beckwith-Wiedemann syndrome. *Eur J Hum Genet.* 2016;24:1377–87. PubMed PMID: 27165005.

Eggermann T, Brioude F, Russo S, Lombardi MP, Blik J, Maher ER, Larizza L, Prawitt D, Netchine I, Gonzales M, Grønsvov K, Tümer Z, Monk D, Mannens M, Chrzanowska K, Walasek MK, Begemann M, Soellner L, Eggermann K, Tenorio J, Nevado J, Moore GE, Mackay DJ, Temple K, Gillessen-Kaesbach G, Ogata T, Weksberg R, Algar E, Lapunzina P. Prenatal molecular testing for Beckwith-Wiedemann and Silver-Russell syndromes: a challenge for molecular analysis and genetic counseling. *Eur J Hum Genet.* 2016;24:784–93. PubMed PMID: 26508573.

Wakeling EL, Brioude F, Lokulo-Sodipe O, O'Connell SM, Salem J, Blik J, Canton AP, Chrzanowska KH, Davies JH, Dias RP, Dubern B, Elbracht M, Giabicani E, Grimberg A, Grønsvov K, Hokken-Koelega AC, Jorge AA, Kagami M, Linglart A, Maghnie M, Mohnike K, Monk D, Moore GE, Murray PG, Ogata T, Petit IO, Russo S, Said E, Toumba M, Tümer Z, Binder G, Eggermann T, Harbison MD, Temple IK, Mackay DJ, Netchine I. Diagnosis and management of Silver-Russell syndrome: first international consensus statement. *Nat Rev Endocrinol.* 2017;13:105–24. PubMed PMID: 27585961.

Literature Cited

Abi Habib W, Brioude F, Edouard T, Bennett JT, Lienhardt-Roussie A, Tixier F, Salem J, Yuen T, Azzi S, Le Bouc Y, Harbison MD, Netchine I. Genetic disruption of the oncogenic HMGA2-PLAG1-IGF2 pathway causes fetal growth restriction. *Genet Med.* 2018;20:250–8. PubMed PMID: 28796236.

Abi Habib W, Brioude F, Azzi S, Salem J, Das Neves C, Personnier C, Chantot-Bastaraud S, Keren B, Le Bouc Y, Harbison MD, Netchine I. 11p15 ICR1 partial deletions associated with IGF2/H19 DMR hypomethylation and Silver-Russell syndrome. *Hum Mutat.* 2017;38:105–111. PubMed PMID: 27701793.

Abraham E, Altiok H, Lubicky JP. Musculoskeletal manifestations of Russell-Silver syndrome. *J Pediatr Orthop.* 2004;24:552–64. PubMed PMID: 15308907.

Abraham MB, Carpenter K, Baynam GS, Mackay DJ, Price G, Choong CS. Report and review of described associations of Mayer-Rokitansky-Küster-Hauser syndrome and Silver-Russell syndrome. *J Paediatr Child Health.* 2015;51:555–60. PubMed PMID: 25418154.

Abu-Amero S, Wakeling EL, Preece M, Whittaker J, Stanier P, Moore GE. Epigenetic signatures of Silver-Russell syndrome. *J Med Genet.* 2010;47:150–4. PubMed PMID: 20305090.

Azcona C, Stanhope R. Hypoglycaemia and Russell-Silver syndrome. *J Pediatr Endocrinol Metab.* 2005;18:663–70. PubMed PMID: 16128243.

Azzi S, Salem J, Thibaud N, Chantot-Bastaraud S, Lieber E, Netchine I, Harbison MD. A prospective study validating a clinical scoring system and demonstrating phenotypical-genotypical correlations in Silver-Russell syndrome. *J Med Genet.* 2015;52:446–53. PubMed PMID: 25951829.

Bartholdi D, Krajewska-Walasek M, Ounap K, Gaspar H, Chrzanowska KH, Ilyana H, Kayserili H, Lurie IW, Schinzel A, Baumer A. Epigenetic mutations of the imprinted IGF2-H19 domain in Silver-Russell syndrome (SRS): results from a large cohort of patients with SRS and SRS-like phenotypes. *J Med Genet.* 2009;46:192–7. PubMed PMID: 19066168.

Begemann M, Spengler S, Gogiel M, Grasshoff U, Bonin M, Betz RC, Dufke A, Spier I, Eggermann T. Clinical significance of copy number variations in the 11p15.5 imprinting control regions: new cases and review of the literature. *J Med Genet.* 2012;49:547–53. PubMed PMID: 22844132.

Begemann M, Zirn B, Santen G, Wirthgen E, Soellner L, Büttel HM, Schweizer R, van Workum W, Binder G, Eggermann T. Paternally inherited IGF2 mutation and growth restriction. *N Engl J Med.* 2015;373:349–56. PubMed PMID: 26154720.

- Bernard LE, Penaherrera MS, Van Allen MI, Wang MS, Yong SL, Gareis F, Langlois S, Robinson WP. Clinical and molecular findings in two patients with Russell-Silver syndrome and UPD7: comparison with non-UPD7 cases. *Am J Med Genet.* 1999;87:230–6. PubMed PMID: 10564876.
- Binder G, Liebl M, Woelfle J, Eggermann T, Blumenstock G, Schweizer R. Adult height and epigenotype in children with Silver-Russell syndrome treated with GH. *Horm Res Paediatr.* 2013;80:193–200. PubMed PMID: 24051620.
- Binder G, Seidel AK, Martin DD, Schweizer R, Schwarze CP, Wollmann HA, Eggermann T, Ranke MB. The endocrine phenotype in Silver-Russell syndrome is defined by the underlying epigenetic alteration. *J Clin Endocrinol Metab.* 2008;93:1402–7. PubMed PMID: 18230663.
- Brioude F, Oliver-Petit I, Blaise A, Praz F, Rossignol S, Le Jule M, Thibaud N, Faussat AM, Tauber M, Le Bouc Y, Netchine I. CDKN1C mutation affecting the PCNA-binding domain as a cause of familial Russell Silver syndrome. *J Med Genet.* 2013;50:823–30. PubMed PMID: 24065356.
- Bruce S, Hannula-Jouppi K, Peltonen J, Kere J, Lipsanen-Nyman M. Clinically distinct epigenetic subgroups in Silver-Russell syndrome: the degree of H19 hypomethylation associates with phenotype severity and genital and skeletal anomalies. *J Clin Endocrinol Metab.* 2009;94:579–87. PubMed PMID: 19017756.
- Bullman H, Lever M, Robinson DO, Mackay DJ, Holder SE, Wakeling EL. Mosaic maternal uniparental disomy of chromosome 11 in a patient with Silver-Russell syndrome. *J Med Genet.* 2008;45:396–9. PubMed PMID: 18474587.
- Carrera IA, de Zaldívar MS, Martín R, Begemann M, Soellner L, Eggermann T. Microdeletions of the 7q32.2 imprinted region are associated with Silver-Russell syndrome features. *Am J Med Genet A.* 2016;170:743–9. PubMed PMID: 26663145.
- Chantot-Bastarud S, Stratmann S, Brioude F, Begemann M, Elbracht M, Graul-Neumann L, Harbison M, Netchine I, Eggermann T. Formation of upd(7)mat by trisomic rescue: SNP array typing provides new insights in chromosomal nondisjunction. *Mol Cytogenet.* 2017;10:28. PubMed PMID: 28770003.
- Courtens W, Vermeulen S, Wuyts W, Messiaen L, Wauters J, Nuytinck L, Peeters N, Storm K, Speleman F, Nöthen MM. An interstitial deletion of chromosome 7 at band q21: a case report and review. *Am J Med Genet A.* 2005;134A:12–23. PubMed PMID: 15732063.
- Dahlgren J, Wikland KA, et al. Final height in short children born small for gestational age treated with growth hormone. *Pediatr Res.* 2005;57:216–22. PubMed PMID: 15585685.
- DeChiara TM, Efstratiadis A, Robertson EJ. A growth-deficiency phenotype in heterozygous mice carrying an insulin-like growth factor II gene disrupted by targeting. *Nature.* 1990;345:78–80. PubMed PMID: 2330056.
- Eggermann T. Segmental maternal UPD(7q) in Silver-Russell syndrome. *Clin Genet.* 2008;74:486–9. PubMed PMID: 18700897.
- Eggermann T, Brioude F, Russo S, Lombardi MP, Blied J, Maher ER, Larizza L, Prawitt D, Netchine I, Gonzales M, Grønskov K, Tümer Z, Monk D, Mannens M, Chrzanowska K, Walasek MK, Begemann M, Soellner L, Eggermann K, Tenorio J, Nevado J, Moore GE, Mackay DJ, Temple K, Gillissen-Kaesbach G, Ogata T, Weksberg R, Algar E, Lapunzina P. Prenatal molecular testing for Beckwith-Wiedemann and Silver-Russell syndromes: a challenge for molecular analysis and genetic counseling. *Eur J Hum Genet.* 2016;24:784–93. PubMed PMID: 26508573.
- Eggermann T, Buiting K, Temple IK. Clinical utility gene card for: Silver-Russell syndrome. *Eur J Hum Genet.* 2011.;19. PubMed PMID: 21150879.
- Eggermann T, Gonzalez D, Spengler S, Arslan-Kirchner M, Binder G, Schonherr N. Broad clinical spectrum Silver-Russell syndrome and consequences for genetic testing in growth retardation. *Pediatrics.* 2009;123:e929–31. PubMed PMID: 19364767.

- Eggermann T, Meyer E, Obermann C, Heil I, Schüler H, Ranke MB, Eggermann K, Wollmann HA. Is maternal duplication of 11p15 associated with Silver-Russell syndrome? *J Med Genet.* 2005;42:e26. PubMed PMID: 15863658.
- Eggermann T, Spengler S, Begemann M, Binder G, Buiting K, Albrecht B, Spranger S. Deletion of the paternal allele of the imprinted MEST/PEG1 region in a patient with Silver-Russell syndrome features. *Clin Genet.* 2012;81:298–300. PubMed PMID: 22211632.
- Fisher AM, Thomas NS, Cockwell A, Stecko O, Kerr B, Temple IK, Clayton P. Duplications of chromosome 11p15 of maternal origin result in a phenotype that includes growth retardation. *Hum Genet.* 2002;111:290–6. PubMed PMID: 12215843.
- Fitzpatrick GV, Soloway PD, Higgins MJ. Regional loss of imprinting and growth deficiency in mice with a targeted deletion of KvDMR1. *Nat Genet.* 2002;32:426–31. PubMed PMID: 12410230.
- Flori E, Girodon E, Samama B, Becmeur F, Viville B, Girard-Lemaire F, Doray B, Schluth C, Marcellin L, Boehm N, Goossens M, Pingault V. Trisomy 7 mosaicism, maternal uniparental heterodisomy 7 and Hirschsprung's disease in a child with Silver-Russell syndrome. *Eur J Hum Genet.* 2005;13:1013–8. PubMed PMID: 15915162.
- Font-Montgomery E, Stone KM, Weaver DD, Vance GH, Das S, Thurston VC. Clinical outcome and follow-up of the first reported case of Russell-Silver syndrome with the unique combination of maternal uniparental heterodisomy 7 and mosaic trisomy 7. *Birth Defects Res A Clin Mol Teratol.* 2005;73:577–82. PubMed PMID: 16007591.
- Fuke T, Mizuno S, Nagai T, Hasegawa T, Horikawa R, Miyoshi Y, Muroya K, Kondoh T, Numakura C, Sato S, Nakabayashi K, Tayama C, Hata K, Sano S, Matsubara K, Kagami M, Yamazawa K, Ogata T. Molecular and clinical studies in 138 Japanese patients with Silver-Russell syndrome. *PLoS One.* 2013;8:e60105. PubMed PMID: 23533668.
- Geoffron S, Abi Habib W, Chantot-Bastarud S, Dubern B, Steunou V, Azzi S, Afenjar A, Busa T, Pinheiro Canton A, Chalouhi C, Dufourg MN, Esteva B, Fradin M, Geneviève D, Heide S, Isidor B, Linglart A, Morice Picard F, Naud-Saudreau C, Oliver Petit I, Philip N, Pienkowski C, Rio M, Rossignol S, Tauber M, Thevenon J, Vu-Hong TA, Harbison MD, Salem J, Brioude F, Netchine I, Giabicani E. Chromosome 14q32.2 imprinted region disruption as an alternative molecular diagnosis of Silver-Russell Syndrome. *J Clin Endocrinol Metab.* 2018;103:2436–46. PubMed PMID: 29659920.
- Ghanim M, Rossignol S, Delobel B, Irving M, Miller O, Devisme L, Plennevaux JL, Lucidarme-Rossi S, Manouvrier S, Salah A, Chivu O, Netchine I, Vincent-Delorme C. Possible association between complex congenital heart defects and 11p15 hypomethylation in three patients with severe Silver-Russell syndrome. *Am J Med Genet A.* 2013;161A:572–7. PubMed PMID: 23401077.
- Gicquel C, Rossignol S, Cabrol S, Houang M, Steunou V, Barbu V, Danton F, Thibaud N, Le Merrer M, Burglen L, Bertrand AM, Netchine I, Le Bouc Y. Epimutation of the telomeric imprinting center region on chromosome 11p15 in Silver-Russell syndrome. *Nat Genet.* 2005;37:1003–7. PubMed PMID: 16086014.
- Goldman V, McCoy TH, Harbison MD, Fragomen AT, Rozbruch SR. Limb lengthening in children with Russell-Silver syndrome: a comparison to other etiologies. *J Child Orthop.* 2013;7:151–6. PubMed PMID: 24432074.
- Graham JM, Hoehn H, Lin MS, Smith DW. Diploid-triploid mixoploidy: clinical and cytogenetic aspects. *Pediatrics.* 1981;68:23–8. PubMed PMID: 6264378.
- Grote L, Myers M, Lovell A, Saal H, Sund KL. Variable approaches to genetic counseling for microarray regions of homozygosity associated with parental relatedness. *Am J Med Genet A.* 2014;164A:87–98. PubMed PMID: 24243712.
- Hannula K, Lipsanen-Nyman M, Kontiokari T, Kere J. A narrow segment of maternal uniparental disomy of chromosome 7q31-qter in Silver-Russell syndrome delimits a candidate gene region. *Am J Hum Genet.* 2001;68:247–53. PubMed PMID: 11112662.

- Heide S, Chantot-Bastaraud S, Keren B, Harbison MD, Azzi S, Rossignol S, Michot C, Lackmy-Port Lys M, Demeer B, Heinrichs C, Newfield RS, Sarda P, Van Maldergem L, Trifard V, Giabicani E, Siffroi JP, Le Bouc Y, Netchine I, Brioude F. Chromosomal rearrangements in the 11p15 imprinted region: 17 new 11p15.5 duplications with associated phenotypes and putative functional consequences. *J Med Genet.* 2018;55:205–13. PubMed PMID: 29223973.
- Hodge N, Evans CA, Simmons KE, Fadavi S, Viana G. Occlusal Characteristics of Individuals with Growth Hormone Deficiency, Idiopathic Short Stature, and Russell-Silver Syndrome. *J Dent Child (Chic).* 2015;82:135–40. PubMed PMID: 26731248.
- Ioannides Y, Lokulo-Sodipe K, Mackay DJ, Davies JH, Temple IK. Temple syndrome: improving the recognition of an underdiagnosed chromosome 14 imprinting disorder: an analysis of 51 published cases. *J Med Genet.* 2014;51:495–501. PubMed PMID: 24891339.
- Jensen RB, Thankamony A, O'Connell SM, Kirk J, Donaldson M, Ivarsson SA, Söder O, Roche E, Hoey H, Dunger DB, Juul A. A randomised controlled trial evaluating IGF1 titration in contrast to current GH dosing strategies in children born small for gestational age: the North European Small-for-Gestational-Age Study. *Eur J Endocrinol.* 2014;171:509–18. PubMed PMID: 25080293.
- Joyce CA, Sharp A, Walker JM, Bullman H, Temple IK. Duplication of 7p12.1-p13, including GRB10 and IGFBP1, in a mother and daughter with features of Silver-Russell syndrome. *Hum Genet.* 1999;105:273–80. PubMed PMID: 10987657.
- Kagami M, Kurosawa K, Miyazaki O, Ishino F, Matsuoka K, Ogata T. Comprehensive clinical studies in 34 patients with molecularly defined UPD(14)pat and related conditions (Kagami-Ogata syndrome). *Eur J Hum Genet.* 2015;23:1488–98. PubMed PMID: 25689926.
- Keren B, Chantot-Bastaraud S, Brioude F, Mach C, Fonteneau E, Azzi S, Depienne C, Brice A, Netchine I, Le Bouc Y, Siffroi JP, Rossignol S. SNP arrays in Beckwith-Wiedemann syndrome: an improved diagnostic strategy. *Eur J Med Genet.* 2013;56:546–50. PubMed PMID: 23892181.
- Kim Y, Kim SS, Kim G, Park S, Park IS, Yoo HW. Detection of maternal uniparental disomy at the two imprinted genes on chromosome 7, GRB10 and PEG1/MEST, in a Silver-Russell syndrome patient using methylation-specific PCR assays. *Clin Genet.* 2005;67:267–9. PubMed PMID: 15691366.
- Lemoine A, Harbison MD, Salem J, Tounian P, Netchine I, Dubern B. Effect of Cyproheptadine on Weight and Growth Velocity in Children With Silver-Russell Syndrome. *J Pediatr Gastroenterol Nutr.* 2018;66:306–11. PubMed PMID: 28806298.
- Luk HM, Ivan Lo FM, Sano S, Matsubara K, Nakamura A, Ogata T, Kagami M. Silver-Russell syndrome in a patient with somatic mosaicism for upd(11)mat identified by buccal cell analysis. *Am J Med Genet A.* 2016a;170:1938–41. PubMed PMID: 27150791.
- Luk HM, Yeung KS, Wong WL, Chung BH, Tong TM, Lo IF. Silver-Russell syndrome in Hong Kong. *Hong Kong Med J.* 2016b;22:526–33. PubMed PMID: 27468965.
- Marsaud C, Rossignol S, Tounian P, Netchine I, Dubern B. Prevalence and management of gastrointestinal manifestations in Silver-Russell syndrome. *Arch Dis Child.* 2015;100:353–8. PubMed PMID: 25700540.
- Martin RA, Grange DK, Zehnbauser B, Debaun MR. LIT1 and H19 methylation defects in isolated hemihyperplasia. *Am J Med Genet A.* 2005;134A:129–31. PubMed PMID: 15651076.
- Monk D, Wakeling EL, Proud V, Hitchens M, Abu-Amero SN, Stanter P, Preece MA, Moore GE. Duplication of 7p11.2-p13, including GRB10. In Silver-Russell syndrome. *Am J Hum Genet.* 2000;66:36–46. PubMed PMID: 10631135.
- Moore GE, Abu-Amero S, Wakeling E, Hitchins M, Monk D, Stanier P, Preece M. The search for the gene for Silver-Russell syndrome. *Acta Paediatr Suppl.* 1999;88:42–8. PubMed PMID: 10626544.

- Netchine I, Rossignol S, Dufourg MN, Azzi S, Rousseau A, Perin L, Houang M, Steunou V, Esteva B, Thibaud N, Demay MC, Danton F, Petriczko E, Bertrand AM, Heinrichs C, Carel JC, Loeuille GA, Pinto G, Jacquemont ML, Gicquel C, Cabrol S, Le Bouc Y. 11p15 imprinting center region 1 loss of methylation is a common and specific cause of typical Russell-Silver syndrome: clinical scoring system and epigenetic-phenotypic correlations. *J Clin Endocrinol Metab.* 2007;92:3148–54. PubMed PMID: 17504900.
- Ocaranza P, Golekoh MC, Andrew SF, Guo MH, Kaplowitz P, Saal H, Rosenfeld RG, Dauber A, Cassorla F, Backeljauw PF, Hwa V. Expanding genetic and functional diagnoses of IGF1R haploinsufficiencies. *Horm Res Paediatr.* 2017;87:412–22. PubMed PMID: 28395282.
- Orbak Z, Orbak R, Kara C, Kavrut F. Differences in dental and bone maturation in regions with or without hemihypertrophy in two patients with Russell-Silver syndrome. *J Pediatr Endocrinol Metab.* 2005;18:701–10. PubMed PMID: 16128247.
- Paganini L, Carlessi N, Fontana L, Silipigni R, Motta S, Fiori S, Gueneri S, Lalatta F, Cereda A, Sirchia S, Miozzo M, Tabano S. Beckwith-Wiedemann syndrome prenatal diagnosis by methylation analysis in chorionic villi. *Epigenetics.* 2015;10:643–9. PubMed PMID: 26061650.
- Price SM, Stanhope R, Garrett C, Preece MA, Trembath RC. The spectrum of Silver-Russell syndrome: a clinical and molecular genetic study and new diagnostic criteria. *J Med Genet.* 1999;36:837–42. PubMed PMID: 10544228.
- Reboul MP, Tadonnet O, Biteau N, Belet-de Putter C, Rebouissoux L, Moradkhani K, Vu PY, Saura R, Arveiler B, Lacombe D, Taine L, Iron A. Mosaic maternal uniparental isodisomy for chromosome 7q21-qter. *Clin Genet.* 2006;70:207–13. PubMed PMID: 16922723.
- Rizzo V, Traggiai C, Stanhope R. Growth hormone treatment does not alter lower limb asymmetry in children with Russell-Silver syndrome. *Horm Res.* 2001;56:114–6. PubMed PMID: 11847473.
- Saal HM, Pagon RA, Pepin MG. Reevaluation of Russell-Silver syndrome. *J Pediatr.* 1985;107:733–7. PubMed PMID: 2414426.
- Sachwitz J, Strobl-Wildemann G, Fekete G, Ambrozaitytė L, Kučinskas V, Soellner L, Begemann M, Eggermann T. Examinations of maternal uniparental disomy and epimutations for chromosomes 6, 14, 16 and 20 in Silver-Russell syndrome-like phenotypes. *BMC Med Genet.* 2016;17:20. PubMed PMID: 26969265.
- Schönherr N, Meyer E, Roos A, Schmidt A, Wollmann HA, Eggermann T. The centromeric 11p15 imprinting centre is also involved in Silver Russell syndrome. *J Med Genet.* 2007;44:59–63. PubMed PMID: 16963484.
- Scott RH, Douglas J, Baskcomb L, Huxter N, Barker K, Hanks S, Craft A, Gerrard M, Kohler JA, Levitt GA, Picton S, Pizer B, Ronghe MD, Williams D, Cook JA, Pujol P, Maher ER, Birch JM, Stiller CA, Pritchard-Jones K, Rahman N, et al. Constitutional 11p15 abnormalities, including heritable imprinting center mutations, cause nonsyndromic Wilms tumor. *Nat Genet.* 2008;40:1329–34. PubMed PMID: 18836444.
- Shuman C, Steele L, Fei YL, Ray PN, Zackai E, Parisi M, Squire J, Weksberg R. Paternal uniparental disomy of 11p15 is associated with isolated hemihyperplasia and expands Beckwith-Wiedemann syndrome spectrum. *Am J Hum Genet.* 2002;71 Suppl:477.
- Smeets CC, Zandwijken GR, Renes JS, Hokken-Koelega AC. Long-term results of GH treatment in Silver-Russell syndrome (SRS): do they benefit the same as non-SRS short-SGA? *J Clin Endocrinol Metab.* 2016;101:2105–12. PubMed PMID: 27007691.
- Stanhope R, Albanese A, Azcona C. Growth hormone treatment of Russell-Silver syndrome. *Horm Res.* 1998;49:37–40.
- Toumba M, Albanese A, Azcona C, Stanhope R. Effect of long-term growth hormone treatment on final height of children with Russell-Silver syndrome. *Horm Res Paediatr.* 2010;74:212–7. PubMed PMID: 20424422.

- Tümer Z, López-Hernández JA, Netchine I, Elbracht M, Grønskov K, Gede LB, Sachwitz J, den Dunnen JT, Eggermann T. Structural and sequence variants in patients with Silver-Russell syndrome or similar features-Curation of a disease database. *Hum Mutat.* 2018;39:345–64. PubMed PMID: 29250858.
- Wakeling EL, Amero A, Alders M, Blik J, Forsythe E, Kumar S, Lim DH, MacDonald F, Mackay DJ, Maher ER, Moore GE, Poole RL, Price SM, Tangeraas T, Turner CLS, Van Haelst MM, Willoughby C, Temple IK, Cobben JM. Epigenotype-phenotype correlations in Silver-Russell syndrome. *J Med Genet.* 2010;47:760–8. PubMed PMID: 20685669.
- Wakeling EL, Brioude F, Lokulo-Sodipe O, O'Connell SM, Salem J, Blik J, Canton AP, Chrzanowska KH, Davies JH, Dias RP, Dubern B, Elbracht M, Giabicani E, Grimberg A, Grønskov K, Hokken-Koelega AC, Jorge AA, Kagami M, Linglart A, Maghnie M, Mohnike K, Monk D, Moore GE, Murray PG, Ogata T, Petit IO, Russo S, Said E, Toumba M, Tümer Z, Binder G, Eggermann T, Harbison MD, Temple IK, Mackay DJ, Netchine I. Diagnosis and management of Silver-Russell syndrome: first international consensus statement. *Nat Rev Endocrinol.* 2017;13:105–24. PubMed PMID: 27585961.
- Wollmann HA, Kirchner T, Enders H, Preece MA, Ranke MB. Growth and symptoms in Silver-Russell syndrome: review on the basis of 386 patients. *Eur J Pediatr.* 1995;154:958–68. PubMed PMID: 8801103.
- Yakoreva M, Kahre T, Žordania R, Reinson K, Teek R, Tillmann V, Peet A, Öglane-Shlik E, Pajusalu S, Murumets Ü, Vals MA, Mee P, Wojcik MH, Öunap K. A retrospective analysis of the prevalence of imprinting disorders in Estonia from 1998 to 2016. *Eur J Hum Genet.* 2019;27:1649–58. PubMed PMID: 31186545.
- Yamaguchi KT Jr, Salem JB, Myung KS, Romero AN Jr, Skaggs DL. Spinal deformity in Russell-Silver syndrome. *Spine Deform.* 2015;3:95–7. PubMed PMID: 27927458.
- Zanelli SA, Rogol AD. Short children born small for gestational age outcomes in the era of growth hormone therapy. *Growth Horm IGF Res.* 2018;38:8–13. PubMed PMID: 29291885.
- Zeschnigk M, Albrecht B, Buiting K, Kanber D, Eggermann T, Binder G, Gromoll J, Prott EC, Seland S, Horsthemke B. IGF2/H19 hypomethylation in Silver-Russell syndrome and isolated hemihypoplasia. *Eur J Hum Genet.* 2008;16:328–34. PubMed PMID: 18159214.

Chapter Notes

Revision History

- 21 October 2019 (ha) Comprehensive update posted live
- 2 June 2011 (me) Comprehensive update posted live
- 9 March 2007 (hs) Revision: methylation analysis for H19 clinically available
- 7 September 2006 (me) Comprehensive update posted live
- 5 March 2004 (me) Comprehensive update posted live
- 2 November 2001 (me) Review posted live
- February 2001 (hs) Original submission

License

GeneReviews® chapters are owned by the University of Washington. Permission is hereby granted to reproduce, distribute, and translate copies of content materials for noncommercial research purposes only, provided that (i) credit for source (<http://www.genereviews.org/>) and copyright (© 1993-2023 University of Washington) are included with each copy; (ii) a link to the original material is provided whenever the material is published elsewhere on the Web; and (iii) reproducers, distributors, and/or translators comply with the [GeneReviews® Copyright Notice and Usage Disclaimer](#). No further modifications are allowed. For clarity, excerpts of GeneReviews chapters for use in lab reports and clinic notes are a permitted use.

For more information, see the [GeneReviews® Copyright Notice and Usage Disclaimer](#).

For questions regarding permissions or whether a specified use is allowed, contact: admasst@uw.edu.