



## Disc volume properties from MRI in adolescent idiopathic scoliosis: correlation to surgical outcome

Pascal Swider, Jérôme Briot, Erik Estivalèzes, Jérôme Sales de Gauzy

### ► To cite this version:

Pascal Swider, Jérôme Briot, Erik Estivalèzes, Jérôme Sales de Gauzy. Disc volume properties from MRI in adolescent idiopathic scoliosis: correlation to surgical outcome. 10th International Symposium on Computer Methods in Biomechanics and Biomedical Engineering - CMBBE 2012, Apr 2012, Berlin, Germany. pp.0. hal-04023071

**HAL Id: hal-04023071**

**<https://hal.science/hal-04023071>**

Submitted on 10 Mar 2023

**HAL** is a multi-disciplinary open access archive for the deposit and dissemination of scientific research documents, whether they are published or not. The documents may come from teaching and research institutions in France or abroad, or from public or private research centers.

L'archive ouverte pluridisciplinaire **HAL**, est destinée au dépôt et à la diffusion de documents scientifiques de niveau recherche, publiés ou non, émanant des établissements d'enseignement et de recherche français ou étrangers, des laboratoires publics ou privés.



## Open Archive TOULOUSE Archive Ouverte (OATAO)

OATAO is an open access repository that collects the work of Toulouse researchers and makes it freely available over the web where possible.

This is an author-deposited version published in : <http://oatao.univ-toulouse.fr/>  
Eprints ID : 10229

**To cite this version** : Swider, Pascal and Briot, Jérôme and Estivalèzes, Erik and Sales de Gauzy, Jérôme. *Disc volume properties from MRI in adolescent idiopathic scoliosis: correlation to surgical outcome*. (2012) In: 10th International Symposium on Computer Methods in Biomechanics and Biomedical Engineering - CMBBE 2012, 11 April 2012 - 14 April 2012 (Berlin, Germany). (Unpublished)

Any correspondance concerning this service should be sent to the repository administrator: [staff-oatao@listes-diff.inp-toulouse.fr](mailto:staff-oatao@listes-diff.inp-toulouse.fr)

## Disc volumetry by MRI and clinical outcome in surgery of adolescent idiopathic scoliosis

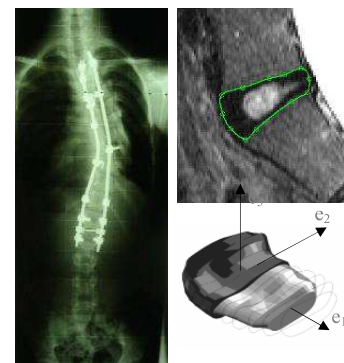
### Purpose :

In young scoliotic patients, the post-operative consequence of spine fusion upon the free lower lumbar spine is one of the major concerns of the surgical treatment. The remodeling of free-motion segment and the role of discs below thoraco-lumbar fusions remains unknown. However, disc hydration and mass exchange flow between disc and vertebral body should play a significant role in the mechano-biology of the vertebral segment. Magnetic resonance imaging is relevant to study intervertebral discs in young scoliotic patients since related to hydration and non-radiant. Despite this, studies focusing on intervertebral disc and MRI in children idiopathic scoliosis were relatively few and rather recent.

We hypothesized that the objective quantification of volume and hydration of intervertebral discs below spine fusion in scoliosis surgery could help in the surgery planning and in the patient follow-up.

### Methods :

MRI performed in the clinical protocol, concerned 65 patients (60 girls and 5 boys, mean age: 15.1) having an idiopathic scoliosis. They underwent posterior instrumentations. MRI was obtained before surgery, after surgery at 3 months (46 patients), 1 year (28 patients) and 2 years (10 patients). The MRI was obtained according to a clinical infant protocol: sagittal joined slices of 3 mm thickness were obtained from  $T_5$ - $T_6$  to  $L_5$ - $S_1$  using a turbo spin echo T2-weighted sequence (Magnetom Vision, 1.5 T). The contours of nucleus pulposus and annulus fibrosus were semi-automatically segmented, 3D reconstruction and volume computation were achieved using a custom-made image processing software developed with Matlab®. The hydration level was defined as the nucleus-disc volume ratio and for all further analysis, the pre-operative configuration was considered as reference.



**Figure 1-** X-ray (frontal plane),  $T_2$  weighted image (sagittal plane), disc segmentation and reconstruction

The clinical follow-up included the Cobb angle, the frontal equilibrium and the inclination of the first disc subjacent to the arthrodesis. Clinical exams were achieved by using radiographs in the frontal plane before and after surgeries. Patients were separated into two groups according to post-operative criterions. The group A showed equilibrated spines in the frontal plane. The distance between the orthogonal projection of C7 centre and the pelvis centre was lower than 2 cm. The inclination of intersomatic angle bisector was lower than  $6.5^\circ$ . Other patients were grouped into group B. The reduction of the Cobb angle has been taken into account and a reduction greater than 65 % was a good clinical result.

### Results :

The 3D reconstruction of disc from MRI was reproducible ( $p = 0.01$ ) with a volume accuracy of 1.62 % (CI: 95%). Before surgery, the disc volume ( $\text{mm}^3$ ) was in the range  $[7.3 \times 10^3; 1 \times 10^4]$  (SD 30%) and the nucleus volume ( $\text{mm}^3$ ) was in the range  $[3.5 \times 10^3; 4.6 \times 10^3]$  (SD 30%). The nucleus-disc volume ratio was 50 % (SD 20%) and rather constant whatever the disc level.

The surgery induced a significant volume increase in disc below the arthrodesis and both volumes of nucleus pulposus and annulus fibrosus were increasing. At 3 months, 1 year and two years post-operatively, subjacent discs in group A with a cobb angle reduction greater than 65 %, showed a significant increase of volume and hydration level up to 20%. At 1 year post-operatively, patients in group B showed an increase in disc volumes even if they were classified incorrect clinically (frontal X-

rays). When the Cobb angle reduction was lower than 65 %, no volume increase or re-hydration was found.

### **Conclusion**

Volume and hydration level of discs subjacent to the arthrodesis increased post-operatively. The strong disruption due to surgery induced a forced redistribution of strain energy into free vertebral segments and this was macroscopically revealed by the modification of the disc properties. Correlations were obtained between the favorable evolution of disc volume properties and post-operative clinical diagnosis (reduction of Cobb angle, spine equilibrium, disc inclination). Mechano-biological factors could explain the post-operative remodeling of free lumbar segments. It was noted that in some cases, MRI showed disc volume increase and re-hydration in patients showing unsatisfying clinical results (X-rays). The patient follow-up should allow quantifying the natural history of free-motion segments and focusing on disc evolution could contribute to the improvement of idiopathic scoliosis surgery planning.