



HAL
open science

Evaluation of furcation involvement with diagnostic imaging methods: a systematic review

Guilhem Jolivet, Olivier Huck, Catherine Petit

► To cite this version:

Guilhem Jolivet, Olivier Huck, Catherine Petit. Evaluation of furcation involvement with diagnostic imaging methods: a systematic review. *Dentomaxillofacial Radiology*, 2022, 51 (8), <10.1259/dmfr.20210529>. <hal-04022381>

HAL Id: hal-04022381

<https://hal.science/hal-04022381v1>

Submitted on 9 Mar 2023

HAL is a multi-disciplinary open access archive for the deposit and dissemination of scientific research documents, whether they are published or not. The documents may come from teaching and research institutions in France or abroad, or from public or private research centers.

L'archive ouverte pluridisciplinaire HAL, est destinée au dépôt et à la diffusion de documents scientifiques de niveau recherche, publiés ou non, émanant des établissements d'enseignement et de recherche français ou étrangers, des laboratoires publics ou privés.



HAL Authorization

SYSTEMATIC REVIEW

Evaluation of furcation involvement with diagnostic imaging methods: a systematic review

^{1,2}Guilhem Jolivet, ^{1,2,3}Olivier Huck and ^{1,2,3}Catherine Petit

¹Université de Strasbourg, Faculté de Chirurgie Dentaire, Periodontology, Strasbourg, France; ²Hopitaux Universitaires de Strasbourg, Pôle de médecine et chirurgie bucco-dentaires, Strasbourg, France; ³INSERM (French National Institute of Health and Medical Research), UMR 1260, Regenerative Nanomedicine, Fédération de Médecine Translationnelle de Strasbourg (FMTS), Strasbourg, France

Objective: Multirooted teeth respond less favorably to non-surgical periodontal treatment and long-term tooth prognosis is influenced by the degree of furcation involvement (FI). Therapeutic strategy for multirooted teeth is essentially based on accurate diagnosis of the FI. The aim of this systematic review is to evaluate the accuracy of the different furcation assessment methods and to determine if radiographic help is needed to determine early stage of FI.

Methods: Electronic databases were searched up to March 2021. Comparative studies describing the reliability of different clinical and/or radiological furcation assessment methods were identified.

Results: A total of 22 studies comparing at least 2 furcation assessment methods, among which 15 retrospective studies, 5 prospective studies, 1 randomized controlled trial and 1 case series, were included in this review. The reliability of cone beam CT (CBCT), intraoral radiographs (IOs), orthopantomograms (OPGs) and MRI to identify FI was evaluated. Using OFS as a reference for FI detection and diagnosis, agreement ranged from 43.3 to 63% for OPG, 38.7 to 83.1% for IO and 82.4 to 84% for CBCT. The validity of the measurements was mainly influenced by the location of the furcation entrance. For radiological diagnosis, CBCT displayed the closest agreement with OFS while the accuracy of IO and OPG showed modest agreement and were influenced by the examiner's experience.

Conclusion: Altogether, it appears that the use of IO, OPG or CBCT allows detection of FI but could not be considered as gold-standard techniques.

Dentomaxillofacial Radiology (2022) **51**, 20210529. doi: [10.1259/dmfr.20210529](https://doi.org/10.1259/dmfr.20210529)

Cite this article as: Jolivet G, Huck O, Petit C. Evaluation of furcation involvement with diagnostic imaging methods: a systematic review. *Dentomaxillofac Radiol* (2022) 10.1259/dmfr.20210529.

Keywords: furcation; cone beam; retro alveolar; interradicular

Introduction

Periodontal diseases comprise a wide range of inflammatory conditions, including gingivitis and periodontitis, that could lead to tooth loss and contribute to systemic inflammation.¹ Periodontitis is classified by its stage and grade based on the severity, complexity of the disease's management and rate of progression.² Its global prevalence is 42.2% and severe forms affect 10–15% of the

population above 40 years old. The disease is influenced by several environmental and host risk factors such as age, tobacco smoking, diabetes and obesity, educational level or stress.³ Periodontal disease initiation and propagation are associated with dysbiosis of the commensal oral microbiota worsening tissue inflammation with a specific role played by keystone pathogens.⁴

Periodontal primary cares aim to restore equilibrium through removal of periodontal pathogens and reduction of inflammation.¹ Alongside with oral hygiene instruction and motivation, scaling and root planing

Correspondence to: Professor Olivier Huck, E-mail: o.huck@unistra.fr

Received 20 December 2021; revised 09 June 2022; accepted 01 July 2022; published online 14 July 2022

(SRP) has been established as the main therapeutic tool of this cause-related therapy. It efficiently reduces periodontal pocket depth (PPD) and improves clinical attachment level (CAL).^{5,6} SRP presents some limitations especially at deep sites with PPD >6 mm, or around multirrooted teeth where “pocket closure” (PPD <4 mm) and the removal of all periodontal pathogens are not easily achieved.^{7,8} Outcomes of clinical trials have shown that furcation-involved molars respond less favourably to non-surgical periodontal therapy compared with molars without furcation involvement (FI), and are more prone to further attachment loss.^{9–11} The degree of FI has been categorized according to the extent of horizontal bone loss by Hamp et al¹² with Class I corresponding to a horizontal bone loss not exceeding one-third of the width of the tooth (less than 3 mm), Class II to a horizontal bone loss greater than one-third of the width of the tooth (more than 3 mm but not encompassing the total width of the furcation area) and Class III to the horizontal “through and through” destruction of the periodontal tissues. However, to fully characterize the lesion, its vertical component should be considered. Therefore, a vertical subclassification was proposed in 1984, by Tarnow and Fletcher. This subclassification considers the number of millimetres of bone loss from the roof of the furcation with three subclasses: A corresponding to 0–3 mm probable depth from the roof of the furcation, B to 4–6 mm and C > 7 mm or greater probable depth from the roof of the furcation.¹³

The impact of periodontal therapy on survival and success rates of furcation-involved teeth was evaluated in a systematic review.¹⁴ Indeed, it was observed high long-term survival rates of multirrooted teeth with FI following various therapeutic approaches. More specifically, Class I FI could be successfully managed by non-surgical mechanical debridement alone.¹² Caries development in the furcation area was found to be the most frequent cause for molar loss after a tunnelling procedure. Finally, the most frequent complications following resective procedures of furcation-involved molars were not associated with the progression of periodontitis but were related to vertical root fractures and endodontic failures. Class II FI at mandibular molars as well as buccal FI in maxillary molars may be successfully treated by regenerative procedures.¹⁵ Altogether, the degree of FI (along with tooth mobility, tooth position, lack of occlusal antagonism and remaining bone support) is one factor found to significantly influence the decision for tooth extraction.¹⁶ Furthermore, long-term studies have shown that molar tooth loss is mainly and negatively influenced by the presence of FI during follow-up and supportive periodontal care.^{17–21} Nibali et al, highlighted, in a retrospective study with a total observation period of 79.1 ± 18.0 months, that both horizontal FI and vertical furcation component were associated with increased risk of tooth loss during supportive periodontal therapy (OR 5.26, 95% CI: 1.46–19.03, $p = 0.012$ and OR 9.83, 95% CI: 1.83–50.11, $p = 0.006$, respectively).²²

Regarding the management of such lesion, the treatment prognosis mainly depends on the location and severity of FI. For instance with non-surgical treatment alone, the survival probability after 5–12 years of FI Class I is 99–100% while for FI Class III it is reduced to 25%.¹⁴ Lately, it has been suggested that, FI Class I may be managed by non-surgical treatment alone while FI Class II may benefit from regenerative approaches and in FI Class III tunnelization, root resection or root separation may be considered.²³

Finally, another aspect of retaining FI molars via periodontal treatments is the cost effectiveness when implants are considered to replace such missing teeth. It has been shown that compared to tooth-retaining periodontal treatments (scaling and root planing, flap debridement, root resection, guided-tissue regeneration, tunnelling), implant supported crowns were retained for shorter time than natural teeth regardless of the degree of FI, the patients age or risk profile (smoker/non-smoker). Also, despite requiring re-treatment later than other strategies, implant supported crowns were the most costly therapy.²⁴

Therefore, accurate presurgical diagnosis of FI is fundamental for decision making and to assess the prognosis of diseased molars. Several techniques have been proposed to assess FI, with the gold-standard being periodontal probing with dedicated tools such as Nabers and periodontal probes or two- and three-dimensional imaging that have been suggested to detect and evaluate the extent of FI. Thus, the aim of this systematic review is to evaluate the accuracy of the different furcation assessment tools, and to determine if radiographic help is needed to determine early stage of FI. Based on the PICO format, the present systematic review focuses on the evaluation of imaging techniques in furcation involved molars detection in human patients.

Methods

Protocol and search strategy: The results of the present systematic review were reported following the PRISMA guidelines. The following databases: MEDLINE, Cochrane Central Register of Controlled Trials and Science Direct databases were searched for publications. Two filters related to publications were applied: publications in the English language and conducted in Humans. Hand searching comprised of checking bibliographic references of included articles and related review articles. A typical search strategy, using Boolean operators and an asterisk symbol (*) as truncation, was employed to identify papers using MeSH, keywords and other free terms: (((((((furcation defects[MeSH Terms]) OR (furcation defect[MeSH Terms])) OR (defects, furcation[MeSH Terms])) OR (defect, furcation[MeSH Terms])) AND (diagnosis*[MeSH Terms])) OR (reliability of results[MeSH Terms])) AND (molar[MeSH Terms])) AND (humans[MeSH Terms])) AND

(periodont*). Article screening has been conducted until March 2021.

Eligibility criteria

A study was considered eligible for inclusion in this systematic review if it was an original research published in peer-reviewed journals and if met the following criteria: (i) all types of longitudinal studies, cases series and randomized controlled trials; (ii) conducted in humans; (iii) assessed the diagnosis of furcation involvement; (iv) comparing different diagnostic methods. Studies were excluded if they: (i) only reported the effect of therapy; (ii) no full-text available or not in English language; (iii) were a duplicate or ancillary study. Reviews were excluded after reference checking.

Screening and selection of papers

Selected publications were reviewed and categorized as suitable or not for inclusion in this review. After selection of the articles, full texts were reviewed if the studies seemed to meet the inclusion criteria or for which there was insufficient information in the title or abstract to decide if they were eligible.

Search outcomes and evaluation

Selected studies assessed the presence/absence and/or the degree of FI with either the Hamp index, the Ramfjord index, the Glickman index and the degree of agreement between the diagnosis methods.^{12,25,26} Imaging techniques used in the selected studies includes intraoral (IO) radiographs, panoramic radiographs (OPG), cone beam CT (CBCT) and MRI.

Quality assessment

The quality assessment for cohort and case-control studies included in the systematic review was based on the Newcastle-Ottawa Scale (NOS) tool evaluating the following criteria: (i) selection of the exposed cohort (multirooted teeth), (ii) comparability of participants with respect to confounding factors, and (iii) assessment of outcome (FI assessment comparison). The studies were classified according to their quality: 0–3 low quality, 4–6 fair quality and 7–10 good quality Supplementary Table 1.

Results

Study selection

Regarding the reliability of furcation assessment methods, 240 articles were identified. After screening of titles and abstracts, inappropriate papers were excluded resulting in 40 publications (Figure 1). After full text reading, 18 articles were excluded according to the inclusion/exclusion criteria, yielding to 22 articles contributing to this review.

Study characteristics

All selected studies are presented in Table 1. Among the included studies, 16 were retrospective, 4 prospective, 1 was a cohort study, 1 was a case-series and 1 was a randomized controlled trial published in English language between 1980 and 2021. The included studies have been conducted in 13 different countries across Asia, Europe, and America. Size of the included population varied across the studies, ranging from 10 to 400 participants.^{31,47} In all included studies, different furcation assessment methods (clinical and radiological) were used and compared.

Study outcomes

Clinical assessment

Intraoral and panoramic radiographs: Ross and Thomson performed one of the first study assessing the prevalence of FI by the mean of probing and/or with IO.⁴² In this study, FI occurred three times more frequently among maxillary molars than in mandibular molars. FI was detected more frequently in maxillary molars by IO than by clinical examination and more frequently by probing than by IO for mandibular molars. At the maxilla, 65% of furcation involved molars were detected by clinical and radiographic examination when 22% were found by radiographic examination only. Only 3% of the cases of FI were detected by clinical examination alone. At the mandible, the agreement between clinical and radiological examination was 18%, 8% of the furcation involved molars were detected by radiographic examination alone and 9% by clinical examination only. Two studies assessed the reliability of the orthopantomogram (OPG)^{34,38} and five studies the reliability of IO and/or bite-wings (BW) (Table 2).^{29,34,35,38,44,46,48,49} Compared to OFS, the accuracy of OPG was 63%, with a specificity of 31% meaning that 69% of the furcation involved teeth were not diagnosed with the OPG. The positive-predictive value of the OPG was 88% and the negative-predictive value 57%.³⁸ In the study of Graetz *et al*, OPG were analysed by an experienced examiner (EE) and a less experienced examiner (LE).³⁴ The closest agreement between OFS and OPG was found for EE compared to LE (55% for EE and 43.3% for LE). Furthermore, the agreement was found to be better for lesions localized at the mandible for both type of examiners.

Some authors assessed the reliability of the “furcation arrow”, a small triangular radiolucent shadow seen across the mesial and the distal root of maxillary molars, as a landmark for the diagnosis of FI.^{29,50} The agreement of the radiographic furcation arrow landmark was confirmed by surgery giving 31.3% agreement for Class I and 48.7% agreement for Class II or III. The sensitivity of the furcation arrow was 71.7% and the specificity 92.2%. For this landmark, the positive-predictive value was 71.7% and the negative-predictive value 74.6%.

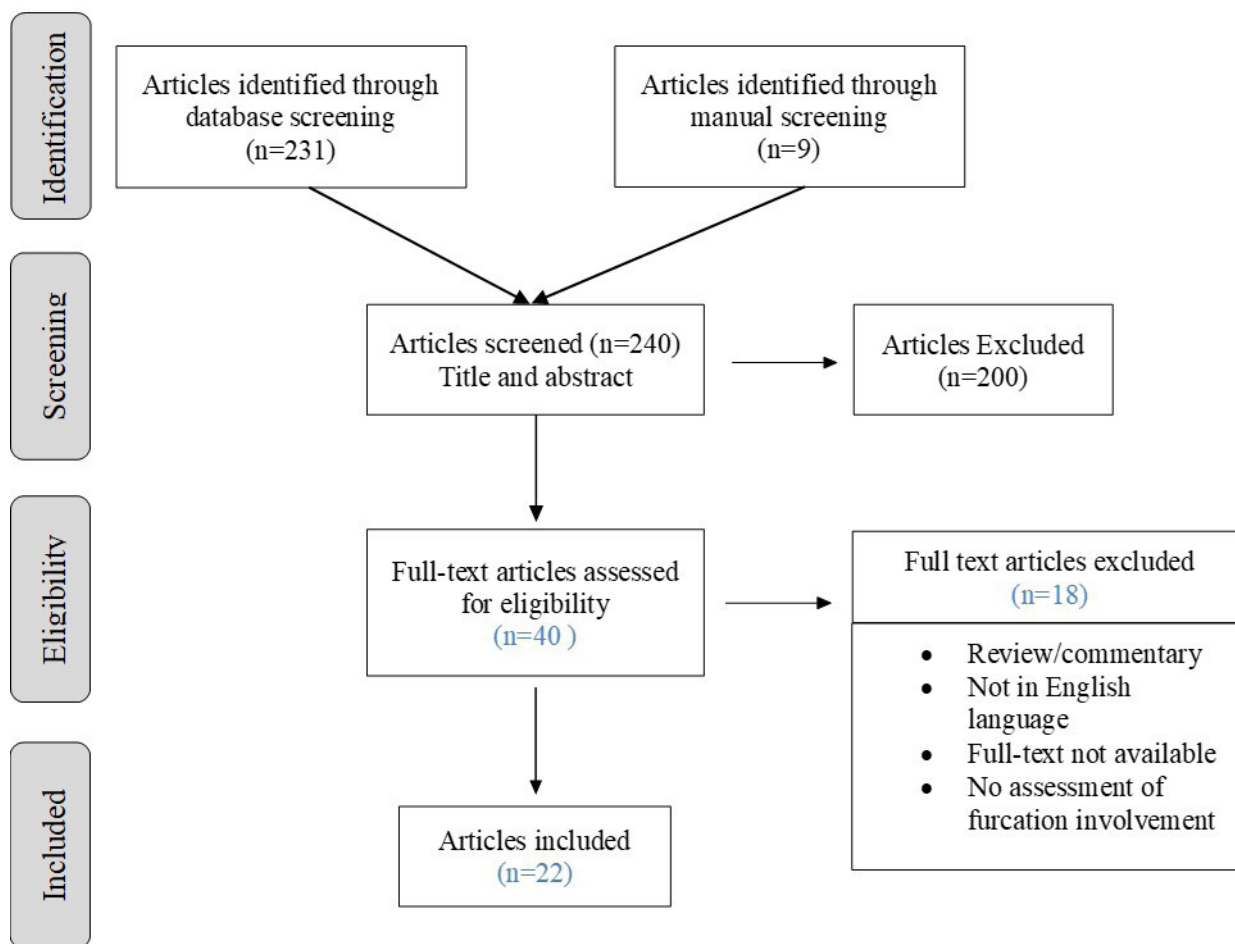


Figure 1 Selection of the studies.

These data suggest that the furcation arrow has limited usefulness as a diagnostic marker of FI.

One study compared IO radiographs with CBCT and clinical detection on maxillary and mandibular first molars.⁴⁶ Spearman's correlation and Steiger's Z-test analysis demonstrated that clinical detection, IO and CBCT were significantly correlated with each other in the assessment of first molar FI (r values ranged between 0.230 and 0.644). Compared to CBCT, clinical detection was overestimated in 18.7% and underestimated in 26.7% of the cases. Compared to clinical detection, IO radiographs exhibited 18.2% of overestimation and 24.6% of underestimation but IO radiographs usually detected only the presence or absence of furcation lesion. Compared with IO, CBCT appeared to have higher correlation coefficients with clinical detection especially at distal palatal side of maxillary first molar.

Cone-beam CT: Five studies assessed the reliability of CBCT for the evaluation on FI (Table 2).^{38,41,43,44,51} When compared to OFS, the accuracy of CBCT was 96% with a sensitivity of 93% and a specificity of 100%.³⁸ The positive-predictive value was 100% and the negative-predictive value 93%. The degree of agreement between

CBCT and OFS was also explored by Qiao et al and Walter et al.^{41,43} The degree of agreement ranged from 82.4 to 84%.^{41,43} The degree of overestimation varied from 1.3 to 5.9%, and the degree of underestimation went from 11.7 to 14.7%.^{41,43} The degree of agreement was also explored for each furcation entrance. Both studies showed that the furcation location had an influence on the accuracy of CBCT diagnosis and that the best agreement was obtained for buccal and distal entrances, while the lowest value was found for mesial entrance. The confidence with FI assessed by CBCT in maxillary molars was also influenced by the image quality.⁵²

Seven studies provided information comparing clinical probing with CBCT (Table 2), showing an overall agreement ranging between 29 and 56%.^{27,28,38,39,46,51,53} However, several factors can influence the degree of agreement such as tooth location (maxilla/mandible), degree of FI and furcation entrance. Regarding tooth location (maxilla/mandible), when the overall agreement between probing and CBCT was 46.9%, a higher agreement was observed in the maxilla (63%) than in the mandible (45%) by Cimbaljevic et al.²⁷ Regarding the

Table 1 Studies characteristics

<i>Study/Country</i>	<i>Type of study</i>	<i>Sample size</i>	<i>Examiners</i>	<i>Furcation assessment methods</i>	<i>Method used as a gold- standard for comparison</i>	<i>Principal findings</i>
Cimbaljevic et al., 2015 ²⁷ Serbia	Retrospective study	15 patients 174 furcation sites	A trained observer blinded to the clinical findings assessed the full CBCT volumes for FI	Periodontal probing (Nabers probe) CBCT FI is set as present or absent in both examination methods	CBCT	FI detection by CBCT > probing Agreement between the evaluation methods was present in 46.9% of cases (63.3% in maxilla, 45.0% in mandible). Clinical detection of FI confirmed by CBCT in 24% of the cases Largest agreement in FI detection between CBCT and clinical probing = 74.7% for disto-palatal maxillary sites Smallest agreement in FI detection between CBCT and clinical probing = 36.6% for buccal site of mandibular molars
Darby et al., 2015 ²⁸ Australia	Retrospective study	27 patients 154 sites	CBCT scans were analyzed by three researchers Furcation probing were determined by trained periodontists and post-graduate students	Periodontal probing (Nabers probe) CBCT	CBCT	Agreement between CBCT and probing = 22% Compared to CBCT probing rendered <ul style="list-style-type: none"> • 58% overestimation • 20% underestimation
Deas et al., 2006 ²⁹ U.K	Retrospective study	89 patients 164 maxillary molars 328 interproximal furcations	5 Board certified periodontists	Intrasurgical assessment Peri-apical radiographs ("furcation arrow" used as a landmark)	OFS	Among the 111 furcations sites confirmed by surgery, 38.7% were predicted by a furcation arrow image seen by at least three of the five examiners. The positive predictive value of the image = 71.7% Negative predictive value = 74.6%. The image is difficult to interpret and highly subjective.
Eickholz et al., 1995 ³⁰ Germany	Retrospective study	50 patients 200 molars		Pre-surgical probing (Nabers probe, CAL-H was assessed 2 times within 14 days for all patients) Intrasurgical measurements (OFS) (34 patients, 127 molars)	OFS	The agreement of replicate measurements of furcation degrees was moderate for furcation locations which showed a CAL-H <3mm and a CAL-H >3 mm, respectively (weighted <i>K-coefficients</i> 0.500 and 0.691). There was no significant difference between furcation classes as assessed pre-surgically and intrasurgically.
Eickholz and Kim, 1998 ³¹ Germany	Retrospective study	105 patients 420 molars (208 mandibular and 212 maxillary)		Pre-surgical clinical measurements with a Nabers probe, PCPUNC15 probe, flexible plastic version of the universal explorer TPS probe Intrasurgical measurements (OFS)	OFS	All pre-surgical furcation measurements were repeated on a second examination within 14 days. Using the Nabers probe, no asymmetries between pre- and intrasurgically obtained class of furcation involvement were revealed, while the TPS and PCPUNC15 probe underestimated furcation degrees. Validity of CAL-H measurements is influenced by distolingual location and height of furcation, PPD, CAL-V and type of probes Clinical diagnosis of furcation lesions using a Nabers probe provide reproducible and valid information about furcation invasion.

(Continued)

Table 1 (Continued)

<i>Study/Country</i>	<i>Type of study</i>	<i>Sample size</i>	<i>Examiners</i>	<i>Furcation assessment methods</i>	<i>Method used as a gold- standard for comparison</i>	<i>Principal findings</i>
Eickholz and Stachle 1994 ³² Germany	Retrospective study	25 patients 100 molars (50 maxillary, 50 mandibular)		Pre-surgical measurements of furcation involvement with a Nabers probe (measurements were repeated within 14 days) Intrasurgical measurements (OFS) in molars in needs for surgery (17 patients, 68 molars)	OFS	The overall standard deviation of single measurements was 0.739 mm. For buccal, lingual, mesiolingual and distolingual furcations, the standard deviations were 0.602 mm, 0.559 mm, 0.759 mm, 1.099 mm, respectively; measurement error was less in buccal and lingual furcations than in distolingual furcations ($p < 0.001$). The excellent agreement of replicate measurements of furcation degrees for buccal, lingual and mesiolingual furcations (weighted κ -coefficients between 0.776 and 0.944), Moderate agreement of replicate measurements for distolingual furcations ($\kappa_w = 0.706$). PAL-H measurement is influenced by furcation depth, width and furcation location. No significant difference between furcation degree as assessed pre- and intrasurgically.
Eickholz et al., 1999 ³³ Germany	Retrospective study	10 patients 60 molars (28 mandibular, 32 maxillary molars)	Three trained and experienced examiners	Clinical examination and assessment of PAL-H with a Nabers probe and pressure-calibrated plastic probe (TPS) Intrasurgical measurements (OFS) in six patients	OFS	Multifactorial analysis of variance revealed that PAL-H measurements were significantly influenced by examiner and furcation location (buccal, lingual, mesiolingual, distolingual) whereas type of probe and schedule of examination had no influence on the interexaminer reproducibility. Reproducibility of furcation degree assessments : <ul style="list-style-type: none"> • degree 0 = poor • degree I and II = moderate • degree III = excellent The difference between clinical and intrasurgical PAL-H assessment was influenced by examiner and location but not by type of probe. Approximately, 70% of the total variance of PAL-H measurements was due to the variance of true values, whereas 30% of the variance may be explained by inter- and intraexaminer variance. Distolingual furcation sites are the most difficult and least reliable to diagnose. The use of a pressure-calibrated TPS probe failed to increase the interexaminer reliability of clinical diagnosis of furcation involvements.

(Continued)

Table 1 (Continued)

<i>Study/Country</i>	<i>Type of study</i>	<i>Sample size</i>	<i>Examiners</i>	<i>Furcation assessment methods</i>	<i>Method used as a gold-standard for comparison</i>	<i>Principal findings</i>
Graetz et al., 2014 ³⁴ Germany	Retrospective study	215 participants 834 molars	One experienced examiner one less experienced examiner	Furcation probing (Nabers probe) 77 Intraoral radiographs 143 OPG Visual assessment during OFS	OFS	When FP is compared to OFS: <ul style="list-style-type: none"> • Agreement = 56% • Overestimation = 29% • Underestimation = 15% FI Class 0 and I had been detected with high probability (74 and 54%, respectively). For Class III 57% were detected correctly by radiographs and 32% by probing. Probing and OFS revealed a weighted κ -coefficient (κ_w)=0.588; radiographs and OFS had $\kappa_w = 0.542$ (OPG $\kappa_w = 0.555$ and I-O $\kappa_w = 0.521$). The interrater reliability for radiographs was dependent on the experience of the examiner (EE $\kappa_w = 0.618$; LE $\kappa_w = 0.426$). Experience in analyzing conventional radiographs increases the potential of correct diagnosis of advanced FI. The reliability of furcation probing compared with radiographic assessment depends on the anatomy and location of the tooth.
Gusmão et al., 2014 ³⁵ Brazil	Retrospective study	70 patients 350 molars		Bite-wing and periapical radiographs with parallel technique Clinical measurements (Nabers probe and Gilckman classification)	Clinical probing	Among the 350 teeth examined, 160 (45.7%) exhibited furcation involvement, with the following distribution: <ul style="list-style-type: none"> • degree I: 38.1% • degree II: 43.1% • degree III: 18.8%. Radiographic examination detected 65.0% of cases of furcation involvement observed with the clinical examination (sensitivity). 98.4% of cases radiographically classified as having no furcation involvement were negative upon clinical examination (specificity). Overall agreement = 83.1% Overestimation of FP/IO radiographs = 16% Underestimation of FP/OI radiographs = 0.9% The κ agreement index was 0.65 (CI = 0.57–0.73), indicating a reasonable level of agreement between the two examinations.

(Continued)

Table 1 (Continued)

<i>Study/Country</i>	<i>Type of study</i>	<i>Sample size</i>	<i>Examiners</i>	<i>Furcation assessment methods</i>	<i>Method used as a gold- standard for comparison</i>	<i>Principal findings</i>
Juerchott et al., 2020 ³⁶ Germany	Prospective study	22 patients 192 furcation entrances	Two examiners (one trained dentist and one trained radiologist)	CBCT Dental Magnetic Resonance Imaging (dMRI) with contrasting agent	CBCT	dMRI measurements showed high agreement with CBCT, and measurement accuracy did not differ among different degrees of FI ($p = 0.67$). For FI detection, sensitivity and specificity of dMRI were 98 and 99%. For FI classification, sensitivity values of dMRI were 89%/84%/100% for degree I/II/III. Sensitivity, based on correct identification of presence and degree of FI, was high for buccal and disto-palatal FI, with values of 86 and 93%, respectively. For mesio-palatal FI, all furcations were assessed correctly, leading to a sensitivity of 100%. Specificity was nearly perfect for buccal (97%), and perfect (100%) for both distopalatal and mesiopalatal furcations.
Juerchott et al., 2020 ³⁶ Germany	Prospective study	23 patients 65 first and second maxillary molars 195 furcation entrances	Two examiners (one trained dentist and one trained radiologist)	CBCT Non-contrasted-enhanced dental magnetic resonance imaging (NCE-dMRI)	CBCT	For the detection of furcation defects, sensitivity/specificity of NCE-dMRI was 98%/100% for horizontal and 99%/99% for vertical components. For defect classification, sensitivity values of NCE-dMRI were 88%/89%/100% (horizontal degree I/II/III) and 95%/91%/80% (vertical subclass A/B/C), respectively. NCE-dMRI demonstrated high reliability and high agreement with CBCT for the assessment of furcation defects in maxillary molars.
Kim et al., 1996 ³⁷ Germany	Retrospective study	100 molars 25 patients 253 furcations		Flexible plastic universal explorer version of the TPS probe (TPS) Color-coded Nabers probe	Clinical probing (Nabers)	Measurement error was less in buccal and lingual furcations than in mesiolingual and distolingual sites ($p < 0.005$). The agreement of replicate measurements of furcation degrees was excellent for buccal and lingual furcations, but only moderate for mesiolingual and distolingual furcations. At all locations the TPS underestimated furcation degrees significantly as compared to Nabers probe. Through and through furcations are likely to be underestimated by using the flexible plastic version of the TPS probe. Hence, it seems to be unsuitable for a proper assessment of the degree of furcation involvement.

(Continued)

Table 1 (Continued)

<i>Study/Country</i>	<i>Type of study</i>	<i>Sample size</i>	<i>Examiners</i>	<i>Furcation assessment methods</i>	<i>Method used as a gold- standard for comparison</i>	<i>Principal findings</i>
Komšić et al., 2019 ³⁸ Croatia	Retrospective study	6 patients 38 molars schedules for surgery 93 furcation sites		Pre-surgical probing (Nabers probe with Glickman classification) 2D panoramic X-ray CBCT Intrasurgical measurement (OFS)	OFS	Periodontal probing, intrasurgical measurement and measurements based on CBCT significantly correlated with each other regarding the assessment of FI, with r values ranging between 0.81 to 1.00 ($p < 0.01$). The correlation of panoramic radiograph with periodontal probing was 0.49, with CBCT 0.39 and with intrasurgical measurements 0.36. Excellent agreement and higher accuracy between intrasurgical measurements and CBCT (0.96), in contrast to clinical examination and panoramic radiography were 0.87 and 0.63 respectively.
Laky et al., 2013 ³⁹ Austria	Case series	75 patients 582 furcations sites assigned for diagnosis of Class II and III	Specialists Post-graduate students Undergraduate students	Periodontal probing (Nabers probe) CBCT (served as control)	CBCT	Agreement of probing with CBCT = 57% Overestimation = 20% Underestimation = 23% Only 32% of Class III furcations in the CT scan were detected clinically. Best correlation of CBCT and clinical probing = buccal sites at the mandible and the maxilla.
Mealey et al., 1994 ⁴⁰ USA	Retrospective study	274 furcations from 67 patients	Three board certified periodontists	Straight PCPUNC15 periodontal probe Curved coloured Nabers probe Intrasurgical measurements served as control	OFS	Compared baseline probing with bone sounding. Use of sounding significantly improved the mean accuracy of vertical (2.40 mm) and horizontal (3.11 mm) furcation depth measurements relative to surgical determinations ($p = 0.000$). Surgical vertical depth was similar as pre-anesthesia probing in 42% of furcations, within ± 1 mm in 72.3% and within ± 2 mm in 83.6%. Use of post anesthesia sounding improved agreement in vertical measurements to 59.5%, 85.7%, and 93.1%, respectively. Surgical horizontal depth was similar as pre-anesthesia probing measurements in 47.1% of furcations, within ± 1 mm in 68.3% and within ± 2 mm in 77.4%. Sounding improved agreement of horizontal measurements to 64.2%, 83.6%, and 88.3%, respectively. Underestimation of surgical furcation depths by pre-anesthesia probing was much more common than overestimation. Sounding reduced the percent and degree of underestimation in all furcation types.

(Continued)

Table 1 (Continued)

<i>Study/Country</i>	<i>Type of study</i>	<i>Sample size</i>	<i>Examiners</i>	<i>Furcation assessment methods</i>	<i>Method used as a gold- standard for comparison</i>	<i>Principal findings</i>
Qiao et al., 2015 ⁴¹ China	Prospective study	15 patients 20 maxillary molars	Two blinded radiographers for CBCT assessment No mention for clinical assessment	Pre-surgical measurements (Nabers probe, PCPUNC-15 probe) CBCT Intrasurgical measurements	OFS	Agreement CBCT/OFS = 82.4% Overestimation CBCT/OFS = 5.9% Underestimation CBCT/OFS = 11.8% Agreement Pre-surgical probing/ OFS = 21.6% Overestimation Pre-surgical probing/ OFS = 33.3% Underestimation Pre-surgical probing/ OFS = 11.8% The agreement between both assessments was the highest in buccal furcation entrances, followed by distopalatal and mesiopalatal furcation entrances. Horizontal bone loss and vertical bone loss were underestimated by CBCT relative to their respective intrasurgical classifications.
Ross and Thomson, 1980 ⁴² USA	Prospective study	72 patients 615 molars	One trained periodontist	Periodontal pocket probe and N°17 explorer Periapical radiographs and bite wings	Clinical probing	FI of molars was a common finding and occurred much more frequently than anticipated. FI occurred three times more frequently among maxillary molars than among mandibular molars. FI was detected more frequently in maxillary molars by radiographic examination than by clinical examination (22% vs 3%). FI was detected more frequently in mandibular molars by clinical examination than by radiographic examination (9% vs 8%).
Walter <i>et al.</i> , 2009 Switzerland	Retrospective study	12 patients 22 maxillary molars	Two trained periodontists	Conventional periodontal diagnosis: Clinical examination (Nabers probe, PCPUNC-15 probe) and peri-apical radiographs CBCT	CBCT	Agreement clinical probing / CBCT = 27% Overestimation Clinical probing /CBCT = 29% Underestimation clinical probing /CBCT = 44% Among FI degree I, underestimation = 25% Among FI degree II and degree II-III, underestimation = 75% CBCT accuracy for class III detection = 100% Discrepancies between clinically and CBCT-based therapeutic treatment approaches were found in 59–82% of the teeth, depending on whether the less invasive or the most invasive treatment recommendation was selected for comparison.

(Continued)

Table 1 (Continued)

<i>Study/Country</i>	<i>Type of study</i>	<i>Sample size</i>	<i>Examiners</i>	<i>Furcation assessment methods</i>	<i>Method used as a gold- standard for comparison</i>	<i>Principal findings</i>
Walter et al., 2010 ⁴³ Switzerland	Retrospective study	14 patients 25 maxillary molars	Two trained periodontists	Intrasurgical furcation involvement assessment CBCT images	CBCT	Agreement CBCT with OFS = 84% Underestimation CBCT/OFS = 14.7% Overestimation CBCT/OFS = 1.3% The agreement between both assessments was the highest in distopalatal furcation entrances, followed by buccal and mesiopalatal.
Yusof et al., 2021 ⁴⁴ Malaysia	Parallel single blinded RCT	22 patients	Two trained and calibrated examiners for clinical examination two trained and calibrated examiners for radiographic examination	CBCT Periapical radiographs Intrasurgical measurements (OFS)	OFS	This study proposed and evaluated five parameters that represent the extent and severity of furcation defects in molars teeth, including CEJ-BD (clinical attachment loss), BL-H (depth), BL-V (height), RT (root trunk), and FW (width). No statistically significant differences between CBCT and intrasurgical linear measurements for any clinical parameter. However, there were statistically significant differences in BL-V measurements ($p < 0.05$) between periapical and intrasurgical measurements in maxillary molars. Sensitivity: <ul style="list-style-type: none"> • CBCT = 62.8% • Periapical radiographs = 56.9% When compared to the intrasurgical measurements, CBCT provided better diagnostic, sensitivity, and quantitative information on CAL, height, depth, and width of the furcation defects than periapical radiograph.
Zappa et al., 1993 ⁴⁵ Switzerland	Prospective study	12 patients	Six dentists: two certified periodontists Two first years graduate students in periodontics two dentists not primarily working in periodontics	Clinical assessment of furcation involvement with Ramfjord index (2 mm) and Hamp index (3 mm) using calibrated and uncalibrated Nabers two probes Intrasurgical assessment (OFS) served as control	OFS	A total of 1180 clinical furcation diagnoses were available, of which 426 could be surgically evaluated using both the straight probe and the impressions. These evaluations were done in a total of 72 furcations using probe and impressions. two indexes are used for evaluation. Overestimation with Ramfjord index: <ul style="list-style-type: none"> • Class I = 5% • Class II = 40% • Class III = 43% Overestimation with Hamp index: <ul style="list-style-type: none"> • Class I = 7% • Class II = 24% • Class III = 0% For FI class III: <ul style="list-style-type: none"> • 43% are not recognized with the Ramfjord index • 27% are not recognized when using the Hamp index

(Continued)

Table 1 (Continued)

<i>Study/Country</i>	<i>Type of study</i>	<i>Sample size</i>	<i>Examiners</i>	<i>Furcation assessment methods</i>	<i>Method used as a gold-standard for comparison</i>	<i>Principal findings</i>
Zhang et al., 2018 ⁴⁶ USA	Retrospective Study	83 patients (Furcation involvement was assessed in maxillary and mandibular first molars)	Pre-doctoral dental students for clinical measurements one trained first year dental student for CBCT and intraoral radiographs examination	Comprehensive periodontal assessment Intraoral peri-apical and/or Bite-wing radiograph (parallel technique) CBCT	CBCT	There were significant correlations ($p < 0.05$) at all measurements sites between: <ul style="list-style-type: none"> clinical detection and intraoral radiography clinical detection and CBCT intraoral radiography and CBCT CBCT generally exhibited higher correlation with clinical detection relative to intraoral radiography, especially at distal palatal side-of maxillary first molar ($p < 0.05$). CBCT provided more accurate assessment, with bone loss measurement up to two decimals in millimeter, whereas clinical detection had three classes and the intraoral radiographs usually only detected the presence of furcation involvement in Glickman Class 2 and 3.

CAL, clinical attachment level; CBCT, cone beam CT; FI, furcation involvement; IO, intraoral radiograph; OPG, orthopantomogram.

degree of FI, Darby et al observed a highest agreement for Class I (65%) and the lowest for Class II (20%) when Class III displayed 29% of agreement.²⁸ The agreement found for Class III by Darby et al is in concordance with Laky et al (32%) and Graetz et al (31.9%).^{34,39} The localization of the furcation entrance also played a role in the agreement between furcation probing and CBCT readings. The highest agreement was found for buccal sites

Table 2 Range of agreement, overestimation and underestimation between diagnostic methods

Probing vs CBCT	
Agreement	29–56%
Overestimation	21–58%
Underestimation	20–44%
Probing vs OFS	
Agreement	21.6–87%
Overestimation	14.8–33.3%
OPG vs OFS or CBCT	
Agreement	43.3–63%
Overestimation	12.8–21.8%
Underestimation	32.3–34.9%
IO vs OFS or CBCT	
Agreement	38.7–83.1%
Overestimation	12.7–16%
Underestimation	0.9–38.9%
CBCT vs OFS	
Agreement	82.4–84%
Overestimation	1.3–5.9%
Underestimation	11.7–14.7%

CBCT, cone beam CT; IO, intraoral radiograph; OFS, open flap surgery.

(62%), followed by lingual sites (57%), mesial sites (56%) and distal sites (49%).³⁹

Furcation probing tend to overestimate the degree of FI in 21 to 58% of the cases. Walter et al found an overall overestimation of 29% and underlined the influence of the degree of FI.^{28,39} Indeed, Class I was more prone to overestimation (55%) than Class II (38%) and Class III (16%).⁵¹ The localization of the furcation entrance influenced also the degree of overestimation. Distal sites were more prone to overestimation (31%) followed by lingual sites (26%), mesial sites (21%) and buccal sites (18%).³⁹ Interestingly, Cimbaljevic et al did not find any overestimation of clinical measurements, either in the maxilla nor in the mandible.²⁷ Regarding the underestimation of furcation probing, it ranged between 20 and 44%.^{27,28,39,51} FI Class III were more prone to underestimation (86%) than Class II (62%) and Class I (25%).⁵¹

Magnetic resonance imaging: Two studies explored the use of dental magnetic resonance imaging (dMRI) and non-contrast enhanced dental magnetic resonance imaging (NCE-dMRI) for the assessment of FI and compared them with CBCT.^{36,54} dMRI and NCE-dMRI showed high agreement with CBCT. The sensitivity of detection ranged from 98 to 99% for the two techniques and the specificity goes from 99 to 100%. The agreement between dMRI and CBCT was 89%/84%/100% for horizontal Class I/II/III respectively. Between NCE-dMRI and CBCT, the agreement was 88%/89%/100% for horizontal Class I/II/III respectively).

Discussion

An accurate diagnosis of FI is of importance while establishing a treatment plan in periodontally compromised patients and can significantly influence the decision for tooth extraction or conservative approaches. However, precise characterization of lesion located at such specific anatomic zone could be challenging. While probing remains the gold-standard, several clinical tools were suggested including imaging techniques to determine the presence and extent of the FI.

As observed in this review, the agreement between all radiographic techniques and clinical measurements is highly heterogeneous. This could be explained by several parameters including the level of horizontal destruction (*i.e.* FI Class II, II or III), the type of probe used for examination and the localization of the furcation entrance with the distopalatal entrance being the most difficult to assess.^{31,33,34,41} Nevertheless, it is of importance to mention that, prior to periodontal treatment, the clinical evaluation of FI is based on the measure of the horizontal and vertical clinical attachment while radiological examination and OFS assess the level of the bone, therefore making the comparison between clinical and radiological examination questionable. Furthermore, IO can only detect the presence or absence of FI while its full description should combine both vertical and horizontal evaluation, those being assessed with probing, OFS or CBCT.

When it comes to treatment, for decision-making and treatment planning, FI characterization needs to be completed with the assessment of the residual bone support and the evaluation of the root morphology. Without this information, OFS may reveal unexpected findings, which could induce modification of the treatment plan during the surgery.

Because the clinician is relatively blind to the root morphology from clinical assessment alone, the availability of CBCT for detection and characterization of FI may be advantageous. The use of CBCT significantly improves the accuracy of furcation diagnosis.^{38,41,43,55} CBCT analyses can identify several morphologic variations and pathologic observations pertinent to the decision-making process, including, root trunk length and the degree of root separation, fusion of partial or the entire surface of the adjacent roots, reduced interdental space, concomitant periapical pathology, the presence of combined contiguous periodontal–endodontic lesions, root perforation, fenestration and inadequate root canal obturation.⁵⁶

Giving the impact of horizontal and vertical FI on long-term molar survival; but also the importance of the degree of FI, the role played by furcation anatomy and bone defect morphology in the decision-making for treatment, 3D imaging is of interest for prognosis evaluation, surgical planning and chair time saving compared to treatment planning based on conventional clinical and radiological diagnosis which will

require the clinician to adapt during the surgical procedure.^{14,20–22,53,56–58}

Although CBCT is a promising technology for periodontal diagnosis and treatment planning, its effective radiation doses are still higher than in conventional OPG and IO radiographs.^{59,60} Like all other diagnostic radiology procedures, CBCT exposes organs and sensitive tissues in the head and neck region, such as the eye lens, thyroid gland, parotid glands and occipital region to radiation. However, the CBCT dose can be optimized depending on the device, field of view and factors of the selected technique such as: exposure time per images, kV and mA settings.⁶¹ Thus, it was found that depending on the scan mode, the radiation dose of a CBCT is about 3–6 times an OPG, 8–14 times an IO radiograph and it is comparable to a full-mouth radiographic examination.^{62,63} Furthermore, it should be remembered that dental restorations containing metal alloys can be a source of artefacts (*e.g.* extinction artefacts, beam hardening) that may interfere with the diagnostic process performed on CBCT.⁶⁴

To overcome the exposure to ionizing radiations, some authors proposed the use of dMRI or NCE-dMRI for three-dimensional diagnosis of furcation exposure.^{36,54} Even if the contrasted and the non-contrasted technique exhibit high correlation with CBCT measurements, the authors highlighted some limitations such as: the higher cost of MRI devices compared to CBCT, the need of intravenous administration of contrasting agent, the spatial resolution of dMRI and NCE-dMRI who are still lower compared to CBCT and the overall examination time which range between 25 and 30 min. However, the number of available data is still low and more studies are clearly needed.

To fully characterize the lesion, its horizontal and vertical dimension should be considered; therefore, as a limitation, only a few studies reported both characteristics.^{30,31,44}

It was recently highlighted that vertical subclassification is of importance to predict long-term molar survival.^{21,22} However, more than the prognosis 3D imaging, in addition to clinical measurements, can be relevant in surgical planning to evaluate key parameters of the defect morphology than can have an impact on the outcomes such as the depth and the width of the defect, or the number of bony walls; especially when regenerative or resective surgery is considered.^{65–67}

Finally, regarding FI management, the true challenge for the clinician is to set an individual tooth prognosis and evaluate the need for surgery of such teeth. While Nabers probe remains the gold-standard to diagnose precisely FI, two-dimension radiological parameters, such as residual bone support, presence of infrabony defects, tooth mobility, pulp vitality, root anatomy and periodontal pocket depth overall will help the clinician in the decision-making process.^{14,20,58,68–71}

Future studies should incorporate this parameter to assess clinical value of all radiological procedures. Another potential limitation is that in almost all included studies FI assessment was performed by experienced clinicians and/or trained periodontists. The experience of the examiner has been demonstrated as a potential bias decreasing the potential of generalization of the results to the whole population of dentists.

Conclusion

To our knowledge, this review is the first to provide comparisons between different diagnosis tools and indexes to correctly identify furcation defects, that may help the clinician in establishing the diagnosis and

treatment plan of such lesions. Clinical and conventional radiographic examination have some limitations that will require the clinician to adapt during treatment. Indeed, the use of radiological examination, especially 3D imaging, may be of interest to detect early bone destruction in the furcation area, for prognosis evaluation and for decision-making and treatment planning. Nevertheless, the use of CBCT needs to be carefully justified by weighing up the benefit–risk ratio. However, the additional radiation risk of radiographic examination is justified, as long as the outcome of the treatment provided can be improved and the fundamental principle for diagnostic radiology known by the acronym ALARA (As Low As Reasonably Achievable) is respected.^{63,72}

REFERENCES

- Kinane DF, Stathopoulou PG, Papapanou PN. Periodontal diseases. *Nat Rev Dis Primers* 2017; **3**: 17038. <https://doi.org/10.1038/nrdp.2017.38>
- Tonetti MS, Greenwell H, Kornman KS. Staging and grading of periodontitis: framework and proposal of a new classification and case definition. *J Clin Periodontol* 2018; **45 Suppl 20**: S149–61. <https://doi.org/10.1111/jcpe.12945>
- Genco RJ, Borgnakke WS. Risk factors for periodontal disease. *Periodontol* 2000 2013; **62**: 59–94. <https://doi.org/10.1111/j.1600-0757.2012.00457.x>
- Hajishengallis G, Darveau RP, Curtis MA. The keystone-pathogen hypothesis. *Nat Rev Microbiol* 2012; **10**: 717–25. <https://doi.org/10.1038/nrmicro2873>
- Cobb CM. Clinical significance of non-surgical periodontal therapy: an evidence-based perspective of scaling and root planing. *J Clin Periodontol* 2002; **29 Suppl 2**: 6–16.
- Heitz-Mayfield LJA, Lang NP. Surgical and nonsurgical periodontal therapy. *Learned and Unlearned Concepts Periodontol* 2000; **62**: 218–31.
- Haffajee AD, Teles RP, Socransky SS. The effect of periodontal therapy on the composition of the subgingival microbiota. *Periodontol* 2000 2006; **42**: 219–58. <https://doi.org/10.1111/j.1600-0757.2006.00191.x>
- Tomasi C, Leyland AH, Wennström JL. Factors influencing the outcome of non-surgical periodontal treatment: a multilevel approach. *J Clin Periodontol* 2007; **34**: 682–90. <https://doi.org/10.1111/j.1600-051X.2007.01111.x>
- Chace R, Low SB. Survival characteristics of periodontally-involved teeth: a 40-year study. *J Periodontol* 1993; **64**: 701–5. <https://doi.org/10.1902/jop.1993.64.8.701>
- Loos B, Nyland K, Claffey N, Egelberg J. Clinical effects of root debridement in molar and non-molar teeth. A 2-year follow-up. *J Clin Periodontol* 1989; **16**: 498–504. <https://doi.org/10.1111/j.1600-051x.1989.tb02326.x>
- Nordland P, Garrett S, Kiger R, Vanooteghem R, Hutchens LH, Egelberg J, et al. The effect of plaque control and root debridement in molar teeth. *J Clin Periodontol* 1987; **14**: 231–36. <https://doi.org/10.1111/j.1600-051x.1987.tb00972.x>
- Hamp SE, Nyman S, Lindhe J. Periodontal treatment of multirooted teeth. results after 5 years. *J Clin Periodontol* 1975; **2**: 126–35. <https://doi.org/10.1111/j.1600-051x.1975.tb01734.x>
- Tarnow D, Fletcher P. Classification of the vertical component of furcation involvement. *J Periodontol* 1984; **55**: 283–84. <https://doi.org/10.1902/jop.1984.55.5.283>
- Huynh-Ba G, Kuonen P, Hofer D, Schmid J, Lang NP, Salvi GE, et al. The effect of periodontal therapy on the survival rate and incidence of complications of multirooted teeth with furcation involvement after an observation period of at least 5 years: a systematic review. *J Clin Periodontol* 2009; **36**: 164–76. <https://doi.org/10.1111/j.1600-051X.2008.01358.x>
- Jepsen S, Gennai S, Hirschfeld J, Kalemaj Z, Buti J, Graziani F, et al. Regenerative surgical treatment of furcation defects: A systematic review and bayesian network meta-analysis of randomized clinical trials. *J Clin Periodontol* 2020; **47 Suppl 22**: 352–74. <https://doi.org/10.1111/jcpe.13238>
- Svärdström G, Wennström JL. Periodontal treatment decisions for molars: an analysis of influencing factors and long-term outcome. *J Periodontol* 2000; **71**: 579–85. <https://doi.org/10.1902/jop.2000.71.4.579>
- Dannewitz B, Zeidler A, Hüsing J, Saure D, Pfefferle T, Eickholz P, et al. Loss of molars in periodontally treated patients: results 10 years and more after active periodontal therapy. *J Clin Periodontol* 2016; **43**: 53–62. <https://doi.org/10.1111/jcpe.12488>
- Graetz C, Schützhold S, Plaumann A, Kahl M, Springer C, Sälzer S, et al. Prognostic factors for the loss of molars—an 18-years retrospective cohort study. *J Clin Periodontol* 2015; **42**: 943–50. <https://doi.org/10.1111/jcpe.12460>
- Nibali L, Zavattini A, Nagata K, Di Iorio A, Lin G-H, Needleman I, et al. Tooth loss in molars with and without furcation involvement - a systematic review and meta-analysis. *J Clin Periodontol* 2016; **43**: 156–66. <https://doi.org/10.1111/jcpe.12497>
- Salvi GE, Mischler DC, Schmidlin K, Matuliene G, Pjetursson BE, Brägger U, et al. Risk factors associated with the longevity of multi-rooted teeth. long-term outcomes after active and supportive periodontal therapy. *J Clin Periodontol* 2014; **41**: 701–7. <https://doi.org/10.1111/jcpe.12266>
- Tonetti MS, Christiansen AL, Cortellini P. Vertical subclassification predicts survival of molars with class II furcation involvement during supportive periodontal care. *J Clin Periodontol* 2017; **44**: 1140–44. <https://doi.org/10.1111/jcpe.12789>
- Nibali L, Sun C, Akcalı A, Yeh Y-C, Tu Y-K, Donos N, et al. The effect of horizontal and vertical furcation involvement on molar survival: A retrospective study. *J Clin Periodontol* 2018; **45**: 373–81. <https://doi.org/10.1111/jcpe.12850>
- Sanz M, Herrera D, Kebschull M, Chapple I, Jepsen S, Beglundh T, et al. Treatment of stage I-III periodontitis—the EFP S3 level clinical practice guideline. *J Clin Periodontol* 2020; **47 Suppl 22**: 4–60. <https://doi.org/10.1111/jcpe.13290>
- Schwendicke F, Plaumann A, Stolpe M, Dörfer CE, Graetz C. Retention costs of periodontally compromised molars in a german population. *J Clin Periodontol* 2016; **43**: 261–70. <https://doi.org/10.1111/jcpe.12509>

25. Ramfjord SP, Ash MM. Periodontology and periodontics. 1979.
26. Glickman I. Clinical Periodontology: Prevention, Diagnosis, and Treatment of Periodontal Disease in the Practice of General Dentistry. 4th ed. (1972).
27. Cimballejic M et al. Clinical and CBCT-based diagnosis of furcation involvement in patients with severe periodontitis. *Quintessence Int Berl Ger* 1985; **46**: 863–70.
28. Darby I, Sanelli M, Shan S, Silver J, Singh A, Soedjono M, et al. Comparison of clinical and cone beam computed tomography measurements to diagnose furcation involvement. *Int J Dent Hyg* 2015; **13**: 241–45. <https://doi.org/10.1111/idh.12116>
29. Deas DE, Moritz AJ, Mealey BL, McDonnell HT, Powell CA. Clinical reliability of the “furcation arrow” as a diagnostic marker. *J Periodontol* 2006; **77**: 1436–41. <https://doi.org/10.1902/jop.2006.060034>
30. Eickholz P. Reproducibility and validity of furcation measurements as related to class of furcation invasion. *J Periodontol* 1995; **66**: 984–89. <https://doi.org/10.1902/jop.1995.66.11.984>
31. Eickholz P, Kim TS. Reproducibility and validity of the assessment of clinical furcation parameters as related to different probes. *J Periodontol* 1998; **69**: 328–36. <https://doi.org/10.1902/jop.1998.69.3.328>
32. Eickholz P, Staehle HJ. The reliability of furcation measurements. *J Clin Periodontol* 1994; **21**: 611–14. <https://doi.org/10.1111/j.1600-051x.1994.tb00752.x>
33. Eickholz P, Steinbrenner H, Lenhard M, Marquardt M, Holle R. Interexaminer reliability of the assessment of clinical furcation parameters as related to different probes. *Eur J Oral Sci* 1999; **107**: 2–8. <https://doi.org/10.1046/j.0909-8836.1999.eos107102.x>
34. Graetz C, Plaumann A, Wiebe J-F, Springer C, Sälzer S, Dörfer CE, et al. Periodontal probing versus radiographs for the diagnosis of furcation involvement. *J Periodontol* 2014; **85**: 1371–79. <https://doi.org/10.1902/jop.2014.130612>
35. Cimoës R, Gusmão E, Picarte ACC, Bené Barbosa MB, Rösing C. Correlation between clinical and radiographic findings on the occurrence of furcation involvement in patients with periodontitis. *Indian J Dent Res* 2014; **25**: 572. <https://doi.org/10.4103/0970-9290.147086>
36. Juerchott A, Sohani M, Schwindling FS, Jende JME, Kurz FT, Rammelsberg P, et al. Comparison of non-contrast-enhanced dental magnetic resonance imaging and cone-beam computed tomography in assessing the horizontal and vertical components of furcation defects in maxillary molars: an in vivo feasibility study. *J Clin Periodontol* 2020; **47**: 1485–95. <https://doi.org/10.1111/jcpe.13374>
37. Kim TS, Knittel M, Staehle HJ, Eickholz P. The reproducibility and validity of furcation measurements using a pressure-calibrated probe. *J Clin Periodontol* 1996; **23**: 826–31. <https://doi.org/10.1111/j.1600-051x.1996.tb00619.x>
38. Komšić S, Plančak D, Kašaj A, Puhar I. A comparison of clinical and radiological parameters in the evaluation of molar furcation involvement in periodontitis. *Acta Stomatol Croat* 2019; **53**: 326–36. <https://doi.org/10.15644/asc53/4/3>
39. Laky M, Majdalani S, Kapferer I, Frantal S, Gahleitner A, Moritz A, et al. Periodontal probing of dental furcations compared with diagnosis by low-dose computed tomography: a case series. *J Periodontol* 2013; **84**: 1740–46. <https://doi.org/10.1902/jop.2013.120698>
40. Mealey BL, Neubauer MF, Butzin CA, Waldrop TC. Use of furcal bone sounding to improve accuracy of furcation diagnosis. *J Periodontol* 1994; **65**: 649–57. <https://doi.org/10.1902/jop.1994.65.7.649>
41. Qiao J, Wang S, Duan J, Zhang Y, Qiu Y, Sun C, et al. The accuracy of cone-beam computed tomography in assessing maxillary molar furcation involvement. *J Clin Periodontol* 2014; **41**: 269–74. <https://doi.org/10.1111/jcpe.12150>
42. Ross IF, Thompson RH. Furcation involvement in maxillary and mandibular molars. *J Periodontol* 1980; **51**: 450–54. <https://doi.org/10.1902/jop.1980.51.8.450>
43. Walter C, Weiger R, Zitzmann NU. Accuracy of three-dimensional imaging in assessing maxillary molar furcation involvement. *J Clin Periodontol* 2010; **37**: 436–41. <https://doi.org/10.1111/j.1600-051X.2010.01556.x>
44. Yusof NAM, Noor E, Reduwan NH, Yusof MYPM. Diagnostic accuracy of periapical radiograph, cone beam computed tomography, and intrasurgical linear measurement techniques for assessing furcation defects: a longitudinal randomised controlled trial. *Clin Oral Investig* 2021; **25**: 923–32. <https://doi.org/10.1007/s00784-020-03380-8>
45. Zappa U, Grosso L, Simona C, Graf H, Case D. Clinical furcation diagnoses and interradicular bone defects. *J Periodontol* 1993; **64**: 219–27. <https://doi.org/10.1902/jop.1993.64.3.219>
46. Zhang W, Foss K, Wang B-Y. A retrospective study on molar furcation assessment via clinical detection, intraoral radiography and cone beam computed tomography. *BMC Oral Health* 2018; **18**(1): 75. <https://doi.org/10.1186/s12903-018-0544-0>
47. Molander B, Ahlqwist M, Gröndahl HG, Hollender L. Agreement between panoramic and intra-oral radiography in the assessment of marginal bone height. *Dentomaxillofac Radiol* 1991; **20**: 155–60. <https://doi.org/10.1259/dmfr.20.3.1808000>
48. Gürkan C, Gröndahl K, Wennström JL. Radiographic detectability of bone loss in the bifurcation of mandibular molars: an experimental study. *Dentomaxillofac Radiol* 1994; **23**: 143–48. <https://doi.org/10.1259/dmfr.23.3.7835514>
49. Hishikawa T, Izumi M, Naitoh M, Furukawa M, Yoshinari N, Kawase H, et al. The effect of horizontal X-ray beam angulation on the detection of furcation defects of mandibular first molars in intraoral radiography. *Dentomaxillofac Radiol* 2010; **39**: 85–90. <https://doi.org/10.1259/dmfr/99338642>
50. Hardekopf JD, Dunlap RM, Ahl DR, Pelleu GB. The “furcation arrow”. A reliable radiographic image? *J Periodontol* 1987; **58**: 258–61. <https://doi.org/10.1902/jop.1987.58.4.258>
51. Walter C, Kaner D, Berndt DC, Weiger R, Zitzmann NU. Three-dimensional imaging as a pre-operative tool in decision making for furcation surgery. *J Clin Periodontol* 2009; **36**: 250–57. <https://doi.org/10.1111/j.1600-051X.2008.01367.x>
52. Rinne CA, Dagassan-Berndt DC, Connor T, Müller-Gerbl M, Weiger R, Walter C, et al. Impact of CBCT image quality on the confidence of furcation measurements. *J Clin Periodontol* 2020; **47**: 816–24. <https://doi.org/10.1111/jcpe.13298>
53. Walter C, Weiger R, Dietrich T, Lang NP, Zitzmann NU. Does three-dimensional imaging offer A financial benefit for treating maxillary molars with furcation involvement? A pilot clinical case series. *Clin Oral Implants Res* 2012; **23**: 351–58. <https://doi.org/10.1111/j.1600-0501.2011.02330.x>
54. Juerchott A, Sohani M, Schwindling FS, Jende JME, Kurz FT, Rammelsberg P, et al. In vivo accuracy of dental magnetic resonance imaging in assessing maxillary molar furcation involvement: A feasibility study in humans. *J Clin Periodontol* 2020; **47**: 809–15. <https://doi.org/10.1111/jcpe.13299>
55. Fuhrmann RA, Bucker A, Diedrich PR. Furcation involvement: comparison of dental radiographs and HR-CT-slices in human specimens. *J Periodontol Res* 1997; **32**: 409–18. <https://doi.org/10.1111/j.1600-0765.1997.tb00553.x>
56. Scarfe WC, Azevedo B, Pinheiro LR, Priaminiarti M, Sales MAO. The emerging role of maxillofacial radiology in the diagnosis and management of patients with complex periodontitis. *Periodontol 2000* 2017; **74**: 116–39. <https://doi.org/10.1111/prd.12193>
57. Walter C, Weiger R, Zitzmann NU. Periodontal surgery in furcation-involved maxillary molars revisited--an introduction of guidelines for comprehensive treatment. *Clin Oral Investig* 2011; **15**: 9–20. <https://doi.org/10.1007/s00784-010-0431-9>
58. Nunn ME, Fan J, Su X, Levine RA, Lee H-J, McGuire MK, et al. Development of prognostic indicators using classification and regression trees for survival. *Periodontology* 2000 2012; **58**: 134–42. <https://doi.org/10.1111/j.1600-0757.2011.00421.x>
59. Batista WOG, Navarro MVT, Maia AF. Effective doses in panoramic images from conventional and CBCT equipment. *Radiat Prot Dosimetry* 2012; **151**: 67–75. <https://doi.org/10.1093/rpd/nrc454>

60. Thilander-Klang A, Helmrot E. Methods of determining the effective dose in dental radiology. *Radiat Prot Dosimetry* 2010; **139**: 306–9. <https://doi.org/10.1093/rpd/ncq081>
61. Ludlow JB, Davies-Ludlow LE, Brooks SL, Howerton WB. Dosimetry of 3 CBCT devices for oral and maxillofacial radiology: CB mercuray, newtom 3G and i-CAT. *Dentomaxillofac Radiol* 2006; **35**: 219–26. <https://doi.org/10.1259/dmfr/14340323>
62. Signorelli L, Patcas R, Peltomäki T, Schätzle M. Radiation dose of cone-beam computed tomography compared to conventional radiographs in orthodontics. *J Orofac Orthop* 2016; **77**: 9–15. <https://doi.org/10.1007/s00056-015-0002-4>
63. Vandenberghe B, Jacobs R, Yang J. Detection of periodontal bone loss using digital intraoral and cone beam computed tomography images: an in vitro assessment of bony and/or infrabony defects. *Dentomaxillofac Radiol* 2008; **37**: 252–60. <https://doi.org/10.1259/dmfr/57711133>
64. Schulze R, Heil U, Gross D, Bruellmann DD, Dranischnikow E, Schwanecke U, et al. Artefacts in CBCT: a review. *Dentomaxillofac Radiol* 2011; **40**: 265–73. <https://doi.org/10.1259/dmfr/30642039>
65. Tonetti MS, Pini-Prato G & Cortellini P. Periodontal regeneration of human intrabony defects. IV. Determinants of healing response. *J Periodontol*. 64, 934–940 (1993).
66. Tonetti MS, Prato GP, Cortellini P. Factors affecting the healing response of intrabony defects following guided tissue regeneration and access flap surgery. *J Clin Periodontol* 1996; **23**: 548–56. <https://doi.org/10.1111/j.1600-051x.1996.tb01823.x>
67. Silvestri M, Sartori S, Rasperini G, Ricci G, Rota C, Cattaneo V, et al. Comparison of infrabony defects treated with enamel matrix derivative versus guided tissue regeneration with a nonresorbable membrane. *J Clin Periodontol* 2003; **30**: 386–93. <https://doi.org/10.1034/j.1600-051x.2003.10146.x>
68. Faggion CM, Petersilka G, Lange DE, Gerss J, Flemmig TF. Prognostic model for tooth survival in patients treated for periodontitis. *J Clin Periodontol* 2007; **34**: 226–31. <https://doi.org/10.1111/j.1600-051X.2006.01045.x>
69. Matulienė G, Pjetursson BE, Salvi GE, Schmidlin K, Brägger U, Zwahlen M, et al. Influence of residual pockets on progression of periodontitis and tooth loss: results after 11 years of maintenance. *J Clin Periodontol* 2008; **35**: 685–95. <https://doi.org/10.1111/j.1600-051X.2008.01245.x>
70. Rosling B, Nyman S, Lindhe J. The effect of systematic plaque control on bone regeneration in infrabony pockets. *J Clin Periodontol* 1976; **3**: 38–53. <https://doi.org/10.1111/j.1600-051x.1976.tb01849.x>
71. Lindhe J, Socransky SS, Nyman S, Haffajee A, Westfelt E. “Critical probing depths” in periodontal therapy. *J Clin Periodontol* 1982; **9**: 323–36. <https://doi.org/10.1111/j.1600-051x.1982.tb02099.x>
72. Farman AG. ALARA still applies. *Oral Surg Oral Med Oral Pathol Oral Radiol Endod* 2005; **100**: 395–97. <https://doi.org/10.1016/j.tripleo.2005.05.055>