



HAL
open science

Tau-PET imaging predicts cognitive decline and brain atrophy progression in early Alzheimer's disease

Julien Lagarde, Pauline Olivieri, Matteo Tonietto, Cecile Tissot, Isabelle Rivals, Philippe Gervais, Fabien Caillé, Martin Mousson, Michel Bottlaender, Marie Sarazin

► To cite this version:

Julien Lagarde, Pauline Olivieri, Matteo Tonietto, Cecile Tissot, Isabelle Rivals, et al.. Tau-PET imaging predicts cognitive decline and brain atrophy progression in early Alzheimer's disease. *Journal of Neurology, Neurosurgery and Psychiatry*, 2022, 93 (5), pp.459-467. 10.1136/jnnp-2021-328623 . hal-04018138

HAL Id: hal-04018138

<https://hal.science/hal-04018138v1>

Submitted on 7 Mar 2023

HAL is a multi-disciplinary open access archive for the deposit and dissemination of scientific research documents, whether they are published or not. The documents may come from teaching and research institutions in France or abroad, or from public or private research centers.

L'archive ouverte pluridisciplinaire **HAL**, est destinée au dépôt et à la diffusion de documents scientifiques de niveau recherche, publiés ou non, émanant des établissements d'enseignement et de recherche français ou étrangers, des laboratoires publics ou privés.



Distributed under a Creative Commons Attribution 4.0 International License

Original research

Tau-PET imaging predicts cognitive decline and brain atrophy progression in early Alzheimer's disease

Julien Lagarde ^{1,2,3}, Pauline Olivieri ^{1,2,3}, Matteo Tonietto,³ Cecile Tissot,⁴ Isabelle Rivals,⁵ Philippe Gervais,³ Fabien Caillé,³ Martin Mousson,^{1,6} Michel Bottlaender,^{3,7} Marie Sarazin^{1,2,3}

► Additional supplemental material is published online only. To view, please visit the journal online (<http://dx.doi.org/10.1136/jnnp-2021-328623>).

For numbered affiliations see end of article.

Correspondence to

Dr Julien Lagarde, Department of Neurology of Memory and Language, GHU Paris Psychiatrie & Neurosciences, Hôpital Sainte-Anne, Paris, France; j.lagarde@ghu-paris.fr

Received 12 December 2021
Accepted 31 January 2022

ABSTRACT

Objectives To explore whether regional tau binding measured at baseline is associated with the rapidity of Alzheimer's disease (AD) progression over 2 years, as assessed by the decline in specified cognitive domains, and the progression of regional brain atrophy, in comparison with amyloid-positron emission tomography (PET), MRI and cerebrospinal fluid (CSF) biomarkers.

Methods Thirty-six patients with AD (positive CSF biomarkers and amyloid-PET) and 15 controls underwent a complete neuropsychological assessment, 3T brain MRI, [¹¹C]-PiB and [¹⁸F]-flortaucipir PET imaging, and were monitored annually over 2 years, with a second brain MRI after 2 years. We used mixed effects models to explore the relations between tau-PET, amyloid-PET, CSF biomarkers and MRI at baseline and cognitive decline and the progression of brain atrophy over 2 years in patients with AD.

Results Baseline tau-PET was strongly associated with the subsequent cognitive decline in regions that are usually associated with each cognitive domain. No significant relationship was observed between the cognitive decline and initial amyloid load, regional cortical atrophy or CSF biomarkers. Baseline tau tracer binding in the superior temporal gyrus was associated with subsequent atrophy in an inferomedial temporal volume of interest, as was the voxelwise tau tracer binding with subsequent cortical atrophy in the superior temporal, parietal and frontal association cortices.

Conclusions These results suggest that tau tracer binding is predictive of cognitive decline in AD in domain-specific brain areas, which provides important insights into the interaction between tau burden and neurodegeneration, and is of the utmost importance to develop new prognostic markers that will help improve the design of therapeutic trials.

INTRODUCTION

The *in vivo* diagnosis of cognitive neurodegenerative diseases remains challenging and relies on a combination of clinical, biological and imaging evidence. Molecular imaging by positron emission tomography (PET) enables the *in vivo* detection of certain proteinopathies and provides comparable pathophysiological evidence to cerebrospinal fluid (CSF) biomarkers, along with topographical information that biofluid markers lack. Beyond amyloid-PET imaging, *in vivo* detection of tau pathology is now possible.¹ [¹⁸F]-flortaucipir (formerly called

Key messages

What is already known on this topic

- Alzheimer's disease (AD) is very heterogeneous and is characterised by variable evolutions from one patient to another.
- We currently have no reliable marker for determining the prognosis and predicting cognitive decline.

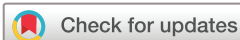What this study adds

- This study suggests that tau tracer binding is predictive of brain atrophy progression and more importantly of cognitive decline in distinct cortical regions according to the cognitive domains considered.

How this study might affect research, practice or policy

- These results are of the utmost importance for better understanding the clinical heterogeneity of AD and developing new prognostic markers that will help improve the design of therapeutic trials.

[¹⁸F]-AV-1451) binds selectively to tau lesions that are composed primarily of paired helical filaments, such as intraneuronal and extraneuronal tangles and dystrophic neurites.^{2,3} The field of Alzheimer's disease (AD) research also lacks reliable prognostic markers, which are necessary for predicting cognitive and functional decline to optimise patient care and adjust the design of therapeutic trials, as AD appears to be a very heterogeneous disease.⁴ Some studies suggest that higher CSF tau levels are associated with faster cognitive decline in AD,⁵ but this has not been consistently observed. The topographical information that is provided by tau-PET imaging, which could reflect the tau pathology that precedes neurodegeneration,⁶ leads to the consideration of this imaging method as a potential effective predictor of neurodegeneration and of subsequent cognitive decline. A recent study showed that the specific distribution of the tau-PET signal was a strong indicator of the topography of future brain atrophy in AD.⁷ Nevertheless, the prognostic value of tau-PET imaging for cognitive decline has rarely been studied,^{8–13} and most studies focused either on restricted brain regions of interest, or on global cognition, without any domain-specific cognitive evaluation.



© Author(s) (or their employer(s)) 2022. No commercial re-use. See rights and permissions. Published by BMJ.

To cite: Lagarde J, Olivieri P, Tonietto M, et al. *J Neurol Neurosurg Psychiatry* Epub ahead of print: [please include Day Month Year]. doi:10.1136/jnnp-2021-328623

In the present study, we aimed at exploring whether regional tau binding that was measured at baseline was associated with the rapidity of AD progression after 2 years of follow-up, which was assessed in terms of both (a) cognitive decline in specified cognitive domains and (b) the progression of regional brain atrophy. We hypothesised that (a) the initial tau load in specified brain areas is associated with decline in distinct cognitive domains according to the well-known neuroanatomical cognitive brain networks (temporal cortex with memory, parietal cortex with instrumental functions and frontal cortex with executive functions) and that (b) the regional tau load at baseline is associated with progression of regional cortical atrophy. To evaluate the 'specificity' of tau imaging as a predictor of cognitive decline and atrophy progression, we also analysed whether (a) initial regional cortical atrophy, as a non-specific marker of neuronal injury, (b) initial amyloid load, as a marker of AD amyloidosis and (c) initial AD CSF biomarkers, as biological pathophysiological markers without topographical information, were also associated with the rapidity of AD progression.

MATERIALS AND METHODS

Study design and participants

We included 51 participants from the Shatau7-Imatau study (NCT02576821-EudraCT2015-000257-20) recruited between March 2016 and November 2019.

Thirty-six patients who had been diagnosed with AD at the mild cognitive impairment or mild dementia stage were included according to the following criteria: (i) a CSF biomarker profile suggestive of AD (total tau (t-tau)/amyloid- β (A β 42) >0.52, which provided a sensitivity of 93% and a specificity of 83% in a previous publication¹⁴; (ii) [¹¹C]-PiB-PET Global Cortical Index (GCI) >1.45^{15 16} and (iii) Clinical Dementia Rating (CDR) scale \leq 1. Twenty-nine patients out of 36 took cholinesterase inhibitors and 2 of them also took N-methyl-D-aspartate antagonists. During the 2-year follow-up, treatment changes were very limited: cholinesterase inhibitors were discontinued in three patients, while they were introduced in three others.

Fifteen healthy elderly controls were included according to the following criteria: (i) Mini-Mental State Examination (MMSE) score \geq 27/30; (ii) normal neuropsychological assessment; (iii) CDR=0; (iv) no memory complaints and (v) negative PiB-PET imaging.

Subjects were not included if they had: (i) sleep apnoea; (ii) extrapyramidal signs or neurological history suggestive of other non-AD neurodegenerative diseases; (iii) systemic illnesses that could interfere with cognitive functioning or (iv) focal lesions on MRI that could interfere with cognition.

All participants underwent complete clinical and neuropsychological assessment, 3T brain MRI, [¹¹C]-PiB and [¹⁸F]-florataucipir PET imaging at baseline. Then, they were monitored annually for 2 years with the same clinical and neuropsychological assessments as performed at baseline and a second 3T MRI at the last visit.

Definition of the cognitive outcomes

Based on a previous work in which principal component analyses were conducted in an independent cohort,¹⁷ in addition to the MMSE, we defined (a) a verbal episodic memory score as the sum of the scores obtained for the free and cued immediate and delayed recalls of the free and cued selective reminding test¹⁸; (b) an instrumental score, defined as the sum of the scores obtained for word naming, gestural praxis and copying of the Rey-Osterrieth complex figure and (c) an executive

score defined as the sum of the scores obtained for the forward and backward digit spans, letter fluency (2 min) and similarities subtest of the Wechsler Adult Intelligence Scale III. These cognitive components showed significant correlations with MRI sulcal morphology parameters in corresponding neuroanatomical brain regions (memory in the temporal cortex, instrumental functions in the parietal cortex and executive functions in the frontal and parietal cortices).¹⁷

Definition of the MRI regional cortical atrophy outcomes

We used both the hippocampal volume and the cortical thickness (CT) in a temporal meta-volume of interest (VOI) that comprised the entorhinal cortices, the fusiform gyri and the inferior and middle temporal gyri¹⁹ as MRI outcomes. We also considered the whole-brain grey matter volume at the voxel level.

Biological assessment

As described in the inclusion criteria, all patients underwent a lumbar puncture. CSF concentrations of A β 42, t-tau and phosphorylated tau (p-tau181) were measured using ELISA with INNOSTEST assays (Fujirebio, Ghent, Belgium). Lumbar punctures were performed 1.8 \pm 1 year before the tau-PET exams. Blood samples were also drawn to determine the APOE genotype.

Magnetic resonance imaging

All subjects underwent MRI at the Centre de Neuro-Imagerie de Recherche (CENIR, ICM, Paris) using a 3T whole-body PRISMA 64-channel system (Siemens). Two years later, longitudinal MRI was performed for 31 patients and 14 controls. The MRI examination included a three-dimensional (3D) T1-weighted volumetric magnetisation-prepared rapid gradient echo (MP-RAGE) sequence (repetition time/echo time/flip angle: 2300 ms/3.43 ms/9°, inversion time=900 ms and voxel size: 1 \times 1 \times 1 mm³).

Volumetric segmentation of the cortex and hippocampus was automatically performed on the 3D T1-weighted MP-RAGE scans using the FreeSurfer 6.0.0 longitudinal processing stream (<http://surfer.nmr.mgh.harvard.edu/>).²⁰ The hippocampal volume measures were normalised to the individual intracranial volume, and we considered the mean value. Mean CT indices for 68 VOIs were also obtained. We considered a temporal meta-VOI as described above. Individual CT from each subregion of the meta-VOI were normalised by their surface area and averaged to obtain an individual thickness index for each participant.

Voxelwise maps of grey matter volume were obtained in MNI space; modulated by multiplying voxel values by non-linear components and smoothed with an 8 mm full-width at half-maximum (FWHM) Gaussian kernel using the voxel-based morphometry pipeline implemented in Computational Anatomy Toolbox (CAT12) via SPM12 software (<http://www.fil.ion.ucl.ac.uk/spm>).

[¹¹C]-PiB and [¹⁸F]-florataucipir PET imaging procedure

All subjects underwent [¹¹C]-PiB and [¹⁸F]-florataucipir PET within 4 months of baseline clinical assessment. MRI and PET scans were also performed within 4 months of each other. All PET examinations were performed at Service Hospitalier Frédéric Joliot (Orsay, CEA) on a high-resolution research tomograph (CTI/Siemens Molecular Imaging). PET acquisitions were performed at least between 40 and 60 min after injection of 338.9 \pm 56.8 MBq of [¹¹C]-PiB, and 80–100 min after injection of 373.3 \pm 30.9 MBq of [¹⁸F]-florataucipir.

The partial volume effect (PVE) was corrected by directly modelling the detector spatial resolution properties (point spread function modelling) in the image reconstruction algorithm,^{21 22} to realise

higher spatial resolution and, thus, reduced PVE without applying a standard partial volume correction technique.

Parametric images were created using BrainVisa software (<http://brainvisa.info>) on averaged images over 40–60 min after injection of [¹¹C]-PiB and over 80–100 min after injection of [¹⁸F]-flortaucipir. Standard uptake value ratio (SUVR) parametric images were obtained by dividing each voxel by the corresponding value for the eroded (4 mm) cerebellar grey matter to avoid including the superior part of the cerebellar vermis, which is a site of [¹⁸F]-flortaucipir off-target binding, and to avoid PVE from the CSF or occipital cortex. VOIs were defined as previously described.²³

For tau-PET imaging, we considered the following regions: (i) a temporal meta-VOI composed of the amygdala, parahippocampus, fusiform gyri, inferior and middle temporal cortices¹⁸; (ii) the temporal lobes; (iii) the parietal lobes and (iv) the frontal lobes. We used the mean of the values obtained on the left and right sides.

For amyloid-PET imaging, we calculated a [¹¹C]-PiB GCI that represents the mean SUVR of the subject's neocortical regions^{15 16} and also considered PiB binding in the precuneus and posterior cingulate.

The tau-PET and amyloid-PET parametric SUVR images were also normalised to MNI space and smoothed with an 8 mm FWHM Gaussian kernel.

Statistical analysis

Characteristics of the participants and voxelwise correlations at baseline

The data were analysed using R V.3.6.1 (R Core Team, 2017). Differences between patients with AD and controls at baseline were assessed using analysis of covariance, and the trajectories of cognitive decline or atrophy progression over 2 years in patients with AD and controls were compared using linear mixed effects models (interaction between the group, ie, AD or control, and time, with subjects as a random intercept). Age and education (for neuropsychological variables) or age and sex (for imaging variables) were included as covariates.

We studied the voxelwise comparison of cortical atrophy and tau load at baseline, and of the progression of cortical atrophy during the follow-up period between patients with AD and controls, as well as the voxelwise relationships between baseline cognitive variables and PET imaging or grey matter volume without any prespecified VOI in patients with AD by using VoxelStats V.1.1.²⁴ We used a regression design and included age and the cognitive profile as covariates.

Predictive study

For the predictive analyses, we considered the following as putative predictors: baseline tau-PET (in the four VOIs specified above), PiB-PET (GCI, precuneus and posterior cingulate), CSF biomarkers (A β 42, t-tau and p-tau181) and MRI (hippocampal volume and CT in the temporal meta-VOI). For the imaging predictors, we performed both VOI and voxelwise analyses.

The relationships between each putative predictor and cognitive progression over 2 years (in terms of MMSE, memory score, instrumental score and executive score) were analysed in patients with AD by using mixed effects models with the cognitive scores as dependent variables and age, sex, APOE genotype, CDR sum of boxes (SOB), the cognitive profile (degree of impairment in instrumental functions, which could have influenced our results by impacting other cognitive domains) and the delay between lumbar puncture and PET as fixed effects. The model also included the interactions between the predictors and time, which

were the regressors of interest. A subject effect was included as a random intercept in the model.

The same model was also used to study the relationships between baseline tau-PET, PiB-PET and CSF biomarkers and the evolution of the hippocampal and inferomedial temporal atrophy over 2 years.

Separate models were built for each predictor and we verified that the residues were normally distributed. We performed Bonferroni corrections within each predictor for $n = (\text{number of modalities of each predictor} \times \text{number of outcome measures})$ tests. The level of statistical significance was set at $p < 0.05$.

The mixed effects models that are described above were run at the voxel level by using VoxelStats V.1.1. We also ran the same mixed effects models with the individual voxelwise grey matter at baseline and after 2 years as dependent variables. A random field theory-based multiple comparison correction²⁵ was performed with a clusterwise threshold of $p < 0.001$ and a cluster-forming threshold of $p < 0.001$.

To further ensure that the disease severity, age and cognitive profile, which were considered covariates, did not influence our results, we repeated separate analyses in several subgroups: patients with a CDR score of 0.5 ($n = 27$), younger (< 70 years, $n = 19$) and older (≥ 70 years, $n = 17$) patients, and patients with relatively preserved instrumental functions ($n = 21$).

RESULTS

Characteristics of the participants and voxelwise correlations between cognition and tau-PET, amyloid-PET and grey matter volume at baseline

The subjects' clinical, cognitive and imaging characteristics at baseline and follow-up are summarised in [table 1](#). Only six patients with AD had a Fazekas score > 1 at baseline and only one of them progressed from Fazekas 2 to 3 during the follow-up. Among the patients with Fazekas 0 at baseline, only three progressed to Fazekas 1. All patients with Fazekas 1 at baseline who performed a second MRI remained stable. The voxelwise comparisons of cortical atrophy, tau load at baseline and of the progression of brain atrophy between patients with AD and controls are shown in the online supplemental figure 1. As expected, tau-PET tracer uptake is significantly higher in patients with AD than in controls in the temporoparietal and to a lesser extent frontal associative cortex.

We found a negative correlation between the instrumental score and tau-PET tracer uptake in the right medial parieto-occipital cortex. Correlations with the MMSE and memory or executive scores and between the cognitive variables and PiB uptake were non-significant.

We found a positive correlation between the memory score and the grey matter volume in the left medial temporal lobe and between the instrumental score and the grey matter volume in the right precuneus and inferior parietal, lateral occipital, superior temporal, middle temporal and supramarginal gyri. The positive correlations between the baseline MMSE score and the grey matter volume in the right prefrontal cortex and between the executive score and the grey matter volume in the right pars orbitalis did not persist after correction for multiple comparisons ($p < 0.001$, uncorrected).

Predictive study on cognitive outcomes

Tau-PET predictor

VOI analysis

We found a trend towards a significant relation between (i) tau tracer uptake in the parietal lobes and decline of the MMSE

Table 1 Main demographic, clinical, biological and imaging characteristics at baseline, and neuropsychological and MRI data at 1 and 2 years

		Baseline		1 year		2 years	
		Patients with AD n=36	Controls n=15	Patients with AD n=36	Controls n=14	Patients with AD n=31	Controls n=14
Demographic data	Age (years)	68.1 (6.7)	68.7 (3.6)	–	–	–	–
	Sex (F/M)	17/19	10/5	–	–	–	–
	Education (years)	14.9 (4.2)	14.9 (3.3)	–	–	–	–
	Disease duration (years)	4.6 (3.3)	NA	–	–	–	–
	Cholinesterase inhibitors (n)	29	–	Introduced in 2, discontinued in 2	–	Introduced in 1, discontinued in 1	–
	NMDA antagonists (n)	2	–	No change	–	No change	–
Functional status	CDR	0	15	0	14	0	14
	0.5	27	0	11	0	3	0
	1	9	0	22	0	19	0
	2	0	0	3	0	9	0
	3	0	0	0	0	0	0
	CDR sum of boxes	3.8 (1.9)	0	5.7 (2.3)	0	7.7 (3.3)	0
Neuropsychological assessment							
Global cognitive efficiency	MMSE (/30)	23.4 (3.3)*	28.8 (1)	20.8 (4.4)	29.3 (0.6)	17.5 (5.7)†	29.8 (0.4)
Memory score	FCSRT (free+total immediate and delayed recalls) (/128)	53.5 (27.5)*	109.7 (6.5)	38.8 (29.4)	111.7 (9.2)	23.9 (27.5)†	111.2 (6.2)
Instrumental score	(Naming+praxis+Rey figure copy) (/188)	166.3 (24.9)	185.6 (1.8)	154.5 (33.1)	185.9 (1.9)	140.2 (42.1)†	186 (2.5)
Executive score	(Digit spans+letter fluency 2 min+WAIS similarities)	42.4 (12.6)*	61.6 (8.8)	38.8 (16.3)	65.4 (11.6)	33.8 (18.6)†	64.4 (12.6)
Genetic status	APOE genotype (n with at least one E4 allele)	24	2	–	–	–	–
CSF biomarkers‡	Amyloid peptide (pg/mL)	471.8 (147.2)	NA	–	–	–	–
	Total tau (pg/mL)	677.3 (411.7)	NA	–	–	–	–
	Phospho-tau181 (pg/mL)	90.5 (41.6)	NA	–	–	–	–
Molecular PET imaging	PiB-PET SUVr (GCI)	2.86 (0.62)*	1.27 (0.08)	–	–	–	–
	PiB-PET SUVr (precuneus)	3 (0.59)*	1.26 (0.11)	–	–	–	–
	PiB-PET SUVr (posterior cingulate)	3.09 (0.67)*	1.42 (0.15)	–	–	–	–
	Tau-PET SUVr (inferomedial temporal meta-VOI)	2.39 (1)*	1.23 (0.11)	–	–	–	–
	Tau-PET SUVr (temporal lobes)	2.4 (1)*	1.24 (0.13)	–	–	–	–
	Tau-PET SUVr (parietal lobes)	2.3 (1.1)*	1.18 (0.13)	–	–	–	–
	Tau-PET SUVr (frontal lobes)	2 (0.9)*	1.24 (0.13)	–	–	–	–
MRI	Fazekas score (0/1/2/3)	21/9/5/1	10/4/1/0	–	–	–	–
	Mean normalised HV	2.00 (0.3)*	2.44 (0.24)	–	–	1.85 (0.28)†	2.38 (0.24)
	Mean inferomedial temporal VOI CT (mm)	2.52 (0.2)*	2.86 (0.12)	–	–	2.34 (0.2)†	2.85 (0.14)

*P<0.05 in the comparison with controls at baseline after Bonferroni correction for 16 tests.

†P<0.05 in the comparison of the 2-year trajectories between patients with AD and controls after Bonferroni correction for 6 tests.

‡Measured prior to inclusion in the study (mean delay of 1.8 years before the tau-PET exams).

APOE, apolipoprotein E; CDR, Clinical Dementia Rating scale; CSF, cerebrospinal fluid; CT, cortical thickness; FCSRT, free and cued selective reminding test; GCI, Global Cortical Index; HV, hippocampal volume (normalised to the intracranial volume); MMSE, Mini-Mental State Examination; NA, not available; NMDA, N-methyl-D-aspartate; PET, positron emission tomography; SUVr, standardised uptake value ratio; VOI, volume of interest; WAIS, Wechsler Adult Intelligence Scale.

score (p=0.06), (ii) tau tracer binding in the temporal lobes and decline of the memory score (p=0.06), particularly on the left side (p=0.04) and (iii) tau tracer uptake in all the VOIs and decline of the instrumental and executive scores (all p<0.0016 except p=0.0048 in the parietal lobes for the executive score) (table 2).

Voxelwise analysis

We found significant associations between tau tracer binding (i) in the superior temporal gyrus and in the precuneus predominating on the left side and decline of the MMSE score, (ii) in

the left temporoparietal cortex and precuneus and decline of the memory score, (iii) in widespread cortical regions predominately in the left inferior parietal cortex and decline of the instrumental score and (iv) in cortical regions predominately in the frontal and anterior temporal cortices and decline of the executive score (figure 1).

Amyloid-PET predictor

No significant result was found for any cognitive component in either the VOI or voxelwise analyses, except for non-specific

Table 2 Results of the mixed effects models exploring the relation of each predictor with the longitudinal evolution of the four cognitive outcomes

Putative predictors	Cognitive outcomes											
	MMSE			Memory score			Instrumental score			Executive score		
	F value	t-value	AIC	F value	t-value	AIC	F value	t-value	AIC	F value	t-value	AIC
Time* Tau meta-VOI	7.36	-2.71	534.1	4.76	-2.18	891.4	28.6*	-5.35	902.8	17*	-4.12	761.4
Time* Tau temporal	8.1	-2.84	532.3	9.1†	-3.02	886.2	21*	-4.59	908.4	18.2*	-4.27	760.6
Time* Tau parietal	8.25	-2.98	534.5	7.4	-2.72	887.6	34.8*	-5.9	896.1	14.6*	-3.81	764.1
Time* Tau frontal	6.9	-2.63	535.1	6.6	-2.57	890.3	22*	-4.69	907.9	19.3*	-4.39	759.7
Time* PiB GCI	0.16	-0.39	542.2	0.9	-0.93	893.3	1.46	-1.21	923.8	2.3	-1.53	773.9
Time* PiB precuneus	0.01	-0.11	534.7	0.14	-0.38	878.6	0.1	-0.32	903.4	0.8	-0.9	762.3
Time* PiB posterior cingulate	0.0029	0.05	534.6	0.026	0.16	878.5	0.56	0.75	902.9	0.27	-0.52	763.1
Time* CSF t-tau	5	-2.24	536.4	4.2	-2.04	888.6	3.1	-1.76	923.7	5.6	-2.36	772
Time* CSF p-tau181	4.6	-2.15	536.8	2.6	-1.6	890.7	3.6	-1.89	923.3	2	-1.43	775.5
Time* CSF Aβ42	0.14	-0.37	543.6	0.04	-0.19	895.4	8.8	2.96	914.2	0.5	0.71	777.1
Time* HV	3.93	-1.98	538.7	3.2	-1.79	893	5.7	-2.38	921.3	0.32	0.56	776.8
Time* CT	0.81	0.9	543	0.75	0.86	894.8	0.05	0.22	926.8	10*	3.16	767.2

*P<0.05 with Bonferroni correction for 16 tests for the tau-PET predictor, 12 tests for the PiB-PET predictor, 12 tests for the CSF biomarkers and 8 tests for the MRI predictor.
†P<0.05 on the left side.

AIC, Akaike information criterion; Aβ42, amyloid peptide 42; CSF, cerebrospinal fluid; CT, cortical thickness; GCI, Global Cortical Index; HV, hippocampal volume (normalised with respect to the intracranial volume); MMSE, Mini-Mental State Examination; PET, positron emission tomography; p-tau181, phosphorylated tau protein; t-tau, total tau protein; VOI, volume of interest.

associations with PiB binding in the occipital lobes (table 2, figure 1).

MRI predictor VOI analysis

No significant association was found between any of the regional cortical volumes and cognitive decline, except between the CT in the temporal meta-VOI and decline in the executive score ($p=0.01$) (table 2).

Voxelwise analysis

We found limited associations between decline of the MMSE score and the grey matter volume in a restricted area within the left inferior temporal gyrus and between decline of the

instrumental score and the grey matter volume in a restricted area within the left parietal lobe (figure 1).

CSF biomarker predictors

No significant association was found for any cognitive component with the CSF biomarkers (table 2).

Subgroup predictive analyses

Considering only the subgroup of patients with a CDR score of 0.5 and considering younger (<70 years) patients and older (≥ 70 years) patients separately, or the subgroup of patients with relatively preserved instrumental functions did not significantly affect our results (figure 2).

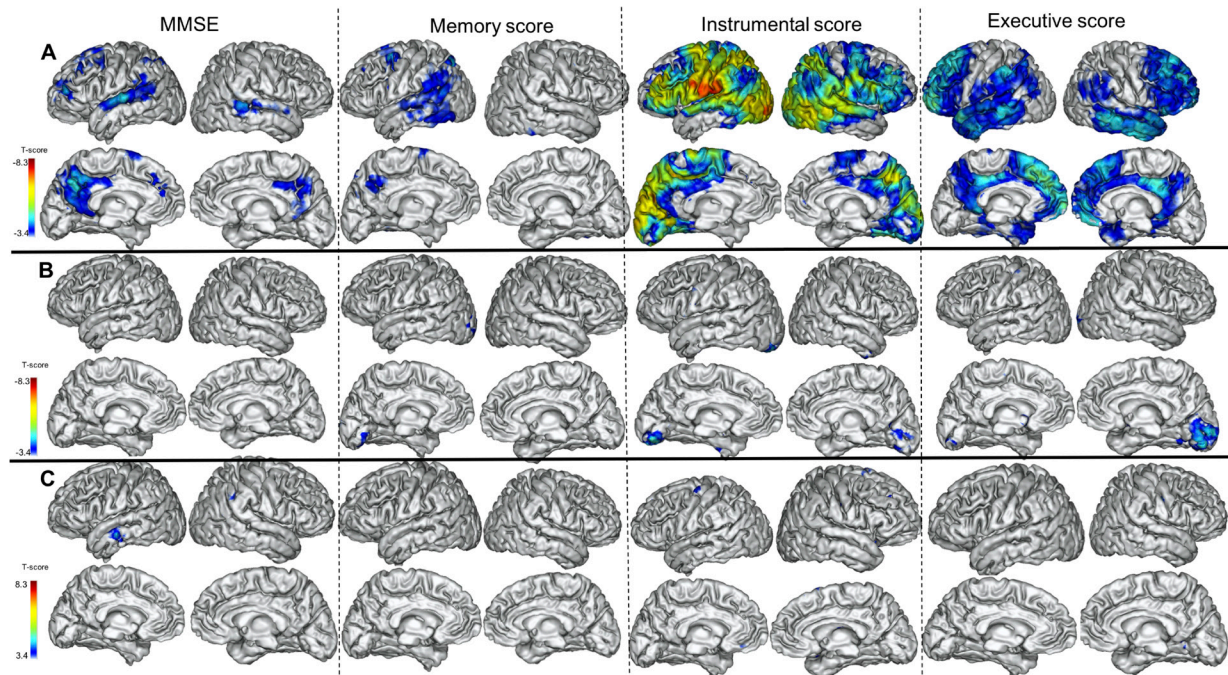


Figure 1 Results of the voxelwise predictive analysis that show the association between baseline tau-PET binding (A), PiB-PET binding (B) and grey matter volume (C) and the evolutions of the four cognitive outcomes over 2 years: MMSE, memory score, instrumental score and executive score (projection on the three-dimensional MRI MNI template). Random field theory-based multiple comparison correction with a clusterwise threshold of $p<0.001$ and a cluster-forming threshold of $p<0.001$. MMSE, Mini-Mental State Examination; PET, positron emission tomography.

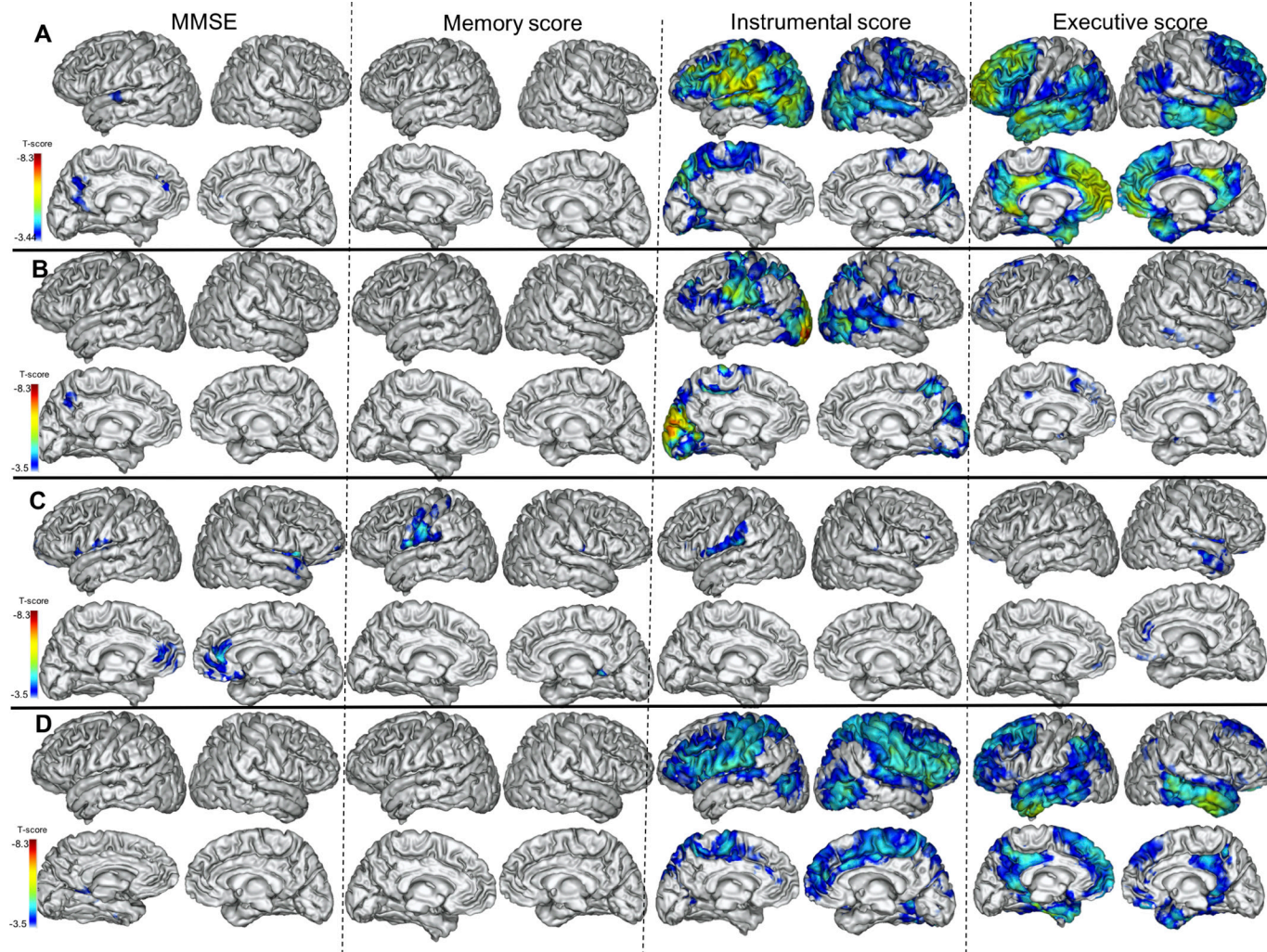


Figure 2 Results of the voxelwise predictive analysis that show the association between baseline tau-PET binding and the evolutions of the four cognitive outcomes over 2 years: MMSE, memory score, instrumental score and executive score in the patients with Clinical Dementia Rating=0.5 (A), in the patients younger than 70 years (B), in the older patients (C) and in the patients with relatively preserved instrumental functions (D) (projection on the three-dimensional MRI MNI template). Random field theory-based multiple comparison correction with a clusterwise threshold of $p < 0.001$ and a cluster-forming threshold of $p < 0.001$. MMSE, Mini-Mental State Examination; PET, positron emission tomography.

Predictive study on MRI regional cortical atrophy outcomes

Tau-PET predictor

VOI analysis

No significant relation was found between tau-PET and the evolution of hippocampal atrophy. We found a significant association between tau tracer binding in the right temporal and parietal lobes and atrophy progression in the right inferomedial temporal VOI ($p = 0.03$) (table 3).

Voxelwise analysis

We found a mild association between initial tau tracer binding in the right medial temporal lobe and decrease in the right hippocampal volume, and a more pronounced association between initial tau tracer binding in the superior temporal gyri and decrease in ipsilateral inferomedial temporal CT. When considering the grey matter volume in the whole brain at the voxel level, we also found an association between tau tracer binding and the progression of cortical atrophy in distributed areas of the superior temporal, parietal and frontal association cortices (figure 3).

Amyloid-PET predictor

Using both VOI and voxelwise analyses, we found no significant association between PiB binding and cortical atrophy progression (table 3, figure 3).

CSF biomarker predictors

The VOI analysis did not yield any significant results (table 3). In the voxelwise analysis, we found only an association between CSF t-tau and atrophy progression in circumscribed areas of the parietal lobes (figure 3).

DISCUSSION

To study the prognostic value of tau-PET imaging in early AD, we investigated the inter-relationships between regional tau binding at baseline and cognitive decline during 2 years of follow-up. For the cognitive outcomes, in addition to the MMSE, we considered three main cognitive components, namely memory, instrumental functions and executive functions, by pooling specified neuropsychological scores as previously described.¹⁷ We confirmed that each score of these distinct cognitive components correlated

Table 3 Results of the mixed effects models exploring the relation of each predictor with the longitudinal evolution of the average hippocampal volume and mean cortical thickness in the temporal meta-VOI

Putative predictors	MRI outcomes					
	Average HV			Mean CT in the temporal meta-VOI		
	F value	t-value	AIC	F value	t-value	AIC
Time* Tau meta-VOI	3.1	-1.77	-52.8	5.7	-2.39	-67.4
Time* Tau temporal	2	-1.41	-51.8	8*	-2.83	-69
Time* Tau parietal	0.45	-0.67	-50.6	8.7†	-2.95	-69.3
Time* Tau frontal	1.6	-1.26	-52.1	7.1	-2.67	-68.5
Time* PiB GCI	1.4	-1.2	-51.2	1.8	1.35	-62.8
Time* PiB precuneus	3.46	-1.86	-54.5	0.52	0.72	-63.5
Time* PiB posterior cingulate	2.69	-1.64	-53.7	1.8	1.34	-65.2
Time* CSF t-tau	0.5	-0.71	-51.2	1.3	-1.12	-61.1
Time* CSF p-tau181	0.7	-0.83	-51.9	0.29	-0.54	-60.2
Time* CSF Aβ42	1.5	-1.22	-55.6	0.04	0.19	-61.8

*P<0.05 on the right side.

†P<0.05 with Bonferroni correction for eight tests for the tau-PET predictor, six tests for the PiB-PET and for the CSF biomarkers predictors.

Aβ42, amyloid peptide 42; CSF, cerebrospinal fluid; CT, cortical thickness; GCI, Global Cortical Index; HV, hippocampal volume (normalised with respect to the intracranial volume); PET, positron emission tomography; p-tau181, phosphorylated tau protein; t-tau, total tau protein; VOI, volume of interest.

with the grey matter volume in corresponding brain regions, namely, the left medial temporal lobe for the memory score, the parietal lobes for the instrumental score and the frontal lobes for the executive score, as previously described using sulcal morphology parameters in AD.¹⁷

In accordance with our hypothesis, tau tracer binding at baseline was associated with the cognitive decline in various brain areas depending on each cognitive component: (a) decline of the verbal episodic memory score was associated with tau tracer binding in the left temporal lobe, (b) decline of the instrumental score with tau tracer binding in the inferior parietal cortex and (c) decline of the executive score with tau tracer binding in the frontal and anterior temporal cortices. In addition, global cognitive decline was associated with initial tau tracer binding in the superior temporal gyrus and precuneus predominately on the left side.

In contrast, no significant relationship was observed between cognitive decline and initial amyloid load, regional cortical atrophy or CSF biomarker levels.

To complete the study of the predictive value of tau imaging, we also considered AD-specific MRI outcomes (progression of hippocampal and cortical atrophy in an inferomedial temporal VOI) and found a relation between baseline tau tracer binding in the superior temporal gyrus and subsequent atrophy in the inferomedial temporal VOI. The voxelwise analysis also showed associations between tau tracer binding and subsequent cortical atrophy in the superior temporal, parietal and frontal association cortices, as reported in previous studies.^{7 26 27}

We considered a group of well-characterised patients with AD based on clinical-biological criteria, which was quite homogeneous in terms of functional impairment at baseline. Since age and initial clinical severity are associated with cognitive decline

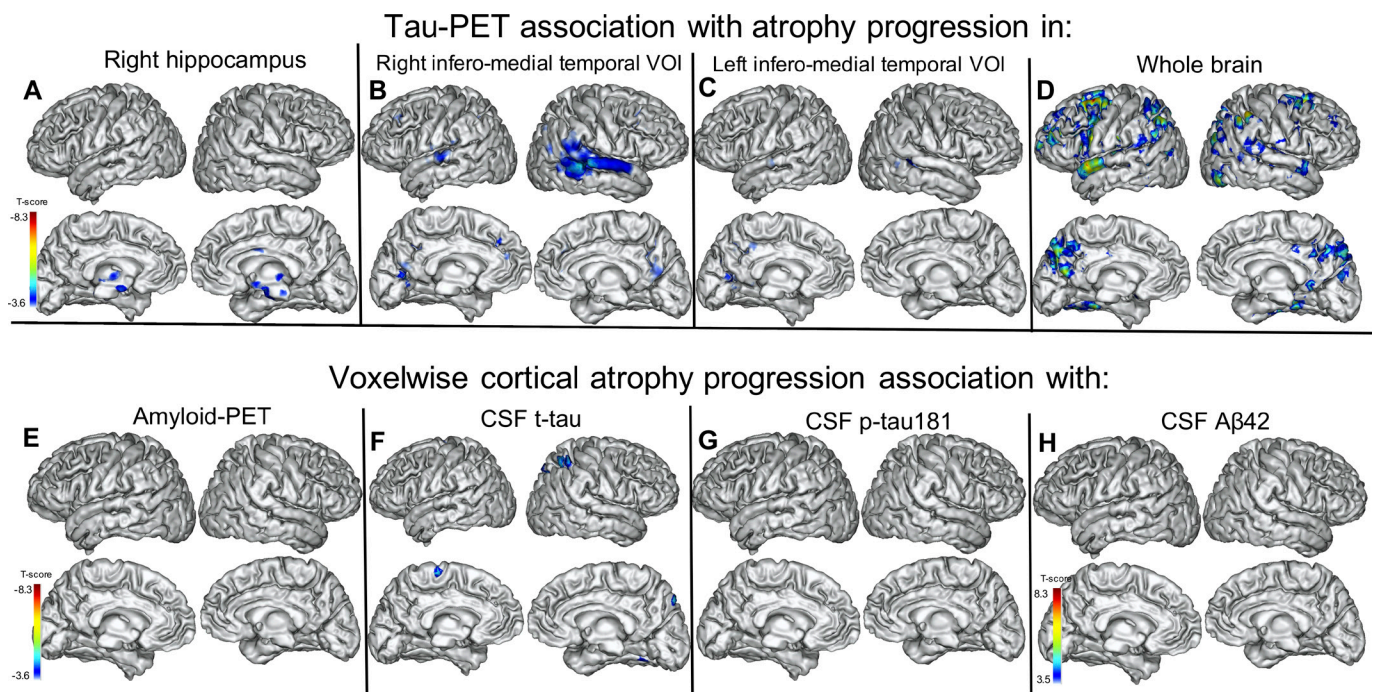


Figure 3 Results of the voxelwise predictive analysis that show the association between baseline tau-PET binding and progression of right hippocampal atrophy (A), progression of atrophy in the right inferomedial temporal VOI (B), progression of atrophy in the left inferomedial temporal VOI (C), progression of voxelwise cortical atrophy (D) and the associations between PiB binding (E), CSF t-tau (F), CSF p-tau181 (G) and CSF Aβ42 (H) and progression of voxelwise cortical atrophy (projection on the three-dimensional MRI MNI template). Random field theory-based multiple comparison correction with a clusterwise threshold of p<0.001 and a cluster-forming threshold of p<0.001. Aβ42, amyloid peptide 42; CSF, cerebrospinal fluid; PET, positron emission tomography; p-tau181, phosphorylated tau protein; VOI, volume of interest.

and tau load severity, we included age and CDR-SOB as covariates in all analyses. In addition, we verified that our results were not significantly affected when we ran our statistical models on prodromal AD (CDR=0.5), on the younger and older patient subgroups separately, or on patients with relatively preserved instrumental functions. We also considered other factors that could influence cognitive progression and the accumulation rate of tau pathology, especially sex and *APOE* genotype, as covariates. The cerebrovascular component leading to white matter damage is also important to consider, as it could interfere with our results by contributing to cognitive decline. However, this does not seem to have played a significant role in our cohort as only four patients experienced an increase in their Fazekas score, which most often went from 0 to 1 during the follow-up period.

It appears that tau-PET imaging outperforms PiB-PET and CSF biomarkers in predicting cognitive decline in AD. We did not find any association between CSF tau levels and cognitive decline. CSF t-tau or p-tau181 and tau-PET imaging capture different aspects of tau pathology,²⁸ and the elevation of CSF p-tau181 precedes tau-PET positivity in AD.²⁹ It has also been suggested that CSF p-tau181 may increase in the early phase of AD, and subsequently decrease in symptomatic patients,²⁸ which could alter the prognostic value of CSF p-tau181, even though lumbar puncture was performed on average almost 2 years before tau-PET imaging in our patients. This delay, which could play a role in the observed difference in prognostic value between CSF biomarkers and tau-PET, was considered a covariate in our analyses.

The higher correlation of grey matter volume with baseline cognition than that of tau tracer binding, which was more closely related to subsequent cognitive decline, is consistent with the hypothesis that tau-PET imaging reflects the tau pathology that precedes neurodegeneration.⁶

More specifically, we found a correspondence between the brain regions in which the association of tau tracer binding with cognitive decline was the highest and the specific cognitive domains studied. This is consistent with the idea that tau-PET imaging anticipates neurodegeneration and subsequent cognitive decline in various brain regions according to the cognitive domain that is considered. This assertion is reinforced by the association found between baseline tau tracer binding and subsequent cortical atrophy in the superior temporal, parietal and frontal association cortices, which are the regions that correspond to high Braak stages, in which cortical atrophy is posited to increase with disease progression.

Our results also raise the issue of suitable measures of cognitive decline, as tests that address global cognition are probably not the best suited for capturing decline in early stages of AD.³⁰ It has been suggested that tests that address more specific cognitive domains could be more sensitive. Our results are in accordance with this assertion, as declines in the instrumental and executive scores and, to a lesser extent, of the memory score were more closely related to baseline tau tracer binding than was decline in the MMSE score. Our results suggest that cognitive tests that assess word naming, gestural praxis and visuospatial abilities could be relevant tools for monitoring the evolution of the disease.

This study has several limitations, especially the relatively small sample size. In addition, it would be interesting to perform these analyses with FDG-PET data to better study the relation between tau pathology and neurodegeneration, as hypometabolism is more closely related to tau tracer binding than CT or grey matter volume.³¹ The prognostic value of tau-PET imaging should also be compared with those of new plasmatic markers,

as plasma p-tau181 and p-tau217 have been suggested to have prognostic value.^{32–34}

The present study suggests that tau tracer binding anticipates cognitive decline in AD in domain-specific brain areas, which was not found with the other considered biomarkers, and confirms the relation between tau-PET imaging and the progression of brain atrophy that was reported in previous works. Understanding which protein is the major driving force of neurodegeneration and cognitive decline is highly relevant for the development and testing effective therapies. These results provide important insights into the major role of tau pathology in symptomatic AD progression and, more specifically, the interaction between the in vivo assessment of tau burden and neurodegeneration, and are of the utmost importance for better understanding the clinical heterogeneity of the disease and developing new prognostic markers that will help improve the design of therapeutic trials.

Author affiliations

¹Department of Neurology of Memory and Language, GHU Paris Psychiatrie & Neurosciences, Hôpital Sainte-Anne, Paris, France

²Université de Paris, Paris, France

³Université Paris-Saclay, BioMaps, Service Hospitalier Frédéric Joliot CEA, CNRS, Inserm, Orsay, France

⁴McGill University Research Centre for Studies in Aging, Montreal, Quebec, Canada

⁵Equipe de Statistique Appliquée, ESPCI Paris, PSL Research University, INSERM, UMRS 1158 Neurophysiologie Respiratoire Expérimentale et Clinique, 10 rue Vauquelin, Paris, France

⁶Centre d'évaluation Troubles Psychiques et Vieillesse, GHU Paris Psychiatrie & Neurosciences, Hôpital Sainte-Anne, Paris, France

⁷Université Paris-Saclay, UNIACT, Neurospin, Joliot Institute, CEA, Gif sur Yvette, France

Acknowledgements The authors are grateful to the chemical/radiopharmaceutical and nursing staff of the Service Hospitalier Frédéric Joliot for the synthesis of [¹¹C]-PiB and [¹⁸F]-flortaucipir and patient management during PET acquisition, respectively, and the staff of the Centre de Neuroimagerie de Recherche (CENIR), Salpêtrière Hospital for patient management during MRI acquisition. We are also indebted to AVID Radiopharmaceuticals for their support in supplying the flortaucipir precursor and chemistry production advice.

Contributors JL, MS and MB designed the work; acquired, analysed and interpreted the data and drafted the manuscript. PO analysed and interpreted the data, revised the manuscript and approved its final version. MT analysed and interpreted the data, revised the manuscript and approved its final version. CT and IR were involved in data analysis, revised the manuscript and approved its final version. PG, FC and MM were involved in data acquisition, revised the manuscript and approved its final version. Authors responsible for the overall content as the guarantors: JL and MS

Funding This study was funded by French Ministry of Health grant (PHRC-2013-0919), CEA (no award/grant number), Fondation pour la recherche sur la maladie d'Alzheimer (no award/grant number), Institut de Recherches Internationales Servier (no award/grant number), France-Alzheimer (no award/grant number).

Competing interests None declared.

Patient consent for publication Not applicable.

Ethics approval The Ethics Committee (Comité de Protection des Personnes Ile-de-France VI) approved the study (Protocole n° 13-15). All subjects provided written informed consent.

Provenance and peer review Not commissioned; externally peer reviewed.

Data availability statement Data are available on reasonable request.

Supplemental material This content has been supplied by the author(s). It has not been vetted by BMJ Publishing Group Limited (BMJ) and may not have been peer-reviewed. Any opinions or recommendations discussed are solely those of the author(s) and are not endorsed by BMJ. BMJ disclaims all liability and responsibility arising from any reliance placed on the content. Where the content includes any translated material, BMJ does not warrant the accuracy and reliability of the translations (including but not limited to local regulations, clinical guidelines, terminology, drug names and drug dosages), and is not responsible for any error and/or omissions arising from translation and adaptation or otherwise.

ORCID iDs

Julien Lagarde <http://orcid.org/0000-0002-2018-261X>

REFERENCES

- Villemagne VL, Fodero-Tavoletti MT, Masters CL, *et al.* Tau imaging: early progress and future directions. *Lancet Neurol* 2015;14:114–24.
- Chien DT, Bahri S, Szardenings AK, *et al.* Early clinical PET imaging results with the novel PHF-tau radioligand [F-18]-T807. *J Alzheimers Dis* 2013;34:457–68.
- Marquié M, Normandin MD, Vanderburg CR, *et al.* Validating novel tau positron emission tomography tracer [F-18]-AV-1451 (T807) on postmortem brain tissue. *Ann Neurol* 2015;78:787–800.
- Mehta RI, Schneider JA. What is 'Alzheimer's disease'? The neuropathological heterogeneity of clinically defined Alzheimer's dementia. *Curr Opin Neurol* 2021;34:237–45.
- Wallin AK, Blennow K, Zetterberg H, *et al.* CSF biomarkers predict a more malignant outcome in Alzheimer disease. *Neurology* 2010;74:1531–7.
- Iaccarino L, La Joie R, Edwards L, *et al.* Spatial relationships between molecular pathology and neurodegeneration in the Alzheimer's disease continuum. *Cereb Cortex* 2021;31:1–14.
- La Joie R, Visani AV, Baker SL, *et al.* Prospective longitudinal atrophy in Alzheimer's disease correlates with the intensity and topography of baseline tau-PET. *Sci Transl Med* 2020;12:eaa5732.
- Chiotis K, Savitcheva I, Poulakis K, *et al.* [¹⁸F]THK5317 imaging as a tool for predicting prospective cognitive decline in Alzheimer's disease. *Mol Psychiatry* 2021;26:5875–87.
- Malpetti M, Kievit RA, Passamonti L, *et al.* Microglial activation and tau burden predict cognitive decline in Alzheimer's disease. *Brain* 2020;143:1588–602.
- Jack CR, Wiste HJ, Weigand SD, *et al.* Predicting future rates of tau accumulation on PET. *Brain* 2020;143:3136–50.
- Pontecorvo MJ, Devous MD, Kennedy I, *et al.* A multicentre longitudinal study of flortaucipir (18F) in normal ageing, mild cognitive impairment and Alzheimer's disease dementia. *Brain* 2019;142:1723–35.
- Ossenkuppele R, Smith R, Mattsson-Carlgen N, *et al.* Accuracy of tau positron emission tomography as a prognostic marker in preclinical and prodromal Alzheimer disease: a head-to-head comparison against amyloid positron emission tomography and magnetic resonance imaging. *JAMA Neurol* 2021;78:961–71.
- Biel D, Brendel M, Rubinski A, *et al.* Tau-PET and in vivo Braak-staging as prognostic markers of future cognitive decline in cognitively normal to demented individuals. *Alzheimers Res Ther* 2021;13:137.
- Duits FH, Teunissen CE, Bouwman FH, *et al.* The cerebrospinal fluid "Alzheimer profile": easily said, but what does it mean? *Alzheimers Dement* 2014;10:713–23.
- de Souza LC, Corlier F, Habert M-O, *et al.* Similar amyloid- β burden in posterior cortical atrophy and Alzheimer's disease. *Brain* 2011;134:2036–43.
- Hamelin L, Lagarde J, Dorothee G, *et al.* Early and protective microglial activation in Alzheimer's disease: a prospective study using 18F-DPA-714 PET imaging. *Brain* 2016;139:1252–64.
- Bertoux M, Lagarde J, Corlier F, *et al.* Sulcal morphology in Alzheimer's disease: an effective marker of diagnosis and cognition. *Neurobiol Aging* 2019;84:41–9.
- Grober E, Buschke H, Crystal H, *et al.* Screening for dementia by memory testing. *Neurology* 1988;38:900–3.
- Jack CR, Wiste HJ, Weigand SD, *et al.* Defining imaging biomarker cut points for brain aging and Alzheimer's disease. *Alzheimers Dement* 2017;13:205–16.
- Reuter M, Schmansky NJ, Rosas HD, *et al.* Within-subject template estimation for unbiased longitudinal image analysis. *Neuroimage* 2012;61:1402–18.
- Sureau FC, Reader AJ, Comtat C, *et al.* Impact of image-space resolution modeling for studies with the high-resolution research tomograph. *J Nucl Med* 2008;49:1000–8.
- Varrone A, Sjöholm N, Eriksson L, *et al.* Advancement in PET quantification using 3D-OP-OSEM point spread function reconstruction with the HRRT. *Eur J Nucl Med Mol Imaging* 2009;36:1639–50.
- Lagarde J, Olivier P, Cailé F, *et al.* [¹⁸F]-AV-1451 tau PET imaging in Alzheimer's disease and suspected non-AD tauopathies using a late acquisition time window. *J Neurol* 2019;266:3087–97.
- Mathotaarachchi S, Wang S, Shin M, *et al.* VoxelStats: a Matlab package for multi-modal voxel-wise brain image analysis. *Front Neuroinform* 2016;10:20.
- Brett M, Penny W, Kiebel S. An introduction to Random Field Theory. In: Frackowiak RSJ, Friston K, Frith C, *et al.*, eds. *Human brain function*. 2nd edition. London: Academic Press, 2004: 867–80.
- Das SR, Xie L, Wisse LEM, *et al.* Longitudinal and cross-sectional structural magnetic resonance imaging correlates of AV-1451 uptake. *Neurobiol Aging* 2018;66:49–58.
- Gordon BA, McCullough A, Mishra S, *et al.* Cross-sectional and longitudinal atrophy is preferentially associated with tau rather than amyloid β positron emission tomography pathology. *Alzheimers Dement* 2018;10:245–52.
- La Joie R, Bejanin A, Fagan AM, *et al.* Associations between [¹⁸F]AV1451 tau PET and CSF measures of tau pathology in a clinical sample. *Neurology* 2018;90:e282–90.
- Meyer P-F, Pichet Binette A, Gonneaud J, *et al.* Characterization of Alzheimer disease biomarker discrepancies using cerebrospinal fluid phosphorylated tau and AV1451 positron emission tomography. *JAMA Neurol* 2020;77:508–16.
- Jutten RJ, Sikkes SAM, Amarglio RE. Identifying Sensitive Measures of Cognitive Decline at Different Clinical Stages of Alzheimer's Disease. *J Int Neuropsychol Soc* 2020:1–13.
- Whitwell JL, Graff-Radford J, Tosakulwong N, *et al.* Imaging correlations of tau, amyloid, metabolism, and atrophy in typical and atypical Alzheimer's disease. *Alzheimers Dement* 2018;14:1005–14.
- Karikari TK, Pascoal TA, Ashton NJ, *et al.* Blood phosphorylated tau 181 as a biomarker for Alzheimer's disease: a diagnostic performance and prediction modelling study using data from four prospective cohorts. *Lancet Neurol* 2020;19:422–33.
- Janelidze S, Berron D, Smith R, *et al.* Associations of plasma Phospho-Tau217 levels with tau positron emission tomography in early Alzheimer disease. *JAMA Neurol* 2021;78:149–56.
- Pereira JB, Janelidze S, Stomrud E, *et al.* Plasma markers predict changes in amyloid, tau, atrophy and cognition in non-demented subjects. *Brain* 2021;144:2826–36.