



HAL
open science

Primary failure of eruption: From molecular diagnosis to therapeutic management

Delphine Wagner, Tristan Rey, Marie Cecile Maniere, Sarah Dubourg, Agnès Bloch-Zupan, Marion Strub

► To cite this version:

Delphine Wagner, Tristan Rey, Marie Cecile Maniere, Sarah Dubourg, Agnès Bloch-Zupan, et al.. Primary failure of eruption: From molecular diagnosis to therapeutic management. *Journal of Oral Biology and Craniofacial Research*, 2023, 13 (2), pp.169-176. 10.1016/j.jobcr.2023.01.001 . hal-04017106

HAL Id: hal-04017106

<https://hal.science/hal-04017106v1>

Submitted on 6 Mar 2023


HAL is a multi-disciplinary open access archive for the deposit and dissemination of scientific research documents, whether they are published or not. The documents may come from teaching and research institutions in France or abroad, or from public or private research centers.

L'archive ouverte pluridisciplinaire **HAL**, est destinée au dépôt et à la diffusion de documents scientifiques de niveau recherche, publiés ou non, émanant des établissements d'enseignement et de recherche français ou étrangers, des laboratoires publics ou privés.



Contents lists available at ScienceDirect

Journal of Oral Biology and Craniofacial Research

journal homepage: www.elsevier.com/locate/jobcr

Primary failure of eruption: From molecular diagnosis to therapeutic management

Delphine Wagner^{a,b,c,1}, Tristan Rey^{d,e,1}, Marie-Cécile Maniere^{a,b,f}, Sarah Dubourg^b,
Agnès Bloch-Zupan^{a,b,d,g}, Marion Strub^{a,b,f,*}

^a Université de Strasbourg, Faculté de Chirurgie Dentaire, 8 rue Ste Elisabeth, 67000, Strasbourg, France

^b Hôpitaux Universitaires de Strasbourg (HUS), Pôle de Médecine et Chirurgie Bucco-dentaires, Hôpital Civil, Centre de référence des maladies rares orales et dentaires O-Rares, Filière Santé Maladies rares TETE COU, European Reference Network ERN CRANIO, Strasbourg, France

^c UMR 7357, ICube laboratory, Boulevard Sébastien Brant 300, 67412, Illkirch, France

^d Université de Strasbourg, Institut de Génétique et de Biologie Moléculaire et Cellulaire (IGBMC), INSERM U1258, CNRS- UMR7104, Illkirch, France

^e Hôpitaux Universitaires de Strasbourg, Laboratoires de diagnostic génétique, Institut de Génétique Médicale d'Alsace, Strasbourg, France

^f INSERM (French National Institute of Health and Medical Research), UMR 1260, Regenerative Nanomedicine (RNM), Fédération de Médecine Translationnelle de Strasbourg (FMTS), 11 rue Human, 67000, Strasbourg, France

^g Université de Strasbourg, Institut d'études avancées (USIAS), Strasbourg, France

ARTICLE INFO

Keywords:

Primary failure of eruption

PTH1R gene

Tooth resorption

Case report

ABSTRACT

Introduction: Primary Failure of Eruption (PFE) is a rare condition affecting posterior teeth eruption resulting in a posterior open bite malocclusion. Differential diagnosis like ankylosis or mechanical eruption failure should be considered. For non-syndromic forms, mutations in *PTH1R*, and recently in *KMT2C* genes are the known etiologies. The aim of this work was to describe the variability of clinical presentations of PFE associated with pathogenic variants of *PTH1R*.

Material and methods: Diagnosis of non-syndromic PFE has been suggested for three members of a single family. Clinical and radiological features were collected, and genetic analyses were performed.

Results: The clinical phenotype (type and number of involved teeth, depth of bone inclusions, functional consequences) is variable within the family. Severe tooth resorptions were detected. A heterozygous substitution in *PTH1R* (NM_000316.3): c.899T > C was identified as a class 4 likely pathogenic variant. The multidisciplinary management is described involving oral biology, pediatric dentistry, orthodontics, oral surgery, and prosthodontics.

Conclusion: In this study, we report a new *PTH1R* variant involved in a familial form of PFE with variable expressivity. Therapeutic care is complex and difficult to systematize, hence the lack of evidence-based recommendations and clinical guidelines.

1. Introduction

First described by Proffit and Vig in 1981,¹ primary failure of eruption (PFE - OMIM #125350- ORPHA:412206) is a rare genetic anomaly of tooth eruption, with a prevalence of 0.06%.² The affected teeth do not follow a physiological eruption, remain fully or partially impacted and therefore cannot be functional. These non-ankylosed teeth remain in their bone crypt, without mechanical obstruction or soft-tissue interference.

1.1. Clinical features

The pathology can concern one to four quadrants and incriminate one or more posterior teeth in each of them, leading to a posterior open bite associated with altered vertical growth of the alveolar process.³ PFE can affect primary and/or permanent teeth.⁴ In permanent dentition, PFE affects all molars distal to the most mesial involved tooth.⁵ In mixed dentition, even if primary teeth are affected, permanent teeth of the same quadrant may or may not be affected.⁶ Patients experiencing PFE

* Corresponding author. Université de Strasbourg, Faculté de Chirurgie Dentaire, 8 rue Ste Elisabeth, 67000, Strasbourg, France.

E-mail addresses: delphine.wagner@unistra.fr (D. Wagner), tristan.rey@chru-strasbourg.fr (T. Rey), maniere.marie-cecile@chru-strasbourg.fr (M.-C. Maniere), sarah.dubourg@gmail.com (S. Dubourg), agnes.bloch-zupan@unistra.fr (A. Bloch-Zupan), m.strub@unistra.fr (M. Strub).

¹ contributed equally to the work and should be considered as joint first authors.

<https://doi.org/10.1016/j.jobcr.2023.01.001>

Received 20 September 2022; Received in revised form 2 January 2023; Accepted 5 January 2023

Available online 6 January 2023

2212-4268/© 2023 The Authors. Published by Elsevier B.V. on behalf of Craniofacial Research Foundation. This is an open access article under the CC BY-NC-ND license (<http://creativecommons.org/licenses/by-nc-nd/4.0/>).

of permanent teeth only demonstrate affected primary teeth in 24.3% of cases.²

Non-syndromic PFE are defined by dental manifestations including sometimes angulated roots and resorptions.^{2,7} Clinical phenotypes of non-syndromic PFE display significant heterogeneity and different degrees of severity. Considering the type of malocclusion, no consensus exists in the literature. Hanisch et al. (2018) report 5.9% of skeletal Classes I, 14.7% of Classes II and 79.4% of Classes.² Yamaguchi et al. (2011) and Awad et al. (2022) cited a predominance of skeletal Classes III.^{8,9}

In some syndromes, failure of tooth eruption is associated to other oral abnormalities, as for instance hypoplastic amelogenesis imperfecta, relative microdontia, intra-pulpal calcification, and/or extra oral manifestations such as nephrocalcinosis in enamel renal syndrome (*FAM20A* gene), ophthalmic abnormalities in GAPO syndrome (*ANTXR1*), ocular dental syndrome (*FGFR3*), Nance-Horan syndrome (*NHS*)^{2,10} or skeletal abnormalities in osteoglophonic dysplasia (*FGFR1*).¹¹ These syndromic forms are genetically distinct.

1.2. Radiological aspects

Diagnosis of PFE is challenging because clinicians have to eliminate differential diagnoses of primary ankylosis or mechanical obstruction. For this purpose, 3D imaging is the key tool.¹² A high-resolution Cone Beam Computerised Tomography (CBCT) allows a precise exploration of the periodontal space and the absence of areas of ankylosis.

The depth of inclusion varies from tooth to tooth. Three-dimensional imaging helps assessing their location and relationship to adjacent anatomical structures such as the inferior alveolar nerve or maxillary sinuses floor.¹³ Another pathognomonic radiological sign is the presence of the intraosseous eruption path. Tooth resorptions can be associated.^{7,13}

1.3. Aetiological diagnosis

Non-syndromic PFE, inherited as an autosomal dominant disease,^{14,15} is due to heterozygous mutations in *PTH1R* gene on chromosome 3p21. This gene encodes the transmembrane receptor PTH1R, a G protein-coupled receptor for both parathyroid hormone (PTH; OMIM 168450) and parathyroid hormone-related protein (PTHrP; OMIM 168470).¹⁴ PTH1R is involved in bone metabolism regulation and calcium homeostasis. Most often pathogenic variants lead to a non-functional receptor. More than 50 *PTH1R* variants have been described (Table 1). Recently, reported mutations in *KMT2C* gene have been suggested as another potential molecular etiology of familial non-syndromic PFE.¹⁶

1.4. Therapeutic management

An interdisciplinary approach is required, most often involving oral biologist, pediatric dentists, dentists, orthodontists, and oral surgeons and multidisciplinary teams as gathered by expert reference centers. The main problem with PFE patient management is the lack of consensus. The issue of choice and timing of treatment would be crucial.²

- Management in dentofacial orthopaedics

In addition to the classic therapeutic objectives, the practitioner must integrate the management of partially or non-evolved teeth into the treatment plan. In the absence of ankylosis confirmed during the initial radiological check-up, the choice of orthodontic-surgical traction needs to be discussed by the multi-disciplinary team. Indeed, several cases of traction failure have been published.^{2,7,17} The management is even more complex, as it can potentially increase the pre-existing lateral infraclusion causing a shift in the occlusion plane. Ankylosis may also occur during and after orthodontic treatment¹⁷; its physiopathology is still to

be understood.

- Surgical and prosthodontic management

If the continuity of the gum is interrupted and teeth are difficult to access with toothbrush, caries may occur. In cases of partial eruption, overlays can be performed to improve function and restore occlusal stability.¹⁸ Cares of deeply included teeth are complex (visibility, access) and the installation of the rubber dam often impossible. In this case, surgical extractions may be the adequate treatment.

Impacted teeth can be kept under a removable denture or avulsed.² Implant rehabilitation is complex because of the small amount of bone available after avulsion of deeply impacted teeth, requiring bone augmentation procedures as autogenous onlay bone grafting.

The objective of this prospective study was to describe the clinical and radiological presentations of PFE in patients affected by pathogenic variants of *PTH1R*, as well as their therapeutic management.

2. Materials and methods

This clinical case was conducted in compliance with the CARE guidelines. Inclusion criteria were people over 6 years old with PFE. Exclusion criteria were: children under 6 years old, endocrine pathology that may interfere with dental eruption, rickets, chemotherapy/radiotherapy, bisphosphonate treatment.

The patients were examined at the Centre de Référence des Maladies Rares orales et dentaires (O-Rares), Hôpitaux Universitaires de Strasbourg, France. The oral phenotype was documented using the D[4]/phenodent registry protocol, a Diagnosing Dental Defects Database [see www.phenodent.org, for assessment form], which is approved by CNIL (French National commission for informatics and liberty, number 908416). Parents gave written informed consent for the transfer of clinical data in D[4]/phenodent database, genetic testing (GenoDENT^{19,20}), DNA biobanking, and the current publication. This clinical study is registered at <https://clinicaltrials.gov>: NCT02397824, and with the MESR (French Ministry of Higher Education and Research) Bioethics Commission as a biological collection "Orofacial Manifestations of Rare Diseases" DC-2012-1677 within DC-2012-1002 and was acknowledged by the CPP (person protection committee) Est IV December 11th 2012. Clinical and radiological examination is planned as part of the study "Primary Failure of Eruption (PFE): Highlighting of Clinical, Radiological and Genetic Diagnostic Criteria: Consequences on the Therapeutic Management", registered at <https://clinicaltrials.gov>: NCT03580785.

The proband and the affected and non-affected family members gave written informed consents in accordance with the Declaration of Helsinki, for the D[4]/phenodent registry, clinical and radiological examinations and for genetic analyses performed on the salivary samples included in the biological collection.

3. Results

3.1. Clinical and radiological descriptions

- Patient 1: the father (I.1)

A 39-year-old male patient was referred to the reference center for rare oral diseases (O-Rares) in Strasbourg, France, by his maxillofacial surgeon seeking a diagnosis. This patient required prosthetic rehabilitation of the posterior sectors. Clinical examination revealed a bilateral severe posterior open bite related to multiple defects of teeth eruption (Fig. 1). Inter-arch contacts existed only in the anterior sector, up to teeth 14 and 45 on the left side and up to teeth 22 and 33 on the right side. In the sagittal plane, a Class III malocclusion could be seen, with an anterior edge to edge occlusion. Significant wear of the free edges was already present. The inter-incisal medians were inconsistent, with a deviation of the inferior midline to the left. Molars were not in occlusion,

Table 1

Pathogenic variants reported in *PTH1R*. List of coding DNA reference sequence based on the transcript NM_000316.3 regrouped by variant's type (substitution, deletion and duplication) and ranked from their 5' to 3' position. The majority of the 67 variants are heterozygous (86%) and most of them are reported for primary failure of tooth eruption (73%). This publication reports a new heterozygous variant c.899T > C; p.(Leu300Pro). This list has been established based on HGMDpro variant database and literature update interrogated on September 2022.

Substitution	Genotype	Protein effect prediction	Phenotype	References
c.75+9C > T	heterozygous	p.?	Primary failure of tooth eruption	Roth H et al., 2014
c.103G > A	homozygous	p.(Glu35Lys)	Eiken skeletal dysplasia with pseudoepiphyses in the hands and primary failure of tooth eruption	Moirangthem A et al., 2018
c.109C > A	homozygous	p.(Gln37Lys)	Hyperphosphatasia mental retardation syndrome	Maddirevula S et al., 2018
c.251C > G	heterozygous	p.(Ser84Cys)	Short stature, patient with skeletal abnormalities	Chen M et al., 2022
c.310C > T	homozygous	p.(Arg104*)	Osteochondrodysplasia, Blomstrand, type 1	Hoogendam J et al., 2007
c.313 + 32A > G	heterozygous	p.?	Primary failure of tooth eruption	Grippaudo C et al., 2018
c.331G > T	heterozygous	p.(Glu111*)	Primary failure of tooth eruption	Roth H et al., 2014
c.342C > A	heterozygous	p.(His114Gln)	Decreased bone mineral density, kyphoscoliotic chest deformity & metacarpal fractures	Nadyrshina D et al., 2022
c.356C > T	heterozygous	p.(Pro119Leu)	Primary failure of tooth eruption	Yamaguchi T et al., 2011
c.395C > T	homozygous/ heterozygous	p.(Pro132Leu)	Metaphyseal chondrodysplasia/Primary failure of tooth eruption	Zhang P et al., 1998
c.401A > C	homozygous	p.(Tyr134Ser)	Eiken skeletal dysplasia	Jacob P et al., 2019
c.425G > T	heterozygous	p.(Gly142Val)	Primary failure of tooth eruption	Aziz S et al., 2019
c.434A > G	heterozygous	p.(Tyr145Cys)	Primary failure of tooth eruption	Roth H et al., 2014
c.436C > A	heterozygous	p.(Arg146 =)	Primary failure of tooth eruption	Roth H et al., 2014
c.436C > T	heterozygous	p.(Arg146*)	Primary failure of tooth eruption	Roth H et al., 2014
c.439C > T	heterozygous	p.(Arg147Cys)	Primary failure of tooth eruption	Yamaguchi T et al., 2011
c.448C > T	heterozygous	p.(Arg150Cys)	Ollier disease	Hopyan S et al., 2002
c.463G > T	heterozygous	p.(Glu155*)	Primary failure of tooth eruption	Decker E et al., 2008
c.505G > T	heterozygous	p.(Glu169*)	Primary failure of tooth eruption	Grippaudo C et al., 2018
c.543 + 1G > A	heterozygous	p.?	Primary failure of tooth eruption	Decker E et al., 2008
c.543 + 1G > T	heterozygous	p.?	Primary failure of tooth eruption	Roth H et al., 2014
c.557G > A	homozygous	p.(Arg186His)	Pseudohypoparathyroidism 1b with neurological involvement	Guerreiro et al., 2016
c.590 T > A	heterozygous	p.(Val197Glu)	Primary failure of tooth eruption	Roth H et al., 2014
c.611T > A	homozygous	p.(Val204Glu)	Primary failure of tooth eruption	Jelani M et al., 2016
c.629C > T	heterozygous	p.(Ala210Val)	Short stature, patient with skeletal abnormalities	Chen M et al., 2022
c.639-2A > C	heterozygous	p.?	Primary failure of tooth eruption	Roth H et al., 2014
c.639-2A > G	heterozygous	p.?	Primary failure of tooth eruption	Roth H et al., 2014
c.668A > G	heterozygous	p.(His223Arg)	Metaphyseal chondrodysplasia	Schipani E et al., 1995
c.695 T > G	heterozygous	p.(Leu232Arg)	Primary failure of tooth eruption	Roth H et al., 2014
c.698G > A	heterozygous	p.(Arg233His)	Primary failure of tooth eruption	Roth H et al., 2014
c.764G > A	heterozygous	p.(Arg255His)	Ollier disease	Couvineau A et al., 2008
c.875 T > C	heterozygous	p.(Leu292Pro)	Primary failure of tooth eruption	Roth H et al., 2014
c.892 T > G	heterozygous	p.(Trp298Gly)	Primary failure of tooth eruption	Risom L et al., 2013
c.899T > C	heterozygous	p.(Leu300Pro)	Primary failure of tooth eruption	This publication
c.947C > A	heterozygous	p.(Ser316*)	Primary failure of tooth eruption	Risom L et al., 2013
c.989G > T	heterozygous	p.(Gly330Val)	Primary failure of tooth eruption	Risom L et al., 2013
c.1016G > A	heterozygous	p.(Trp339*)	Primary failure of tooth eruption	Roth H et al., 2014
c.1049 + 29C > T	homozygous	p.?	Osteochondrodysplasia, Blomstrand, type 2	Hoogendam J et al., 2007
c.1050-3C > G	heterozygous	p.?	Primary failure of tooth eruption	Decker E et al., 2008
c.1082G > A	heterozygous	p.(Trp361*)	Primary failure of tooth eruption	Risom L et al., 2013
c.1142 T > G	heterozygous	p.(Ile381Ser)	Primary failure of tooth eruption	Roth H et al., 2014
c.1148G > A	heterozygous	p.(Arg383Gln)	Primary failure of tooth eruption	Yamaguchi T et al., 2011
c.1168C > T	heterozygous	p.(Arg390Trp)	Hypoparathyroidism	García-Castaño A et al., 2021
c.1182C > T	heterozygous	p.(Ala394 =)	Primary failure of tooth eruption	Roth H et al., 2014
c.1228A > C	heterozygous	p.(Thr410Pro)	Metaphyseal chondrodysplasia	Schipani E et al., 1996
c.1229C > G	heterozygous	p.(Thr410Arg)	Metaphyseal chondrodysplasia	Bastepe M et al., 2004
c.1305G > A	heterozygous	p.(Thr435 =)	Primary failure of tooth eruption	Roth H et al., 2014
c.1324C > G	heterozygous	p.(His442Asp)	Primary failure of tooth eruption	Roth H et al., 2014
c.1354-1G > A	heterozygous	p.?	Primary failure of tooth eruption	Frazier-Bowers SA et al., 2010
c.1355G > A	heterozygous	p.(Gly452Glu)	Primary failure of tooth eruption	Roth H et al., 2014
c.1373T > G	heterozygous	p.(Ile458Arg)	Metaphyseal chondrodysplasia	Schipani E et al., 1999
c.1373T > A	heterozygous	p.(Ile458Lys)	Metaphyseal dysplasia, Jansen	Savoldi G et al., 2013
c.1389 T > C	heterozygous	p.(Asn463 =)	Primary failure of tooth eruption	Roth H et al., 2014
c.1453C > T	homozygous	p.(Arg485*)	Eiken skeletal dysplasia	Duchatelet S et al., 2005
c.1636G > A	heterozygous	p.(Glu546Lys)	Primary failure of tooth eruption	Roth H et al., 2014
c.1736A > C	heterozygous	p.(Glu579Ala)	Primary failure of tooth eruption	Roth H et al., 2014
c.1765T > C	heterozygous	p.(Trp589Arg)	Primary failure of tooth eruption	Grippaudo C et al., 2018
Deletion				
c.322delT	heterozygous	p.(Cys108Valfs*82)	Primary failure of tooth eruption	Roth H et al., 2014
c.544-26_544-23del	heterozygous	p.?	Primary failure of tooth eruption	Risom L et al., 2013
c.572delA	heterozygous	p.(Tyr191Serfs*14)	Primary failure of tooth eruption and osteoarthritis	Frazier-Bowers SA et al., 2014
c.1036delC	heterozygous	p.(Leu346Trpfs*9)	Primary failure of tooth eruption	Roth H et al., 2014

(continued on next page)

Table 1 (continued)

Substitution	Genotype	Protein effect prediction	Phenotype	References
c.1093delG	homozygous/ heterozygous	p.(Val365Cysfs*141)	Osteochondrodysplasia, Blomstrand/Primary failure of tooth eruption	Karperien M et al., 1999
c.1348_1350del	heterozygous	p.(Phe450del)	Primary failure of tooth eruption	Risom L et al., 2013
c.1595delC Duplication	heterozygous	p.(Pro532Leufs*85)	Primary failure of tooth eruption	Grippaudo C et al., 2018
c.636dupT	heterozygous	p.(Arg213*)	Primary failure of tooth eruption	Roth H et al., 2014
c.813dupT	heterozygous	p.(Ala272Cysfs*127)	Primary failure of tooth eruption	Roth H et al., 2014
c.996dupC	heterozygous	p.(Ala333Argfs*66)	Primary failure of tooth eruption and osteoarthritis	Frazier-Bowers SA et al., 2014

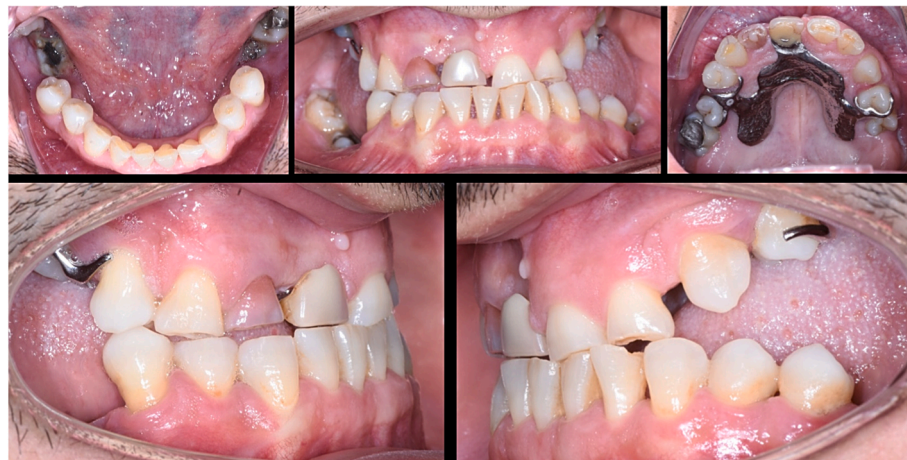

Fig. 1. Intra oral photographs of a 40-year-old patient affected by primary failure of eruption. The four posterior sectors are severely affected and associated with a bilateral open bite.

but a partial eruption was noticed which may explain the presence of dental amalgam fillings or recurrent caries.

Removable partial denture replaced the upper right permanent central incisor (11) lost during a previous trauma. No history of any relevant medical condition was mentioned. The patient never had orthodontic treatment. He did not report eruption disorders in the primary dentition.

Panoramic image reconstruction schema from dental computed tomography (Fig. 2) revealed impacted molars and premolars. Infected foci were associated with caries and/or periodontal disease in impacted teeth as for example on 37 and 46. Internal resorption was suspected in

the second lower left permanent molar (37) and in the first upper left premolar (24). External resorption was also suspected in the first upper left premolar (24). CBCT was performed to assess the presence of ankylosis area, the severity of internal and external resorptions (Fig. 3), radicular morphology, and proximity to adjacent anatomical structures. Indeed, resorptions were detected on nine teeth (15,16,24,25,27,36,37,46,47). Intrapulpal calcifications were visible in several pulp chambers (38,48). No mechanical obstruction has been identified but areas of ankylosis have been detected in some affected teeth (18,17,27,28,36,38,46,47).

I.1 has two daughters aged 7 and 12, who were also examined for

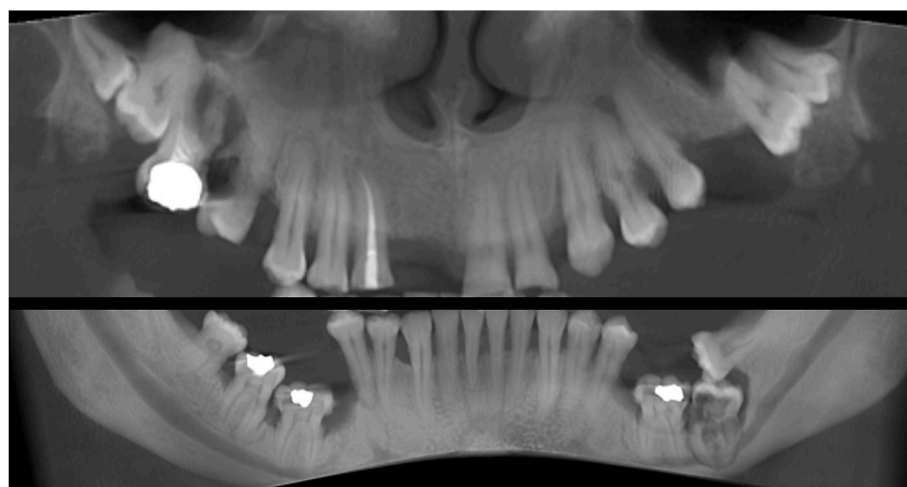


Fig. 2. Automatic panoramic image reconstruction schema from dental computed tomography images of severe primary failure of eruption in a 40-year-old patient. The posterior teeth are impacted even in the absence of a mechanical obstacle.

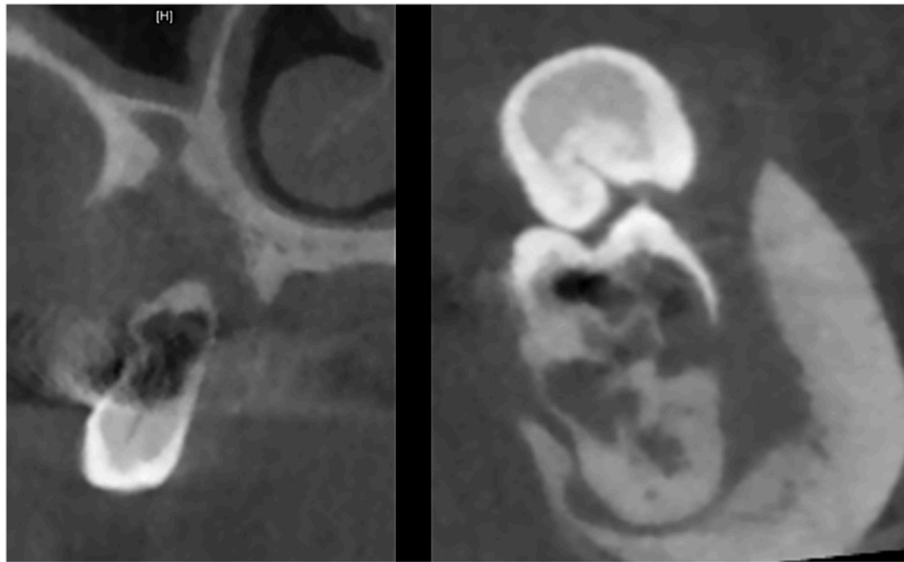


Fig. 3. Severe resorptions detected in the teeth affected by primary failure of eruption (computed tomography images).

possible family involvement. Both girls presented with failure of eruption in primary teeth.

II.1 was 12 years old during initial clinical and radiological examination. No dental abnormalities had been noticed by the parents and the last visit to the dentist was over one year ago. She was in the phase of establishing the young adult denture (Fig. 4). Partial eruption of the first right permanent mandibular molar (46) was observed. The second permanent mandibular molar (47) had not yet erupted but this is still a normal physiological situation related to her age. She presented a Class II malocclusion, with anterior deep bite. Only the right posterior maxilla was affected by PFE. The second upper right primary molar (55) was decayed, rhizolyzed and in a high buccal infraclusion, with a radiolucent associated bone lesion (Fig. 5). The first upper permanent molar and the second premolar partially erupted with mesial and distal tipping respectively.

II.2: The second child, a girl, 7 years old, had a bilateral form of PFE affecting first and second primary molars but not the permanent molars (Figs. 6 and 7). Indeed, the first permanent maxillary and mandibular molars had erupted and were visible in the oral cavity and were in occlusion.

3.2. Genetic testing

Each patient received a detailed explanation of the nature of the study and informed consent was obtained. Saliva of participants was sampled using Oragene-DNA® (Genotek) and DNA was extracted. GenoDENT 4.0, a designed NGS panel targeted towards orodental rare diseases¹⁹ was used to explore the genotype of I.1. This genetic diagnostic solution highlighted a heterozygous substitution in *PTHIR* (NM_000316.3): c.899T > C. This substitution variant is predicted to change a well-conserved amino acid though evolution. The *in silico* predictive algorithms SIFT (v6.2.0),²¹ MutationTaster (v2013)²² and PolyPhen-2 (v2.2.2r398)²³ predict a deleterious variant. This variant localizes into one of the transmembrane protein domains. It is not present in the gnomAD database^{24,25} and to the best of our knowledge never reported in the literature. Other heterozygous missense variants have been linked to PFE (Table 1). Sanger sequencing was used to explore variant co-segregation with PFE in the family. The affected father (I.1) transmitted the class 4 likely-pathogenic variant (according to the ACMG guidelines²⁶) to his two daughters (II.1 and II.2).

3.3. Therapeutic management

Therapeutic management of I.1 consisted in extractions of

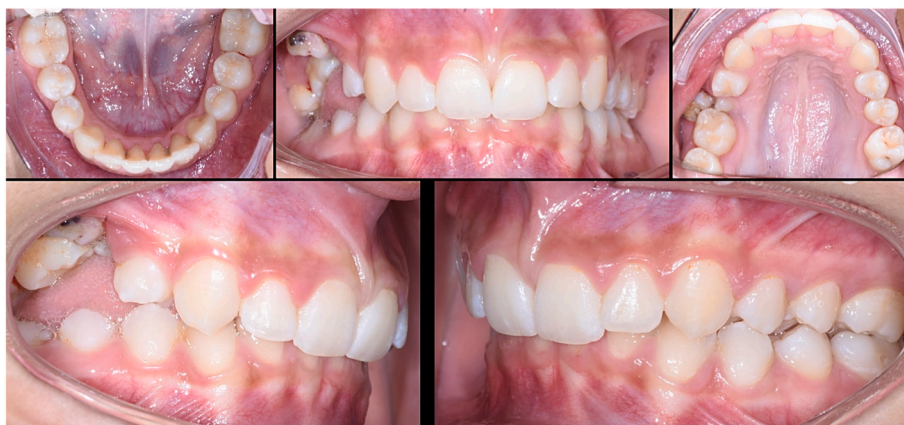

Fig. 4. Intra oral photographs of a 12-year-old girl affected by primary failure of eruption (PFE). The upper right primary second molar is affected. The situation of adjacent teeth could also be related to PFE.

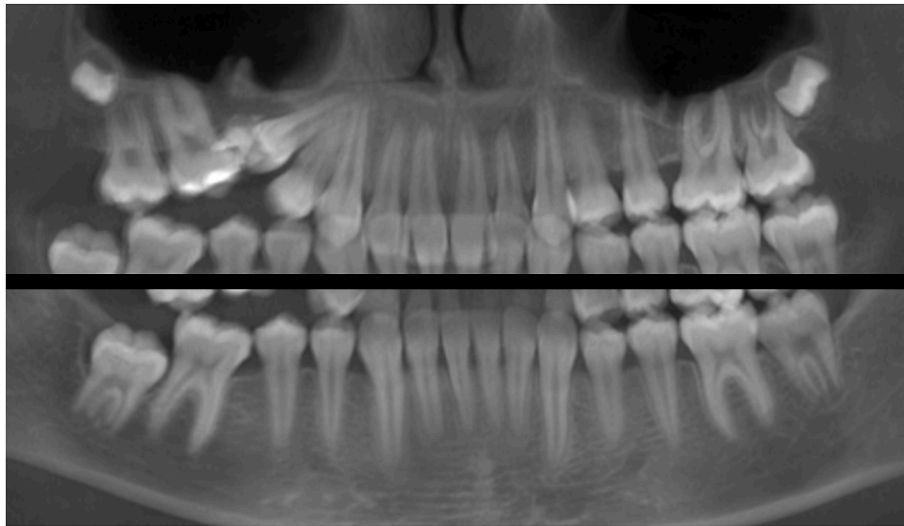


Fig. 5. Automatic panoramic image reconstruction schema from dental computed tomography images in a 12-year-old girl affected by primary failure of eruption.

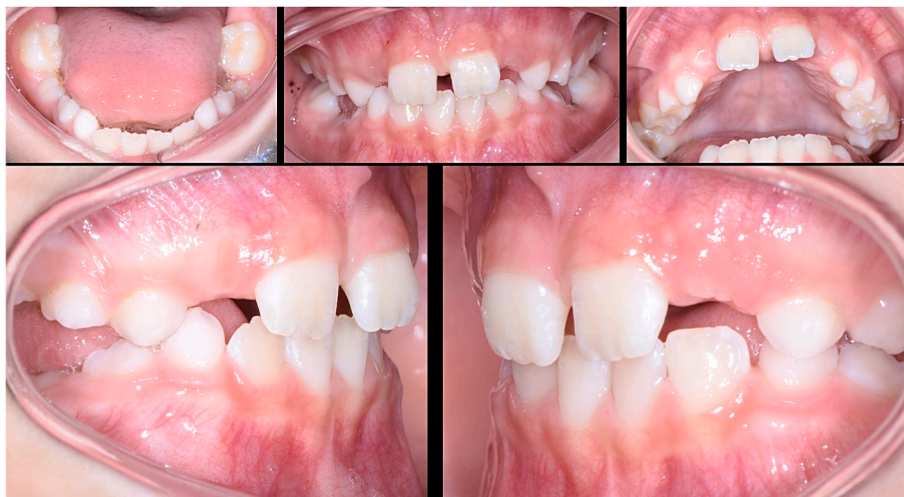

Fig. 6. Intra oral photographs of a 9-year-old girl affected by primary failure of eruption showing the incomplete eruption of the lower primary molars while the first permanent molars are in occlusion.

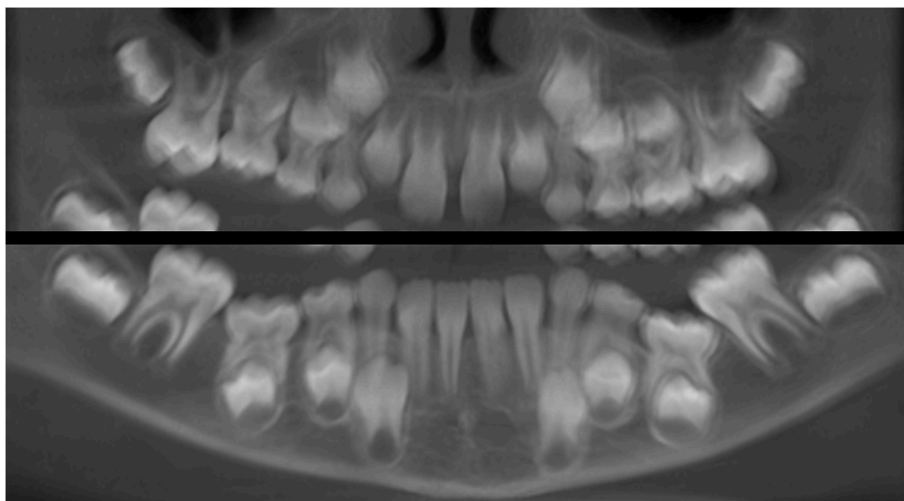


Fig. 7. Primary failure of eruption in mixed denture (automatic panoramic image reconstruction schema from dental computed tomography images).

15,16,17,18,24,25,26,36,37,38 and decoronation of the first and second right mandibular molars (46 and 47) under general anesthesia. Decoronation allowed the preservation of more height and thickness of alveolar bone compared to a surgical extraction, potentially more traumatic, but it could not be performed on teeth with complex internal resorptions.

An implant was placed to replace the incisor, but this sector was not involved in eruption defects. The success of the implant osteointegration in the anterior sector and the bone healing in the posterior sectors were positive outcomes (Fig. 8).

For Patient II. 1, the treatment plan considered the avulsion of the second upper right primary molar (55). A clinical and radiological re-evaluation was done at 6 months post-extraction. The spontaneous evolution was not favourable in the upper right sector, as the teeth had not completed their eruption and the axes were unfavourable. Tooth 4.7 was still unerupted. Initially, the orthodontist began treatment with braces without bone anchorage. Parasitic effects were then observed with worsening of the lateral inclusion and tilting of the occlusal plane. After multidisciplinary consultation, a new approach including a bone anchor was decided upon. A mandibular bone anchor will provide support for the traction of tooth 15. The use of temporary anchorage devices (TADs) will ensure anchorage and limit side effects. Pre-existing tipping of adjacent permanent teeth will then be taken care of.

II.2: Overlap-type bonded restorations will be performed on the second primary molars to restore function. These overlays will be made in composite using CAD/CAM technology. Mesial tipping of the first mandibular molars will prevent the placement of an overlay on the adjacent primary molars. A lingual arch will be positioned to maintain the lee-way until the teenage teeth evolve. Regular monitoring will be needed to monitor the occlusion during growth.

4. Discussion

We have shown that within a family affected by PFE, with all members having the same pathogenic variant of *PTH1R*, the interindividual variability of clinical manifestations is large. The first signs can appear as early as childhood, especially in the primary teeth. Therapeutics must therefore be adapted to the clinical situation, age and growth of the patient.⁸

Genetic diagnosis, based on *PTH1R* sequencing, appears useful in the global management of patients affected by PFE. Indeed, it prevents and explains inefficient orthodontic traction, potential complications of the orthodontic treatment and allows early detection of PFE and management of the offspring.

Decoronations have never been described in patients with PFE. *PTH1R* gene is involved in bone metabolism and calcium homeostasis. However, patients with non-syndromic forms of PFE have no described associated skeletal manifestation, except in rare cases of osteoarthritis.²⁷ So, we can therefore hope that a replacement bone resorption will occur after decoronation at the level of the mandibular molars, thus allowing to maintain alveolar bone height.

PTH1R encodes the transmembrane receptor PTHR1. PTHR1 is the receptor for PTH and PTHrP. Many studies have shown the role of PTH in bone healing.²⁸ Bone healing and implant osseointegration in affected areas could therefore be compromised in patients with *PTH1R* mutation. The placement of dental implants has never been described in PFE patients with a *PTH1R* mutation. These parameters have never been studied, however the healing and osseointegration in our patient seemed optimal. In fact, in the case of the father, an implant was placed in the incisal sector but this sector was not involved in eruption defects. Thus, we plan to restore patients with severe PFE thanks to implants in the molar sector, most often requiring large bone grafts.

5. Conclusion

The diagnosis and management approach in non-syndromic forms of

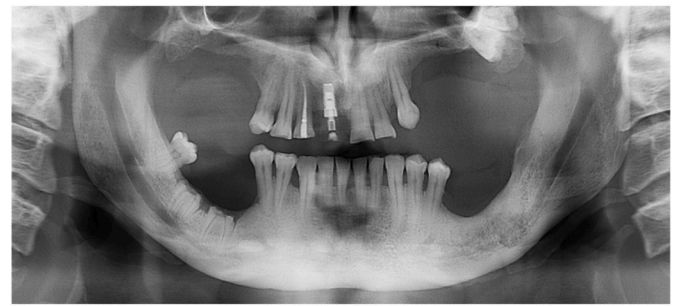


Fig. 8. Panoramic X-ray 18 month after surgery.

PFE is complex. Radiological examination and molecular exploration complete clinical examination and diagnosis. Treatment is multidisciplinary, from child to adulthood, and complex. As PTHR1 plays a role in bone metabolism, therapeutics involving bone remodeling and healing phases such as decoronation or implantology should be the subject of future studies. The prognosis should be better with early diagnosis in childhood and regular follow-up. Genetic diagnosis and counselling are important. Reference center for rare diseases gather the expertise and know how to guide and support treating practitioners and families along the path.

Funding sources

The study "Primary Failure of Eruption (PFE): Highlighting of Clinical, Radiological and Genetic Diagnostic Criteria: Consequences on the Therapeutic Management" was supported by University Hospital, Strasbourg, France (HUS, APJC 2016).

Additional funding were provided by the University Hospital of Strasbourg (HUS, API, 2009–2012, 'Development of the oral cavity: from gene to clinical phenotype in Human', the EU-funded projects (ERDF): A27 'Oro-dental manifestations of rare diseases, supported by the RMT-TMO Offensive Sciences initiative, INTERREG IV Upper Rhine program (www.genosmile.eu), by the INTERREG V N° 1.7 "RARENET" project and by Fonds d'Intervention Régionale (FIR) de l'Agence Régionale de Santé Grand Est Innovation en santé (2019–2022) e-GenoDENT project; NCT02397824.

Acknowledgement

We thank Dr Jean-Christophe Lutz for his collaboration in the management of this case.

References

- Proffit WR, Vig KW. Primary failure of eruption: a possible cause of posterior open-bite. *Am J Orthod.* 1981;80:173–190.
- Hanisch M, Hanisch L, Kleinheinz J, Jung S. Primary failure of eruption (PFE): a systematic review. *Head Face Med.* 2018;15(14):5.
- Grippaudo C, D'Apolito I, Cafiero C, Re A, Chiurazzi P, Frazier-Bowers SA. Validating clinical characteristic of primary failure of eruption (PFE) associated with PTH1R variants. *Prog Orthod.* 2021;13(1):43, 22.
- Grippaudo C, Cafiero C, D'Apolito I, Ricci B, Frazier-Bowers SA. Primary failure of eruption: clinical and genetic findings in the mixed dentition. *Angle Orthod.* 2018;88: 275–282.
- Frazier-Bowers SA, Koehler KE, Ackerman JL, Proffit WR. Primary failure of eruption: further characterization of a rare eruption disorder. *Am J Orthod Dentofacial Orthop.* 2007;131:578.
- Jain U, Kallury A, Rao DD, Bharti HV. Primary failure of eruption (PFE). *BMJ Case Rep.* 2015;2015, bcr2015209703.
- Strub M, Kramer E, Manière MC, Wagner D. Primary failure of eruption: a French prospective survey among the orthodontists from the Grand Est and Bourgogne-Franche-Comté regions. *Orthod Fr.* 2019;90:149–159.
- Yamaguchi T, Tomoyasu Y, Shirota T, et al. Craniofacial and dental characteristics of patients with primary failure of tooth eruption in Japanese. *Hosp Dent.* 2011;23: 11–15.

- 9 Awad MG, Dalbah L, Srirengalakshmi M, Venugopal A, Vaid NR. Review and case report of the treatment in a young girl with primary failure of eruption. *Clin Case Rep.* 2022;17(3), e05632, 10.
- 10 De la Dure-Molla M, Quentric M, Yamaguti PM, et al. Pathognomonic oral profile of Enamel Renal Syndrome (ERS) caused by recessive FAM20A mutations. *Orphanet J Rare Dis.* 2014;9:84.
- 11 Zou Y, Lin H, Chen W, et al. Abnormal eruption of teeth in relation to FGFR1 heterozygote mutation: a rare case of osteoglophonic dysplasia with 4-year follow-up. *BMC Oral Health.* 2022;22:36.
- 12 Ducommun F, Bornstein MM, Bosshardt D, Katsaros C, Dula K. Diagnosis of tooth ankylosis using panoramic views, cone beam computed tomography, and histological data: a retrospective observational case series study. *Eur J Orthod.* 2018;40:231–238.
- 13 Aruna U, Annamalai PR, Nayar S, Bhuminathan S. Primary failure of eruption- a case report with cone beam computerized tomographic imaging. *J Clin Diagn Res.* 2014;8: ZD14–Z16.
- 14 Decker E, Stelzig-Eisenhauer A, Fiebig BS, et al. PTHR1 loss-of-function mutations in familial, nonsyndromic primary failure of tooth eruption. *Am J Hum Genet.* 2008;83: 781–786.
- 15 Risom L, Christoffersen L, Dagaard-Jensen J, et al. Identification of six novel PTH1R mutations in families with a history of primary failure of tooth eruption. *PLoS One.* 2013;8, e74601.
- 16 Assiry AA, Albalawi AM, Zafar MS, et al. KMT2C, a histone methyltransferase, is mutated in a family segregating non-syndromic primary failure of tooth eruption. *Sci Rep.* 2019;9, 16469.
- 17 Frazier-Bowers SA, Simmons D, Timothy Wright J, Proffit WR, Ackerman JL. Primary eruption failure and PTH1R: the importance of a genetic diagnosis for orthodontic treatment planning. *Am J Orthod Dentofacial Orthop.* 2010;137:160.
- 18 Sehra B, Johnson J. The prosthetic management of an infra-occluded first permanent molar: case report. *Dent Update.* 2016;43:482–484.
- 19 Rey T, Tarabeux J, Gerard B, et al. Protocol GenoDENT: implementation of a new NGS panel for molecular diagnosis of genetic disorders with orodental involvement. *Methods Mol Biol.* 2019;1922:407–452.
- 20 Prasad MK, Geoffroy V, Vicaire S, et al. A targeted next-generation sequencing assay for the molecular diagnosis of genetic disorders with orodental involvement. *J Med Genet.* 2016;53(2):98–110.
- 21 Vaser R, Adusumalli S, Leng SN, Sikic M, Ng PC. SIFT missense predictions for genomes. *Nat Protoc.* 2016;11:1–9.
- 22 Schwarz JM, Rödelsperger C, Schuelke M, Seelow D. MutationTaster evaluates disease-causing potential of sequence alterations. *Nat Methods.* 2010;7(8):575–576.
- 23 Adzhubei IA, Schmidt S, Peshkin L, et al. A method and server for predicting damaging missense mutations. *Nat Methods.* 2010;7:248–249.
- 24 Karczewski KJ, Francioli LC, Tiao G, et al. The mutational constraint spectrum quantified from variation in 141,456 humans. *Nature.* 2020;581(7809):434–443.
- 25 Lek M, Karczewski KJ, Minikel EV, Samocha KE, Banks E, et al. Analysis of protein-coding genetic variation in 60,706 humans. Exome Aggregation Consortium. *Nature.* 2016;536:285–291.
- 26 Richards S, Aziz N, Bale S, et al. Standards and guidelines for the interpretation of sequence variants: a joint consensus recommendation of the American college of medical genetics and genomics and the association for molecular pathology. *Genet Med.* 2015;17:405–424.
- 27 Frazier-Bowers SA, Hendricks HM, Wright JT, et al. Novel mutations in PTH1R associated with primary failure of eruption and osteoarthritis. *J Dent Res.* 2014;93: 134–139.
- 28 Stutz C, Batool F, Petit C, et al. Influence of parathyroid hormone on periodontal healing in animal models: a systematic review. *Arch Oral Biol.* 2020;120, 104932.