



**HAL**  
open science

# The use of TNF- $\alpha$ antagonists in tuberculosis to control severe paradoxical reaction or immune reconstitution inflammatory syndrome: a case series and literature review

Lucas Armange, Adèle Lacroix, Paul Petitgas, Cédric Arvieux, Caroline Piau-Couapel, Patrice Poubeau, Matthieu Revest, Pierre Tattevin

## ► To cite this version:

Lucas Armange, Adèle Lacroix, Paul Petitgas, Cédric Arvieux, Caroline Piau-Couapel, et al.. The use of TNF- $\alpha$  antagonists in tuberculosis to control severe paradoxical reaction or immune reconstitution inflammatory syndrome: a case series and literature review. *European Journal of Clinical Microbiology and Infectious Diseases*, 2023, 42 (4), pp.413-422. 10.1007/s10096-023-04564-2 . hal-04016411

**HAL Id: hal-04016411**

**<https://hal.science/hal-04016411>**

Submitted on 5 May 2023

**HAL** is a multi-disciplinary open access archive for the deposit and dissemination of scientific research documents, whether they are published or not. The documents may come from teaching and research institutions in France or abroad, or from public or private research centers.

L'archive ouverte pluridisciplinaire **HAL**, est destinée au dépôt et à la diffusion de documents scientifiques de niveau recherche, publiés ou non, émanant des établissements d'enseignement et de recherche français ou étrangers, des laboratoires publics ou privés.



Distributed under a Creative Commons Attribution - NonCommercial 4.0 International License

1 **The use of TNF- $\alpha$  antagonists in tuberculosis to control severe paradoxical**  
2 **reaction or immune reconstitution inflammatory syndrome: a case series and**  
3 **literature review**

4 Lucas Armange,<sup>1,2</sup> Adèle Lacroix,<sup>3</sup> Paul Petitgas,<sup>1</sup> Cédric Arvieux,<sup>1</sup> Caroline Piau-Couapel,<sup>4</sup>  
5 Patrice Poubeau,<sup>2</sup> Matthieu Revest,<sup>1</sup> Pierre Tattevin<sup>1</sup>

6 <sup>1</sup> Infectious diseases and intensive care unit, Pontchaillou University Hospital, Rennes, France

7 <sup>2</sup> Infectious diseases, Saint-Pierre Hospital, La Réunion, France

8 <sup>3</sup> Infectious diseases, General Hospital, Avignon, France

9 <sup>4</sup> Microbiology, Pontchaillou University Hospital, Rennes, France

10

11 **Running Head:** TNF- $\alpha$  antagonists in tuberculosis to control severe paradoxical reaction

12

13 **Corresponding author:**

14 Prof. Pierre Tattevin, MD, PhD

15 Infectious diseases and intensive care unit, Pontchaillou Hospital, University Rennes-1, F-  
16 35033, Rennes, France.

17 e-mail : pierre.tattevin@chu-rennes.fr

18

19 **Word count: 2798**

20

21

22 **ABSTRACT**

23 **BACKGROUND:** Paradoxical reaction (PR) and immune reconstitution inflammatory  
24 syndrome (IRIS) are common complications of tuberculosis treatment. Corticosteroids are first-  
25 line treatment for severe PR or IRIS, particularly neurological.

26 **METHODS:** We report four cases of severe PR or IRIS during tuberculosis treatment who  
27 required TNF- $\alpha$  antagonists, and identified 20 additional cases through literature review.

28 **RESULTS:** They were 14 women and 10 men, with a median age of 36 years [interquartile  
29 range, 28-52]. Twelve were immunocompromised before tuberculosis: untreated HIV infection  
30 (n=6), or immunosuppressive treatment (TNF- $\alpha$  antagonists, n=5; tacrolimus, n=1).  
31 Tuberculosis was mostly neuromeningeal (n=15), pulmonary (n=10), lymph node (n=6), and  
32 miliary (n=6), multi-susceptible in 23 cases. PR or IRIS started after a median time of 6 weeks  
33 (IQR, 4-9) following anti-tuberculosis treatment start, and consisted primarily of tuberculomas  
34 (n=11), cerebral vasculitis (n=8), and lymphadenitis (n=6). First-line treatment of PR or IRIS  
35 was high dose corticosteroids in 23 cases. TNF- $\alpha$  antagonists were used as salvage treatment in  
36 all cases, with infliximab (n=17), thalidomide (n=6), and adalimumab (n=3). All patients  
37 improved, but 6 had neurological sequelae, and 4 had TNF- $\alpha$  antagonist-related severe adverse  
38 events.

39 **CONCLUSIONS:** TNF- $\alpha$  antagonists are safe and effective as salvage or corticosteroid-  
40 sparing therapeutic for severe PR or IRIS during tuberculosis treatment.

41

42 **Keywords.** TNF- $\alpha$  antagonists; tuberculosis; paradoxical reaction; immune reconstitution  
43 inflammatory syndrome; infliximab

44

## 45 **Introduction**

46 Patients with tuberculosis may develop paradoxical reaction (PR) while on anti-tuberculosis  
47 treatment, especially those with neuromeningeal tuberculosis. The pathway of PR is close to  
48 the immune reconstitution inflammatory syndrome (IRIS), primarily reported in  
49 immunocompromised HIV-infected patients when they start antiretrovirals (ARV), or in  
50 patients with iatrogenic immunosuppression, when their immunosuppressive treatment is  
51 interrupted: Both PR and IRIS imply an exacerbated immune response to infectious antigens.  
52 Diagnostic criteria,<sup>1</sup> and guidelines for management have been proposed.<sup>2,3</sup> In HIV-infected  
53 patients IRIS occur in 8-45% of patients, with a median delay of two weeks after ARV start.<sup>4</sup>  
54 Most experts recommend symptomatic treatment for non-severe tuberculosis-related PR and  
55 IRIS (ie, not life-threatening, no neurological manifestation), and high-dose corticosteroids as  
56 first-line treatment otherwise.<sup>5,6</sup>

57 When this first-line treatment fails, or in patients who relapse during corticosteroids doses  
58 tapering, TNF- $\alpha$  antagonists may be considered as salvage treatment, given the primary role of  
59 TNF- $\alpha$  in the immune response to tuberculosis, despite the fear that it may jeopardize the control  
60 of tuberculosis. We report four cases of TNF- $\alpha$  antagonists use for severe PR or IRIS and  
61 performed a systematic literature review to better characterize their efficacy and tolerability in  
62 this indication.

63

## 64 **Methods**

65 Rennes University Hospital is a 1800-bed referral centre for complex tuberculosis in western  
66 France (population catchment area, 1 million inhabitants). We extracted all cases of tuberculosis  
67 disease managed between 2010 and 2020 in adults from a computerized database. Among the  
68 823 patients identified, three (0.4%) received TNF- $\alpha$  antagonists. We identified a fourth

69 unpublished case from La Réunion island, a French oversea territory in Indian Ocean. Data  
70 were collected from medical files on a standardized questionnaire, and anonymized in line with  
71 the French regulation for data collection. All patients provided informed consent. Data collected  
72 included demographics, comorbidities with a special focus on immunosuppressive diseases and  
73 treatments, the characteristics and the management of tuberculosis and tuberculosis-related PR  
74 or IRIS, and the outcome.

75 We performed a systematic literature review, on PUBMED (NCBI databases) looking for  
76 any case of tuberculosis-related PR or IRIS treated by TNF- $\alpha$  antagonists. Pediatric cases (age  
77 <18 years) were excluded. Patients treated with TNF- $\alpha$  antagonists before tuberculosis and who  
78 developed IRIS following discontinuation of TNF- $\alpha$  antagonists were included if TNF- $\alpha$   
79 antagonists were reintroduced as a treatment of tuberculosis-related IRIS. The search strategy  
80 used the following terms: "IMMUNE RECONSTITUTION INFLAMMATORY  
81 SYNDROME" OR "PARADOXICAL REACTION."; "TUBERCULOSIS" OR  
82 "MYCOBACTERIUM TUBERCULOSIS"; " TNF- $\alpha$  INHIBITORS" OR " TNF- $\alpha$   
83 ANTAGONIST" OR "INFLIXIMAB" OR "ADALIMUMAB" OR "ETANERCEPT" OR  
84 "THALIDOMIDE". We also reviewed the citations of main articles to identify additional cases.  
85 Qualitative data are reported as numbers (%), and quantitative data as medians [interquartile  
86 range].

87

## 88 **Results**

### 89 *Case reports*

90 *Case 1:* A 33-year-old HIV-negative woman who grew up in Cambodia presented with weight  
91 loss, fever, dyspnea and confusion. Chest CT scan revealed apical lung mass, and respiratory  
92 samples yielded multi-susceptible *Mycobacterium tuberculosis*. Brain magnetic resonance

93 imaging (MRI) studies showed thickening of the meninges. On cerebrospinal fluid (CSF)  
94 analysis, white cells count was  $160/\text{mm}^3$  (98% lymphocytes), protein 2.25 g/L, glucose 3.3  
95 mmol/L (glycemia, 5.7 mmol/L), with a positive PCR for *M. tuberculosis*. Isoniazid, rifampicin,  
96 and pyrazinamide were started along with prednisolone, 1 mg/kg/day during 4 weeks, and the  
97 confusion resolved within the first week. On week 5, while prednisolone dose was tapered to  
98 0.75 mg/kg/day, confusion relapsed. Brain MRI found a non-communicating hydrocephalus,  
99 with brain vasculitis. We performed a ventriculo-peritoneal shunt (VPS) with septostomy, and  
100 she received a three-day course of high-dose dexamethasone, followed by prednisolone 1  
101 mg/kg/day. Her neurological status did not return to normal with cognitive disorders, and motor  
102 deficit of the left lower limb. Control MRI at 3 months revealed cerebral and medullar  
103 tuberculomas with perilesional edema (Figure 1). We introduced thalidomide (50 mg t.i.d.) for  
104 two months, with an additional three-day course of high-dose dexamethasone, again followed  
105 by prednisolone 1 mg/kg/day, and she gradually improved. Five months later, when  
106 prednisolone dose was tapered to 0.75 mg/kg/day, the left lower limb motor deficit reappeared,  
107 and MRI revealed worsening of brain and medullar lesions. Intravenous infliximab was started  
108 (10 mg/kg every month during 3 months), and she dramatically improved, clinically and on  
109 imaging studies, which allowed to prednisolone dose tapering to 0.25 mg/kg/day. Two months  
110 after the third perfusion of infliximab, a ptosis appeared and brain MRI revealed worsening of  
111 brain lesions with perilesional edema. Prednisolone was increased to 1 mg/kg/day and  
112 infliximab monthly infusions (10 mg/kg) were restarted, for an additional 6 months.  
113 Prednisolone was tapered to 5 mg/day. Five months after the last injection, clinical condition  
114 and MRI had dramatically improved. Prednisolone was slowly tapered and stopped 2 months  
115 after. Five years later, she remained with mild neurological sequels.

116 *Case 2:* A 27-year-old HIV-negative man who grew up in Guinea was admitted with fever,  
117 headache, confusion, and orchitis. Brain imaging revealed non-communicating hydrocephalus.

118 On CSF analysis, white cells count was 860/mm<sup>3</sup> (80% lymphocytes), protein 3.76 g/L, glucose  
119 0.96 mmol/L (glycemia, 5.8 mmol/L), and tests for tuberculosis on CSF, including PCR and  
120 cultures, returned negative. Biopsy of the epididymis yielded pan-susceptible *M. tuberculosis*.  
121 We performed ventriculo-septostomy with VPS, and started isoniazid, rifampicin,  
122 pyrazinamide, and prednisolone, 1 mg/kg/day. He gradually improved, and prednisolone was  
123 tapered during the second month (daily dose decreased by 25% every week), and stopped after  
124 2 months. After 6 months, he developed left hemiparesis. MRI revealed one cerebellar and one  
125 extra-axial tuberculoma with brainstem compression (Figure 2). We started high dose  
126 dexamethasone, followed by 3 monthly intravenous infusions of infliximab (10 mg/kg) along  
127 with prednisolone, 1 mg/kg/day during one month, followed by slow tapering (10% decrease  
128 every week). The patient gradually improved, with no sequelae at a follow-up of 3 years after  
129 all treatments were stopped.

130 *Case 3:* A 26-year-old HIV-negative woman who grew up in Serbia was admitted for asthenia,  
131 night sweats, fever, and blurred vision, while she was pregnant (13 weeks). Her past medical  
132 history was remarkable for severe Crohn disease, treated by adalimumab and prednisolone.  
133 Respiratory samples yielded pan-susceptible *M. tuberculosis*. Ophthalmologic examination was  
134 suggestive of tuberculosis-related uveitis. We started isoniazid, rifampicin, pyrazinamide, and  
135 prednisolone (1 mg/kg/day during one month, with gradual tapering by 25% each week during  
136 the second month), and adalimumab was stopped. She dramatically improved and the  
137 pregnancy went well, but 17 days after delivery, she presented abdominal pain, contracture,  
138 fever and hypotension. She underwent emergency laparotomy which revealed granulomatous  
139 peritonitis. Per-operative and respiratory samples tested negative for tuberculosis by PCR and  
140 cultures. She spontaneously improved and was diagnosed with post-pregnancy IRIS. Six  
141 months later, she developed enlarged supraclavicular lymph nodes with a 37 mm presternal  
142 mass on CT scan (Figure 3). Biopsy of the presternal mass revealed necrotizing epithelioid

143 granulomas with acid-fast bacilli after Ziehl-Neelsen stain and positive tuberculosis PCR, but  
144 negative cultures. As the patient presented no complaint, and the investigations were suggestive  
145 of IRIS, she received no treatment. Three years later, she developed enlargement of cervical  
146 and supraclavicular lymph nodes. CT scan revealed multiple collections (cervical, thoracic,  
147 pleural, peritoneal, hepatic). Test for tuberculosis on respiratory samples returned negative, and  
148 lymph nodes returned to normal. Six months later (i.e., 4.5 years after the end of antituberculosis  
149 treatment), cervical lymph nodes increased again, with the reappearance of the pre-sternal mass.  
150 PCR test for tuberculosis was still positive on a biopsy, with no genetic resistance to isoniazid  
151 and rifampicin. In line with the patient wish, we restarted isoniazid, rifampicin, pyrazinamide,  
152 associated with three monthly infusions of infliximab (5 mg/kg). She completed a 6-month  
153 course of antituberculosis treatment, but enlarged lymph nodes and the presternal mass  
154 remained stable at one year, still asymptomatic.

155 *Case 4:* A 61-year-old HIV-negative woman, who grew up in Mayotte, was admitted for fever,  
156 weight loss, and dyspnea. Her past medical history was remarkable for meningeal bleeding  
157 following ruptured brain aneurysm, complicated by hydrocephalus treated by a VPS. Chest  
158 radiography and CT scan on admission revealed unilateral moderate pleural effusion, with  
159 lymphocytic and exudative pleural fluid (3900 white cells/mm<sup>3</sup> with 69% lymphocytes, protein  
160 45 g/L). Respiratory samples and pleural fluid tested negative for tuberculosis on microscopic  
161 examination and cultures. Four months later, she complained of abdominal pain. CT scan  
162 revealed a 10 cm-abdominal collection encompassing the VPS tip. The collection was  
163 percutaneously drained, and microbiological tests, including tests for tuberculosis, returned  
164 negative. The collection relapsed, and required surgical resection 8 months later. Histological  
165 studies of the collection wall revealed necrotizing giganto-cellular epithelioid granuloma  
166 suggestive of tuberculosis, but microscopic examination and cultures for tuberculosis returned  
167 negative. Two months later, she was readmitted for fever and status epilepticus. On CSF



168 analysis, white cells count was 1100/mm<sup>3</sup> (91% lymphocytes), protein 6 g/L, glucose 2.9  
169 mmol/L (glycemia, 9.6 mmol/L), but all tests for tuberculosis on CSF, including PCR and  
170 cultures, returned negative. Brain MRI showed hydrocephalus and vasculitis, VPS was replaced  
171 by external ventricular catheter, followed by a ventriculoatrial shunt (VAS). Finally, PCR test  
172 for tuberculosis retrospectively performed from the granulomatous abdominal collection wall  
173 returned positive. She was treated with isoniazid, rifampicin, pyrazinamide, ethambutol and  
174 moxifloxacin, associated with intravenous dexamethasone, 10 mg x 4/day, and her neurological  
175 status improved. Every attempt to decrease corticosteroids was followed by deterioration of her  
176 neurological status associated with worsening of brain imaging and CSF analysis. She received  
177 3 injections of infliximab (5 mg/kg every 2 weeks), and dramatically improved, clinically, on  
178 CSF analysis, and on imaging studies. She was transferred to a rehabilitation department.

#### 179 *Literature review*

180 Our literature review identified 16 reports of tuberculosis-related PR or IRIS treated by TNF- $\alpha$   
181 antagonists, with a total of 20 cases reported. The characteristics of these cases, merged with  
182 the 4 reported above, are presented in Tables 1 and 2. They were 14 women (including two  
183 pregnant women), and 10 men, with a median age of 36 years [28-52]. Twelve were  
184 immunocompromised before tuberculosis diagnosis: Six were HIV-infected, all uncontrolled  
185 (median CD4 count, 67/mm<sup>3</sup> [30-121]), mostly because HIV infection was diagnosed as the  
186 same time as tuberculosis (n=4). Six additional patients were immunocompromised due to  
187 immunosuppressive treatment: Five were on TNF- $\alpha$  antagonists for rheumatic diseases (n=3),  
188 or Crohn disease (n=2), and one on tacrolimus for sarcoidosis.

189 Tuberculosis was mostly neuromeningeal (n=15), pulmonary (n=10), lymph node (n=6),  
190 and miliary (n=6), multi-susceptible in all cases tested (23/23). Treatment included isoniazid,  
191 rifampicin, pyrazinamide, and ethambutol in all cases, in addition to moxifloxacin in 4 cases,  
192 and corticosteroids in 16 cases. Overall, PR or IRIS started after a median time of 6 weeks [4-

193 9] following anti-tuberculosis treatment start. More precisely, the median time from  
194 tuberculosis treatment start to PR onset was 4 weeks [4-7] in immunocompetent patients, mostly  
195 (9/12, 75%) during corticosteroids tapering. In untreated HIV-infected patients, median time  
196 from ARV start to IRIS onset was 2 weeks [2-2]. For patients previously on TNF- $\alpha$  antagonist,  
197 median time from TNF- $\alpha$  antagonist discontinuation to IRIS onset was 3 months [2-3].

198 PR or IRIS included tuberculomas (n=11), cerebral vasculitis (n=8), lymph nodes  
199 enlargement (n=6), hydrocephalus (n=5), meningitis (n=3), arthritis (n=2), spondylodiscitis,  
200 brain abscess, pneumonia, lung nodules, lung abscess, chylothorax, peritonitis, and kidney  
201 granuloma (one patient each). First-line treatment of PR or IRIS was high-dose corticosteroids  
202 in 23 cases: dexamethasone (n=10), methylprednisolone (n=4), prednisone (n=4), prednisolone  
203 (n=3), or not specified (n=2). TNF- $\alpha$  antagonists were used as second-line treatment for PR or  
204 IRIS in all cases, with infliximab (n=17), thalidomide (n=6), and adalimumab (n=3), with  
205 heterogenous regimens in terms of doses and intervals. All patients improved clinically, and  
206 20/24 (83%) improved on follow-up imaging studies: MRI (n=16), CT (n=3), or PET scan  
207 (n=1). One patient died, for unrelated reason. Six patients had neurological sequelae, and four  
208 had TNF- $\alpha$  antagonist-related severe adverse events: peripheral neuropathy (thalidomide, n=3),  
209 and hypersensitivity (infliximab, n=1).

210

## 211 **Discussion**

212 The major findings of this case series and literature review on the use of TNF- $\alpha$  antagonists to  
213 control severe tuberculosis-related PR or IRIS are the followings: First, limited data are  
214 currently available, as we could only identify 20 cases through a systematic literature review.  
215 Although this small number is certainly an underestimate, as most cases have probably not been  
216 reported in the literature, it reflects that use of TNF- $\alpha$  antagonists in this indication is probably

217 rare, restricted to corticosteroid-resistant cases, or as corticosteroid-sparing regimen in case of  
218 corticosteroid-dependence. Second, CNS involvement is a key factor in the pathogenesis of  
219 severe PR or IRIS. Indeed, 15/24 patients (63%) developed severe PR or IRIS while they were  
220 treated for neuromeningeal tuberculosis, while the proportion of tuberculosis with CNS  
221 involvement is 2-4%.<sup>7</sup> In addition, CNS is also the primary site for severe PR or IRIS  
222 manifestations, with at least one CNS complication in 16/24 (67%) of cases, primarily  
223 tuberculomas (n=11), cerebral vasculitis (n=8), and hydrocephalus (n=5). Third, TNF- $\alpha$   
224 antagonists were only prescribed as second-line treatment, after different regimens of  
225 corticosteroids, mostly for PR or IRIS of early onset (median time from tuberculosis treatment  
226 start, 6 weeks [IQR 4-9]). Fourth, infliximab was the main TNF- $\alpha$  antagonists in this indication  
227 (17/24, 71%), with a striking heterogeneity in terms of dose per injection (3 to 10 mg/kg),  
228 intervals (2 to 4 weeks), and total duration (1 day,<sup>8</sup> to 9 months). Fifth, despite TNF- $\alpha$   
229 antagonists have been used as salvage treatment in the most complicated PR or IRIS, the  
230 outcome was good in most cases, with 100% rate of improvement, and good tolerability. This  
231 is particularly remarkable, given that 50% of patients (12/24) were immunocompromised prior  
232 to TNF- $\alpha$  antagonists start, and none experienced uncontrolled tuberculosis following TNF- $\alpha$   
233 antagonists use for severe PR or IRIS.

234 TNF- $\alpha$  is a pro-inflammatory and immunoregulatory cytokine, playing a major role in  
235 adaptive immunity against *M. tuberculosis*: it enhances the release of pro-inflammatory  
236 cytokines IL-1 and IL-6, stimulates phagocytosis by leukocytes, and recruits various immune  
237 cells around the infectious foci. In latent tuberculosis infection, TNF- $\alpha$  is of paramount  
238 importance for granulomas genesis, which allows to control *M. tuberculosis* replication and  
239 dissemination. This key role is illustrated by the disproportionate incidence of tuberculosis  
240 disease following initiation of TNF- $\alpha$  antagonists in patients with untreated latent tuberculosis  
241 infection.<sup>9</sup> Conversely, PR and IRIS are characterized by an excess of pro-inflammatory

242 cytokines (TNF- $\alpha$ , IL-1, IL-6), not compensated by anti-inflammatory cytokines (IL-10).<sup>10</sup> This  
243 observation lead to the hypothesis that TNF- $\alpha$  antagonists would be appropriate to control  
244 corticoid-resistant PR or IRIS, with the benefit of selective action on the main cytokine  
245 involved, contrarily to the broad effect of corticosteroids on the immune system. However, the  
246 powerful and long-lasting effect of TNF- $\alpha$  antagonists may lead to the progression of  
247 tuberculosis due to the loss of TNF- $\alpha$  activity. The literature review is quite reassuring in this  
248 regard: Indeed, we did not identify a single case of uncontrolled tuberculosis associated with  
249 the use of TNF- $\alpha$  antagonists as salvage treatment of PR or IRIS.

250 Overall, the tolerability of TNF- $\alpha$  antagonists was good, with the notable exception of  
251 thalidomide. The incidence of severe adverse event was 5.9% (1/17) in patients treated with  
252 infliximab (hypersensitivity), as compared to 50% (3/6) in those treated with thalidomide  
253 (peripheral neuropathy). Of note thalidomide has been only used for the first cases, in our series  
254 (case #1) as well as in the literature, with no report of thalidomide use over the last 8 years in  
255 this indication. All recent cases received infliximab. The high risk of peripheral neuropathy,  
256 combined with the difficulty to detect this severe adverse event early due to the high prevalence  
257 of neurological impairment in these patients advocate against the use of thalidomide for severe  
258 PR or IRIS. We would recommend infliximab as the preferential TNF- $\alpha$  antagonist in this  
259 indication. The fact that most cases of PR and IRIS had a favourable outcome with a large  
260 heterogeneity of infliximab dose, and duration, suggests that PR and IRIS control does not  
261 necessarily requires high dose, or prolonged duration of infliximab. In our opinion, first-line  
262 treatment could be subcutaneous infliximab, 5 mg/kg at week 0, 2, and 6. A maintenance  
263 regimen (eg, 5 mg/kg every 8 weeks), may be indicated in the most severe or refractory cases.

264 This study has limitations, primarily due to study design, and limited sample size. As the  
265 study was retrospective and observational, we may have failed to collect important data, and  
266 several biases may have occurred. The follow-up was not standardized (median 12 months [12-

267 12], range 6-144 months): Although we could collect data after at least 12 months of follow-up  
268 for 16/24 patients, we may have missed late relapses, or delayed adverse events related to TNF-  
269  $\alpha$  antagonists. Finally, publication bias is of particular concern: Indeed, case reports are more  
270 likely to be submitted, and accepted for publication, when the outcome is favourable, which  
271 limits the interpretation of cumulative findings extracted from single case reports. However,  
272 our study - by far the largest to date – adds a brick in the wall by demonstrating that the use of  
273 TNF- $\alpha$  antagonists as salvage treatment for severe cortico-resistant PR or IRIS – primarily  
274 infliximab - has been associated with good outcomes in most cases, with 100% rate of  
275 improvement, good tolerability, and no emergence of uncontrolled tuberculosis disease.

276

### 277 *Acknowledgements*

278 The authors would like to thank the patients who participated in the study, and the health care  
279 workers who took care of them.

280 The authors have no competing interests to declare that are relevant to the content of this article.

281 The authors did not receive support from any organization for the submitted work.

**Table 1.** Patients treated with TNF- $\alpha$  antagonists for severe paradoxical reaction or immune reconstitution inflammatory syndrome (case reports and literature review)

Author, year	Sex, age (years)	Immuno suppression	Tuberculosis (TB) sites	TB treatment	Time from treatment to PR or IRIS onset	PR or IRIS Manifestations	First line corticosteroid	TNF- $\alpha$ antagonists	Outcome	Follow-up, months
Roberts, 2003 [11]	F, 23	No	Pulmonary, CNS, lymph nodes	IREP	ND	Tuberculoma, visual pathway compression	Dexamethasone (dose not specified)	Thalidomid 50 mg bid (duration not available)	Improved, with sequelae (hemianopsia)	12
Roberts, 2003 [11]	F, 37	No	CNS	IREP	8 weeks	Tuberculoma, CNS vasculitis	Dexamethasone (dose not specified)	Thalidomid 50 mg tid (9 months)	Improved, but unrelated death (stroke)	9
Blackmore, 2008 [12]	F, 42	No	Miliary, CNS	IREP	4 weeks	Tuberculoma	Methylprednisolone 1 g/day	Infliximab 10 mg/kg/month (3 months)	Improved, no sequelae	12
Wallis, 2009 [13]	F, 29	Rheumatoid arthritis (adalimumab)	Pulmonary	IREP	2 weeks	Severe pneumonia	Methylprednisolone 2 mg/kg/day	Adalimumab (restart)	Improved, no sequelae	ND
O'Dowd, 2011 [14]	M, 28	Crohn disease (infliximab)	Lymph nodes	IREP	8 weeks	Lymph nodes, pulmonary abscess	Prednisolone 40 mg/day	Infliximab (restart)	Improved, no sequelae	12
Jorge, 2012 [15]	M, 20	Juvenile idiopathic arthritis (infliximab)	Miliary, CNS	IREP, MXF	12 weeks	Tuberculoma, CNS vasculitis, hydrocephalus	Dexamethasone (dose not specified)	Infliximab (restart)	Improved, no sequelae	12
Lee, 2012 [16]	M, 63	No	CNS	IREP	1 week	Meningitis, hydrocephalus	Dexamethasone 20 mg/day	Adalimumab 40 mg every 2 months (6 months)	Improved, with sequelae (cognitive)	12
Vandecasteele, 2012 [17]	M, 58	Rheumatic disease (infliximab)	Pulmonary, lymph nodes	IREP	12 weeks	CNS vasculitis	Dexamethasone 12 mg/day	Infliximab (restart)	Improved, no sequelae	12
Brunel, 2012 [18]	F, 19	HIV	ND	IREP	28 weeks	Lymph nodes, kidney granuloma	Prednisone 2 mg/kg/day	Thalidomid 100 mg/day (14 months)	Improved, no sequelae	12
De La Riva, 2013 [19]	F, 35	No	Pulmonary, CNS	IREP	6 weeks	Tuberculoma	Dexamethasone (dose not specified)	Thalidomid 100 mg bid (8 months)	Improved, with sequelae (ataxia)	12
Fourcade, 2014 [20]	F, 51	HIV	CNS	IREP	4 weeks	Tuberculoma, meningitis	Methylprednisolone 2 mg/kg/day	Thalidomid 100 mg/day, then 50 mg/day (5 months)	Improved, no sequelae	ND
Richaud, 2015 [21]	M, 30	HIV	Lymph nodes	IREP, MXF	6 weeks	Lymph nodes, spondylo-discitis	Corticosteroids (molecule and dose not specified)	Infliximab 5 mg/kg/month (6 months)	Improved, no sequelae	ND
Molton, 2015 [22]	F, 60	No	CNS	IREP	4 weeks	CNS vasculitis, brain abscesses	Dexamethasone (dose not specified)	Infliximab 10 mg/kg/month (3 months)	Improved, with sequelae (cognitive)	12
Molton, 2015 [22]	F, 32	No	Miliary, CNS, laryngeal	IREP	4 weeks	Tuberculoma, hydrocephalus	Prednisolone 60 mg/day	Infliximab 5 mg/kg/2 weeks (2 months)	Improved, no sequelae	12

Hsu, 2016 [8]	M, 41	HIV	Miliary, pulmonary, articular	IREP	8 weeks	Lung nodules, arthritis, chylothorax	Prednisone 80 mg/day	Infliximab 4 mg/kg one injection	Improved, no sequelae	ND
Hsu, 2016 [8]	M, 42	HIV	Pulmonary, lymph nodes	IREP	6 weeks	Lymph nodes	Prednisone 50 mg/day	Infliximab 5 mg/kg/2 weeks (6 weeks)	Improved, no sequelae	ND
Lwin, 2018 [23]	M, 51	HIV	Miliary, CNS	IREP	6 weeks	Meningitis, CNS vasculitis	Prednisolone 60 mg/day	Infliximab* then adalimumab 40 mg/2 weeks (3 months)	Improved, no sequelae	ND
Santin, 2020 [24]	F, 53	Sarcoidosis (tacrolimus)	Pulmonary, CNS	IREP	5 weeks	Tuberculoma	Dexamethasone 24 mg/day	Infliximab 300 mg/kg 3 injections (2 months)	Improved, no sequelae	12
Santin, 2020 [24]	M, 19	No	CNS	IREP, MXF	4 weeks	Tuberculoma, CNS vasculitis, hydrocephalus	Dexamethasone (dose not specified)	Infliximab 3 mg/kg/month (6 months)	Improved, with sequelae (deafness)	12
Eshag, 2020 [25]	F, 55	No	Lymph nodes	IREP	3 weeks	Arthritis, lymph nodes	Prednisone 60 mg/day	Infliximab 5mg/kg/month (9 months)	Improved, no sequel	12
Case 1 (Rennes)	F, 33	No	Pulmonary, CNS	IREP	4 weeks	CNS vasculitis, hydrocephalus tuberculoma	Methylprednisolone 3 mg/kg/day	Thalidomid** then Infliximab 10 mg/kg/month (9 months)	Improved, with sequelae (common oculomotor nerve and left lower limb paresis)	144
Case 2 (Rennes)	M, 27	No	Genital, CNS	IREP	16 weeks	Tuberculoma	Dexamethasone 10 mg/day	Infliximab 10 mg/kg/month (3 months)	Improved, no sequelae	84
Case 3 (Rennes)	F, 26	Crohn disease (adalimumab)	Miliary, pulmonary, ocular	IREP	24 weeks	Peritonitis, lymph nodes, multiple collections	-	Infliximab 5 mg/kg/month (3 months)	Stable (10 years)	120
Case 4 (Reunion Island)	F, 61	No	Pulmonary, abdominal, CNS	IREP, MXF	9 weeks	Status epilepticus, CNS vasculitis	Corticosteroids (molecule and dose not specified)	Infliximab 5 mg/kg/2 weeks (6 weeks)	Initial improvement (6 months), ongoing early rehabilitation	6

*PR, paradoxical reaction; IRIS, immune reconstitution inflammatory syndrome; CNS, central nervous system; IREP, isoniazid rifampicin ethambutol pyrazinamide; MXF, moxifloxacin; IRIS, immune reconstitution inflammatory syndrome; TB, Tuberculosis*

*\*Infliximab 300 mg/2 weeks (1 month), then adalimumab*

*\*\*Thalidomide 50 mg tid during 2 months, then infliximab*

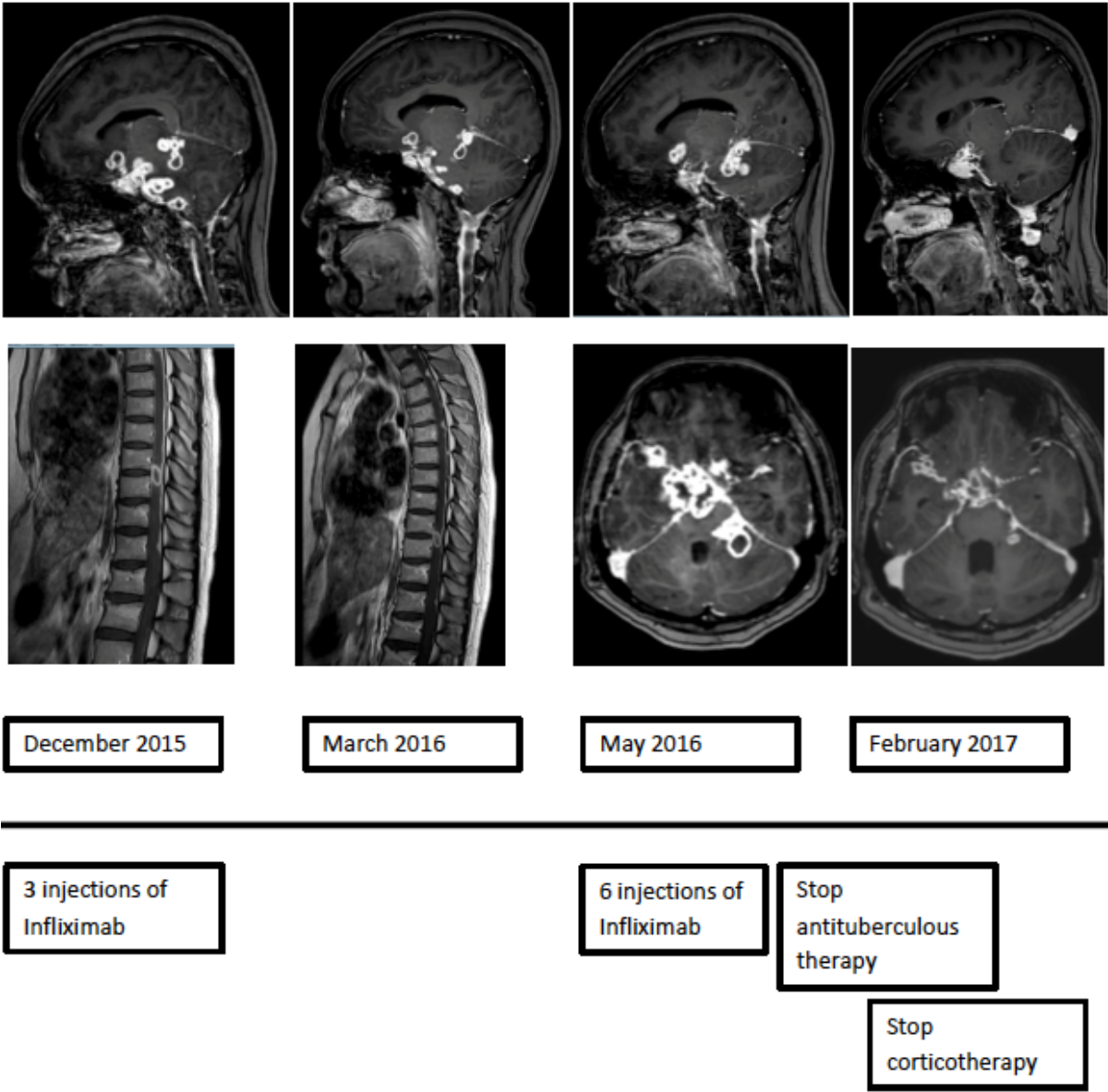
**Table 2.** Paradoxical reaction and immune reconstitution inflammatory syndrome

	Paradoxical reaction (PR) ( <i>n</i> =12)	Immune reconstitution inflammatory syndrome (IRIS, <i>n</i> =12)		Total ( <i>n</i> =24)
		HIV-infected ( <i>n</i> =6)	Others ( <i>n</i> =6)	
		Female sex <i>n</i> / <i>N</i>	9/12	
Age, median (IQR)	36 (31-56)	42 (33-49)	29 (27-47)	36 (28-52)
<b>Tuberculosis features</b>				
<i>Neuromeningeal</i>	11/12	2/6	2/6	15/24 (63%)
<i>Pulmonary</i>	4/12	2/6	4/6	10/24 (42%)
<i>Lymph nodes</i>	2/12	2/6	2/6	6/24 (25%)
<i>Miliary</i>	2/12	2/6	2/6	6/24 (25%)
<b>Others<sup>£</sup></b>	3/12	2/6	1/6	6/24 (25%)
<b>Tuberculosis treatment</b>				
Standard anti-tuberculosis drugs	12/12	5/5*	6/6	23/23*
Early corticosteroids	11/12	2/6	3/6	16/24 (67%)
<b>Characteristics of PR or IRIS</b>				
Single occurrence	9/12	3/6	4/6	16/24 (67%)
Prolonged (> 1 year) or recurrent	3/12	3/6	2/6	8/24 (33%)
Median time of onset, weeks (IQR)				
- after tuberculosis treatment start	4 (4-7) *	6 (6-8)	10 (6-12)	6 (4-9) *
- after antiretroviral treatment start	-	2 (2-2)	-	-
- after TNF- $\alpha$ antagonists stop	-	-	12 (8-12)	-
Onset during corticosteroids tapering	9/12	2/6	2/6	13/24 (54%)
<b>Treatment of PR or IRIS §</b>				
High-dose corticosteroids	12/12	6/6	5/6	23/24 (96%)
Infliximab	8/12	4/6	5/6	17/24 (71%)
Adalimumab	1/12	1/6	1/6	3/24 (13%)
Thalidomide	4/12	2/6	0/6	6/24 (25%)
<b>Outcome</b>				
Initial improvement	12/12	6/6	6/6	24/24
Sequelae	6/11**	0/6	0/6	6/23* (26%)
TNF- $\alpha$ antagonist severe adverse events	2/12	1/6	1/6	4/24 (17%)

\* missing data; £ Others: abdominal (*n*=2), ocular, genital, laryngeal, articular (one patient each); § One patient had infliximab then adalimumab; one had thalidomide then infliximab; \*\* cognitive disorders (*n*=2), paralysis of common oculomotor nerve and paresis of left lower limb (one patient), deafness, hemianopsia, ataxia (one patient each). One patient with missing data because still in early rehabilitation.

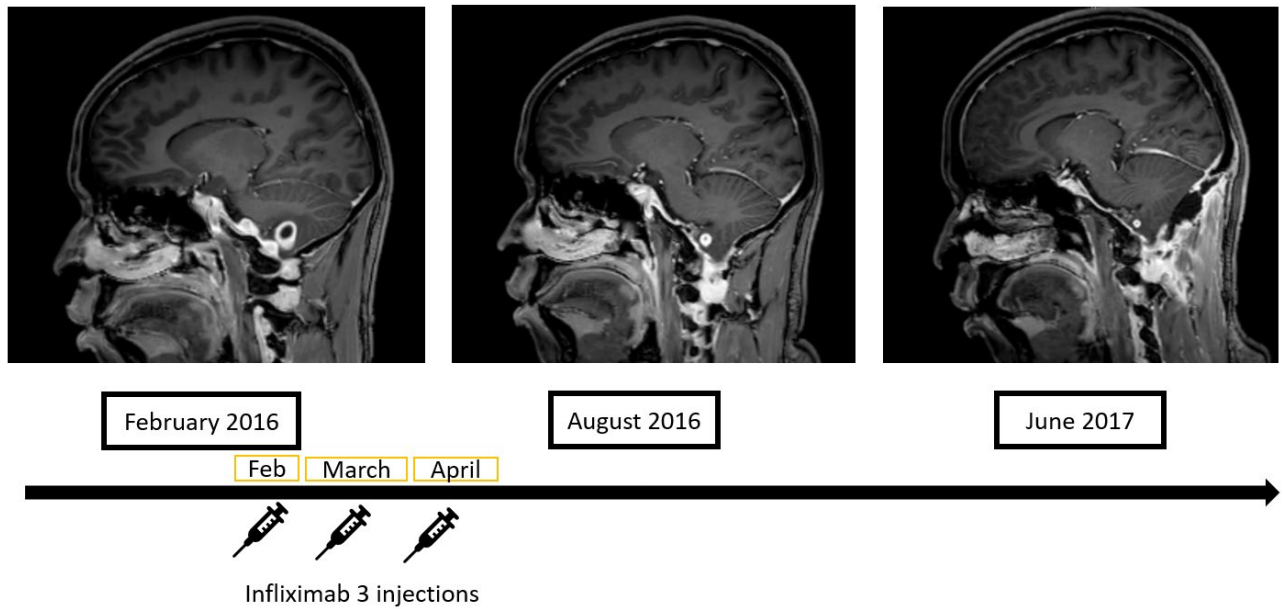


**Figure 1.** Case report #1: Evolution of cerebral and medullar lesions on infliximab. Sagittal and axial gadolinium-enhanced T1-weighted sequences on magnetic resonance imaging.

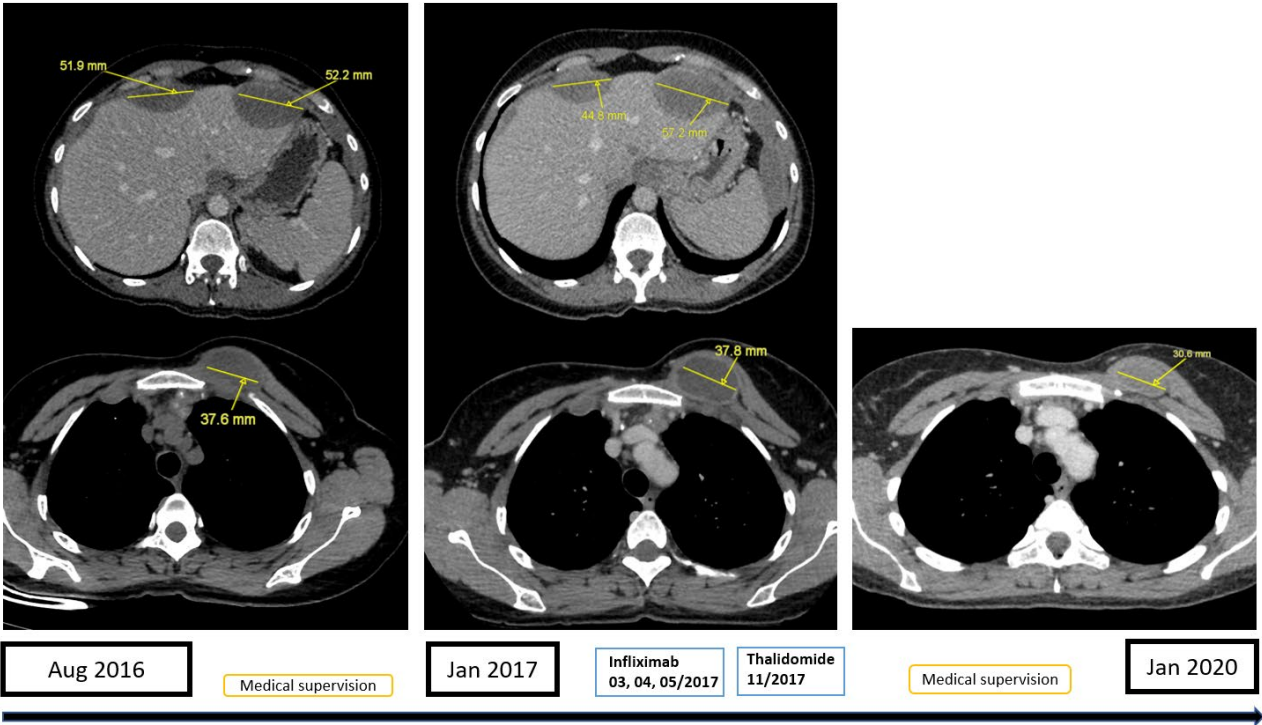


**Figure 2.** Case report #2: Evolution of cerebellar tuberculoma after 3 injections of infliximab.

Sagittal gadolinium-enhanced T1-weighted sequences on magnetic resonance imaging.



**Figure 3.** Case report #3: Chest and abdominal contrast-enhanced, axial CT scan. A five-year follow-up of intra-abdominal and presternal collections.



## *References*

1. Shelburne S a. I, Hamill RJ, Rodriguez-Barradas MC, Greenberg SB, Atmar RL, Musher DM, et al. Immune Reconstitution Inflammatory Syndrome: Emergence of a Unique Syndrome During Highly Active Antiretroviral Therapy. *Medicine (Baltimore)*. 2002;81(3):213-27.
2. European AIDS Clinical Society. EACS. Guidelines for the management of people living with HIV in Europe V.11. 2021. [https://www.eacsociety.org/media/guidelines-11.1\\_final\\_09-10.pdf](https://www.eacsociety.org/media/guidelines-11.1_final_09-10.pdf) *Accessed on December 2022*
3. Consolidated Guidelines on HIV Prevention, Testing, Treatment, Service Delivery and Monitoring: Recommendations for a Public Health Approach. World Health Organization ; 2021. <https://www.who.int/publications/i/item/9789240031593> *Accessed on December 2022*
4. Groupe des experts « Prise en charge médicale des personnes infectées par le VIH » sous l'égide du CNS (Conseil National du Sida), Rapport Morlat ; 2018. [https://cns.sante.fr/wp-content/uploads/2018/05/experts-vih\\_infections.pdf](https://cns.sante.fr/wp-content/uploads/2018/05/experts-vih_infections.pdf) *Accessed on December 2022*
5. Breton G, Bourgarit A, Pavy S, Bonnet D, Martinez V, Duval X, et al. Treatment for tuberculosis-associated immune reconstitution inflammatory syndrome in 34 HIV-infected patients. *Int J Tuberc Lung Dis*. 2012;16(10):1365-70.
6. Meintjes G, Wilkinson RJ, Morroni C, Pepper DJ, Rebe K, Rangaka MX, et al. Randomized placebo-controlled trial of prednisone for paradoxical tuberculosis-associated immune reconstitution inflammatory syndrome. *AIDS*. 2010;24(15):2381-90.
7. Furin J, Cox H, Pai M. Tuberculosis. *Lancet*. 2019;393(10181):1642-56.

8. Hsu DC, Faldetta KF, Pei L, Sheikh V, Utay NS, Roby G, et al. A Paradoxical Treatment for a Paradoxical Condition: Infliximab Use in Three Cases of Mycobacterial IRIS. *Clin Infect Dis.* 2016;62(2):258-61.
9. Zhang Z, Fan W, Yang G, Xu Z, Wang J, Cheng Q, et al. Risk of tuberculosis in patients treated with TNF- $\alpha$  antagonists: a systematic review and meta-analysis of randomised controlled trials. *BMJ Open.* 2017;7(3):e012567.
10. Ravimohan S, Tamuhla N, Nfanyana K, Steenhoff AP, Letlhogile R, Frank I, et al. Robust Reconstitution of Tuberculosis-Specific Polyfunctional CD4<sup>+</sup> T-Cell Responses and Rising Systemic Interleukin 6 in Paradoxical Tuberculosis-Associated Immune Reconstitution Inflammatory Syndrome. *Clin Infect Dis.* 2016;62(6):795-803.
11. Roberts MTM, Mendelson M, Meyer P, Carmichael A, Lever AML. The use of thalidomide in the treatment of intracranial tuberculomas in adults: two case reports. *J Infect.* 2003;47(3):251-5.
12. Blackmore TK, Manning L, Taylor WJ, Wallis RS. Therapeutic Use of Infliximab in Tuberculosis to Control Severe Paradoxical Reaction of the Brain and Lymph Nodes. *Clin Infect Dis.* 2008;47(10):e83-5.
13. Wallis RS, van Vuuren C, Potgieter S. Adalimumab Treatment of Life-Threatening Tuberculosis. *Clin Infect Dis.* 2009;48(10):1429-32.
14. O'Dowd C, Kewin P, Morris J, Cotton M. Tuberculosis complicated by immune reconstitution inflammatory syndrome in a patient on anti-TNF $\alpha$  therapy for Crohn's disease. *BMJ Case Rep.* 2011;2011:bcr0920103376.

15. Jorge JH, Graciela C, Pablo AP, Luis SHJ. A life-threatening central nervous system-tuberculosis inflammatory reaction nonresponsive to corticosteroids and successfully controlled by infliximab in a young patient with a variant of juvenile idiopathic arthritis. *J Clin Rheumatol*. 2012;18(4):189-91.
16. Lee HS, Lee Y, Lee SO, Choi SH, Kim YS, Woo JH, et al. Adalimumab treatment may replace or enhance the activity of steroids in steroid-refractory tuberculous meningitis. *J Infect Chemother*. 2012;18(4):555-7.
17. Vandecasteele SJ, De Vriese AS, Vanhooren GT. Reversion of cerebral artery stenoses due to tuberculomas with TNF- $\alpha$  antibodies. *Clin Neurol Neurosurg*. 2012;114(7):1016-8.
18. Brunel AS, Reynes J, Tuailon E, Rubbo PA, Lortholary O, Montes B, et al. Thalidomide for steroid-dependent immune reconstitution inflammatory syndromes during AIDS. *AIDS*. 2012;26(16):2110-2.
19. de la Riva P, Urtasun M, Castillo-Trivino T, Camino X, Arruti M, Mondragón E, et al. Clinical response to thalidomide in the treatment of intracranial tuberculomas: case report. *Clin Neuropharmacol*. 2013;36(2):70-2.
20. Fourcade C, Mauboussin JM, Lechiche C, Lavigne JP, Sotto A. Thalidomide in the Treatment of Immune Reconstitution Inflammatory Syndrome in HIV Patients with Neurological Tuberculosis. *AIDS*. 2014;28(11):567-9
21. Richaud C, Ghosn J, Amazzough K, Poiree S, Lortholary O. Anti-tumor necrosis factor monoclonal antibody for steroid-dependent TB-IRIS in AIDS. *AIDS*. 2015;29(9):1117-9.
22. Molton J, Huggan P, Archuleta S. Infliximab therapy in two cases of severe neurotuberculosis paradoxical reaction. *Med J Aust*. 2015;202(3):156-7

23. Lwin N, Boyle M, Davis JS. Adalimumab for Corticosteroid and Infliximab-Resistant Immune Reconstitution Inflammatory Syndrome in the Setting of TB/HIV Coinfection. *Open Forum Infect Dis.* 2018;5(2):ofy027.
24. Santin M, Escrich C, Majòs C, Llaberia M, Grijota MD, Grau I. Tumor necrosis factor antagonists for paradoxical inflammatory reactions in the central nervous system tuberculosis. *Medicine (Baltimore).* 2020;99(43):e22626.
25. Eshagh D, Benali K, Dossier A, Chauveheid MP, Rouzaud D, Goulenok T, et al. Infliximab use for corticosteroid-resistant tuberculosis immune reconstitution inflammatory syndrome (TB-IRIS) in an immunocompetent patient. *Infection.* 2020;48(5):799-802.