



HAL
open science

Immune checkpoint inhibitor-associated myocarditis and coronary artery disease: There may be more than meets the eye!

Alexandre T.J. Maria, Clement Delmas, Cyrille Coustal, Pascale Palassin,
François Roubille

► To cite this version:

Alexandre T.J. Maria, Clement Delmas, Cyrille Coustal, Pascale Palassin, François Roubille. Immune checkpoint inhibitor-associated myocarditis and coronary artery disease: There may be more than meets the eye!. *European Journal of Cancer*, 2022, 177, pp.194-196. 10.1016/j.ejca.2022.09.028 . hal-04013666

HAL Id: hal-04013666

<https://hal.science/hal-04013666>

Submitted on 3 Mar 2023

HAL is a multi-disciplinary open access archive for the deposit and dissemination of scientific research documents, whether they are published or not. The documents may come from teaching and research institutions in France or abroad, or from public or private research centers.

L'archive ouverte pluridisciplinaire **HAL**, est destinée au dépôt et à la diffusion de documents scientifiques de niveau recherche, publiés ou non, émanant des établissements d'enseignement et de recherche français ou étrangers, des laboratoires publics ou privés.



Distributed under a Creative Commons Attribution - NonCommercial - NoDerivatives 4.0
International License

Immune checkpoint inhibitor-associated myocarditis and coronary artery disease: There may be more than meets the eye!

Alexandre T.J. Maria¹ ; Clement Delmas² ; Cyrille Coustal³ ; Pascale Palassin⁴ ; François Roubille*⁵

¹ Internal Medicine & Immuno-Oncology (MedI2O), Institute for Regenerative Medicine and Biotherapy (IRMB), Saint Eloi Hospital, Montpellier University Hospital, Montpellier, France
Cardiology Department INI-CRT PhyMedExp INSERM

² CNRS CHU de Montpellier Université de Montpellier France,
France

³ Department of Internal Medicine, Multi-Organic Diseases, Local Referral Center for Rare Auto-immune Diseases, Montpellier University Hospital, Montpellier, France

⁴ Regional Pharmacovigilance Centre, Department of Medical Pharmacology and Toxicology, Montpellier University Hospital, Montpellier, France

⁵ Cardiology Department INI-CRT PhyMedExp INSERM CNRS CHU de Montpellier Université de Montpellier France, France

***Corresponding author:** Intensive Cardiac Care Unit, Cardiology Department, Montpellier, France; PhyMedExp, University of Montpellier, INSERM U1046, CNRS UMR 9214. 34295 Montpellier cedex 5, France.

E-mail address: francois.roubille@gmail.com

KEYWORDS

Myocarditis; Heart failure; Immune checkpoint blocker; Immune-related adverse events; Myocardial biopsy; Coronary angiogram.

The Immune checkpoint blockers (ICB) have greatly improved clinical outcomes in multiple cancer types and are increasingly being used in earlier disease settings alone or in combination with other therapies. However, rare but life-threatening complications defined as immune-related adverse events (irAE) as ICI-induced myocarditis can occur, justifying close monitoring and specific management [1,2].

1. Difficult ICI-myocarditis diagnosis

Patients with cancer are also at increased risk of coronary artery disease (CAD) with both chronic coronary syndromes (angina and/or elevated biomarkers) and acute events (mainly acute coronary syndromes). It is mainly explained by shared risk factors for cardiovascular diseases and cardiovascular toxicity, as they present a cancer-induced pro-inflammatory and prothrombotic state [3]. Consistently, in the recent ESC guidelines [4], ICI are acknowledged to promote both accelerated atherosclerosis and plaque rupture, but also coronary thrombosis.

That is the reason why, when ICI-myocarditis is suspected, alternative diagnoses have to be ruled out first (acute or chronic artery disease leading to acute coronary syndromes, toxic cardiomyopathy, takotsubo cardiomyopathy, pericarditis, etc.) [4]. A rigorous diagnostic workup is mandatory because of the potentially severe consequences of myocarditis under or overdiagnosis (respectively cardiovascular complications including cardiac death, or ICI discontinuation leading to compromised cancer's outcomes). However, the best strategy to manage suspected ICI-myocarditis remains a bone of contention, especially since clinical, biological, and imaging presentation are not specific (14-37% chest pain, 71e76% dyspnea/fatigue, 17-40% arrhythmia, 50-100% troponin elevation, 49-51% decrease in LVEF, and 23-48% cMRI late gadolinium enhancement) [5], leading to specific classification [6] and new definitions [7].

2. High prevalence of associated coronary artery disease

Through the large multicentric retrospective JOint use of database to identify risk factors of CARDIo-vascular Toxicity InducEd by Immune checkpoint Blocker (JOCARDITE) registry [8] (n =474 patients in 57 centers/11 countries), Nowatzke et al. showed that only half of the patients diagnosed with ICI-myocarditis underwent coronary angiography (n= 261/474, 55.1%) while a concomitant coronary artery disease (CAD defined as coronary artery stenosis >70%) was found in about a quarter of them (22.6%; n = 59/261), consistent with our recent pharmacovigilance study where CAD represented one-third of all [9] MACE 9. The absence of difference in clinical, electrocardiographic, and biological presentation between patients with or without CAD highlights the utmost importance of systematic coronarography, especially since a coronary revascularization was required for 32.3% of them (19/59).

3. Need for a definite diagnosis of ICI-myocarditis

In accordance with clinical practice, only three patients out of four in this report [8] have a confirmed ICI-myocarditis diagnosis by cMRI or histology suggesting possible under or overdiagnosis. As previously suggested, systematic cMRI with dedicated tissue characterization techniques (T1, T1 with gadolinium, T2, T1, and T2 mapping) should be practiced in each suspected case based on modified LakeeLouise criteria [10]. Nonetheless, the normality on transthoracic echocardiography and cMRI should not dismiss the diagnosis

of myocarditis, and endomyocardial biopsy (EMB) should be considered, especially in patients with recent exposure to ICI for whom an alternative cardiac diagnosis has not been determined. This may concern patients who exhibit clinical symptoms or have elevated biomarkers, electrocardiographic changes, malignant arrhythmias, or a new reduced left ventricular ejection fraction. However, these patients are complex, with a need for cardiologic and pathologic expertise for EMB, and thus might be referred to dedicated cardio-oncology centers [4]. In this paper, the picture is probably not fully representative of real-life settings, where ICIMACE may be largely under-reported [9].

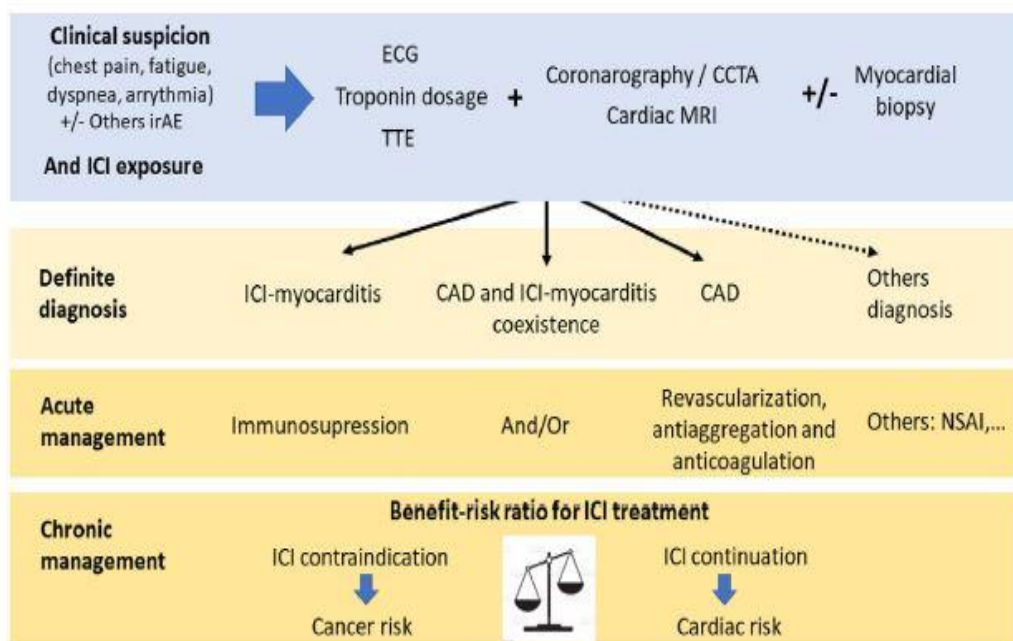


Fig. 1 Suggested algorithm for the diagnosis and management of suspected ICI-myocarditis.

CAD, coronary artery disease; CCTA, coronary computed tomography angiography; ICB, immune checkpoint blockers; irAE, immune-related adverse events; NSAID, nonsteroidal anti-inflammatory drugs; TTE, transthoracic echocardiography.

4. Need to standardize evaluation of ICI-myocarditis suspected cases

The recent ESC guidelines underline that the diagnosis of ACS is based on the same principles as in patients without cancer, but this remains challenging, because of atypical presentation and symptoms masked by cancer or therapy-related side effects [4]. Importantly, an invasive strategy is recommended in the case of NSTEMI (class I, level B) [11]. In that perspective, most patients presented in this study [8] should have undergone coronary angiogram. That was not the case, mainly because myocarditis was first suspected. The risk is to consider only this possibility in clinical practice because there is no high level and pragmatical recommendation that could help clinicians to make a definite ICI-myocarditis diagnosis. Nevertheless, ICI-associated myocarditis diagnosis urges for early steroids and/or immunosuppressants administration and may definitively contraindicate ICI, both affecting the cancer prognosis of these patients [5]. In the other hand, the poorer prognosis found for ICI-myocarditis patients with CAD requiring revascularization highlights the importance to search and detect associated CAD, a situation where steroids may conversely be deleterious.

Older age, male sex, preexisting cardiovascular risk factors, and current cardiometabolic protective drugs seem associated with more coronary revascularization and should reinforce the need for coronarography evaluation. History and physical examination should also evaluate for other irAEs and should more specifically include a thorough musculoskeletal and neurologic examination and dedicated biomarkers (CK, anti-acetylcholine receptor antibodies) with regard to the risk of associated myositis and/or myasthenia gravis (3M syndrome) [12].

5. Conclusion

Evaluation of ICI-associated cardiac injury should aim to confirm the diagnosis of ICI-myocarditis while looking for an associated CAD in order to adapt both the neoplastic and cardiological management of the patient (Fig. 1). Ideally, such patients should benefit from specific cardio-oncologic units of expertise. To adequately address the issues mentioned here, randomized clinical trial remain mandatory to assess first the value of a systematic diagnostic strategy in the face of clinicobiological and electrocardiogram signs of cardiac injury in the context of ICI treatment. Others will have to evaluate the interest of the concomitant management of CAD on the cardiovascular and general prognosis of these patients.

Fundings

None.

Conflict of interest statement

The authors declare that they have no known competing financial interests or personal relationships that could have appeared to influence the work reported in this paper.

References

- [1] Moslehi JJ, Salem JE, Sosman JA, Lebrun-Vignes B, Johnson DB. Increased reporting of fatal immune checkpoint inhibitor-associated myocarditis. *Lancet* 2018;391(10124):933.
- [2] Moslehi JJ, Johnson DB, Sosman JA. Myocarditis with immune checkpoint blockade. *N Engl J Med* 2017;376(3):292.
- [3] Drobni ZD, Alvi RM, Taron J, Zafar A, Murphy SP, Rambarat PK, et al. Association between immune checkpoint inhibitors with cardiovascular events and atherosclerotic plaque. *Circulation* 2020;142(24):2299e311.
- [4] Lyon AR, Lo´pez-Ferna´ndez T, Couch LS, Asteggiano R, Aznar MC, Bergler-Klein J, et al. 2022 ESC guidelines on cardiooncology developed in collaboration with the European hematology association (EHA), the European Society for therapeutic radiology and oncology (ESTRO) and the international cardiooncology Society (IC-OS) -. *Eur Heart J* 2022 Aug 26:e4244.
- [5] Lehmann LH, Cautela J, Palaskas N, Baik AH, Meijers WC, Allenbach Y, et al. Clinical strategy for the diagnosis and treatment of immune checkpoint inhibitor-associated myocarditis: a narrative review. *JAMA Cardiol* 2021;6(11):1329e37.

- [6] Bonaca MP, Olenchock BA, Salem JE, Wiviott SD, Ederhy S, Cohen A, et al. Myocarditis in the setting of cancer therapeutics: proposed case definitions for emerging clinical syndromes in cardio-oncology. *Circulation* 2019;140(2):80e91.
- [7] Herrmann J, Lenihan D, Armenian S, Barac A, Blaes A, Cardinale D, et al. Defining cardiovascular toxicities of cancer therapies: an International Cardio-Oncology Society (IC-OS) consensus statement. *Eur Heart J* 2022;43(4):280e99.
- [8] Nowatzke J, Guedeney P, Palaskas N, Lehmann L, Ederhy S, Zhu H, et al. Coronary artery disease and revascularization associated with immune checkpoint blocker myocarditis: report from an international registry. *Eur J Cancer* 2022; S0959e8049(22):443e9.
- [9] Palassin P, Faillie JL, Coustal C, Quantin X, Topart D, Roubille F, et al. Under-reporting of major cardiac adverse events with immune checkpoint inhibitors in clinical trials: importance of post-marketing pharmacovigilance surveys. *J Clin Oncol*. Accepted for publication Sept 2022.
- [10] Ferreira VM, Schulz-Menger J, Holmvang G, Kramer CM, Carbone I, Sechtem U, et al. Cardiovascular magnetic resonance in nonischemic myocardial inflammation: expert recommendations. *J Am Coll Cardiol* 18 de'c 2018;72(24):3158e76.
- [11] Collet JP, Thiele H, Barbato E, Barthe'le'my O, Bauersachs J, Bhatt DL, et al. 2020 ESC Guidelines for the management of acute coronary syndromes in patients presenting without persistent ST segment elevation. *Eur Heart J* 2021 Apr 7;42(14):1289e367.
- [12] Nguyễn T, Maria ATJ, Ladhari C, Palassin P, Quantin X, Lesage C, et al. Rheumatic disorders associated with immune checkpoint inhibitors: what about myositis? An analysis of the WHO's adverse drug reactions database. *Ann Rheum Dis* 2022; 81(2):e32.