



Outcomes and survival of a modern dual mobility cup and uncemented collared stem in displaced femoral neck fractures at a minimum 5-year follow-up

Maxence Bordes, Anthony Viste, Mathieu Fauvernier, Marcelle Mercier, Philippe Chaudier, Mathieu Severyns, Michel-Henri Fessy

► To cite this version:

Maxence Bordes, Anthony Viste, Mathieu Fauvernier, Marcelle Mercier, Philippe Chaudier, et al.. Outcomes and survival of a modern dual mobility cup and uncemented collared stem in displaced femoral neck fractures at a minimum 5-year follow-up. *Orthopaedics & Traumatology: Surgery & Research*, 2022, 108 (1), pp.103164. 10.1016/j.otsr.2021.103164 . hal-04009327

HAL Id: hal-04009327

<https://hal.science/hal-04009327>

Submitted on 8 Apr 2024

HAL is a multi-disciplinary open access archive for the deposit and dissemination of scientific research documents, whether they are published or not. The documents may come from teaching and research institutions in France or abroad, or from public or private research centers.

L'archive ouverte pluridisciplinaire **HAL**, est destinée au dépôt et à la diffusion de documents scientifiques de niveau recherche, publiés ou non, émanant des établissements d'enseignement et de recherche français ou étrangers, des laboratoires publics ou privés.

Outcomes and survival of a modern dual mobility cup and uncemented collared stem in displaced femoral neck fractures at a minimum 5-year follow-up.

Maxence **Bordes**^a, Anthony **Viste**^{a,b,*}, Mathieu **Fauvernier**^{c,d}, Marcelle **Mercier**^a, Philippe **Chaudier**^a, Mathieu **Severyns**^e, Michel-Henri **Fessy**^{a,b}

a Hospices Civils de Lyon, Hôpital Lyon Sud, Service de Chirurgie Orthopédique et Traumatologique, 165 Chemin du Grand Revoyet, 69495 Pierre Benite Cedex, France

b Univ de Lyon, Université Claude Bernard Lyon 1, Univ Gustave Eiffel, LBMC UMRT_9406, Lyon, France

c Université de Lyon, Université Lyon 1, CNRS; UMR 5558, Laboratoire de Biométrie et Biologie Évolutive, Équipe Biostatistique-Santé, Villeurbanne, France.

d Hospices Civils de Lyon, Pôle Santé Publique, Service de Biostatistique - Bioinformatique, Lyon, France

e Département de Chirurgie Orthopédique, Hôpital Pierre Zobda-Quitman, CHU de Martinique, 97261, Fort-de-France, France.

* **Corresponding author:** Dr Anthony Viste,

Hospices Civils de Lyon, Hôpital Lyon-Sud, Service de Chirurgie Orthopédique et Traumatologique, 165 Chemin du Grand Revoyet, 69495 Pierre Bénite Cedex, France

E-mail: anthony.viste@chu-lyon.fr

Telephone: +33(0)4 78 86 37 38 // Fax: +33(0)478865934

Introduction

The choice of implant type for total hip replacement in the treatment of femoral neck fractures remains debated. Some authors advocate for the systematic use of cemented stems, while others do not use dual mobility first-line. We therefore conducted a retrospective study using a dual mobility cup (DMC) and an uncemented collared stem (UCS) in order to: 1) confirm the low dislocation rate in this indication, 2) assess other surgical complications, in particular periprosthetic fractures, 3) ensure that these benefits are maintained over time, at a minimum follow-up of 5 years and, 4) assess the rate of revision of the implants.

Hypothesis

Our hypothesis was that the dual mobility dislocation rate for the treatment of femoral neck fractures was lower than for bipolar hemiarthroplasties or single mobility hip prostheses.

Patients and Methods

A retrospective study of 244 femoral neck fractures (242 patients) treated with DMC and UCS was conducted, between 2013 and 2014. The mean age was 83 ± 10 years (60-104). The occurrence of dislocation, periprosthetic fracture, infection of the surgical site, loosening, reoperation and revision were investigated. The HOOS Joint Replacement (JR) score was collected. The cumulative incidence with mortality was used as a competing risk.

Results

The mean follow-up was 6 years ± 0.5 (5-7). At the last follow-up, 108 patients (50%) had died. Twenty-three patients (9.5%) were lost to follow-up. One case of symptomatic aseptic loosening of DMC was observed. The cumulative incidence of dislocations and periprosthetic fractures at 5 years were 2% (95% CI: 0.9-5.4) and 3% (95% CI: 1.2-6), respectively. The 5-

year cumulative incidence of surgical site infections was 3.5% (95% CI: 1.8-7). The cumulative incidence of reoperations at 5 years was 7% (95% CI: 4.5-11). The causes of reoperation were periprosthetic fracture (n = 6), infection (n = 8), postoperative hematoma (n = 2) and cup malposition (n = 2). The cumulative incidence of a revision at 5 years was 2.7% (95% CI: 1.2-6). The cumulative incidence of a surgical complication from any cause at 5 years was 9% (95% CI: 6.7-14.8). The mean HOOS JR score was 79 ± 5 (52-92).

Discussion

The cumulative incidence of dislocation at 5 years is low and other surgical complications (including periprosthetic fractures) do not increase during this period for DMC associated with UCS, in femoral neck fractures. The use of this type of implant is reliable in the treatment of femoral neck fractures.

Level of evidence: IV; retrospective study without control group

Keywords: Dual mobility; Uncemented stem; Displaced femoral neck fracture; Total hip arthroplasty; Hip Dislocation; Periprosthetic fracture

1. Introduction

Hip replacement surgery has revolutionized the surgical management of femoral neck fractures. It is the recommended treatment for elderly patients [1]. Regarding the type of implant, the choice between a total hip prosthesis and bipolar hemiarthroplasty remains debated [2-4]. Total hip prostheses are associated with better functional results, a decrease in revision rate, lower health costs, but disadvantages include: dislocations, intraoperative blood loss and longer operating times compared to bipolar hemiarthroplasties [2– 4]. Thus, the total hip replacement is often the preferred option for patients with few comorbidities and a high Parker mobility score.

The benefit of the dual mobility cup (DMC) in reducing the rate of total hip prosthesis dislocations has been demonstrated [5–8]. There are many risk factors for dislocations in the patient population with femoral neck fractures [9]. For this reason, we systematically use DMC for total hip replacement in these patients, although this approach is not systematic [3]. Recently, clinical studies have published low dislocation rates, between 0 and 7% with DMC, in the treatment of femoral neck fractures [10–19]. However, these studies are primarily interested in the rate of short-term dislocations, and none of them look for all mid- and long-term surgical complications. In addition, some authors report an increased risk of periprosthetic fractures with DMC [20]. Likewise, the use of uncemented stems increases the risk of periprosthetic fractures [14]. We therefore conducted a retrospective study of femoral neck fractures, treated with DMC and uncemented collared stems (UCS), to meet the following objectives:

1. Confirm the low rate of dislocation in femoral neck fractures.
2. Evaluate other surgical complications, particularly periprosthetic fractures.

3. Ensure that these benefits are maintained over time, with a minimum follow-up of 5 years.
4. Report the revision rate of implants.

Our hypothesis was that the rate of dislocation of DMC with UCS for the treatment of femoral neck fractures was lower than for bipolar hemiarthroplasties or single-mobility hip prostheses, without increasing other surgical complications (notably periprosthetic fractures) and the revision rate.

2. Patients and methods

2.1 Patients

This retrospective, monocentric and non-comparative study was conducted on patients who underwent hip replacement surgery for femoral neck fractures between January 2013 and December 2014. We identified 300 hip replacements with neck fractures in the registry of our service, during this period. We performed primary total hip arthroplasty with DMC and UCS for femoral neck fractures except amongst patients with a Parker mobility score below 6, for whom a bipolar hemiarthroplasty is preferred.

All patients undergoing total hip arthroplasty for a femoral neck fracture were included. The exclusion criteria were: bipolar hemiarthroplasty, conventional cup, retentive cup, acetabular reinforcement and hip arthroplasty after failure of internal fixation (Figure 1).

We included 242 patients (177 women, 65 men) or 244 total hip arthroplasties with DMC and UCS for femoral neck fractures. At the time of surgery, the mean age and mean Body Mass Index (BMI) were $83 \text{ years} \pm 10$ (60-104) and $22 \text{ kg/m}^2 \pm 4$ (15-40), respectively. The mean American Society of Anesthesiologists (ASA) score was 2.4 ± 0.6 (1-4) with an ASA of 1 in 11 patients (4%), ASA 2 in 138 (57%), ASA 3 in 88 (36%) and ASA 4 in 5 (2%). The mean

preoperative Parker mobility score was 7.4 ± 1.4 (6-9) with Parker 6 in 94 patients (39%), Parker 7 in 27 (11%), and Parker 8 and 9 in 121 (50%). Dementia and neurological comorbidities (Parkinson's syndrome, neurological deficit of central or peripheral origin) were found in 58 patients (24%) and 27 patients (11%), respectively. Four patients (1.7%) had undergone spine surgery, and six patients (2.5%) suffered from chronic alcoholism. A total of 126 (52%) patients had at least one of the following criteria: ASA score greater than or equal to 3, dementia, neurological history and history of spinal surgery. The mean time from hospital admission to surgery was 2 ± 4 days (0-21).

2.2 Surgery

The same standardized surgical technique was used for all patients (Figure 2). Preoperative planning was systematically carried out. A posterolateral approach was performed for all total hip replacements. Stability was assessed with trial implants. The calcar was prepared with a suitable reamer on the test stem to prevent the risk of fracture and to perfectly fit the collar. In this series, modern DMC were represented by three types of uncemented DMC with new generation polyethylene: 204 (93%) Sunfit TH™ (Serf, Décines, France), 12 (5.4%) Stafit™ (Zimmer) and 3 (1.3%) Novae-E™ (Serf, Décines, France). All these cups have primary fixation by impaction. The Novae-E cup includes a screw and two additional studs. An uncemented stem with a CORAIL™ collar (Depuy, Warsaw, IN) was implanted in all patients. No cemented stems were used.

Cobalt chrome heads (Articul-eze, DePuy) of 22.225mm diameter were used for 43mm diameter cups and 28mm heads were used for a diameter of 45mm or more. The piriformis tendon and joint capsule were reinserted at the end of the operation. A drain was systematically used. No immobilization was put in place postoperatively. Second-generation cephalosporin antibiotic prophylaxis was performed in accordance with the recommendations

of the French Anesthesiology Society. Prophylaxis of phlebitis was carried out with low molecular weight heparin or calciparine for a period of 45 days postoperatively. Full resumption of weight-bearing was authorized immediately after surgery except in the event of intraoperative complications. Daily rehabilitation was started from the first postoperative day until the patient was discharged.

2.3 Data collection

Follow-up in consultation by the surgeon was organized at 2 months, 1 year and 5 years. The following parameters were collected: dislocation, periprosthetic fracture, surgical site infection, symptomatic aseptic loosening, reoperation, and revision of an implant. Reoperation is new surgery regardless of the cause. A revision of an implant is the change of the implant. The functional Hip Disability and Osteoarthritis Outcome Score Joint Replacement (HOOS JR) score was collected. Ethics committee approval was not required as this was a retrospective study of data collected during the patient's usual follow-up. When the patient had not presented for the 5-year consultation (death or other reason), information was collected in the computerized medical file of our institution. The patient was considered lost to follow-up if they did not show up for the 5-year consultation and the information could not be collected from their medical file.

2.4 Statistical analysis

The cumulative incidence at 5 years was used to describe the occurrence of a complication. We used a competing risk model, using mortality as a competing risk because the risk of death at 5 years was high in this population. The cumulative incidence at 5 years of follow-up, with death as a competing risk, was calculated for the following 6 events: dislocation, periprosthetic fracture, infection of the surgical site, reoperation, revision and all-cause

complication. R package mstate software was used for the analysis [21]. These data were presented with a 95% confidence interval (95% CI).

3. Results

The mean follow-up was 6 years \pm 0.5 (5-7). At the last follow-up, 108 patients (50%) had died and 23 patients (9.5%) were lost to follow-up. The 1-year mortality rate was 15% (n = 37). The mean HOOS JR score was 79 \pm 13.5 (52-92) at the last follow-up, and it was calculated for 66 of the 111 living patients remaining at the last follow-up.

3.1 Complications

Postoperative complications and their management are summarized in Table 1. Only 1 intraoperative complication was found: a functionally treated fracture of the greater trochanter which did not require reoperation.

Five dislocations (2%) occurred during follow-up: an early dislocation during the first postoperative month, a late dislocation at 10 months postoperatively (Figure 3), and 3 dislocations occurred between 1 to 2 months. Four dislocations were spontaneous and 1 was post-traumatic. Concerning the 4 spontaneous dislocations, 1 patient had a neurological history (Parkinson's) and 1 patient had a malposition of the cup in retroversion (radiographic measurement). All dislocations were reduced under general anesthesia and none of them had further surgery. Only 1 patient had recurrent dislocations and died before reoperation. There were no intra-prosthetic dislocations.

Seven post-traumatic periprosthetic fractures (3.1%) occurred postoperatively. One fracture occurred early at 5 months, 5 fractures in the third year, 1 fracture in the fourth year, and 1 fracture at 6 years. Two fractures were localized to the acetabulum and 5 fractures were localized to the femur. A roof fracture, without implant displacement, was found at the

acetabular slope, and a transverse fracture, with cup protrusion, was identified. According to the Vancouver classification [22], we noted one type A fracture in the femur, two type B2 fractures, one type B3 fracture and one type C fracture. The median time to onset of a periprosthetic fracture was 4 years \pm 1.3 (0.2 to 6).

Eight surgical site infections (3.6%) were reported. The median time to onset of surgical site infection was 9.5 weeks \pm 25.7 (1-73). All patients were treated by reoperation with lavage, implant retention and targeted antibiotic therapy. There was no recurrence of infections with this management. There were no revisions for surgical site infections.

Symptomatic aseptic loosening of DMC (Sunfit TH™) was reported at 31 months. The patient died prior to cup revision.

The causes of reoperation were as follows: periprosthetic fracture (n = 6), infection of the surgical site (n = 8), postoperative hematoma (n = 2) and iliopsoas impingement due to cup malposition (n = 2) (anteversion $<10^\circ$). The median time to reoperation was 1 month (0-76).

The main cause of femoral stem revision was periprosthetic fracture (n = 4). The two causes of cup revision were periprosthetic fracture (n = 1) and iliopsoas impingement due to cup malposition (n = 2). The median time to revision was 40 months (5-76).

3.2 Cumulative incidence with death as a competing risk (Figure 4)

The cumulative incidence of dislocation at 5 years was 2% (95% CI: 0.9-5.4) (Figure 4a). The cumulative incidence of periprosthetic fracture at 5 years was 3% (95% CI: 1.2-6) (Figure 4b). The cumulative incidence of a revision at 5 years was 3% (95% CI: 1.2-6) (Figure 4c). The cumulative incidence of surgical site infection at 5 years was 4% (95% CI: 1.8-7) (Figure 4d). The cumulative incidence of reoperation at 5 years was 7% (95% CI: 4.5-11) (Figure 4e).

The cumulative incidence of surgical complications from any cause at 5 years was 9% (95% CI: 6.7-14.8) (Figure 4f).

4. Discussion

In this retrospective study of a cohort of femoral neck fractures treated with DMC and UCS; 1) the cumulative incidence of dislocation at 5 years was low, 2) the cumulative incidence of other surgical complications remained low at 5 years of follow-up. Finally, 3) the cumulative impact of the revision was 3%.

We selected studies of more than 50 patients to compare our results [10–18] (Table 2). Clinical studies of DMC in femoral neck fractures have low minimum follow-up times (between 0 and 19 months), and most of them focus on dislocation, without considering other surgical complications or revision rates. To our knowledge, our study has the longest minimum follow-up period, reporting surgical complications and DMC revision rates, in femoral neck fractures.

Our study identified a cumulative incidence of 2% for dislocation, at 5 years of follow-up. In the literature, some series concerning DMC in femoral neck fractures report a low incidence of dislocation (0-2%) [10-14] and for others, a higher incidence (3-7%) [15–18]. Meta-analyzes and randomized control studies concerning conventional implants used in femoral neck fractures [2,3] report a risk between 2% to 4% for bipolar hemiarthroplasties and between 4% to 8% for total hip prostheses. Our results are comparable to the low incidence of dislocation found in some series concerning DMC, and support the fact that DMC has a lower incidence of dislocations than conventional implants.

The difference in the DMC dislocation rate amongst the different series in the literature can be explained by selection bias. In the non-selective cohorts [14–18], all femoral neck fractures

are treated with DMC during the inclusion period. In selective cohorts, or those with strict exclusion criteria [10–14], the low incidence of dislocations can be explained by patient selection: elderly patients with cognitive comorbidities or walking difficulties tend to undergo bipolar hemiarthroplasties. Consequently, the mean age of patients is higher in series reporting higher dislocation rates. Age is known to be a risk factor for dislocation due to cognitive decline and muscle weakness [9]. In our study, 20 patients had a bipolar hemiarthroplasty during the inclusion period. Our study involves a selective cohort, thus introducing selection bias. However, in comparison with the other selective cohorts, the number of patients treated with a bipolar hemiarthroplasty is low, resulting in a high average age of the patients in our cohort, comparable to the non-selective cohorts.

Many patient-related and surgical-related factors are associated with an increased risk of dislocation [9]; high ASA score, neurological history, history of spinal pathology, non-repair of the joint capsule and tilting of the cup out of the socket beyond the Lewinnek safe zone. Of our patients, 52% had at least one of these risk factors for dislocation. Multivariate analysis was not performed since the incidence of dislocation was very low.

Some studies suggest that DMC increase hip stability at the cost of a risk of periprosthetic fractures, by transfer of forces to the femur [20,23]. In addition, female sex and older age are risk factors for periprosthetic fractures [20], over-represented in the femoral neck fracture population. However, Jobory et al. [19] did not confirm these findings for femoral neck fractures in the Nordic registry: the revision rate for periprosthetic fractures was comparable for conventional implants and DMC. In the literature, the incidence of periprosthetic fractures varies between 0 and 3.5% with DMC [10–18]. With conventional implants, the rate of periprosthetic fractures at 24 months of follow-up was 4.8% for bipolar hemiarthroplasties and 5.3% for total hip prostheses in the randomized HEALTH study [3]. We found a low incidence of periprosthetic fractures in our study with DMC; 2.7%, although our follow-up

was longer. In addition, we used an uncemented stem. Tabori-Jensen et al. [20] associated 76.7% of their DMC with a cemented stem and reported a higher risk of femoral complications with uncemented stems. The use of an uncemented stem would result in more periprosthetic fractures than a cemented stem in femoral neck fractures [14,24]. Our uncemented stem had a collar. The collar offers good primary stability (we did not use the cemented stem due to a lack of primary fixation) but its role in preventing femoral complications remains controversial. Demey et al. [24] showed that fractures occurred at higher stresses for UCS compared to uncemented stems without a collar, in an experimental study. Another in vitro study found no influence of the collar on migration or micromovements of the femoral stem [25]. Recently, the National Joint Registries in the United Kingdom revealed that UCS reduced the revision rate by 8% compared to cemented stems, and by 28% compared to uncemented stems without a collar [26]. The benefit of the collar (as used in this study) should be considered in reducing the incidence of periprosthetic fractures of uncemented stems in femoral neck fractures.

In our study, the main cause of reoperations was infection of the surgical site. The cumulative incidence of surgical site infections was 4%, at 5 years. This result is comparable with the incidence of surgical site infections in the literature, which is between 0 and 4% [10–18]. In the HEALTH study, the incidence of surgical site infection was 3% for bipolar hemiarthroplasties, and 4% for total hip prostheses [3].

In the past, DMC have been associated with an increased risk of aseptic loosening [5]. However, modern DMC are associated with a risk of loosening comparable to conventional cups, over the long term [27–30]. In femoral neck fractures, Jobory et al. [19] observed a lower risk of aseptic loosening with DMC compared to conventional implants in the Nordic registry. We observed only aseptic loosening in our DMC cohort. In the literature, few studies have focused on aseptic loosening, but this event seems to have a very low incidence;

between 0 and 0.8% [11,17,18]. Likewise, the rate of loosening was very low in the HEALTH study with conventional implants (0.7%) [3]. Aseptic loosening in femoral neck fractures does not appear to be a common complication. Patients with femoral neck fractures have low functional demands and a short life expectancy, explaining these results.

The cumulative incidence of revision was 3% at 5 years, in our study. In a recent review of the literature, Jonker et al. [31] showed that DMC prevented dislocation without increasing the revision rate in hip prostheses. Very few studies of DMC in femoral neck fractures analyze revision rates. Bensen et al. [16] and Tabori-Jensen et al. [17] reported an incidence of 5% and 1.4%, respectively, for the revision of hip arthroplasties with DMC. Jobory et al. [19] reported a revision rate of 4% for DMC compared to 5.4% for conventional cups. Regarding the etiology of the revisions, the first cause is periprosthetic fracture (n = 4) and the second is cup malposition (n = 2). The impingement of the psoas with the metallic part of the cup has previously been described [32], and the impingement with the polyethylene insert of the DMC has recently been reported [33]. We did identify any revisions for dislocation, aseptic loosening, or infection of the operative site. For Jobory et al. [19], surgical site infection was the primary cause of revision hip replacements with DMC, followed by periprosthetic fractures.

The functional results were evaluated by the HOOS JR score [33]. Our population was elderly, and only 66 patients could be evaluated functionally at 5 years because of the decrease in cognitive function and the high mortality rate. The Hospital for Special Surgery (HSS) score has been reported in the literature for DMC in femoral neck fractures, and was between 71 and 94.1, depending on the series [10,11,13,14,17,18].

This study has several limitations; 1) its retrospective and non-comparative nature limits its level of proof. In addition, 50% of patients were deceased by the last follow-up. However, our

1-year mortality rate is comparable with that of other studies treating femoral neck fractures [10–18] but the high mortality of this population makes it difficult to assess medium and long-term results. In order to take into account death, which is a competing risk for the occurrence of a surgical complication, we used a competing risk regression model to reduce evaluation bias [35]. 2) Twenty patients were treated with a bipolar hemiarthroplasty, giving a selective character to our cohort, but also still offering demographic characteristics close to the non-selective cohorts. 3) Finally, the absence of an X-ray available at the last follow-up does not make it possible to highlight any asymptomatic complications, although these are rarely the cause of surgical revisions in this elderly population.

5. Conclusion

The cumulative incidence of surgical complications at 5 years is particularly low with DMC for femoral neck fractures. Other surgical complications do not increase during this time and the incidence of periprosthetic fractures remains low. The combination of DMC and UCS appears to offer a reliable surgical technique for the treatment of femoral neck fractures.

Conflict of interest: MHF receives royalties from DePuy and Serf. AV is a consultant for Serf and Smith & Nephew. Dr Chaudier received convention support from Adler and Leo Pharma, Dr Mercier received convention support from Johnson & Johnson and Smith & Nephew.

Funding: No funding was collected for this study.

Contribution of the authors: M.B: acquisition of data; drafting the article. A.V: conception and design of the study; acquisition of data; drafting the article and revising it critically for important intellectual content; final approval of the version for submission. M.F: statistics.

M.M: conception and design of the study; acquisition of data. P.C: performing surgery; acquisition of data. M.S: drafting the article; critically revising the article for important intellectual content. M.F: conception and design of the study; critically revising the article for important intellectual content; final approval of the version for submission.

REFERENCES

- [1] American Academy of Orthopedic Surgeons (2019) Management of hip fractures in the elderly: Evidence-based clinical guidelines. Available from: <https://www.aaos.org/quality/quality-programs/lower-extremity-programs/hip-fractures-in-the-elderly>. Accessed January 20, 2021
- [2] Lewis DP, Wæver D, Thorninger R, Donnelly WJ. Hemiarthroplasty vs total hip arthroplasty for the management of displaced neck of femur fractures: A systematic review and meta-analysis. *J Arthroplasty* 2019;34:1837-1843.e2.
- [3] HEALTH Investigators, Bhandari M, Einhorn TA, Guyatt G, Schemitsch EH, Zura RD, et al. Total hip arthroplasty or hemiarthroplasty for hip fracture. *N Engl J Med* 2019;381:2199–208.
- [4] Ravi B, Pincus D, Khan H, Wasserstein D, Jenkinson R, Kreder HJ. Comparing Complications and Costs of Total Hip Arthroplasty and Hemiarthroplasty for Femoral Neck Fractures: A Propensity Score-Matched, Population-Based Study. *J Bone Joint Surg Am* 2019;101:572–9.
- [5] Philippot R, Farizon F, Camilleri J-P, Boyer B, Derhi G, Bonnan J, et al. Survival of cementless dual mobility socket with a mean 17 years follow-up. *Rev Chir Orthop* 2008;94:e23-27.
- [6] Romagnoli M, Grassi A, Costa GG, Lazaro LE, Lo Presti M, Zaffagnini S. The efficacy of dual-mobility cup in preventing dislocation after total hip arthroplasty: a systematic review and meta-analysis of comparative studies. *Int Orthop* 2019;43:1071–82.
- [7] Vermersch T, Viste A, Desmarchelier R, Fessy M-H. Prospective longitudinal study of one hundred patients with total hip arthroplasty using a second-generation cementless dual-mobility cup. *Int Orthop* 2015;39:2097–101.
- [8] Philippot R, Adam P, Reckhaus M, Delangle F, Verdot F-, Curvale G, Farizon F. Prevention of dislocation in total hip reoperation using a dual mobility design. *Orthop Traumatol Surg Res* 2009;95:407-13.
- [9] Fessy MH, Putman S, Viste A, Isida R, RaDMCne N, Ferreira A, et al. What are the risk factors for dislocation in primary total hip arthroplasty? A multicenter case-control study of 128 unstable and 438 stable hips. *Orthop Traumatol Surg Res* 2017;103:663–8.

- [10] Assi CC, Barakat HB, Caton JH, Najjar EN, Samaha CT, Yammine KF. Mortality Rate and Mid-Term Outcomes of Total Hip Arthroplasty Using Dual Mobility Cups for the Treatment of Femoral Neck Fractures in a Middle Eastern Population. *J Arthroplasty* 2019;34:333–7.
- [11] Tabori-Jensen S, Hansen TB, Bøvling S, Aalund P, Homilius M, Stilling M. Good function and high patient satisfaction at mean 2.8 years after dual mobility THA following femoral neck fracture: a cross-sectional study of 124 patients. *Clin Interv Aging* 2018;13:615–21.
- [12] Adam P, Philippe R, Ehlinger M, Roche O, Bonnomet F, Molé D, et al. Dual mobility cups hip arthroplasty as a treatment for displaced fracture of the femoral neck in the elderly. A prospective, systematic, multicenter study with specific focus on postoperative dislocation. *Orthop Traumatol Surg Res* 2012;98:296–300.
- [13] Hwang JH, Kim SM, Oh K-J, Kim Y. Dislocations after use of dual-mobility cups in cementless primary total hip arthroplasty: prospective multicentre series. *Int Orthop* 2018;42:761–7.
- [14] Kim YT, Yoo JH, Kim MK, Kim S, Hwang J. Dual mobility hip arthroplasty provides better outcomes compared to hemiarthroplasty for displaced femoral neck fractures: a retrospective comparative clinical study. *Int Orthop* 2018;42:1241–6.
- [15] Boukebous B, Boutroux P, Zahi R, Azmy C, Guillon P. Comparison of dual mobility total hip arthroplasty and bipolar arthroplasty for femoral neck fractures: A retrospective case-control study of 199 hips. *Orthop Traumatol Surg Res* 2018;104:369–75.
- [16] Bensen AS, Jakobsen T, Krarup N. Dual mobility cup reduces dislocation and re-operation when used to treat displaced femoral neck fractures. *Int Orthop* 2014;38:1241–5.
- [17] Tabori-Jensen S, Hansen TB, Stilling M. Low dislocation rate of Saturne®/Avantage® dual-mobility THA after displaced femoral neck fracture: a cohort study of 966 hips with a minimum 1.6-year follow-up. *Arch Orthop Trauma Surg* 2019;139:605–12.

- [18] Nich C, Vandenbussche E, Augereau B, Sadaka J. Do Dual-Mobility Cups Reduce the Risk of Dislocation in Total Hip Arthroplasty for Fractured Neck of Femur in Patients Aged Older Than 75 Years? *J Arthroplasty* 2016;31:1256–60.
- [19] Jobory A, Kärrholm J, Overgaard S, Becic Pedersen A, Hallan G, Gjertsen J-E, et al. Reduced Revision Risk for Dual-Mobility Cup in Total Hip Replacement Due to Hip Fracture: A Matched-Pair Analysis of 9,040 Cases from the Nordic Arthroplasty Register Association (NARA). *J Bone Joint Surg Am* 2019;101:1278.
- [20] Sappey-Marinier E, Viste A, Blangero Y, Desmarchelier R, Fessy M-H. A comparative study about the incidence of dislocation and peri-prosthetic fracture between dual mobility versus standard cups after primary total hip arthroplasty. *Int Orthop* 2019;43:2691–5..
- [21] de Wreede LC, Fiocco M, Putter H. The mstate package for estimation and prediction in non- and semi-parametric multi-state and competing risks models. *Computer Methods and Programs in Biomedicine* 2010;99:261–74.
- [22] Duncan CP, Masri BA. Fractures of the femur after hip replacement. *Instr Course Lect* 1995;44:293-304.
- [23] Ehlinger M, Delaunay C, Karoubli M, Bonnomet F, RaDMCne N, Hamadouche M, Société Française de Chirurgie Orthopédique et Traumatologique (SOFECOT). Revision of primary total hip arthroplasty for peri-prosthetic fracture: A prospective epidemiological study of 249 consecutive cases in France. *Orthop Traumatol Surg Res* 2014;100:657-62.
- [24] Kannan A, Kancherla R, McMahon S, Hawdon G, Soral A, Malhotra R. Arthroplasty options in femoral-neck fracture: answers from the national registries. *Int Orthop* 2012;36:1–8.
- [25] Demey G, Fary C, Lustig S, Neyret P, si Selmi TA. Does a collar improve the immediate stability of uncemented femoral hip stems in total hip arthroplasty? A bilateral comparative cadaver study. *J Arthroplasty* 2011;26:1549–55.
- [26] Camine V, Rüdiger HA, Pioletti DP, Terrier A. Effect of a collar on subsidence and local micromotion of cementless femoral stems: in vitro comparative study based on micro-computerised tomography. *Int Orthop* 2018;42:49-57.

- [27] National Joint Registry for England, Wales, Northern Ireland and the Isle of Man, 16th Annual Report 2019 Table 3.3. Available from: <https://reports.njrcentre.org.uk/annual-progress>. Accessed January 20, 2021
- [28] Fessy M-H, Jacquot L, Rollier J-C, Chouteau J, Ait-Si-Selmi T, Bothorel H, et al. Midterm Clinical and Radiographic Outcomes of a Contemporary Monoblock Dual-Mobility Cup in Uncemented Total Hip Arthroplasty. *J Arthroplasty* 2019;34:2983–91.
- [29] Ferreira A, Prudhon J-L, Verdier R, Puch J-M, Descamps L, Dehri G, et al. Contemporary dual-mobility cup regional and private register: methodology and results. *Int Orthop* 2017;41:439–45.
- [30] Gaillard R, Kenney R, Delalande J-L, Batailler C, Lustig S. Ten- to 16-Year Results of a Modern Cementless Dual-Mobility Acetabular Implant in Primary Total Hip Arthroplasty. *J Arthroplasty* 2019;34:2704–10.
- [31] Jonker RC, van Beers LWAH, van der Wal BCH, Vogely HC, Parratte S, Castelein RM, Poolman RW. Can dual mobility cups prevent dislocation without increasing revision rates in primary total hip arthroplasty? A systematic review. *Orthop Traumatol Surg Res*. 2020;106:509-517.
- [32] Batailler C, Bonin N, Wettstein M, Nogier A, Martres S, Ollier E and al. Outcomes of cup revision for ilio-psoas impingement after total hip arthroplasty: Retrospective study of 46 patients. *Orthop Traumatol Surg Res* 2017;103:1147–53.
- [33] Fessy MH, Riglet L, Gras L-L, Neyra H, Pialat J-B, Viste A. Ilio-psoas impingement with a dual-mobility liner: an original case report and review of literature. *SICOT J* 2020;6:27.
- [34] Hung M, Saltzman CL, Greene T, Voss MW, Bounsanga J, Gu Y, et al. Evaluating instrument responsiveness in joint function: The HOOS JR, the KOOS JR, and the PROMIS PF CAT. *J Orthop Res* 2018;36:1178–84.
- [35] Biau DJ, Latouche A, Porcher R. Competing events influence estimated survival probability: when is Kaplan-Meier analysis appropriate? *Clin Orthop Relat Res* 2007;462:229–33.

Table 1. Postoperative complications of the series

Complications	Number (%)	Management
Dislocations	5 (2.2%)	Reduction by external maneuvers (n = 5)
Infection	8 (3.1%)	Lavage (n = 8) with change of moving parts
Asceptic loosening	1 (0.4%)	Death prior to revision
Periprosthetic fracture	7 (3.1%)	Orthopedic (n=1) Internal fixation (n=1) Revision (n=5)
Acetabulum	2	
Femur ^a :		
A	1	
B2	2	
B3	1	Reoperation (n=2)
C	1	
Post-operative hematoma	2	Revision (n=2)
Impingement of the psoas with the cup	2	
Total complications	25 (11.3%)	Reoperation (n = 18) Revision with cup or pivot change (n = 7)

^a Vancouver Classification [22].

Table 2. Literature review: series including more than 50 patients and using a double mobility cup in femoral neck fractures (Study group 1 = studies with low incidence of dislocation (0-2%); Study group 2 = studies with higher incidence of dislocation (3-7%))

G r o u p	Authors	N=	Age	f	M	Dis (%)	PPF (%)	SSI (%)	Cup (%)	Reop (%)	Revision (%)
1	Assi et al. [10]	174	78	2	1.7	0	0	0	0	NA	NA
	Tabori-Jensen et al. [11]	124	74	12	NA	0.8	0.8	0.8	0.8	3.2	NA
	Adam et al. [12]	214	83	9	19	1.4	0.5	2.4	0	3.7	NA
	Hwang et al. [13]	167	72	6	NA	2.3	1.8	0	0	NA	NA
	Kim et al. [14]	84	73	12	8	2.4	NA	NA	NA	NA	NA
2	Boukebous et al. [15]	98	80	0	12	3	3	4	NA	7.7	NA
	Bensen et al. [16]	174	75	0.3	17	4.6	3.4	2.2	NA	9	5.1
	Tabori-Jensen et al. [17]	966	80	19	22	5.5	3.5	1	0.8	5.8	1.4
	Nich et al. [18]	82	87	12	19	6.7	0	2.4	0	6	NA
<i>This study</i>		<i>244</i>	<i>82</i>	<i>60</i>	<i>15</i>	<i>2.3</i>	<i>2.7</i>	<i>3.6</i>	<i>0.4</i>	<i>7.2</i>	<i>2.7</i>

Age = average age; f: Minimum follow-up (in months); M: mortality at 1 year; Dis: dislocation; Cup: loosening of the cup; Reop: reoperation; PPF = periprosthetic fracture, SSI = surgical site infection, NA = not available

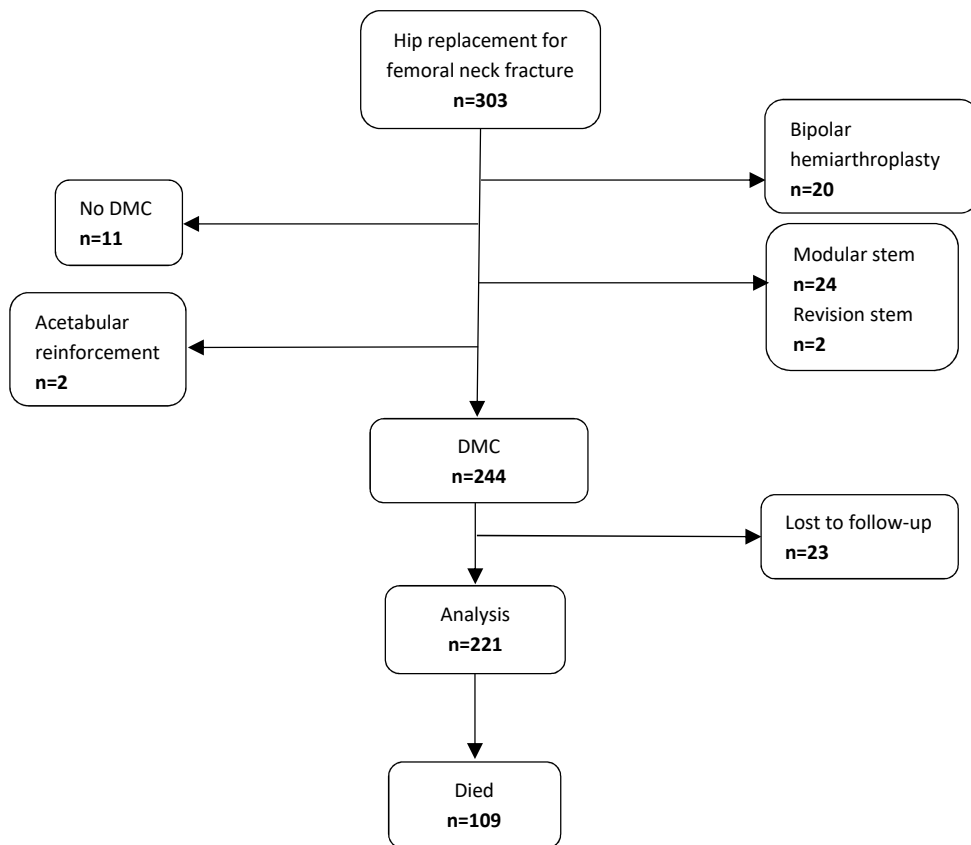
LEGENDS OF THE FIGURES

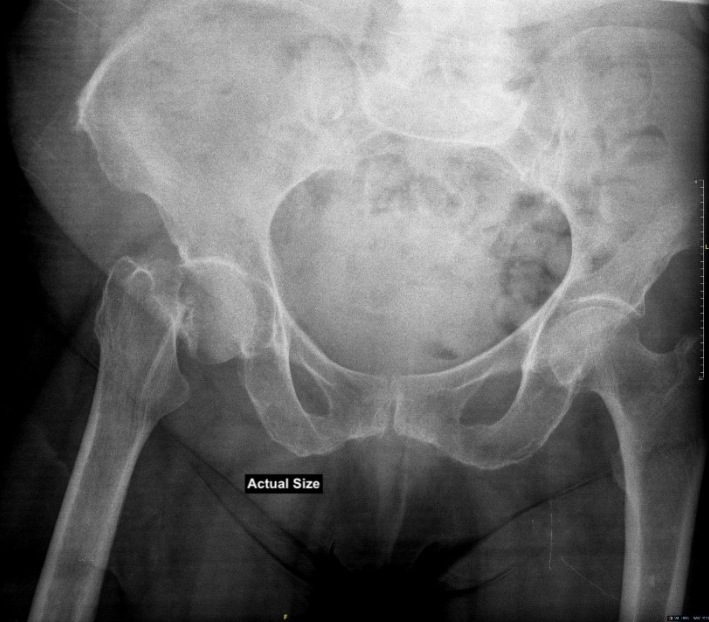Figure 1: Flowchart (DMC = Dual mobility cup).

Figure 2: a) Preoperative and b) Postoperative X-rays showing a femoral neck fracture treated with a total hip prosthesis with a dual mobility cup and cementless femoral stem with collar.

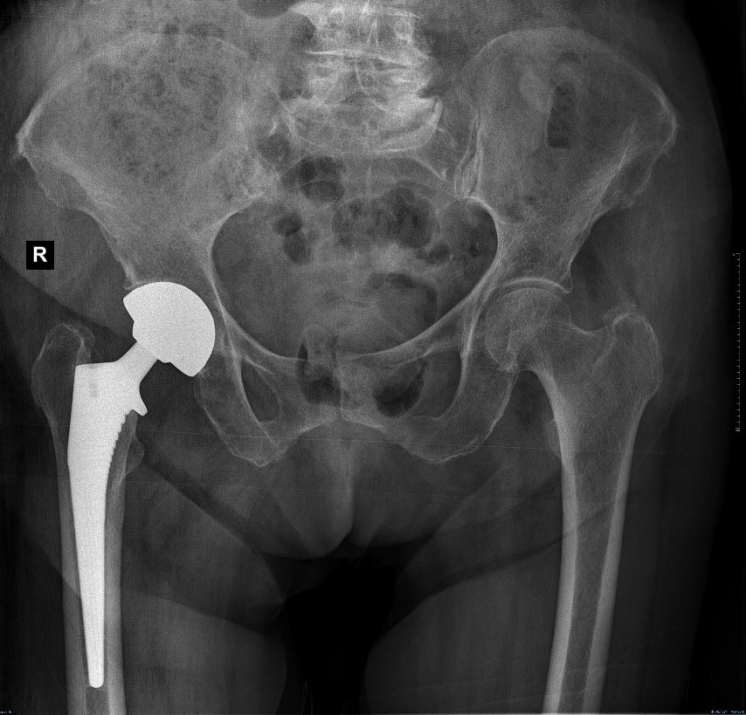
Figure 3: Case of a dislocation of a total hip prosthesis with a dual mobility cup, occurring two months after surgery, and secondary to trauma, caused by the patient falling from his height. A reduction by an external maneuver under general anesthesia was performed.

Figure 4. Graphs showing the cumulative incidences at 5 years of follow-up with death as a competing risk, presented with a 95% confidence interval, for the following events: 4a: dislocation; 4b: periprosthetic fracture; 4c: infection: prosthetic joint infection; 4d: revision; 4e: reoperation; 4f: surgical complication of any cause.

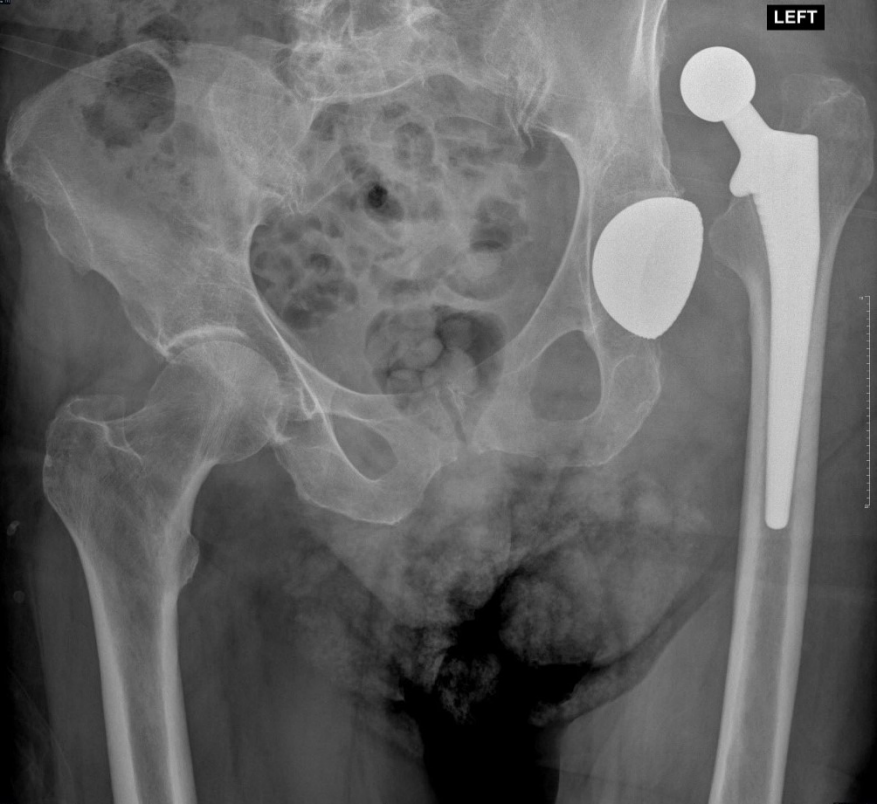



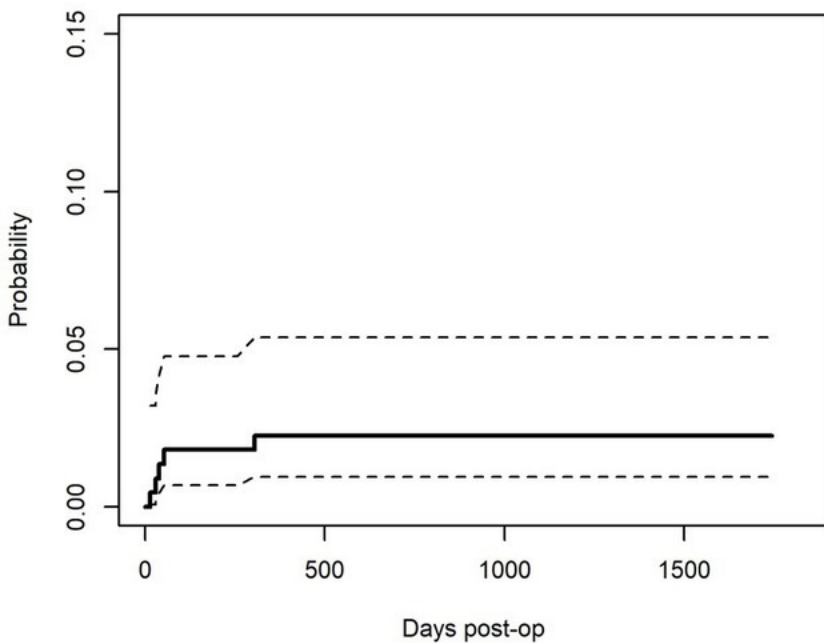
R



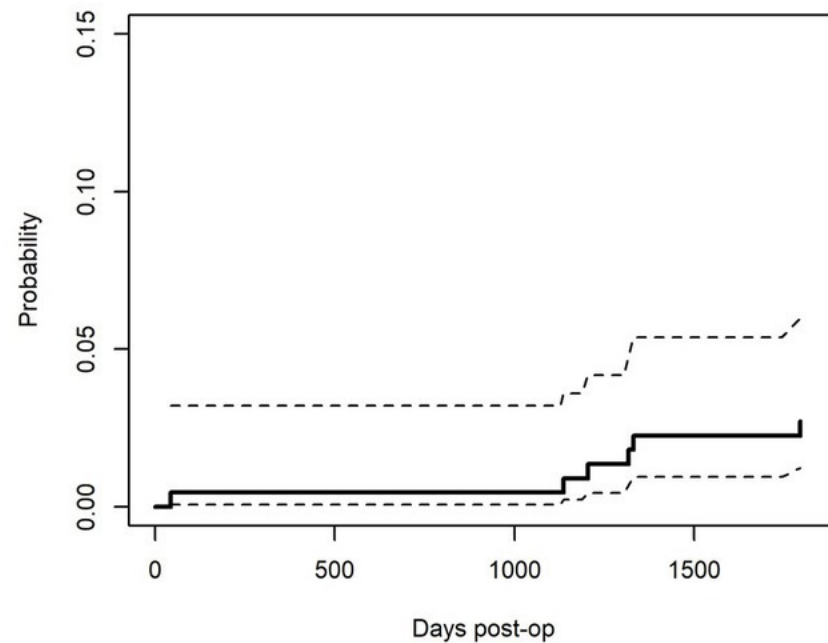
LEFT



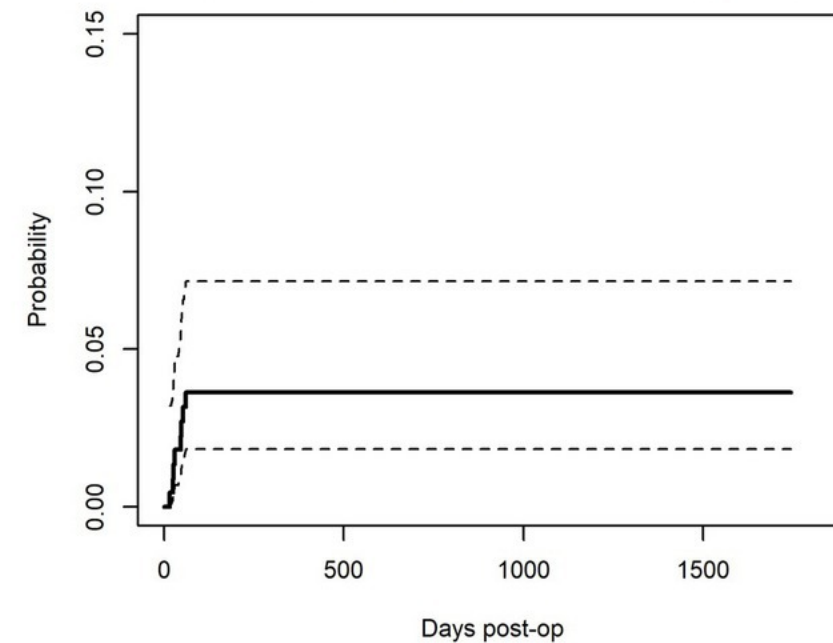
4a DISLOCATION



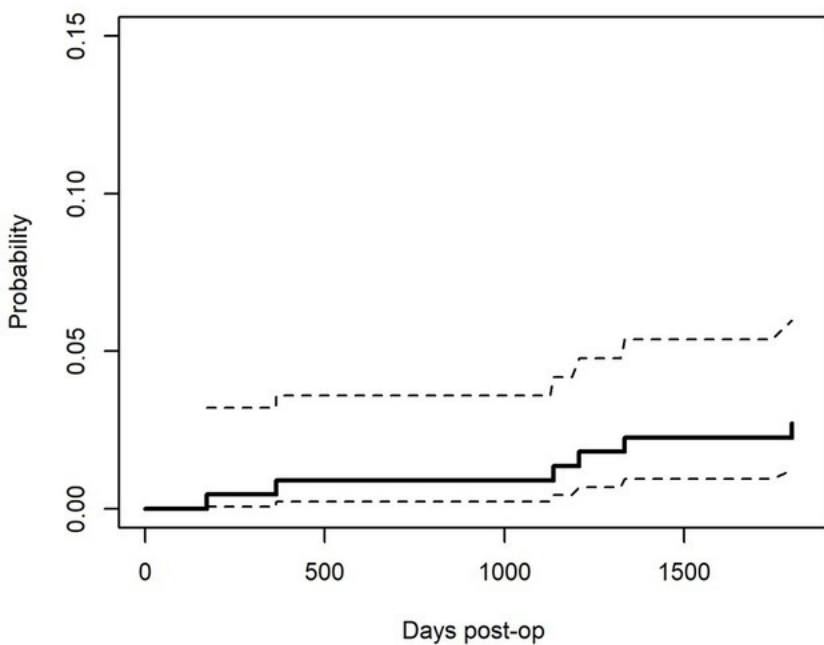
4b PERIPROSTHETIC FRACTURE



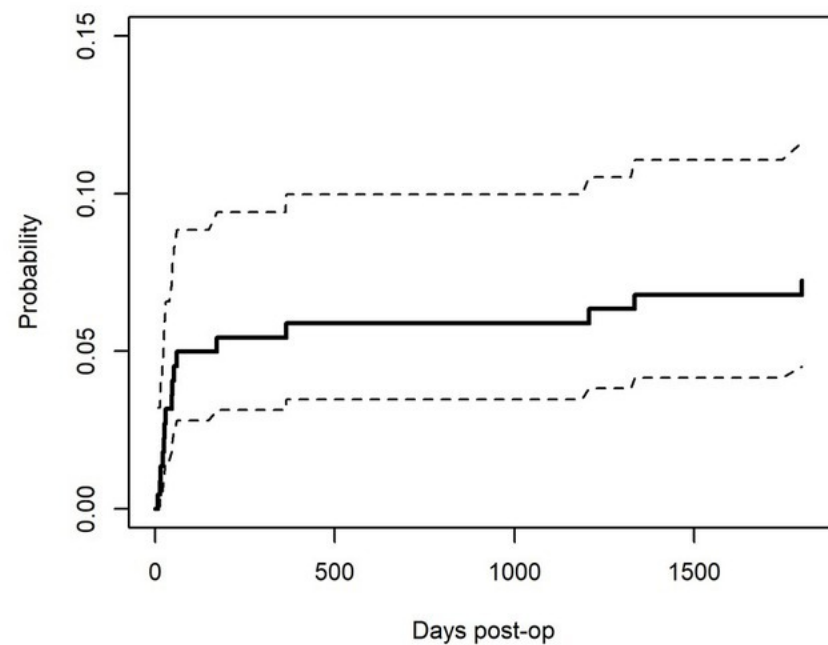
4c PROSTHETIC JOINT INFECTION



4e REVISION



4d REOPERATION



4f COMPLICATION

