



HAL
open science

Focus on stereotactic radiotherapy: A new way to treat severe ventricular arrhythmias?

Frédéric Sacher, Estelle Gandjbakhch, Philippe Maury, Catherine Jenny, Jonathan Khalifa, Serge Boveda, Pascal Defaye, Daniel Gras, Didier Klug, Gabriel Laurent, et al.

► To cite this version:

Frédéric Sacher, Estelle Gandjbakhch, Philippe Maury, Catherine Jenny, Jonathan Khalifa, et al.. Focus on stereotactic radiotherapy: A new way to treat severe ventricular arrhythmias?. Archives of cardiovascular diseases, 2021, 114 (2), pp.140-149. 10.1016/j.acvd.2020.11.003 . hal-04007616

HAL Id: hal-04007616

<https://hal.science/hal-04007616v1>

Submitted on 15 Mar 2023

HAL is a multi-disciplinary open access archive for the deposit and dissemination of scientific research documents, whether they are published or not. The documents may come from teaching and research institutions in France or abroad, or from public or private research centers.

L'archive ouverte pluridisciplinaire **HAL**, est destinée au dépôt et à la diffusion de documents scientifiques de niveau recherche, publiés ou non, émanant des établissements d'enseignement et de recherche français ou étrangers, des laboratoires publics ou privés.



Distributed under a Creative Commons Attribution - NonCommercial 4.0 International License

Focus on stereotactic radiotherapy: A new way to treat severe ventricular arrhythmias?

Abbreviated title: Stereotactic radiotherapy for severe ventricular arrhythmias

Tweet: All you need to know if you plan to start non-invasive cardiac radioablation for ventricular tachycardia

Frédéric Sacher^{a,*}, Estelle Gandjbakhch^b, Philippe Maury^c, Catherine Jenny^d, Jonathan Khalifa^e, Serge Boveda^f, Pascal Defaye^g, Daniel Gras^h, Didier Klugⁱ, Gabriel Laurent^j, Nicolas Lellouche^k, Jacques Mansourati^l, Eloi Marijon^m, Olivier Piotⁿ, Jerome Taieb^o, Hubert Cochet^p, Philippe Maingon^d, Etienne Pruvot^q, Laurent Fauchier^r, for the Working Group of Cardiac Pacing and Electrophysiology of the French Society of Cardiology

^a *Department of Cardiology, IHU Liryc, Electrophysiology and Heart Modelling Institute, University of Bordeaux, Bordeaux University Hospital (CHU), 33600 Pessac, France*

^b *Department of Cardiology, La Pitié-Salpêtrière University Hospital, AP-HP, 75013 Paris, France*

^c *Department of Cardiology, Toulouse University Hospital, 31059 Toulouse, France*

^d *Department of Radiotherapy, La Pitié-Salpêtrière University Hospital, AP-HP, 75013 Paris, France*

^e *Departments of Radiotherapy and Cardiology, Toulouse University Hospital, 31059 Toulouse, France*

^f *Department of Cardiology, Clinique Pasteur, 31076 Toulouse, France*

^g *Department of Cardiology, Grenoble University Hospital, 38700 La Tronche, France*

^h *Department of Cardiology, Nouvelles Cliniques Nantaises, 44277 Nantes, France*

ⁱ *Department of Cardiology, Lille University Hospital, 59000 Lille, France*

^j *Department of Cardiology, Dijon University Hospital, 21000 Dijon, France*

^k *Department of Cardiology, Hôpital Henri Mondor, AP-HP, 94010 Créteil, France*

^l *Department of Cardiology, Brest University Hospital, 29609 Brest, France*

^m *Department of Cardiology, Hôpital Européen Georges Pompidou, AP-HP, 75015 Paris, France*

ⁿ *Department of Cardiology, Centre Cardiologique du Nord, 93200 Saint-Denis, France*

^o *Department of Cardiology, Aix-en-Provence Hospital, 13616 Aix-en-Provence, France*

^p *Department of Radiology, IHU Liryc, Electrophysiology and Heart Modelling Institute, University of Bordeaux, Bordeaux University Hospital (CHU), 33600 Pessac, Bordeaux, France*

^q *Department of Cardiology, CHUV, 1011 Lausanne, Switzerland*

^r *Department of Cardiology, Tours University Hospital, 37000 Tours, France*

* Corresponding author at: Hôpital Cardiologique du Haut Lévêque, CHU de Bordeaux, Avenue du Haut Lévêque, 33604 Pessac CEDEX, France.

E-mail address: frederic.sacher@chu-bordeaux.fr (F. Sacher).

Twitter address:@FredSacher_EP

Summary

Ventricular tachycardia has a significant recurrence rate after ablation for several reasons, including inaccessible substrate. A non-invasive technique to ablate any defined areas of myocardium involved in arrhythmogenesis would be a potentially important therapeutic improvement if shown to be safe and effective. Early feasibility studies of single-fraction stereotactic body radiotherapy have demonstrated encouraging results, but rigorous evaluation and follow-up are required. In this document, the basic concepts of stereotactic body radiotherapy are summarized, before focusing on stereotactic arrhythmia radioablation. We describe the effect of radioablation on cardiac tissue and its interaction with intracardiac devices, depending on the dose. The different clinical studies on ventricular tachycardia radioablation are analysed, with a focus on target identification, which is the key feature of this approach. Our document ends with the indications and requirements for practicing this type of procedure in 2020. Finally, because of the limited number of patients treated so far, we encourage multicentre registries with long-term follow-up.

KEYWORDS

Ventricular tachycardia;

Catheter ablation;

Stereotactic radiotherapy;

Stereotactic body radiation therapy

Abbreviations: CIED, cardiac implanted electronic device; CT, computed tomography; ICD, implantable cardioverter defibrillator; LINAC, linear accelerator; SABR, stereotactic ablative radiotherapy; SBRT, stereotactic body radiotherapy; STAR, stereotactic arrhythmia radioablation; VT, ventricular tachycardia.

Background

Catheter ablation of ventricular tachycardia (VT) is poorly standardized, can be lengthy and is potentially associated with significant risks. Despite being performed in expert centres, significant recurrence rates have been reported (up to 40–50% arrhythmia recurrence, leading to additional interventions) [1-4]. Efficacy is limited when the VT substrate is not easily accessible because of deep intramural locations or when catheter access is precluded by the presence of a mechanical prosthetic valve or an intracavitary thrombus. Furthermore, its invasive nature and potential complications make this procedure less attractive for patients with multiple co-morbidities and haemodynamic compromise. A non-invasive technique that can ablate defined areas of myocardium involved in arrhythmogenesis would be a potentially important therapeutic improvement if shown to be safe and effective. Early feasibility studies of single-fraction stereotactic body radiotherapy (SBRT) have demonstrated encouraging results [5-10], but rigorous evaluation and follow-up are required because of potential delayed complications [6, 8].

SBRT: Basic concepts

SBRT involves directing highly focused external beam radiation therapy to target a well-defined and demarcated volume of tissue. The use of stereotactic radiation therapy was first described for the treatment of brain diseases, with the goal of delivering a high therapeutic dose to the lesion of interest, while minimizing radiation to the surrounding normal tissue [11]. Stereotactic radiation therapy first started with the gamma knife, which typically contains a large number of cobalt-60 sources placed in a hemispheric array in a heavily shielded assembly. The device delivers gamma radiation intersecting at a target point in the patient's brain. The patient is immobilized by a frame that is surgically fixed to the skull, so that the brain tumour remains stationary at the gamma ray target point. Nowadays, some patients can also be immobilized with a repositionable mask, which is less invasive than the frame, and allows fractionation of the treatment. Application of this technology to other organs was initially limited by physiological motion and difficulties with accurate targeting [12]. However, the development of linear accelerators (LINACs), advances in imaging and new means of treatment, such as gating, tracking and intensity modulation, have enabled the application of stereotactic radiation to extracranial

organs, and it is now referred to as SBRT [13] (or stereotactic ablative radiotherapy [SABR] when the target is outside the central nervous system).

LINACs equipped with image guidance, a high-resolution multileaf collimator and improved mechanical accuracy are recommended for best practice of SBRT [14], as well as a dedicated linear accelerator (LINAC), such as the Cyberknife® (Accuray Incorporated, Sunnyvale, CA, USA). The Cyberknife® uses a 6 MV photon beam, produced by a LINAC mounted on a robot. Compared with a conventional LINAC, the arm of which moves in a single rotational plane, the robotic arm of the Cyberknife® has 6 degrees of freedom of motion. A computer monitors the patient's position during treatment in order to correct for patient movements, to achieve < 1 mm accuracy. It is possible to track real-time tumour movement while the patient is breathing, using either image contrast or fiducial markers implanted in or near the tumour volume. The Cyberknife® G4™ and M6™ systems, as well as the TrueBeam™ and the Edge™ (Varian Medical Systems, Palo Alto, CA, USA) are the systems that have been used so far for VT radioablation. Another potential technology suitable for SBRT is proton or carbon beam therapy, which is used less frequently than photon therapy, as it requires large and costly accelerators.

SBRT precisely delivers a high dose to an extracranial well-limited tumour, in a single or a few fractions (fewer than six). The radiobiological doses are higher than those used in conventional treatment, so the dose must decrease rapidly between the target and the healthy tissue. The key requirement for SBRT is therefore a high level of accuracy at each step of the treatment process [15].

Patient immobilization should be effective and reproducible between the four-dimensional computed tomography (CT) scan and the fraction(s) of treatment. Stereotactic target localization and accurate target delineation are crucial; this step requires the use of multimodality imaging to help to differentiate healthy from diseased tissue. A highly conformed dosimetry is needed: LINACs should have microleaf collimators with thin leaves (≤ 5 mm) or conical collimators. It is necessary to use multiple non-overlapping small beams with energy < 10 MV. It is possible to treat with static or rotational beams, with or without intensity modulation radiation therapy or volumetric modulated arc therapy. To achieve the required dose calculation accuracy, the planning system should be specifically commissioned for SBRT, with a dedicated beam model, and the algorithm should account for tissue heterogeneities. Improved delivery precision needs a specific quality control programme. Image guidance is a prerequisite: each of the commercially available systems uses CT or X-ray imaging to

ensure accurate patient positioning before and sometimes during treatment (patients may move during treatment, requiring realignment). The integration of magnetic resonance imaging and LINACs into new treatment systems (i.e. magnetic resonance LINACs) now allows magnetic resonance online guidance. Additionally, the internal location of the target, because of respiratory-, cardiac- or bowel-associated movement, must be accounted for in the treatment planning and delivery. Motion management may be accomplished in a variety of ways, from plans that fully encompass the movement of the target to respiratory gating (where the dose is delivered only when the target is within a defined region of the respiratory cycle) to respiratory tracking (where the target is tracked throughout the cycle). Generally, a radio-opaque fiducial marker serves as a surrogate for the target position and is used to image movement with X-ray or CT imaging. Motion compensation can be achieved with: dampening/inhibition, which aims to limit respiratory motion using abdominal compression or breath-hold techniques; gating, which follows the respiratory cycle to deliver radiation during a specific segment of this cycle; or tracking systems, which move the radiation beam to follow a moving target.

SBRT has emerged as standard therapy for early-stage lung cancer, for localized prostate cancer and primary pancreatic, liver, kidney and breast cancer, and for limited metastatic disease. The extension of SBRT to cardiac tissue came with the recognition that respiratory gating can effectively reduce the treated volume of the heart [16].

Stereotactic arrhythmia radioablation

SBRT for cardiac arrhythmias is also referred to as stereotactic arrhythmia radioablation (STAR).

Lesion pathophysiology

In experimental animal models, STAR has been used to create atrioventricular block, conduction block in the cavotricuspid isthmus and lesions in the venoatrial junctions of the pulmonary veins [16]. Unlike catheter-directed radiofrequency or cryoablation, in which tissue destruction is affected by thermal injury, radiotherapy uses high-dose X-rays (typically 25–30 Gy) directed towards a three-dimensional volume of target tissue. The radiobiology of SBRT remains to be completely characterized. The mechanism of tissue injury is probably multifactorial, and is not fully understood, being in part the consequence of double-strand breaks in deoxyribonucleic acid and intracellular production of oxygen reactive species, leading to apoptosis, but also of microcirculation vascular damage and ischaemic

cell death. Unlike with catheter-based thermal injury, which produces immediate effects, the results of radiotherapy-related ablation probably depend on the dose, and may take days to months to manifest fully. In experimental studies of cardiac ablation, conduction block in ablated tissue was not seen until 30 days after therapy. However, with a single dose of 25 Gy, clinical effects in patients have been observed acutely, with an immediate reduction [6] in arrhythmia burden to reduction within days or weeks after therapy [5, 8]. Therefore, the effect cannot only be caused by the ischaemic-induced fibrosis resulting from the radioablation. Inflammatory cells and oedema in the cardiac tissue have been observed acutely in experimental studies, and may explain the early direct effect on arrhythmogenesis [17].

Post-mortem cardiac pathological assessments have been performed in some patients. Prominent ectasic blood vessels were identified at the interface of dense scar and viable myocardium in the series reported by Cuculich et al. [5]. This pattern has been described as a component of the acute vascular injury that is usually observed in the early weeks after radiation exposure. In such cases, the injury pattern is typically accompanied by endothelial cell swelling, vacuolization and perivascular tissue oedema, which were not found in these patients. Lloyd et al. [7] reported microscopic analysis of the SBRT-treated regions in the hearts of three patients who underwent cardiac transplant. Examination indicated oedema and vacuolization of endothelial cells with mild fibrosis. Electron microscopy showed disruption of intercalated disc/gap junction areas, which may explain the relatively acute treatment responses using a single high dose of 25 Gy.

Interaction between the heart, devices and radiation

The immediate attraction of non-invasive SBRT for VT ablation is its suitability for patients in whom standard VT ablation has failed or is deemed not feasible, particularly sicker patients and those with epicardial substrate with previous cardiac surgery or VT substrates that are not accessible to current methodologies, such as deep intraseptal or intramural substrate. However, the limitations of STAR will need to be carefully considered. The long-term toxic effect of radiotherapy on the cardiac structures is well documented, and is derived from experience with mantle field radiation for the treatment of Hodgkin lymphoma and breast cancer [18]. Damage to the coronary arteries, conduction system, valve structures, myocardium and pericardium can emerge years later. The pathophysiology of cardiac damages involves micro- and macrovascularization [19]. Microvascular damage results from

the destruction of capillaries, which provokes myocardial ischaemia and fibrosis that may be responsible for valve dysfunction, pericardial fibrosis (constrictive pericarditis) [20], pericardial effusion [21, 22] and diastolic dysfunction [19, 23]. Macrovascular damage induces accelerated atherosclerosis [24]. Conduction disturbances and arrhythmias have also been described [21, 22]. To limit these complications, breast radiotherapy has been adapted to decrease the dose on the heart by delivering the energy during breath hold in deep inspiration, which allows irradiation of the breast while the heart is far from the target [25]. Although SBRT is designed to minimize toxicity to adjacent structures, respiratory and cardiac motion increase the risk of off-target delivery. This risk profile, although acceptable when SBRT is used as palliation, might be of concern for patients who have an anticipated longer survival. For 16 patients from the ENCORE study [10], detailed information on cardiac structure irradiation has been reported [26]. Unsurprisingly, the highest median dose was received by the left ventricle (11.3 Gy), followed by the left anterior descending artery (10.1 Gy) and the circumflex artery (9.2 Gy), which may increase the risk of delayed atherosclerosis. Irradiation was next-most pronounced on the right ventricle (8.3 Gy) and the pericardium (7.2 Gy). The limits of normal tissue dose tolerance remain uncertain to date. In the context of conventionally fractionated radiation to the lung, patients with > 25% of the heart receiving ≥ 50 Gy had an increased rate of cardiac toxicity and a decrease in overall survival [27, 28]. In lung SBRT, the median dose to the left ventricle was 0.2 Gy and 0.8 Gy to the left anterior descending artery. No relationship was found between whole-heart or substructure dose and cardiac events [29]. No increase in heart failure directly linked to STAR has been described so far. However, one patient from the ENCORE-VT study [10] was admitted for heart failure exacerbation 65 days after treatment, but it is not known whether this was the normal course of his cardiac disease or was caused by STAR. Radioablation of myocardium in close proximity to digestive structures (oesophagus, stomach, etc.) may expose to acute or delayed gastrointestinal radiation injuries, such as necrosis, ulceration, perforation or chronic enteropathy [30]. The maximal dose admitted as safe in the adjacent healthy structure is 16 Gy for the healthy heart in < 15 cc and 11 Gy for the oesophagus/stomach in multifraction treatments [31]. Of note, no case of radiotherapy - induced neoplasia has been published since the beginning of SBRT. Moreover, the heart is probably relatively protected from this side effect by the usual lack of division of adult cardiac cells.

Another potential issue with radiotherapy concerns cardiac implanted electronic devices (CIEDs) [32, 33]. Increased radiation sensitivity has been reported with modern versus older CIEDs,

independent of the type of ionizing radiation (direct or scattered) [34]. Beam energy ≥ 10 MV was demonstrated to be the most important predicting factor for radiotherapy-related CIED malfunction, because high-photon energies cause excessive production of secondary neutrons that harm the random-access memory or complementary metal oxide semiconductor components present in contemporary CIEDs [35]. In addition, a study by Elders et al. [36] reported implantable cardioverter defibrillator (ICD) failures with 18 MV beam energy, whereas no radiotherapy-correlated events were observed at 6 MV. A maximum photon dose of 2 Gy for pacemakers and possibly 1 Gy for ICDs is generally accepted as safe [32, 37]. However, no ICD damage has been reported to date with STAR. ICD irradiation is generally as low as 0.13 Gy (0.03–0.6 Gy) [26], as the can is away from the irradiated field. The different centres performing these procedures switch off the ICD or apply a magnet to the ICD during the procedure, with an external defibrillator close by.

Concerning patients with a left ventricular assist device, two patients from the series of Lloyd et al. [7] had a left ventricular assist device and one had an intra-aortic balloon pump, and did not experience any technical problems.

Clinical experience of VT treatment

Early experience with the use of stereotactic radiotherapy as palliation for VT has been encouraging, but it should be noted that the reports are limited to very small numbers of patients (51 when pooling all the studies) with limited follow-up (Table 1) [5-10]. Indications were patients receiving recurrent ICD therapies despite antiarrhythmic drugs and previous VT ablation or with contraindication to invasive VT ablation. Some of the patients were in arrhythmic storm and/or in advanced heart failure. In a more recent study [10], they extended the indication to patients with premature ventricular complex-induced tachycardiomyopathy with failed antiarrhythmic drugs and conventional ablation. Of note, they excluded patients with previous radiotherapy to the anticipated treatment field. STAR was performed in all using 25 Gy in one session, with variable success rates.

The distal dipole of the right ventricular ICD lead can be used as a fiducial marker for real-time tracking. However, some centres using a LINAC did not use a fiducial marker, whereas others inserted a temporary pacing wire (Cyberknife® users). Some centres used the concept of a “safety margin” of 1–5 mm around the volume targeted to compensate the risk of missing a zone as a result of respiratory and cardiac motion during application. It should be pointed out that the motion of the target

may be different from the motion of the marker, and has to be carefully assessed and compared with imaging and electrophysiological information to avoid inappropriate normal tissue irradiation.

Treatment times ranged from 10 to 90 minutes based on the dose rate of the beams, varying with the machines used, target size and location (Table 1). The treatment is painless, and requires no concomitant invasive procedures. One crucial point developed below is the identification of the target, keeping in mind that the volume of the target is correlated to the dose of collateral irradiation to healthy tissue and the risk of potential radiation injury of the adjacent structure. In the different series, the target volume varied from 14 to 299 mL, with a median of around 70 mL.

Concerning efficacy, comparison with catheter ablation is difficult because: (1) all these patients had failed catheter ablation or were contraindicated to catheter ablation; and (2) results are presented differently – mainly as a decrease in VT burden, which may be an acceptable endpoint in this very sick population, resistant to all therapies. However, in terms of recurrence, Neuwirth et al. [9] reported only two of 10 patients without VT recurrence. Longer-term efficacy is not well described, with controversial data; Gianni et al. [38] reported 100% recurrence at 12 months.

Delayed efficacy [5, 8, 9], possibly as a result of ischaemic-induced fibrosis, has been reported in several studies, but in others [6, 7] an immediate effect was noted, which makes this strategy possibly suitable, even in case of electrical storm.

In terms of safety, few complications have been reported so far (Table 1), but no long-term data are available, and radiation complications of the heart have been described, sometimes > 10 years later. All of the studies reported a low dose per fraction. None of them mentioned with accuracy the relationship between the dose delivered and the specific cardiac area receiving irradiation. However, this hypothetical risk appears acceptable in these very sick patients with intractable arrhythmias, as the mortality from an arrhythmia storm remains high if untreated (~25%). It should be noted, however, that most of these complications (pericardial, conductive and coronary artery) can be well managed today in these otherwise very sick patients with intractable arrhythmias, and have not been described to date.

Target identification

Identification of the target is the crucial point of STAR. In scar-related ventricular arrhythmias, the arrhythmia origin is usually related to the ventricular scar/border zone containing surviving myocyte

bundles [39]. However, the entire scar may not be participating in arrhythmogenesis. Entire scar homogenization [40], as described for VT catheter ablation, implies too large a volume to treat, increasing the dose of collateral irradiation to healthy tissue, and is therefore not recommended. The maximal acceptable volume to treat is not well defined, but should be as limited as possible. The median volume treated in studies on STAR was around 70 mL (Table 1). To improve target identification, several tools can be used.

Cardiac imaging

Cardiac imaging allows scar identification with different modalities: delayed enhancement cardiac magnetic resonance imaging, cardiac CT scan or positron emission tomography scan. The advantages are that delineation of the volume to treat by SBRT can be performed on a dedicated CT scan, and that an additional CT scan or chest X-ray performed on-line in the radioablation unit may be used to optimize the tracking at the cost of additional irradiation. However, even if cardiac imaging gives a global idea of the area to treat, it is not specific enough. Therefore, there may be a place for new optimized solutions identifying anatomical VT channels/isthmii on cardiac imaging, such as MUSIC® (inHEART, Pessac, France) [41, 42] or ADAS 3D® (Galgo Medical, Barcelona, Spain) [43] software.

Twelve-lead morphology of the VT

Twelve-lead morphology of the VT helps to identify the exit of the electrical activity from the scar, and can refine the area to target when scar is identified on a CT scan.

Body-surface mapping

Body-surface mapping may refine VT exit localization compared with twelve-lead electrocardiography [5, 10]. However, it requires the VT to be induced, for example using an ICD (i.e. non-invasive ventricular stimulation).

Electroanatomical mapping

Electroanatomical mapping has mostly been performed during the failed VT ablation procedure, and may be merged with scar visualized on a CT scan. Even if the VT is not fully mapped (i.e. missing

isthmus), it gives a better idea of the substrate and potential isthmus (Fig. 1). However, to date, no automatic exportation of such three-dimensional imaging is possible into an on-site CT scan.

Targeting is still manually based, decreasing the accuracy of target identification in the radiotherapy system.

To be effective, it is important to treat the VT isthmus and not just the exit. In the different series, isthmus localization (volume) was derived from the different tools mentioned above, and suspected by the electrophysiologists, based on their experience (Fig. 1). This defines the gross target volume, which is manually delineated on the planning software coupled to the SBRT system, increasing the risk of approximation. In the literature, it is sometimes labelled as clinical target volume, which is defined as a target volume, including the potential spreading of tumour cells around the gross target volume. This then has to be optimized on each of the phases of the cardiac cycle. The union of all gross target volumes generates the internal target volume, which allows respiratory/cardiac motions to be taken into account. An additional isotropic margin (0–5 mm in studies for VT) can be added to compensate for set-up motion uncertainties, creating the planning target volume. In the ENCORE study, the median gross target volume was 25.1 cm³ and the internal target volume was 30.1 cm³. The planning target volume (97.9 cm³) was generated as a 5 mm volumetric expansion from the internal target volume [26]. This raises the problem of compensating for the uncertainties of target localization in a moving organ as a result of set-up respiratory/cardiac/patient motion. In this study, it increases the volume to treat by 4, and therefore the radiation dose delivered.

While we await technological improvements (cardiac on top of respiratory gating) in the SBRT system, a platform (Fig. 2) integrating all imaging and electrophysiological information to refine delineation of the target volumes is warranted, to optimize the workflow and accuracy of SBRT delivery; as a byproduct this will limit the planning target volume, reducing potential side effects. It is of particular importance that such a platform proves to be compatible with SBRT software, to define with accuracy the internal target volume after merging these data.

Reasonable indications in 2020

Based on published data and the uncertainty regarding possible long-term complications of cardiac irradiation, indications should be carefully evaluated. Eligible patients are those with recurrent VT

despite at least one antiarrhythmic medication, who have failed catheter ablation in an experienced centre or are contraindicated to VT ablation (intracardiac thrombus and failure of/contraindication for epicardial ablation or access, double mechanical valve, epicardial VT with no pericardial access). A minimum VT burden of at least three VT episodes in the last 6 months was the inclusion criterion in most of the series. Finally, a 12-lead electrocardiogram of the VT, either spontaneously or during an invasive or non-invasive electrophysiology study, is important to focus the treatment on the clinical VT, particularly in case of large scar/multiple scars.

In the different series, exclusion criteria were: (1) patient with a past history of radiotherapy within the projected treatment field delivering clinically significant radiation (but this point should be discussed on a case-by-case basis with radiation oncologists); and (2) myocardial scar (diffuse substrate) that would require stereotactic delivery to a target volume deemed unsafe by the treating physician.

At the present time, STAR probably should not be proposed for patients without severe heart disease or as a first-line therapy until long-term safety has been demonstrated.

Requirements and perspectives

To perform such a procedure, there is a need for close collaboration between radiation oncologists, medical physicists and electrophysiologists trained in VT ablation. The absence of one of these specialists would impair the results and may increase patient risk. A standardized workflow should be established by each institution. Accurate identification of the target is a key point for an optimal efficacy/safety ratio; this identification is currently based on the experience of the electrophysiologist, who makes their decision based on multiple data (electrocardiogram, invasive or non-invasive mapping, imaging, etc.). Target identification would definitely benefit from machine learning if a large amount of data were available. Therefore, we are working on a common nationwide prospective registry that should certainly improve our knowledge on the optimal workflow to perform such a procedure, with insight into efficacy and longer-term safety profile.

We also need better tools to translate from electrophysiology to a radiotherapy system. At present, medical physicists and radiation oncologists have to delineate the target identified by the electrophysiologist manually into the SBRT system, and undertake treatment planning to eradicate it and avoid collateral damage. In terms of material, compatible LINAC equipment is also mandatory.

Conclusions

SBRT appears to be extremely appropriate for the delivery of high energy to a specific part of the heart. It seems to be a promising non-invasive technique to treat refractory VTs. As a result of the accurate energy delivery and the high gradient between dose delivered to the target versus to the adjacent structure (i.e. the organ at risk), acute as well as late toxicity should be minimal [44].

However, even if only a limited number of complications have been reported so far after SBRT [10], there is a need for a national registry including all patients receiving this treatment, to evaluate long-term efficacy and safety, and further determine the place of STAR in VT management.

Sources of funding

None.

Disclosure of interest

The authors declare that they have no conflicts of interest concerning this article.

References

- [1] Cronin EM, Bogun FM, Maury P, et al. 2019 HRS/EHRA/APHRS/LAHRS expert consensus statement on catheter ablation of ventricular arrhythmias. *Europace* 2019;21:1143-4.
- [2] Dinov B, Fiedler L, Schonbauer R, et al. Outcomes in catheter ablation of ventricular tachycardia in dilated nonischemic cardiomyopathy compared with ischemic cardiomyopathy: results from the Prospective Heart Centre of Leipzig VT (HELP-VT) Study. *Circulation* 2014;129:728-36.
- [3] Sacher F, Tedrow UB, Field ME, et al. Ventricular tachycardia ablation: evolution of patients and procedures over 8 years. *Circ Arrhythm Electrophysiol* 2008;1:153-61.
- [4] Sapp JL, Wells GA, Parkash R, et al. Ventricular Tachycardia Ablation versus Escalation of Antiarrhythmic Drugs. *N Engl J Med* 2016;375:111-21.
- [5] Cuculich PS, Schill MR, Kashani R, et al. Noninvasive Cardiac Radiation for Ablation of Ventricular Tachycardia. *N Engl J Med* 2017;377:2325-36.
- [6] Jumeau R, Ozsahin M, Schwitter J, et al. Rescue procedure for an electrical storm using robotic non-invasive cardiac radio-ablation. *Radiother Oncol* 2018;128:189-91.
- [7] Lloyd MS, Wight J, Schneider F, et al. Clinical experience of stereotactic body radiation for refractory ventricular tachycardia in advanced heart failure patients. *Heart Rhythm* 2020;17:415-22.
- [8] Loo BW, Jr., Soltys SG, Wang L, et al. Stereotactic ablative radiotherapy for the treatment of refractory cardiac ventricular arrhythmia. *Circ Arrhythm Electrophysiol* 2015;8:748-50.
- [9] Neuwirth R, Cvek J, Knybel L, et al. Stereotactic radiosurgery for ablation of ventricular tachycardia. *Europace* 2019;21:1088-95.
- [10] Robinson CG, Samson PP, Moore KMS, et al. Phase I/II Trial of Electrophysiology-Guided Noninvasive Cardiac Radioablation for Ventricular Tachycardia. *Circulation* 2019;139:313-21.
- [11] Leksell L. The stereotaxic method and radiosurgery of the brain. *Acta Chir Scand* 1951;102:316-9.
- [12] Timmerman RD, Herman J, Cho LC. Emergence of stereotactic body radiation therapy and its impact on current and future clinical practice. *J Clin Oncol* 2014;32:2847-54.
- [13] Folkert MR, Timmerman RD. Stereotactic ablative body radiosurgery (SABR) or Stereotactic body radiation therapy (SBRT). *Adv Drug Deliv Rev* 2017;109:3-14.

- [14] Potters L, Kavanagh B, Galvin JM, et al. American Society for Therapeutic Radiology and Oncology (ASTRO) and American College of Radiology (ACR) practice guideline for the performance of stereotactic body radiation therapy. *Int J Radiat Oncol Biol Phys* 2010;76:326-32.
- [15] SFPM. Rapport N° 35: Qualite et securite des radiochirurgies et des radiotherapies stereotaxiques. Février 2019. Available at: http://documents.sfpf.fr/docs_sfpf/sfpf_2019_35_rapport_qualite_secutite_rth_stereotaxique.pdf.
- [16] Sharma A, Wong D, Weidlich G, et al. Noninvasive stereotactic radiosurgery (CyberHeart) for creation of ablation lesions in the atrium. *Heart Rhythm* 2010;7:802-10.
- [17] Fajardo LF, Stewart JR. Experimental radiation-induced heart disease. I. Light microscopic studies. *Am J Pathol* 1970;59:299-316.
- [18] Yusuf SW, Sami S, Daher IN. Radiation-induced heart disease: a clinical update. *Cardiol Res Pract* 2011;2011:317659.
- [19] Darby SC, Cutter DJ, Boerma M, et al. Radiation-related heart disease: current knowledge and future prospects. *Int J Radiat Oncol Biol Phys* 2010;76:656-65.
- [20] Hoening MJ, Aleman BM, van Rosmalen AJ, Kuenen MA, Klijn JG, van Leeuwen FE. Cause-specific mortality in long-term survivors of breast cancer: A 25-year follow-up study. *Int J Radiat Oncol Biol Phys* 2006;64:1081-91.
- [21] Larsen RL, Jakacki RI, Vetter VL, Meadows AT, Silber JH, Barber G. Electrocardiographic changes and arrhythmias after cancer therapy in children and young adults. *Am J Cardiol* 1992;70:73-7.
- [22] Orzan F, Brusca A, Gaita F, Giustetto C, Figliomeni MC, Libero L. Associated cardiac lesions in patients with radiation-induced complete heart block. *Int J Cardiol* 1993;39:151-6.
- [23] Heidenreich PA, Hancock SL, Vagelos RH, Lee BK, Schnittger I. Diastolic dysfunction after mediastinal irradiation. *Am Heart J* 2005;150:977-82.
- [24] Cuzick J, Stewart H, Rutqvist L, et al. Cause-specific mortality in long-term survivors of breast cancer who participated in trials of radiotherapy. *J Clin Oncol* 1994;12:447-53.
- [25] Boda-Heggemann J, Knopf AC, Simeonova-Chergou A, et al. Deep Inspiration Breath Hold-Based Radiation Therapy: A Clinical Review. *Int J Radiat Oncol Biol Phys* 2016;94:478-92.

- [26] Knutson NC, Samson PP, Hugo GD, et al. Radiation Therapy Workflow and Dosimetric Analysis from a Phase 1/2 Trial of Noninvasive Cardiac Radioablation for Ventricular Tachycardia. *Int J Radiat Oncol Biol Phys* 2019;104:1114-23.
- [27] Chun SG, Hu C, Choy H, et al. Impact of Intensity-Modulated Radiation Therapy Technique for Locally Advanced Non-Small-Cell Lung Cancer: A Secondary Analysis of the NRG Oncology RTOG 0617 Randomized Clinical Trial. *J Clin Oncol* 2017;35:56-62.
- [28] Speirs CK, DeWees TA, Rehman S, et al. Heart Dose Is an Independent Dosimetric Predictor of Overall Survival in Locally Advanced Non-Small Cell Lung Cancer. *J Thorac Oncol* 2017;12:293-301.
- [29] Reshko LB, Kalman NS, Hugo GD, Weiss E. Cardiac radiation dose distribution, cardiac events and mortality in early-stage lung cancer treated with stereotactic body radiation therapy (SBRT). *J Thorac Dis* 2018;10:2346-56.
- [30] Shadad AK, Sullivan FJ, Martin JD, Egan LJ. Gastrointestinal radiation injury: symptoms, risk factors and mechanisms. *World J Gastroenterol* 2013;19:185-98.
- [31] Benedict SH, Yenice KM, Followill D, et al. Stereotactic body radiation therapy: the report of AAPM Task Group 101. *Med Phys* 2010;37:4078-101.
- [32] Riva G, Alessandro O, Spoto R, et al. Radiotherapy in patients with cardiac implantable electronic devices: clinical and dosimetric aspects. *Med Oncol* 2018;35:73.
- [33] Zaremba T, Jakobsen AR, Sogaard M, Thogersen AM, Riahi S. Radiotherapy in patients with pacemakers and implantable cardioverter defibrillators: a literature review. *Europace* 2016;18:479-91.
- [34] Hudson F, Coulshed D, D'Souza E, Baker C. Effect of radiation therapy on the latest generation of pacemakers and implantable cardioverter defibrillators: A systematic review. *J Med Imaging Radiat Oncol* 2010;54:53-61.
- [35] Zaremba T, Jakobsen AR, Thogersen AM, Oddershede L, Riahi S. The effect of radiotherapy beam energy on modern cardiac devices: an in vitro study. *Europace* 2014;16:612-6.
- [36] Elders J, Kunze-Busch M, Smeenk RJ, Smeets JL. High incidence of implantable cardioverter defibrillator malfunctions during radiation therapy: neutrons as a probable cause of soft errors. *Europace* 2013;15:60-5.

- [37] Zecchin M, Morea G, Severgnini M, et al. Malfunction of cardiac devices after radiotherapy without direct exposure to ionizing radiation: mechanisms and experimental data. *Europace* 2016;18:288-93.
- [38] Gianni C, Rivera D, Burkhardt JD, et al. Stereotactic arrhythmia radioablation for refractory scar-related ventricular tachycardia. *Heart Rhythm* 2020;17:1241-8.
- [39] de Bakker JM, van Capelle FJ, Janse MJ, et al. Reentry as a cause of ventricular tachycardia in patients with chronic ischemic heart disease: electrophysiologic and anatomic correlation. *Circulation* 1988;77:589-606.
- [40] Di Biase L, Burkhardt JD, Lakkireddy D, et al. Ablation of Stable VTs Versus Substrate Ablation in Ischemic Cardiomyopathy: The VISTA Randomized Multicenter Trial. *J Am Coll Cardiol* 2015;66:2872-82.
- [41] Cochet H, Komatsu Y, Sacher F, et al. Integration of merged delayed-enhanced magnetic resonance imaging and multidetector computed tomography for the guidance of ventricular tachycardia ablation: a pilot study. *J Cardiovasc Electrophysiol* 2013;24:419-26.
- [42] Komatsu Y, Cochet H, Jadidi A, et al. Regional myocardial wall thinning at multidetector computed tomography correlates to arrhythmogenic substrate in postinfarction ventricular tachycardia: assessment of structural and electrical substrate. *Circ Arrhythm Electrophysiol* 2013;6:342-50.
- [43] Andreu D, Penela D, Acosta J, et al. Cardiac magnetic resonance-aided scar dechanneling: Influence on acute and long-term outcomes. *Heart Rhythm* 2017;14:1121-8.
- [44] Spartalis M, Spartalis E, Athanasiou A, Nikiteas N. Safety concerns regarding ablative radiotherapy for ventricular tachycardia. *Radiother Oncol* 2018;128:387.

Figure legends

Figure 1. Target identification. A. Three-dimensional (3D) activation map of the ventricular tachycardia (VT), with the VT morphology on the right. B. Computed tomography (CT) scan of the left ventricle, identifying the wall thickness from 1 mm (dark red) to 5 mm (light yellow); heterogeneity of wall thickness has been correlated to VT isthmus [42]. In this case, the VT was dependent on the most apical channel. Merging of the 3D map and the CT scan allows accurate identification of the target. C. The target has been drawn on the CT scan (white circle); it is also important to study its relationship with the adjacent organ at risk. D. Translation and delineation of the gross/clinical target volume (yellow line), the internal target volume (in pink line) and the planned target volume (blue line) in the radiotherapy scanner with dedicated software.

Figure 2: Proposal for an optimal platform to perform ventricular arrhythmia treatment with stereotactic body radiotherapy (SBRT). CT: computed tomography; MRI: magnetic resonance imaging; Pet: positron emission tomography.

Table 1 Summary of the different studies on stereotactic radiotherapy for ventricular arrhythmia.

	Loo et al. [8]	Cuculich et al. [5]	Jumeau et al. [6]	Neuwirth et al. [9]	Lloyd et al. [7]	Robinson et al. [10]	Gianni et al. [38]
Number of patients	1	5	1	10	10	19	5
Sex	M	4 M; 1 F	M	9 M; 1 F	7 M; 3F	17 M; 2 F	5 M
Age (years)	71	66 ± 10	75	66 (61–78)	62 ± 9	66 (49–81)	63 ± 12
Storm	No	At least two	Yes	Six with storm	-	10/19	-
Type of cardiomyopathy	ICMP	Two ICMP; three NICMP	NICMP	Eight ICMP; two NICMP	Four ICMP; four NICMP; one sarcoidosis; one postmyocarditis	Eleven ICMP; five NICMP; two postmyocarditis; one valvular CMP	Four ICMP; one NICMP
LVEF (%)	24	23 ± 9	30	27 ± 3	?	25 (15–58)	34 ± 15
Technique	Cyberknife® ^a	TrueBeam™ ^b	Cyberknife® ^a	Cyberknife® ^a	TrueBeam™ ^b	TrueBeam™ ^b (<i>n</i> = 3); Edge™ ^b (<i>n</i> = 16)	Cyberknife® ^a
Fiducial marker	Yes; temporary pacing wire placed at the RV apex	No	Yes; RV ICD lead	Yes; RV ICD lead	Yes; RV ICD lead	No	Yes; temporary pacing wire placed in the RV
Dose (Gy)	25 (maximum 33)	25	25	25	25	25	25
Planning target volume (mL)	-	49 ± 23	21	22.2 (14.2–29.6)	81.4 ± 56 (29–238)	98.9 (60.9–298.8)	143 ± 50

Treatment duration (minutes)	90	14 (11–18)	45	68 (45–80)	-	15 (5.4–32.3)	82 ± 11
Delay for efficacy	After month 2	Progressive effect after ablation, but maximum effect after 6 weeks	Immediate	Progressive effect	Within the first 2 weeks	Within the first 6 weeks	Four patients had marked reduction in VT burden during first 6 months
VT free at end of follow-up	VT burden decrease	VT burden decrease	1/1	2/10; VT burden decrease for the others	VT burden decrease in all but one	Decrease in VT burden in 17/19	0
Follow-up (months)	9	12 (median)	4	28 (median)	6 (4–9)	13	12 ± 2
Complications							
Acute	None	None; fatigue in three patients	None	Nausea in four patients	Mild pneumonitis responsive to corticosteroids in two patients	-	None
Delayed	Died from COPD exacerbation at month 9	One fatal stroke 3 weeks after treatment	None	Three died of non-arrhythmic cause; progression of mitral valve		Pericarditis; heart failure exacerbation at 2 months	Two died of heart failure

regurgitation at 17

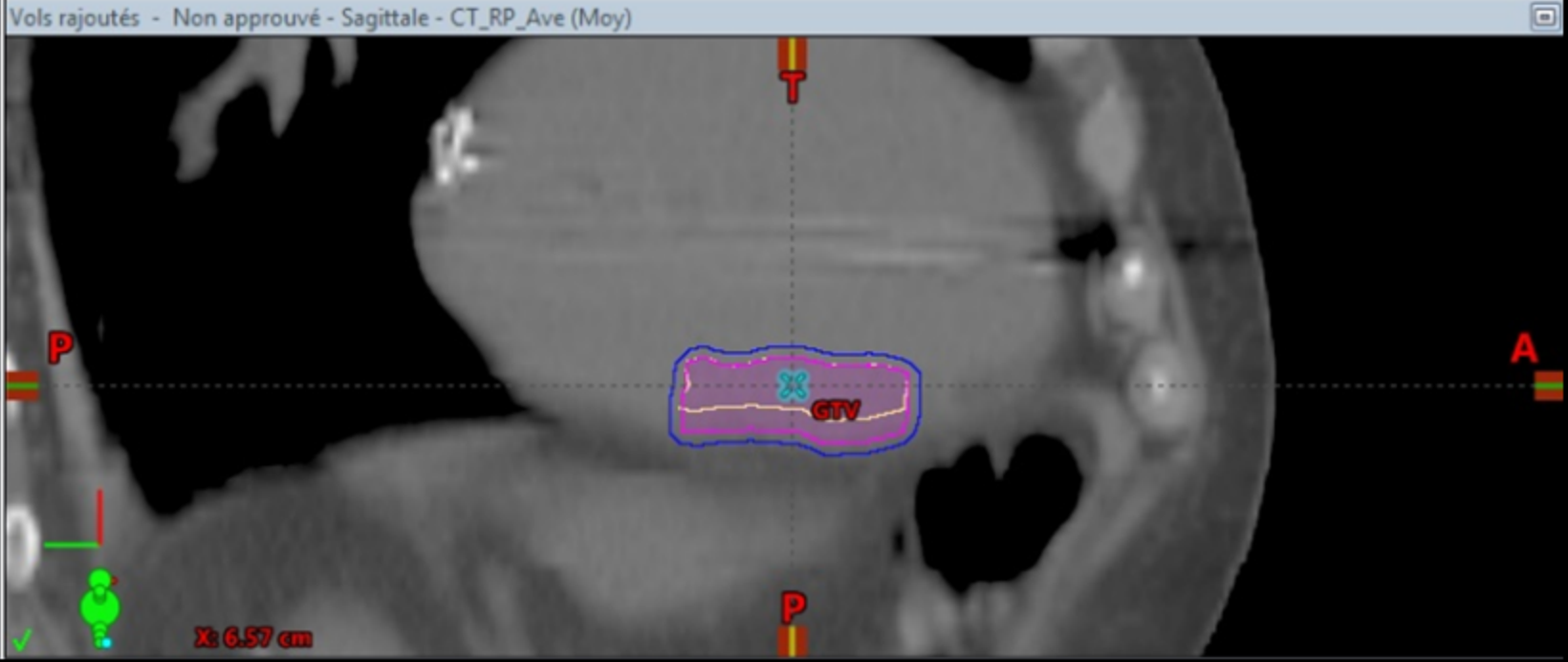
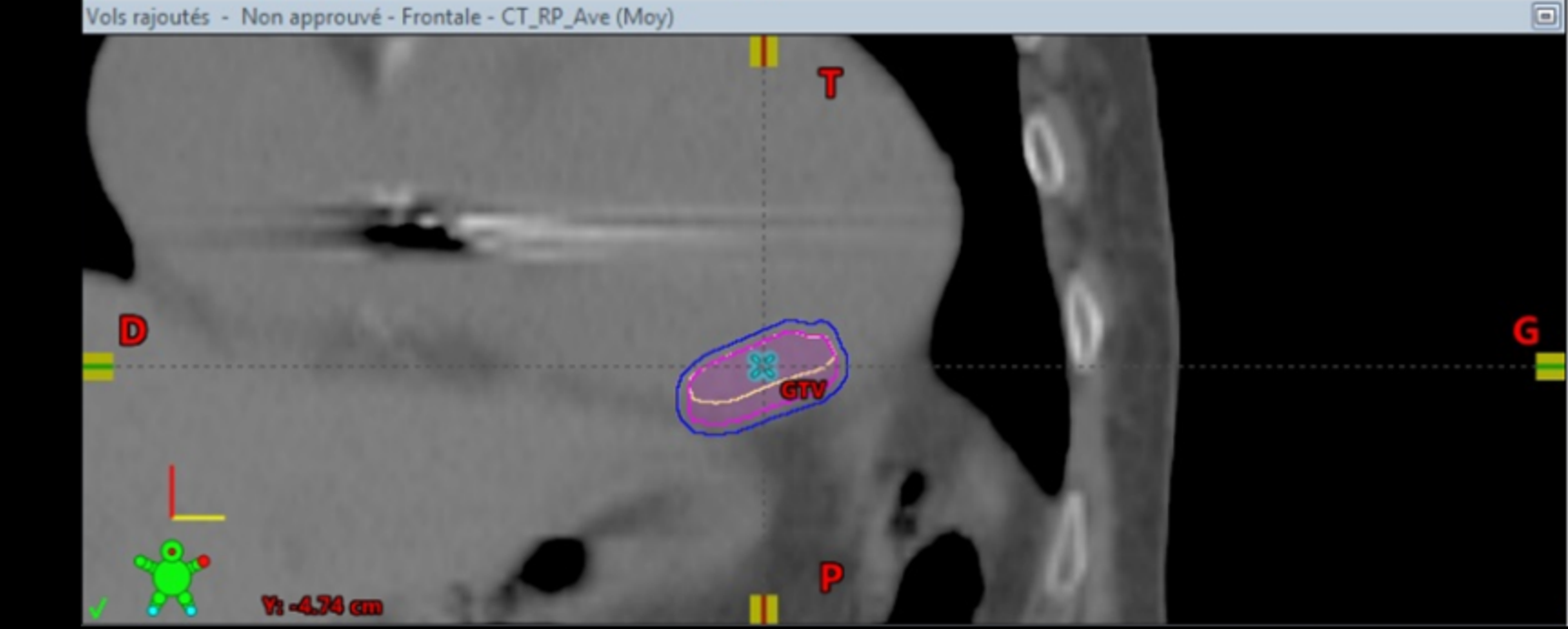
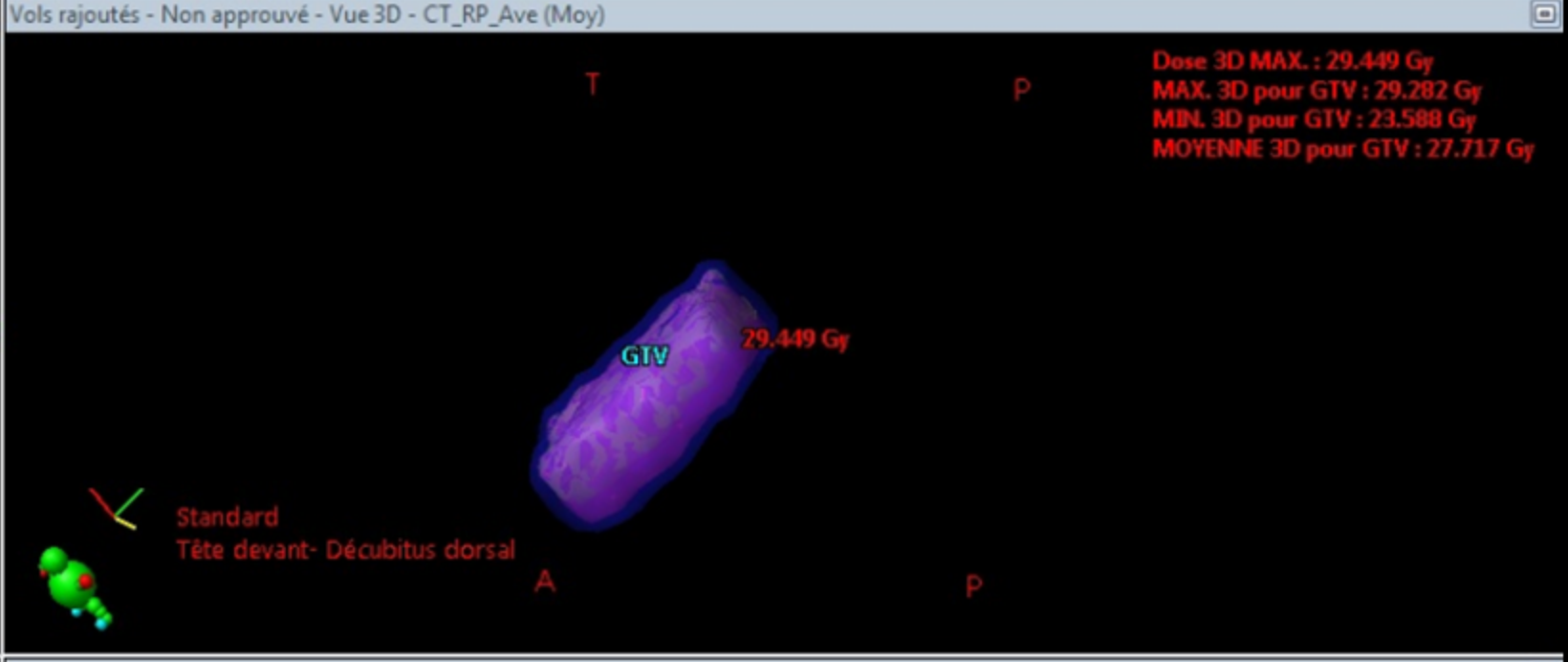
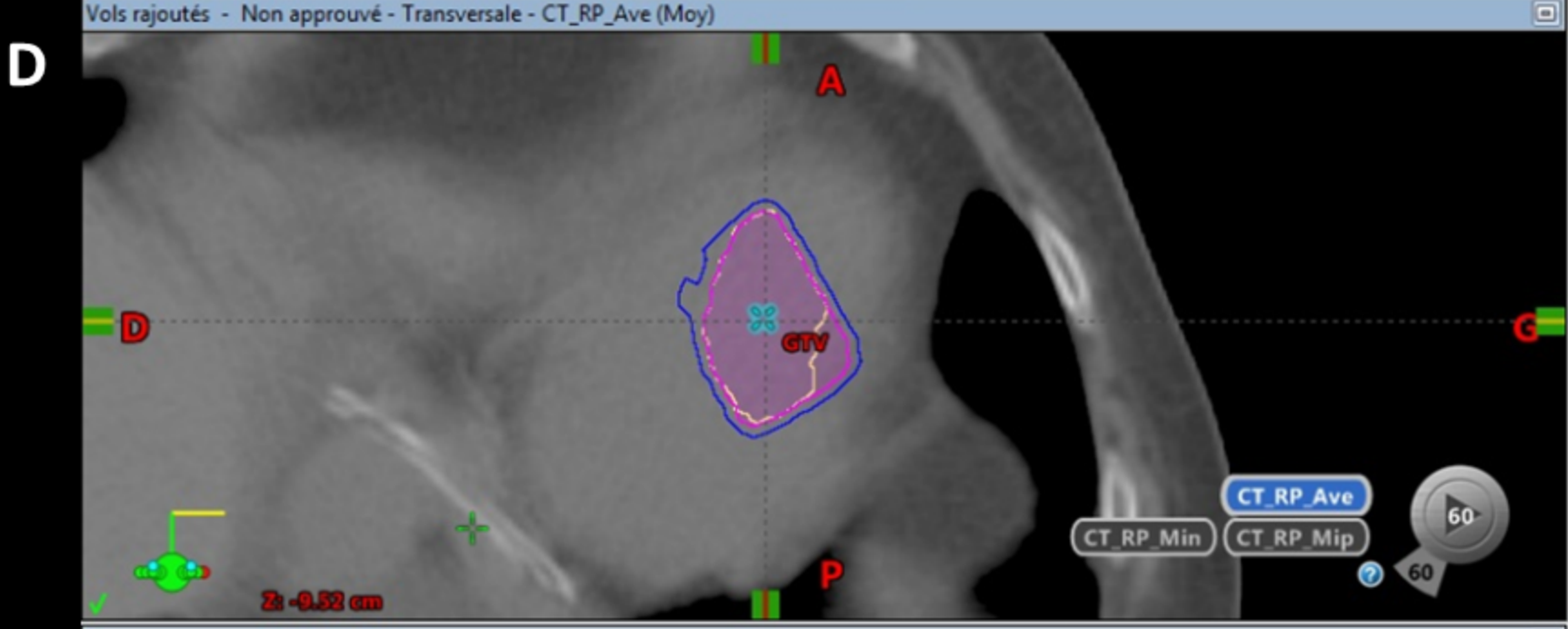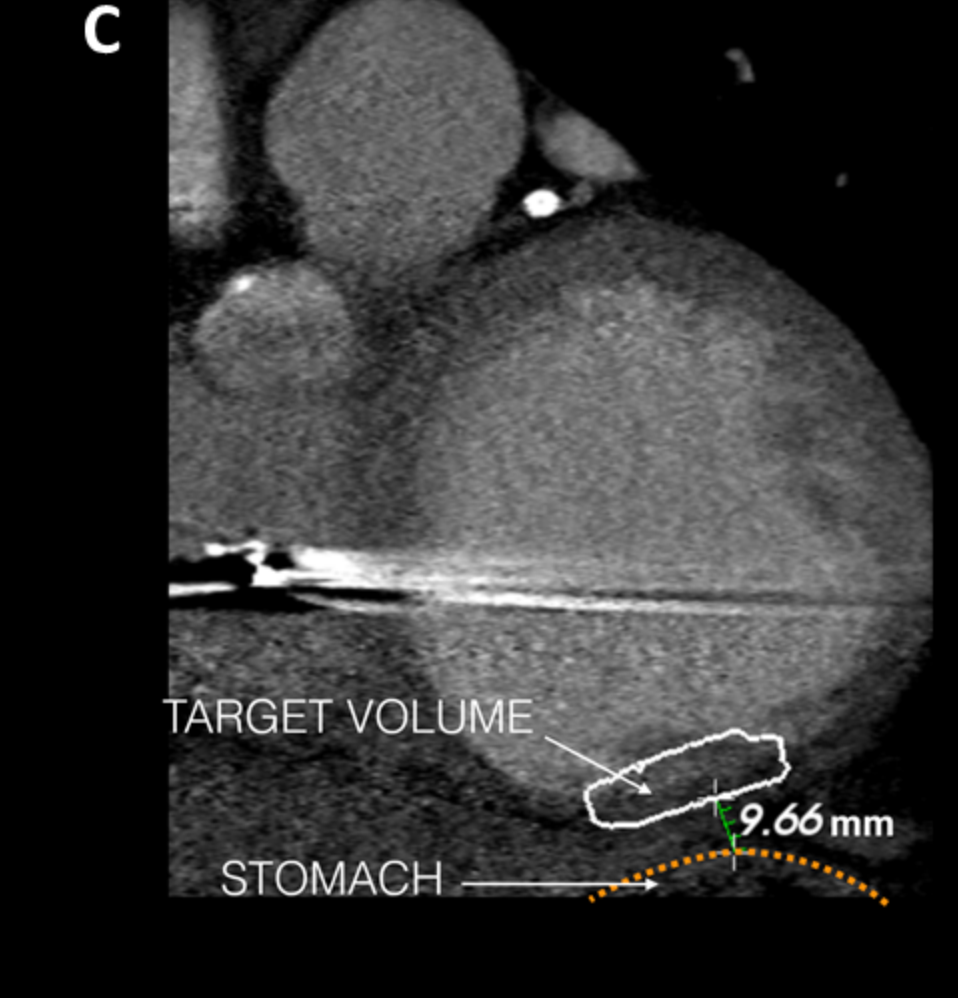
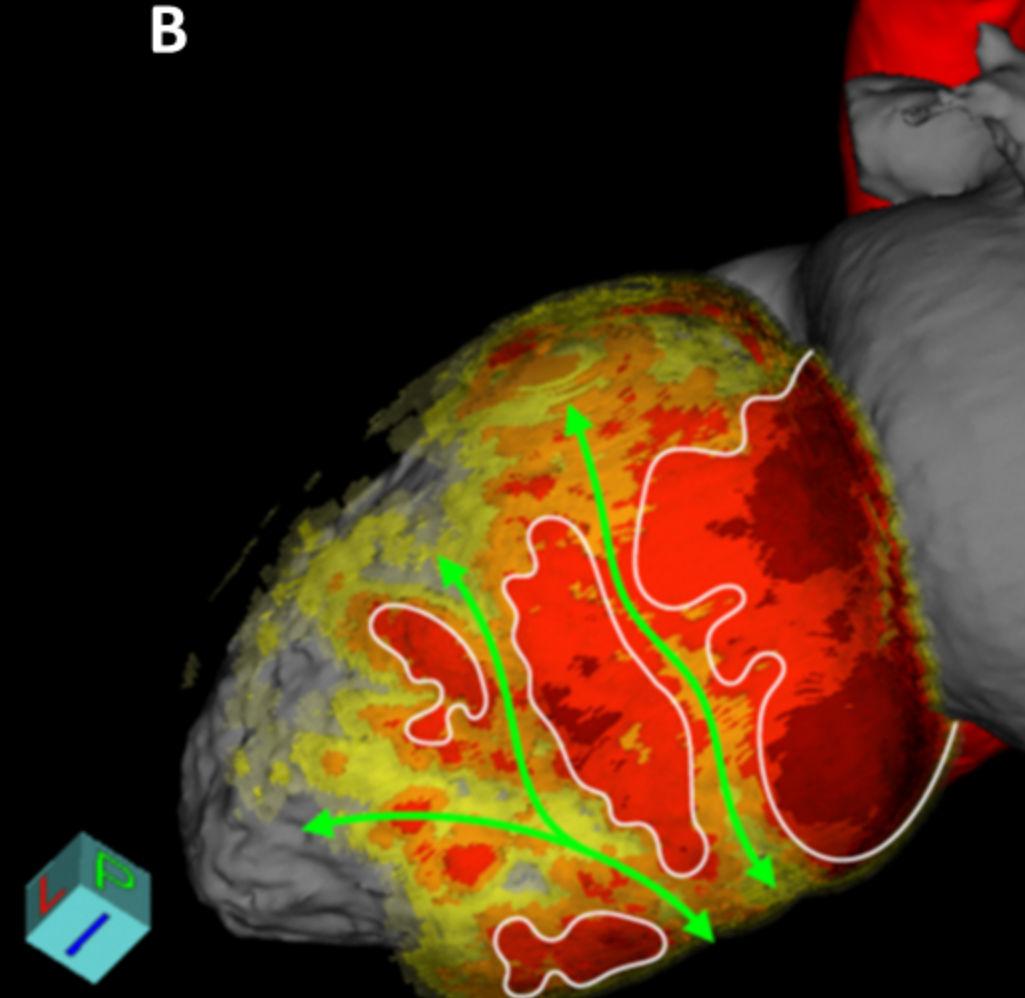
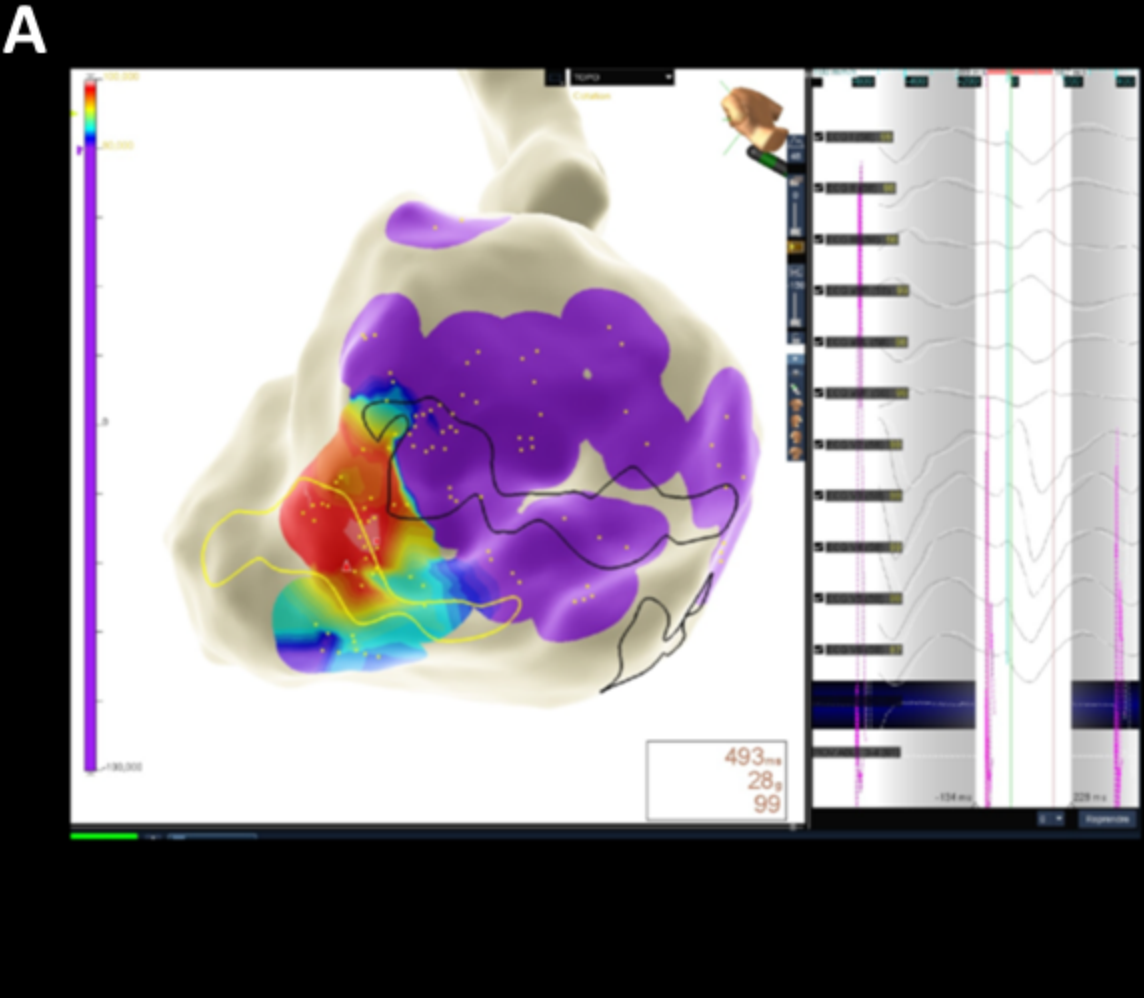
months

Data are expressed as mean \pm standard deviation or median (range) unless otherwise indicated. CMP: cardiomyopathy; F: female; ICD: implantable cardioverter defibrillator; ICMP:


ischaemic cardiomyopathy; LVEF: left ventricular ejection fraction; M: male; NICMP: non-ischaemic cardiomyopathy; RV: right ventricle/ventricular; VT: ventricular tachycardia.

^a Accuracy Incorporated, Sunnyvale, CA, USA.

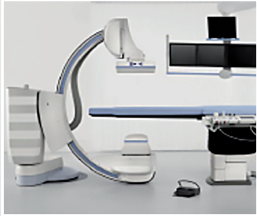
^b Varian Medical Systems, Palo Alto, CA, USA.



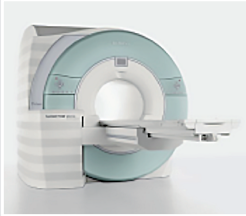
Non-invasive mapping



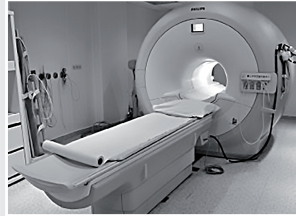Rotational angiography



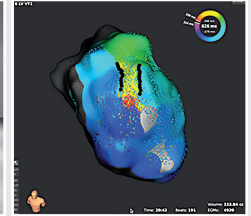
CT-scan



MRI



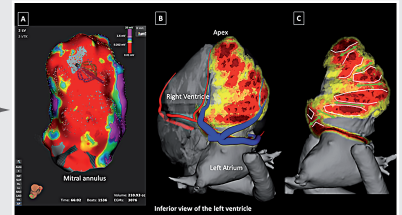
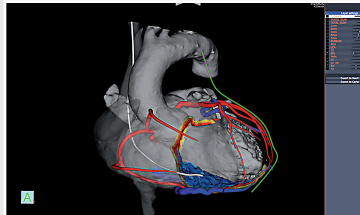
Invasive mapping



- Scintigraphy, PET-scan,
any imaging modality

Ideal platform

- All images integration
- +/- identification of anatomical isthmii
- Target delineation by cardiologist
- Vulnerable structures identification
- Importation in the treating system



Integration and merge in
SBRT system

