



**HAL**  
open science

# A Morphometric Fixed-Bearing Unicompartmental Knee Arthroplasty Can Reproduce Normal Knee Kinematics. An In Vitro Robotic Evaluation

Marc Bandi, Francesco Benazzo, Cécile Batailler, Iris Blatter, Eik Siggelkow, Sébastien Parratte

► **To cite this version:**

Marc Bandi, Francesco Benazzo, Cécile Batailler, Iris Blatter, Eik Siggelkow, et al.. A Morphometric Fixed-Bearing Unicompartmental Knee Arthroplasty Can Reproduce Normal Knee Kinematics. An In Vitro Robotic Evaluation. *Arthroplasty Today*, 2022, 16, pp 151-157. 10.1016/j.artd.2022.02.023 . hal-04001185


**HAL Id: hal-04001185**

**<https://hal.science/hal-04001185v1>**

Submitted on 22 Feb 2023

**HAL** is a multi-disciplinary open access archive for the deposit and dissemination of scientific research documents, whether they are published or not. The documents may come from teaching and research institutions in France or abroad, or from public or private research centers.

L'archive ouverte pluridisciplinaire **HAL**, est destinée au dépôt et à la diffusion de documents scientifiques de niveau recherche, publiés ou non, émanant des établissements d'enseignement et de recherche français ou étrangers, des laboratoires publics ou privés.



## Original research

# A Morphometric Fixed-Bearing Unicompartmental Knee Arthroplasty Can Reproduce Normal Knee Kinematics. An In Vitro Robotic Evaluation

Marc Bandi, MS<sup>a</sup>, Francesco Benazzo, MD, PhD<sup>b, c</sup>, Cécile Batailler, MD, PhD<sup>d</sup>, Iris Blatter, MS<sup>a</sup>, Eik Siggelkow, MS<sup>a</sup>, Sébastien Parratte, MD, PhD<sup>e, f, \*</sup>

<sup>a</sup> Zimmer Biomet, Winterthur, Switzerland

<sup>b</sup> Sezione di Chirurgia Protesica ad Indirizzo Robotico - Unità di Traumatologia dello Sport, U.O. Ortopedia e Traumatologia Fondazione Poliambulanza, Brescia, Italy

<sup>c</sup> Università degli Studi di Pavia, Pavia, Italy

<sup>d</sup> Orthopaedics surgery and Sports Medicine Department, Croix-Rousse Hospital, Lyon University Hospital, Lyon, France

<sup>e</sup> International Knee and Joint Centre, Abu Dhabi, United Arab Emirates

<sup>f</sup> Institute for Locomotion, Aix-Marseille University, Marseille, France

## ARTICLE INFO

## Article history:

Received 5 December 2021

Accepted 15 February 2022

Available online 17 June 2022

## Keywords:

Robotic assessment

Unicompartmental knee arthroplasty

Osteoarthritis

Fixed-bearing

Morphometric implant

Knee kinematic

## ABSTRACT

**Background:** A new morphometric fixed-bearing unicompartmental knee arthroplasty (UKA) system has been introduced to address the anatomical patient-specific challenges. It was our hypothesis that accurate restoration of the patient-specific anatomy would restore normal knee kinematics after UKA. Therefore, we aimed in this cadaveric study to analyze the impact of a medial morphometric UKA on (1) the varus-valgus and anterior-posterior stability of the knee, (2) the knee kinematics during standardized activities of the daily living, and (3) the patellar tracking, measured using a dedicated robotic testing protocol.

**Methods:** Eight human knee specimens underwent full-leg computed tomography CT scanning and comprehensive robotic assessments of tibiofemoral and patellofemoral kinematics. Specimens were tested in the intact state and after implantation of a fixed-bearing medial UKA. Assessments included passive flexion, laxity testing and simulations of level walking, lunge, and stair descent.

**Results:** Medial and lateral joint laxity after UKA closely resembled intact laxity across the full arc of flexion. Anterior-posterior envelope of motion showed a close match between the intact and UKA groups. Net rollback and average laxity were both not statistically different. Simulation of activities of daily living showed a close match in the anterior-posterior motion profile between the medial condyle and lateral condyle. Patellar tilt and medial-lateral shift during knee flexion matched closely between groups.

**Conclusion:** Functional assessment of this UKA system shows nearly identical behavior to the intact knee. Fixed-bearing UKA with morphometric, compartment-specific geometry and precise mechanical instrumentation replicates complex knee balance and kinematics.

© 2022 The Authors. Published by Elsevier Inc. on behalf of The American Association of Hip and Knee Surgeons. This is an open access article under the CC BY-NC-ND license (<http://creativecommons.org/licenses/by-nc-nd/4.0/>).

## Introduction

Unicompartmental knee arthroplasty (UKA) is a proven option for the treatment of unicompartmental knee osteoarthritis and may

offer several clinical benefits over total knee arthroplasty [1–4]. The use of unicompartmental implants has increased in popularity over the last decades due to excellent clinical results as it facilitates minimal invasive surgery, faster recovery, and a higher post-operative knee function. Several studies have reported good joint survival and superior function following UKA, especially in young and very active patients [5–7].

While kinematics similar to a normal knee are expected after UKA due to preserving both cruciate ligaments and maintaining 2

\* Corresponding author. International Knee and Joint Centre, Hazza Bin Zayed Street, Intersection with Fatima Bin Mubarak Street, PO box 46705, Abu Dhabi, United Arab Emirates. Tel.: +33 686 248 043.

E-mail address: [sebparratte@gmail.com](mailto:sebparratte@gmail.com)

compartments, the degree to which UKA is reported to restore normal knee function varies. *In vitro* studies demonstrated theoretical reproduction of normal knee kinematics with close-to-normal knee motion following a medial UKA [8–10]. *In vivo* studies, however, reported contrasting results regarding physiological motion [8–11].

These reports may be attributed to the challenge to properly reconstruct the complex anatomy of the knee in the light of joint degeneration, large physiological variations, and potential limitations in implant and instrument design. When correcting articular deformity during joint replacement surgery, periarticular soft-tissue balancing is important with the goal of restoring full range of motion and stability to the reconstructed joint. When performed improperly, chronic pain due to increased strain on the medial collateral ligament in case of overstuffing, component loosening, and/or progression of osteoarthritis in the preserved compartment may lead to early revision surgery. To date, normal values of laxity of the native knee are still subject of discussion [12]. Furthermore, kinematics in knees with unicompartmental osteoarthritis and intact anterior cruciate ligament differ from healthy knee motion patterns due to pathological changes such as cartilage wear, meniscus degeneration, and osteophytes [13,14]. Lastly, proper joint restoration may be hindered by nonanatomic implants, limited size offerings, or instrumentation that impedes accurate balancing.

Recently, a new morphometric fixed-bearing UKA system has been introduced to address the anatomical patient-specific challenges through anatomic compartment-specific shapes, anatomic articular geometry, broad sizing options, and precise mechanical instrumentation. It was our hypothesis that an accurate restoration of the patient-specific anatomy would restore natural knee kinematics after UKA. Therefore, we aimed in this cadaveric study to analyze the impact of the implantation of a medial morphometric UKA on (1) the varus-valgus and anterior-posterior stability of the knee, (2) the kinematics of the knee during standardized activities of the daily living, and (3) patellar tracking, measured using a dedicated robotic testing protocol.

## Material and methods

In this cadaveric study, 8 fresh-frozen full-leg cadaveric human knee specimens (4 males, 4 females, mean age  $55 \pm 11$  years, mean body mass index  $23 \text{ kg/m}^2 \pm 5$ ) were included. All specimens had functional ligaments but no evidence of bone deformities, previous surgery, or trauma. The study design involved robotic evaluation of the intact knees for stability, activities of daily living, and patellar tracking. After testing the native knees, all specimens were implanted with the same fixed-bearing cemented UKA according to the same standardized previously published technique [15]. The implanted specimens underwent the same robotic testing protocol.

### Specimen preparation


After obtaining full-leg computed tomography (CT) scans, the soft tissue approximately 16 cm below and above the epicondylar axis was removed, and the femur, tibia, and fibula were embedded in aluminum cylinders using polyurethane resin (Neukadur MultiCast 20 hardener ISO 5, Altpropol Kunststoff GmbH, Stockeldorf, Germany). Four aluminum beads were implanted in the patella. All soft tissue around the knee including the skin was preserved. After preparation, a second set of CT scans was obtained. Three-dimensional bone geometries were reconstructed from the full-leg CT scans (Mimics; Materialise, Leuven, Belgium) and served as bases to establish anatomical references. Anatomical coordinate

systems were defined using a modified Grood and Suntay convention [16]. The medial and lateral flexion facet centers (FFCs) [17] were derived from the axis of a cone fitted to the posterior condyles. The femoral joint center was defined as the midpoint between the FFCs. The anatomical references were registered to the robot via the CT scans of the potted specimens. Prior to testing, the specimens were thawed for at least 48 hours and conditioned by manual manipulation.

### Robotic testing

The specimens were reproducibly mounted in a 6 degree-of-freedom KUKA robotic simulator (KR140 comp; Augsburg, Germany—repeatability  $\pm 0.15$  mm) allowing comprehensive, load-controlled assessments of tibiofemoral kinematics (Fig. 1). The setup limit for extension was  $7^\circ$  recurvatum and  $140^\circ$  of flexion. Tibiofemoral assessments included limb alignment in extension, passive flexion, laxity testing, and simulated activities of daily living. Laxity testing was performed at 7 flexion angles ( $0^\circ$ ,  $15^\circ$ ,  $30^\circ$ ,  $45^\circ$ ,  $60^\circ$ ,  $90^\circ$ , and  $120^\circ$ ) and involved loading the knee with 12 Nm in the varus and valgus directions and 100 N in the anterior and posterior directions in combination with a compressive load of 44 N ensuring tibiofemoral contact. Three activities of daily living (lunge, level walking, and stair descent) were simulated by applying *in vivo* flexion profiles in combination with *in vivo* loading profiles in the remaining 5 degrees of freedom. The loading profiles were based on *in vivo* telemetric implant data [18] and were scaled to 35% to avoid specimen damage.

Patellofemoral kinematics were measured during robotic playback of the previously established tibiofemoral kinematics during passive flexion. The quadriceps tendon was loaded (196 N) in the direction of the anterior superior iliac spine via a pulley system. Patellofemoral kinematics were tracked optically (Prime 41, OptiTrack; NaturalPoint, Corvallis, OR) using marker frames attached to the femur and patella registered to the potting cylinders and aluminum beads embedded in the patella.



**Figure 1.** Robotic test setup. The femur is mounted on the pedestal, and the robot applies forces and moments to the tibia via a 6 degree-of-freedom load cell. The quadriceps force is applied via a pulley system. Patella kinematics are tracked optically.

**Table 1**  
Overall alignment and range of motion for the intact state and after medial UKA.

Specimen	Varus/valgus alignment		Extension <sup>b</sup>		Flexion <sup>c</sup>	
	Intact	UKA	Intact	UKA	Intact	UKA
1	0.2° varus	1.1° varus	0°	0°	138°	140°
2	5.7° varus <sup>a</sup>	5.5° varus	0°	3°	137°	125°
3°	1.5° varus	0.3° varus	-6°	-7°	140°	140°
4°	1.3° varus	0.9° varus	-5°	-5°	140°	140°
5°	2.2° valgus	0.8° valgus	3°	-2°	126°	137°
6°	1.0° varus	1.8° varus	-5°	-7°	140°	140°
7°	0.2° valgus	1.4° varus	0°	-4°	117°	127°
8°	0.8° varus	1.2° varus	-6°	-7°	140°	133°
Average	1.0° varus	1.4° varus	-3°	-4°	135°	135°
Std	2.1°	1.7°	3.3°	3.5°	8.1°	5.8°
P	.25		.26		.91	

Values in italics described the values observed during the testing where the setup limits were reached

<sup>a</sup> Extra-articular deformation.

<sup>b</sup> Negative values represent hyperextension; setup limit: -7.

<sup>c</sup> Setup limit: 140.

### Data analysis

Postprocessing and statistical analyses were performed using the software Matlab (R2013b; The MathWorks, Natick, MA). The 6 components of knee motion were computed following the method described by Grood and Suntay [16]. Envelopes of motion were calculated as positive and negative extents of motion in a given degree of freedom throughout flexion [19]. Medial and lateral openings were calculated as range of movement of the medial or lateral FFC in the proximal-distal direction during valgus or varus loading, respectively. Net rollback was calculated as the difference between the centers of the anterior-posterior envelope at 0° and 120° flexion. The similarity of kinematics between the UKA and intact state was expressed by the root mean square of deviations (RMSDs) along the curves. The paired Student’s T-test ( $\alpha = 0.05$ ) was used to detect significant differences between the intact and UKA situation.

### Surgical technique

Prosthetic implantations were performed by 2 experienced knee surgeons (F.B. and S.P.) using a standard technique. Through a medial, minimal invasive subvastus approach with respect to the integrity of the deep and superficial medial collateral ligaments, specimens were implanted with a cemented, fixed-bearing, medial partial knee (Persona Partial Knee; Zimmer Biomet, Warsaw, IN) following previously published techniques for UKA [15]. After implantation and cementation, the capsule, soft-tissue approach, and skin were meticulously closed.

### Results

#### Limb alignment and range of motion

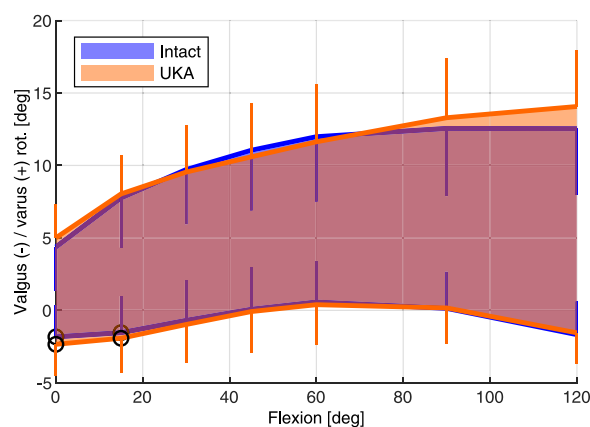
Mean limb alignment before implantation was 1.0° varus, with varus alignment in 6 out of 8 cases (range 0.2° to 5.7°). In one case there was an extra-articular varus deformity (5.7°). In the other 2 cases there was an initial 0.2° and 2.2° valgus alignment. After implantation, an overall varus alignment of 1.4° was seen ( $P = .25$ ). Preimplantation evaluation of the range of motion showed a mean hyperextension of 3° (range -6° to 3° of flexion) and a mean flexion of 135° (range 117° to 140° [setup limit]). After implantation, a mean hyperextension of 4° ( $P = .26$ ) and a mean flexion of 135° ( $P = .91$ ) were found. Specimen-specific data are provided in Table 1.

### Varus-valgus balancing

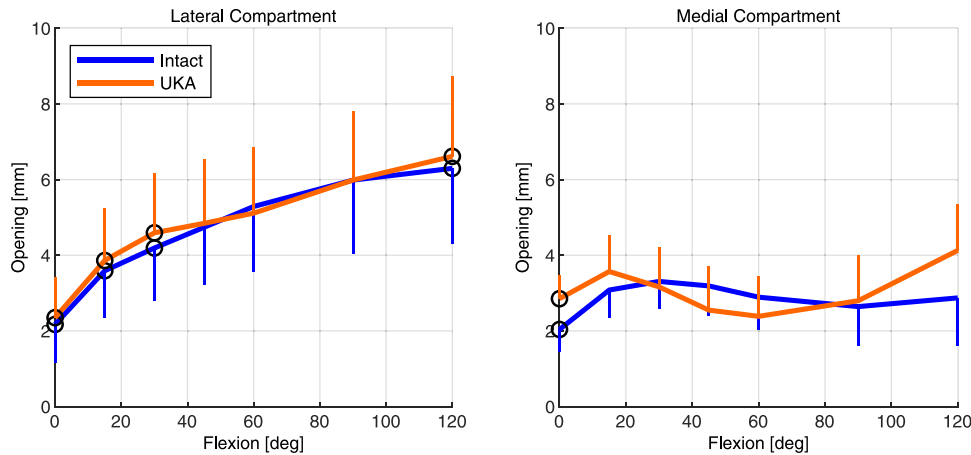
The envelope of varus-valgus motion (Fig. 2) and the medial and lateral openings during the varus-valgus balancing assessment of the UKAs closely resembled the intact measurements across the full arc of flexion. Differences in compartmental openings were below 1 mm and not statistically significant at the majority of flexion angles (Fig. 3, Table 2). The medial opening was nearly constant across flexion, and its average across all flexion angles was not statistically different between the intact ( $2.9 \pm 0.8$  mm) and postimplantation situations ( $3.1 \pm 1.0$  mm) ( $P = .58$ ). The lateral opening increased with knee flexion. The opening was nearly identical between the groups in extension (intact:  $2.2 \pm 1.0$  mm, UKA:  $2.4 \pm 1.1$  mm,  $P = .03$ ) or 90° of flexion (intact:  $6.0 \pm 1.9$  mm, UKA:  $6.0 \pm 1.8$  mm,  $P = .99$ ).

### Anterior-posterior stability

Anterior-posterior envelope of motion assessments revealed a close match between the intact and UKA groups (Fig. 4). Net rollback was not statistically different (intact:  $10.9 \pm 1.5$  mm, UKA:  $10.7 \pm 1.2$ ,  $P = .64$ ). Similarly, average laxity was not statistically different (intact:  $7.7 \pm 3.2$  mm, UKA:  $8.6 \pm 2.5$  mm,  $P = .09$ ). Individual specimen data are reported in Table 3.



**Figure 2.** Average envelope motion for the varus-valgus laxity assessment before and after UKA. Circular markers indicate statistically significant differences. Error bars represent standard deviations and are plotted unilaterally for clarity.



**Figure 3.** Average lateral and medial opening during varus-valgus laxity testing of the intact and UKA groups. Circular markers indicate statistically significant differences. Error bars represent standard deviations and are plotted unilaterally for clarity.

*Lunge, level walking, and stair descent*

Activities of daily living exhibited a close match in the anterior-posterior motion profile of the medial condyle (RMSD: lunge,  $2.2 \pm 1.0$  mm; level walking,  $2.4 \pm 0.9$  mm; stair descent,  $2.2 \pm 0.6$  mm) and lateral condyle (RMSD: lunge,  $2.4 \pm 1.4$  mm; level walking,  $2.2 \pm 1.4$  mm; stair descent,  $2.8 \pm 2.0$  mm). The average curves for the lunge activity are shown in Figure 5. Individual specimen comparisons for all activities are reported in Table 4.

*Patellar tracking*

Patellar medial-lateral tilt (RMSD:  $3.4 \pm 3.8^\circ$ ) and medial-lateral shift (RMSD:  $1.5 \pm 0.6$  mm) during knee flexion matched closely between groups (Fig. 6). Individual specimen comparisons are reported in Table 4.

**Discussion**

Medial UKA aims to restore normal joint kinematics through the preservation of both cruciate ligaments, the lateral compartment, and the patellofemoral joint. Recently, a new morphometric fixed-bearing UKA system has been introduced to address the anatomic patient-specific challenges. It was our hypothesis that a medial morphometric UKA would restore native knee kinematics. Therefore, we aimed at analyzing the impact of the implantation of a

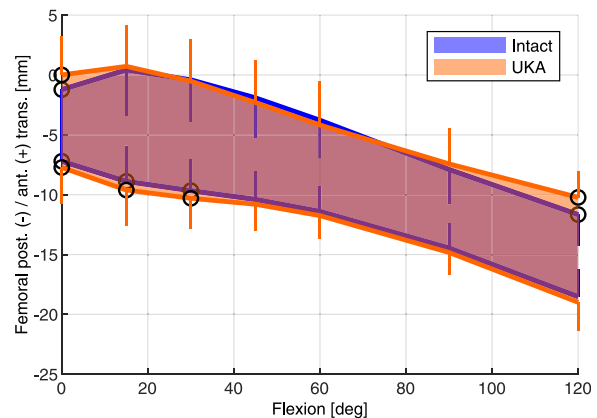
medial morphometric UKA on (1) the varus-valgus and anterior-posterior stability of the knee, (2) the kinematics of the knee during standardized activities of daily living, and (3) the patellar tracking, measured using a dedicated robotic testing protocol.

The results of our study demonstrated a restoration of the preoperative varus-valgus laxity during the full range of motion, with a preservation of the physiological lateral laxity in flexion after implantation of a morphometric fixed-bearing UKA. The exhibited asymmetry in varus-valgus laxity is consistent with a recent meta-analysis of 76 in vitro studies. The meta-analysis revealed substantial asymmetry between the anterior-posterior, varus-valgus, and internal-external laxity dependent on the knee flexion angle [12].

In vivo and in vitro studies assessing the knee kinematics after UKA are contradictory [8–11,20]. Nevertheless, most of these studies reported some level of discrepancy between kinematics after medial UKA and native knee kinematics [9–11,20–22]. The main described difference concerned the varus-valgus movement [23,24]. The varus rotation in flexion was decreased significantly [25,26], with the loss of lateral laxity in flexion [23]. With a morphometric implant, we found restoration of the preoperative varus-valgus movement over the full range of motion, with preservation of the physiological lateral laxity in flexion. Studies about a previous model of this prosthesis described that UKA kinematics

**Table 2**  
Lateral and medial compartmental opening during varus-valgus laxity testing in extension and at 90° of flexion before and after UKA.

Specimen	Lateral opening (mm)				Medial opening (mm)			
	0° flexion		90° flexion		0° flexion		90° flexion	
	Intact	UKA	Intact	UKA	Intact	UKA	Intact	UKA
1	1.3	1.5	7.2	7.3	1.9	2.8	1.7	2.0
2	2.6	3.0	8.6	8.2	2.1	2.4	4.2	3.0
3	3.8	3.8	7.3	6.7	2.5	1.9	3.0	1.8
4	3.3	3.7	7.4	7.6	3.2	3.4	3.9	3.0
5	1.2	1.2	4.6	5.4	1.9	3.3	2.3	4.1
6	1.9	1.9	4.6	3.9	1.4	2.4	1.2	0.7
7	1.0	1.2	2.8	3.1	1.5	3.7	2.5	4.1
8	2.2	2.6	5.4	5.7	1.8	2.9	2.2	3.7
Average	2.2	2.4	6.0	6.0	2.0	2.9	2.6	2.8
Std	1.0	1.1	1.9	1.8	0.6	0.6	1.0	1.2
P	.03		.99		.03		.74	



**Figure 4.** Average envelope of motion of the anterior-posterior laxity assessment before and after UKA. Circular markers indicate statistically significant differences. Error bars represent standard deviations and are plotted unilaterally for clarity.

**Table 3**

A/P laxity averaged over all flexion angles and net rollback between extension and 120° of flexion before and after UKA.

Specimen	Average A/P laxity (mm)		Net rollback (mm)	
	Intact	UKA	Intact	UKA
1	9.6	11.8	10.1	10.1
2	9.6	9.0	11.9	11.2
3	13.4	12.4	12.3	12.2
4	8.8	9.4	10.5	11.4
5	3.9	5.6	12.5	11.0
6	6.4	6.6	7.9	8.4
7	4.4	6.4	11.5	11.7
8	5.8	7.5	10.4	10.1
Average	7.7	8.6	10.9	10.7
Std	3.2	2.5	1.5	1.2
P	.09		.64	

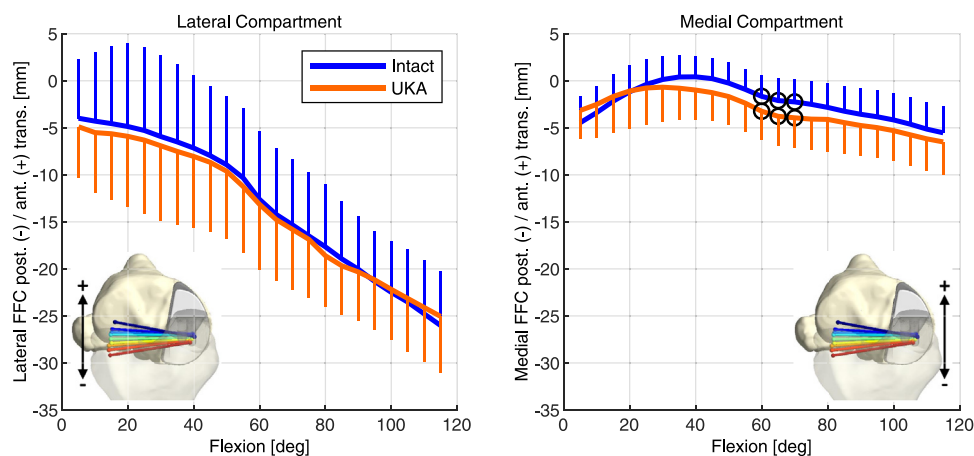
A/P, anterior-posterior.

were similar to those of preoperative arthritic knees but not the same as a normal knee [13,14]. In our study, the assessed knees had no osteoarthritis. Thus, there was no risk of bias in the implant's assessment, as it may be observed in osteoarthritis with stiffness or knee deformity. Moreover, the femoral and tibial anatomy is not strictly similar between the healthy knees and operated knees in the in vivo studies. In addition to a morphometric implant restoring the extension and flexion gaps, the ideal restoration of the joint line level and the preservation of the knee envelope thanks to a very rigorous surgical technique that can explain the satisfying restoration of varus-valgus movement.

The second difference between the healthy knee and the knee after UKA concerned the restoration of the physiological rollback and screw-home mechanism. Although some studies reported that the femoral axial rotation after UKA was close to that of normal knees [9,10,27], the loss of the stabilizing effect of the meniscus can lead to decreased internal tibial rotation and increased posterior translation of the medial femoral condyle for fixed-bearing UKA [13,28,29]. Our study did not find a significant difference in the femoral rollback motion between preoperative and postoperative knees. The advantages of the morphometric implants in the UKA positioning have been described in a previous comparative study [30]. They allow to optimize the rotational-coverage ratio and the femoral fit, avoiding the compromises between size and positioning. A better implant positioning can explain this satisfying restoration of normal knee kinematic.

In cadaver studies, the knee motion after UKA has been described close to normal [8,10], but when performed in vivo, the results were sometimes less obvious [22,25–27]. An in vitro assessment with more complex movements is thus interesting. A cadaveric study assessing 6 knees before and after UKA implantation with a dynamic knee simulator system reported less internal tibial rotation and a more posterior position of the femoral medial condyle during simulation of squatting after UKA [9]. The authors explained this difference by a nonanatomical femoral implant, with a modification of the femoral medial condyle center. This difference of knee kinematics was not demonstrated during passive and open-chain motion for the same 6 cadaveric knees [9]. In our study, the simulation of activities of daily living showed a close match in the anterior-posterior motion profile between the medial condyle and lateral condyle. Our study demonstrated that morphometric medial UKA restored the native knee kinematics even in complex movements, independent of functional characteristics of patients. One of the advantages of cadaveric studies was to avoid bias due to patients' diseases or complaints. In vivo, simple daily activities, such as squatting motion or stair ascent, were assessed by fluoroscopy or gait analysis after UKA. The knee kinematics in vivo after fixed-bearing or mobile-bearing UKA was not completely restored during squatting [13,23] or stair ascent [25]. Moreover, the patients with medial UKA displayed a reduced range of knee flexion compared with the healthy population during daily activities [25,26]. These are muscularly demanding daily functional activities and, therefore, an excellent functional evaluation of UKA. Our study did not report a significant difference in knee range of motion during the lunge, level walking, or stair descent. The extension defect in UKA patients reported in vivo was probably secondary to weaker knee extensor strength on the UKA limb [31]. These muscular alterations are currently not assessable with the robotic simulator. Some studies have described a significant interindividual variation in kinematics following UKA [27,32], which might be partially due to the individual anatomy, functional recovery, as well as surgical and implant-related factors. These data cannot be assessed in vitro and would need a clinical study with this morphometric implant.

Patellar tracking is not assessed in the literature after medial UKA. However, a poor restoration of knee kinematics could impact the patellar tracking or stability [33]. In our study, the patellar medial-lateral tilt and medial-lateral shift during knee flexion matched closely between preoperative and postoperative knees. Close restoration of limb alignment, varus-valgus movement, and



**Figure 5.** Average lateral and medial anterior-posterior FFC motion during simulated lunge activity before and after UKA. Circular markers indicate statistically significant differences. Error bars represent standard deviations and are plotted unilaterally for clarity.

**Table 4**

Comparison of tibiofemoral kinematics for activities of daily living and patellofemoral kinematics for passive flexion between the intact state and after medial UKA.

Specimen	Tibiofemoral						Patellofemoral	
	Lunge		Level walking		Stair descent		Passive flexion	
	RMSD of FFC A/P (mm)		RMSD of FFC A/P (mm)		RMSD of FFC A/P (mm)		RMSD of M/L shift (mm)	RMSD of tilt (deg)
	Lateral	Medial	Lateral	Medial	Lateral	Medial		
1	1.2	1.8	1.7	4.0	1.8	2.6	1.1	0.9
2	4.3	0.9	5.4	2.5	6.9	2.1	2.1	1.4
3	2.3	1.6	2.4	2.4	4.3	2.7	1.9	12.2
4	3.4	3.4	2.6	2.5	3.2	3.1	1.7	0.9
5	0.4	1.1	1.2	1.4	1.6	2.3	1.2	3.1
6	1.7	2.3	1.5	1.6	1.2	1.4	0.6	4.5
7	4.2	3.4	1.0	1.6	1.6	1.7	2.3	1.3
8	1.8	2.9	2.1	3.3	1.6	1.8	1.3	2.7
Average	2.4	2.2	2.2	2.4	2.8	2.2	1.5	3.4
Std	1.4	1.0	1.4	0.9	2.0	0.6	0.6	3.8

A/P, anterior-posterior.

Curve differences are expressed by the RMSD along the curves.

screw-home mechanism allows for obtaining a satisfying patellar tracking in this robotic simulation.

Several limitations should be outlined in our study. First, this study was an *in vitro* cadaveric study. Second, the robotic simulator incorporates the physiological muscle forces of hamstrings and quadriceps only indirectly and in a quasi-static manner when simulating functional activities. Extrapolation of *in vitro* data to the native functional knee remains difficult, causing a potential discordance between *in vitro* test results and *in vivo* findings in the literature. Nevertheless, more complex motions have been assessed with the simulation of daily activities to mimic *in vivo* assessment more closely. An efficient *in vitro* testing model is highly desirable to study the influence of different implant types, sizes, and positions within the same knee as this comparative data cannot easily be achieved via *in vivo* methods. Third, the loads applied to the tibia were not exactly the same as those acting in normal knee during functional activities, and the quadriceps load was constant when assessing patellar tracking. However, the ratio between the load components was maintained, and the conditions were the same before and after UKA implantation, enabling a group comparison that isolates the effect of the surgical intervention. Despite these limitations, our study was to our knowledge the first assessing the restoration of the knee kinematics with a medial morphometric fixed-bearing UKA using an advanced robotic testing apparatus.

## Conclusions

Medial morphometric fixed-bearing UKA accurately restores knee kinematics, similar to a normal knee, as shown in comprehensive robotic *in vitro* assessments.

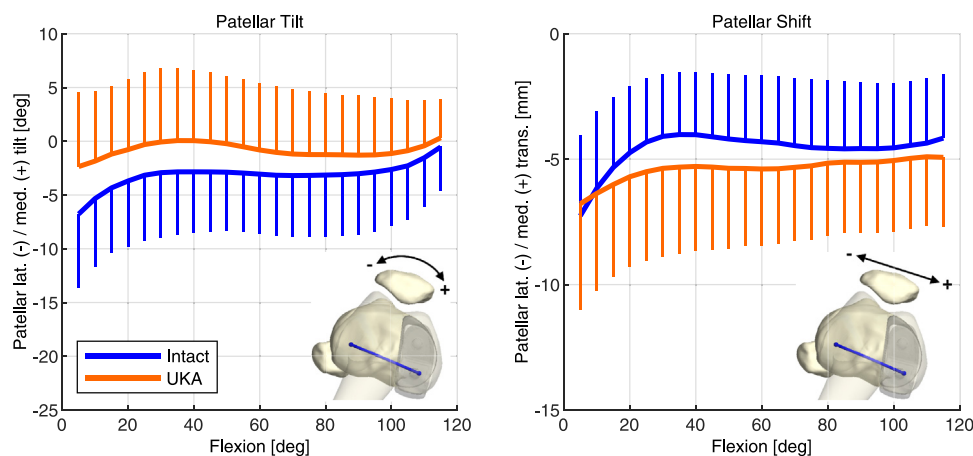
## Funding

The study was funded by ZimmerBiomet.

## Conflicts of interest

The authors declare the following financial interests/personal relationships which may be considered as potential competing interests: M.B. is an employee of Zimmer Biomet and a shareholder of Zimmer Biomet. F.B. is a consultant for Zimmer Biomet and Limacorporate and receives grants from Limacorporate and royalties from Zimmer Biomet and Limacorporate. C.B. receives institutional research support from Lepine and grant from SoFCOT. I.B. is an employee of Zimmer Biomet. E.S. is an employee of Zimmer Biomet. S.P. receives royalties from Zimmer Biomet and Newclip, is a consultant for Zimmer Biomet, and is a treasurer for European Knee Society.

For full disclosure statements refer to <https://doi.org/10.1016/j.artd.2022.02.023>.



**Figure 6.** Average patellar tilt and medial-lateral shift throughout the arc of flexion before and after UKA. No statistically significant differences were found. Error bars represent standard deviations and are plotted unilaterally for clarity.

## Ethical approval

Declaration of clearance was obtained from the ethics commission of the canton of Zurich (Switzerland) before the start of the study (#83-2015).

## References

- [1] Heyse TJ, Khefacha A, Peersman G, Cartier P. Survivorship of UKA in the middle-aged. *Knee* 2012;19:585–91. <https://doi.org/10.1016/j.knee.2011.09.002>.
- [2] Mohammad HR, Strickland L, Hamilton TW, Murray DW. Long-term outcomes of over 8,000 medial Oxford Phase 3 unicompartmental knees—a systematic review. *Acta Orthop* 2018;89:101–7. <https://doi.org/10.1080/17453674.2017.1367577>.
- [3] Courtney PM, Froimson MI, Meneghini RM, Lee GC, Della Valle CJ. Should Medicare remove total knee arthroplasty from its Inpatient only list? A total knee arthroplasty is not a partial knee arthroplasty. *J Arthroplasty* 2018;33(7S):S23–7. <https://doi.org/10.1016/j.arth.2017.11.028>.
- [4] Kim MS, Koh IJ, Choi YJ, Lee JY, In Y. Differences in patient-reported outcomes between unicompartmental and total knee arthroplasties: a propensity score-matched analysis. *J Arthroplasty* 2017;32:1453–9. <https://doi.org/10.1016/j.arth.2016.11.034>.
- [5] Winnock de Grave P, Barbier J, Luyckx T, Ryckaert A, Gunst P, Van den Daelen L. Outcomes of a fixed-bearing, medial, cemented unicompartmental knee arthroplasty design: survival analysis and functional score of 460 cases. *J Arthroplasty* 2018;33:2792–9. <https://doi.org/10.1016/j.arth.2018.04.031>.
- [6] Felts E, Parratte S, Pauly V, Aubaniac JM, Argenson JN. Function and quality of life following medial unicompartmental knee arthroplasty in patients 60 years of age or younger. *Orthop Traumatol Surg Res* 2010;96:861–7. <https://doi.org/10.1016/j.otsr.2010.05.012>.
- [7] Mannan A, Pilling RWD, Mason K, Stirling P, Duffy D, London N. Excellent survival and outcomes with fixed-bearing medial UKA in young patients (<= 60 years) at minimum 10-year follow-up. *Knee Surg Sports Traumatol Arthrosc* 2020;28:3865–70. <https://doi.org/10.1007/s00167-020-05870-4>.
- [8] Becker R, Mauer C, Starke C, et al. Anteroposterior and rotational stability in fixed and mobile bearing unicompartmental knee arthroplasty: a cadaveric study using the robotic force sensor system. *Knee Surg Sports Traumatol Arthrosc* 2013;21(11):2427–32. <https://doi.org/10.1007/s00167-012-2157-5>.
- [9] Heyse TJ, El-Zayat BF, De Corte R, et al. UKA closely preserves natural knee kinematics in vitro. *Knee Surg Sports Traumatol Arthrosc* 2014;22:1902–10. <https://doi.org/10.1007/s00167-013-2752-0>.
- [10] Patil S, Colwell Jr CW, Ezzet KA, D'Lima DD. Can normal knee kinematics be restored with unicompartmental knee replacement? *J Bone Joint Surg Am* 2005;87:332–8. <https://doi.org/10.2106/JBJS.C.01467>.
- [11] Catani F, Benedetti MG, Bianchi L, Marchionni V, Giannini S, Leardini A. Muscle activity around the knee and gait performance in unicompartmental knee arthroplasty patients: a comparative study on fixed- and mobile-bearing designs. *Knee Surg Sports Traumatol Arthrosc* 2012;20:1042–8. <https://doi.org/10.1007/s00167-011-1620-z>.
- [12] Ferle M, Guo R, Hurschler C. The laxity of the native knee: a meta-analysis of in vitro studies. *J Bone Joint Surg Am* 2019;101:1119–31. <https://doi.org/10.2106/JBJS.18.00754>.
- [13] Mochizuki T, Sato T, Blaha JD, et al. Kinematics of the knee after unicompartmental arthroplasty is not the same as normal and is similar to the kinematics of the knee with osteoarthritis. *Knee Surg Sports Traumatol Arthrosc* 2014;22:1911–7. <https://doi.org/10.1007/s00167-013-2767-6>.
- [14] Mochizuki T, Sato T, Tanifuji O, et al. Unicompartmental knee arthroplasty cannot restore the functional flexion axis of a living knee to normal. *Knee Surg Sports Traumatol Arthrosc* 2015;23:3736–42. <https://doi.org/10.1007/s00167-014-3296-7>.
- [15] Argenson JN, Parratte S, Flecher X, Aubaniac JM. Unicompartmental knee arthroplasty: technique through a mini-incision. *Clin Orthop Relat Res* 2007;464:32–6. <https://doi.org/10.1097/BLO.0b013e3180986da7>.
- [16] Grood ES, Suntay WJ. A joint coordinate system for the clinical description of three-dimensional motions: application to the knee. *J Biomech Eng* 1983;105:136–44. <https://doi.org/10.1115/1.3138397>.
- [17] Iwaki H, Pinskerova V, Freeman MA. Tibiofemoral movement 1: the shapes and relative movements of the femur and tibia in the unloaded cadaver knee. *J Bone Joint Surg Br* 2000;82:1189–95. <https://doi.org/10.1302/0301-620x.82b8.10717>.
- [18] Kutzner I, Heinlein B, Graichen F, et al. Loading of the knee joint during activities of daily living measured in vivo in five subjects. *J Biomech* 2010;43:2164–73. <https://doi.org/10.1016/j.jbiomech.2010.03.046>.
- [19] Blankevoort L, Huiskes R, de Lange A. The envelope of passive knee joint motion. *J Biomech* 1988;21:705–20. [https://doi.org/10.1016/0021-9290\(88\)90280-1](https://doi.org/10.1016/0021-9290(88)90280-1).
- [20] Kono K, Inui H, Tomita T, Yamazaki T, Taketomi S, Tanaka S. Bicruciate-retaining total knee arthroplasty reproduces in vivo kinematics of normal knees to a lower extent than unicompartmental knee arthroplasty. *Knee Surg Sports Traumatol Arthrosc* 2020;28:3007–15. <https://doi.org/10.1007/s00167-019-05754-2>.
- [21] Kia M, Warth LC, Lipman JD, et al. Fixed-bearing medial unicompartmental knee arthroplasty restores neither the medial pivoting behavior nor the ligament forces of the intact knee in passive flexion. *J Orthop Res* 2018;36:1868–75. <https://doi.org/10.1002/jor.23838>.
- [22] Mochizuki T, Sato T, Tanifuji O, et al. In vivo pre- and postoperative three-dimensional knee kinematics in unicompartmental knee arthroplasty. *J Orthop Sci* 2013;18:54–60. <https://doi.org/10.1007/s00776-012-0322-9>.
- [23] Kono K, Inui H, Tomita T, et al. In vivo kinematic comparison before and after mobile-bearing unicompartmental knee arthroplasty during high-flexion activities. *Knee* 2020;27:878–83. <https://doi.org/10.1016/j.knee.2020.03.002>.
- [24] Peersman G, Slane J, Vuylsteke P, et al. Kinematics of mobile-bearing unicompartmental knee arthroplasty compared to native: results from an in vitro study. *Arch Orthop Trauma Surg* 2017;137:1557–63. <https://doi.org/10.1007/s00402-017-2794-8>.
- [25] Fu YC, Simpson KJ, Brown C, Kinsey TL, Mahoney OM. Knee moments after unicompartmental knee arthroplasty during stair ascent. *Clin Orthop Relat Res* 2014;472:78–85. <https://doi.org/10.1007/s11999-013-3128-y>.
- [26] Kakar RS, Fu YC, Kinsey TL, Brown CN, Mahoney OM, Simpson KJ. Lower limb kinematics of unicompartmental knee arthroplasty individuals during stair ascent. *J Orthop* 2020;22:173–8. <https://doi.org/10.1016/j.jor.2020.04.009>.
- [27] Argenson JN, Komistek RD, Aubaniac JM, et al. In vivo determination of knee kinematics for subjects implanted with a unicompartmental arthroplasty. *J Arthroplasty* 2002;17:1049–54. <https://doi.org/10.1054/arth.2002.34527>.
- [28] Cassidy KA, Tucker SM, Rajak Y, et al. Kinematics of passive flexion following balanced and overstuffed fixed bearing unicompartmental knee arthroplasty. *Knee* 2015;22:542–6. <https://doi.org/10.1016/j.knee.2015.07.014>.
- [29] Li MG, Yao F, Joss B, Ioppolo J, Nivbrant B, Wood D. Mobile vs. fixed bearing unicompartmental knee arthroplasty: a randomized study on short term clinical outcomes and knee kinematics. *Knee* 2006;13:365–70. <https://doi.org/10.1016/j.knee.2006.05.003>.
- [30] Escudier JC, Jaquet C, Flecher X, Parratte S, Ollivier M, Argenson JN. Better implant positioning and clinical outcomes with a morphometric unicompartmental knee arthroplasty. Results of a retrospective, matched-controlled study. *J Arthroplasty* 2019;34:2903–8. <https://doi.org/10.1016/j.arth.2019.07.031>.
- [31] Kim MK, Yoon JR, Yang SH, Shin YS. Unicompartmental knee arthroplasty fails to completely restore normal gait patterns during level walking. *Knee Surg Sports Traumatol Arthrosc* 2018;26:3280–9. <https://doi.org/10.1007/s00167-018-4863-0>.
- [32] Akizuki S, Mueller JK, Horiuchi H, Matsunaga D, Shibakawa A, Komistek RD. In vivo determination of kinematics for subjects having a Zimmer Unicompartmental High Flex Knee System. *J Arthroplasty* 2009;24:963–71. <https://doi.org/10.1016/j.arth.2008.06.013>.
- [33] McPherson EJ. Patellar tracking in primary total knee arthroplasty. *Instr Course Lect*; 2006. p. 55439–48.