



HAL
open science

Contemporary stroke prevention strategies in 11 096 European patients with atrial fibrillation: a report from the EURObservational Research Programme on Atrial Fibrillation (EORP-AF) Long-Term General Registry

Hubert Delasnerie, Estelle Gandjbakhch, Romain Sauve, Maxime Beneyto, Guillaume Domain, Quentin Voglimacci-Stephanopoli, Franck Mandel, Nicolas Badenco, Xavier Waintraub, Pierre Mondoly, et al.

► To cite this version:

Hubert Delasnerie, Estelle Gandjbakhch, Romain Sauve, Maxime Beneyto, Guillaume Domain, et al.. Contemporary stroke prevention strategies in 11 096 European patients with atrial fibrillation: a report from the EURObservational Research Programme on Atrial Fibrillation (EORP-AF) Long-Term General Registry. EP-Europace, 2018, 20 (5), pp.747-757. 10.1016/j.amjcard.2022.11.042 . hal-04000331

HAL Id: hal-04000331

<https://hal.science/hal-04000331v1>

Submitted on 8 Jan 2025

HAL is a multi-disciplinary open access archive for the deposit and dissemination of scientific research documents, whether they are published or not. The documents may come from teaching and research institutions in France or abroad, or from public or private research centers.

L'archive ouverte pluridisciplinaire **HAL**, est destinée au dépôt et à la diffusion de documents scientifiques de niveau recherche, publiés ou non, émanant des établissements d'enseignement et de recherche français ou étrangers, des laboratoires publics ou privés.



Distributed under a Creative Commons Attribution - NonCommercial 4.0 International License

Correlations Between Endocardial Voltage Mapping, Diagnosis and Genetic in Patients With Arrhythmogenic Right Ventricular Cardiomyopathy

Hubert Delasnerie¹, MD, Estelle Gandjbakhch², MD, PhD, Romain Sauve³, BE, Maxime Beneyto¹, MD, Guillaume Domain¹, MD, Quentin Voglimacci-Stephanopoli¹, MD, Franck Mandel¹, MD, Nicolas Badenco², MD, Xavier Waintraub², MD, Pierre Mondoly¹, MD, Véronique Fressart⁴, MD, Anne Rollin¹, MD, Philippe Maury^{1,5}, MD

1. Cardiology, University Hospital Toulouse, France 2. Sorbonne Universités, AP-HP, Heart Institute, La Pitié-Salpêtrière University Hospital, 75013 Paris, France 3. Biosense, Johnson & Johnson, 92787 Issy-les-Moulineaux, France 4. Service de Biochimie Métabolique, La Pitié-Salpêtrière University Hospital, 75013 Paris, France 5. I2MC, INSERM UMR 1297, Toulouse, France

Address for correspondance:

Dr. Philippe Maury, Cardiology, University Hospital Rangueil, 31059 Toulouse, France

Tel: + 33 (0) 5 61 32 30 54 Fax : + 33 (0) 5 61 32 22 46

e-mail: mauryjphil@hotmail.com

Disclosures : none for any author except R Sauve (employee of Biosense Webster)

Fundings : none

Abstract

The relations between endocardial voltage mapping and genetical background of patients with arrhythmogenic right ventricular cardiomyopathy (ARVC) have not been investigated so far. Ninety-seven patients with proved or suspected ARVC undergoing 3D endocardial mapping and genetical testing have been retrospectively included. Presence, localisation and size of scar areas were correlated to ARVC diagnosis and presence of a pathogenic variant. Seventy-eight patients (80%) presented with some bipolar or unipolar scar on endocardial voltage mapping, while 43 (44%) carried pathogenic variants. Significant associations were observed between presence of endocardial scars on voltage mapping and previous or inducible ventricular tachycardia (VT), right ventricular function and dimensions or ECG features of ARVC. Sixty out of the 78 patients with endocardial scar (77%) fulfilled the criteria for a definitive ARVD diagnosis versus 8 out of 19 patients without scar (42%) ($p=0.003$). Patients with a definitive diagnosis of ARVC had more scars from any location and scars were larger in ARVC patients. In the 68 patients with a definitive diagnosis of ARVC, the presence of any endocardial scar was similar whether an ARVC-causal mutation was present or not. Only scar extend was significantly greater in patients with pathogenic variants. There was no difference in the presence and characteristics of scars when PKP2 mutated vs other mutated patients. 3D endocardial mapping could have an important role for refining ARVC diagnosis and may be able to detect minor forms with otherwise insufficient criteria for diagnosis. Trend for larger scar extends were observed in mutated patients, without difference according to the mutated genes.

Key words: arrhythmogenic right ventricular cardiomyopathy ; voltage mapping ; scar ; genetics

Clinical Competencies

- Eight out of ten patients with a clinical suspicion of arrhythmogenic right ventricular cardiomyopathy (ARVC) present with some bipolar or unipolar scar when endocardial voltage mapping is performed

- Less than 10% of patients with a definitive diagnosis of ARVC did not present with scar on endocardial voltage mapping, and patients with a definitive diagnosis of ARVC had more and larger scars

- Presence of scar is roughly similar whether an ARVC-causal mutation is present or not, without difference according to the mutated genes

Translational Outlook

- Sensitivity and specificity of scars on endocardial voltage mapping for the diagnosis of ARVC should be more widely investigated in the future
- Presence of scar in patients without a clear diagnosis of ARVC should prompt to question about alternative causes of structural right ventricular alterations
- Role of endocardial mapping in patients with incomplete criteria for ARVC may be more deeply investigated

Introduction:

Arrhythmogenic right ventricular cardiomyopathy (ARVC) is an inherited condition leading to the development of fibro-fatty infiltration of the right ventricle (RV), associating right ventricular dilatation, RV scars and segmental wall abnormalities, together with a risk of sudden cardiac death and ventricular tachycardia (VT) (1). A culprit genetic mutation is found in around 50 % of cases. The diagnosis of ARVC is still currently defined by the 2010 Task Force criteria (2). However sensitivity of the Task Force criteria is far from perfect, especially at the earliest stages of the disease (2). Diseased areas in ARVC are classically located in the so-called “ARVC triangle “ associating the basal infero-lateral right ventricle (ILRV), the right ventricular outflow tract (RVOT) and the right ventricular apex (RV) (3,4). 3D voltage mapping is commonly used during catheter ablation for VT in ARVC (5–8). RV scars can be visualized on voltage maps (9, 10) and voltage abnormalities in ARVC are correlated to histological disorders (11), ARVC diagnosis (11, 12) and long-term prognosis (11, 13, 14). To date, a link between genetical background and scar localisation and characteristics in ARVC was only demonstrated for the left ventricle (15) and there is no study focusing on RV scar localisation or size according to the genetical background in ARVC. The aim of this study was to investigate if the genetical background could correlate with scar localisation and size on endocardial voltage mapping, and additionally if voltage mapping may add some useful information for the diagnosis of ARVC.

Methods:

This is a retrospective study performed at the University Hospitals of Toulouse and Paris La Pitié-Salpêtrière, including all successive patients with suspected or proved ARVC who have undergone both endocardial voltage mapping and genetical testing between 2005 and 2020.

Diagnosis of ARVC has been made according to modified Task Force criteria (2). Familial and personal cardiac history, ECG, history of ventricular arrhythmias, signal averaged ECG (SA-ECG), CMR, echocardiography, and pathological datas were retrospectively collected for each patient upon availability. Suspected ARVC was defined by patients incompletely fulfilling the Task Force criteria. Endocardial mapping had been performed in each case and programmed ventricular stimulation and RV angiography in most, since a significant part of the patients were referred for ablation or because it was part of our standard diagnosis setup or screening in any patients with suspected or proved ARVC and especially for any RV scar related VT ablation.

1 All patients have been genotyped at the time of invasive investigation. As
2 for endocardial mapping, genetic screening was part of our standard diagnosis
3 setup or screening in any patients with suspected or proved ARVC. Due to the
4 large period of time for inclusion, not every patient underwent genetic screening
5 using a large panel of genes as currently performed, but main ARVC-related
6 genes had been screened in each case. Only pathogenic or probably pathogenic
7 variants on genes commonly known to be involved in ARVC were considered as
8 a positive result (DSC2, DSG2, DSP, JUP, PKP2, TMEM43, CTNNA3, CDH2,
9 DES, LMNA, PLN, SCN5A, RYR2 and TGFβ3) (1, 16). Pathogenic or probably
10 pathogenic variants were defined by ACMG criteria (17).

11
12 Except for amiodarone, anti-arrhythmic drugs were interrupted prior to the
13 procedure. 3D electro-anatomical systems (Carto Biosense™ or Rhythmia
14 Boston Scientific™) were used for creating complete endocardial RV maps (with
15 or without additional epicardial maps) during sinus rhythm. Navistar™,
16 Smartouch™, Thermocool™ and Intella Nav Mifi™ or multipolar Pentarray™
17 or Orion™ catheters have been used over the years. The peak-to-peak signal
18 amplitude of local bipolar and unipolar electrograms was measured automatically
19 at each point, further confirmed during manual review when needed, and
20 displayed on the 3D computerized anatomical reconstruction of the RV shell
21 according to a standardized colour scale. Maps were obtained during sinus
22 rhythm (premature ventricular beats were excluded).

23 Abnormal bipolar RV endocardial voltage was defined as electrogram
24 amplitude < 1,5 mV for Carto™ (10) or < 0,8 mV for Rhythmia™ (18). For
25 unipolar recordings, abnormal areas were defined by voltage < 5,5 mV (9, 10).
26 Areas with normal voltage were coded in purple. Voltage < 0,5 (Carto™) or < 0,2
27 mV (Rhythmia™) were considered as dense scar and coded in red. Scars were
28 defined as areas of abnormal voltage of at least 1 cm² and including more than
29 one electrogram. Scar perimeters and areas were manually traced and calculated
30 using dedicated 3D mapping system softwares. RV volume and surfaces were
31 automatically calculated by the systems. RV scar extend was defined by the ratio
32 of scar surface over RV surface. For patients referred for ablation, usual substrate
33 mapping (i.e. late potential elimination, dechanneling, scar homogeneization or
34 encircling) as well as activation mapping (transsection of the VT isthmus) was
35 performed.

36 Locations of scars comprised ILRV, RVOT and RVA (3, 4). Particular
37 efforts have been made to achieve good catheter contact in some areas such as
38 ILRV, in order to enhance specificity of low voltage areas, and local electrograms

1 from such areas were accepted in the map only when sufficient contact was
2 expected with a certain degree of confidence. Areas including or immediately
3 neighbouring the expected locations of tricuspid and pulmonary valve annulus
4 were not included in analysis. Scars were also characterized in the same way in
5 the subset of patients undergoing epicardial mapping for ablation purposes.

6 Signed informed consent was obtained from all patients. According to
7 the French ethics and regulatory law, retrospective studies based on the
8 exploitation of usual care data shouldn't be submitted to an ethical committee but
9 have to be covered by reference methodology of the French National Commission
10 for Informatics and Liberties (CNIL). This study completing all the criteria is
11 registered at the Toulouse University Hospital under the n° RnIPH 2022-52 and
12 covered by the MR-004 (CNIL number: 2206723 v 0).

13 Continuous variables are reported as mean \pm standard deviations (SD)
14 and compared with unpaired or paired t-test as suitable. Categorical variables
15 were compared using chi-square test. Analysis and calculations were performed
16 using StatView™ program (Abacus Concepts, Inc. Berkeley, CA 1992-1996,
17 version 5.0). A p value < 0.05 was considered statistically significant.

18 **Results:**

19
20 Ninety-seven successive unrelated patients with suspected or proved
21 ARVC and having undergone both genetical testing and endocardial voltage
22 mapping over a 15 years period at the University Hospital Toulouse and Paris La
23 Pitié were included. Most of them were males (n= 77, 79%) with a mean age of
24 49 ± 15 years old at the time of investigation (47 ± 16 at the time of diagnosis).
25 There was no case of competitive athletes in this population. Main characteristics
26 of the patient population are given in table I.

27 Indications for investigation were palpitations (n=53, 55%), syncope
28 (n=32, 33%), sustained VT (n=59, 61%, mean 2 ± 1 episodes) and cardiac arrest in
29 5 patients.

30 When familial screening had been performed (n=51), 21 patients (41%)
31 had a family history of ARVC. Familial unexplained sudden cardiac death
32 (before 35 years old) was noted in 4 cases.

33 Ninety-two percent (n=89) of the patients were on anti-arrhythmic
34 drugs. Most of them were on beta-blockers (n=62, 64%), while sotalol was
35 prescribed in 24, amiodarone in 9 and flecainide in 16. Twenty-three patients
36 (24%) were implanted with an ICD at the time of investigation.

1 Results of transthoracic echography (TTE) was available in 94 patients
2 (97%), 82 had undergone CMR (85%) (performed before ICD implantation or in
3 patients without ICD), radionuclide imaging was available in 63 (65%), and RV
4 angiography had been performed at the time of the voltage mapping in 66 patients
5 (68%). Mean left ventricular ejection fraction (LVEF) was 58 ± 9 % for TTE,
6 54 ± 10 % for CMR and 61 ± 8 % for radionuclide. Mean RV ejection fraction
7 (RVEF) on CMR was 42 ± 12 % and 41 ± 10 % on radionuclide. At TTE, mean RV
8 surface fractional shortening was 32 ± 12 %. Dilated RV was found in 69% on
9 CMR (i.e. > 90-100 cc/m² according to gender).

10 Sustained monomorphic VT was induced in 44 (48%) of the 91 patients
11 undergoing programmed ventricular stimulation. Fifteen patients (51%)
12 underwent concomitant VT catheter ablation (twelve patients had undergone a
13 previous VT ablation).

14 On the 97 patients, 43 (44%) were considered carriers of pathogenic or
15 probably pathogenic variants: *PKP2* (n=23), *DSG2* (n=9), *DSP* (n=2), *DSC2*
16 (n=1), *RYR2* (n=2), *DES* (n=2), *CTNNA3* (n=1), *DSG2 + PKP2* (n=1), *DSP +*
17 *SCN5A* (n=1) and *PKP2 + DSP* (n=1) (see figure 1 and table II).

18 Sixty-eight patients (70%) fulfilled the Task Force criteria for definitive
19 ARVC diagnosis, with a mean 2 ± 1.3 major criteria and 1.4 ± 0.8 minor criteria.

20 Voltage mapping was done using the Carto™ system in 72 patients and
21 the Rhythmia™ system in 25. Mean RV volume was 224 ± 111 cm³, mean RV
22 surface was 265 ± 72 cm², with a mean acquisition duration of 49 ± 27 min and
23 2146 ± 4272 collected electrograms per map (from 100 to 21389).

24 On the 97 patients, 78 (80%) presented with some bipolar or unipolar
25 endocardial scar on voltage mapping (median 2 scars, 1 to 3). Of the 78 patients
26 with scars, there was only one single scar in 34 (44%) (ILRV in 19, RVOT in 12
27 and RVA in 3), while 44 patients (56%) had multiple scars (20 ILRV+RVOT, 16
28 ILRV+RVOT+RVA, 7 ILRV+RVA and one RVOT+RVA). As a whole, ILRV
29 scars were the most frequent ones (n=62, 45% of the total scar number), followed
30 by RVOT (n=49, 36%) and RV apex (n=27, 19%). There was no case of septal
31 scar. Examples of bipolar and unipolar scars are shown in figure 2.

32 Mean bipolar scar surface was 26.6 ± 29.8 cm² and 44.7 ± 45.2 cm² for
33 unipolar mapping. RV scar extend was 9 ± 10 % for bipolar and 17 ± 15 % for
34 unipolar mapping. Mean scar perimeters were 29 ± 24 cm (bipolar) and 42 ± 32 cm
35 (unipolar). Total scar surfaces (p=0.0003), extends (p<0.0001) and perimeters
36 (p=0.0005) were significantly larger in unipolar versus bipolar voltage mapping.

1 In 66 patients, scars were found on both bipolar and unipolar voltage
2 maps and at the same areas, while in 12 patients some scars in unipolar map did
3 not have corresponding scars on bipolar recordings. Total scar surface ($p=0.01$),
4 extend ($p=0.001$) and perimeter ($p=0.02$) were significantly larger in unipolar
5 versus bipolar voltage mapping for patients with corresponding scars on both
6 bipolar and unipolar mapping.

7 Twenty-seven patients (28%) underwent epicardial voltage mapping at
8 the time of ablation, all of them presenting with epicardial scar, facing some
9 corresponding endocardial scars in all but one cases (purely epicardial scar in the
10 last case). Mean bipolar epicardial scar area was 243 ± 233 cm².

11 Significant associations between presence of endocardial scars on voltage
12 mapping and clinical, ECG and imaging criteria are depicted in table III.
13 Negative T waves in precordial leads, presence of epsilon wave, inducible VT, an
14 history of spontaneous VT and presence of an ICD were each significantly
15 associated with the presence of endocardial scars. Significantly more dilated RV
16 and more altered systolic RV function with lower RVEF and higher RV volumes
17 were also present in the presence of endocardial scars. Even if relatively
18 preserved, LVEF on CMR was significantly lower in case of endocardial RV
19 scars and there was more RV late gadolinium enhancement when endocardial
20 scars were found. AA drug therapy (class 1 drugs) and VT ablation were more
21 often present in patients with endocardial scar. None of these criteria was found
22 to remain significant in multivariate analysis. No other diagnosis criteria was
23 significantly correlated with the presence of endocardial scar.

24 More patients with scars on voltage mapping had some RV LGE (15/49 vs
25 1/15, $p=0.06$). There was a good correlation between locations of RV LGE and
26 scars in 85 % (12 out of 14).

27 When only bipolar scars were analysed, all the parameters remained
28 significant, except negative T waves in precordial leads, epsilon waves, RV >
29 100-110 cc/m² and class 1 drugs.

30 Sixty out of the 78 patients with endocardial scar (77%) fulfilled the
31 criteria for a definitive ARVD diagnosis versus 8 out of 19 patients without scar
32 (42%) ($p=0.003$). Mean major Task Force criteria number was 2.2 ± 1.3 in patients
33 with endocardial scar vs 1 ± 1 in the absence of scar ($p=0.0004$), while there was
34 no difference in minor Task Force criteria (1.4 ± 0.8 vs 1.4 ± 0.8 , $p=ns$). Only 8 out
35 of the 68 patients (12%) with a diagnosis of ARVC according to the Task Force
36 did not present with any endocardial scar on voltage mapping, while 18 out of 29
37 patients (62%) without a diagnosis of ARVC had some scar. Sensitivity,
38 specificity, positive and negative predictive values of an endocardial scar on

1 voltage mapping for the diagnosis of ARVC (based on Task Force criteria) were
2 88%, 38%, 77% and 42% respectively.

3 From the eight patients with a diagnosis of ARVC but without
4 endocardial scar, two had familial ARVC cases, five had pathogenic variants and
5 one displayed a purely epicardial scar. The remaining three cases without these
6 features had 2 major criteria (n=1) or 1 major and 2 minor criteria (n=2). Since,
7 none seemed to evaluate toward more clearer ARVC phenotype.

8 Patients with a definitive diagnosis of ARVC presented significantly
9 more often with ILRV, RVOT and RVA scars or multiple scars (mean 1.7 ± 1 vs
10 0.8 ± 0.7 scar per patient, $p<0.0001$). Scar surfaces, extends and perimeters as well
11 as RV volume were significantly larger in ARVC patients (see table IV). Results
12 were similar when only bipolar scars were analysed.

13 In the 68 patients with a definitive diagnosis of ARVC, the presence of
14 any endocardial scar was similar whether an ARVC-causal mutation was present
15 or not (35/40 vs 25/28, $p=ns$). While there was slightly more ILRV scars in
16 patients carrying a pathogenic genetic variant (34/40 vs 18/28, $p=0.04$), there was
17 no difference for RVOT (24/40 vs 17/28) and RVA scars (12/40 vs 11/28) or for
18 multiple scars (26/35 vs 14/25 patients with scars). Scar surfaces or perimeters
19 were greater in patients carrying a pathogenic genetic variant but without
20 statistical significance, except RV scar extend which was significantly greater in
21 patients with pathogenic variants (bipolar 12 ± 10 vs $6\pm 10\%$, $p=0.02$, and unipolar
22 22 ± 13 vs $12\pm 15\%$, $p=0.01$).

23 When comparing *PKP2* positive ARVC patients (n=23, the most
24 frequent mutated gene (19)) with the other gene carriers (n=17), *PKP2* patients
25 did not have more frequent scars (21/23 vs 14/17) or more frequent ILRV (21/23
26 vs 13/17), RVOT (13/23 vs 11/17) or RVA scars (7/23 vs 5/17) or more multiple
27 scars (15/21 vs 11/14) ($p=ns$). There was no significant difference in RV volume,
28 scar area, extend or perimeter in *PKP2* vs other mutated patients. The three
29 patients with > 1 pathogenic genetic variants presented each with RVOT and
30 ILRV scars, with unremarkable scar surface or perimeter compared to the other
31 ones (no statistical comparison due to the low number of cases).

32 Mean follow-up duration was 80 ± 77 months. Seventeen patients were
33 lost to follow-up. Only one patient died (end-stage right ventricular heart failure).
34 Sustained VT occurred in 10 patients during the follow-up, all of them with a
35 previous history of VT and all but one having undergone ablation at the time of
36 investigation. There was no relapse of VT in the 41 other patients undergoing
37 ablation and no VT in any patient without a previous history of VT. There was no
38 difference in VT recurrence when patient with a definitive diagnosis of ARVC
39 were compared to suspected ARVC.

1 The occurrence of sustained VT during the follow-up was not
2 significantly related to the presence of scar (9 VT out of 78 patients with scars vs
3 one out of 19, p=ns), although the bipolar RV scar extend was significantly
4 greater in patients with recurring VT (17 ± 23 vs 8 ± 7 %, $p=0.03$) % (ns for
5 unipolar).

6 7 **Discussion:**

8 In this study we evaluated the presence, localisation and extend of
9 endocardial scars using electro-anatomical voltage mapping in a population of 97
10 patients with suspected or definitively proved ARVC according to the Task Force
11 criteria. Our findings are as follow:

- 12 - significant associations were present between the presence of endocardial
13 scars and previous or inducible ventricular tachycardia (VT), right ventricular
14 function and dimensions or ECG features of ARVC in the whole population
- 15 - endocardial scars were more often present in patients with a diagnosis of
16 ARVC based on the Task Force Criteria, with a sensitivity of 88%, and scar
17 surfaces, extends and perimeters were significantly larger in ARVC patients
- 18 - apart more frequent ILRV scars and greater RV scar extend in the presence of
19 a pathogenic genetic variant, the presence and characteristics of endocardial
20 scars in ARVC patients were similar, whether a ARVC-causal genetic variant
21 was present or not. There was no scar difference when patients with *PKP2*
22 mutations were compared to others genes.

23
24 The presence of endocardial scars was correlated to negative T waves in
25 precordial leads and epsilon wave, and to dilated RV and altered systolic RV
26 function. This means that RV scars may affect the RV enough to alter ECG and
27 imaging parameters and that scars on endocardial voltage mapping are probably
28 the sign of extended right ventricular structural alterations. Moreover, the
29 presence of endocardial scars was related to spontaneous or inducible VT or
30 presence of ICD, AA drug therapy or VT ablation, which is expected because
31 representing the substrate for reentrant arrhythmia. However, no clear prognosis
32 role of voltage mapping could be drawn from this study.

33 It has been proposed that endocardial voltage mapping may be
34 considered in the prognosis evaluation of ARVC patients (class IIb) (20). Scar-
35 related VTs have a high recurrence rate, both in patients fulfilling or not ARVC
36 diagnosis criteria (13). Occurrence of VT had been linked to the presence of
37 endocardial scars (11) or to bipolar/unipolar low voltage area ratio as a potential
38 surrogate parameter for scar distribution between the endocardium and the
39 epicardium (21). In a previous work on endocardial voltage mapping, the only

1 independent predictor of malignant arrhythmias was the bipolar low-voltage
2 electrogram burden (14). Although we reached similar results in some analysis,
3 comparison was hampered by the low number of VT during follow-up probably
4 because most patients were ablated, thus it is uncertain if voltage mapping may
5 be proposed as a predictive factor in the future, at least in this population.
6 However, VT never occurred in any patient without a previous history of VT (i.e
7 non ablated) whatever the presence of scars or not.

8 The presence of scar significantly and closely correlated with a
9 diagnosis of ARVC according to the Task Force criteria (which do not include
10 voltage mapping). Only 12% of ARVC patients did not have any visible scar on
11 voltage mapping, possibly due to absent, minor or purely epicardial scarring
12 (frusta form of true ARVC still not fulfilling the diagnosis criteria) or explained
13 by the fact that some patients without structural heart diseases had been included
14 (as part of diagnosis purposes), On the other hand, 62% of patients without
15 ARVC diagnosis according to the task Force Criteria had some scar, reflecting
16 either an underdiagnosis according to these criteria, either the presence of a still
17 unidentified other structural heart disease. Pending exclusion of other (unusual)
18 causes for RV scarring, it is tempting to suspect ARVC in these patients.
19 Sensitivity, specificity, positive and negative predictive values of a scar on
20 endocardial voltage mapping for the diagnosis of ARVC were 88%, 38%, 77%
21 and 42% respectively.

22 Patients with a definitive diagnosis of ARVC presented significantly
23 more often with ILRV, RVOT and RVA scars or multiple scars, and scar
24 surfaces, extends and perimeters as well as RV volume were significantly larger
25 in ARVC patients.

26 It was proposed that endocardial voltage mapping may be considered in the
27 diagnosis evaluation of ARVC patients (class IIb) (20). Voltage mapping had
28 been already proposed as an interesting diagnosis tool, since low bipolar voltage
29 areas have been proved to correspond to echocardiographic/angiographic RV wall
30 motion abnormalities, and to correlate with myocyte loss and fibrofatty
31 replacement on biopsy and with an history of familial ARVC (11). Voltage
32 mapping is able to reveal concealed ARVC by detecting RVOT scars that
33 correlate with fibrofatty myocardial replacement at biopsy (22). Right ventricular
34 voltage mapping has been demonstrated to be more sensitive than CMR in
35 detecting right forms of arrhythmogenic ventricular cardiomyopathy (12). Similar
36 findings were observed in this study, with a 88% rate of abnormal endocardial
37 voltage mapping in patients with ARVC, while CMR was indicative of ARVC in
38 only around two thirds of them. Thus, it seems that endocardial voltage mapping
39 currently conveys still better sensitivity for the presence of right ventricular scars
40 than imaging. However, because endocardial voltage mapping is an invasive

1 technique, moreover with a significant risk of inaccurate interpretation of low-
2 voltage recordings due to suboptimal catheter contact in some areas, it is
3 currently not recommended as a routine diagnosis tool (20, 23). Whether invasive
4 voltage mapping could be used in the future for enhancing ARVC diagnosis
5 deserves however further studies.

6 Specific location of scars in the inferior or lateral part of the basal RV
7 is a well-known feature of ARVC (3, 4) and may be used for differential
8 diagnosis with sarcoidosis for example, where inter-ventricular septum is more
9 involved (24, 25). In opposition to previous works (4), this study does not
10 indicate that the “triangle of dysplasia is displaced”, at least in the RV, since
11 apical scars were found in a significant number of cases.

12 Except for more frequent ILRV scars or greater RV scar extends in
13 patients carrying a pathogenic genetic variant, we did not find major relevant
14 differences according to the presence of a genetic variant in ARVC patients when
15 the diagnosis was based on Task Force criteria. This means that pathological
16 processes may be more extended in patients carrying pathogenic genetic variants,
17 possibly because of more aggressive gene-dependant mutations compared to
18 unknown genetical background, or because some patients with scars presented in
19 fact with other and undetermined diagnosis with different consequences and
20 evolution.

21 The link between genetical background and presence, localisation and
22 extend of scars has poorly been investigated so far. Isolated LV scars on CMR
23 were mentioned in two patients with DSP mutations, but there was no further
24 correlation between genetics and scar localisation in this work (4). In a recent
25 work, patients with non-desmosomal mutations had lower LV systolic function
26 with LV fibrosis frequently located at the postero-lateral LV wall, while a LV
27 subepicardial circumferential LGE pattern was significantly associated with
28 desmin mutation (15). For patients with desmosomal mutations, reduced LVEF
29 was more frequent among patients with DSC2/DSG2/DSP than PKP2 mutations,
30 but there was no evaluation of scar localisation in this work (26).

31 We were not able to demonstrate any difference between *PKP2*-carriers
32 and the other gene carriers. Because of the low number of cases, it will remain
33 uncertain if some specific mutations/genes may lead to specific scar localisation
34 or extend, but in view of our results, at least for the right ventricle, similar scarring
35 seems to happen in presence of PKP2 or other pathogenic variants, thus as a final
36 consequence whatever the genetical background.

37 The main limitations of our study were the retrospective design and
38 some possible selection bias: for example, half of the patients underwent voltage
39 mapping at the time of a VT ablation procedure, which had probably selected a

1 subgroup of patients with more advanced pathological process and more scars on
2 endocardial mapping. Conversely, some patients with only suspected ARVC were
3 included, because of additional information expected to be available from voltage
4 mapping, but who do not finally fulfill the diagnosis criteria. However they were
5 found useful in view of our goal and results.

6 Due to the long-time of inclusion, mapping technique has evolved, for
7 example with the advent of contact force catheters, or high definition and multi-
8 point acquisition, thus voltage maps are not uniform and difficult to compare. All
9 patients not investigated with multi electrode-catheters were mapped using force
10 sensing mapping catheters. Thus, patients could be divided in two groups: either
11 investigated with multi-electrode mapping (no contact sensing) either with
12 contact sensing catheter (no multi-electrode mapping). Comparing scar
13 localisations, number and extend/size, scars were not more frequent, but
14 significantly larger in case of multi-electrode mapping/without contact sensing
15 catheter. However, making new statistical analysis in the subgroup of patients
16 with contact sensing catheters did not change the results, thus conclusions remain
17 the same in this population (and then probably also in patients with multi-
18 electrode mapping).

19 A few patients with previous RF ablation have been included: although
20 this may have modify voltage mapping, there was no difference in scar size
21 between patients with and without previous VT ablation, and none of our results
22 were modified when these cases were excluded.

23 Since ARVC is a progressive disease, our results are only valid at the
24 time of investigation. This precludes speculations about the expected changes
25 over time in sensitivity of voltage mapping or relationships with genetical
26 background.

27 Only a few patients underwent epicardial mapping, which fully
28 matched the endocardial mapping in all but one cases. Endocardial mapping has
29 been proposed for the detection of epicardial scars (7, 27) by using unipolar
30 voltage mapping. In view of our study, epicardial scars could be suspected in the
31 vast majority of cases by endocardial voltage mapping. Use of epicardial voltage
32 mapping as a tool for ARVC evaluation cannot be considered anyway because of
33 the risky nature of the technique.

34

35

1 **Conclusion:**

2 Patients with a diagnosis of ARVC according to the Task Force Criteria
3 demonstrate more frequent and larger scars at endocardial voltage mapping.
4 Endocardial voltage mapping could be useful for the diagnosis of ARVC, able to
5 detect minor forms with otherwise insufficient criteria for diagnosis. Presence and
6 characteristics of scars on endocardial voltage mapping do not seem to depend on
7 the genetical background.

8

References:

1
2 1. Gandjbakhch E, Redheuil A, Pousset F, Charron P, Frank R. Clinical
3 Diagnosis, Imaging, and Genetics of Arrhythmogenic Right Ventricular
4 Cardiomyopathy/Dysplasia: JACC State-of-the-Art Review. *J Am Coll Cardiol*
5 2018;72:784–804.

6 2. Marcus FI, McKenna WJ, Sherrill D, Basso C, Bauce B, Bluemke DA,
7 Calkins H, Corrado D, Cox MG, Daubert JP, Fontaine G, Gear K, Hauer R, Nava
8 A, Picard MH, Protonotarios N, Saffitz JE, Sanborn DM, Steinberg JS, Tandri H,
9 Thiene G, Towbin JA, Tsatsopoulou A, Wichter T, Zareba W. Diagnosis of
10 arrhythmogenic right ventricular cardiomyopathy/dysplasia: proposed
11 modification of the task force criteria. *Circulation* 2010;121:1533–1541.

12 3. Marcus FI, Fontaine GH, Guiraudon G, Frank R, Laurenceau JL, Malergue
13 C, Grosogeat Y. Right ventricular dysplasia: a report of 24 adult cases.
14 *Circulation* 1982;65:384–398.

15 4. Te Riele AS, James CA, Philips B, Rastegar N, Bhonsale A, Groeneweg
16 JA, Murray B, Tichnell C, Judge DP, Van Der Heijden JF, Cramer MJ, Velthuis
17 BK, Bluemke DA, Zimmerman SL, Kamel IR, Hauer RN, Calkins H, Tandri H.
18 Mutation-positive arrhythmogenic right ventricular dysplasia/cardiomyopathy:
19 the triangle of dysplasia displaced. *J Cardiovasc Electrophysiol* 2013;24:1311–
20 1320.

21 5. Verma A, Kilicaslan F, Schweikert RA, Tomassoni G, Rossillo A,
22 Marrouche NF, Ozduran V, Wazni OM, Elayi SC, Saenz LC, Minor S,
23 Cummings JE, Burkhardt JD, Hao S, Beheiry S, Tchou PJ, Natale A. Short- and
24 long-term success of substrate-based mapping and ablation of ventricular
25 tachycardia in arrhythmogenic right ventricular dysplasia. *Circulation*
26 2005;111:3209–3216.

27 6. Bai R, Di Biase L, Shivkumar K, Mohanty P, Tung R, Santangeli P, Saenz
28 LC, Vacca M, Verma A, Khaykin Y, Mohanty S, Burkhardt JD, Hongo R,
29 Beheiry S, Dello Russo A, Casella M, Pelargonio G, Santarelli P, Sanchez J,
30 Tondo C, Natale A. Ablation of ventricular arrhythmias in arrhythmogenic right
31 ventricular dysplasia/cardiomyopathy: arrhythmia-free survival after endo-
32 epicardial substrate based mapping and ablation. *Circ Arrhythm Electrophysiol*
33 2011;4:478–485.

34 7. Berruezo A, Fernández-Armenta J, Mont L, Zeljko H, Andreu D, Herczku
35 C, Boussy T, Tolosana JM, Arbelo E, Brugada J. Combined endocardial and
36 epicardial catheter ablation in arrhythmogenic right ventricular dysplasia

1 incorporating scar dechanneling technique. *Circ Arrhythm Electrophysiol*
2 2012;5:111–121.

3 8. Philips B, Madhavan S, James C, Tichnell C, Murray B, Dalal D, Bhonsale
4 A, Nazarian S, Judge DP, Russell SD, Abraham T, Calkins H, Tandri H.
5 Outcomes of catheter ablation of ventricular tachycardia in arrhythmogenic right
6 ventricular dysplasia/cardiomyopathy. *Circ Arrhythm Electrophysiol* 2012;5:499–
7 505.

8 9. Hsia HH, Callans DJ, Marchlinski FE. Characterization of endocardial
9 electrophysiological substrate in patients with nonischemic cardiomyopathy and
10 monomorphic ventricular tachycardia. *Circulation* 2003;108:704–710.

11 10. Marchlinski FE, Zado E, Dixit S, Gerstenfeld E, Callans DJ, Hsia H, Lin
12 D, Nayak H, Russo A, Pulliam W. Electroanatomic substrate and outcome of
13 catheter ablative therapy for ventricular tachycardia in setting of right ventricular
14 cardiomyopathy. *Circulation* 2004;110:2293–2298.

15 11. Corrado D, Basso C, Leoni L, Tokajuk B, Bauce B, Frigo G, Tarantini G,
16 Napodano M, Turrini P, Ramondo A, Daliento L, Nava A, Buja G, Iliceto S,
17 Thiene G. Three-dimensional electroanatomic voltage mapping increases
18 accuracy of diagnosing arrhythmogenic right ventricular
19 cardiomyopathy/dysplasia. *Circulation* 2005;111:3042–3050.

20 12. Marra MP, Leoni L, Bauce B, Corbetti F, Zorzi A, Migliore F, Silvano M,
21 Rigato I, Tona F, Tarantini G, Cacciavillani L, Basso C, Buja G, Thiene G, Iliceto
22 S, Corrado D. Imaging study of ventricular scar in arrhythmogenic right
23 ventricular cardiomyopathy: comparison of 3D standard electroanatomical
24 voltage mapping and contrast-enhanced cardiac magnetic resonance. *Circ*
25 *Arrhythm Electrophysiol* 2012;5:91–100.

26 13. Wijnmaalen AP, SchaliJ MJ, Bootsma M, Kies P, DE Roos A, Putter H,
27 Bax JJ, Zeppenfeld K. Patients with scar-related right ventricular tachycardia:
28 determinants of long-term outcome. *J Cardiovasc Electrophysiol* 2009;20:1119–
29 1127.

30 14. Migliore F, Zorzi A, Silvano M, Bevilacqua M, Leoni L, Marra MP,
31 Elmaghawry M, Brugnaro L, Dal Lin C, Bauce B, Rigato I, Tarantini G, Basso C,
32 Buja G, Thiene G, Iliceto S, Corrado D. Prognostic value of endocardial voltage
33 mapping in patients with arrhythmogenic right ventricular
34 cardiomyopathy/dysplasia. *Circ Arrhythm Electrophysiol* 2013;6:167–176.

35 15. Segura-Rodríguez D, Bermúdez-Jiménez FJ, Carriel V, López-Fernández
36 S, González-Molina M, Oyonarte Ramírez JM, Fernández-Navarro L, García-Roa
37 MD, Cabrerizo EM, Durand-Herrera D, Alaminos M, Campos A, Macías R,

1 Álvarez M, Tercedor L, Jiménez-Jáimez J. Myocardial fibrosis in arrhythmogenic
2 cardiomyopathy: a genotype-phenotype correlation study. *Eur Heart J*
3 *Cardiovasc Imaging* 2020;21:378-386.

4 16. McNally E, MacLeod H, Dellefave-Castillo L. Arrhythmogenic Right
5 Ventricular Cardiomyopathy. In: Adam MP, Ardinger HH, Pagon RA, Wallace
6 SE, Bean LJ, Stephens K, et al., editors. GeneReviews® [Internet]. Seattle (WA):
7 University of Washington, Seattle; 1993-2021

8 17. Richards S, Aziz N, Bale S, Bick D, Das S, Gastier-Foster J, Grody WW,
9 Hegde M, Lyon E, Spector E, Voelkerding K, Rehm HL; ACMG Laboratory
10 Quality Assurance Committee. Standards and Guidelines for the Interpretation of
11 Sequence Variants: A Joint Consensus Recommendation of the American College
12 of Medical Genetics and Genomics and the Association for Molecular Pathology.
13 *Genet Med* 2015;17: 405–424.

14 18. Martin R, Hocini M, Haïsaquerre M, Jaïs P, Sacher F. Ventricular
15 Tachycardia Isthmus Characteristics: Insights from High-density Mapping.
16 *Arrhythmia Electrophysiol Rev* 2019;8:54–59.

17 19. Jacob KA, Noorman M, Cox MGPI, Groeneweg JA, Hauer RNW, van der
18 Heyden MAG. Geographical distribution of plakophilin-2 mutation prevalence in
19 patients with arrhythmogenic cardiomyopathy. *Neth Heart J* 2012;20:234–239.

20 20. Corrado D, Wichter T, Link MS, Hauer R, Marchlinski F, Anastasakis A,
21 Bauce B, Basso C, Brunckhorst C, Tsatsopoulou A, Tandri H, Paul M, Schmied
22 C, Pelliccia A, Duru F, Protonotarios N, Estes NA 3rd, McKenna WJ, Thiene G,
23 Marcus FI, Calkins H. Treatment of arrhythmogenic right ventricular
24 cardiomyopathy/dysplasia: an international task force consensus statement. *Eur*
25 *Heart J* 2015;36:3227–3237.

26 21. Müssigbrodt A, Bertagnolli L, Efimova E, Kosiuk J, Dinov B, Bode K,
27 Kircher S, Dagnes N, Döring M, Richter S, Sommer P, Husser D, Bollmann A,
28 Hindricks G, Arya A. Myocardial voltage ratio in arrhythmogenic right
29 ventricular dysplasia/cardiomyopathy. *Herzschrittmachertherapie*
30 *Elektrophysiologie* 2017;28:219–224.

31 22. Corrado D, Basso C, Leoni L, Tokajuk B, Turrini P, Bauce B, Migliore F,
32 Pavei A, Tarantini G, Napodano M, Ramondo A, Buja G, Iliceto S, Thiene G.
33 Three-dimensional electroanatomical voltage mapping and histologic evaluation
34 of myocardial substrate in right ventricular outflow tract tachycardia. *J Am Coll*
35 *Cardiol* 2008;51:731–739.

36 23. Corrado D, van Tintelen PJ, McKenna WJ, Hauer RNW, Anastastakis A,
37 Asimaki A, Basso C, Bauce B, Brunckhorst C, Bucciarelli-Ducci C, Duru F,

1 Elliott P, Hamilton RM, Haugaa KH, James CA, Judge D, Link MS, Marchlinski
2 FE, Mazzanti A, Mestroni L, Pantazis A, Pelliccia A, Marra MP, Pilichou K,
3 Platonov PGA, Protonotarios A, Rampazzo A, Saffitz JE, Saguner AM, Schmied
4 C, Sharma S, Tandri H, Te Riele ASJM, Thiene G, Tsatsopoulou A, Zareba W,
5 Zorzi A, Wichter T, Marcus FI, Calkins H. Arrhythmogenic right ventricular
6 cardiomyopathy: evaluation of the current diagnostic criteria and differential
7 diagnosis. *Eur Heart J* 2020; 41: 1414–1429

8 24. Philips B, Madhavan S, James CA, te Riele AS, Murray B, Tichnell C,
9 Bhonsale A, Nazarian S, Judge DP, Calkins H, Tandri H, Cheng A.
10 Arrhythmogenic right ventricular dysplasia/cardiomyopathy and cardiac
11 sarcoidosis distinguishing features when the diagnosis is unclear. *Circ Arrhythm*
12 *Electrophysiol* 2014;7: 230-236

13 25. Steckman DA, Schneider PM, Schuller JL, Aleong RG, Nguyen DT,
14 Sinagra G, Vitrella G, Brun F, Cova MA, Pagnan L, Mestroni L, Varosy PD,
15 Sauer WH. Utility of cardiac magnetic resonance imaging to differentiate cardiac
16 sarcoidosis from arrhythmogenic right ventricular cardiomyopathy. *Am J Cardiol*
17 2012;110:575-579

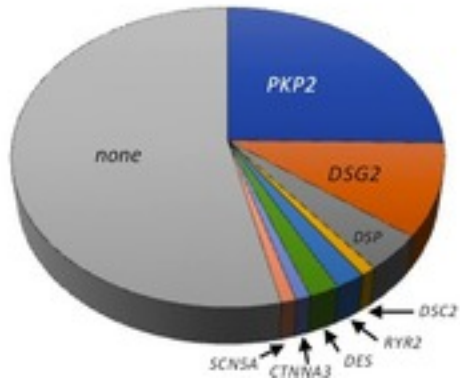
18 26. Christensen AH, Platonov PG, Jensen HK, Chivulescu M, Svensson A,
19 Dahlberg P, Madsen T, Frederiksen TC, Heliö T, Lie ØH, Haugaa KH, Hastrup
20 Svendsen J, Bundgaard H. Genotype-phenotype correlation in arrhythmogenic
21 right ventricular cardiomyopathy-risk of arrhythmias and heart failure. *J Med*
22 *Genet* 2021 doi: 10.1136/jmedgenet-2021-107911.

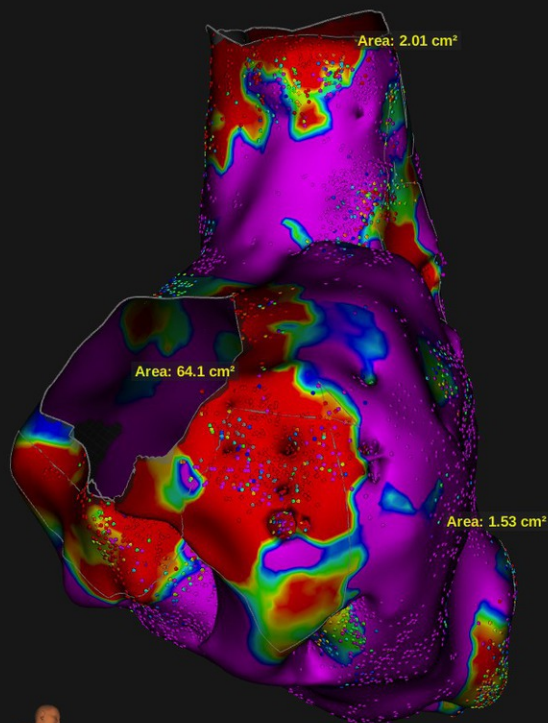
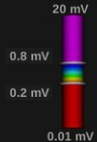
23 27. Polin GM, Haqqani H, Tzou W, Hutchinson MD, Garcia FC, Callans DJ,
24 Zado ES, Marchlinski FE. Endocardial unipolar voltage mapping to identify
25 epicardial substrate in arrhythmogenic right ventricular
26 cardiomyopathy/dysplasia. *Heart Rhythm* 2011;8:76–83

27 Legends to figures

28 **Figure 1** Pathogenic variants in the mutated patients

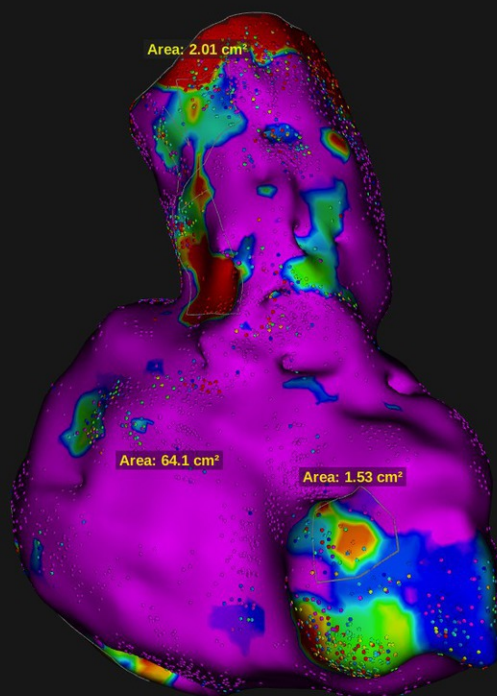
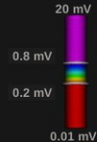
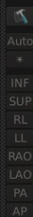
29
30
31 **Figure 2** examples of right infero-lateral, outflow tract and apical scars in bipolar
32 (upper) and unipolar (lower) endocardial mapping (left: right anterior oblique
33 view ; right: left anterior oblique view). Scar areas are depicted. Points can be
34 seen directly on the map (number of points appears as EGM numbers on the low
35 right side of each map).





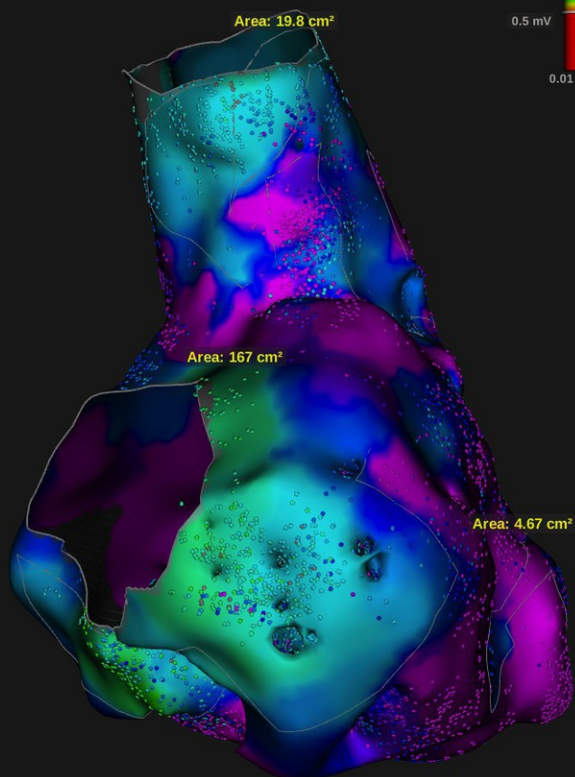
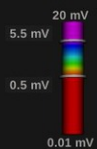
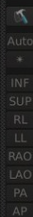
Time: 45:13 Beats: 1191

Volume: 228.63 cc
EGMs: 21389



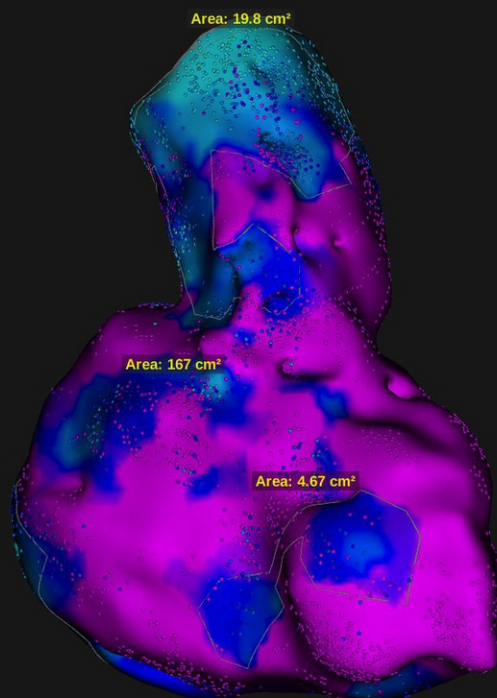
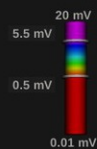
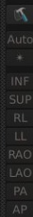
Time: 45:13 Beats: 1191

Volume: 228.63 cc
EGMs: 21389



Time: 45:13 Beats: 1191

Volume: 228.63 cc
EGMs: 21389



Time: 45:13 Beats: 1191

Volume: 228.63 cc
EGMs: 21389

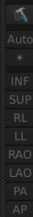


Table I: Characteristics of the study population.

Parameter	Number	Proportion
> 500 PVC / 24 h	45 / 66	68%
Negative T wave in V1-V3 (no right bundle branch block)	37 / 90	41%
Negative T waves in inferior leads	16 / 97	16%
Epsilon wave	17 / 97	18%
Positive SA-ECG (≥ 1 criteria)	45 / 69	65%
RV surface fractional shortening < 33% (TTE)	27 / 79	34%
RVEF < 40% (CMR)	30 / 65	46%
Late RV gadolinium enhancement	19 / 66	29%
Late LV gadolinium enhancement	25 / 71	35%
RV dyskinesia (CMR)	45 / 72	62%
RVEF < 40% (radionuclide)	28 / 60	47%
< 60% cardiomyocytes on biopsy	6 / 36	17%

Table II: Genetic details about the 46 variants found in the 43 mutated patients. Even if some similar variants are found in several patients, these were not related (except one case) and such variants were considered “hot spots” and not private mutations.

gene	Aminoacide change	Nucleotide change	Type of mutation
PKP2	p.Arg143* p.Gly548Calfs*15 splice p.Thr50Serfs*61 p.Leu422Serfs*3 p.Asn74Lysfs*10 p.Asp600Valfs*56 splice p.Tyr857-Lys859 del p.? p.Met110lIefs*11 p.Leu92* p.Gly548Valfs*15 p.Ser837Valfs*94 p.Gly548Valfs*15 p.? splice p.Arg413* p.Gly548Valfs*15 splice p.Ser688Pro p.Ser329Argfs*23 p.Leu30Arg	c.1237C>T c.1643del c.2489+1G>A c.148_151del c.1264_1265del c.219_223+5del c.1799del c.2146-1G>C c.2569-2577+41del c.337_1170+1dup c.329dup c.274T>A c.1643del c.2509del c.1643delG c.2489+1G>A c.1378+1delG c.1237C>T c.1643delG c.223+6T>G c.2062T>C c.987del c.89T>G	nonsense frameshift splicing deletion deletion deletion deletion splicing deletion duplication frameshift nonsense frameshift deletion deletion splicing splicing premature codon stop deletion splicing missense frameshift missense
DSG2	p.Phe214Ser p.Gly812Ser p.Thr804Leufs*4 p.Thr804Leufs*4 insGA2687-2688 splice p.Glu230Glyfs*37 p.? p.Glu278Lysfs*11 splice p.Asp162Valfs*10 c.1892-1898delInsG	c.641T>C c.2334G>A c.2410del c.2410del NA c.690+1G>T c.689_690del c.690+1G>A c.828_828+2delGGT c.523+2T>C c.485del p.Tyr631*	missense missense deletion deletion insertion splicing deletion splicing frameshift splicing frameshift nonsense
DSP	p.Lys1222Serfs*26 p.(Tyr1169*) p.Leu272Pro p.Leu235Pro	c.3665_3672delinsG c.3507C>G c.815T>C c.704T>C	deletion-duplication premature stop codon missense missense
DSC2	p.Phe214Ser	c.641T>C	missense
RYR2	p.Ala2498Val* p.Ala2458Val	NA c.7373C>T	NA missense
DES	p.Ile402Ser	c.1205T>G	missense

	p.Ala63Ser	c.187G>T	missense
CTNNA3	p.Ile880Asnfs*9	c.2638dup	frameshift
SCN5A	p.Thr1304Met	c.3911C>T	missense

Table III: clinical, ECG and imaging characteristics significantly related to the presence of scars on endocardial voltage mapping

Criteria	Endocardial scar (n=78)	No endocardial scar (n=19)	p value
negative T waves V1-V3	33 / 71	4 / 19	0.04
Previous VT	55 / 78	4 / 19	< 0.0001
Epsilon wave	17 / 78	0 / 19	0.02
Previous ICD	22 / 78	1 / 19	0.03
Inducible VT	43 / 73	1 / 18	<0.0001
RVEF < 40% (CMR)	29 / 50	1 / 15	0.0005
RV > 100-110 cc/m ² (CMR)	32 / 53	4 / 15	0.02
RV late gadolinium enhancement	18 / 51	1 / 15	0.03
RVEF (CMR)	41±12 %	51±10 %	0.003
LVEF (CMR)	53±10 %	59±7 %	0.02
AA drug therapy	76 / 78	13 / 19	< 0.0001
Class 1 AA drugs	16 / 78	0 / 19	0.03
Concomitant VT ablation	46 / 78	4 / 19	0.003

Table 4. Characteristics of the scars according to the diagnosis of ARVC based on the 2010 task force criteria

	definite ARVC (n=68)	no definite ARVC (n=29)	p value
ILRV scar	52/68 (76%)	10/29 (34%)	<0.0001
RVOT scar	41/68 (60%)	8/29 (28%)	0.003
RVA scar	23/68 (34%)	4/29 (14%)	0.04
Multiple scars	40/60 with scars (66%)	4/18 with scars (22%)	0.0009
RV volume	241±117 cc	184±84 cc	0.02
Total scar surface (bipolar)	32±32 cm ²	9±11 cm ²	0.004
RV scar extension (bipolar)	11±11 %	3±4 %	0.0037
Total scar perimeter (bipolar)	36±24 cm	12±10 cm	0.0004
Total scar surface (unipolar)	51±47 cm ²	22±30 cm ²	0.03
RV scar extension (unipolar)	20±15 %	7±8 %	0.004
Total scar perimeter (unipolar)	48±30 cm	24±31 cm	0.01