



**HAL**  
open science

# Reporting Criteria for Clinical Trials on Medication-Related Osteonecrosis of the Jaw (MRONJ): A Review and Recommendations

Camille Gaudet, Stephane Odet, Christophe Meyer, Brice Chatelain, Elise Weber, Anne-Laure Parmentier, Stephane Derruau, Sebastien Laurence, Cedric Mauprivez, Esteban Brenet, et al.

## ► To cite this version:

Camille Gaudet, Stephane Odet, Christophe Meyer, Brice Chatelain, Elise Weber, et al.. Reporting Criteria for Clinical Trials on Medication-Related Osteonecrosis of the Jaw (MRONJ): A Review and Recommendations. *Cells*, 2022, 11 (24), <10.3390/cells11244097>. <hal-03998986>

**HAL Id: hal-03998986**

**<https://hal.science/hal-03998986v1>**

Submitted on 21 Feb 2023

HAL is a multi-disciplinary open access archive for the deposit and dissemination of scientific research documents, whether they are published or not. The documents may come from teaching and research institutions in France or abroad, or from public or private research centers.








L'archive ouverte pluridisciplinaire HAL, est destinée au dépôt et à la diffusion de documents scientifiques de niveau recherche, publiés ou non, émanant des établissements d'enseignement et de recherche français ou étrangers, des laboratoires publics ou privés.



Distributed under a Creative Commons CC BY 4.0 - Attribution - International License

Review

# Reporting Criteria for Clinical Trials on Medication-Related Osteonecrosis of the Jaw (MRONJ): A Review and Recommendations

Camille Gaudet<sup>1</sup>, Stephane Odet<sup>1</sup>, Christophe Meyer<sup>1,2</sup>, Brice Chatelain<sup>1</sup>, Elise Weber<sup>1</sup>, Anne-Laure Parmentier<sup>3</sup>, Stéphane Derruau<sup>4,5</sup>, Sébastien Laurence<sup>4,6</sup> , Cédric Mauprivez<sup>4,7,8</sup> , Esteban Brenet<sup>9</sup>, Halima Kerdjoudj<sup>7,8</sup> , Mathilde Fenelon<sup>10,11</sup> , Jean-Christophe Fricain<sup>10,11</sup>, Narcisse Zwetyenga<sup>12</sup>, David Hoarau<sup>12</sup> , Rémi Curien<sup>13</sup>, Eric Gerard<sup>13</sup>, Aurélien Louvrier<sup>1,14</sup>  and Florelle Gindraux<sup>1,2,\*</sup> 

- <sup>1</sup> Service de Chirurgie Maxillo-Faciale, Stomatologie et Odontologie Hospitalière, CHU Besançon, F-25000 Besançon, France
- <sup>2</sup> Laboratoire de Nanomédecine, Imagerie, Thérapeutique EA 4662, Université Bourgogne Franche-Comté, F-25000 Besançon, France
- <sup>3</sup> Unité de Méthodologie, INSERM Centre d'Investigation Clinique 1431, CHU Besançon, F-25000 Besançon, France
- <sup>4</sup> Pôle Médecine Bucco-Dentaire, Hôpital Maison Blanche, CHU Reims, F-51092 Reims, France
- <sup>5</sup> Laboratoire BioSpecT EA-7506, UFR de Pharmacie, Université de Reims Champagne-Ardenne, F-51100 Reims, France
- <sup>6</sup> Biomatériaux et Inflammation en Site Osseux, Pôle Santé, URCA, HERVI EA3801 UFR de Médecine, Université de Reims Champagne Ardenne, F-51100 Reims, France
- <sup>7</sup> Biomatériaux et Inflammation en Site Osseux, Pôle Santé, URCA, BIOS EA 4691, Université de Reims Champagne Ardenne, F-51100 Reims, France
- <sup>8</sup> UFR d'Odontologie, Université de Reims Champagne Ardenne, F-51100 Reims, France
- <sup>9</sup> Service d'ORL et Chirurgie Cervico-Faciale, CHU Reims, F-51092 Reims, France
- <sup>10</sup> CHU Bordeaux, Dentistry and Oral Health Department, F-33404 Bordeaux, France
- <sup>11</sup> INSERM U1026, University of Bordeaux, Tissue Bioengineering (BioTis), F-33076 Bordeaux, France
- <sup>12</sup> Chirurgie Maxillo-Faciale-Stomatologie-Chirurgie Plastique Réparatrice et Esthétique-Chirurgie de La main, CHU Dijon, F-21079 Dijon, France
- <sup>13</sup> Service d'Odontologie, CHR Metz-Thionville, F-57530 Thionville, France
- <sup>14</sup> INSERM, EFS BFC, UMR1098, RIGHT Interactions Greffon-Hôte-Tumeur/Ingénierie Cellulaire et Génique, Université Bourgogne Franche-Comté, F-25000 Besançon, France
- \* Correspondence: fgindraux@chu-besancon.fr



**Citation:** Gaudet, C.; Odet, S.; Meyer, C.; Chatelain, B.; Weber, E.; Parmentier, A.-L.; Derruau, S.; Laurence, S.; Mauprivez, C.; Brenet, E.; et al. Reporting Criteria for Clinical Trials on Medication-Related Osteonecrosis of the Jaw (MRONJ): A Review and Recommendations. *Cells* **2022**, *11*, 4097. <https://doi.org/10.3390/cells11244097>

Academic Editors: Bruce A. Bunnell and Jorge S. Burns

Received: 9 August 2022

Accepted: 12 December 2022

Published: 16 December 2022

**Publisher's Note:** MDPI stays neutral with regard to jurisdictional claims in published maps and institutional affiliations.



**Copyright:** © 2022 by the authors. Licensee MDPI, Basel, Switzerland. This article is an open access article distributed under the terms and conditions of the Creative Commons Attribution (CC BY) license (<https://creativecommons.org/licenses/by/4.0/>).

**Abstract:** Medication-related osteonecrosis of the jaw (MRONJ) is a complication caused by anti-resorptive agents and anti-angiogenesis drugs. Since we wanted to write a protocol for a randomized clinical trial (RCT), we reviewed the literature for the essential information needed to estimate the size of the active patient population and measure the effects of therapeutics. At the same time, we designed a questionnaire intended for clinicians to collect detailed information about their practices. Twelve essential criteria and seven additional items were identified and compiled from 43 selected articles. Some of these criteria were incorporated in the questionnaire coupled with data on clinical practices. Our review found extensive missing data and a lack of consensus. For example, the success rate often combined MRONJ stages, diseases, and drug treatments. The occurrence date and evaluation methods were not harmonized or quantitative enough. The primary and secondary endpoints, failure definition, and date coupled to bone measurements were not well established. This information is critical for writing a RCT protocol. With this review article, we aim to encourage authors to contribute all their findings in the field to bridge the current knowledge gap and provide a stronger database for the coming years.

**Keywords:** osteonecrosis; oral mucosa; bone healing; bisphosphonates; denosumab; anti-angiogenic; tools; consensus

## 1. Introduction

Osteonecrosis of the jaw is a site-specific, osseous pathology that has been reported in the literature since the 19th century. Management of osteonecrosis is based on the disease stage, size of the lesion(s), and the presence of contributing drug therapy and comorbidities [1]. The American Association of Oral and Maxillofacial Surgeons (AAOMS) introduced the term “medication-related osteonecrosis of the jaw” (MRONJ), which includes osteonecrosis caused by both anti-resorptive agents and anti-angiogenesis drugs [2]. Its incidence varies widely from 0.4% to 12% [1,3] and can reach 28% [4]. Further research is needed to refine the epidemiology of these MRONJ estimates [5,6]. These medications inhibit bone remodeling and are used to treat osteoporosis or bone metastases. Their main side effect is osteonecrosis of the jaw due to their direct toxicity on the jaw, whose vascularization differs from other bones.

The literature contains many studies and clinical trials, systematic reviews, and meta-analyses on this topic [7–14]. For example, in 2020, 353 articles were published on PubMed, including 28 meta-analyses and 10 randomized clinical trials (RCTs). Although there are many publications on the management of MRONJ, there is currently no consensus on the ideal treatment protocol [6] or measurable effects of therapeutics. Recent studies show that adverse events still occur, and the incidence rate remains stable despite the harmful consequence of anti-resorptive drugs for patients [15–17].

The effectiveness of the different management methods was evaluated in a systematic review and meta-analysis [18]. Out of 3026 articles identified via the MEDLINE database, only 51 were eligible. Only 13 studies had a medium to high probability of meeting the review’s inclusion criteria, including two with quantitative data. The authors concluded that high quality research is needed for conclusive statements to be made about treatment strategies for MRONJ. In 2020, a systematic review of the literature (30 of 3297 articles were included) concluded that adjuvant surgical therapies for the treatment of MRONJ are beneficial for mucosal healing, but scientific evidence is still lacking [19]. More RCTs are needed to define the most beneficial treatment protocols.

Human amniotic membrane (hAM) has been used for many years to treat various pathologies because of its regenerative, anti-fibrotic, anti-scarring, anti-microbial, anti-inflammatory, and analgesic properties [20]. In addition, it modulates angiogenesis, and induces epithelialization and wound healing [21]. Finally, it has low immunogenicity, which makes it suitable as an allograft.

We have accumulated extensive experience on the use of hAM for bone repair and in oral surgery [22–32]. Recently, we explored its use for managing osteonecrosis [33,34] and conducted a pilot study [35]. To develop an RCT to evaluate hAM effectiveness in MRONJ, we analyzed the literature in detail and selected relevant articles to assist in protocol writing. However, we found a lot of missing and/or inaccurate data. For example, one of the most important—success rate—often combines: (i) stage 1–2 or 3 patients, (ii) cancers and osteoporosis, and (iii) oral and intravenous (iv) treatments. In addition, the date at which healing is evaluated is not standardized and varies from 1 month to 24 months for mucosal closure or bone healing. Moreover, the follow-up may be up to 60 months [36–38]. In the studies, the definition of healing varies between complete wound healing mucosal closure, gingival coverage with no exposed bone, and the absence of bone exposure or osseous lesions. Finally, since hAM has some physical properties that are common with platelet-rich fibrin (PRF), we sought to collect information on its application method.

This review identifies crucial missing data on MRONJ management. It suggests, thanks to a questionnaire, the information that should be included in future publications to facilitate the writing of research protocols, define the size of the active patient population, and allow measurable effects of therapeutics, especially in RCTs.

## 2. Materials and Methods

### 2.1. Focused Questions

The clinical research manager (FG) assisted by the methodologist (ALP) and two surgeons (CG, SO) compiled a list of 12 essential criteria to define the size of the active patient population and identify measurable effects of therapeutics: MRONJ grade classification tool; mucosal defect measurement; number of sites affected and number of sites treated; continuation of MRONJ-inducing drug; PRF application method; primary endpoint, evaluation method, and occurrence date; success rate by MRONJ grade; secondary endpoints, evaluation method, and occurrence date; criterion for defining failure; failure rate and occurrence date; bone re-exposure measurement; imaging tools.

### 2.2. Search Strategy

Literature reviews that were the most cited or considered the most relevant according to the participating clinicians (ChM, BC, EW, SD, SL, CeM, EB, MF, JCF, NZ, DH, RC, EG) were evaluated by the clinical research manager (FG) and two surgeons (CG, SO). Additional, articles were added after manually screening the list of references of all publications selected by the search.

### 2.3. Selection Criteria

Studies published in English and conducted on human subjects were included. Only studies on MRONJ management were considered. Prospective (randomized controlled, nonrandomized controlled, cohort) and retrospective studies (controlled, case-control, single cohort) and case series were included. Studies reporting only MRONJ epidemiology data (and not management of the disease) were excluded.

### 2.4. Screening of Studies and Data Extraction

The article selection and data collection were performed independently by three investigators (CG, SO, FG). An article was evaluated in its entirety if it reported at least 5 of 12 essential criteria.

Discrepancies between the three investigators were discussed to select the final articles. Tables were generated and used to collect the relevant information (Supplementary Materials). Seven additional items were collected at that time: RCT (Yes/No); number of patients; medication; MRONJ grade; number of patients with multiple lesions; which grade of MRONJ was treated; treatment differs by stage (Yes/No).

### 2.5. Elaboration of the Questionnaire

Two surgeons (SO, ChM) assisted by the methodologist (ALP) and the clinical research manager (FG) developed a questionnaire based on the previously listed criteria and important information often missing in the literature and patient medical records.

## 3. Results

Eighteen relevant and highly cited reviews were identified [1,2,6,8,9,12,16,17,39–48]. From these 18 publications, 43 relevant articles were extracted and used in our review (Figure 1).

Data related to the 12 essential criteria and seven additional items are summarized in Tables S1 (part A and B) and S2. The following sections detail the 12 essential criteria (Figure 2a–j).

For the needs of our RCT, the questionnaire mainly focused on AAOMS stage 2 disease (Appendix A).

### 3.1. MRONJ Grade Classification Tool

The majority (39/43) of studies used the AAOMS definition of MRONJ to define the symptoms experienced by patients. Two studies used the Marx classification [37,49] (Table S1 part A). One study reported preoperative symptoms with necrotic bone exposure

of the mandible or maxilla for 12 weeks in patients who had received, or were receiving, either IV or oral bisphosphonate therapy [13]. One study did not mention a classification or define the MRONJ grade [50] (Figure 2a).

### 3.2. Mucosal Defect Measurement

Even if the authors clearly defined the osteonecrosis, studies focused only on the patient’s clinical status at the time of inclusion, without giving specific information on lesion size, for example. Only three studies reported (as part of the primary outcome) the size of mucosal dehiscence, graded by size at the largest diameter or the maximum diameter of exposed bone, and the size before and after MRONJ treatment [45,51,52] (Figure 2b) (Table S1 part A). However, no details about the measurement technique were given.

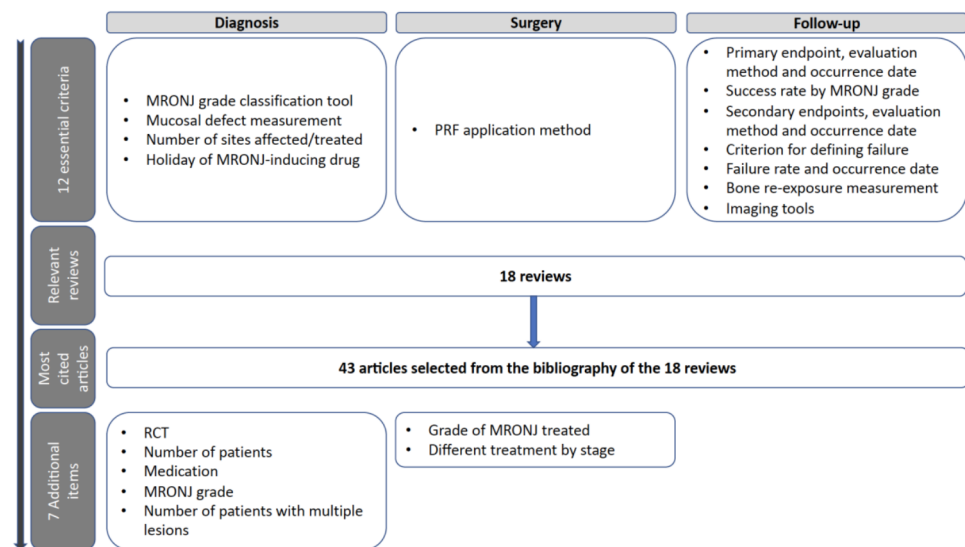


Figure 1. Summary of the curative steps applied to the selected references.

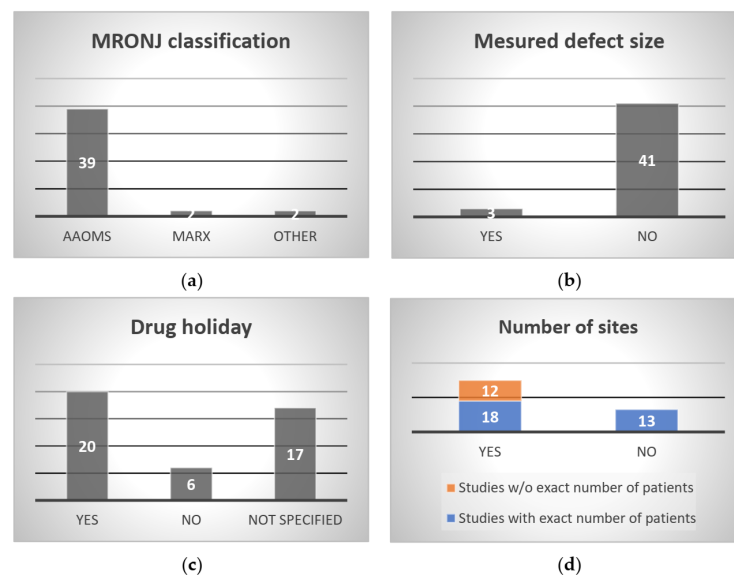
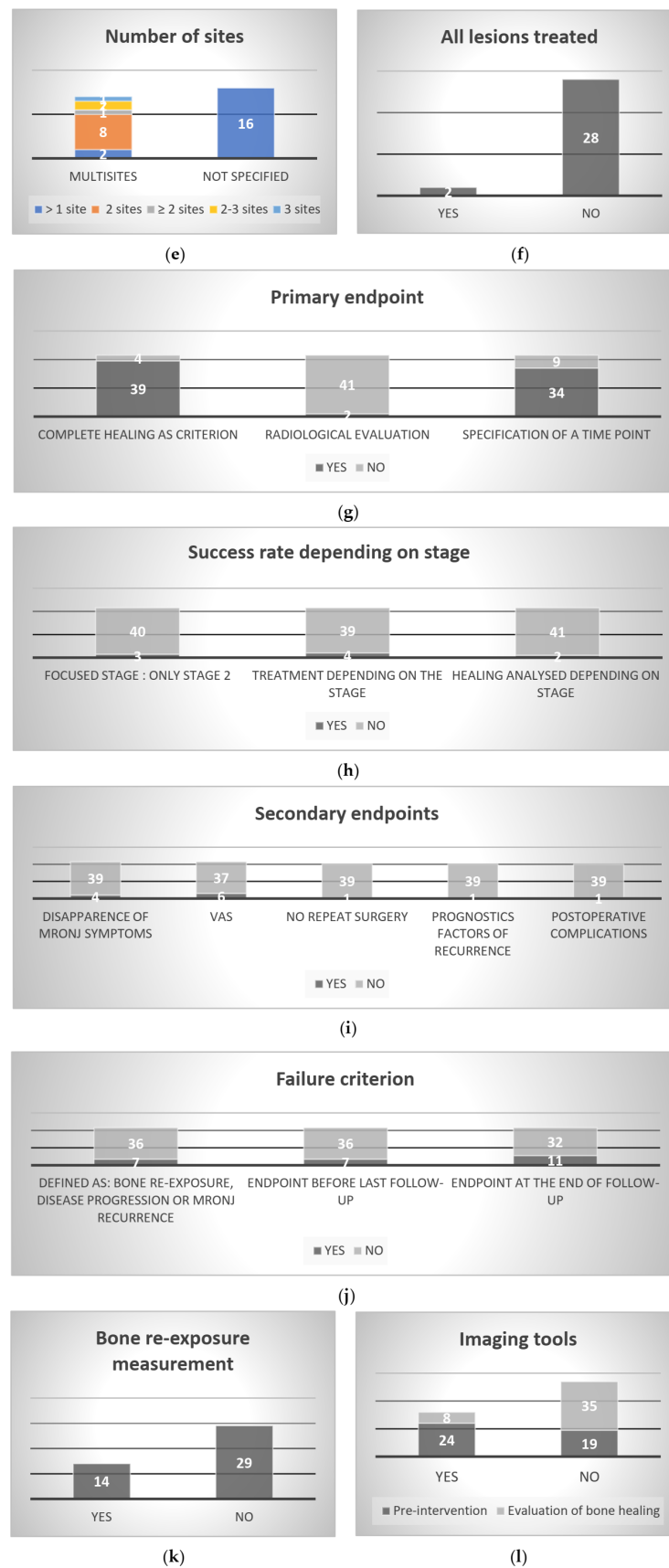


Figure 2. Cont.



**Figure 2.** (a–l): Summary of the 12 essential criteria and associated missing data. AAOMS: Association of Oral and Maxillofacial Surgeons; MRONJ: medication-related osteonecrosis of the jaw; VAS: visual analog scale; w/o: without.

### 3.3. Continuation of MRONJ-Inducing Drug

When a drug holiday was required ( $n = 20$ ), it was performed after consultation with the treating physician or the oncologist to ascertain whether it was possible to suspend BP and/or denosumab while treating the osteonecrosis (Table S1 part A). Therefore, the drug holiday was implemented at different times depending on the study. When specified ( $n = 7$ ), it occurred between a few weeks and a maximum of 3 months before MRONJ treatment or a few weeks to a maximum of 3 months after MRONJ treatment [13,39,51,53–56]. In one study, IV bisphosphonates were discontinued or shifted to oral bisphosphonates [57]. In three studies, the causative drug therapy was not interrupted during the management of osteonecrosis [37,58,59]. No drug holiday was implemented in six studies (Table S1 part A). Seventeen studies did not disclose if patients interrupted their drug therapy (Figure 2c).

### 3.4. Number of Sites Affected and Treated

By coupling the “Number of patients/Number of lesions” and “Number of patients with multiple lesions”, 30 studies reported having patients with multiple lesions although the exact number of patients was not disclosed in 12 of these studies [43,47,53,60–68] (Figure 2e) (Table S2). Thirteen studies did not specify if patients had multisite lesions or not (Figure 2d) (Table S2).

Among the 30 studies, only 14 studies specified the number of osteonecrosis sites, with two sites being most common ( $n = 8$ ) (Figure 2d) (Table S1 part A). Again the exact number of sites was not defined: two studies mentioned “>1 site” [36,38], one study “ $\geq 2$  sites” [56], and two studies “2–3 sites” [69,70]. Only one study reported three sites [71] (Figure 2e).

When patients suffered from multiple lesions, the authors did not specify if all the lesions were treated or not ( $n = 28$ ) (Table S1 part A). Only two studies specified that all lesions were treated [51,57] (Figure 2f).

### 3.5. PRF Application Method

Only five studies used the PRF technique to treat MRONJ [37,39,47,50,72] (Table S1 part A). However, they did not clearly describe the method used to apply the PRF. In all cases, the surgeon performed a hermetic closure at the wound margins to obtain complete primary closure.

### 3.6. Primary Endpoint, Evaluation Method, and Occurrence Date

As in clinical practice, complete healing—usually defined by complete mucosal coverage or absence of bone exposure after the end of the follow-up period—was the primary outcome in most studies ( $n = 39$ ) (Table S1 part B). Healing also integrated a complete epithelialization of the osteonecrosis site in two studies [67,73]. In two studies, the primary outcome was the onset of osteonecrosis recurrence [55,60]. Bedogni et al. also added the 24-month mortality rate [60]. For Fernando et al., the primary outcome was the success of surgical treatment (hard and soft tissue healing at treated site, disappearance of any symptoms) and the occurrence of postsurgical complications [39]. For Freiburger et al., it was the characterization of the oral lesion (size and number), and its potential improvement, stability, or degradation [45] (Figure 2g).

Forty-one studies evaluated the primary outcome clinically, with no objective assessment of complete healing (such as X-ray or CT scan) (Table S1 part B). Only two studies defined healing both clinically and radiologically as the cessation of osteonecrosis extension [49,74] (Figure 2g).

Again, as in clinical practice, in all these studies, the success of mucosal closure was associated with no MRONJ symptoms and no signs of residual infection, fistula, pain, or swelling.

We found no consistency in the date on which the primary outcome was measured. In 15 studies, it varied between 1 month and 24 months (Table S1 part B). In six studies, the primary outcome was evaluated at the last follow-up visit, between 2 and

12 months [43,50,56,57,72,75]. In nine studies, the authors did not specify when the primary outcome was evaluated [13,37,53,55,58,62,67,68,74] (Figure 2g).

### 3.7. Success Rate by MRONJ Grade

Out of 43 studies, only three focused on stage 2 MRONJ, and they reported a success rate of 0% to 100% [39,53,54]. The others combined several stages (Figure 2h) (Table S1 part B).

Four studies applied different osteonecrosis treatments depending on the stage [55,69,76,77] (Figure 2h). In one study, stage 1 and 2 were treated the same way, unlike stage 3 [69]. Therefore, some studies considered the differences in stages, whereas in other studies, the osteonecrosis treatment was similar no matter the stage [36,38,43,62] (Table S1 part B).

Only two studies analyzed the healing rate by stage; they showed that stage 1 or 2 cases have better healing than stage 3 [36,66] (Figure 2h).

### 3.8. Secondary Endpoints, Evaluation Method, and Occurrence Date

In four studies, the authors considered the disappearance of MRONJ symptoms (absence of signs of infection or signs of disease, or mucosal integrity) as secondary outcomes instead of the primary outcome [47,65,67,78] (Table S1 part B). In four others, the amount of pain, evaluated on a visual analogue scale (VAS) was used [36,37,45,47,57,60] (Figure 2i).

Interestingly, for Holzinger et al., the need for repeat surgery was a secondary endpoint [77]. For Mucke et al., the secondary outcome was the identification of important prognostic factors related to MRONJ recurrence such as bone exposure, mucosal defect, or signs of infection [55]. In one study [60], postoperative complications, the duration of hospital stay after surgery, and time to resume oral feeding were considered as secondary outcomes (Figure 2i) (Table S1 part B).

### 3.9. Criterion for Defining Failure

Only seven studies clearly defined the failure criterion, as in clinical practice, as either bone re-exposure, disease progression, or MRONJ recurrence [38,54,56,61,63,72,75] (Figure 2j) (Table S1 part B).

For Nisi and al., re-operation corresponded to failure [38]. Interestingly, for Bodem et al., surgical treatment was unsuccessful if there was no improvement in MRONJ stage [63].

In the other studies, the authors did not specifically report their failure criterion but considered all the patients who did not meet the primary endpoint as failures (Table S1 part B).

### 3.10. Failure Rate and Occurrence Date

Again, as in clinical practice, failure depended on several criteria such as (i) the treatment indication for malignant disease or osteoporosis [62,69], (ii) the bisphosphonate protocol (dosage, frequency, etc.) [13,74], (iii) the use of a surgical treatment [54], and (iv) the use of additional therapy such as PRF [50]. In general, the rate depended on the treatment choice. For example, the failure rate was 100% in the non-PRF group compared to the PRF group [50].

The failure rate was still not properly defined in the studies, and only 27 studies reported or calculated an approximative rate (Table S1 part B). Only two articles reported the healing rate [46,62].

In our review, we found that the time point for evaluating secondary endpoints was not harmonized and occurred before ( $n = 7$ ) [47,60,65,66,76,78,79] or at the end of follow-up ( $n = 11$ ) [43,50,51,54,56,57,63,66,72,75,76] (Figure 2j) (Table S1 part B).

### 3.11. Bone Re-Exposure Measurement

In cases of bone re-exposure, the authors did not measure it and only specified whether it occurred ( $n = 14$ ) [13,37,38,47,56,58,60,62,65,66,70,75,76,80] or not (Figure 2k) (Table S1 part B).

### 3.12. Imaging Tools

Approximately half the studies ( $n = 24$ ) used radiological examinations—orthopantomography (OPT), computed tomography (CT) scan, and cone beam computed tomography (CBCT)—to support the clinical diagnosis and to determine the size/extension of the lesion (Figure 2I) (Table S1 part B).

One study performed additional investigations such as magnetic resonance imaging (MRI) or bone scintigraphy of the affected region as needed [75]. One study used a positron emission tomography (PET) scan to identify bony sequestrum and determine the surgical strategy [64]. Interestingly, four studies described using a fluorescence-guided surgery technique with the VELscope system [43,59,65,75,78,81].

In eight studies, radiological examinations supplemented the evaluation of bone healing but were not used as the primary outcome, which was mucosal healing [37–39,55,57,60,68,70] (Figure 2I) (Table S1 part B).

### 3.13. Seven Additional Items

Only four of the selected studies were randomized [45,47,65,78]. The number of patients included per study varied between 5 and 190. Patients received BPP alone ( $n = 29$ ) or combination with denosumab ( $n = 12$ ). In one study, a monoclonal antibody (mAb) was administered to one patient, while the others received BPP [82]. In another study, denosumab was used alone [47], with and without previous intake of BPP [53].

Six studies mixed all the MRONJ grades (0–3); 18 studies had three grades (1–3); and 11 studies had two grades (2–3,  $n = 9$ , and 1–2,  $n = 2$ ). Only four studies focused on stage 2 ( $n = 3$ ) [39,51,54] or stage 1 ( $n = 1$ ) [80]. Furthermore, the grade was defined using the Marx classification in two studies [37,49].

Very few patients per cohort had multiple lesions except for two studies [39,51].

When specified ( $n = 33$ ), all grades of MRONJ were treated ( $n = 26$ ). One study only addressed grades 2–3 [47]; the others only grade 1 ( $n = 1$ ) [80], grade 2 ( $n = 4$ ) [39,51,53,54], or lesions meeting the Marx IIB classification ( $n = 1$ ) [37]. When all MRONJ grades were treated, the treatment differed by stage only in five studies [55,57,69,76,77] (Table S2).

## 4. Discussion

We identified important shortcomings in almost all MRONJ-related parameters as previously mentioned by Lorenzo-Pouso et al. [6]. Here we analyzed the literature and reported the information missing from 43 published studies. This forms a basis for us to reach a consensus on how to harmonize practices and define the information to include in future publications (Table 1). From our analysis, we noted that only four studies were randomized, which confirms the need for RCTs.

MRONJ grade was mainly categorized according to the AAOMS classification, but some authors used Marx's classification [37,49] or their own criterion [13,50]. The American Society of Bone and Mineral Research (ASBMR) definition is also found in the literature [8]. It is worth mentioning that some classifications differ between them [6]. Harmonization seems to be necessary, and the classification used in a published study must always be named by the authors.

As mentioned in the introduction, the MRONJ patient percentage sometimes combined (i) associated diseases (cancers and osteoporosis), (ii) the drug that contributed to MRONJ (anti-resorptive and anti-angiogenic drugs), (iii) the route of administration (IV and per os), (iv) MRONJ stage, and (v) mandibular/maxillary—multiple lesions [47,53,83]. However, it is well accepted that these parameters influence the success rate and affect the error when calculating percentages [47,53,83]. Here, 39 studies reported the use of BPP; 24 studies mixed three or four MRONJ grades; and only four studies focused on one grade. Since nonsurgical treatment is a promising alternative for stage 1 patients [52], it is not appropriate to mix this population with stage 2 and/or 3 patients. Thus, a representative percentage of MRONJ patients for each stage based on previously listed criteria is essential and must be clearly stated in a publication. This will assist with sample size calculation and the choice of

statistical models in an RCT. We suggest that authors provide MRONJ patient percentages based on the suggested criteria.

For the diagnosis, associated clinical characteristics of the lesions, including site, and signs of secondary infection were often reported [2,10,84]. From our analysis, only three references reported mucosal defect size or diameter of exposed bone but did not describe the measurement technique [45,51,52]. Velez et al. reported the use of a North Carolina #15 calibrated periodontal probe in patients undergoing dental implant surgery to evaluate wound size [85]. We believe that measuring the lesion's size (with a soft plastic ruler) could be a quantitative tool to calculate the benefits of a specific treatment, especially in RCTs.

Of the 43 studies, only 30 reported multisite lesions. Among these 30 studies, only 18 specified the number of patients suffering from multiple lesions. Only 14 studies specified the number of osteonecrosis sites, with the exact number (two or three sites) disclosed in only 9 studies. Furthermore, the precise location of the lesion(s) (left/right/posterior/anterior mandibular or mandible sectors; multifocal or uni- or bilateral involvement) was often not detailed, nor was the number of sites treated, except for two studies [51,57]. Additionally, it was difficult for us to understand if treated patients were compared to a control group, or if patients were their own controls in the case of multiple lesions. An updated AAOMS classification was published recently but does not point out this missing information [40]. We strongly suggest providing the most data possible about the lesions (number and precise location), number of multisite patients, and if patients are their own control.

The role of a drug holiday is debated [17], and it seems that there is no significant relationship between discontinuing administration of the causative agent and the treatment outcome [46]. Here, a drug holiday was required in 20 studies but only seven specified it. We recommend being more descriptive.

In the management of MRONJ, it appears that 26 studies treated all grades and only five studies adapted the treatment to the grade. Consequently, it was unclear which groups were compared. For example, two treatments (innovative treatment versus standard surgery) could be compared in two groups of patients that mixed all stages [72,74]. Only six studies addressed only one grade. Thus, as in current practice, it seems the treatment choice is not influenced by the MRONJ grade. This is not amenable to an RCT, and we encourage authors to be more restrictive and not mix the MRONJ grades together.

In the context of our RCT, we wanted to collect details on PRF application to assist us with hAM grafting; however, the literature does not describe it. We encourage authors to be more descriptive when using PRF.

The clinical assessment of healing was often different between studies [86] and was mainly based on the criteria proposed by Vescovi et al. [87]. According to our analysis, primary and secondary endpoints and their evaluation methods are neither harmonized nor quantitative. It seems that no consensus has been established. Focusing on lesion size, mucosal healing or coverage, and bone exposure, we were unable to find a quantitative measurement tool. Here, we suggest mucosal healing with no bone exposure as the primary endpoint (objectively proven by photography), and as secondary endpoints, pain evaluation (with VAS), Oral Health Impact Profile (OHIP) 14 [88], postoperative complications, and new bone formation (objectively proven with radiological examinations). We also recommend establishing or using a scale or index to evaluate wound healing. In a very comprehensive approach, Blatt et al. [89] combined eight items, each measured on a 5-point scale (with 0 indicating the lowest and 5 the highest value of the item): wound size, depth, necrotic tissue type, total amount of necrotic tissue, granulation tissue type, total amount of granulation tissue, edges, and peri-ulcer skin/mucosa viability. In addition, pain and oral health-related quality of life were assessed. Integrity of the mucosa and wound healing were assessed via the IPR (I = inflammatory, P = proliferative, R = remodeling) Wound Healing Scale [90]. This score is used depending on the wound healing phase; the total score ranges from 0 to 16, where 11–16 is considered excellent healing. Wound healing was evaluated with the revised photographic wound assessment tool (PWAT) [91].

**Table 1.** Critical information to be included in future clinical trials on MRONJ.

Essential Criteria for MRONJ Clinical Trials	Corrective Actions/Comments
MRONJ grade classification	Harmonization is needed; authors must name which classification is being used in a published study.
MRONJ patient percentage	Provide MRONJ patient percentages based on the suggested criteria: (i) associated diseases (cancers and osteoporosis), (ii) the drug that contributed to MRONJ (anti-resorptive and anti-angiogenic drugs), (iii) route of administration (IV and per os), (iv) MRONJ stage, and (v) mandibular/maxillary—multiple lesions.
For the diagnosis: <ul style="list-style-type: none"> <li>- Mucosal defect</li> <li>- Number of sites affected and treated</li> </ul>	<ul style="list-style-type: none"> <li>- The lesion's size (measured with a soft plastic ruler) could be used to calculate the benefits of a specific treatment, especially in RCTs.</li> <li>- The number of sites affected, and the number of sites treated must be reported while providing the most data possible about the lesions (precise location and size).</li> <li>- The number of multisite patients and if patients are their own controls are absolutely necessary.</li> </ul>
Continuation of MRONJ-inducing drug	Clinical practices should be harmonized and a precise description of the timing of any drug holiday should be provided.
Management of MRONJ: <ul style="list-style-type: none"> <li>- When two treatments are compared</li> <li>- PRF application method</li> </ul>	<ul style="list-style-type: none"> <li>- MRONJ grades should not be mixed together.</li> <li>- Provide a complete description of how PRF is applied.</li> </ul>
Clinical assessment of healing: <ul style="list-style-type: none"> <li>- Primary and secondary endpoints and their evaluation methods</li> <li>- Exact date on which healing has occurred</li> </ul>	<ul style="list-style-type: none"> <li>- Primary endpoint: Mucosal healing with no bone exposure (objectively proven by photography).</li> <li>- Secondary endpoints: pain level (VAS), OHIP 14 [88], postoperative complications, new bone formation (objectively proven with radiographs).</li> <li>- Scale or index used to evaluate wound healing.</li> <li>- Establish a consensus on the date on which healing is assessed, e.g., the primary endpoint could be evaluated at 3-months post-surgery.</li> </ul>
Success rate by MRONJ grade	Provide a clear definition of healing and describe the success rate by parameter: patient grade, associated disease, type of drug and route of administration, mandibular/maxillary—multiple lesions, and date of occurrence.
Criteria for defining failure, its measurement and date of occurrence	Failure could be defined as wound dehiscence with exposed necrotic bone within 3-months post-treatment, whether a new surgery is required or not. Any bone re-exposure should be measured using a soft plastic ruler.
Bone healing measurement	OPT at 3- and 6-months post-treatment combined with CBCT.

CBCT: cone beam computed tomography; MRONJ: medication-related osteonecrosis of the jaw; OHIP: Oral Health Impact Profile; OPT: orthopantomography; PRF: plasma rich fibrin; RCTs: randomized clinical trials; VAS: visual analogue scale.

No consensus was found on the exact date on which healing is determined. In our review, we found that the time point at which the primary endpoint was evaluated is not standardized and occurred before or at the end of follow-up. In a retrospective study, 6 months post-surgery, one in two patients healed with no improvement in the cure rate at 12 months [7]. The authors stated that the estimated cure rates in the literature are, respectively, 61% and 71% at 6 and 12 months postoperatively. In their study, the cure rate was not optimized from 6 to 12 months after the first surgical intervention but only beyond 1 year after additional surgical interventions [7]. They contend that the literature showed 10% additional healing from 6 to 12 months postoperatively and 9% additional healing from 6 to 18 months postoperatively. They concluded that, in the absence of healing, within

6 to 12 months after surgery, bone exposure appeared to be persistent and was associated with a slow and uncertain recovery [7]. Similarly, Giudice et al. reported that mucosal integrity, absence of infection, and pain evaluation showed a significant difference between the two groups in favor of PRF only at 1 month ( $p < 0.05$ ), whereas no differences were found at 6 months and 1 year ( $p > 0.05$ ) [47]. We believe that a consensus is needed on which date healing is assessed. For example, the primary endpoint could be evaluated at 3 months post-surgery and the secondary endpoint at 6 months.

In the literature, due to the mixing of variable data (grades, associated disease, type of drug and route of administration, mandibular or maxillary lesions, date of occurrence), the healing rate percentage varies from 33% to 100% when a medical or surgical treatment or adjuvant therapy is used [92]. Investigating 77 studies, Hsu et al. reported 86% clinical effectiveness in pooled patients. Surprisingly, they identified a homogeneity of clinical outcomes in case series suggesting that case series were far more consistent in their patient selection and treatment protocol. Here, the percentage varied from 0% to 100% [50] from 2 months up to 8 months [56]. To highlight this possible miscalculation, for example, focusing on stage 2 patients being treated for cancer, the healing percentage—evaluated between 6 and 54 months—varied from 61% to 100% when a surgical treatment or adjuvant therapy was applied [53,56,59,61,62,72,73]. Again, a representative percentage of healing success for each stage is necessary and must be clearly reported in a publication. This will assist in sample size calculation and the choice of statistic models when designing an RCT. We suggest providing a clear definition of healing, and a well-described rate dissociating patient grade, associated disease, type of drug and route of administration, mandibular/maxillary—multiple lesions, and date of occurrence.

The criteria for defining failure, its measurement and date of occurrence, also varied between studies and were rarely quantitative [54,56,75]. Here we suggest the definition of failure as wound dehiscence with exposed necrotic bone, within 3 months post-treatment, whether a new surgery is required or not. In the case of bone re-exposure, we suggest documenting its size using a soft plastic ruler.

Bone healing measurement methods also varied greatly among conventional radiographs (intraoral and panoramic radiographs), CT scan, CBCT, MRI, and functional imaging with bone scintigraphy and PET [10,11,14]. Here, only four publications used CBCT. We suggest using OPT at 3- and 6-months post-treatment combined with CBCT, as it seems essential to know the real extent of MRONJ [14].

Recently, Gindraux et al. critiqued the [ClinicalTrials.gov](https://www.clinicaltrials.gov) website, which was mainly built for administrative purposes, as it is difficult for researchers and investigators to find relevant information [93]. However, all this information is essential to assess the success of a study and enable its translation into clinical practice.

Based on the findings of this review, the missing data identified in the literature and in patient medical records were incorporated in a questionnaire intended for practitioners to assist in the writing of our RCT protocol, defining the active patient population and measuring the effects of therapeutics. We hope this questionnaire will encourage authors to incorporate this important information in their future publications to add to our collective knowledge about MRONJ.

Our multicenter RCT on the effectiveness of hAM in MRONJ will be conducted in five French hospitals (grant PHRCI-2020).

## 5. Limitations and Conclusions

During our search, we realized that no systematic review contained the information we were looking for. We chose to look for these data in publications that clinicians identified as most relevant. A systematic review of literature would have implied an analysis of more than 4000 PubMed references with low probability of finding an answer to our 12 focused questions.

This review identified missing information or absence of consensus related to MRONJ grade classification, drug holiday, and PRF application methods. Additionally, it high-

lighted a lack of quantitative values sometimes coupled with heterogeneity in (i) patient percentage by MRONJ stage and healing rate, (ii) mucosal defect size, and number of affected sites and treated sites, (iii) primary and secondary endpoints, (iv) criterion for defining failure, its rate, and time of occurrence, (v) bone re-exposure, its measurement, and the use of imaging tools, and (vi) follow-up duration. Consequently, we developed a questionnaire to increase the likelihood this information will be included in future publications. Based on our findings, we have proposed some harmonized practices and encourage clinicians to establish a consensus.

**Supplementary Materials:** The following supporting information can be downloaded at: <https://www.mdpi.com/article/10.3390/cells11244097/s1>, Table S1 (part A and B). Summary of the 12 essential criteria extracted from the selected articles; Table S2. Summary of seven additional items. Legend for Tables S1, S2: AAOMS: Association of Oral and Maxillofacial Surgeons; BPP: bisphosphonates; BFPF: buccal fat pad flap; CBCT: cone beam computed tomography; CT: computer tomography; FDG: fluorodeoxyglucose; IV: intravenous; mAb: monoclonal antibody; MRI: magnetic resonance imaging; MRONJ: medication-related osteonecrosis of the jaw; NA: not applicable; OAC: oroantral communication; OPT: orthopantomography; PET: positron emission tomography; PRF: plasma rich fibrin; QOL: quality of life; RCT: randomized clinical trial; VAS: visual analogue scale; VELscope: Visually Enhanced Lesion Scope; (-): Not specified.

**Author Contributions:** Conceptualization, F.G., C.G., S.O. and A.-L.P.; methodology, F.G., C.G., S.O. and A.-L.P.; validation, C.M. (Christophe Meyer), B.C., E.W., S.D., S.L., C.M. (Cédric Mauprivez), E.B., H.K., M.F., J.-C.F., N.Z., D.H., R.C., E.G. and A.L.; investigation, F.G., C.G. and S.O.; resources, F.G., C.G. and S.O.; data curation, F.G., C.G. and S.O.; writing—original draft preparation, F.G., C.G. and S.O.; writing—review and editing, F.G., C.G. and S.O.; visualization, F.G.; supervision, F.G. All authors have read and agreed to the published version of the manuscript.

**Funding:** This study was supported by a grant from the French Ministry of Health (PHRCI-20-036).

**Institutional Review Board Statement:** Not applicable.

**Informed Consent Statement:** Not applicable.

**Data Availability Statement:** Not applicable.

**Acknowledgments:** The authors are grateful to Franck Daval (Bibliothèque Universitaire Santé, Université Bourgogne Franche-Comté, Besançon, France) for the bibliographic support. The authors acknowledge the language support provided by Joanne Archambault.

**Conflicts of Interest:** The authors declare that the research was conducted in the absence of any commercial or financial relationships that could be construed as a potential conflict of interest.

## Appendix A

Questionnaire on medication-related osteonecrosis of the jaw (MRONJ) management and practices by center and/or practitioner

I/Diagnosis

1/How many MRONJ consultations do you have per year in your center?

- Stage 1
- Stage 2
- Stage 3

2/According to which classification do you rank the MRONJ?

3/Do you always specify the MRONJ grade in the patient's medical record?

No

If no: do you always list the symptoms that will allow it to be classified? (bone exposure and size, multiple lesions and precise location, gingival swelling, pain, paresthesia, intraoral or extraoral fistulas, cellulitis, abscess, purulent discharge, sepsis, quality of life)

Yes

4/How many patients do you personally follow, in the cancer context, for MRONJ induced by:

- Bisphosphonates:
- Denosumab:
- Angiogenesis inhibitors:

5/How many patients are treated in your center, in the cancer context, for MRONJ induced by:

- Bisphosphonates:
- Denosumab:
- Angiogenesis inhibitors:

6/About MRONJ stages:

- Which proportion of stage 1 MRONJ (bone exposure without symptoms) progresses to stage 2 (bone exposure + pain or local infection)?
- Which proportion of stage 2 MRONJ recurs after the initial treatment?
- Which proportion of stage 2 MRONJ progresses to stage 3 (bone exposure with diffuse infection/pathological fracture/extraoral fistula)?

7/About MRONJ lesions:

- Which proportion of patients have only 1 lesion?
- Which proportion of patients have 2 lesions?
  - Specify the number of lesions treated:
- Which proportion of patients have >2 lesions?
  - Specify the number of lesions treated:

8/Have you implemented a drug holiday?

No

Yes

If yes: specify the duration and starting point

II/Surgery and management of MRONJ

1/What is the usual surgical management of stage 2 MRONJ in your center? specify the type of surgical treatment, etc.

2/Do you use platelet-rich fibrin (PRF)?

No

Yes

If yes: specify the methods

3/Which portion of these patients benefits from bone resection (surgery or milling)?

4/Which portion of these patients benefits from a sequestrectomy?

5/How long between the first consultation and the surgery?

III/Assessment of bone exposure (or lesions)

1/Is bone exposure measured?

No (go to paragraph IV)

Yes (please answer next questions)

2/For which stage?

Stage 1

Stage 2

Stage 3

3/When is it performed?

Preoperative visit

Just before the surgery

During the follow-up (specify the follow-up dates)

4/Who carries it out? (you or someone else? Specify surgeon or radiologist)

5/With which material?

Camera (if yes: which model?)

Calibrated plastic sticks

Other, specify

6/Do you have software to calculate the display area from a photograph?

No

Yes

If yes:

Which model?

Is it easily accessible?

Are there any constraints to its use, to its availability?

Does it require training?

7/Can the images taken during surgery be stored?

No

Yes

If yes: specify the location of the recording, its format, and the backup duration:

IV/Pain assessment

1/Does the VAS seem suitable to you?

2/Do you use another scale?

V/Assessment of quality of life and oral hygiene

1/Does the GOHAI scale seem suitable to you?

2/Do you use another scale?

VI/Healing

1/Which criterion(s) do you use to define healing?

Lack of bone re-exposure

Mucosa healing

Other? Specify:

VII/Complications/failure rate post-surgery

1/Which complications do you observe?

2/During follow-up visits, are these complications always listed in the patient's medical record?

No

Yes

3/Which percentage of postoperative complications is attributable to surgery? Failure rate?

4/Date of occurrence?

VIII/Imaging

1/Which imaging method do you use?

Orthopantomogram (OPT)

Cone Beam Computed Tomography (CBCT)

Positron-Emission Tomography (PET)-scan

Magnetic resonance imaging (MRI)

2/When?

Preoperative

Postoperative

During the follow-up (specify which month(s)):

3/What do you expect to see on the follow-up imaging 6 months after surgery:

- From a bone point of view:
- From a mucosal point of view:

## IX/Active patient population

- 1/What percentage of patients attend their follow-up visits?
- 2/What percentage of subjects are lost to follow-up?
- 3/What percentage of subjects die during the follow-up period?

## References

1. Ruggiero, S.L.; Dodson, T.B.; Assael, L.A.; Landesberg, R.; Marx, R.E.; Mehrotra, B. American Association of Oral and Maxillofacial Surgeons Position Paper on Bisphosphonate-Related Osteonecrosis of the Jaws—2009 Update. *J. Oral Maxillofac. Surg.* **2009**, *67*, 2–12. [[CrossRef](#)] [[PubMed](#)]
2. Ruggiero, S.L.; Dodson, T.B.; Fantasia, J.; Goodday, R.; Aghaloo, T.; Mehrotra, B.; O’Ryan, F. American Association of Oral and Maxillofacial Surgeons Position Paper on Medication-Related Osteonecrosis of the Jaw—2014 Update. *J. Oral Maxillofac. Surg.* **2014**, *72*, 1938–1956. [[CrossRef](#)] [[PubMed](#)]
3. Ruggiero, S.; Gralow, J.; Marx, R.E.; Hoff, A.; Schubert, M.M.; Hurn, J.M.; Toth, B.; Damato, K.; Valero, V. Practical guidelines for the prevention, diagnosis, and treatment of osteonecrosis of the jaw in patients with cancer. *J. Oncol. Pract.* **2006**, *2*, 7–14. [[CrossRef](#)] [[PubMed](#)]
4. Gunepin, M.; Derache, F.; De Jaureguibery, J.-P.; Bladé, J.-S.; Gisserot, O.; Cathelinaud, O.; Bédrupe, B.; Rivière, D. Ostéonécroses des maxillaires dues aux bisphosphonates administrés par voie intraveineuse: Incidence et facteurs de risque. *Méd. Buccale Chir. Buccale* **2013**, *19*, 21–31. [[CrossRef](#)]
5. Kim, H.-Y.; Kim, J.-W.; Kim, S.-J.; Lee, S.-H.; Lee, H.-S. Uncertainty of current algorithm for bisphosphonate-related osteonecrosis of the jaw in population-based studies: A systematic review. *J. Bone Miner. Res.* **2017**, *32*, 584–591. [[CrossRef](#)]
6. Lorenzo-Pouso, A.I.; Bagán, J.; Bagán, L.; Gándara-Vila, P.; Chamorro-Petronacci, C.M.; Castelo-Baz, P.; Blanco-Carrión, A.; Blanco-Fernández, M.Á.; Álvarez-Calderón, Ó.; Carballo, J.; et al. Medication-Related Osteonecrosis of the Jaw: A Critical Narrative Review. *J. Clin. Med.* **2021**, *10*, 4367. [[CrossRef](#)]
7. Berquet, A.; Louvrier, A.; Denis, F.; Bornert, F.; Weber, E.; Meyer, C. Evaluation of healing time of osteochemonecrosis of the jaw after surgery: Single-center retrospective study and review of the literature. *J. Stomatol. Oral Maxillofac. Surg.* **2017**, *118*, 11–19. [[CrossRef](#)]
8. Fortunato, L.; Bennardo, F.; Buffone, C.; Giudice, A. Is the application of platelet concentrates effective in the prevention and treatment of medication-related osteonecrosis of the jaw? A systematic review. *J. Cranio-Maxillofac. Surg.* **2020**, *48*, 268–285. [[CrossRef](#)]
9. Gavalda, C.; Bagan, J. Concept, diagnosis and classification of bisphosphonate-associated osteonecrosis of the jaws. A review of the literature. *Med. Oral. Patol. Oral. Cir. Bucal.* **2016**, *21*, e260–e270. [[CrossRef](#)]
10. Khan, A.A.; Morrison, A.; Hanley, D.A.; Felsenberg, D.; McCauley, L.K.; O’Ryan, F.; Reid, I.R.; Ruggiero, S.L.; Taguchi, A.; Tetradis, S.; et al. Diagnosis and Management of Osteonecrosis of the Jaw: A Systematic Review and International Consensus. *J. Bone Miner. Res.* **2015**, *30*, 3–23. [[CrossRef](#)]
11. Migliorati, C.A.; Epstein, J.B.; Abt, E.; Berenson, J.R. Osteonecrosis of the jaw and bisphosphonates in cancer: A narrative review. *Nat. Rev. Endocrinol.* **2010**, *7*, 34–42. [[CrossRef](#)]
12. Moraschini, V.; Calasans-Maia, M.; Louro, R.S.; Arantes, E.B.R.; Calasans-Maia, J. Weak evidence for the management of medication-related osteonecrosis of the jaw: An overview of systematic reviews and meta-analyses. *J. Oral Pathol. Med.* **2020**, *50*, 10–21. [[CrossRef](#)]
13. Stanton, D.C.; Balasarian, E. Outcome of Surgical Management of Bisphosphonate-Related Osteonecrosis of the Jaws: Review of 33 Surgical Cases. *J. Oral Maxillofac. Surg.* **2009**, *67*, 943–950. [[CrossRef](#)]
14. Assili, Z.; Dolivet, G.; Salleron, J.; Griffaton-Tallandier, C.; Egloff-Juras, C.; Phulpin, B. A Comparison of the Clinical and Radiological Extent of Denosumab (Xgeva(R)) Related Osteonecrosis of the Jaw: A Retrospective Study. *J. Clin. Med.* **2021**, *10*, 2390. [[CrossRef](#)]
15. Legendre, Q.; Faillie, J.; Lapeyrie, P.; Tramini, P.; Maladiere, E.; Torres, J.; Lallemand, B. Epidemiology of osteochemonecrosis of the jaws in France, update of data since 2015. *J. Stomatol. Oral Maxillofac. Surg.* **2021**, *123*, e448–e453. [[CrossRef](#)]
16. Suryani, I.R.; Ahmadzai, I.; Shujaat, S.; Ma, H.; Jacobs, R. Non-antiresorptive drugs associated with the development of medication-related osteonecrosis of the jaw: A systematic review and meta-analysis. *Clin. Oral Investig.* **2022**, *26*, 2269–2279. [[CrossRef](#)]
17. Hsu, K.-J.; Hsiao, S.-Y.; Chen, P.-H.; Chen, H.-S.; Chen, C.-M. Investigation of the Effectiveness of Surgical Treatment on Maxillary Medication-Related Osteonecrosis of the Jaw: A Literature Review. *J. Clin. Med.* **2021**, *10*, 4480. [[CrossRef](#)]
18. El-Rabbany, M.; Sgro, A.; Lam, D.K.; Shah, P.S.; Azarpazhooh, A. Effectiveness of treatments for medication-related osteonecrosis of the jaw: A systematic review and meta-analysis. *J. Am. Dent. Assoc.* **2017**, *148*, 584–594.e2. [[CrossRef](#)]
19. Govaerts, D.; Piccart, F.; Ockerman, A.; Coropciuc, R.; Politis, C.; Jacobs, R. Adjuvant therapies for MRONJ: A systematic review. *Bone* **2020**, *141*, 115676. [[CrossRef](#)]
20. Silini, A.R.; Cargnoni, A.; Magatti, M.; Pianta, S.; Parolini, O. The Long Path of Human Placenta, and Its Derivatives, in Regenerative Medicine. *Front. Bioeng. Biotechnol.* **2015**, *3*, 162. [[CrossRef](#)]
21. Mamede, A.C.; Carvalho, M.J.; Abrantes, A.M.; Laranjo, M.; Maia, C.; Botelho, M.F. Amniotic membrane: From structure and functions to clinical applications. *Cell Tissue Res.* **2012**, *349*, 447–458. [[CrossRef](#)] [[PubMed](#)]

22. Laurent, R.; Nallet, A.; Obert, L.; Nicod, L.; Gindraux, F. Storage and qualification of viable intact human amniotic graft and technology transfer to a tissue bank. *Cell Tissue Bank*. **2014**, *15*, 267–275. [[CrossRef](#)] [[PubMed](#)]
23. Gindraux, F.; Rondot, T.; de Billy, B.; Zwetyenga, N.; Fricain, J.-C.; Pagnon, A.; Obert, L. Similarities between induced membrane and amniotic membrane: Novelty for bone repair. *Placenta* **2017**, *59*, 116–123. [[CrossRef](#)] [[PubMed](#)]
24. Laurent, R.; Nallet, A.; Obert, L.; Nicod, L.P.; Meyer, C.; Layrolle, P.; Zwetyenga, N.; Gindraux, F.; De Billy, B. Fresh and in vitro osteodifferentiated human amniotic membrane, alone or associated with an additional scaffold, does not induce ectopic bone formation in Balb/c mice. *Cell Tissue Bank*. **2016**, *18*, 17–25. [[CrossRef](#)] [[PubMed](#)]
25. Fénelon, M.; Chassande, O.; Kalisky, J.; Gindraux, F.; Brun, S.; Bareille, R.; Ivanovic, Z.; Fricain, J.-C.; Boiziau, C. Human amniotic membrane for guided bone regeneration of calvarial defects in mice. *J. Mater. Sci. Mater. Med.* **2018**, *29*, 78. [[CrossRef](#)]
26. Fenelon, M.; Maurel, D.B.; Siadous, R.; Gremare, A.; Delmond, S.; Durand, M.; Brun, S.; Catros, S.; Gindraux, F.; L'Heureux, N.; et al. Comparison of the impact of preservation methods on amniotic membrane properties for tissue engineering applications. *Mater. Sci. Eng. C Mater. Biol. Appl.* **2019**, *104*, 109903. [[CrossRef](#)]
27. Gualdi, T.; Laurent, R.; Moutarlier, V.; Fenelon, M.; Nallet, A.; Pouthier, F.; Obert, L.; de Billy, B.; Meyer, C.; Gindraux, F. In vitro osteodifferentiation of intact human amniotic membrane is not beneficial in the context of bone repair. *Cell Tissue Bank*. **2019**, *20*, 435–446. [[CrossRef](#)]
28. Fenelon, M.; Etchebarne, M.; Siadous, R.; Grémare, A.; Durand, M.; Sentilhes, L.; Torres, Y.; Catros, S.; Gindraux, F.; L'Heureux, N.; et al. Assessment of fresh and preserved amniotic membrane for guided bone regeneration in mice. *J. Biomed. Mater. Res. Part A* **2020**, *108*, 2044–2056. [[CrossRef](#)]
29. Gulameabasse, S.; Gindraux, F.; Catros, S.; Fricain, J.; Fenelon, M. Chorion and amnion/chorion membranes in oral and periodontal surgery: A systematic review. *J. Biomed. Mater. Res. Part B Appl. Biomater.* **2020**, *109*, 1216–1229. [[CrossRef](#)]
30. Etchebarne, M.; Fricain, J.-C.; Kerdjoudj, H.; Di Pietro, R.; Wolbank, S.; Gindraux, F.; Fenelon, M. Use of Amniotic Membrane and Its Derived Products for Bone Regeneration: A Systematic Review. *Front. Bioeng. Biotechnol.* **2021**, *9*, 661332. [[CrossRef](#)]
31. Fénelon, M.; Catros, S.; Meyer, C.; Fricain, J.-C.; Obert, L.; Auber, F.; Louvrier, A.; Gindraux, F. Applications of Human Amniotic Membrane for Tissue Engineering. *Membranes* **2021**, *11*, 387. [[CrossRef](#)]
32. Fenelon, M.; Etchebarne, M.; Siadous, R.; Grémare, A.; Durand, M.; Sentilhes, L.; Catros, S.; Gindraux, F.; L'Heureux, N.; Fricain, J.-C. Comparison of amniotic membrane versus the induced membrane for bone regeneration in long bone segmental defects using calcium phosphate cement loaded with BMP-2. *Mater. Sci. Eng. C* **2021**, *124*, 112032. [[CrossRef](#)]
33. Odet, S.; Louvrier, A.; Meyer, C.; Nicolas, F.J.; Hofman, N.; Chatelain, B.; Mauprivez, C.; Laurence, S.; Kerdjoudj, H.; Zwetyenga, N.; et al. Surgical Application of Human Amniotic Membrane and Amnion-Chorion Membrane in the Oral Cavity and Efficacy Evaluation: Corollary With Ophthalmological and Wound Healing Experiences. *Front. Bioeng. Biotechnol.* **2021**, *9*, 685128. [[CrossRef](#)]
34. Odet, S.; Solecki, L.; Meyer, C.; Weber, E.; Chatelain, B.; Euvrard, E.; Barrabé, A.; Gualdi, T.; Parmentier, A.-L.; Tatu, L.; et al. Human amniotic membrane application in oral surgery—An ex vivo pilot study. *Front. Bioeng. Biotechnol.* **2022**, *10*, 968346. [[CrossRef](#)]
35. Odet, S.; Meyer, C.; Gaudet, C.; Weber, E.; Quenot, J.; Derruau, S.; Laurence, S.; Bompoy, L.; Girodon, M.; Chatelain, B.; et al. Tips and Tricks and Clinical Outcome of Cryopreserved Human Amniotic Membrane Application for the Management of Medication-Related Osteonecrosis of the Jaw (MRONJ): A Pilot Study. *Front. Bioeng. Biotechnol.* **2022**, *10*, 936074. [[CrossRef](#)]
36. Hallmer, F.; Andersson, G.; Götrick, B.; Warfvinge, G.; Anderud, J.; Bjørnland, T. Prevalence, initiating factor, and treatment outcome of medication-related osteonecrosis of the jaw—A 4-year prospective study. *Oral Surg. Oral Med. Oral Pathol. Oral Radiol.* **2018**, *126*, 477–485. [[CrossRef](#)]
37. Mozzati, M.; Gallesio, G.; Arata, V.; Pol, R.; Scoletta, M. Platelet-rich therapies in the treatment of intravenous bisphosphonate-related osteonecrosis of the jaw: A report of 32 cases. *Oral Oncol.* **2012**, *48*, 469–474. [[CrossRef](#)]
38. Nisi, M.; Karapetsa, D.; Gennai, S.; Ramaglia, L.; Graziani, F.; Gabriele, M. Conservative surgical treatment of medication related osteonecrosis of the jaw (MRONJ) lesions in patients affected by osteoporosis exposed to oral bisphosphonates: 24 months follow-up. *J. Cranio-Maxillofac. Surg.* **2018**, *46*, 1153–1158. [[CrossRef](#)]
39. Mourão, C.F.D.A.B.; Calasans-Maia, M.D.; Del Fabbro, M.; Vieira, F.L.D.; Machado, R.C.D.M.; Capella, R.; Miron, R.J.; Alves, G.G. The use of Platelet-rich Fibrin in the management of medication-related osteonecrosis of the jaw: A case series. *J. Stomatol. Oral Maxillofac. Surg.* **2019**, *121*, 84–89. [[CrossRef](#)]
40. Ruggiero, S.L.; Dodson, T.B.; Aghaloo, T.; Carlson, E.R.; Ward, B.B.; Kademani, D. American Association of Oral and Maxillofacial Surgeons' Position Paper on Medication-Related Osteonecrosis of the Jaws—2022 Update. *J. Oral. Maxillofac. Surg.* **2022**, *80*, 920–943. [[CrossRef](#)]
41. Ruggiero, S.L.; Mehrotra, B.; Rosenberg, T.J.; Engroff, S.L. Osteonecrosis of the jaws associated with the use of bisphosphonates: A review of 63 cases. *J. Oral Maxillofac. Surg.* **2004**, *62*, 527–534. [[CrossRef](#)] [[PubMed](#)]
42. Woo, S.B.; Hellstein, J.W.; Kalmar, J.R. Narrative [corrected] review: Bisphosphonates and osteonecrosis of the jaws. *Ann. Intern. Med.* **2006**, *144*, 753–761. [[CrossRef](#)] [[PubMed](#)]
43. Otto, S.; Ristow, O.; Pache, C.; Troeltzsch, M.; Fliefel, R.; Ehrenfeld, M.; Pautke, C. Fluorescence-guided surgery for the treatment of medication-related osteonecrosis of the jaw: A prospective cohort study. *J. Cranio-Maxillofac. Surg.* **2016**, *44*, 1073–1080. [[CrossRef](#)] [[PubMed](#)]

44. Marx, R.E.; Sawatari, Y.; Fortin, M.; Broumand, V. Bisphosphonate-Induced Exposed Bone (Osteonecrosis/Osteopetrosis) of the Jaws: Risk Factors, Recognition, Prevention, and Treatment. *J. Oral Maxillofac. Surg.* **2005**, *63*, 1567–1575. [[CrossRef](#)] [[PubMed](#)]
45. Freiberger, J.J.; Padilla-Burgos, R.; McGraw, T.; Suliman, H.B.; Kraft, K.H.; Stolp, B.W.; Moon, R.E.; Piantadosi, C.A. What Is the Role of Hyperbaric Oxygen in the Management of Bisphosphonate-Related Osteonecrosis of the Jaw: A Randomized Controlled Trial of Hyperbaric Oxygen as an Adjunct to Surgery and Antibiotics. *J. Oral Maxillofac. Surg.* **2012**, *70*, 1573–1583. [[CrossRef](#)]
46. Hayashida, S.; Soutome, S.; Yanamoto, S.; Fujita, S.; Hasegawa, T.; Komori, T.; Kojima, Y.; Miyamoto, H.; Shibuya, Y.; Ueda, N.; et al. Evaluation of the Treatment Strategies for Medication-Related Osteonecrosis of the Jaws (MRONJ) and the Factors Affecting Treatment Outcome: A Multicenter Retrospective Study with Propensity Score Matching Analysis. *J. Bone Miner. Res.* **2017**, *32*, 2022–2029. [[CrossRef](#)]
47. Giudice, A.; Barone, S.; Giudice, C.; Bennardo, F.; Fortunato, L. Can platelet-rich fibrin improve healing after surgical treatment of medication-related osteonecrosis of the jaw? A pilot study. *Oral Surgery, Oral Med. Oral Pathol. Oral Radiol.* **2018**, *126*, 390–403. [[CrossRef](#)]
48. Kim, H.Y.; Lee, S.-J.; Kim, S.M.; Myoung, H.; Hwang, S.J.; Choi, J.-Y.; Lee, J.-H.; Choung, P.-H.; Kim, M.J.; Seo, B.M. Extensive Surgical Procedures Result in Better Treatment Outcomes for Bisphosphonate-Related Osteonecrosis of the Jaw in Patients With Osteoporosis. *J. Oral Maxillofac. Surg.* **2016**, *75*, 1404–1413. [[CrossRef](#)]
49. Williamson, R. Surgical management of bisphosphonate induced osteonecrosis of the jaws. *Int. J. Oral Maxillofac. Surg.* **2010**, *39*, 251–255. [[CrossRef](#)]
50. Coviello, V.; Peluso, F.; Dehkhargani, S.Z.; Verdugo, F.; Raffaelli, L.; Manicone, P.F.; D'Addona, A. Platelet-rich plasma improves wound healing in multiple myeloma bisphosphonate-associated osteonecrosis of the jaw patients. *J. Biol. Regul. Homeost. Agents* **2012**, *26*, 151–155.
51. Çanakçı, F.G.; Er, N.; Duygu, G.; Varol, G.F. Surgical management of stage-2 medication-related osteonecrosis of the jaw with transplantation of human amniotic membrane: Preliminary results. *J. Stomatol. Oral Maxillofac. Surg.* **2021**, *123*, e28–e31. [[CrossRef](#)]
52. Klingelhöffer, C.; Zeman, F.; Meier, J.; Reichert, T.E.; Ettl, T. Evaluation of surgical outcome and influencing risk factors in patients with medication-related osteonecrosis of the jaws. *J. Cranio-Maxillofacial Surg.* **2016**, *44*, 1694–1699. [[CrossRef](#)]
53. Aljohani, S.; Gaudin, R.; Weiser, J.; Tröltzsch, M.; Ehrenfeld, M.; Kaeppler, G.; Smeets, R.; Otto, S. Osteonecrosis of the jaw in patients treated with denosumab: A multicenter case series. *J. Cranio-Maxillofac. Surg.* **2018**, *46*, 1515–1525. [[CrossRef](#)]
54. Eguchi, T.; Kanai, I.; Basugi, A.; Miyata, Y.; Inoue, M.; Hamada, Y. The assessment of surgical and non-surgical treatment of stage II medication-related osteonecrosis of the jaw. *Med. Oral Patol. Oral. Cir. Bucal.* **2017**, *22*, e788–e795. [[CrossRef](#)]
55. Mücke, T.; Koschinski, J.; Deppe, H.; Wagenpfeil, S.; Pautke, C.; Mitchell, D.A.; Wolff, K.-D.; Hölzle, F. Outcome of treatment and parameters influencing recurrence in patients with bisphosphonate-related osteonecrosis of the jaws. *J. Cancer Res. Clin. Oncol.* **2011**, *137*, 907–913. [[CrossRef](#)]
56. Stockmann, P.; Vairaktaris, E.; Wehrhan, F.; Seiss, M.; Schwarz, S.; Spriewald, B.; Neukam, F.-W.; Nkenke, E. Osteotomy and primary wound closure in bisphosphonate-associated osteonecrosis of the jaw: A prospective clinical study with 12 months follow-up. *Support. Care Cancer* **2010**, *18*, 449–460. [[CrossRef](#)]
57. Wutzl, A.; Biedermann, E.; Wanschitz, F.; Seemann, R.; Klug, C.; Baumann, A.; Watzinger, F.; Schicho, K.; Ewers, R.; Milesi, G. Treatment results of bisphosphonate-related osteonecrosis of the jaws. *Head Neck* **2008**, *30*, 1224–1230. [[CrossRef](#)]
58. Lemound, J.; Eckardt, A.; Kokemüller, H.; Von See, C.; Voss, P.J.; Tavassol, F.; Rucker, M.; Rana, M.; Gellrich, N.-C. Bisphosphonate-associated osteonecrosis of the mandible: Reliable soft tissue reconstruction using a local myofascial flap. *Clin. Oral Investig.* **2011**, *16*, 1143–1152. [[CrossRef](#)]
59. Pautke, C.; Bauer, F.; Otto, S.; Tischer, T.; Steiner, T.; Weitz, J.; Kretzner, K.; Hohlweg-Majert, B.; Wolff, K.-D.; Hafner, S.; et al. Fluorescence-Guided Bone Resection in Bisphosphonate-Related Osteonecrosis of the Jaws: First Clinical Results of a Prospective Pilot Study. *J. Oral Maxillofac. Surg.* **2011**, *69*, 84–91. [[CrossRef](#)]
60. Bedogni, A.; Saia, G.; Bettini, G.; Tronchet, A.; Totola, A.; Bedogni, G.; Ferronato, G.; Nocini, P.F.; Blandamura, S. Long-term outcomes of surgical resection of the jaws in cancer patients with bisphosphonate-related osteonecrosis. *Oral Oncol.* **2011**, *47*, 420–424. [[CrossRef](#)]
61. Wilde, F.; Heufelder, M.; Winter, K.; Hendricks, J.; Frerich, B.; Schramm, A.; Hemprich, A. The role of surgical therapy in the management of intravenous bisphosphonates-related osteonecrosis of the jaw. *Oral Surg. Oral Med. Oral Pathol. Oral Radiol. Endodontology* **2011**, *111*, 153–163. [[CrossRef](#)] [[PubMed](#)]
62. Vescovi, P.; Merigo, E.; Meleti, M.; Manfredi, M.; Fornaini, C.; Nammour, S. Surgical Approach and Laser Applications in BRONJ Osteoporotic and Cancer Patients. *J. Osteoporos.* **2012**, *2012*, 1–8. [[CrossRef](#)] [[PubMed](#)]
63. Bodem, J.P.; Schaal, C.; Kargus, S.; Saure, D.; Mertens, C.; Engel, M.; Hoffmann, J.; Freudlsperger, C. Surgical management of bisphosphonate-related osteonecrosis of the jaw stages II and III. *Oral Surg. Oral Med. Oral Pathol. Oral Radiol.* **2015**, *121*, 367–372. [[CrossRef](#)] [[PubMed](#)]
64. Fleisher, K.E.; Pham, S.; Raad, R.A.; Friedman, K.P.; Ghesani, M.; Chan, K.C.; Amintavakoli, N.; Janal, M.; Levine, J.P.; Glickman, R.S. Does Fluorodeoxyglucose Positron Emission Tomography with Computed Tomography Facilitate Treatment of Medication-Related Osteonecrosis of the Jaw? *J. Oral Maxillofac. Surg.* **2016**, *74*, 945–958. [[CrossRef](#)] [[PubMed](#)]

65. Giudice, A.; Bennardo, F.; Barone, S.; Antonelli, A.; Figliuzzi, M.; Fortunato, L. Can Autofluorescence Guide Surgeons in the Treatment of Medication-Related Osteonecrosis of the Jaw? A Prospective Feasibility Study. *J. Oral Maxillofac. Surg.* **2018**, *76*, 982–995. [[CrossRef](#)]
66. Ristow, O.; Rückschloß, T.; Bodem, J.; Berger, M.; Bodem, E.; Kargus, S.; Engel, M.; Hoffmann, J.; Freudlsperger, C. Double-layer closure techniques after bone surgery of medication-related osteonecrosis of the jaw – A single center cohort study. *J. Cranio-Maxillofac. Surg.* **2018**, *46*, 815–824. [[CrossRef](#)]
67. Aljohani, S.; Troeltzsch, M.; Hafner, S.; Kaeppler, G.; Mast, G.; Otto, S. Surgical treatment of medication-related osteonecrosis of the upper jaw: Case series. *Oral Dis.* **2019**, *25*, 497–507. [[CrossRef](#)]
68. Altay, M.A.; Radu, A.; Pack, S.E.; Yildirimyan, N.; Dds, A.F.-H.; Baur, D.A.; Quereshy, F.A. Medication-related osteonecrosis of the jaw: An institution’s experience. *Cranio* **2018**, *38*, 333–341. [[CrossRef](#)]
69. Hallmer, F.; Bjørnland, T.; Nicklasson, A.; Becktor, J.P.; Andersson, G. Osteonecrosis of the jaw in patients treated with oral and intravenous bisphosphonates: Experience in Sweden. *Oral Surgery, Oral Med. Oral Pathol. Oral Radiol.* **2014**, *118*, 202–208. [[CrossRef](#)]
70. Voss, P.J.; Oshero, J.J.; Kovalova-Müller, A.; Merino, E.A.V.; Sauerbier, S.; Al-Jamali, J.; Lemound, J.; Metzger, M.C.; Schmelzeisen, R. Surgical treatment of bisphosphonate-associated osteonecrosis of the jaw: Technical report and follow up of 21 patients. *J. Cranio-Maxillofac. Surg.* **2012**, *40*, 719–725. [[CrossRef](#)]
71. Altay, M.A.; Tasar, F.; Tosun, E.; Kan, B. Low-Level Laser Therapy Supported Surgical Treatment of Bisphosphonate Related Osteonecrosis of Jaws: A Retrospective Analysis of 11 Cases. *Photomed. Laser Surg.* **2014**, *32*, 468–475. [[CrossRef](#)]
72. Martins, M.A.; Martins, M.D.; Lascala, C.A.; Curi, M.M.; Migliorati, C.A.; Tennis, C.A.; Marques, M.M. Association of laser phototherapy with PRP improves healing of bisphosphonate-related osteonecrosis of the jaws in cancer patients: A preliminary study. *Oral Oncol.* **2012**, *48*, 79–84. [[CrossRef](#)]
73. Atalay, B.; Yalcin, S.; Emes, Y.; Aktas, I.; Aybar, B.; Issever, H.; Mandel, N.M.; Cetin, O.; Oncu., B. Bisphosphonate-related osteonecrosis: Laser-assisted surgical treatment or conventional surgery? *Lasers Med. Sci.* **2011**, *26*, 815–823. [[CrossRef](#)]
74. Angiero, F.; Sannino, C.; Borloni, R.; Crippa, R.; Benedicenti, S.; Romanos, G.E. Osteonecrosis of the jaws caused by bisphosphonates: Evaluation of a new therapeutic approach using the Er:YAG laser. *Lasers Med Sci.* **2009**, *24*, 849–856. [[CrossRef](#)]
75. Assaf, A.T.; Zrnc, T.A.; Riecke, B.; Wikner, J.; Zustin, J.; Friedrich, R.E.; Heiland, M.; Smeets, R.; Gröbe, A. Intraoperative efficiency of fluorescence imaging by Visually Enhanced Lesion Scope (VELscope®) in patients with bisphosphonate related osteonecrosis of the jaw (BRONJ). *J. Cranio-Maxillofac. Surg.* **2014**, *42*, e157–e164. [[CrossRef](#)]
76. Rugani, P.; Acham, S.; Kirnbauer, B.; Truschnegg, A.; Obermayer-Pietsch, B.; Jakse, N. Stage-related treatment concept of medication-related osteonecrosis of the jaw—A case series. *Clin. Oral Investig.* **2014**, *19*, 1329–1338. [[CrossRef](#)]
77. Holzinger, D.; Seemann, R.; Klug, C.; Ewers, R.; Millesi, G.; Baumann, A.; Wutzl, A. Long-term success of surgery in bisphosphonate-related osteonecrosis of the jaws (BRONJs). *Oral Oncol.* **2013**, *49*, 66–70. [[CrossRef](#)] [[PubMed](#)]
78. Ristow, O.; Otto, S.; Geiß, C.; Kehl, V.; Berger, M.; Troeltzsch, M.; Koerdt, S.; Hohlweg-Majert, B.; Freudlsperger, C.; Pautke, C. Comparison of auto-fluorescence and tetracycline fluorescence for guided bone surgery of medication-related osteonecrosis of the jaw: A randomized controlled feasibility study. *Int. J. Oral Maxillofac. Surg.* **2016**, *46*, 157–166. [[CrossRef](#)]
79. Pichardo, S.E.; Kuijpers, S.C.; van Merkesteyn, J.R. Bisphosphonate-related osteonecrosis of the jaws: Cohort study of surgical treatment results in seventy-four stage II/III patients. *J. Cranio-Maxillofac. Surg.* **2016**, *44*, 1216–1220. [[CrossRef](#)] [[PubMed](#)]
80. Markose, G.; Mackenzie, F.R.; Currie, W.; Hislop, W. Bisphosphonate osteonecrosis: A protocol for surgical management. *Br. J. Oral Maxillofac. Surg.* **2009**, *47*, 294–297. [[CrossRef](#)] [[PubMed](#)]
81. Otto, S.; Abu-Id, M.H.; Fedele, S.; Warnke, P.H.; Becker, S.T.; Kolk, A.; Mücke, T.; Mast, G.; Köhnke, R.; Volkmer, E.; et al. Osteoporosis and bisphosphonates-related osteonecrosis of the jaw: Not just a sporadic coincidence—A multi-centre study. *J. Cranio-Maxillofac. Surg.* **2011**, *39*, 272–277. [[CrossRef](#)]
82. Lemound, J.; Muecke, T.; Zeller, A.-N.; Lichtenstein, J.; Eckardt, A.; Gellrich, N.-C. Nasolabial Flap Improves Healing in Medication-Related Osteonecrosis of the Jaw. *J. Oral Maxillofac. Surg.* **2018**, *76*, 877–885. [[CrossRef](#)]
83. Pichardo, S.E.; van Merkesteyn, J.R. Evaluation of a surgical treatment of denosumab-related osteonecrosis of the jaws. *Oral Surg. Oral Med. Oral Pathol. Oral Radiol.* **2016**, *122*, 272–278. [[CrossRef](#)]
84. Kim, K.M.; Park, W.; Oh, S.Y.; Kim, H.-J.; Nam, W.; Lim, S.-K.; Rhee, Y.; Cha, I.H. Distinctive role of 6-month teriparatide treatment on intractable bisphosphonate-related osteonecrosis of the jaw. *Osteoporos. Int.* **2014**, *25*, 1625–1632. [[CrossRef](#)]
85. Velez, I.; Parker, W.B.; Siegel, M.A.; Hernandez, M. Cryopreserved Amniotic Membrane for Modulation of Periodontal Soft Tissue Healing: A Pilot Study. *J. Periodontol.* **2010**, *81*, 1797–1804. [[CrossRef](#)]
86. Anabtawi, M.; Tweedale, H.; Mahmood, H. The role, efficacy and outcome measures for teriparatide use in the management of medication-related osteonecrosis of the jaw. *Int. J. Oral Maxillofac. Surg.* **2021**, *50*, 501–510. [[CrossRef](#)]
87. Vescovi, P.; Merigo, E.; Meleti, M.; Manfredi, M. Bisphosphonate-associated osteonecrosis (BON) of the jaws: A possible treatment? *J. Oral Maxillofac. Surg.* **2006**, *64*, 1460–1462. [[CrossRef](#)]
88. Slade, G.D. Derivation and validation of a short-form oral health impact profile. *Community Dent. Oral Epidemiol.* **1997**, *25*, 284–290. [[CrossRef](#)]
89. Blatt, S.; Krüger, M.; Kämmerer, P.W.; Thiem, D.G.E.; Matheis, P.; Eisenbeiß, A.-K.; Wiltfang, J.; Al-Nawas, B.; Naujokat, H. Non-Interventional Prospective Observational Study of Platelet Rich Fibrin as a Therapy Adjunctive in Patients with Medication-Related Osteonecrosis of the Jaw. *J. Clin. Med.* **2022**, *11*, 682. [[CrossRef](#)]

90. Hamzani, Y.; Chaushu, G. Evaluation of early wound healing scales/indexes in oral surgery: A literature review. *Clin. Implant Dent. Relat. Res.* **2018**, *20*, 1030–1035. [[CrossRef](#)]
91. Thompson, N.; Gordey, L.; Bowles, H.; Parslow, N.; Houghton, P. Reliability and Validity of the Revised Photographic Wound Assessment Tool on Digital Images Taken of Various Types of Chronic Wounds. *Adv. Ski. Wound Care* **2013**, *26*, 360–373. [[CrossRef](#)] [[PubMed](#)]
92. Comas-Calonge, A.; Figueiredo, R.; Escoda, C.G. Surgical treatment vs. conservative treatment in intravenous bisphosphonate-related osteonecrosis of the jaws. Systematic review. *J. Clin. Exp. Dent.* **2017**, *9*, e302–e307. [[CrossRef](#)] [[PubMed](#)]
93. Gindraux, F.; Hofmann, N.; Agudo-Barriuso, M.; Antica, M.; Couto, P.S.; Dubus, M.; Forostyak, S.; Girandon, L.; Gramignoli, R.; Jurga, M.; et al. Perinatal derivatives application: Identifying possibilities for clinical use. *Front. Bioeng. Biotechnol.* **2022**, *10*, 977590. [[CrossRef](#)] [[PubMed](#)]