



HAL
open science

MRI Assessment of Ischemic Lesion Evolution within White and Gray Matter

Lise-Prune Berner, Tae-Hee Cho, Julie Haesebaert, Julien Bouvier, Marlène Wiart, Niels Hjort, Irene Klærke Mikkelsen, Laurent Derex, Götz Thomalla, Salvador Pedraza, et al.

► **To cite this version:**

Lise-Prune Berner, Tae-Hee Cho, Julie Haesebaert, Julien Bouvier, Marlène Wiart, et al.. MRI Assessment of Ischemic Lesion Evolution within White and Gray Matter. *Cerebrovascular Diseases*, 2016, 41 (5-6), pp.291-297. 10.1159/000444131 . hal-03996512

HAL Id: hal-03996512

<https://hal.science/hal-03996512v1>

Submitted on 20 Feb 2023

HAL is a multi-disciplinary open access archive for the deposit and dissemination of scientific research documents, whether they are published or not. The documents may come from teaching and research institutions in France or abroad, or from public or private research centers.

L'archive ouverte pluridisciplinaire **HAL**, est destinée au dépôt et à la diffusion de documents scientifiques de niveau recherche, publiés ou non, émanant des établissements d'enseignement et de recherche français ou étrangers, des laboratoires publics ou privés.

MRI Assessment of Ischemic Lesion Evolution within White and Gray Matter

Lise-Prune Berner^{a, d} Tae-Hee Cho^{b, d} Julie Haesebaert^c Julien Bouvier^{a, d}
Marlène Wiart^{a, d} Niels Hjort^f Irene Klærke Mikkelsen^f Laurent Derex^{b, d}
Götz Thomalla^g Salvador Pedraza^h Leif Østergaard^f Jean-Claude Baron^{e, i}
Norbert Nighoghossian^{b, d} Yves Berthezène^{a, d}

^aDepartment of Neuroradiology, ^bDepartment of Stroke Medicine, and ^cPôle Information Médicale Evaluation Recherche, Hospices Civils de Lyon, ^dCREATIS, CNRS UMR 5220-INSERM U1044, Université Lyon 1 INSA-Lyon, Lyon, and ^eINSERM U894, Université Paris Descartes, Sorbonne Paris Cité, France; ^fCenter of Functionally Integrative Neuroscience, Århus University, Aarhus, Denmark; ^gKlinik und Poliklinik für Neurologie, Kopf- und Neurozentrum, Universitätsklinikum Hamburg-Eppendorf, Hamburg, Germany; ^hDepartment of Radiology (IDI), Girona Biomedical Research Institute (IDIBGI), Hospital Universitari de Girona Dr. Josep Trueta, Girona, Spain; ⁱDepartment of Clinical Neurosciences, University of Cambridge, Cambridge, UK

Key Words

Ischemic stroke · MRI · Diffusion MRI · Perfusion MRI · Gray and white matter

Abstract

Background: In acute ischemic stroke (AIS), gray matter (GM) and white matter (WM) have different vulnerabilities to ischemia. Thus, we compared the evolution of ischemic lesions within WM and GM using MRI. **Methods:** From a European multicenter prospective database (I-KNOW), available T1-weighted images were identified for 50 patients presenting with an anterior AIS and a perfusion weighted imaging (PWI)/diffusion weighted imaging (DWI) mismatch ratio of 1.2 or more. Six lesion compartments were outlined: initial DWI ($b = 1,000 \text{ s/mm}^2$) lesion, initial PWI-DWI mismatch ($T_{\max} > 4 \text{ s}$ and DWI-negative), final infarct mapped on 1-month fluid-attenuated inversion recovery (FLAIR) imaging, lesion growth between acute DWI and 1-month FLAIR, DWI lesion reversal at 1 month and salvaged mismatch. The WM and GM were segmented on T1-weighted images, and all images were co-registered within subjects to the baseline MRI. WM

and GM proportions were calculated for each compartment. **Results:** Fifty patients were eligible for the study. Median delay between symptom onset and baseline MRI was 140 min. The percentage of WM was significantly greater in the following compartments: initial mismatch (52.5 vs. 47.5%, $p = 0.003$), final infarct (56.7 vs. 43.3%, $p < 0.001$) and lesion growth (58.9 vs. 41.2%, $p < 0.001$). No significant difference was found between GM and WM percentages within the initial DWI lesion, DWI reversal and salvaged mismatch compartments. **Conclusions:** Ischemic lesions may extend preferentially within the WM. Specific therapeutic strategies targeting WM ischemic processes may deserve further investigation.

© 2016 S. Karger AG, Basel

Introduction

The different vulnerability of the white matter (WM) and gray matter (GM) compartments to ischemia reflects their distinct thresholds of cerebral blood flow (CBF) and metabolism [1–3]. Neuroprotective and reperfusion ther-

apies aim to salvage the ischemic penumbra. Given the differences in vulnerability to ischemia between GM and WM, it is relevant to quantify ischemic damage separately in each component.

In stroke studies, brain tissue segmentation into GM or WM is usually based on probabilistic maps [3–5], but this does not take into account the inter-individual variability. Furthermore, T1-weighted images are more appropriate for defining these 2 components [6].

The purpose of this study was to compare the baseline and outcome of ischemic lesions within both GM and WM components using individual segmentation based on T1-weighted images.

Methods

Patients and Clinical Data

We analyzed a European multicenter, prospective database of patients who underwent sequential MRI for acute ischemic stroke (AIS) (I-KNOW). Several previously published reports are based on this cohort [7–10]. The inclusion criteria were National Institutes of Health Stroke Scale (NIHSS) score ≥ 4 , diffusion-weighted images (DWI; $b = 1,000$ s/mm²) and perfusion-weighted images (PWI) consistent with an acute anterior circulation ischemic stroke and admission MRI completed within 6 h for patients treated with intravenous tPA or within 12 h if conservative treatment was proposed. No patient received intra-arterial therapy. Exclusion criteria were lacunar or posterior circulation stroke, unknown time of onset and intracerebral hemorrhage on admission MRI. Additional inclusion criteria were applied for the present retrospective analysis: a relevant PWI/DWI mismatch ratio of 1.2 or more [11–14] and available T1-weighted images for individual tissue segmentation.

For each patient, the NIHSS score was assessed at admission and information on age, gender, time from symptom onset to imaging and use of tPA was recorded. The regional ethics committee approved the study, and informed consent was obtained from all patients or their next of kin.

MRI Protocol

At the time of admission, all patients underwent DWI (3 or 12 directions; repetition time $>6,000$ s, field of view 24 cm, matrix 128×128 , slice thickness 3 or 5 mm), fluid-attenuated inversion recovery (FLAIR; repetition time 8,690 ms, echo time 109 ms, inversion time 2,500 ms, flip angle 150° , field of view 21 cm, matrix 224×256 , 24 sections, section thickness 5 mm, slice gap 1 mm) imaging, T2*-weighted gradient echo and T1-weighted spin echo imaging (repetition time 498 ms, echo time 11 ms, flip angle 70° , field of view 172 cm, matrix 384×512 , 24 sections, section thickness 5 mm, slice gap 1 mm), time of flight magnetic resonance angiography and PWI (echo time 30–50 ms, repetition time 1,500 ms, field of view 24 cm, matrix 128×128 , 18 slices, thickness 5 mm with 1 mm gap, gadolinium contrast at 0.1 mmol/kg). A repeat MRI using the same sequences was performed 3 h after the first scan. Follow-up examinations were acquired at 1 month without PWI.

Image Processing and Analysis

Stroke Lesion Segmentation and Definitions

Masks of the acute ischemic lesion on DWI ($b = 1,000$ s/mm² images) were generated semi-automatically by an independent reader using in-house developed software. Post-processing was performed on perfusion data using in-house developed software (Penguin software, MATLAB 2010b; MathWorks Inc., Natick, Mass., USA). After motion correction, perfusion maps were generated using the single value deconvolution method [15] with an arterial input function placed on the contralateral middle cerebral artery. Hypoperfusion was defined as voxels with $T_{\max} \geq 4$ s [14, 16].

The final infarct was mapped on 1-month FLAIR images, excluding pre-existing microangiopathy lesions. Four raters, to whom only acute T2-FLAIR, DWI and ADC images were available, manually outlined the final ischemic lesion. Next, the 4 sets of lesion masks were combined to create a final common lesion mask comprising voxels marked by at least 2 readers. Figure 1 shows an example of the different lesion masks.

Recanalization was evaluated after 3 h using the arterial occlusive lesion (AOL) classification [17] by a rater blinded to clinical data and then dichotomized into absent (AOL 0–1) or present (AOL 2–3).

GM and WM Segmentation

Tissue segmentation was performed using Statistical Parametric Mapping 8 (SPM8; Wellcome Trust Centre for Neuroimaging, University College London, London, UK; <http://www.fil.ion.ucl.ac.uk/spm/>). GM, WM and cerebrospinal fluid (CSF) were segmented on each patient's individual T1-weighted sequence using SPM8 with a threshold of 0.5 [6, 18]. An example of individual segmentation obtained in this study is shown in figure 2.

For each patient, all morphological images, perfusion maps and corresponding lesion masks were co-registered to the initial ADC map using SPM8 and MATLAB (MathWorks Inc., Natick, Mass., USA), and the accuracy of co-registration was visually assessed.

Compartment Definitions

Six tissue compartments were defined: initial ischemic lesion on DWI, initial PWI-DWI mismatch (voxels with $T_{\max} \geq 4$ s but not included in the initial DWI lesion), final infarct, lesion growth (i.e., the difference between the baseline DWI lesion and the final FLAIR lesion), DWI lesion reversal (i.e. voxels included in the initial DWI lesion but not in the final FLAIR lesion) and salvaged mismatch (i.e. voxels with $T_{\max} \geq 4$ s included in the initial mismatch but not in the final FLAIR lesion). The volumes and percentages of GM and WM were calculated for each compartment using a voxel-counting algorithm.

Statistical Analysis

All continuous variables were checked for normal distribution. Continuous variables are presented as mean \pm SD or median and interquartile range (IQR) when variables are not normally distributed, and categorical variables are presented as number (percentage). GM and WM volumes were not normally distributed. We compared the volume in a lesion using the Wilcoxon signed rank test for paired observations. The relationship between lesion growth and percentage of WM in the initial PWI-DWI mismatch was determined using Pearson correlation and linear regression. Subgroup analyses were performed according to recanalization

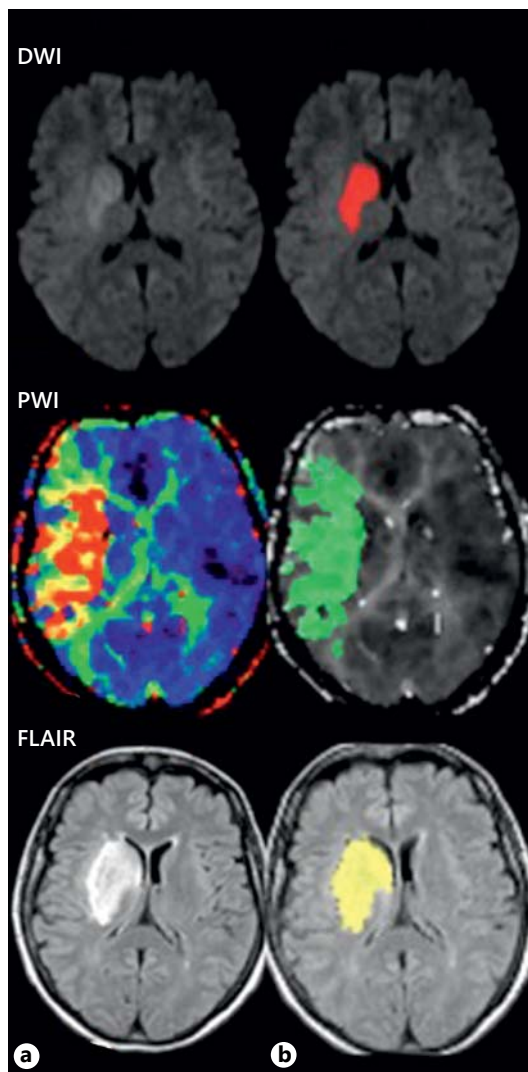


Fig. 1. Example of lesion masks after co-registration to the initial ADC map. **a** Lesion masks were outlined on the initial DWI, PWI (T_{\max} map, threshold 4 s) and 1-month follow-up FLAIR. **b** Next, all images (T_{\max} map and FLAIR) and corresponding lesion masks were co-registered to the initial DWI (ADC map). Note the lower in-plane spatial resolution of the FLAIR images after co-registration.

status. All *p* values were 2-tailed, and values <0.05 were considered significant. Statistical analyses were performed using SAS (version 9.3, SAS Institute Inc., Cary, N.C., USA).

Results

Out of the I-KNOW cohort of 168 patients, 50 were eligible for the present study. Causes for exclusion were incomplete data set ($n = 29$), missing or poor quality T1-

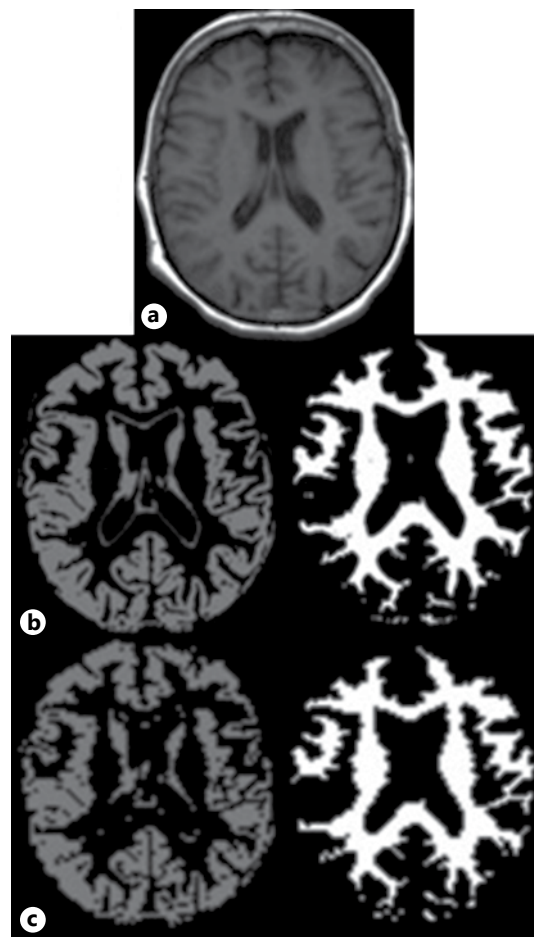


Fig. 2. Individual T1 segmentation. From the original T1-weighted image (**a**), GM (light gray, left) and WM (white, right) masks were obtained after segmentation (**b**) and co-registration to the initial ADC map (**c**).

weighted images ($n = 46$), PWI-DWI mismatch <1.2 or PWI images with artifacts ($n = 37$) and co-registration inaccuracies ($n = 6$). We found no imbalance between included and excluded patients regarding baseline clinical parameters (i.e. age, gender and NIHSS score at admission). The median age was 71 (IQR 56–77) years, and 29 of the patients (58%) were men. The median NIHSS score at admission was 10 (IQR 6–14), and the median time from symptom onset to first imaging was 140 min (IQR 107.5–170.5 min). The initial occlusion level was distal ($>M1$) in 25 patients (50%) and proximal ($\leq M1$) in 20 patients (40%) but could not be assessed in 5 patients.

The median initial DWI lesion and final FLAIR lesion volumes were 10.76 ml (IQR 4.64–19.51 ml) and 13.89 ml (IQR 4.08–28.06 ml), respectively. The median initial mismatch, growth compartment and DWI reversal vol-

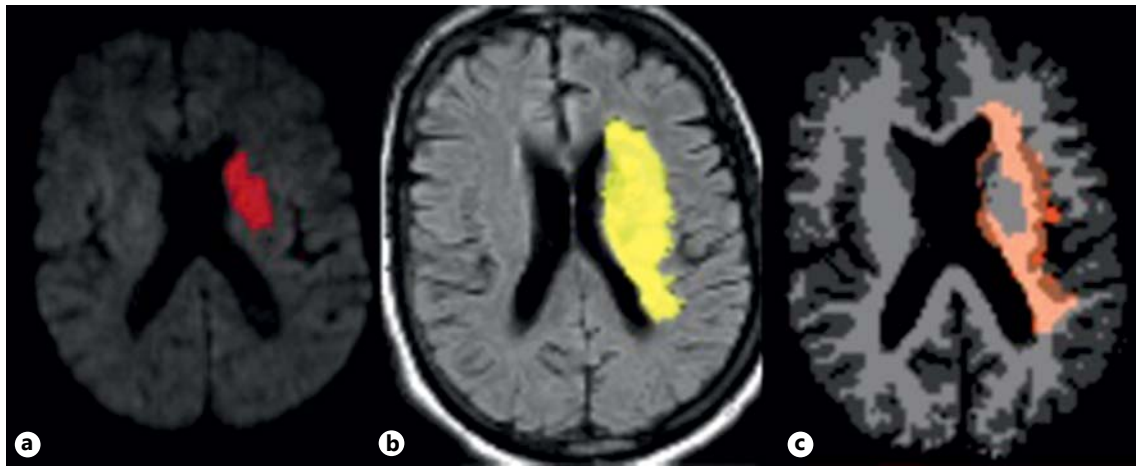


Fig. 3. Example of lesion growth. Mask of the initial DWI lesion (a), final FLAIR lesion (b) and the lesion growth compartment (c, DWI mask subtracted from the FLAIR mask) superimposed on GM/WM segmentation maps after co-registration, showing that the extension of the ischemic lesion predominates in the WM.

Table 1. Percentage of GM and WM in the different compartments

Compartment	GM, %	WM, %	p value
Initial DWI lesion	49.2 (35.6–60.3)	50.9 (39.7–64.4)	0.420
Final FLAIR infarct	43.3 (35.6–48.7)	56.7 (51.3–64.4)	<0.001
Lesion growth	41.2 (30.4–52.0)	58.9 (48.0–69.7)	<0.001
Diffusion reversal	49.1 (0.71–3.12)	50.9 (30.2–63.6)	0.523
Initial PWI-DWI mismatch	47.5 (42.1–40.8)	52.5 (49.2–57.9)	<0.01
Salvaged mismatch	48.5 (43.7–52.4)	51.5 (47.6–56.3)	0.156

Data are presented as median (IQR).

umes were 27.07 ml (IQR 10.32–47.66 ml), 8.31 ml (IQR 1.22–17.2 ml) and 4.17 ml (IQR 1.87–7.04 ml), respectively. The median percentages of GM and WM in each compartment are shown in table 1.

We found no significant difference between the GM and WM percentages within the initial DWI lesion. WM percentages were significantly greater than GM percentages in the following compartments: initial mismatch (52.5 vs. 47.5%, $p = 0.003$), lesion growth (58.9 vs. 41.2%, $p < 0.001$) and final infarct (56.7 vs. 43.3%, $p < 0.001$). Figure 3 shows an example of WM being greater in the lesion growth compartment. GM and WM percentages were not significantly different in the DWI reversal or in the salvaged mismatch compartments.

The percentage of WM in the initial mismatch was not correlated with the percentage of WM in the lesion growth compartment ($\beta = -0.225$; $SE = 0.289$; $p = 0.439$; $R = -0.113$; fig. 4).

Thirty-eight patients (76%) received intravenous tPA. Of the 28 patients assessed for recanalization at 3 h, only 10 patients (36%) exhibited recanalization. Patients without recanalization ($n = 18$) had significantly greater WM percentages in the final infarct (59.2 vs. 40.8%, $p = 0.008$) and lesion growth compartments (60.1 vs. 39.9%, $p = 0.002$).

Discussion

In line with previous studies [1–6], but using individual GM and WM segmentation based on T1-weighted scans, our results confirm the need to assess changes in GM and WM at the acute stage of ischemic stroke separately. WM constitutes approximately 50% of human brain [19]. Thus, the differing evolution of ischemic injuries between GM and WM can be attributed to differ-

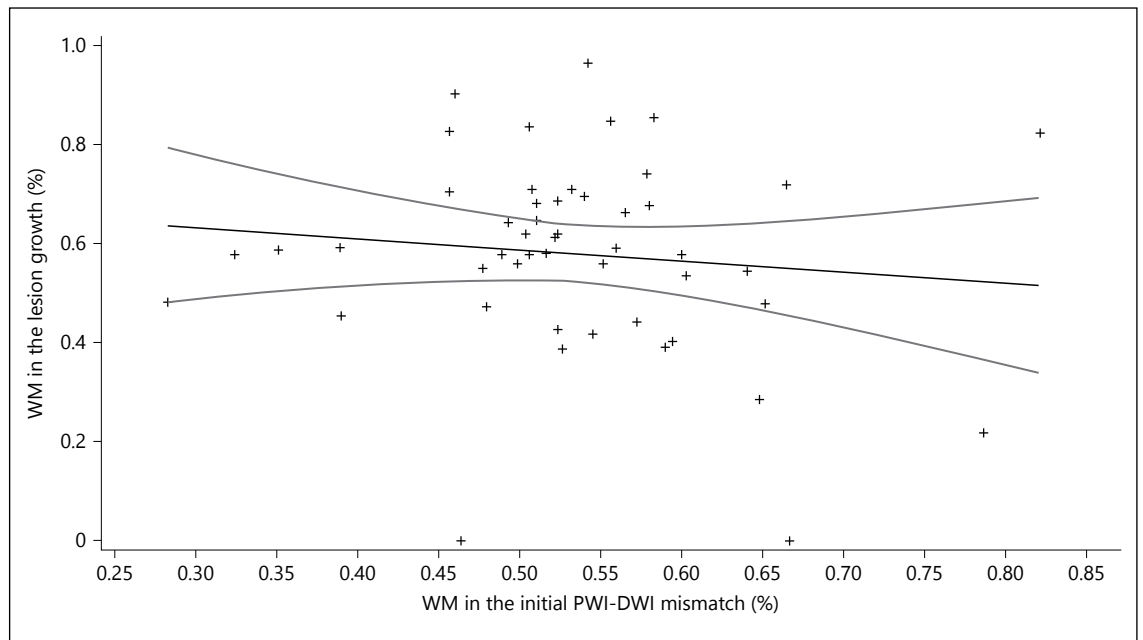


Fig. 4. Scatterplot of percentage of WM in the lesion growth plotted against percentage of WM in the initial PWI-DWI mismatch. Data are presented with regression line and 95% CIs.

ences in structure and metabolism [20]. In our study, WM percentages were significantly larger in the initial mismatch, final infarct and lesion growth compartments, but no baseline difference was found between GM and WM in the initial ischemic core.

We selected patients presenting with a PWI/DWI ratio >1.2 [11–14], excluding small mismatch volumes in order to minimize co-registration and spatial resolution problems. In our study, the mismatch compartment had a significantly greater proportion of WM, suggesting that WM predominates within salvageable tissue. Previous studies using PET or MRI have also suggested that the amount of salvageable tissue is greater within WM [4–6]. This difference is likely due to different ischemic thresholds between GM and WM [1–3, 21] as documented by lower CBV, CBF and ADC infarct thresholds in WM [1, 3].

Ischemic penumbra is a dynamic concept; the infarct grows with time at the expense of the penumbra [22]. As the percentage of WM was significantly more important not only in the mismatch but also in the final infarct and lesion growth compartments, the infarct growth within WM might only reflect the distribution of the mismatch. However, we did not find a significant correlation between the percentage of WM in the mismatch and in the lesion growth, suggesting that the differing evolution be-

tween GM and WM might not be only due to the initial mismatch distribution.

These results are consistent with the post-ischemic cascade differing between WM and GM components [20, 23]. Initially, increased resistance of WM to ischemia can be supported by protective mechanisms due to GABA receptor and adenosine accumulation [4, 24], but after the mechanisms of the ischemic cascade are triggered, both axons and oligodendrocytes exhibit rapid structural changes, including cytoskeletal breakdown of axons and oligodendrocyte swelling [25]. WM injuries may also in part result from the destruction of white fiber tracts related to irreversibly damaged GM regions, but this issue could not be evaluated on the standard MRI sequences available.

In addition to reperfusion therapies, the development of neuroprotective strategies is an important issue in stroke treatment [26]. Although many positive trials have investigated neuroprotective molecules in animal models, none have translated effectively to humans [20, 26]. One reason could be the inability of the molecules to prevent WM damage [23]. Most of these molecules have been tested in rodents, in which GM represents only $\sim 80\%$ of the brain volume versus 50% in humans [19]. Thus, they were probably more efficient at preventing GM damage than WM damage, and neuroprotective tri-

als have been found to focus less on protecting WM [20, 23].

We did not find any difference between GM and WM volumes in the reversible abnormalities (salvaged mismatch and diffusion lesion reversal compartments). Similarly, Koga et al. [6] found an equal proportion of GM and WM salvaged at 3 months. Conversely, Tisserand et al. [5] analyzed large reversal acute DWI (RAD) lesions (>10 ml) and showed that WM was more prone to early diffusion lesion reversal after thrombolysis. This difference might be explained by the smaller median RAD volume in our study and by the fact that the frequency and amount of DWI reversal are still unclear and remain a matter of debate [27, 28].

Few studies have evaluated the differences between GM and WM based on individual segmentation [1, 2]. In most AIS studies, segmentation of the GM and WM is generally based on a probabilistic map [3–6, 21, 23] because T1-weighted images are not part of a standard stroke MRI protocol [5, 6]. To the best of our knowledge, this is the first study to analyze the differences between GM and WM using T1-weighted images, which are considered the reference for anatomical tissue segmentation. However, the main limitations of this approach are the need to set a probability threshold to classify voxels into one of the 3 categories (GM, WM or CSF) and potential partial volume effects related to the thickness of the T1-weighted axial slices. Three-dimensional high-resolution T1 acquisitions would have been more appropriate for accurate segmentation but would have been too time consuming in the acute stroke setting.

Co-registration of DWI and PWI images allows a more precise estimation of mismatch volumes and is important for accurate assessment of lesion volume changes over time [13, 29]. However, co-registration

analyses may be hampered by several limitations including errors due to motion artefacts or structural changes such as hemorrhagic transformation or tissue shrinkage [29] and lower spatial resolution after co-registration.

The limitations of our study mainly relate to the retrospective nature of the analysis in a heterogeneous and limited sample. Absolute volumes were relatively small, and the clinical significance of the difference in WM versus GM proportions remains debatable. I-KNOW was not designed to assess the efficacy of intravenous thrombolysis, and treatment allocation was not randomized or otherwise controlled. Thus, no conclusion can be made about the effect of treatment with intravenous thrombolysis. We could not take into account some possible confounding factors, such as the effects of recanalization, and no conclusion could be drawn regarding the response to thrombolysis because the number of patients in each group was too small to reach significance. So, larger prospective cohorts are required to confirm these results in patients treated with reperfusion therapies.

In conclusion, the present results suggest that ischemic lesions may extend preferentially within WM. The development of therapeutic strategies targeting WM ischemic injuries may deserve further investigation.

Sources of Funding

This work was supported by the European Commission's Sixth Framework Program (grant 027294).

Disclosures Statement

None to declare.

References

- 1 Bristow MS, Simon JE, Brown RA, Eliasziw M, Hill MD, Coutts SB, Frayne R, Demchuk AM, Mitchell JR: MR perfusion and diffusion in acute ischemic stroke: human gray and white matter have different thresholds for infarction. *J Cereb Blood Flow Metab* 2005;25:1280–1287.
- 2 Simon JE, Bristow MS, Lu H, Lauzon ML, Brown RA, Manjón JV, Eliasziw M, Frayne R, Buchan AM, Demchuk AM, Mitchell JR; Calgary Stroke Program: A novel method to derive separate gray and white matter cerebral blood flow measures from MR imaging of acute ischemic stroke patients. *J Cereb Blood Flow Metab* 2005;25:1236–1243.
- 3 Arakawa S, Wright PM, Koga M, Phan TG, Reutens DC, Lim I, Gunawan MR, Ma H, Perera N, Ly J, Zavala J, Fitt G, Donnan GA: Ischemic thresholds for gray and white matter: a diffusion and perfusion magnetic resonance study. *Stroke* 2006;37:1211–1216.
- 4 Falcao AL, Reutens DC, Markus R, Koga M, Read SJ, Tochon-Danguy H, Sachinidis J, Howells DW, Donnan GA: The resistance to ischemia of white and gray matter after stroke. *Ann Neurol* 2004;56:695–701.
- 5 Tisserand M, Malherbe C, Turc G, Legrand L, Edjlali M, Labeyrie MA, Seners P, Mas JL, Méder JF, Baron JC, Oppenheim C: Is white matter more prone to diffusion lesion reversal after thrombolysis? *Stroke* 2014;45:1167–1169.
- 6 Koga M, Reutens DC, Wright P, Phan T, Markus R, Pedreira B, Fitt G, Lim I, Donnan GA: The existence and evolution of diffusion-perfusion mismatched tissue in white and gray matter after acute stroke. *Stroke* 2005;36:2132–2137.

- 7 Alawneh JA, Jones PS, Mikkelsen IK, Cho TH, Siemonsen S, Mouridsen K, Ribe L, Morris RS, Hjort N, Antoun N, Gillard JH, Fiehler J, Nighoghossian N, Warburton EA, Østergaard L, Baron JC: Infarction of 'non-core-non-penumbra' tissue after stroke: multivariate modelling of clinical impact. *Brain* 2011; 134(pt 6):1765–1776.
- 8 Carrera E, Jones PS, Alawneh JA, Klærke Mikkelsen I, Cho TH, Siemonsen S, Guadagno JV, Mouridsen K, Ribe L, Hjort N, Fryer TD, Carpenter TA, Aigbirhio FI, Fiehler J, Nighoghossian N, Warburton EA, Østergaard L, Baron JC: Predicting infarction within the diffusion-weighted imaging lesion: does the mean transit time have added value? *Stroke* 2011;42:1602–1607.
- 9 Hermitte L, Cho TH, Ozenne B, Nighoghossian N, Mikkelsen IK, Ribe L, Baron JC, Østergaard L, Derex L, Hjort N, Fiehler J, Pedraza S, Hermier M, Maucort-Boulch D, Berthezène Y: Very low cerebral blood volume predicts parenchymal hematoma in acute ischemic stroke. *Stroke* 2013;44:2318–2320.
- 10 Cheng B, Forkert ND, Zavaglia M, Hilgetag CC, Golsari A, Siemonsen S, Fiehler J, Pedraza S, Puig J, Cho TH, Alawneh J, Baron JC, Østergaard L, Gerloff C, Thomalla G: Influence of stroke infarct location on functional outcome measured by the modified Rankin scale. *Stroke* 2014;45:1695–1702.
- 11 Davis SM, Donnan GA, Parsons MW, Levi C, Butcher KS, Peeters A, Barber PA, Bladin C, De Silva DA, Byrnes G, Chalk JB, Fink JN, Kimber TE, Schultz D, Hand PJ, Frayne J, Hankey G, Muir K, Gerraty R, Tress BM, Desmond PM; EPITHET Investigators: Effects of alteplase beyond 3 h after stroke in the echoplanar imaging thrombolytic evaluation trial (EPITHET): a placebo-controlled randomised trial. *Lancet Neurol* 2008;7:299–309.
- 12 Albers GW, Thijs VN, Wechsler L, Kemp S, Schlaug G, Skalabrin E, Bammer R, Kakuda W, Lansberg MG, Shuaib A, Coplin W, Hamilton S, Moseley M, Marks MP; DEFUSE Investigators: Magnetic resonance imaging profiles predict clinical response to early reperfusion: the diffusion and perfusion imaging evaluation for understanding stroke evolution (DEFUSE) study. *Ann Neurol* 2006;60: 508–517.
- 13 Ogata T, Christensen S, Nagakane Y, Ma H, Campbell BC, Churilov L, Lansberg MG, Straka M, De Silva DA, Mlynash M, Bammer R, Olivot JM, Desmond PM, Albers GW, Davis SM, Donnan GA; EPITHET and DEFUSE Investigators: The effects of alteplase 3 to 6 hours after stroke in the EPITHET-DEFUSE combined dataset: post hoc case-control study. *Stroke* 2013;44:87–93.
- 14 Campbell BC, Macrae IM: Translational perspectives on perfusion-diffusion mismatch in ischemic stroke. *Int J Stroke* 2013;10:153–162.
- 15 Østergaard L, Sorensen AG, Kwong KK, Weisskoff RM, Gyldensted C, Rosen BR: High resolution measurement of cerebral blood flow using intravascular tracer bolus passages. Part II: experimental comparison and preliminary results. *Magn Reson Med* 1996;36:726–736.
- 16 Olivot JM, Mlynash M, Thijs VN, Kemp S, Lansberg MG, Wechsler L, Bammer R, Marks MP, Albers GW: Optimal Tmax threshold for predicting penumbral tissue in acute stroke. *Stroke* 2009;40:469–475.
- 17 Khatri P, Neff J, Broderick JP, Khoury JC, Carrozzella J, Tomsick T; IMS-I Investigators: Revascularization end points in stroke interventional trials: recanalization versus reperfusion in IMS-I. *Stroke* 2005;36:2400–2403.
- 18 Cocosco CA, Zijdenbos AP, Evans AC: A fully automatic and robust brain MRI tissue classification method. *Med Image Anal* 2003;7: 513–527.
- 19 Zhang K, Sejnowski TJ: A universal scaling law between gray matter and white matter of cerebral cortex. *Proc Natl Acad Sci U S A* 2000;97:5621–5626.
- 20 Matute C, Domercq M, Pérez-Samartín A, Ransom BR: Protecting white matter from stroke injury. *Stroke* 2013;44:1204–1211.
- 21 Payabvash S, Souza LC, Wang Y, Schaefer PW, Furie KL, Halpern EF, Gonzalez RG, Lev MH: Regional ischemic vulnerability of the brain to hypoperfusion: the need for location specific computed tomography perfusion thresholds in acute stroke patients. *Stroke* 2011;42:1255–1260.
- 22 Baron JC: Mapping the ischaemic penumbra with PET: implications for acute stroke treatment. *Cerebrovasc Dis* 1999;9:193–201.
- 23 Ho PW, Reutens DC, Phan TG, Wright PM, Markus R, Indra I, Young D, Donnan GA: Is white matter involved in patients entered into typical trials of neuroprotection? *Stroke* 2005; 36:2742–2744.
- 24 Dohmen C, Kumura E, Rosner G, Heiss WD, Graf R: Adenosine in relation to calcium homeostasis: comparison between gray and white matter ischemia. *J Cereb Blood Flow Metab* 2001;21:503–510.
- 25 Dewar D, Yam P, McCulloch J: Drug development for stroke: importance of protecting cerebral white matter. *Eur J Pharmacol* 1999; 375:41–50.
- 26 Saver JL, Starkman S, Eckstein M, Stratton SJ, Pratt FD, Hamilton S, Conwit R, Liebeskind DS, Sung G, Kramer I, Moreau G, Goldweber R, Sanossian N; FAST-MAG Investigators and Coordinators: Prehospital use of magnesium sulfate as neuroprotection in acute stroke. *N Engl J Med* 2015;372:528–536.
- 27 Campbell BC, Purushotham A, Christensen S, Desmond PM, Nagakane Y, Parsons MW, Lansberg MG, Mlynash M, Straka M, De Silva DA, Olivot JM, Bammer R, Albers GW, Donnan GA, Davis SM; EPITHET-DEFUSE Investigators: The infarct core is well represented by the acute diffusion lesion: sustained reversal is infrequent. *J Cereb Blood Flow Metab* 2012;32:50–56.
- 28 Sakamoto Y, Kimura K, Shibazaki K, Inoue T, Uemura J, Aoki J, Sakai K, Iguchi Y: Early ischaemic diffusion lesion reduction in patients treated with intravenous tissue plasminogen activator: infrequent, but significantly associated with recanalization. *Int J Stroke* 2013;8:321–326.
- 29 Nagakane Y, Christensen S, Brekenfeld C, Ma H, Churilov L, Parsons MW, Levi CR, Butcher KS, Peeters A, Barber PA, Bladin CF, De Silva DA, Fink J, Kimber TE, Schultz DW, Muir KW, Tress BM, Desmond PM, Davis SM, Donnan GA; EPITHET Investigators: EPITHET: positive result after reanalysis using baseline diffusion-weighted imaging/perfusion-weighted imaging co-registration. *Stroke* 2011;42:59–64.