



**HAL**  
open science

# The contribution of visual areas to speech comprehension: a PET study in cochlear implants patients and normal-hearing subjects

Anne Lise Giraud, Eric Truy

► **To cite this version:**

Anne Lise Giraud, Eric Truy. The contribution of visual areas to speech comprehension: a PET study in cochlear implants patients and normal-hearing subjects. *Neuropsychologia*, 2002, 40 (9), pp.1562-1569. 10.1016/S0028-3932(02)00023-4 . hal-03995081

**HAL Id: hal-03995081**

**<https://hal.science/hal-03995081v1>**

Submitted on 17 Feb 2023

**HAL** is a multi-disciplinary open access archive for the deposit and dissemination of scientific research documents, whether they are published or not. The documents may come from teaching and research institutions in France or abroad, or from public or private research centers.

L'archive ouverte pluridisciplinaire **HAL**, est destinée au dépôt et à la diffusion de documents scientifiques de niveau recherche, publiés ou non, émanant des établissements d'enseignement et de recherche français ou étrangers, des laboratoires publics ou privés.



Distributed under a Creative Commons Attribution - NonCommercial - NoDerivatives 4.0 International License



# The contribution of visual areas to speech comprehension: a PET study in cochlear implants patients and normal-hearing subjects

Anne Lise Giraud<sup>a,\*</sup>, Eric Truy<sup>b</sup>

<sup>a</sup> *Physiology and Neurology Departments, J.W. Goethe University, Theodor Stern Kai 7, 60590 Frankfurt am Main, Germany*

<sup>b</sup> *UMR CNRS 5020, Hôpital Edouard Herriot, Pavillon U, 3 Place d'Arsonval, 69003 Lyon, France*

Received 28 September 2001; received in revised form 21 January 2002; accepted 23 January 2002

## Abstract

Early visual cortex can be recruited by meaningful sounds in the absence of visual information. This occurs in particular in cochlear implant (CI) patients whose dependency on visual cues in speech comprehension is increased. Such cross-modal interaction mirrors the response of early auditory cortex to mouth movements (speech reading) and may reflect the natural expectancy of the visual counterpart of sounds, lip movements. Here we pursue the hypothesis that visual activations occur specifically in response to meaningful sounds. We performed PET in both CI patients and controls, while subjects listened either to their native language or to a completely unknown language. A recruitment of early visual cortex, the left posterior inferior temporal gyrus (ITG) and the left superior parietal cortex was observed in both groups. While no further activation occurred in the group of normal-hearing subjects, CI patients additionally recruited the right perirhinal/fusiform and mid-fusiform, the right temporo-occipito-parietal (TOP) junction and the left inferior prefrontal cortex (LIPF, Broca's area). This study confirms a participation of visual cortical areas in semantic processing of speech sounds. Observation of early visual activation in normal-hearing subjects shows that auditory-to-visual cross-modal effects can also be recruited under natural hearing conditions. In cochlear implant patients, speech activates the mid-fusiform gyrus in the vicinity of the so-called face area. This suggests that specific cross-modal interaction involving advanced stages in the visual processing hierarchy develops after cochlear implantation and may be the correlate of increased usage of lip-reading. © 2002 Published by Elsevier Science Ltd.

*Keywords:* Languages; Auditory; Brain imaging; Deafness; Semantics

## 1. Introduction

In previous studies performed in subjects using a cochlear implant (CI) we found an engagement of early visual cortex in response to speech [17]. This effect was ascribed to automatic expectancy of the visual counterpart of sounds in subjects who are used to resort to visual cues, e.g. lip-reading, to compensate for degraded auditory information [19]. These observations are comparable to the recruitment of the early auditory cortex when subjects watch people mouthing speech in the absence of auditory input [5,6,26,40,41,43]. However, the absence of systematic visual activation in control subjects performing the same task as CI patients [17,19] indicates that cross-modal interaction is not necessarily engaged by tasks where speech is clearly perceived.

As visual activation did not occur in response to noises, our studies suggested that visual activations were related

to the meaning of sounds, perhaps through association with internal images, including images of phonological sounds expressed by mouth movements. This hypothesis is supported by other imaging data showing early visual activation during semantic tasks with purely auditory input [3]. In this study, we sought to confirm the involvement of visual regions during speech processing and establish their participation in the processing of meaning rather than familiarity of speech. We contrasted a condition where both proficient CI patients and normal-hearing subjects listened to their native language (L1) with a condition where they listened to an unknown language (L3) produced by the same speaker at the same rate. Based on studies suggesting that semantic activations do not significantly differ between first and second languages [24], we controlled for an effect of familiarity of native speech stimuli, using an intermediate condition where subjects listened to a second language (L2). This language was rarely practised (non-familiar) but could nonetheless be correctly understood under scanning conditions. Thus, semantic-related activations present in both contrasts L1 > L3 and L2 > L3 could be distinguished from pure effects of familiarity probed by L1 > L2.

\* Corresponding author. Tel.: +49-69-6301-6895;

fax: +49-69-6301-6842.

E-mail address: giraud@em.uni-frankfurt.de (A.L. Giraud).

## 2. Methods

Six normal-hearing subjects and six post-lingually deaf CI patients took part in the study that was approved by the local ethics committee (Hospices Civils de Lyon, France). All subjects used French as their first language. Patients were selected among the 10% best performers. Selection was based on intelligibility performance during clinical tests (scores for consonant–nucleus–consonant word discrimination better than 60% and for sentence comprehension better than 90%). From this initial selection, we retained for the PET experiment only those patients who had sentence comprehension better than 90% (correctly repeated phonemes) under scanning conditions (head in the scanner, see Section 3.1).

The mean duration of profound deafness prior to implantation was 2.33 years. Patients had a rehabilitation time ranging from 18 months to 5 years. Four were implanted on the right side, two on the left. Four had a Nucleus Spectra 22 (Cochlear), two had a Digisonic (MXM) implant. The implants had between 15 and 22 functioning electrodes.

Regional cerebral blood flow was assessed by recording cerebral radioactivity following the i.v. injection of  $H_2^{15}O$ . This study was part of a larger protocol during which patients and controls received 14 injections of 9 mCi [17]. Here, we describe results based on six injections per subject. PET images were acquired parallel to the bicommissural (AC-PC) plane, using a Siemens CTI HR+ camera. The counts were integrated over a period of 60 s after the detected activity in the head had reached 400% of background noise. Stimuli started 10 s before the acquisition period and lasted 70 s. Standardised procedures of realignment, normalisation, smoothing (16 mm Gaussian filter) and statistical analysis were performed using statistical parametric mapping (SPM97, Wellcome Department of Cognitive Neurology, London, UK) implemented in Matlab 4.0 software (Mathworks, Sherborne, MA, USA).

Subjects listened with eyes closed to digitised natural speech stimuli generated by the same trilingual female speaker: French sentences (L1), English sentences (L2) and Norwegian sentences (L3) delivered at constant rate. Normal prosody was respected (140 words/min), but the mean rate of the whole sequence was two syllables/s (14 sentences, mean number of syllables per sentence = 10, one sentence every 5 s). A slow presentation rate was used to ensure equal comprehension in normals and patients and across languages. Stimuli were delivered in free field with loudspeakers located behind subjects in the PET camera. The sound level was set to be comfortable for each subject and optimise speech comprehension with the implant. Subjects were instructed to listen carefully to speech stimuli to be able to answer questions after the scans. No response was required during data collection, but a series of 10 questions were asked post-hoc. Subjects were not informed prior to scanning about the language used.

### 2.1. Data analysis

We modelled each subject individually and all seven conditions of the protocol (corresponding to 14 scans per subject) although we report only results related to three conditions. Contrasts between conditions and groups were assessed using the parameter estimates corresponding to each subject and condition. The statistics were performed on one sample per subject and condition, thus meeting the requirements for a random-effects analysis. Our contrast of interest,  $L1 > L3$ , was assessed in each group separately (with  $P < 0.001$ , uncorrected). A conjunction analysis [39] between the two groups was also calculated. The conjunction was masked by each single contrast at a level of 0.05 for each contributing mask, which yields a  $P < 0.001$  for the whole masking procedure. We also assessed the differences between groups (CI patients  $>$  controls and controls  $>$  CI patients;  $P < 0.001$ ). The interaction was masked (inclusive,  $P < 0.001$ ) by the main effect of interest ( $L3-L1$  in patients, and  $L3-L1$  in controls, respectively) to ensure that we detect effects corresponding to a true increase in blood flow in the group of interest. We additionally analysed the effects of  $L1 > L2$  and  $L2 > L3$  in both groups to determine whether the effect of interest ( $L3-L1$ ) was related to comprehension ( $L2 > L3$ ) or familiarity ( $L1 > L2$ ).

## 3. Results

### 3.1. Behavioural data

Prior to the experiment, we assessed speech comprehension for L1 and L2, under scanning conditions (head in the PET camera), in both groups and languages. Subjects were exposed to a set of sentences (20 sentences per language) and asked to repeat. The percentage of correct phoneme repetition was calculated. Normal subjects achieved 100% correct repetition in French and English, patients 97% in French and 95% in English. Three patients confused some words in English, the others repeated perfectly. None of them reported not having understood a sentence. To preserve complete novelty of the unknown language, subjects were not pre-exposed to Norwegian sentences. All subjects confirmed after the experiment that they had never been exposed to the Norwegian language before.

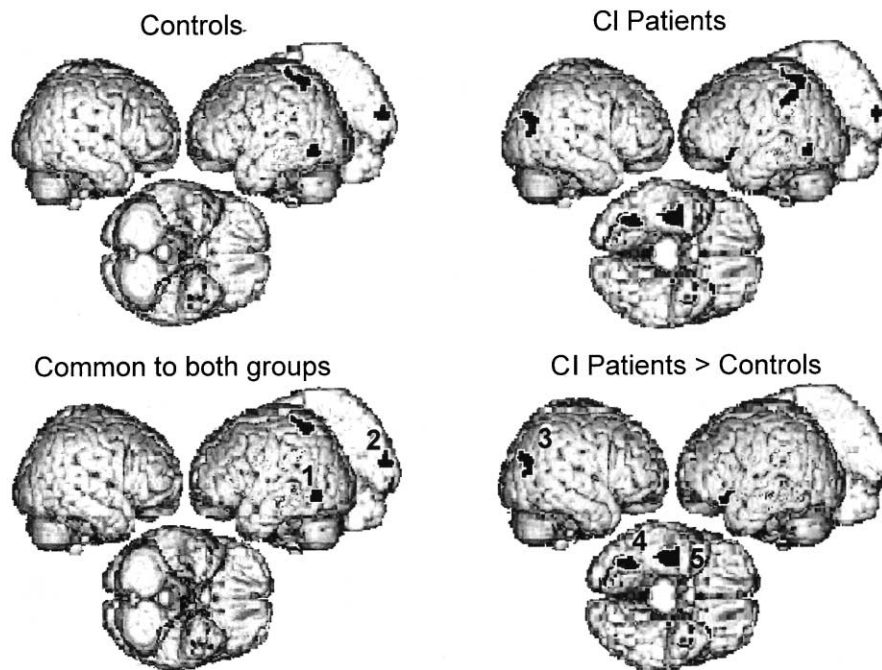
After each scan, subjects were asked to repeat complete sentences, and fill incomplete sentences with the correct missing word. We rated their performance on a scale ranging from 1 to 10. Controls scored 10 and 9.8, and patients 9.6 and 9.7 in French and English, respectively. These observations indicate that patients and controls understood the meaning of the sentences almost equally well. Thus, observed differences in brain activity are unlikely to be related to group differences in speech comprehension. In order to ensure that all conditions were treated with a similar attentional load we also informed subjects prior to the scans with L3 that we

Table 1  
Regions activated when native (L1) is contrasted with unknown language (L3), in controls (C) and rehabilitated cochlear implant (P)

| Anat. Region          | B.A.  | Patients L1–L3   |     | Controls L1–L3   |     | Conjunction (P&C) |            | Interaction (P>C) |     | Interaction (C>P) |   | Familiarity         |                     | Comprehension       |                     |      |
|-----------------------|-------|------------------|-----|------------------|-----|-------------------|------------|-------------------|-----|-------------------|---|---------------------|---------------------|---------------------|---------------------|------|
|                       |       | Co-ordinates (Z) |     | Co-ordinates (Z) |     | Co-ordinates (Z)  |            | Co-ordinates (Z)  |     | Co-ordinates (Z)  |   | Patients<br>L1>L2 Z | Controls<br>L1>L2 Z | Patients<br>L2>L3 Z | Controls<br>L2>L3 Z |      |
| Left post. inf. temp. | 21/37 | –42              | –58 | –4 (3.63)        | –44 | –58               | –6 (3.48)  | –42               | –58 | –4 (3.83)         | * | *                   | ns                  | ns                  | 3.25                | 3.10 |
| Right occipital       | 18    | 14               | –82 | 10 (3.52)        | 22  | –90               | –14 (3.25) | 16                | –88 | –12 (3.65)        | * | *                   | ns                  | ns                  | 3.20                | 3.02 |
| Left sup. parietal    | 7     | –28              | –50 | 58 (3.13)        | –34 | –40               | 58 (3.21)  | –28               | –48 | 60 (3.53)         | * | ns                  | 3.1                 | ns                  | ns                  | 3.12 |
| Right T-O-P junct.    | 39    | 42               | –68 | 24 (3.91)        | *   | *                 | *          | 42                | –68 | 24 (3.26)         | * | *                   | ns                  | ns                  | 3.1                 | ns   |
| Right ant. fusiform   | 20/36 | 38               | –20 | –26 (4.69)       | *   | *                 | *          | 36                | –16 | –28 (3.18)        | * | *                   | ns                  | ns                  | 4.57                | ns   |
| Right fusiform        | 37    | 34               | –60 | –16 (4.03)       | *   | *                 | *          | 34                | –60 | –16 (3.10)        | * | *                   | ns                  | ns                  | 3.37                | ns   |
| LIPF                  | 47    | –34              | 24  | –14 (4.34)       | *   | *                 | *          | –28               | –16 | –12 (3.74)        | * | *                   | 3.70                | ns                  | ns                  | ns   |

$p < 0.001$ . We additionally report the statistical levels of the contrasts L1>L2 (low familiar second language) and L2>L3 to determine whether the effects came from comprehension (L2>L3) and/or familiarity (L1>L2).

## (A) Native Language (French) - Unknown Language (Norwegian)



## (B) Controls Patients

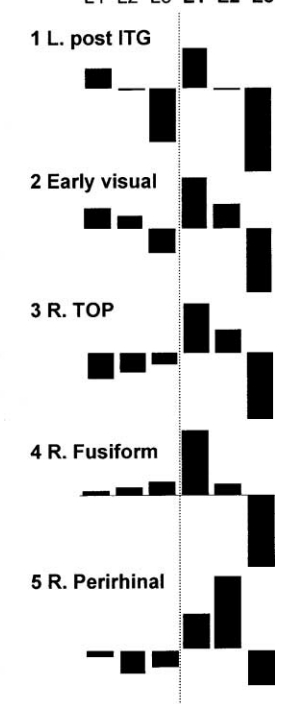


Fig. 1. (A) Brain regions ( $P < 0.001$ , uncorrected) recruited when listening to native language (French) relative to an unknown language (Norwegian); (B) relative cerebral blood flow in the five regions where the activation was mostly related to the meaning rather than familiarity of sounds; 1, left temporo-occipital junction; 2, early visual cortex; 3, right TOP junction; 4, right mid-fusiform; 5, right perirhinal region.

would ask questions, and did so after the scans although we did not evaluate their responses, e.g. ‘did you notice interrogative forms?’, ‘did you recognise some words’, etc.

### 3.2. Neuroimaging data

In both CI patients and normal-hearing controls, listening to the native language (i.e. L1) activated the left posterior inferior temporal gyrus (ITG), the left superior parietal and the right occipital cortices more than listening to a language that was never heard before (L3). No further brain region was specifically recruited by controls but the CI patients additionally recruited the right temporo-occipito-parietal (TOP) junction, the right anterior fusiform/perirhinal region, the right mid-fusiform and the left inferior prefrontal cortex (LIPF, see Fig. 1).

The contrast L2 > L3 that probed comprehension of an understood but not very familiar language revealed a significant effect ( $P < 0.001$ ) in the left posterior ITG and the right occipital cortex in both groups and, only in patients, in the right TOP and the right fusiform gyrus (anterior and posterior clusters). The contrast L1 > L2 that probes an effect of familiarity of language was significant ( $P < 0.001$ ) in the LIPF in patients. An effect of mixed origin, i.e. detected in both contrasts probing for familiarity and comprehension, was detected in the left superior parietal cortex that was recruited by both controls and patients (see Table 1).

## 4. Discussion

Effects associated with the meaning of speech, as probed by the contrast between native and unknown language, were detected in the left posterior ITG, in the right TOP, the right anterior fusiform/perirhinal, the right mid-fusiform gyrus and the early visual cortex. These regions are multi-modal semantic areas [30,31,47] with the exception of the two latter which respond best to simple or complex visual stimuli [10,16]. We discuss next the function of these regions in semantic processing and the specific role they can play in patients using a CI implant.

The implication of the left posterior ITG (recruited by both groups of subjects) in multi-modal semantic processing has been shown by other studies [3,48,50]. The role proposed for this region is to allow the semantic system to access stored lexical information [15] and retrieve implicitly or explicitly the name of a concept [38]. A recruitment of this region by both groups of subjects in both L1 > L3 and L2 > L3 is consistent with access to lexical information that occurs while understanding sentences in languages that are understood but not when listening to an unknown language.

The activation specific to CI patients in the right anterior fusiform/perirhinal region confirms prior imaging and electrophysiological data showing that this region is sensitive to the semantic content of words [33,51]. We repeatedly observed activation in the right and left fusiform/perirhinal

region in CI in our previous studies in particular when we contrasted environmental sounds and words with syllables and thus tapped semantic activation [17,20]. Based on other experimental data showing that this region interfaces between visual perception and encoding of stimuli [4,27,42] and results of Wise et al. [51], showing that the perirhinal area is sensitive to noun imageability whatever the modality of input, we speculate that activation of this region in CI patients was somehow related to the evocation and/or manipulation of internal images corresponding to sounds. This is consistent with the concrete content of the sentences presented to the subjects during PET scanning. In CI patients, an enhanced manipulation of internal images in response to sounds could conceivably be induced by long-term training in audio–visual matching to compensate for the degradation of the sounds coming from the implant.

We found further evidence for enhanced manipulation of visual representations of speech sounds in CI patients. The activation located more posteriorly in the fusiform gyrus partially overlaps with the “fusiform face area” (see Fig. 2), a region of the visual ventral stream specific to face processing [16,21,23,25,40]. Activation of the face area in response to degraded speech coming from an implant can be seen as a counterpart to the recruitment of association auditory cortices in response to faces mouthing speech [5,41]. As after implantation patients are confronted with completely new sounds, *de novo* pairing between sounds and their visual source is required. Even years after

implantation, patients keep on relying on visual cues to distinguish ambiguous sounds [22,39,46]. With respect to speech perception, lip-reading is the main visual source of information. It allows patients to discriminate speech events with very similar temporal macro-structure such as words that differ only by the placement of the point of articulation, e.g. buck/duck [11,45]. The chronic use of lip-reading is likely to generate a set of representations of speech sounds, stored in the form of mouth movement sequences that should involve to some extent the face area. By virtue of cross-modal binding [28], such representations could be activated by speech alone. Moreover, they should be limited to the set of phonological sounds patients have been trained to recognise after implantation, and therefore be selective to the native language. Consistent with this, we observed a large response in the right fusiform region for L1, a very weak response for L2 and a relative deactivation for L3.

Visual responses to sounds were primarily observed in early visual areas [19]. Despite stronger visual responses in patients, co-localised effects were also detected in normal-hearing subjects. These results confirm auditory-to-visual cross-modal effects that were previously observed in response to words [17,19,20]. We additionally show that these effects are associated with meaningful stimuli [3]. Visual effects in normal-hearing subjects show that the recruitment of visual regions in sound processing does not merely depend on cross-modal reorganisation occurring during deafness [1,32], but rather participates in a

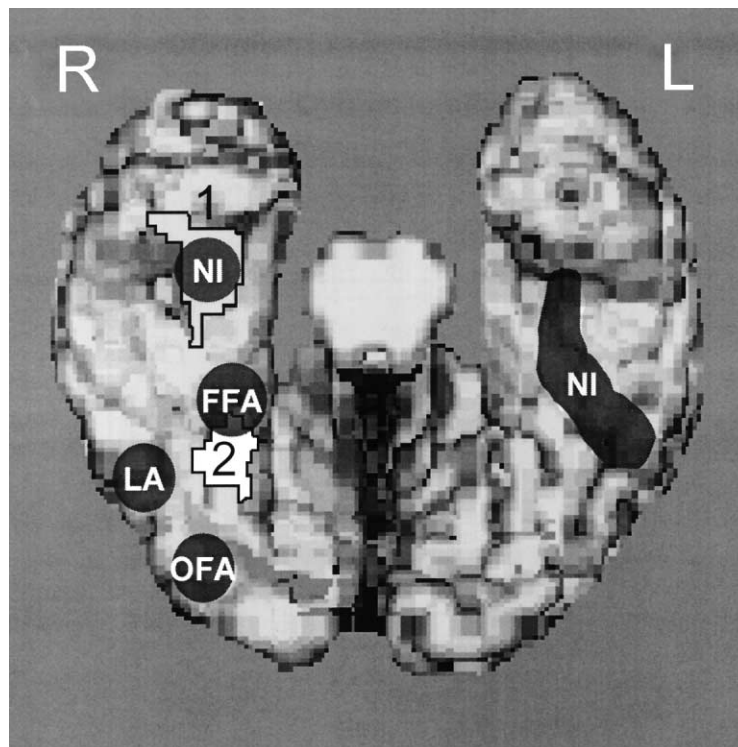


Fig. 2. Surface view of the inferior temporal lobe. Localisation of the peaks obtained in this study: 1, perirhinal; 2, mid-fusiform in relation with activations of the same region in former studies; NI, noun imageability (after [51]); FFA, fusiform face area; LA, letter area; OFA, occipital face area (after [16]).

physiological mechanism that allows auditory and visual information to be bound together. As suggested by behavioural data showing an increase in lip-reading performance after cochlear implantation [19], cross-modal cooperation is enhanced after cochlear implantation.

Given the lack of direct anatomical connections between the auditory pathways and early visual regions, visual activation should be mediated indirectly via supra-modal higher order associative areas. Activation of the superior parietal region in both groups of subjects supports this hypothesis. This area, associated with attentional control [8,29,36] and directed visual attention [7], could mediate cross-modal effects [44], e.g. automatic expectancy for the visual complement of sounds as observed after specific cross-modal learning [28]. This hypothesis is also consistent with our former findings showing that the activation of early visual cortex was correlated with that of the left superior parietal cortex [20]. However, this region did not show the same specificity in the two groups. It was associated with semantic processing in controls ( $L2 > L3$ ) and with familiarity in patients ( $L1 > L2$ ).

Another semantic-related activation was detected in the right TOP junction, in patients only. Bilateral TOP junction has been associated with lexical-semantic processing in many former studies [9,13,14,21,30,37,50]. In a previous study, we observed decreased rather than increased activity in bilateral temporo-parietal regions in cochlear implant patients relative to controls during a word repetition task. We hypothesised that because acoustico-phonological steps required extensive processing, patients presented reduced activation in the language regions located downstream to the most demanding steps, except in those subserving steps critical for the task. Word repetition does not absolutely require lexico-semantic processing and could be performed via a route linking phonological input to phonological output. Here, the task drove subjects towards global comprehension (to be able to later answer questions about the sentences). Semantic associations were probably stronger with this less demanding task, that only requires global comprehension, than with a repetition task. However, it remains unclear why the activation of the right TOP junction was observed without co-activation of its left homologue and what specific role this region could play in CI users. The functional specificity of the right TOP junction is indeed unclear since lesions of this region provoke a variety of syndromes including neglect and deficits in representational memory [2,30].

In patients, we additionally detected an activation of the inferior part of the left prefrontal cortex. This region participates in different aspects of semantic and phonological processing [35,52], but is seldom recruited in the absence of an output task (here passive listening). Like the TOP junction, we previously found the LIPF to be less activated in patients than in controls during a word repetition task [20]. The same interpretation as above applies to this finding, namely that the difficulty of word repetition in implant patients

emphasises early phonological steps and hence limits further processing to the indispensable components, e.g. the speech production steps mediated by the left insula [12,49]. A passive listening task with sentences to be recalled later on undoubtedly engages more semantic memory than a word repetition task. As this region was not recruited by L2 (no significant difference between L2 and L3), even though L2 was correctly understood, we conclude this activation to reflect an effect of familiarity rather than an effect of comprehension. Activation of the left LIPF may reflect a compensatory strategy that functions automatically for L1, but not for a language with less familiar forms. The LIPF is not necessarily recruited when confronted with clearly spoken speech but it may be recruited when the quality of the auditory signal is degraded and when comprehension of auditory signals requires integration of the entire sequence (sentence). This is supported by the idea that the LIPF serves as a semantic working memory and executive system that accesses, maintains and manipulates semantic representations stored elsewhere [35]. The finding is also compatible with the notion that the LIPF plays a role in attention to auditory inputs [18,52].

The specific goals of this study were focussed on cross-modal effects produced by meaningful speech stimuli. However, our data also confirm the lack of a difference between L1 and L2 in normal-hearing subjects when both languages are correctly understood as it has been observed in most studies performed in bilingual subjects (see [24] for a recent review). No difference was found in spite of a difference in familiarity (our subjects were late bilinguals with low proficiency in L2). In contrast to previous reports, however, we did observe a difference between L2 and an unknown language [34]. These data do not reproduce our former findings of less activation in semantic regions in CI patients than in controls [17,19]. We probed semantic-related activations using a passive listening task that places no demand on a specific input–output loop. Under these conditions, we not only observed identical semantic-related activation in both groups, but we also found the meaning of sounds to be processed outside the classical language areas, in brain regions that process images rather than sounds. In CI users, these cross-modal effects were not limited to early visual cortex as previously observed [3,17,19,20] but extended to advanced stages in the visual processing hierarchy that have been implicated in the representation of the most important visual stimuli for speech comprehension, i.e. facial expressions.

## Acknowledgements

This study was possible thanks to the facilities of the CERMEP (Lyon, France). The PET examinations were funded by the Hospices Civils de Lyon (France). We are grateful to Andreas Kleinschmidt for his comments on an earlier version of this manuscript.

## References

- [1] Bavelier D, Tomann A, Hutton C, Mitchell T, Corina D, Liu G, et al. Visual attention to the periphery is enhanced in congenitally deaf individuals. *Journal of Neuroscience* 2000;20:1–6.
- [2] Bisiach E, Luzzatti C. Unilateral neglect of representational space. *Cortex* 1978;14:129–33.
- [3] Bookheimer SY, Zeffiro TA, Blaxton TA, Gaillard WD, Malow B, Theodore WH. Regional cerebral blood flow during auditory responsive naming: evidence for cross-modal neural activation. *Neuroreport* 1998;9:2409–13.
- [4] Buffalo EA, Ramus SJ, Clark RE, Teng E, Squire LR, Zola SM. Dissociation between the effects of damage to perirhinal cortex and area TE. *Learning and Memory* 1999;6:572–99.
- [5] Campbell R. Speech reading: advances in understanding its cortical bases and implications for deafness and speech rehabilitation. *Scandinavian Audiology Supplement* 1998;49:80–6.
- [6] Calvert GA, Bullmore ET, Brammer MJ, Campbell R, Williams SC, McGuire PK, et al. Activation of auditory cortex during silent lip-reading. *Science* 1997;276:593–6.
- [7] Corbetta M. Functional anatomy of visual attention in the human brain. Studies with positron emission tomography. In: Parasuraman R, editor. *The attentive brain*. Cambridge, MA: MIT Press; 1998. p. 95–122.
- [8] Coull J, Nobre A. Where and when to pay attention: the neural systems for directing attention to spatial locations and to time intervals as revealed by both PET and fMRI. *Journal of Neuroscience* 1998;18:7426–35.
- [9] Démonet JF, Price C, Wise R, Frackowiak RSJ. Differential activation of right and left posterior sylvian regions by semantic and phonological tasks: a positron emission tomography study in normal human subjects. *Neuroscience Letters* 1994;182:25–8.
- [10] DeYoe EA, Carman GJ, Bandettini P, Glickman S, Wieser J, Cox R, et al. Mapping striate and extrastriate visual areas in human cerebral cortex. *Proceedings of the National Academy of Sciences USA* 1996;93:2382–6.
- [11] Dorman MF, Soli S, Dankowski K, Smith LM, McCandless G, Parkin J. Acoustic cues for consonant identification by patients who use the Ineraid cochlear implant. *The Journal of the Acoustical Society of America* 1990;88:2074–9.
- [12] Dronkers N. A new region for co-ordinating speech articulation. *Nature* 1996;384:159–61.
- [13] Engelien A, Silbersweig D, Stern E, Huber W, Dring W, Frith C, et al. The functional anatomy of recovery from auditory agnosia. A PET study of sound categorization in a neurological patient and normal controls. *Brain* 1995;118:1395–409.
- [14] Friederici AD. The time course of syntactic activation during language processing: a model based on neuropsychological and neurophysiological data. *Brain and Language* 1995;50:259–81.
- [15] Foundas A, Daniels SK, Vasterling JJ. Anomia: case studies with lesion localisation. *Neurocase* 1998;4:35–43.
- [16] Gauthier I, Tarr M, Moylan J, Skudlarski P, Gore JC, Anderson AW. The fusiform ‘face area’ is part of a network that processes faces at the individual level. *Journal of Cognitive Neuroscience* 2000;12:495–504.
- [17] Giraud AL, Truy E, Grégoire MC, Frackowiak RSJ, Collet L. Functional reorganisation and speech comprehension adaptive strategies after cochlear implantation. *Brain* 2000;123:1391–402.
- [18] Giraud AL, Price CJ. The constraints functional anatomy places on cognitive models of auditory word processing. *Journal of Cognitive Neuroscience* 2001;13:754–65.
- [19] Giraud AL, Price CJ, Graham JM, Frackowiak RSJ. Cross-modal plasticity underpins recovery of human language comprehension after auditory re-afferentation by cochlear implants. *Neuron* 2001;30:657–63.
- [20] Giraud AL, Price CJ, Graham JM, Frackowiak RSJ. Functional plasticity of language-related brain areas after cochlear implantation. *Brain* 2001;124:1307–16.
- [21] Gorno-Tempini ML, Price CJ, Josephs O, Vandenberghe R, Cappa SF, Kapur N, et al. The neural systems sustaining face and proper-name processing. *Brain* 1998;121:2103–18.
- [22] Gray RF, Wareing MJ, Court I. Cochlear implant results: a comparison of live-voice and videotaped tests. *Laryngoscope* 1995;105:1001–4.
- [23] Haxby JV, Horwitz B, Ungerleider LG, Maisog JM, Pietrini P, Grady CL. The functional organization of human extrastriate cortex: a PET-rCBF study of selective attention to faces and locations. *Journal of Neuroscience* 1994;14:6336–53.
- [24] Illes J, Francis WS, Desmond JE, Gabrieli JD, Glover GH, Poldrack R. Convergent cortical representation of semantic processing in bilinguals. *Brain and Language* 1999;70:347–63.
- [25] Kanwisher N, McDermott J, Chun MM. The fusiform face area: a module in human extrastriate cortex specialized for face perception. *Journal of Neuroscience* 1997;17:4302–11.
- [26] MacSweeney M, Amaro E, Calvert GA, Campbell R, David AS, McGuire P, et al. Silent speech reading in the absence of scanner noise: an event-related fMRI study. *Neuroreport* 2000;11:1729–33.
- [27] McDermott KB, Ojemann JG, Petersen SE, Ollinger JM, Snyder AZ, Akbudak E, et al. Direct comparison of episodic encoding and retrieval of words: an event-related fMRI study. *Memory* 1996;7:661–78.
- [28] McIntosh AR, Cabeza RE, Lobaugh NJ. Analysis of neural interactions explains the activation of occipital cortex by an auditory stimulus. *Journal of Neurophysiology* 1998;80:2790–6.
- [29] Mishkin M, Lewis ME, Ungerleider LG. Equivalence of parieto-occipital subareas for visuospatial ability in monkeys. *Behavioral Brain Research* 1982;6:41–55.
- [30] Mummery CJ, Patterson K, Hodges JR, Price CJ. Functional neuroanatomy of the semantic system: divisible by what? *Journal of Cognitive Neuroscience* 1998;10:766–77.
- [31] Mummery CJ, Patterson K, Wise RJ, Vandenberg R, Price CJ, Hodges JR. Disrupted temporal lobe connections in semantic dementia. *Brain* 1999;122:61–73.
- [32] Neville HJ. Intermodal competition. *Annals of the New York Academy of Sciences* 1990;608:71–91.
- [33] Nobre AC, Allison T, McCarthy G. Word recognition in the human inferior temporal lobe. *Nature* 1994;372:260–3.
- [34] Perani D, Dehaene S, Grassi F, Cohen L, Cappa SF, Dupoux E, et al. *Neuroreport* 1996;7:2439–44.
- [35] Poldrack R, Wagner AD, Prull MW, Desmond JE, Glover GH, Gabrieli JDE. Functional specialization for semantic and phonological processing in the left inferior prefrontal cortex. *Neuroimage* 1999;10:15–35.
- [36] Posner MI. Attention: the mechanisms of consciousness. *Proceedings of the National Academy of Sciences USA* 1994;91:7398–403.
- [37] Price CJ, Moore CJ, Humphreys GW, Wise RJS. Segregating semantic from phonological processing during reading. *Journal of Cognitive Neuroscience* 1997;9:27–33.
- [38] Price C, Friston K. Cognitive conjunction: a new approach to brain activation experiments. *Neuroimage* 1997;5:261–70.
- [39] Proops DW, Donaldson I, Cooper HR, Thomas J, Burrell SP, Stoddart RL, et al. Outcomes from adult implantation, the first 100 patients. *Journal of Laryngology and Otology Supplement* 1999;24:5–13.
- [40] Puce A, Allison T, Asgari M, Gore JC, McCarthy G. Differential sensitivity of human visual cortex to faces, letterstrings, and textures: a functional magnetic resonance imaging study. *Journal of Neuroscience* 1996;16:5205–15.
- [41] Puce A, Allison T, Bentin S, Gore JC, McCarthy G. Temporal cortex activation in humans viewing eye and mouth movements. *Journal of Neuroscience* 1998;18:2188–99.
- [42] Rombouts SA, Scheltens P, Machielson WC, Barkhof F, Hoogenraad FG, Veltman DJ, et al. Parametric fMRI analysis of visual



- encoding in the human medial temporal lobe. *Hippocampus* 1999;9: 637–43.
- [43] Sams M, Aulanko R, Hamalainen M, Hari R, Lounasmaa OV, Lu ST, et al. Seeing speech: visual information from lip movements modifies activity in the human auditory cortex. *Neuroscience Letters* 1991;127:141–5.
- [44] Seltzer B, Pandya DN. Parietal, temporal, and occipital projections to cortex of the superior temporal sulcus in the rhesus monkey: a retrograde tracer study. *Journal of Comparative Neurology* 1994;343:445–63.
- [45] Tyler RS, Moore BC. Consonant recognition by some of the better cochlear-implant patients. *Journal of the Acoustical Society of America* 1992;92:3068–77.
- [46] Tyler RS, Parkinson AJ, Woodworth GG, Lowder MW, Gantz BJ. Performance over time of adult patients using the Ineraid or nucleus cochlear implant. *Journal of the Acoustical Society of America* 1997;102:508–22.
- [47] Vandenberghe R, Price C, Wise R, Josephs O, Frackowiak RSJ. Functional anatomy of a common semantic system for words and pictures. *Nature* 1996;383:254–6.
- [48] Warburton E, Wise RJ, Price CJ, Weiller C, Hadar U, Ramsay S. Studies with positron emission tomography of noun and verb retrieval in normal subjects. *Brain* 1996;119:159–80.
- [49] Wise RJS, Greene J, Büchel C, Scott SK. Brain regions involved in articulation. *The Lancet* 1999;353:1057–61.
- [50] Wise R, Chollet F, Hadar U, Friston K, Hoffner E, Frackowiak R. Distribution of cortical neural networks involved in word comprehension and word retrieval. *Brain* 1991;114:1803–17.
- [51] Wise RJ, Howard D, Mummery CJ, Fletcher P, Leff A, Büchel C. Noun imageability and the temporal lobes. *Neuropsychologia* 2000;38:985–94.
- [52] Zatorre RJ, Meyer E, Gjedde A, Evans A. PET studies of phonetic processing of speech: review, replication and re-analysis. *Cerebral Cortex* 1996;6:21–30.