



HAL
open science

Severe Congenital Adrenal Hyperplasia Presenting as Bilateral Testicular Tumors and Azoospermia in the Third Decade of Life

Julie Sarfati, Camille Vatier, Isabelle Keller, Jérôme Guéchet, Christine
Bellanné-Chantelot, Sophie Christin-Maitre

► **To cite this version:**

Julie Sarfati, Camille Vatier, Isabelle Keller, Jérôme Guéchet, Christine Bellanné-Chantelot, et al.. Severe Congenital Adrenal Hyperplasia Presenting as Bilateral Testicular Tumors and Azoospermia in the Third Decade of Life. *Journal of the Endocrine Society*, 2018, 2 (9), pp.997 - 1000. 10.1210/js.2018-00103 . hal-03982827

HAL Id: hal-03982827

<https://hal.science/hal-03982827>

Submitted on 10 Feb 2023

HAL is a multi-disciplinary open access archive for the deposit and dissemination of scientific research documents, whether they are published or not. The documents may come from teaching and research institutions in France or abroad, or from public or private research centers.

L'archive ouverte pluridisciplinaire **HAL**, est destinée au dépôt et à la diffusion de documents scientifiques de niveau recherche, publiés ou non, émanant des établissements d'enseignement et de recherche français ou étrangers, des laboratoires publics ou privés.

Severe Congenital Adrenal Hyperplasia Presenting as Bilateral Testicular Tumors and Azoospermia in the Third Decade of Life

Julie Sarfati,^{1,2} Camille Vatiez,^{1,2,3} Isabelle Keller,⁴ Jérôme Guéchet,^{1,5} Christine Bellanné-Chantelot,⁶ and Sophie Christin-Maitre^{1,2,3}

¹Assistance Publique-Hôpitaux de Paris, Hôpital Saint Antoine, 75012 Paris, France; ²Service d'Endocrinologie et Médecine de la Reproduction, 75012 Paris, France; ³Sorbonne Université, 75012 Paris, France; ⁴Service de Médecine Nucléaire, 75020 Paris, France; ⁵Laboratoire d'Hormonologie, F-75012 Paris, France; and ⁶Hôpital La Pitié Salpêtrière Centre de Génétique Moléculaire et Chromosomique, 75103 Paris, France

Classic forms of 21-hydroxylase deficiency (21OHD) are usually diagnosed at birth by salt wasting or precocious puberty in male patients. Here we report the case of a 32-year-old male patient who presented with azoospermia and bilateral testicular tumors. He was referred to our endocrine unit after testicular surgery. His gonadotropins were undetectable. Liquid chromatography–tandem mass spectrometry revealed a high serum progesterone level, high 17-hydroxyprogesterone (17OHP) (255 ng/mL), and high levels of 17OHP metabolites, suggesting a classic form of 21OHD. His blood pressure was normal. Molecular analysis showed a homozygous large 21-hydroxylase gene (*CYP21A2*) conversion. Furthermore, an adrenal CT scan revealed voluminous, heterogeneous bilateral and asymmetric adrenal masses containing calcifications. Our case report illustrates the fact that a classic form of 21OHD can be diagnosed in late adulthood, manifested by azoospermia and large adrenal tumors, associated with elevated 17OHP.

Copyright © 2018 Endocrine Society

This article has been published under the terms of the Creative Commons Attribution Non-Commercial, No-Derivatives License (CC BY-NC-ND; <https://creativecommons.org/licenses/by-nc-nd/4.0/>).

Freeform/Key Words: 21 hydroxylase deficiency, adrenal tumors, azoospermia, TARTs

Congenital adrenal hyperplasia (CAH) (MIM 201910) is a group of autosomal recessive disorders caused by a deficiency of an enzyme involved in cortisol biosynthesis. CAH due to 21-hydroxylase deficiency (21OHD) is a rare autosomal recessive disorder characterized by variable impairment of adrenal function [1]. Deficiencies of 21OH are caused by mutations in the *CYP21A2* gene encoding the adrenal enzyme 21-hydroxylase. This enzyme is necessary for the production of cortisol and aldosterone. The phenotype is related to the genotype of the less severe mutated allele. They are classified as classic (for the severe form) or nonclassic. The classic form of 21OHD is divided into the salt-wasting (SW) and simple virilizing (SV) forms, depending on the degree of aldosterone deficiency. In the absence of neonatal screening, 21OHD is usually revealed during the neonatal period by a life-threatening adrenal crisis.

Clinical manifestations of 21OHD also depend on androgen excess, mainly in female patients. The goals of 21OHD treatment are to avoid adrenal insufficiency and to reduce excessive ACTH production and consequently increased androgen production [2].

Abbreviations: 17OHP, 17-hydroxyprogesterone; ¹⁸F-FDG-PET, ¹⁸F-fluorodeoxyglucose–positron emission tomography; 21OHD, 21-hydroxylase deficiency; CAH, congenital adrenal hyperplasia; LC-MS/MS, liquid chromatography–tandem mass spectrometry; SUV_{max}, maximum standardized uptake value; SV, simple virilizing; SW, salt-wasting; TART, testicular adrenal rest tumor.

Here, we report an unusual case of the classic form of 21OHD in a 32-year-old man with azoospermia. The patient also presented with bilateral adrenal enlargement with calcifications mimicking adrenocortical carcinomas.

1. Case Report

A 32-year-old man with no history of other previous illnesses first came to a general hospital to explore his infertility. His semen analysis revealed azoospermia. A testicular ultrasound showed bilateral hypotrophic testis associated with bilateral heterogeneous nodules containing calcifications. In response to these atypical images, a scrotal exploration was performed. A Leydig cell tumor was suspected after histological examination.

Hormonal testing performed after surgery revealed undetectable FSH and LH serum levels and a normal testosterone level (Table 1). Therefore, he was referred to our endocrine department.

The patient's history revealed no familial history, no known consanguineous parents, and no previous hospitalization as an infant or a child. He was born in Haiti. He did not mention precocious puberty or delayed puberty.

Physical examination was normal (including normal blood pressure) apart from a short stature of 1.62 m, for a target height of 1.76 m. He was overweight, with a body mass index of 28.6 kg/m². The patient did not complain of tiredness and was able to work as a taxi driver.

Liquid chromatography–tandem mass spectrometry (LC-MS/MS) was performed, and the diagnosis of CAH was suspected, given a high level of 17-hydroxyprogesterone (17OHP) and its metabolites (Table 1). The diagnosis was confirmed by molecular analysis. It revealed a large gene conversion including exons 4 to 7 of *CYP21A2*. This conversion has been previously described and has been associated with severe 21OHD [3]. The patient is homozygous for this gene defect.

His testosterone level was within the normal range (Table 1), with undetectable FSH and LH. This hormonal profile of a non–gonadotropin-driven source of steroids suggested an adrenal origin. It was confirmed by a low level of insulinlike factor 3 at 112 pg/mL (normal range 400 to 1420 pg/mL), a peptide known to be produced only by Leydig cells.

A second evaluation of his testicular tumors revealed testicular adrenal rest tumors (TARTs). A CT scan revealed asymmetric bilateral adrenal masses. Their sizes were 56 × 35 mm on the left adrenal and 79 × 64 mm on the right (Fig. 1). Their unenhanced densities

Table 1. Steroid Levels by LC-MS/MS

Steroids	At Diagnosis	After 6 Months of Steroid Treatment	Normal Range
17OHP, ng/mL	255	28	0.4–2.5
Progesterone, ng/mL	27	5	<0.2
Testosterone, ng/mL	2.9	1.1	2.5–11
Δ4-A, ng/mL	24	5	0.25–2
DHEA, ng/mL	1.1	0.2	1–15
Pregnenolone, ng/mL	17	4.8	<2
17-hydroxypregnenolone, ng/mL	5.5	0.6	<2
21-Deoxycorticosterone, ng/mL	24	4	<0.2
21-Deoxycortisol, ng/mL	55	12	<0.3
11-Deoxycorticosterone, ng/mL	0.16	0.03	0.15–0.7
11-Deoxycortisol, ng/mL	0.08	0.02	<1
11β-OH-Δ4-A, ng/mL	41	14	1–3
Corticosterone, ng/mL	4	0.5	0.5–12
Cortisol, ng/mL	7.7	162	77–220
Cortisone, ng/mL	1.2	24	10–27

Abbreviations: 11β-OH-Δ4-A, 11β hydroxy Δ4-androstenedione; Δ4-A, Δ4-androstenedione; DHEA, dehydroepiandrosterone.

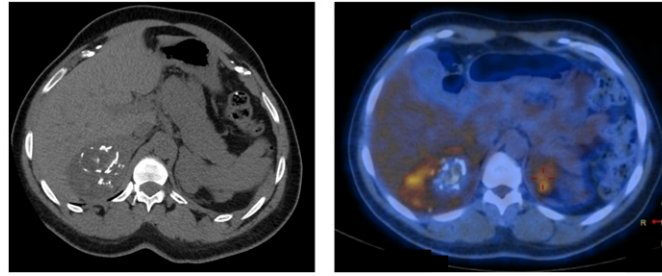


Figure 1. (Left) Adrenal CT scan showing large asymmetric bilateral adrenal masses. Multiple calcifications are present in the right adrenal tumor. (Right) ^{18}F -FDG-PET scan showing a mild bilateral hypermetabolism evaluated with an SUV_{max} of 5.2. The adrenal to liver SUV_{max} ratio is 1.8.

were 36 and 25 Hounsfield units, and the absolute enhancement washouts were 74% and 6%, respectively. Furthermore, the right gland was heterogeneous and contained multiple calcifications. An ^{18}F -fluorodeoxyglucose–positron emission tomography (^{18}F -FDG-PET)/CT scan was performed because adrenal malignancy was initially suspected. It revealed a mild bilateral hypermetabolism evaluated with a mean maximum standardized uptake value (SUV_{max}) of 5.2 and an adrenal to liver SUV_{max} ratio of 1.8 (Fig. 1).

After the diagnosis of 21OHD was confirmed, hydrocortisone treatment was initiated. Although the patient did not complain of tiredness during the first evaluation, his level of fatigue was much lower after 1 month of hydrocortisone. Measurement of his steroids 6 months after he began hormonal replacement therapy revealed a significant decrease in 17OHP serum level and all its metabolites, including testosterone (Table 1). His testicular failure was then revealed (Table 1). Adrenal CT scans performed 6 and 12 months after initiating steroid treatment revealed stable adrenal volume (data not shown).

2. Discussion

We report an unusual classic form of 21OHD in a 32-year-old man. The diagnosis was suspected in light of a normal testosterone level with undetectable gonadotropins just after a bilateral testicular surgery.

Our patient had no clinical phenotype suggesting classic 21OHD, apart from a short stature and being overweight. This phenotype is probably related to advanced skeletal maturation, secondary to an excess of androgen secretion during infancy and early adolescence. He presented at the age of 32 with bilateral testicular masses.

TARTs are a common finding in patients with 21OHD, identified in $\leq 86\%$ of examined patients [4]. TARTs can affect both endocrine and exocrine testicular functions and therefore can lead to infertility [4, 5]. In our patient, a Leydig cell tumor was initially suspected. Indeed, Leydig cells share many functional and morphological similarities with TARTs. A recent study reported different expression patterns of *DLK1*, insulinlike factor 3, and most adrenocortical markers between Leydig cells and TARTs [6]. This type of analysis could help distinguish TARTs from Leydig cell tumors and therefore potentially avoid surgery. Unfortunately, the diagnosis of 21OHD was performed in our patient after his bilateral orchidectomy.

Mutations in *CYP21A2* can be classified according to the impact on 21-hydroxylase enzymatic activity. The homozygous mutation identified in our patient has been previously associated with a severe form of 21OHD, revealed by SW during the neonatal period [3]. In this recent study, genotype is well correlated with the phenotype in most patients. However, disparity in phenotypic appearance appeared in a small portion of patients [3]. Several factors may be responsible for the genotype-phenotype variability in patients with CAH. Apart from the *CYP21A2* mutations, other genes may affect the phenotype by modifying steroid action or salt balance. Furthermore, differences in extra-adrenal 21-hydroxylation (as already shown in mice and human liver of patients with CAH) could justify the discordances between

genotype and phenotype. Interestingly, our case illustrates potential survival, without any episode of adrenal failure, in a patient carrying a severe genetic form of 21OHD, although he had not been on steroids during infancy or adulthood. To our knowledge, such a mild phenotype has never been reported with such a severe mutation.

An increased prevalence of adrenal tumors has been reported in patients with 21OHD: $\leq 82\%$ of male homozygous patients and 45% in heterozygous patients [7]. Reisch *et al.* [8] documented a correlation between total adrenal volume and current hormonal control in patients with 21OHD. Development of adrenal tumors is probably increased by prolonged ACTH stimulation of the adrenal cortex. However, some of these tumors are unilateral, which means that other factors may contribute to adrenal tumor development in patients with CAH. To our knowledge, in patients with 21OHD, massive calcifications within adrenal glands have never been described. Our patient's ^{18}F -FDG-PET scan was reassuring [9].

In conclusion, we describe a severe form of 21OHD, diagnosed in late adulthood in light of bilateral testicular tumors, azoospermia, and large bilateral adrenal masses, mimicking adrenocortical carcinoma. Our patient illustrates the natural history of severe 21OHD without steroid replacement treatment. Hormonal evaluation of combined testicular and adrenal lesions is necessary before orchidectomy should be considered.

Acknowledgments

Correspondence: Julie Sarfati, MD, PhD, Service d'Endocrinologie, Diabétologie et Médecine de la Reproduction, Hôpital Saint Antoine, 184 Rue du Faubourg Saint Antoine, 75012 Paris, France. E-mail: julie.sarfati@aphp.fr.

Disclosure Summary: The authors have nothing to disclose.

References and Notes

1. El-Maouche D, Arlt W, Merke DP. Congenital adrenal hyperplasia. *Lancet*. 2017;**390**(10108):2194–2210.
2. Auchus RJ, Arlt W. Approach to the patient: the adult with congenital adrenal hyperplasia. *J Clin Endocrinol Metab*. 2013;**98**(7):2645–2655.
3. Wang R, Yu Y, Ye J, Han L, Qiu W, Zhang H, Liang L, Gong Z, Wang L, Gu X. 21-hydroxylase deficiency-induced congenital adrenal hyperplasia in 230 Chinese patients: genotype-phenotype correlation and identification of nine novel mutations. *Steroids*. 2016;**108**:47–55.
4. Falhammar H, Nyström HF, Ekström U, Granberg S, Wedell A, Thorén M. Fertility, sexuality and testicular adrenal rest tumors in adult males with congenital adrenal hyperplasia. *Eur J Endocrinol*. 2012;**166**(3):441–449.
5. Bouvattier C, Esterle L, Renoult-Pierre P, de la Perrière AB, Illouz F, Kerlan V, Pascal-Vigneron V, Drui D, Christin-Maitre S, Galland F, Brue T, Reznik Y, Schillo F, Pinsard D, Piguel X, Chabrier G, Decoudier B, Emy P, Tauveron I, Raffin-Sanson ML, Bertherat J, Kuhn JM, Caron P, Cartigny M, Chabre O, Dewailly D, Morel Y, Touraine P, Tardy-Guidollet V, Young J. Clinical outcome, hormonal status, gonadotrope axis, and testicular function in 219 adult men born with classic 21-hydroxylase deficiency. A French national survey. *J Clin Endocrinol Metab*. 2015;**100**(6):2303–2313.
6. Lottrup G, Nielsen JE, Skakkebaek NE, Juul A, Rajpert-De Meyts E. Abundance of DLK1, differential expression of CYP11B1, CYP21A2 and MC2R, and lack of INSL3 distinguish testicular adrenal rest tumours from Leydig cell tumours. *Eur J Endocrinol*. 2015;**172**(4):491–499.
7. Jaresch S, Kornely E, Kley HK, Schlaghecke R. Adrenal incidentaloma and patients with homozygous or heterozygous congenital adrenal hyperplasia. *J Clin Endocrinol Metab*. 1992;**74**(3):685–689.
8. Reisch N, Scherr M, Flade L, Bidlingmaier M, Schwarz HP, Müller-Lisse U, Reincke M, Quinkler M, Beuschlein F. Total adrenal volume but not testicular adrenal rest tumor volume is associated with hormonal control in patients with 21-hydroxylase deficiency. *J Clin Endocrinol Metab*. 2010;**95**(5):2065–2072.
9. Launay N, Silvera S, Tenenbaum F, Groussin L, Tissier F, Audureau E, Vignaux O, Dousset B, Bertagna X, Legmann P. Value of 18-F-FDG PET/CT and CT in the diagnosis of indeterminate adrenal masses. *Int J Endocrinol*. 2015;**2015**:213875.