



HAL
open science

Autoimmune hypoglycemia expands the biological spectrum of HHV8+ multicentric Castleman disease

Pierre Arnautou, Martine Auclair, Soraya Fellahi, Clara Bouché, Claire Fieschi, Elias Barrak, Viviane Queyrel-Moranne, Lucy Chaillous, Nicolas Blin, Marion Malphettes, et al.

► To cite this version:

Pierre Arnautou, Martine Auclair, Soraya Fellahi, Clara Bouché, Claire Fieschi, et al.. Autoimmune hypoglycemia expands the biological spectrum of HHV8+ multicentric Castleman disease. *Blood Advances*, 2021, 5 (7), pp.1848 - 1852. <10.1182/bloodadvances.2020002801>. <hal-03974919>

HAL Id: hal-03974919

<https://hal.science/hal-03974919v1>

Submitted on 6 Feb 2023

HAL is a multi-disciplinary open access archive for the deposit and dissemination of scientific research documents, whether they are published or not. The documents may come from teaching and research institutions in France or abroad, or from public or private research centers.

L'archive ouverte pluridisciplinaire HAL, est destinée au dépôt et à la diffusion de documents scientifiques de niveau recherche, publiés ou non, émanant des établissements d'enseignement et de recherche français ou étrangers, des laboratoires publics ou privés.



HAL Authorization

Autoimmune hypoglycemia expands the biological spectrum of HHV8⁺ multicentric Castleman disease

Pierre Arnautou,¹ Martine Auclair,² Soraya Fellahi,³ Clara Bouché,⁴ Claire Fieschi,^{1,5} Elias Barrak,⁶ Viviane Queyrel-Moranne,⁷ Lucy Chaillous,⁶ Nicolas Blin,⁶ Marion Malphettes,^{1,5} Jehane Fadlallah,^{1,5} Remi Bertinchamp,^{1,5} Laurence Gérard,^{1,5} Djaouida Bengoufa,⁸ Lionel Galicier,^{1,5} Eric Oksenhendler,^{1,5} Corinne Vigouroux,^{2,9,10} and David Boutboul^{1,5,11}

¹Clinical Immunology Department, Hôpital Saint Louis, Université de Paris, Paris, France; ²Sorbonne Université, INSERM UMRS_938, Saint-Antoine Research Centre, IHU ICAN, Paris, France; ³Biochemistry Laboratory, Hôpital Henri Mondor, Créteil, France; ⁴Endocrinology Department, Hôpital Lariboisière, and ⁵National Reference Center for Castleman disease, Hôpital Saint Louis, Université de Paris, Paris, France; ⁶Endocrinology Department, CHU Nantes, Nantes, France; ⁷Rheumatology Department, CHU Nice, Nice, France; ⁸Immunology and Histocompatibility Laboratory, Hôpital Saint Louis, Université de Paris, Paris, France; ⁹Department of Endocrinology and ¹⁰Department of Molecular Biology and Genetics, Assistance Publique–Hôpitaux de Paris, Saint Antoine Hospital, National Reference Centre for Rare Diseases of Insulin Secretion and Insulin Sensitivity (PRISIS), Paris, France; and ¹¹U976 HIPI, INSIGHT team, Hôpital Saint Louis, Université de Paris, Paris, France

Key Points

- Autoimmune hypoglycemia belongs to the clinical spectrum of HHV8⁺ MCD and rituximab is an effective treatment of this condition.
- This rare complication is related to autoantibodies directed toward the insulin receptor and activating the insulin signaling pathway.

Introduction

Castleman disease (CD) is a rare nonclonal lymphoproliferative disorder. Diagnosis is based on histological features.¹ Some cases of multicentric Castleman disease (MCD) are related to a polyclonal proliferation of human herpesvirus 8 (HHV8)-infected plasmablasts (called “HHV8⁺ MCD”), mostly encountered in immunocompromised hosts. The infected cells are uniformly immunoglobulin M and λ positive and locate in the mantle zone of the lymph node. These cells are associated with a marked polyclonal plasma cell infiltrate. Hemophagocytic lymphohistiocytosis and other cytokine release complications make this condition life threatening.^{2,3} Numerous autoantibodies can develop during MCD flares, and autoimmune thrombocytopenia, autoimmune hemolytic anemia, and thrombotic thrombocytopenic purpura⁴ have been described. We report on autoimmune hypoglycemia as a new autoimmune complication occurring in 5 patients with active HHV8⁺ MCD. We demonstrate that hypoglycemia is caused by autoantibodies directed toward the insulin receptor (IR) and that rituximab is an effective and safe treatment of this condition.

Methods

Definition of HHV8⁺ MCD

MCD was defined by the presence of a clinical flare as previously described,⁵ and node biopsy consistent with HHV8⁺ MCD.²

Experimental methods, including inhibition of ¹²⁵I-insulin binding on insulin receptor by the patients' serum, purification of serum immunoglobulins, effect of patient serum immunoglobulins on insulin signaling, and immunofluorescence characterization of anti-IR immunoglobulin light chains, have been detailed in the supplemental Methods.⁶⁻⁸ This study was approved by the local institutional review board (IMMUNOLYMPH protocol, CLEA-2020-113) and was conducted in accordance with the Declaration of Helsinki.

IL-6 measurement

Interleukin-6 (IL-6) plasma levels were measured using an electrochemiluminescent immunoassay (Roche Diagnostics).

Statistical analysis

Statistical comparison between HHV8⁺ MCD patients with or without autoimmune hypoglycemia was based on the nonparametric Wilcoxon rank sum test.

Results and discussion

Patient 1

An 80-year-old man was referred with deterioration of general status and fever. Past medical history was positive for HIV⁻ HHV8⁺ MCD treated with rituximab 3 years before admission and insulin-treated type 2 diabetes diagnosed 12 years earlier.

Clinical examination revealed generalized supracentimetric lymphadenopathies. Biological features showed elevated levels of acute phase reactants, anemia, polyclonal hypergammaglobulinemia, and high HHV8 whole blood viral load (5.8 log copies per mL). Histological examination of a left cervical lymph node showed typical aspects of HHV8⁺ MCD.

Concomitant to MCD relapse, the patient presented with recurrent fasting hypoglycemia despite discontinuation of insulin therapy for 4 weeks and low levels of endogenous serum insulin and C-peptide. The patient serum was shown to strongly inhibit the binding of insulin to its receptor on Chinese hamster ovary (CHO)-IR cells, even at high dilution, so that half-maximal inhibition of insulin binding was observed at a serum dilution of at least 1:1500 (Figure 1A). Inhibition of ¹²⁵I-insulin binding on IR was retained using purified immunoglobulins from the patient serum (data not shown). Serum immunoglobulins from the patient mimicked the effect of insulin on phosphorylation of IR and IR substrate-1, as well as on activation of the mitogen-activated protein (MAP)-kinase ERK1/2 and the protein kinase B Akt/PKB in CHO-IR cells. The effect was dose dependent and was not induced by control immunoglobulins (Figure 1B). Screening for anti-insulin antibody was negative. Immunofluorescence assay performed on CHO-IR cells showed that both κ and λ light chains colocalized with the IR, indicating that anti-IR antibodies were polyclonal. Control serum used at the same concentration did not show any light chain staining (supplemental Figure 1A,C).

Treatment with etoposide resulted in prompt improvement of fever and polyadenopathy. Short-term evolution was marked by the onset of transitory intense hyperglycemia requiring high-insulin doses compatible with extreme insulin resistance syndrome. The addition of 4-weekly rituximab infusions finally allowed a rapid and durable return to baseline blood sugar levels, and the patient remained free of MCD flares.

Clinical and biological characteristics of 4 additional patients

Between December 2000 and June 2018, 4 patients (patients 2 to 5) presented with recurrent hypoglycemia in the setting of HHV8⁺ MCD flares. This complication affected 1.9% of the patients included in our HHV8⁺ MCD cohort consisting of 257 patients. No cases of antibodies to the insulin receptor were reported to be present in 2 large cohorts representing more than 100 HHV8⁺ MCD patients (M. Bower, British National Centre for HIV Malignancy, London, United Kingdom, and Mario Corbellino, III Division of Infectious Diseases, FBF-Sacco Hospital, Milan, Italy, e-mail communication, 29 July 2020). Patient characteristics are summarized in Table 1. Hypoglycemia clinical signs were psychomotor retardation in 4 patients with altered consciousness in one of them. Other causes of hypoglycemia, such as insulinoma, IGF-1-producing tumors, and adrenal insufficiency, had been ruled out. No acanthosis nigricans was noted. No patient had a previous history of diabetes. Two patients were HIV infected. A HIV⁻ patient

was concomitantly diagnosed with a bone marrow localization by a low-grade B-cell lymphoma. In 2 of 5 patients, hypoglycemia was concomitant of the first flare of HHV8⁺ MCD. All patients had a presentation suggesting HHV8⁺ MCD flare at hypoglycemia onset. All of them showed polyclonal hypergammaglobulinemia, and 2 had evidence of low-level IgG κ (patient 1) and IgA κ (patient 5) monoclonal components. Of note, all patients displayed slightly significant higher gammaglobulin levels than the 252 other patients diagnosed with HHV8⁺ MCD issued from our cohort (median: 34 g/L vs 23.5 g/L; $P = .04$). Median C-reactive protein (CRP) level was lower in the described patients compared with 252 patients diagnosed with HHV8⁺ MCD issued from our cohort (50 mg/L vs 131 mg/L; $P = .009$). This latter result has uncertain significance because of quick fluctuations of CRP levels occurring in HHV8⁺ MCD. These results need to be taken cautiously because of the small sample of patients with autoimmune hypoglycemia. Diagnosis of HHV8⁺ MCD was confirmed on lymph node biopsy in the 4 patients. Patient 3 also presented with mild cutaneous Kaposi sarcoma lesions. Two patients had other clinical or biological autoimmune manifestations detailed in Table 1. No anti-insulin antibody was found.

Characterization of anti-IR antibodies

Anti-IR antibody was isolated in the 4 additional patients and resulted in inhibition of insulin binding (data not shown). Characterization of antibody isotype by immunofluorescence staining in P5 showed a polyclonal pattern as in P1 (supplemental Figure 1B).

Disease course

Four patients were treated with 4-weekly rituximab infusions, and one was lost to follow-up. This treatment correlated with rapid remission of autoimmune hypoglycemia. Disappearance of anti-IR autoantibodies was observed in the 3 patients for whom follow-up samples were available. No relapse occurred in these 3 patients.

Discussion

Type B insulin resistance syndrome, more aptly named “syndrome of antibodies to the insulin receptor,” is caused by autoantibodies directed toward the IR. It can be primary or secondary to connective tissues diseases or malignancies.^{6,8-13} Common presentation is severe hyperglycemia requiring extremely high insulin doses associated with widespread acanthosis nigricans, weight loss, and hyperandrogenism, but hypoglycemia may also occur.^{7,8,11}

We report 5 cases of symptomatic autoimmune hypoglycemia occurring during HHV8⁺ MCD flares that were reversible using MCD therapy. Anti-IR antibodies were identified in all samples leading to inhibition of insulin binding. Agonistic effect of this antibody could be biochemically demonstrated in 2 patients. Interestingly, following etoposide administration, patient 1 developed hyperglycemia requiring very high doses of insulin. The occurrence of both hypoglycemic and hyperglycemic episodes in the same patient was previously described during the course of type B insulin resistance syndrome.^{7,8,11} Pathophysiological hypotheses have involved the coexistence of activating and blocking autoantibodies and/or modifications in antibody titers leading to insulin-like or desensitization effects.^{11,14} Return to baseline blood glucose levels was achieved after rituximab administration and was concomitant to antibody disappearance in the serum.¹²⁻¹⁵ This latter point suggests that the observed hyperglycemic state was, at least partially, linked to the effect of the antibody.

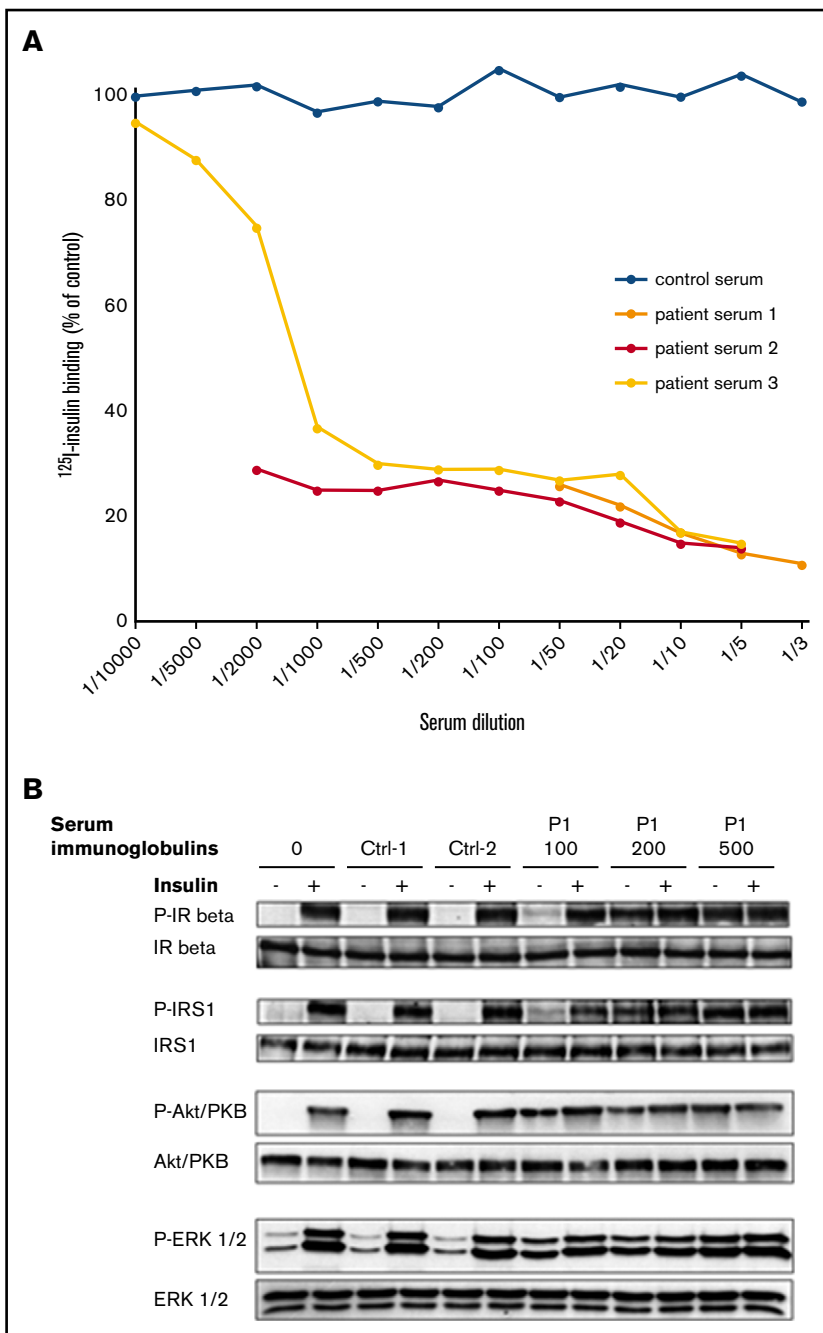


Figure 1. Effects of P1 serum on insulin binding and signaling. (A) Effect of patient 1 serum on ^{125}I -insulin binding to IR. Results from 3 independent experiments. (B) Effect of P1's serum immunoglobulins (100, 200, and 500 $\mu\text{g}/\text{mL}$ as indicated) on insulin signaling. Immunoglobulins from 2 control subjects were used at 200 $\mu\text{g}/\text{mL}$ for comparison. Activated (phosphorylated) and total forms of the IR β , the insulin receptor substrate-1 (IRS1), the MAP-kinase ERK1/2, and the protein kinase B (Akt-PKB) are evaluated by western blot on lysates from cells incubated or not with insulin, as indicated (see supplemental Methods). Data are representative of 2 independent experiments.

To date, only 1 patient with hypoglycemia has been previously described in association with $\text{HHV8}^- \text{HHV8}^+$ MCD, and no specific etiology was retained.¹⁶ This singular autoimmune complication seems to be restricted to HHV8^+ MCD, as it has never been reported in HHV8^- idiopathic variant of MCD. We suggest that HHV8 itself may not be the sole trigger, as autoimmune hypoglycemia appears to be closely related to HHV8^+ MCD and has never been reported in other HHV8 -associated diseases. This latter point makes cross-reactivity between HHV8 and the insulin-receptor-shared epitopes less likely than the emergence of an anti-IR-secreting plasma-cell driven by HHV8 . Moreover, the finding of both κ and λ light chains colocalizing

with the IR in patients 1 and 5 rules out its sole secretion by HHV8 -infected B cells, which are uniformly $\text{IgM-}\lambda^+$ cells.^{17,18} This finding was in accordance with the IgG isotype of anti-ADAMTS13 antibody found in MCD-associated thrombotic thrombocytopenic purpura.⁴ This may rather indicate that high human IL-6 secretion, a hallmark of MCD, could promote the occurrence of self-reacting plasma cells, as suggested by human IL-6 transgenic mice studies.¹⁹ HHV8^+ MCD is also associated with the secretion of HHV8 -related viral IL-6, that might exert additional effects on plasma cell growth.²⁰

Autoimmune hypoglycemia belongs to the clinical spectrum of HHV8^+ MCD and should be carefully sought in patients with neurological impairment in this setting. On the other hand, HHV8^+ MCD should also

Table 1. Characteristics of patients at hypoglycemia onset

	Patient 1	Patient 2	Patient 3	Patient 4	Patient 5
Age, y	80	24	72	72	55
Sex	Male	Male	Male	Male	Male
Date of hypoglycemia diagnosis	2015	2000	2012	2017	2018
MCD, y since diagnosis	3	4	0	8	0
Clinical presentation	Fever Adenopathy	Splenomegaly Adenopathy	Fever Adenopathy	Splenomegaly Adenopathy	Splenomegaly Adenopathy Coma
CRP, mg/L	117	5	200	50	37
IL-6, pg/mL	NA	31.9	NA	NA	33
Gammaglobulin, g/L	58.9	20.8	18.4	34	65
KS, at diagnosis	No	No	Yes	No	No
HHV8 RT-PCR (log)	5.8	4.78	+*	+*	6.29
HIV, y since diagnosis	†	14	†	12	†
CD4, mm ⁻³	†	330	†	432	†
HIV viral load, copies per mL	†	2210	†	47	†
Glycemia, mmol/L	2.0	2.3	2.05	1.6	3.4
Insulin, mIU/L	2.84	4.1	290	242	NA
C-peptide, nmol/L	<0.10	<0.10	1.491	3.3	NA
Anti-IR Ab	Yes	Yes	Yes	Yes	Yes
Inhibition of insulin binding	Yes	Yes	Yes	Yes	Yes
Anti-insulin Ab	No	No	No	No	No
Other immune manifestations	No	No	No	wAIHA	wAIHA, lupus anticoagulant

Ab, antibody; KS, Kaposi sarcoma; NA, not available; RT-PCR, real-time polymerase chain reaction; wAIHA, warm autoimmune hemolytic anemia.

*HHV8 qualitative evaluation.

†Not appropriate (HIV⁻).

be ruled out in patients presenting with fever and unexplained hypoglycemia. Rituximab is effective in the treatment of type B insulin resistance syndrome¹⁴ and is also the preferred treatment of HHV8⁺ MCD. This justified the use of the drug in this particular setting, which was shown to be an effective and safe strategy.

Acknowledgments

The authors thank Romain Morichon (UMS LUMIC platform, Sorbonne Université, Centre de Recherche Saint-Antoine, INSERM U938, Paris, France) for confocal microscopy, Mark Bower and Mario Corbellino for sharing helpful information on HHV8⁺ MCD patients, and Constance Guillaud, Justine Poirot, and Mirlinda Berisha for technical support.

Authorship

Contribution: P.A. and D. Boutboul wrote the manuscript; P.A., D. Boutboul, L. Galicier, C.B., C.F., E.B., V.Q.-M., L.C., N.B., M.M.,

J.F., R.B., L. Gérard, and E.O. contributed to the patient recruitment and management; M.A., C.V., D. Bengoufa, and D. Boutboul performed the experiments and analyzed the data; S.F. performed IL-6 dosage and analyzed the data; L. Gérard performed statistical analysis; C.V. and D. Boutboul supervised the project; and all the authors reviewed the manuscript.

Conflict-of-interest disclosure: The authors declare no competing financial interests.

ORCID profiles: S.F., 0000-0003-0086-4821; C.B., 0000-0003-3369-7644; C.F., 0000-0003-2136-6178; L. Gérard, 0000-0002-8130-713X; E.O., 0000-0001-8588-7138; C.V., 0000-0002-8181-4721; D. Boutboul, 0000-0002-5006-8279.

Correspondence: David Boutboul, Clinical Immunology Department, Hôpital Saint Louis, 1 Av Claude Vellefaux, Université de Paris, 75010 Paris, France; e-mail: david.boutboul@aphp.fr.

References

- Peterson BA, Frizzera G. Multicentric Castleman's disease. *Semin Oncol*. 1993;20(6):636-647.
- Soulier J, Grollet L, Oksenhendler E, et al. Kaposi's sarcoma-associated herpesvirus-like DNA sequences in multicentric Castleman's disease. *Blood*. 1995;86(4):1276-1280.
- Oksenhendler E, Boutboul D, Fajgenbaum D, et al. The full spectrum of Castleman disease: 273 patients studied over 20 years. *Br J Haematol*. 2018; 180(2):206-216.

4. London J, Boutboul D, Agbalika F, et al. Autoimmune thrombotic thrombocytopenic purpura associated with HHV8-related Multicentric Castleman disease. *Br J Haematol*. 2017;178(3):486-488.
5. Gérard L, Bérezné A, Galicier L, et al. Prospective study of rituximab in chemotherapy-dependent human immunodeficiency virus associated multicentric Castleman's disease: ANRS 117 CastlemaB Trial. *J Clin Oncol*. 2007;25(22):3350-3356.
6. Kahn CR, Flier JS, Bar RS, et al. The syndromes of insulin resistance and acanthosis nigricans. Insulin-receptor disorders in man. *N Engl J Med*. 1976;294(14):739-745.
7. Kawashiri SY, Kawakami A, Fujikawa K, et al. Type B insulin resistance complicated with systemic lupus erythematosus. *Intern Med*. 2010;49(5):487-490.
8. Arioglu E, Andewelt A, Diabo C, Bell M, Taylor SI, Gorden P. Clinical course of the syndrome of autoantibodies to the insulin receptor (type B insulin resistance): a 28-year perspective. *Medicine (Baltimore)*. 2002;81(2):87-100.
9. Liminet C, Vouillarmet J, Chikh K, Disse E. Antibody-mediated insulin resistance: when insulin and insulin receptor act as autoantigens in humans. *Can J Diabetes*. 2016;40(5):462-465.
10. Braund WJ, Naylor BA, Williamson DH, et al. Autoimmunity to insulin receptor and hypoglycaemia in patient with Hodgkin's disease. *Lancet*. 1987;1(8527):237-240.
11. Dons RF, Havlik R, Taylor SI, Baird KL, Chernick SS, Gorden P. Clinical disorders associated with autoantibodies to the insulin receptor. Simulation by passive transfer of immunoglobulins to rats. *J Clin Invest*. 1983;72(3):1072-1080.
12. Coll AP, Thomas S, Mufti GJ. Rituximab therapy for the type B syndrome of severe insulin resistance. *N Engl J Med*. 2004;350(3):310-311.
13. Malek R, Chong AY, Lupsa BC, et al. Treatment of type B insulin resistance: a novel approach to reduce insulin receptor autoantibodies. *J Clin Endocrinol Metab*. 2010;95(8):3641-3647.
14. Manikas E-D, Isaac I, Semple RK, Malek R, Führer D, Moeller LC. Successful treatment of type B insulin resistance with rituximab. *J Clin Endocrinol Metab*. 2015;100(5):1719-1722.
15. Klubo-Gwiedzinska J, Lange M, Cochran E, et al. Combined immunosuppressive therapy induces remission in patients with severe type B insulin resistance: a prospective cohort study. *Diabetes Care*. 2018;41(11):2353-2360.
16. Codish S, Abu-Shakra M, Ariad S, et al. Manifestations of three HHV-8-related diseases in an HIV-negative patient: immunoblastic variant multicentric Castleman's disease, primary effusion lymphoma, and Kaposi's sarcoma. *Am J Hematol*. 2000;65(4):310-314.
17. Hassman LM, Ellison TJ, Kedes DH. KSHV infects a subset of human tonsillar B cells, driving proliferation and plasmablast differentiation. *J Clin Invest*. 2011;121(2):752-768.
18. Nicol SM, Sabbah S, Brulois KF, et al. Primary B lymphocytes infected with Kaposi's sarcoma-associated herpesvirus can be expanded in vitro and are recognized by LANA-Specific CD4+ T cells. *J Virol*. 2016;90(8):3849-3859.
19. Suematsu S, Matsuda T, Aozasa K, et al. IgG1 plasmacytosis in interleukin 6 transgenic mice. *Proc Natl Acad Sci USA*. 1989;86(19):7547-7551.
20. Adam N, Rabe B, Suthaus J, Grötzinger J, Rose-John S, Scheller J. Unraveling viral interleukin-6 binding to gp130 and activation of STAT-signaling pathways independently of the interleukin-6 receptor. *J Virol*. 2009;83(10):5117-5126.