



HAL
open science

Swollen bones in jacks and relatives (Teleostei: Acanthomorphata: Carangidae)

Bruno Chanet

► **To cite this version:**

Bruno Chanet. Swollen bones in jacks and relatives (Teleostei: Acanthomorphata: Carangidae). *Cybium : Revue Internationale d'Ichtyologie*, 2018, 42 (1), pp.99-103. <10.26028/cybium/2018-421-010>. <hal-03971149>

HAL Id: hal-03971149

<https://hal.science/hal-03971149v1>

Submitted on 3 Feb 2023

HAL is a multi-disciplinary open access archive for the deposit and dissemination of scientific research documents, whether they are published or not. The documents may come from teaching and research institutions in France or abroad, or from public or private research centers.

L'archive ouverte pluridisciplinaire HAL, est destinée au dépôt et à la diffusion de documents scientifiques de niveau recherche, publiés ou non, émanant des établissements d'enseignement et de recherche français ou étrangers, des laboratoires publics ou privés.



Distributed under a Creative Commons CC BY 4.0 - Attribution - International License

Swollen bones in jacks and relatives (Teleostei: Acanthomorpha: Carangidae)

by

Bruno CHANET (1)



© SFI
Received: 16 Nov. 2017
Accepted: 18 Dec. 2017
Editor: O. Otero

Key words

Carangidae
Hyperostosis
Review

Abstract. – The Carangidae form one of the teleostean families having the most frequent cases of hyperostosis: these bony gall-like structures can develop in many places of their skeleton. The known cases of this condition are described and analysed in a phylogenetic context. However, the presence of these swollen bones remains for now enigmatic.

Résumé. – Des os gonflés chez les carangues (Teleostei: Acanthomorpha: Carangidae).

Les Carangidae forment une des familles de téléostéens où les cas d'hyperostose sont les plus fréquents : des masses osseuses arrondies, gonflées, se développent çà et là dans le squelette. Ces cas sont décrits et analysés au regard de la phylogénie du groupe. Cependant, à ce jour, la présence de ces masses osseuses atypiques reste énigmatique.

Jacks (*Caranx* sp.) and pompanos (*Trachinotus* sp.) are members of the family Carangidae, which forms a group of marine, tropical and subtropical acanthomorphs (Nelson, 2006). While

dissecting, cooking or eating a carangid fish, it is not rare to observe gall-like, inflated hard bony masses on the haemal and neural spines, the pterygiophores and some bones of the cephalic skeleton (Figs 1, 2). In English, these structures are called hyperostotic bones, or swollen bones, or even “Tilly bones” (named after the late Tilly Edinger, an enthusiastic student of these structures, see Konnerth, 1966; Smith-Vaniz *et al.*, 1995). They are the result of the phenomenon of hyperostosis, also spelled ‘hyperosteosis’ (Francillon-Vieillot *et al.*, 1990). In medicine, this term refers to a pathological context of an abnormally high amount of primary bone deposition (Francillon-Vieillot *et al.*, 1990). However, at least in teleostean fishes, these bony structures do not seem to affect their behaviour, health or longevity (Smith-Vaniz *et al.*, 1995). Although such structures have been observed in several (38) teleostean genera (Smith-Vaniz *et al.*, 1995), they are far more frequent in trichiurid, carangid and sciaenid species (Smith-Vaniz *et al.*, 1995; Meunier *et al.*, 2008; Giarratana *et al.*, 2012). A review of these bony peculiarities within carangid species is herein presented in a phylogenetic framework.

Material and methods

This article is essentially a review and not a direct study on specimens, with one exception. A radiograph of the head of a silver scabbard fish [*Lepidopus caudatus* (Euphrasen 1788), SL: 790 mm, Trichiuridae, fished off the East Atlantic Ocean coast] has been performed at ONIRIS (Nantes, France). The fish was placed in lateral view and imaged using a Convix 30 Machine with a Universix 120 command at 46 kV and mAs at 6.4 with 17 ms. Images were developed using a Fuji FCR 5000. The specimen is conserved in the collections of the department of “Anatomie Comparée” at ONIRIS (Nantes, France).

What is known about hyperostosis, notably in carangids

Swollen bones, as a whole or as a part of the bone, have been mentioned in numerous teleostean fishes (Desse *et al.*, 1981; Gaudie and Czochanska, 1990; Meunier and Desse, 1994; Smith-Vaniz *et al.*, 1995; Smith-Vaniz et Carpenter, 2006; among others). They have the appearance of a gall, such as an osseous inflated pouch (Figs 1, 2). They can be present on the skull bones, including the neurocranium, on the elements of the pectoral and pelvic girdles, and on the axial skeleton, including on the pterygiophores (Fig. 3) and the haemal and the neural spines (Figs 1, 2).

Histologically, these masses are composed of acellular bone in most cases and result from activation of osteogenesis that yields primary spongy bone directly, or after an associated remodelling (Fierstine, 1968; Desse *et al.*, 1981;

(1) ISYEB, UMR 7205 CNRS-MNH-UPMC-EPHE, Muséum national d'Histoire naturelle, Département Systématique et Évolution, CP 50, 57 rue Cuvier 75005 Paris, France. [chanet@mnhn.fr]

Figure 1. – Radiographs of carangid fishes exhibiting hyperostosis. **A:** *Caranx hippos* (Linnaeus, 1766); **B:** *Alectis alexandrina* (Geoffroy St. Hilaire, 1817). Swollen, opaque bones with red dots are sites of hyperostosis, modified from Smith-Vaniz *et al.* (1995: 576, fig. 1). SL non indicated by these authors.

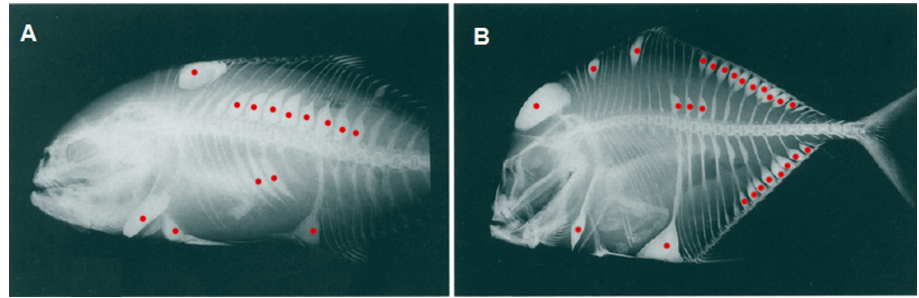
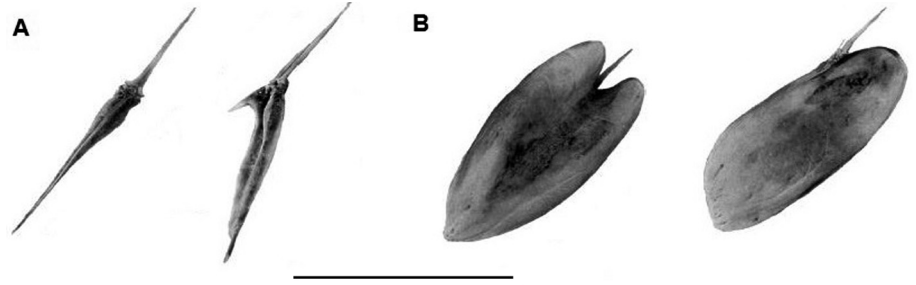


Figure 2. – First dorsal-fin pterygiophore of two adult carangids, modified from Smith-Vaniz *et al.* (1995: 576, fig. 2). **A:** *Caranx latus* Agassiz, 1831 (non hyperostotic), at left in dorsal view, at right in right lateral view. **B:** *Caranx hippos* (Linnaeus, 1766) (hyperostotic), at left in dorsal view, at right in right lateral view. Scale bar = 50 mm.



Gauldie and Czochanska, 1990; Meunier and Desse, 1994; Smith-Vaniz *et al.*, 1995). They often show a spongy and full of holes structure (Kaiser, 1960; Fierstine, 1968; Desse *et al.*, 1981; Gauldie and Czochanska, 1990). They are not pathological formations (Olsen, 1971; Desse *et al.*, 1981; Gauldie and Czochanska, 1990) because fishes bearing these structures have entirely normal behaviour (Johnson, 1973). The composition of the swellings is not different from that of normal bones (Desse *et al.*, 1981; Laroche *et al.*, 1982; Gaudant *et al.*, 2010). Carangid hyperostoses appear with increasing specimen size and are thus present in rather large and aged individuals (Desse *et al.*, 1981; Gaudant *et al.*, 2010).

Because the skeleton of the Carangidae is composed of acellular bone (= anosteocytic bone: Weiss and Watabe, 1979; Meunier *et al.*, 2008), hyperostotic structures are truly scattered islands of cellular bone in a skeleton otherwise characterized by acellular bony tissue. This makes carangid hyperostosis different from that encountered in species such as *Euthynnus lineatus* Kishinouye, 1920 (Scombridae) (*e.g.* Béarez *et al.*, 2005). Therefore, this scattering seems to occur consistently with ontogenetic development in the same bones in carangid species.

Hyperostosis has been observed in 22 teleostean families (Smith-Vaniz *et al.*, 1995), such as the Trichiuridae (Fig. 3), in which 80% of the examined specimens were hyperostotic (Giarratana *et al.*, 2012). However, it is within the Carangidae that genera affected by hyperostosis are the most frequent (Smith-Vaniz *et al.*, 1995: 574, tab. 1). This aptitude to hyperostosis seems to be absent, or at least very rare, in the closest relatives of carangids (Harrington *et al.*, 2016):

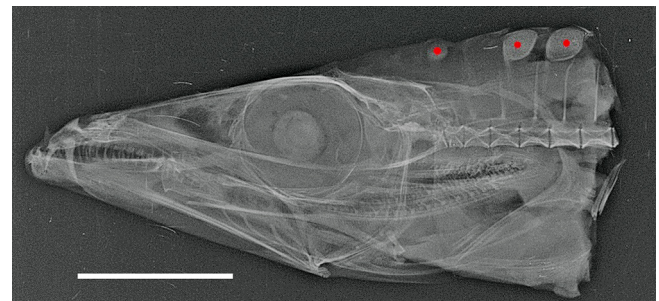


Figure 3. – Hyperostotic dorsal-fin pterygiophores on a radiographed head of a silver scabbard fish (*Lepidopus caudatus* (Euphrasen, 1788), SL: 790 mm, Trichiuridae). Hyperostotic structures are marked by red dots. Scale bar = 50 mm.

Coryphaenidae, Rachycentridae, Echeneidae, Polynemmiidae and Pleuronectiformes.

Successive interpretations and assumptions

The first illustrated case of hyperostosis in teleosts seems to be in a pterygiophore figured by Worm (1655: 270; Fig. 4), and cited by Weiler (1973). This bone was present in Ole Worm's "cabinet of curiosities". It was first incorrectly identified and called 'os wormiamum' (Worm, 1655), whereas Weiler (1973) identified this bone as a pterygiophore of *Ephippus* sp. (Ephippidae). Later, Bell (1793) described as tumours and probable exostoses swollen bony rounded masses on the pterygiophores of a species of *Chaetodon* [this specimen was later identified as a batfish (Ephippidae) by Rayer (1843) following Cuvier and Valenciennes (1831), and the currently accepted valid attribution is *Chaetodipterus faber* (Broussonet, 1782) (Eschmeyer and Fricke, 2010)]. Because the same structures exist in all specimens of the same species, Bell (1793) concluded that these swollen bones

were a normal part of their anatomy. Less than one century later, Gervais (1875a, b) described cases of hyperostosis in humans and animals. He illustrated (*ibid*: fig. 7) abnormal bony masses at the distal extremities of some pterygiophores of scabbard fish (*Lepidopus* sp., Trichiuridae), similar to the earliest description figured by Worm (1655; Fig. 3). The sec-

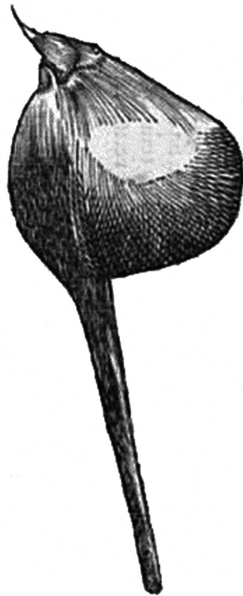

Figure 4. – First known illustration of a hyperostotic bone: a pterygiophore of *Chaetodipterus faber* (Broussonet, 1782), Ehippiidae, modified from Worm (1655: 270). No scale indicated by this author.

ond part of his 1875 work (Gervais, 1875b) is fully dedicated to hyperostoses in teleosts, which are described both morphologically and histologically. Ten years later, Bland-Sutton (1885) referred to such structures as either bony tumours or as cases of exostoses [*i.e.* any formation of new bony tissue at the surface of a bone (Manuila *et al.*, 1995)].

All these authors examined a variety of actinopterygian species [*e.g.* see Meunier and Herbin (2014: table 1: 38-39) for a list of species examined by Gervais, 1875a, b]. Therefore, numerous cases of hyperostoses have been described in various species distributed in teleostean fishes (Smith-Vaniz *et al.*, 1995, tab. 1:574) and especially in Acanthomorpha (Fig. 5). As frequently mentioned by various authors, this peculiarity is often present within the members of the Carangidae, whereas its occurrence is generally more sporadic in other families, such as the Gadidae (Bland-Sutton, 1885; Meunier *et al.*, 2008). So far, no clear explanation has been proposed to explain the over-representation in the Carangidae (Smith-Vaniz *et al.*, 1995). The latter authors suggest that hyperostosis may have a genetic origin (Smith-Vaniz *et al.*, 1995). However, functional hypotheses have generally been preferred and these have been various and numerous: from aiding in fin erection, aiding in neutral buoyancy, ageing action on bone, reaction to high temperatures, metabolic abnormality, pathogenic phenomenon, etc., but without reliable evidence (Meunier and Desse 1986; Smith-Vaniz *et al.*, 1995; Meunier *et al.*, 2008; Gaudant *et al.*, 2010).

Outside of carangids, hyperostotic structures have been reported in various teleostean species of the following fami-

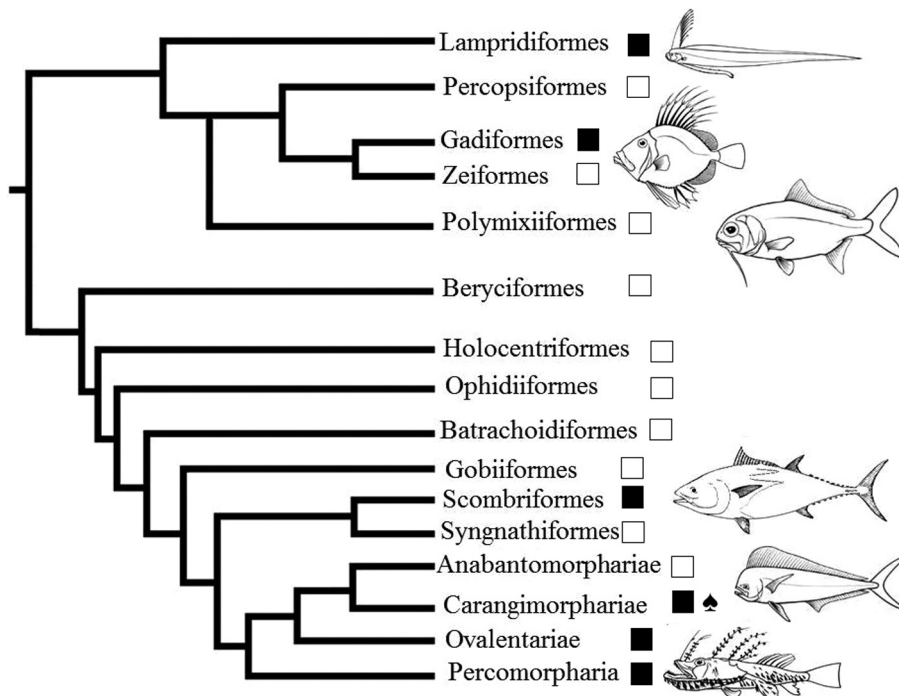


Figure 5. – Distribution of the known cases of hyperostosis in Acanthomorpha. The interrelationship tree has been modified after Chanet and Meunier (2014), following data from Smith-Vaniz *et al.* (1995, tab. 1:574), Betancur-R *et al.* (2013) and Chen *et al.* (2014). Spade ♠ indicates the position of the Carangidae. Black squares ■ represent groups where cases of hyperostosis are known, while white squares □ represent where no case of hyperostosis has been reported so far. See text for details.

lies: Muraenesocidae, Gadidae, Merlucciidae, Cyprinodontidae, Veliferidae, Triglinae, Platycephalidae, Centropomidae, Serranidae, Carangidae, Lutjanidae, Haemulidae, Sparidae, Sciaenidae, Drepanidae, Ephippidae, Scatophagidae, Pentaceroideae, Polynemidae, Trichiuridae, Monacanthidae, Tetraodontidae (Smith-Vaniz *et al.*, 1995) and Scombridae (Béarez *et al.*, 2005). The search for the homology between these different cases of hyperostosis could be interesting but would require histological studies on a large sample of species and specimens, from Carangidae to Muraenesocidae, Tetraodontidae, Trichiuridae, Haemulidae, Lutjanidae and Sciaenidae among others. At the present state of our knowledge, this distribution does not seem to be related to phylogeny, as these families occupy very different positions in our present representation of the evolutionary story of the teleosts (Betancur-R *et al.*, 2013; Chen *et al.*, 2014), including among Acanthomorpha (Fig. 5). We may think that the appearance of these swollen bones, if homologous, in such different groups, is the result of convergences, not common ancestry. Nevertheless, within some groups like the Carangidae, it is possible to think that an aptitude to hyperostosis may represent a common feature.

Finally, as Smith-Vaniz *et al.* (1995: 578) wrote: “Hyperostotic bones in fishes have stimulated curiosity for centuries, yet their function remains unknown”. That remains true even for the family where the phenomenon is best represented, *i.e.* the Carangidae.

Acknowledgements. – Deep thanks go to F. Giarratana (Polo Universitario dell’Annunziata, Messina, Italy) for providing specimens, to C. Guintard and S. Madec (ONIRIS, Nantes, France) for technical assistance, to J.F. Dejouannet (UMR 7138 CNRS S and pôle dessin UMS 2700 CNRS S, MNHN, Paris, France) for illustrations of figure 5, to J.C. Tyler (Smithsonian Institution, Washington D.C) for reviewing accurately the English text, to the two anonymous referees for valuable advice and to O. Otero (PalEvo-Prim - UMR7262 CNRS, Université de Poitiers, Poitiers, France) for inviting me to write in this volume dedicated to François J. Meunier. I first met François J. Meunier in 1984 at Roscoff (29, France) to learn on the strand the basics of marine biology. Later, he became one of my important teachers in zoology and comparative anatomy and then a colleague. I remember how puzzled I was when François showed me for the first time the gall-like swollen bones of a *Caranx* in his office at the MNHN in Paris. Since that time, even if my career followed different ways and subjects, I have always been interested in those swollen bones and this curiosity was driven by François J. Meunier.

REFERENCES

- BÉAREZ P., MEUNIER F.J. & KACEM A., 2005. - Description morphologique et histologique de l’hyperostose vertébrale chez la thonine noire, *Euthynnus lineatus* (Teleostei, Perciformes, Scombridae). *Cah. Biol. Mar.*, 46: 21-28.
- BELL W., 1793. - Description of a species of *Chaetodon*, called by the Malays, Ecan Bonna. *Phil. Trans. R. Soc. Lond.*, 83(3):7-9.
- BETANCUR-R. R., BROUGHTON R.E., WILEY E.O. *et al.* [24 authors], 2013. - The tree of life and a new classification of bony fishes. *PLoS Currents Tree of Life*. 2013 Apr 18: 1-45.
- BLAND-SUTTON J., 1885. - Tumours in animals. *J. Anat. Physiol.*, 19(Pt 4): 414-475.
- CHEN W.J., SANTINI F., CARNEVALE G., CHEN J.N., LIU S.H., LAVOUÉ S. & MAYDEN R.L., 2014. - New insights on early evolution of spiny-rayed fishes (Teleostei: Acanthomorpha). *Front. Mar. Sci.*, 1(53): 1-17.
- CHANET B. & MEUNIER F.J., 2014. - The anatomy of the thyroid gland among “fishes”: phylogenetic implications for the Vertebrata. *Cybium*, 38(2): 90-116.
- CUVIER G. & VALENCIENNES M., 1831. - Histoire naturelle des Poissons. 573 p. Paris: F. G. Levrault.
- DESSE G., MEUNIER F.J., PERON M. & LAROCHE J., 1981. - Hyperostose vertébrale chez l’animal. *Rhumatologie*, 33: 105-119.
- ESCHMEYER W.N. & FRICKE R., 2010. - Catalog of Fishes. World Wide Web electronic publication. Online Version, Updated 1 Nov. 2017. Available at research.calacademy.org/ichthyology/catalog/fishcatmain.asp.
- FIERSTINE H.L., 1968. - Swollen dorsal fin elements in living and fossil *Caranx* (Teleostei: Carangidae). *Contrib. Sci. Los Angeles*, 137: 1-10.
- FRANCILLON-VIEILLOT H., (de) BUFFRÉNIL V., CASTANET J., GÉRAUDIE J., MEUNIER F.J., SIRE J.Y., ZYLBERBERG L. & (de) RICQLÈS A., 1990. - Microstructure and mineralization of vertebrate skeletal tissues. *In: Skeletal Biomineralization: Patterns, Processes and Evolutionary Trends* (Carter J.G., ed.), Vol. 1, pp. 471-530. New York: Van Nostrand Reinhold.
- GAUDANT J., MEUNIER F.J. & BONELLI E., 2010. - Morphological and histological study of the hyperostosis of *Lepidopus* a fossil Trichiuridae from the Tortonian (Upper Miocene) of Piedmont (Italy). *Cybium*, 34(3): 293-301.
- GAULDIE R.W. & CZOCHANSKA Z., 1990. - Hyperostotic bones from the New Zealand snapper *Chrysophrys auratus* (Sparidae). *Fish. Bull.*, 88: 201-206.
- GERVAIS P., 1875a. - De l’hyperostose chez l’homme et chez les animaux (1 : mammifères, oiseaux, reptiles). *J. Zool.*, 4: 272-284.
- GERVAIS P., 1875b. - De l’hyperostose chez l’homme et chez les animaux (2 : poissons). *J. Zool.*, 4: 445-462.
- GIARRATANA F., RUOLO A., MUSCOLINO D., MARINO F., GALLO M. & PANEBIANCO A., 2012. - Occurrence of hyperostotic pterygiophores in the Silver Scabbardfish, *Lepidopus caudatus* (Actinopterygii: Perciformes: Trichiuridae). *Acta Ichthyol. Piscatoria*, 42(3): 233-237.
- HARRINGTON R.C., FAIRCLOTH B.C., EYTAN R.I., SMITH W.L., NEAR T.J., ALFARO M.E. & FRIEDMAN M., 2016. - Phylogenomic analysis of carangimorph fishes reveals flatfish asymmetry arose in a blink of the evolutionary eye. *BMC Evol. Biol.*, 16(1): 224.
- JOHNSON C.R., 1973. - Hyperostosis in fishes of the genus *Platycephalus* (Platycephalidae). *Jpn. J. Ichthyol.*, 20: 178.
- KAISER H.E., 1960. - Untersuchungen zur Vergleichender Osteologie des Fossilen und regenten Pachyostosen. *Paleontology*, 114: 113-196.
- KONNERTH A., 1966. - Tilly bones. *Oceanus*, 12(2): 6-9.
- LAROCHE J., PERON M. & LE GAL Y., 1982. - Étude de l’hyperostose vertébrale et crânienne chez deux téléostéens *Trachurus trachurus* et *Trachurus mediterraneus*, par la diffraction des rayons X et l’incorporation de 45 Ca. *C. R. Acad. Sci.*, 294: 1045-1050.

- MANUILA L., MANUILA A. & NICOULIN M., 1995. - Dictionnaire médical. 6th edit., 505 p. Paris: Masson.
- MEUNIER F.J. & DESSE G., 1986. - Les hyperostoses chez les Téléostéens: description, histologie et problèmes étiologiques. *Ichthyophysiol. Acta*, 10: 130-141.
- MEUNIER F.J. & DESSE J., 1994. - Histological structure of hyperostotic cranial remains of *Pomadasys hasta* (Osteichthyes, Perciformes, Haemulidae) from archeological sites of the Arabian Gulf and the Indian Ocean. In: Fish Exploitation in the Past, Proc. 7th Meet. ICAZ Fish Remains Working Group (Van Neer W., ed.), *Ann. Mus. R. Afr. Cent., Sci. Zool.*, 274: 47-53.
- MEUNIER F.J. & HERBIN M., 2014. - La collection de préparations histologiques effectuées par Paul Gervais (1816-1879) sur le squelette des "poissons". *Cybium*, 38(1): 23-42.
- MEUNIER F.J., DESCHAMPS M.H., LECOMTE F. & KACEM A., 2008. - Le squelette des poissons téléostéens : structure, développement, physiologie, pathologie. *Bull. Soc. Zool. Fr.*, 133(1-3): 9-32.
- NELSON J., 2006. - Fishes of the World. 4th edit., 601 p. New Jersey: John Wiley & Sons.
- OLSEN S.J., 1971. - Swollen bones in the Atlantic cutlass fish *Trichiurus lepturus* Linnaeus. *Copeia*, (1): 174-175.
- RAYER P.F., 1843. - Archives de médecine comparée. *Arch. Méd. Comp.*, 1(2): 1-311.
- SMITH-VANIZ W.F. & CARPENTER K., 2006. - Review of the crevalle jacks, *Caranx hippos* complex (Teleostei: Carangidae), with a description of a new species from West Africa. *Fish. Bull.*, 106 : 207-233.
- SMITH-VANIZ W.F., KAUFMAN L.S. & GLOVACKI J., 1995. - Species-specific patterns of hyperostosis in marine teleost fishes. *Mar. Biol.*, 121: 573-580.
- WEILER W., 1973. - Durch Hyperostose verdickte Fischknochen aus dem oberen Sarmat von Nord-Carolina, USA. *Senckenb. Lethaea*, 53: 469-477.
- WEISS R.E. & WATABE N., 1979. - Studies on the biology of fish bone. III. Ultrastructure of osteogenesis and resorption in osteocytic (cellular) and anosteocytic (acellular) bones. *Calcif. Tissue Int.*, 28: 43-56.
- WORM(ius) O., 1655. - Museum Wormianum, seu, Historia rerum rariorum : tam naturalium, quam artificialium, tam domesticarum, quam exoticarum, quae Hafniae Danorum in aedibus authoris servantur. 389 p. Amsterdam: Ludovicum & Danielem Elzevirios.

