



HAL
open science

RVOT premature ventricular contractions induce significant anatomical displacement during 3D mapping: A cause of mid-term ablation failure?

Corentin Chaumont, Raphaël P Martins, Guillaume Viart, Dominique Pavin, Brieuc Noirot-Cosson, David Huchette, Arnaud Savouré, Bénédicte Godin, Adrian Mirolo, Jorys Achard, et al.

► To cite this version:

Corentin Chaumont, Raphaël P Martins, Guillaume Viart, Dominique Pavin, Brieuc Noirot-Cosson, et al.. RVOT premature ventricular contractions induce significant anatomical displacement during 3D mapping: A cause of mid-term ablation failure?. Archives of Cardiovascular Diseases, 2023, 10.1016/j.acvd.2022.10.008 . hal-03970029

HAL Id: hal-03970029

<https://hal.science/hal-03970029>

Submitted on 15 Feb 2023

HAL is a multi-disciplinary open access archive for the deposit and dissemination of scientific research documents, whether they are published or not. The documents may come from teaching and research institutions in France or abroad, or from public or private research centers.

L'archive ouverte pluridisciplinaire **HAL**, est destinée au dépôt et à la diffusion de documents scientifiques de niveau recherche, publiés ou non, émanant des établissements d'enseignement et de recherche français ou étrangers, des laboratoires publics ou privés.



Distributed under a Creative Commons Attribution - NonCommercial 4.0 International License

RVOT premature ventricular contractions induce significant anatomical displacement during 3D mapping: a cause of mid-term ablation failure?

Abbreviated title: RVOT PVCs induce anatomical displacement during 3D mapping

Corentin Chaumont^{a,b}, Raphael P. Martins^c, Guillaume Viart^d, Dominique Pavin^c, Briec Noiro-Cosson^e, David Huchette^e, Arnaud Savoure^a, Benedicte Godin^a, Adrian Mirolo^a, Jorys Achard^f, Simon Rivron^f, H el ene Eltchaninoff^{a,b}, Fr ed eric Anselme^{a,b}

^a *Department of Cardiology, Rouen University Hospital, Rouen, 76000, France*

^b *FHU REMOD-VHF, UNIROUEN, INSERM U1096, 76000, France*

^c *University of Rennes, CHU Rennes, INSERM, LTSI – UMR 1099, 35000 Rennes, France*

^d *Department of Cardiology, GCS-Groupement des  h opitaux de l’institut Catholique de Lille/Facult  Libre de M decine, Lille, 59800, France*

^e *Department of Cardiology, Lens Hospital, Lens, 62300, France*

^f *Biosense Webster France, Johnson&Johnson, Issy-Les-Moulineaux, 92787, France*

* *Corresponding author at: CHU – H opitaux de Rouen, 1 rue de Germont, 76031 Rouen Cedex.*

E-mail address: Frederic.anselme@chu-rouen.fr (F. Anselme).

Highlights

- RVOT PVCs induce anatomical displacement during 3D electroanatomical mapping
- Target ablation site displacement occurs predominantly along a vertical axis
- RVOT PVC-induced displacement can mislead the operator about the site of origin

Summary

Background. – Catheter ablation is a first-line treatment for symptomatic right ventricular outflow tract (RVOT) premature ventricular complexes (PVCs). There is evidence of displacement of the ablation target site during PVCs relative to the location in sinus rhythm (SR).

Aim. – To analyse the extent of displacement induced by RVOT PVCs and its effect on the ablation sites and the mid-term efficacy of ablation.

Methods. – In this multicentre French study, we retrospectively included 18 consecutive adults referred for ablation of RVOT PVCs using a three-dimensional (3D) mapping system. PVC activation maps were performed conventionally (initial map), then each PVC activation point was manually reannotated considering the 3D location on a previous SR beat (corrected map). The ablation-site locations on the initial or the corrected area, including the 10 best activation points, were analysed. Mid-term efficacy was evaluated.

Results. – The direction of map shift during PVCs relative to the map in SR occurred along a vertical axis in 16 of 18 patients. The mean activation-point displacement for each of the 18 mapped chambers was 5.6 ± 2.2 mm. Mid-term recurrence of RVOT PVCs occurred in 5 (28%) patients. In all patients with recurrences, no significant ablation lesion was located on the corrected (true) site of origin.

Conclusions. – RVOT PVCs induce a vertical anatomical shift that can mislead physicians about the true location of the arrhythmia's site of origin. Our study highlights the association between mid-term PVC recurrence and the absence of spatial overlap between ablation points and the corrected site of origin.

KEYWORDS

Premature ventricular contraction;

RVOT PVC;

Radiofrequency ablation;

3D electroanatomical mapping system;

Cardiac arrhythmia

Abbreviations: AI: ablation index; LAT: local activation time; LVEF: left ventricular ejection fraction;
PVCs: premature ventricular complexes; RVOT: right ventricular outflow tract.

Journal Pre-proof

Introduction

Premature ventricular complexes (PVCs) originating from the right ventricular outflow tract (RVOT) are a common arrhythmia. While RVOT PVCs are frequently benign, they can be symptomatic and disabling or even cause a cardiomyopathy with impaired left ventricular ejection fraction (LVEF) [1]. Catheter ablation has become a first-line treatment for symptomatic and frequent RVOT PVCs because of the high acute success and low complication rates [2,3]. In a retrospective study in 510 patients, catheter ablation significantly reduced PVC burden and improved LVEF compared with antiarrhythmic drug therapy [4]. Over the past few years, the development of 3-dimensional (3D)-electroanatomical mapping systems has given the opportunity to study the ventricular electrical activation pattern with a high degree of precision and has further increased the efficiency of catheter ablation. However, 30% of patients may experience PVC recurrence within 12 months of the ablation procedure [5]. Whereas it was assumed that the chamber geometry remained identical during both sinus rhythm and PVCs, Andreu D *et al.* [6] were the first to show the existence of a displacement of the ventricles and the ablation target site during a PVC beat compared with that in the sinus rhythm position. As ablation lesions are often delivered during sinus rhythm, this PVC-induced displacement could deceive the operator about the true location of the PVC site of origin. The aim of this study was, therefore, to analyse the extent of displacement induced by RVOT PVCs and its implications for the ablation sites and mid-term efficacy of ablation.

Methods

This study was conducted in four hospitals in France. We retrospectively included all consecutive patients referred over the past 12 months for ablation of idiopathic ventricular ectopies originating from the RVOT using the CARTO 3D electroanatomical mapping system. All ablation procedures were performed with the Pentaray® catheter for mapping and a contact-force open-irrigation radiofrequency catheter for ablation. The "Tissue Proximity Index" filter was activated in all cases. Exclusion criteria were age less than 18 years, mapping procedures performed using only pace mapping, and activation maps for which less than 100 points were obtained. Acute success was defined as abolition of PVC activity at baseline and during isoprenaline infusion, after a 30-min wait following the last radiofrequency delivery.

The local ethics committee approved the study and all patients provided informed consent for the procedure and data collection.

Follow-up

Clinical evaluation and 24-h Holter monitoring were performed in all patients 3–6 months after the ablation procedure. Afterwards, patients continued usual follow-up with their referring cardiologist and general practitioner. Clinical follow-up included review of the patients' medical records and telephone contact with their referring physicians, if necessary. Documented recurrence was defined as PVCs with the same electrocardiographic pattern as that recorded preablation. Patients with more than 3000 PVCs on 24-h Holter monitoring performed during follow-up were considered to have recurrence of frequent PVCs.

Technical approach of 3D-map analysis and reannotation of activation points

All activation maps were analysed retrospectively. We first verified that the morphology of the PVC was unique and constant throughout the acquisition of all the activation points. Activation points taken on bursts of more than two PVCs were excluded. Activation times during PVCs were automatically determined using the CARTO® WAVEFRONT ANNOTATION™ Module (Biosense Webster, Issy-Les-Moulineaux, France), a dedicated annotation algorithm that considers both unipolar and bipolar signals. All activation points were then manually checked and adjusted if needed.

The initial local activation time (LAT) map was used as a reference (the raw PVC map). A copy was generated, on which each point was manually reannotated considering the previous sinus rhythm beat 3D location (the corrected PVC map). This manoeuvre did not modify the activation times of reannotated points. Of importance, only the original activation points (raw PVC maps) were visualized during the ablation procedures as this reannotation method was performed retrospectively.

We finally checked that raw and corrected PVC activation maps had the same number of points. The 10 best activation points were identified and used for analysis. The 3D location of each point was extracted from the CARTO system for both maps. Spatial point coordinates (i.e. x, y and z coordinates) for raw and corrected PVC maps were generated and recorded in a calculation workbook. The Euclidean distance between each point on both maps, representing the PVC-induced displacement, was calculated. The total number of VISITAGs (ablation sites) and their location, either

within the initial or corrected area including the 10 best points, were collected. Of note, a CARTO VISITAG location represents a single ablation site, accumulating consecutive catheter positions recorded during application of radiofrequency energy while the ablation catheter is stable in a specific area. In our study, VISITAG apparition filters were established as follow: minimum distance change below 3 mm; minimum application time up to 3 s; and minimum force contact up to 3 g. We also collected the corresponding ablation index (AI), a visual indication based on evaluation of power, force and time parameters according to an equation and coefficients. VISITAGS were classified into two groups according to an ablation index threshold set at 450, in accordance with what has already been shown as producing an effective lesion in PVC ablation [7]. Colouring threshold was accordingly fixed to 450 (i.e. red for $AI \geq 450$ and pink for < 450).

Statistical analysis

Continuous variables are expressed as mean \pm standard deviation (SD) for normally distributed data and as median and interquartile range (IQR) for non-normally distributed data. Normal distribution was assessed by a Shapiro–Wilk test. Categorical variables are expressed as counts and percentage.

Results

Fifty-four patients underwent RVOT PVC ablation procedures at four hospitals in France from January 2019 to January 2020. Fifteen patients whose ablation procedures were performed using a 3D mapping system other than CARTO were excluded. Thirty-nine patients were screened for inclusion, 21 of whom did not meet the study criteria (i.e. activation map with < 100 points [$n = 14$] or ablation procedure performed using pace mapping only [$n = 7$]). The study population therefore comprised 18 patients (Fig. 1).

Patient baseline characteristics are shown in Table 1. All patients had symptomatic frequent PVCs and 1 had PVC-induced cardiomyopathy. Mean LVEF was $58 \pm 9\%$ and 1 patient had an LVEF of $< 40\%$. From these patients, 18 unique chamber maps and a total of 2049 individual mapped points were analysed.

Acute procedural outcomes

Mean procedure duration was 65 ± 19 min. Acute procedural success was obtained in all patients. Mean PVC duration was 130 ± 13 ms and mean coupling interval was 494 ± 93 ms. The site of origin within the RVOT was septal in 9 patients, lateral in 2, anterior in 3 and posterior in 4. The direction of map shift during PVCs relative to the map in sinus rhythm occurred along a craniocaudal axis in 16 of 18 patients (Fig. A.1). For those patients, the corrected PVC site of origin was located superior to the initial site of origin. The displacement was lateral in 2 patients. Considering all activation points, the mean displacement for each of the 18 mapped chambers was 5.6 ± 2.2 mm. The maximal displacement for each mapped chamber was 13.9 ± 3.2 mm. Considering only the 10 best activation points, for each of the 18 mapped chambers, the mean displacement distance was 5.1 ± 1.8 mm and the maximal displacement was 8.2 ± 3.4 mm.

Mid-term follow up

At 3–6-month follow up (mean 4.4 ± 1.9 months), 13 patients remained free from symptoms, with less than 500 PVCs on 24-h Holter monitoring. Recurrence of frequent and symptomatic RVOT PVCs occurred in 5 patients (Fig. A.2). The characteristics of these patients are shown in Table 2. Of note, they all underwent a successful redo procedure. The sites of interest were in the same area within the RVOT.

There was no significant difference in the mean displacement distance between patients who remained free from arrhythmias and those with recurrence (5.3 ± 1.8 vs 6.3 ± 3.0 , respectively). However, when considering these 5 patients, none had a VISITAG ≥ 450 AI on the area including the 10 best LAT corrected points, whereas all had significant ablation lesions on the initial best points (Central illustration). Conversely, 8 of 13 patients free from PVCs had a VISITAG ≥ 450 AI on the 10 best LAT corrected points (0/5 vs 8/13) (Fig. 2). In the remaining 5 patients without recurrence, none of the recorded VISTAGS were ≥ 450 AI, but most of the VISITAGs (mean of 6) were on the area including the 10 best LAT corrected points.

Discussion

Spatial displacement during 3D electroanatomical mapping of RVOT PVCs

3D geometry volume acquisition as well as radiofrequency ablation lesions are mainly performed during sinus rhythm whereas the PVC activation map is, by definition, performed during PVC beats.

Consequently, in case of anatomical displacement of the heart chamber during PVC, points mapped during PVCs would be spatially displaced with regards to their true location on the map in sinus rhythm and could potentially be misleading for ablation.

Our study confirms the existence of a PVC-induced anatomical displacement during 3D mapping and ablation of RVOT PVCs. PVC-induced anatomical displacement could be explained by two phenomena: the short coupling interval between PVC and the previous sinus beat, and a mechanical activation pattern of the ventricle during PVC that differs from sinus rhythm. Other studies have demonstrated a significant spatial displacement between the activation point position in sinus rhythm and during PVC beats, regardless of the origin of the PVC [6,8,9]. Interestingly, this displacement has been shown to increase with the shortening of the PVC coupling interval and to be greater in the right than in the left ventricle [6]. In a study including 55 consecutive patients undergoing PVC ablation and a total of 7000 points from 71 electroanatomical activation maps, a median distance of 9 mm was found between the points position during sinus rhythm and PVC [6]. De Potter *et al.* [8] also showed that PVCs caused a position shift in 3D mapping systems due to motion of the heart within the established geometry. In this study, the mean shift was also 9 mm. In another study, the earliest annotated PVC location was spatially displaced from the corresponding successful ablation site annotated during sinus rhythm by a mean of 6.7 mm (range 3.3–13.0 mm) [9].

In the present study focusing solely on RVOT PVCs, we confirmed a significant displacement of 5.6 ± 2.2 mm, and first demonstrated that the targeted ablation site displacement occurs predominantly along a craniocaudal axis. In 15 of 18 patients, the corrected PVC site of origin was located superiorly to the initial site of origin, likely due to an inferior displacement of the heart chamber during PVC beats (Central illustration and Fig. 2). In a study using a home-made algorithm, a systematic and similar displacement in terms of axis was found in a subgroup of 9 patients with RVOT PVCs. The corrected area was located superior and posterior to the initial site of interest [8]. Another study including 21 patients (only 8 with RVOT PVCs) found an overall direction of map shift during PVC leftwards and inferior relative to the map for sinus rhythm. However, all types of PVCs were included in this study and the displacement direction was not detailed for each patient and for each PVC origin [9].

Clinical efficacy of PVC ablation

Our study also focused on the clinical efficacy of PVC ablation. We first investigated the impact of this displacement on clinical efficacy of radiofrequency PVC ablation. The mid-term success rate was 72%, similar to what has been described in the literature [4]. Our results also showed that the mid-term arrhythmia recurrences were most likely related to PVC-induced displacement, as ablation lesions were delivered remote from the area of interest in all these cases ([Central illustration](#)). Despite acute success, those mid-term recurrences might also be explained by insufficient radiofrequency delivery on site of origin (i.e. low AI and/or deep foci). Taking this displacement into account during the index PVC ablation procedure could therefore affect the outcome.

Considering that irrigated radiofrequency application generally induces a lesion 5–6 mm wide (2.5 mm of radius), the mean displacement of 5.6 mm could very well be of clinical relevance except if additional application lesions are systematically performed around the site of origin.

The amount of shift was not correlated with the mid-term success of ablation. However, the lack of significant ablation lesions (i.e. ablation index ≥ 450) within the corrected area including the 10 best points seemed to be associated with clinical recurrences. To our knowledge, this association between mid-term PVC recurrence and the absence of spatial overlap between the ablation points and the corrected site of origin has not previously been described.

Of importance, only the original activation points (raw PVC maps) were visualized during the ablation procedures. Looking at maps recorded in patients with mid-term success, we found that ablation lesions were always delivered within the corrected PVC site of origin area. In some patients, radiofrequency lesions were first delivered at the initial site of origin on the geometry and then, due to lack of efficacy, were delivered slightly above ([Fig. 2](#)). In others, ablation was directly applied at the corrected site of origin, mainly guided by the online analysis of the PVC signal rather than looking at the site of origin on the map.

Clinical applications of this new approach

While the manual approach used in our study is extremely time-consuming, the recent version of the CARTO system incorporates a so-called LAT Hybrid module. This new algorithm automatically adjusts the points considering the 3D location during the sinus beat while preserving the local activation time

of the PVC beat. Our method, although performed manually, corresponds to the algorithm as evidenced by recent cases performed with both approaches (Fig. 3). In case of PVC ablation performed with other 3D mapping system, it could be wise to pay attention to the PVC electrogram morphology and its prematurity at the site located just cranially to the initial best site of origin, particularly if initial ablation lesions do not lead to immediate PVC disappearance. Further studies will be needed to evaluate whether this new approach will lead to better long-term clinical efficacy.

Limitations

This was a retrospective study with its inherent biases. The population was also highly selected (i.e. limited to ablation procedures using the CARTO 3D electroanatomical mapping system and activation maps of > 100 points).

Conclusions

RVOT PVCs induce an anatomical shift that can mislead physicians about the true location of the arrhythmia's site of origin. This displacement occurs predominantly on a craniocaudal axis. Our study highlights the association between mid-term PVC recurrence and the absence of spatial overlap between the ablation points and the corrected site of origin. Taking this phenomenon into account may improve PVC ablation outcomes.

Sources of funding

None.

Disclosure of interest

F.A. is a consultant for and has received lecture fees from Boston Scientific, Medtronic and Microport CRM; R.P.M. and D.H. are consultants for and have received lecture fees from Biosense. J.A and S.R. (Biosense Webster Engineers) participated in the reannotation of 3D maps and were blinded to the known of clinical outcomes. They did not participate in follow-up data collection, data analysis or writing of the manuscript. The other authors report no conflicts of interest.

References

- [1] Yarlagadda RK, Iwai S, Stein KM, et al. Reversal of cardiomyopathy in patients with repetitive monomorphic ventricular ectopy originating from the right ventricular outflow tract. *Circulation* 2005; 112:1092-1097.
- [2] Morady F, Kadish AH, DiCarlo L, et al. Long-term results of catheter ablation of idiopathic right ventricular tachycardia. *Circulation* 1990; 82:2093-2099.
- [3] Zeppenfeld K, Tfelt-Hansen J, de Riva M, et al. 2022 ESC Guidelines for the management of patients with ventricular arrhythmias and the prevention of sudden cardiac death. *Eur Heart J* 2022; 43:3997-4126.
- [4] Zhong L, Lee YH, Huang XM, et al. Relative efficacy of catheter ablation vs antiarrhythmic drugs in treating premature ventricular contractions: a single-center retrospective study. *Heart Rhythm* 2014; 11:187-193.
- [5] Abraham P, Ambrus M, Herczeg S, et al. Similar outcomes with manual contact force ablation catheters and traditional catheters in the treatment of outflow tract premature ventricular complexes. *Europace* 2021; 23:596-602.
- [6] Andreu D, Berruezo A, Fernandez-Armenta J, et al. Displacement of the target ablation site and ventricles during premature ventricular contractions: relevance for radiofrequency catheter ablation. *Heart Rhythm* 2012; 9:1050-1057.
- [7] Casella M, Gasperetti A, Gianni C, et al. Ablation Index as a predictor of long-term efficacy in premature ventricular complex ablation: A regional target value analysis. *Heart Rhythm* 2019; 16:888-895.

- [8] De Potter T, Ilidromitis K, Bar-On T, Silva Garcia E, Ector J. Premature ventricular contractions cause a position shift in 3D mapping systems: analysis, quantification, and correction by hybrid activation mapping. *Europace* 2020; 22:607-612.
- [9] Steyers CM, 3rd, Sodhi S, Faddis MN, Cooper DH, Cuculich PS, Noheria A. Ablation using 3D maps adjusted for spatial displacement of premature ventricular complexes relative to sinus beats: Improving precision by correcting for the shift. *J Cardiovasc Electrophysiol* 2019; 30:2319-2325.

Journal Pre-proof

Figures

Figure 1. Flow chart. PVCs: premature ventricular complexes; RVOT: right ventricular outflow tract.

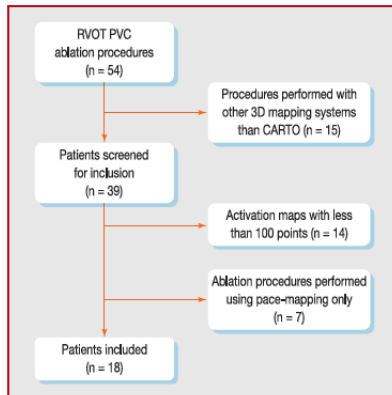


Figure 2. 3D map showing the 10 best activation points of a RVOT PVC (left anterior oblique view) and the locations of the ablation lesions. Panel A: 3D map of the targeted PVC showing the 10 best activation times; initial points (raw PVC map) are shown in orange and manually reannotated points (corrected map) in green. The displacement direction is craniocaudal and the mean distance is 8.2 mm. Panel B: During the radiofrequency applications, only the initial points (orange area) were visualized by the operator. Note that the operator first targeted the initial points and, due to the lack of efficacy, ablation lesions with ablation index ≥ 450 were then applied higher within the corrected PVC map (green area). This patient remained free from PVCs at 4-month follow-up. VISITAGS are shown in size 2 (2 mm radius). 3D: three-dimensional; PVCs: premature ventricular complexes; RVOT: right ventricular outflow tract.

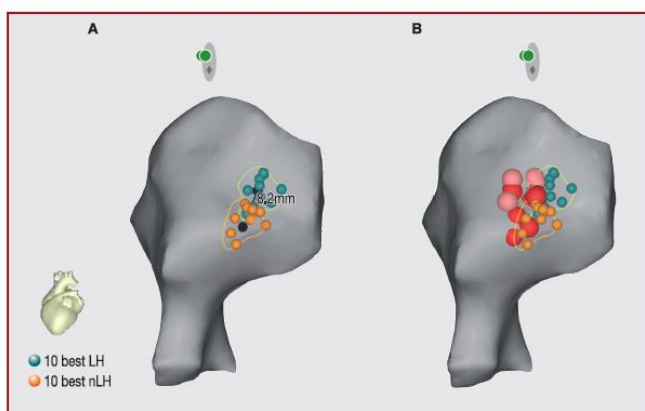
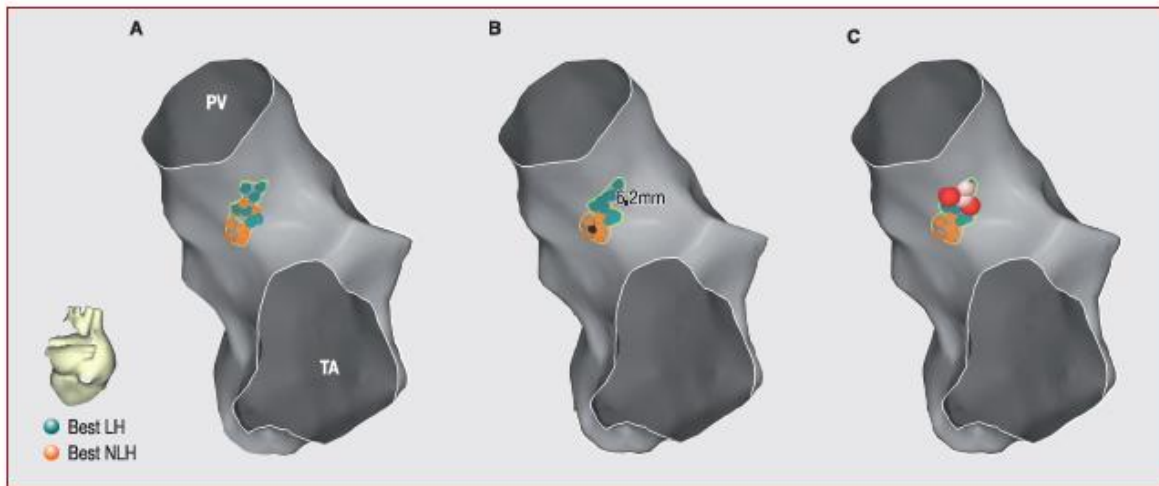


Figure 3. Comparison between the manual reannotation method used in the study and the new LAT hybrid algorithm. Panel A: 3D map of targeted PVCs showing the 10 best activation times; initial points (raw PVC map) are shown in orange and manually reannotated points (corrected PVC map) in green. Panel B: Initial points are shown in orange and automatically reannotated points (using the LAT hybrid algorithm) in green. The displacement (6.2 mm) is similar to that observed using the manual method. Panel C: 3D map showing the ablation lesions (VISITAGS). Note that ablation lesions with significant ablation index (i.e. $AI \geq 450$) were applied directly within the corrected PVC area (green area), above the raw PVC area. This patient remained free from PVCs at 4-month follow-up. VISITAGS are shown in size 2 (2 mm radius). AI: ablation index; LAT: local activation time; PVCs: premature ventricular complexes; RVOT: right ventricular outflow tract.



Central illustration. 3D map showing the 10 best activation points of a septal RVOT PVC and the ablation lesion locations. Panel A: 3D map of the targeted PVC showing the 10 best activation times: initial points are shown in orange and manually reannotated points in green. The displacement direction is craniocaudal and the mean distance is 8.4 mm. Panel B: During radiofrequency applications, only the initial points (orange area) were visualized by the operator. Note that there are no significant ablation lesions (i.e. AI \geq 450) located within the corrected area (green points). This ablation was acutely successful but the patient required a second ablation procedure 3 months later. VISITAGS are shown in size 2 (2 mm radius). AI: ablation index; LH: lat hybrid; PVCs: premature ventricular complexes; RVOT: right ventricular outflow tract.

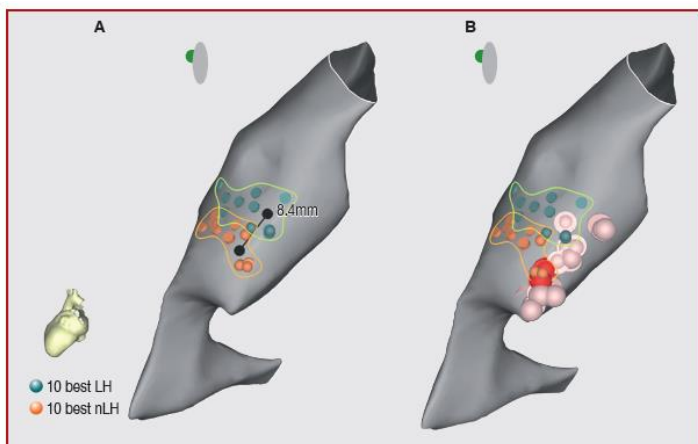


Table 1. Patient baseline characteristics (*n* = 18)

Characteristic	
Baseline characteristics	
Age (years)	46 ± 15
Body mass index (kg/m ²)	27.6 ± 3.8
Female sex	9 (50)
Symptoms	
Palpitations	13 (72)
Dyspnoea	5 (28)
Syncope or lightheadedness	4 (22)
Antiarrhythmic drugs	
Beta-blockers	13 (72)
Amiodarone	1 (6)
Calcium-channel blocker	1 (6)
Echocardiography	
Underlying structural heart disease	0 (0)
PVC-induced LVEF impairment	1 (6)
LVEF (%)	58 ± 9
24-h Holter monitoring	
Number of PVCs	23 461 ± 10 815
Monomorphic PVC	18 (100)
PVC characteristics	
PVC duration (ms)	130 ± 13
Mean coupling interval (ms)	493 ± 90
Fixed coupling interval	10 (55)

Data are expressed as number (%) or mean ± standard deviation. LVEF: left ventricular ejection fraction; PVCs: premature ventricular complexes.

Table 2. Characteristics of patients who needed a redo-procedure

	Patient 1	Patient 2	Patient 3	Patient 4	Patient 5
Baseline characteristics					
Age (years)	23	48	58	59	20
Body mass index (kg/m ²)	25	27	31	23	33
Female sex	Male	Male	Female	Female	Female
Symptoms					
Palpitations	1	1	0	1	1
Dyspnoea	1	0	1	0	0
Syncope or lightheadedness	0	0	0	1	0
Echocardiography					
PVC-induced LVEF impairment	1	0	0	0	0
LVEF (%)	38	55	61	76	64
PVC characteristics					
Number of PVCs/24 h	12,000	30,000	32,500	31,000	19,000
PVC duration (ms)	148	127	115	146	139
Mean coupling interval (ms)	570	612	445	511	346
Fixed coupling interval	0	0	1	0	1
Procedure characteristics					
VISITAGS (AI ≥ 450) on 10 best LAT initial points	2	1	1	1	2
VISITAGS (AI ≥ 450) on 10 best LAT corrected points	0	0	0	0	0
Shift direction	CC ^a	Lateral	CC	CC	CC
Mean displacement (mm)	7.9 ± 2.5	4.3 ± 2.7	10.7 ± 3.9	5.0 ± 1.9	3.4 ± 2.4
Maximal displacement (mm)	16.5	13	18.7	9.5	14.2
Mean displacement for 10 best LAT (mm)	6.6 ± 2.3	2.9 ± 1.0	9.6 ± 4.7	4.3 ± 0.9	3.9 ± 1.6
Post-ablation data					

Number of PVCs/24h	17,000	22,000	27,000	25,000	12,000
--------------------	--------	--------	--------	--------	--------

Data are expressed as number (%) or mean \pm standard deviation. LVEF: left ventricular ejection fraction; PVCs: premature ventricular complexes.

^a Craniocaudal axis.

Journal Pre-proof

1 **Table 3.** Characteristics of patients without recurrences

	Patient 6	Patient 7	Patient 8	Patient 9	Patient 10	Patient 11	Patient 12	Patient 13	Patient 14	Patient 15	Patient 16	Patient 17	Patient 18
Baseline characteristics													
Age (years)	30	45	46	48	37	33	50	72	52	52	60	71	30
Body mass index (kg/m ²)	23	24	28	21	29	26	33	25	27	28	26	33	25
Female sex	M	M	M	F	F	M	F	F	F	M	M	M	F
Symptoms													
Palpitations	0	1	1	0	1	0	1	1	1	1	1	0	1
Dyspnoea	1	0	0	1	0	1	0	0	0	0	0	0	0
Syncope or lightheadedness	0	0	1	0	0	0	0	0	0	0	0	1	1
Echocardiography													
PVC-induced LVEF impairment	0	0	0	0	0	0	0	0	0	0	0	0	0
LVEF (%)	59	57	60	55	68	63	55	60	55	51	63	65	50
PVC characteristics													
Number of PVCs/24 h (× 10 ³)	14	42	38	12	11	37	36	34	27	23	19	17	11

PVC duration (ms)	120	136	135	122	145	140	110	133	120	153	122	126	122
Mean coupling interval (ms)	526	591	675	541	530	454	467	435	350	478	337	484	549
Fixed coupling interval	1	0	0	0	0	1	1	1	1	0	1	1	1
Procedure characteristics													
VISITAGS (AI \geq 450) on 10 best LAT initial points	0	1	0	0	2	0	0	3	3	3	4	5	0
VISITAGS (AI \geq 450) on 10 best LAT corrected points	1	1	0	0	1	0	0	3	3	2	3	5	0
Shift direction	CC	CC	CC	CC	CC	CC	Lateral	CC	CC	CC	CC	CC	CC
Mean displacement (mm)	5.8	2.0	4.8	8.5	7.0	6.2	3.7	4.2	5.3	7.3	3.9	3.6	6.9
Maximal displacement (mm)	14.1	9.6	22	13.6	15.8	11.8	14.6	16.2	14.2	10.7	9.9	11.5	14.4
Mean displacement for 10 best LAT (mm)	5.9	2.0	4.7	8	5.6	6.8	4.3	4.8	3.5	6.9	4.4	4.2	5.3
Number of PVCs/24 h post ablation	7	16	438	23	12	0	86	156	92	0	373	93	117

1 AI: ablation index; LAT: local activation time; CC: craniocaudal axis; F: female; LVEF: left ventricular ejection fraction; M: male; PVCs: premature
2 ventricular complexes.

3

Journal Pre-proof