



HAL
open science

Chest computed tomography improvement in patients with cystic fibrosis treated with elexacaftor-tezacaftor-ivacaftor: Early report

Romain Bec, Martine Reynaud-Gaubert, François Arnaud, Romain Naud, Nadine Dufeu, Mathieu Di Bisceglie, Benjamin Coiffard, Jean-Yves Gaubert, Julien Bermudez, Paul Habert

► To cite this version:

Romain Bec, Martine Reynaud-Gaubert, François Arnaud, Romain Naud, Nadine Dufeu, et al.. Chest computed tomography improvement in patients with cystic fibrosis treated with elexacaftor-tezacaftor-ivacaftor: Early report. *European Journal of Radiology*, 2022, 154, pp.110421. 10.1016/j.ejrad.2022.110421 . hal-03966290

HAL Id: hal-03966290

<https://hal.science/hal-03966290>

Submitted on 22 Jul 2024

HAL is a multi-disciplinary open access archive for the deposit and dissemination of scientific research documents, whether they are published or not. The documents may come from teaching and research institutions in France or abroad, or from public or private research centers.

L'archive ouverte pluridisciplinaire **HAL**, est destinée au dépôt et à la diffusion de documents scientifiques de niveau recherche, publiés ou non, émanant des établissements d'enseignement et de recherche français ou étrangers, des laboratoires publics ou privés.



Distributed under a Creative Commons Attribution - NonCommercial 4.0 International License

TITLE PAGE

Chest computed tomography improvement in patients with cystic fibrosis treated with elexacaftor-tezacaftor-ivacaftor: early report

ARTICLE TYPE Original Research, Thoracic Imaging

Word count: Abstract: 245 / main text: 2434

Author list:

Romain BEC ¹ romain.bec@ap-hm.fr

Martine REYNAUD-GAUBERT ² MartineLouise.REYNAUD@ap-hm.fr

François ARNAUD ¹ francois.arnaud@ap-hm.fr

Romain NAUD ² romain.naud@ap-hm.fr

Nadine DUFEU ² nadine.dufeu@ap-hm.fr

Mathieu DI BISCEGLIE ^{1,3,4} Mathieu.DI-BISCEGLIE@ap-hm.fr

Benjamin COIFFARD ² benjamin.coiffard@ap-hm.fr

Jean-Yves GAUBERT ^{3,4,5} jeanyves.gaubert@ap-hm.fr

Julien BERMUDEZ ² julien.bermudez@ap-hm.fr

Paul HABERT ^{1,3,4} paul.habert@ap-hm.fr

1. Imaging Department, Hopital Nord, APHM, Aix Marseille University ;
2. Service de Pneumologie et équipe de transplantation pulmonaire, Centre de Ressources et de Compétences de la Mucoviscidose (CRCM) Adulte, AP-HM Hôpital Nord, 13015 Marseille, France. Aix Marseille Université, Marseille France ;
3. Aix Marseille Univ, LIIE, Marseille, France;
4. Aix Marseille Univ, CERIMED, Marseille, France ;
5. Service de radiologie, La Timone Hôpital, 264 rue Saint Pierre, 13005 Marseille.

Corresponding author informations:

Dr. Paul HABERT; Hôpital Nord, 15 chemin des Bourrelly, 13015 Marseille.

Fax: +33413429066 Phone number: +33491964656.

paul.habert@ap-hm.fr

KEY WORDS LIST

Cystic fibrosis ; CFTR modulator ; X-Ray Computed Tomography; elexacaftor-tezacaftor-ivacaftor

HIGHLIGHT

- After one year of triple therapy elexacaftor-tezacaftor-ivacaftor the visual Brody-II score measured on chest CT decrease.
- After one year of treatment mucoid plugs and bronchial thickening are improved while bronchial dilatation, parenchymal involvement and air trapping do not change.
- After one year of treatment chronic sinusitis evaluated by paranasal sinus CT score was improved.

ABBREVIATIONS LIST

CFTR: cystic fibrosis transmembrane conductance regulator

CT: Computed tomography

ETI: Elexacaftor-Tezacaftor-Ivacaftor

FEF25-75%: forced expiratory flow at 25–75%

FEV₁: percent predicted forced expiratory volume in 1 second

FVC: forced vital capacity

TLC: total lung capacity

Abstract

Rationale and Objectives: Cystic fibrosis transmembrane conductance regulator (CFTR) modulators have revolutionised the treatment of cystic fibrosis (CF). Chest computed tomography (CT) is key in the diagnosis and follow-up of anatomical damage to the lungs. Our study aimed to evaluate changes on lung CT scans of patients with CF after receiving elexacaftor-tezacaftor-ivacaftor (ETI) therapy for one year.

Materials and Methods: We conducted a retrospective, observational, single-centre study between 2018 and 2021 on adult patients with CF administered ETI. We reviewed chest CT scans before and at least one year after starting ETI. The Brody-II score (BSII) was measured by two experienced radiologists who were blinded to the treatment. Paranasal sinus CT scans and clinical and functional data were also compared. Wilcoxon tests were used to compare differences, and Spearman's correlation coefficient was used to evaluate changes in forced expiratory volume in one second (FEV_1) and total BSII.

Results: In the period, 63 patients were given ETI, and 12 met the criteria for analysis. The inter-observer reproducibility of BSII was satisfactory (intraclass correlation coefficient=0.83, 95% confidence interval 0.57–0.91). The BSII decreased after one year of treatment (-18 ± 16 , $p=0.002$) due to lower mucous plugging (-7 ± 4 , $p<0.001$) and peribronchial thickening (-9 ± 10 , $p=0.002$) scores. Bronchial, parenchymal, and hyperinflation scores were unchanged. Clinical and functional parameters were significantly improved, except for total lung capacity. The correlation between ΔFEV_1 and Δ total BSII was strong ($r=0.88$, $p<0.001$). The paranasal sinus CT score significantly improved with ETI treatment.

Conclusions: ETI decreased pulmonary and sinus morphological abnormalities after one year of treatment.

INTRODUCTION

Cystic fibrosis (CF), an autosomal recessive disease, is one of the most common lethal genetic diseases in Caucasian populations (1). This disease is caused by mutations in the gene encoding for the cystic fibrosis transmembrane conductance regulator (CFTR) protein (2). CFTR protein dysfunction can affect various organs, especially the lungs, leading to progressive airway mucus obstruction, bronchiectasis, persistent bacterial infection, and inflammation (3). Life expectancy has greatly increased over the past few decades due to pharmacological approaches and lung transplantation (4). The recent triple combination of elexacaftor-tezacaftor-ivacaftor (ETI) therapy has revolutionised CF treatment. Elexacaftor and tezacaftor are CFTR correctors that act together to increase the amount of CFTR protein reaching the cell membrane (5). Ivacaftor is a CFTR potentiator that helps mutated and normal CFTR proteins stay open longer at the cell membrane to allow more chloride to leave the cell and reduce sodium absorption (6). Since December 2019, this therapy has been US Food and Drug Administration-approved for patients who are over 12 years old and have at least one allele with the f508del mutation. ETI significantly improves respiratory function, especially the percentage-predicted forced expiratory volume in 1 s (FEV₁), with gains of 10% in patients with homozygous mutations when compared to tezacaftor-ivacaftor treatment (7) and 13.8% in patients with heterozygous mutations when compared to placebo, leading to reduced pulmonary exacerbations and improved quality of life (8).

Currently, chest computed tomography (CT) is considered the best imaging modality to evaluate the extent of the disease, assess complications such as infectious exacerbation, perform angiography in cases of haemoptysis, and follow up with patients. Abnormalities noted on imaging can help differentiate between bronchiectasis, mucous plug, bronchial thickening, and parenchymal lesions. Changes observed on chest CT in patients receiving previously available pharmacological therapies have been explored, and the mucous plugging and bronchial thickening scores seem to improve with ivacaftor (9,10) and the combination of lumacaftor and ivacaftor (11,12). Although

improvement is also expected with ETI therapy, the effect of ETI on pulmonary and sinus morphological changes has not yet been evaluated on CT for over 1 year.

This study aimed to assess changes in lung CT lesions based on a score in patients with CF after one year of ETI therapy. The secondary objectives were to evaluate changes in the other clinical and functional parameters, measure the correlation between the change in FEV₁ and the CT score, and investigate the difference in paranasal sinus obstruction CT score.

MATERIAL & METHODS

Population

This was a retrospective, observational, non-interventional, single-centre study conducted at the French CF centre of Marseille University Hospital (Hôpital Nord, Assistance Publique- Hôpitaux de Marseille, France) from April 2018 (date of the oldest chest CT scan) to November 2021. The study included adult patients with CF (≥ 18 years) who were heterozygous or homozygous for the f508del mutation and were included in the French early access program for the use of ETI from December 2019 (temporary authorisation for nominative use of ETI in patients who had an FEV₁ of less than 40%, experienced multiple exacerbations, and/or were waiting for lung transplantation) (13). The presence of a chest CT scan in the picture archiving and communication system (PACS) before and after starting treatment (maximum 24 months before and 12 months after) was mandatory for inclusion. Patients must have been treated with ETI for at least one year. Patients were excluded if a chest CT scan was not available within the required time frame or if it had been performed during an exacerbation phase. ETI therapy involved the oral administration of two tablets (100 mg elexacaftor / 50 mg tezacaftor / 75 mg ivacaftor) every morning, and one tablet (150 mg ivacaftor) every evening. Institutional Review Board approval was obtained (Comité d’Ethique pour la Recherche en Imagerie Médicale n°CRM-2106-209), and written information was sent to all included patients.

Chest CT

All CT scans were performed using the same system (Revolution EVO, GE Healthcare, Milwaukee, WI, USA) according to the following parameters: 120 kV and 1 mAs/kg with care dose modulation and reconstruction in joint slices of 1:1 mm. Doses were adjusted manually according to the patient template: 100 kV if they weighed less than 60 kg, if above 120 kV. The thoracic CT scans were acquired during breath-hold inspiration from the adrenal glands to the neck and at the end of forced expiratory flow. The total lung volume was recorded from the CT inspiratory volume using the post-treatment station, Thoracic VCAR (GE Healthcare). The two CT scans were reviewed before and

after ETI therapy was administered to each patient. The chest CT scans were first anonymised by a radiologist (F.A.), with each scan assigned a random number (1 to 24) and exported outside of the PACS to be read on another workstation. Lung damage was evaluated by a thoracic radiologist with 8 years of experience (P.H.) and a resident radiologist (R.B.) with 2 years of experience, who were anonymous to each other and the treatment status (before or after ETI treatment initiation).

Paranasal sinus CT

If a patient had a paranasal sinus CT available in the PACS, it was anonymised by F.A. and reviewed at another workstation. R.B. performed the scoring before and after therapy, blinded to the treatment status.

Clinical and functional parameters

The following clinical parameters were recorded from the medical reports: age, sex, weight, height, and body mass index. The following respiratory functional parameters were also recorded: forced vital capacity (FVC), total lung capacity (TLC), and FEV₁, forced expiratory flow at 25–75% (FEF_{25-75%}). The number of exacerbations per year and the distance on the 6-minute walk test were evaluated.

Image analysis

The Brody-II score was used to stage the lungs (14). Each lung was divided into three lobes (culmen and lingula in the left upper lobe counted for two lobes). For each lobe, parenchymal and bronchial involvement were assessed using five criteria: extent and size of bronchiectasis; extent of mucous plugging; extent and severity of peribronchial thickening; extent of dense parenchymal opacity, ground glass, cysts, and bullae; and extent and severity of hyperinflation. The maximum score obtained was 207.

The modified Lund-Mackay score (15) was used to quantify sinus obstruction. A score was assigned for each cavity, ranging from 0 to 5, based on the percentage of sinus opacification caused by mucosal thickening at every 25% of obstruction. The ostiomeatal complex was graded differently, from 0 to 2 (normal, partial, or complete obstruction). The maximum score was 54.

Statistical analysis

Continuous data with normal distribution are expressed as the mean \pm standard deviation, and for data with non-normal distribution, the results are expressed as the median \pm interquartile range. Categorical data are expressed as counts (percentages). The intraclass correlation coefficient (ICC) (95% confidence interval [CI]) was estimated based on a single rating, an absolute agreement, and a 2-way random-effects model to assess the inter-observer reliability between all the measurements made by P.H. and R.B. (16). For each of the five components of the Brody-II score, the mean of the values obtained by each reader was registered for the analysis of each patient as the ground truth. Groups were compared using a paired t-test or Wilcoxon test for quantitative variables, depending on the distribution. Because there were missing values in expiration acquisitions (four before and two after treatment) and the distribution of other values was Gaussian, an interpolation was conducted for the missing values using the least-squares method. Spearman's correlation coefficient was used to correlate total lung volume measured by CT and TLC and to correlate Δ total Brody-II score and Δ FEV₁. Statistical significance was set at $p < 0.05$. All data were analysed using Prism 8 (GraphPad Software, Inc., La Jolla California, USA, www.graphpad.com) and "R" (version 3.2.1, R Foundation, Vienna, Austria).

RESULTS

Population

During the study period, 160 non-transplanted patients were followed up in our adult CF centre; 63 were treated with ETI, 41 of whom were excluded due to the lack of a chest CT scan before or after ETI treatment. In the remaining 12 patients, two chest CT scans had been performed—one before treatment initiation and another at least one year after starting treatment (**Fig. 1**). The 12 patients had a mean age of 36 ± 10 years, and they were retrospectively included for analysis. The patient characteristics are detailed in **Table 1**.

Chest and paranasal sinus CT scores

There was good inter-observer agreement for all measurements (ICC = 0.83; 95% CI = 0.57–0.91) using the Brody-II score. The total Brody-II score improved from 90 ± 24 to 72 ± 18 ($p = 0.002$), mainly due to the improvements in the mucous plugging (from 13 ± 6 to 6 ± 5 , $p < 0.001$) and bronchial thickening (from 30 ± 8 to 20 ± 8 , $p = 0.001$) scores (**Fig. 2**). There were no improvements in the scores for bronchial dilatation (36 ± 10 vs 34 ± 8 , $p = 0.39$), parenchymal lesions (3.7 ± 2.4 vs 3.8 ± 1.9 , $p = 0.70$), or hyperinflation (8 ± 4 vs 9 ± 3 , $p = 0.51$) (**Fig. 3**). There was no difference in the total lung volume on CT before and after treatment (6.2 ± 1.3 L vs 5.4 ± 1.4 L, respectively; $p = 0.51$); in other words, there was no difference in the depth of inspiration before and after treatment. The Lund-Mackay score decreased from 28 ± 19 to 17 ± 10 points ($p = 0.008$) with ETI treatment (**Fig. 4**).

Clinical and functional parameters

Body mass index (20.1 ± 6.4 to 21.9 ± 5.9 , $p = 0.007$) and weight (58 ± 21 kg to 64 ± 20 kg, $p = 0.007$) improved with ETI therapy. The number of exacerbations per year decreased from 3.3 ± 2.9 to 0.1 ± 0.3 ($p = 0.003$).

FVC improved with gains of 1.0 ± 0.8 L ($p = 0.001$) and $22 \pm 19\%$ ($p = 0.003$). FEV₁ (1.0 ± 0.3 L to 1.7 ± 0.6 L, $p < 0.001$) and percent predicted FEV₁ ($26 \pm 8\%$ to $45 \pm 15\%$, $p < 0.001$) also improved.

The gain in FEV₁ was $\geq 5\%$ for all patients except for one, who had a gain of 4%. The FEF_{25-75%} (0.4 ± 0.2 L to 0.7 ± 0.4 L, $p = 0.02$) and percent predicted FEF_{25-75%} ($8 \pm 2\%$ to $15 \pm 7\%$, $p = 0.03$) improved as well. There was no significant change in the TLC (6.9 ± 1.6 L to 7.2 ± 1.4 L, $p = 0.27$) (**Table 2**).

There was a strong inverse correlation between the Δ total score and Δ FEV₁ ($r = -0.88$). The correlation between TLC and total lung volume on CT showed very strong correlations before and after ETI treatment initiation ($r = 0.93$ and $r = 0.87$, respectively) (**Fig. 5**).

DISCUSSION

ETI therapy significantly improved the visual Brody-II score in patients with advanced CF after one year of treatment.

The decrease in the Brody-II score in this cohort was -18 points or 21%. Despite the small number of patients in this sample, the significant results were not associated with a lack of power in our study. The mucous plugging and peribronchial thickening scores were reduced by 50%; to our knowledge, this is the first time that such results have been seen on chest CT in patients with CF. The anonymous evaluation of scores by thoracic radiologists limited bias in the scoring system. Bronchial dilatation, parenchymal lesions, and hyperinflation scores did not improve, as previously reported with lumacaftor-ivacaftor by Arnaud et al. and Campredon et al. (11,12); in the former, peribronchial thickening scores were reduced by 29% with lumacaftor-ivacaftor treatment. An article in 2015 reported improvements in mucous plugging and peribronchial thickening using ivacaftor alone for the G551D mutation; moreover, a minor but significant improvement in bronchial dilatation was found (-2.7 ; $p = 0.001$) (9). This was neither reported in our study nor in the articles on the lumacaftor-ivacaftor combination. Conversely, another study on ivacaftor monotherapy with long-term follow-up showed a worsening of bronchial dilatation after 18 months of follow-up (10), but this could have been an artefact due to the lower amount of mucous present in the bronchi. Despite these minor discrepancies, it seems logical that CFTR modulators improve mucus clearance by improving ion transport, resulting in better hydration of mucus and a reduction in mucus plugging. Bronchial obstruction and peribronchial inflammation can be improved by decreasing mucous stagnation, as confirmed by the improvement in exacerbations per year (17). However, bronchiectasis does not disappear, and when the bronchial tissue is altered by repeated infection, CFTR modulators cannot repair this supportive conjunctive tissue. This supports the recommendation that treatment should be provided early to patients with CF (18).

Very recently two studies were published on adults with CF under ETI therapy assessed by lung MRI, they found the same results as in our study that mean an improvement in the score due to

the lowering of mucous plugs and bronchial wall thickening. This is certainly the best way to assess these patients since MRI do not use ionising radiation. But image quality is more affected by movement and the access to MRI is more limited than CT, especially in France (19,20).

One patient in our cohort had a Δ total Brody-II score of +20 points, while all other scores decreased. Due to this surprising abnormality, the two radiologists collaborated to review the patient's data and confirmed that the chest CT was worse, whereas the FEV₁ increased by 5% (or 0.2 L) and the 6-minute walk test increased by 20 meters. This cohort included patients with severe disease, and it is possible that some patients with advanced disease will not respond to therapy. The initial results of prior studies appear to show a lower efficacy of ETI therapy in patients with advanced disease than in those with moderate disease (13,21); however, the results of phase 3 trials are yet to be published.

The Brody-II score was chosen instead of the Bhalla score (22) because it allowed for finer quantification of morphological changes by evaluating each lobe in the centre and periphery, whereas the Bhalla score only considers the lobe as a whole. We only included a small number of patients that permit us to use this scoring method because it is very extensive and time consuming. The Brody-II score integrates the expiratory volume, while the Bhalla score does not. These visual scores are not easy to use, and identifying the border between one-third and two-thirds or two-thirds and three-thirds of a lobe is challenging, particularly for small lobes such as the lingula or middle lobe. Concerning the slices at the end of forced expiration, as some data were missing, a correction was made using the least-squares method that forced the results to be homogenous. This concerned only a few data, however, and the distribution for other hyperinflation score values was Gaussian before and after the initiation of ETI therapy.

The secondary objective demonstrates an important improvement in sinus obstruction on CT imaging. As ETI treatment repairs the CFTR protein function, its efficacy can be seen not only in the lungs but also in other organs affected by CF. A recent study on 34 patients followed for 9 months shows an improvement in symptoms, endoscopic findings, and CT imaging. Symptoms improved

within 7 days of therapy and plateaued by day 28 (23). Chronic sinusitis in patients with CF is an important concern regarding the quality of life (24). Because ETI could be effective (25), this leads to the question of whether to administer ETI to patients who have undergone a transplant (26); however, its potential interaction with immunosuppressive drugs and its possible effects on the transplanted lung are still being debated.

This study has some limitations, including its retrospective design, the lack for some expiration slices, and the limited number of patients. However, despite these limitations, the results are strongly significant, justifying the validation of this CT score in a larger cohort with longer treatment duration.

In conclusion, patients with severe CF who were administered one year of ETI treatment showed improvement in lung damage on chest CT and a decrease in the visual Brody-II score of 21%. To our knowledge, such a reduction has never been seen with previous CFTR modulator therapies. Mucous plugging and peribronchial thickening were improved, while bronchiectasis, parenchymal lesions, and air trapping were not, as with previous therapy. This supports initiating treatment early in a CF patient's life to avoid lung sequelae. Sinus obstruction on CT improved after one year of ETI therapy.

REFERENCES

1. Sibley CD, Rabin H, Surette MG. Cystic fibrosis: a polymicrobial infectious disease. *Future Microbiol.* June 2006;1(1):53-61.
2. Gentsch M, Mall MA. Ion Channel Modulators in Cystic Fibrosis. *Chest.* Aug 2018;154(2):383-93.
3. Mall MA, Hartl D. CFTR: cystic fibrosis and beyond. *Eur Respir J.* Oct 2014;44(4):1042-54.
4. Elborn JS. Cystic fibrosis. *The Lancet.* Nov 2016;388(10059):2519-31.
5. Keating D, Marigowda G, Burr L, Daines C, Mall MA, McKone EF, et al. VX-445–Tezacaftor–Ivacaftor in Patients with Cystic Fibrosis and One or Two Phe508del Alleles. *N Engl J Med.* 25 Oct 2018;379(17):1612-20.
6. Fohner AE, McDonagh EM, Clancy JP, Whirl Carrillo M, Altman RB, Klein TE. PharmGKB summary: ivacaftor pathway, pharmacokinetics/pharmacodynamics. *Pharmacogenet Genomics.* Jan 2017;27(1):39-42.
7. Heijerman HGM, McKone EF, Downey DG, Van Braeckel E, Rowe SM, Tullis E, et al. Efficacy and safety of the elexacaftor plus tezacaftor plus ivacaftor combination regimen in people with cystic fibrosis homozygous for the F508del mutation: a double-blind, randomised, phase 3 trial. *The Lancet.* Nov 2019;394(10212):1940-8.
8. Middleton PG, Mall MA, Dřevínek P, Lands LC, McKone EF, Polineni D, et al. Elexacaftor–Tezacaftor–Ivacaftor for Cystic Fibrosis with a Single Phe508del Allele. *N Engl J Med.* 7 Nov 2019;381(19):1809-19.
9. Sheikh SI, Long FR, McCoy KS, Johnson T, Ryan-Wenger NA, Hayes D. Computed tomography correlates with improvement with ivacaftor in cystic fibrosis patients with G551D mutation. *J Cyst Fibros.* Jan 2015;14(1):84-9.
10. Chassagnon G, Hubert D, Fajac I, Burgel PR, Revel MP. Long-term computed tomographic changes in cystic fibrosis patients treated with ivacaftor. *Eur Respir J.* July 2016;48(1):249-52.
11. Arnaud F, Stremmer-Le Bel N, Reynaud-Gaubert M, Mancini J, Gaubert JY, Gorincour G. Computed Tomographic Changes in Patients with Cystic Fibrosis Treated by Combination Therapy with Lumacaftor and Ivacaftor. *J Clin Med.* 7 May 2021;10(9):1999.
12. Campredon A, Battistella E, Martin C, Durieu I, Mely L, Marguet C, et al. Using chest CT scan and unsupervised machine learning for predicting and evaluating response to lumacaftor-ivacaftor in people with cystic fibrosis. *Eur Respir J.* 18 Nov 2021;2101344.
13. Burgel PR, Durieu I, Chiron R, Ramel S, Danner-Boucher I, Prevotat A, et al. Rapid Improvement after Starting Elexacaftor–Tezacaftor–Ivacaftor in Patients with Cystic Fibrosis and Advanced Pulmonary Disease. *Am J Respir Crit Care Med.* 1 July 2021;204(1):64-73.

14. Brody AS, Klein JS, Molina PL, Quan J, Bean JA, Wilmott RW. High-resolution computed tomography in young patients with cystic fibrosis: Distribution of abnormalities and correlation with pulmonary function tests. *J Pediatr*. July 2004;145(1):32-8.
15. Zinreich SJ. Imaging for Staging of Rhinosinusitis. *Ann Otol Rhinol Laryngol*. May 2004;113(5_suppl):19-23.
16. Benchoufi M, Matzner-Lober E, Molinari N, Jannot AS, Soyer P. Interobserver agreement issues in radiology. *Diagn Interv Imaging*. Oct 2020;101(10):639-41.
17. Morrison CB, Shaffer KM, Araba KC, Markovetz MR, Wykoff JA, Quinney NL, et al. Treatment of cystic fibrosis airway cells with CFTR modulators reverses aberrant mucus properties *via* hydration. *Eur Respir J*. 25 June 2021;2100185.
18. Zemanick ET, Taylor-Cousar JL, Davies J, Gibson RL, Mall MA, McKone EF, et al. A Phase 3 Open-Label Study of Elexacaftor/Tezacaftor/Ivacaftor in Children 6 through 11 Years of Age with Cystic Fibrosis and at Least One *F508del* Allele. *Am J Respir Crit Care Med*. 15 June 2021;203(12):1522-32.
19. Wucherpfennig L, Triphan SMF, Wege S, Kauczor HU, Heussel CP, Schmitt N, et al. Magnetic resonance imaging detects improvements of pulmonary and paranasal sinus abnormalities in response to elexacaftor/tezacaftor/ivacaftor therapy in adults with cystic fibrosis. *J Cyst Fibros Off J Eur Cyst Fibros Soc*. 7 April 2022;S1569-1993(22)00088-1.
20. Graeber SY, Renz DM, Stahl M, Pallenberg ST, Sommerburg O, Naehrlich L, et al. Effects of Elexacaftor/Tezacaftor/Ivacaftor Therapy on Lung Clearance Index and Magnetic Resonance Imaging in Patients with Cystic Fibrosis and One or Two *F508del* Alleles. *Am J Respir Crit Care Med*. 10 May 2022;
21. O'Shea KM, O'Carroll OM, Carroll C, Grogan B, Connolly A, O'Shaughnessy L, et al. Efficacy of elexacaftor/tezacaftor/ivacaftor in patients with cystic fibrosis and advanced lung disease. *Eur Respir J*. Feb 2021;57(2):2003079.
22. Bhalla M, Turcios N, Aponte V, Jenkins M, Leitman BS, McCauley DI, et al. Cystic fibrosis: scoring system with thin-section CT. *Radiology*. June 1991;179(3):783-8.
23. Stapleton AL, Kimple AJ, Goralski JL, Nouraie SM, Branstetter BF, Shaffer AD, et al. Elexacaftor-Tezacaftor- Ivacaftor improves sinonasal outcomes in cystic fibrosis. *J Cyst Fibros*. March 2022;S1569199322000510.
24. Le C, McCrary HC, Chang E. Cystic Fibrosis Sinusitis. In: Woodworth BA, Poetker DM, Reh DD, éditeurs. *Advances in Oto-Rhino-Laryngology* [Internet]. S. Karger AG; 2016 [quoted 16 Dec 2021]. p. 29-37. Available on: <https://www.karger.com/Article/FullText/444959>
25. DiMango E, Overdevest J, Keating C, Francis SF, Dansky D, Gudis D. Effect of highly effective modulator treatment on sinonasal symptoms in cystic fibrosis. *J Cyst Fibros*. May 2021;20(3):460-3.
26. Benninger LA, Trillo C, Lascano J. CFTR modulator use in post lung transplant recipients. *J Heart Lung Transplant*. Dec 2021;40(12):1498-501.

TABLE

Table 1 Characteristics of patients and CT scans

	N = 12
Sex	
Male	10 (83%)
Female	2 (17%)
Age (years)	36 ± 11 [21–60]
Mutation status	
Homozygous ΔF508/ΔF508	5 (42%)
Heterozygous ΔF508/others*	7 (58%)
Delay between the first chest CT and initiation of triple therapy (months)	5 ± 7 [0–24]
Delay between initiation of triple therapy and the last chest CT (months)	13 ± 5 [12–20]
Delay between the two chest CT scans (months)	19 ± 13 [13–41]
Paranasal sinus CT available	
Before ETI	8 (67%)
After one year of ETI	11 (92%)

Note: This table represents the patient characteristics, including mutational status and available imaging data. Data are expressed as the median ± interquartile range [minimum–maximum] or number (percentage). CT: computed tomography; ETI: elexacaftor-tezacaftor-ivacaftor; *others: Δi507, 574delA, Leu1335Pro, 1303K, M1V, del exon 22-23.

Table 2 Chest CT findings and clinical and functional parameters before and after triple therapy

	Before	After	p-value
Weight (kg)	56 ± 15 [37–118]	63 ± 23 [39–114]	0.007
Body mass index	20 ± 6.4 [15–39]	22 ± 5.9 [15–38]	0.007
Brody-II score			
Total score	90 ± 24 [46–118]	72 ± 18 [45–99]	0.002
Bronchiectasis score	36 ± 10 [19–52]	34 ± 8 [19–44]	0.385
Mucous plugging score	13 ± 6 [2–26]	6 ± 5 [0–16]	< 0.001
Peribronchial thickening score	30 ± 11 [12–41]	16 ± 12 [12–35]	0.002
Parenchyma score	4 ± 2 [0–7]	4 ± 2 [1–7]	0.701
Hyperinflation score	8 ± 4 [2–14]	9 ± 3 [4–14]	0.508
Total lung volume measure on CT (L)	6.2 ± 1.3 [4.2–8.0]	6.3 ± 1.4 [3.9–8.6]	0.506
Lung function parameters			
FVC (L)	2.2 ± 0.7 [1.2–3.3]	3.2 ± 0.9 [1.9–4.9]	0.001
Percent predicted FVC (%)	51 ± 16 [25–73]	72 ± 20 [33–104]	0.003
FEV ₁ (L)	1.0 ± 0.3 [0.6–1.7]	1.7 ± 0.6 [0.9–2.6]	< 0.001
Percent predicted FEV ₁ (%)	26 ± 8 [14–43]	45 ± 15 [19–76]	< 0.001
TLC (L)	6.9 ± 1.6 [4.4–8.7]	7.2 ± 1.4 [5.1–8.5]	0.208
FEF _{25–75%} (L)	0.4 ± 0.2 [0.2–0.7]	0.7 ± 0.4 [0.3–1.3]	0.016
Percent predicted FEF _{25–75%} (%)	8 ± 2 [5–11]	14 ± 7 [7–28]	0.026
6-minute walk test (m)	468 ± 120 [308–636]	597 ± 123 [402–800]	0.024
Pulmonary exacerbations per year	3.3 ± 2.9 [0–9]	0.1 ± 0.3 [0–1]	0.003

Note: This table represents the clinical, imaging, and functional data before and after treatment with elexacaftor-tezacaftor-ivacaftor. Data following a normal distribution are expressed as the mean ± standard deviation [minimum–maximum], and those with a non-normal distribution are expressed as the median ± interquartile range [minimum–maximum]. CT: computed tomography; FVC: forced vital capacity; FEV₁: forced expiratory volume in one second; TLC: total lung capacity; FEF: forced expiratory flow. P-values lower than 0.05 were highlighted in bold.

FIGURE LEGEND

Figure 1: Flowchart of the study. ETI: elexacaftor-tezacaftor-ivacaftor.

Figure 2: A) Axial chest computed tomography (CT) images of a patient with cystic fibrosis show mucous plugs (arrow) and peribronchial thickening (arrowhead) before elexacaftor-tezacaftor-ivacaftor (ETI) initiation B) and an improvement one year after ETI initiation, with the disappearance of mucous plugs and normalisation of bronchial thickness. CT images of a patient with bronchiectasis C) before and D) after one year of ETI treatment show no change in the width of bronchial dilatation.

Figure 3: Each patient is represented by a line with a dot before and after one year of elexacaftor-tezacaftor-ivacaftor treatment. Every component of the Brody-II score is illustrated. The total, mucous plugging, and peribronchial thickening scores are significantly improved, while the bronchiectasis, parenchymal lesion, and hyperinflation scores are not affected.

Figure 4: Axial sinus CT of a patient with CF. A) Chronic rhinosinusitis is seen in the axial bone window of these sinuses, merging septal thickening plus osteosclerosis and sinus obstruction. B) A significant improvement is observed, with the sinus totally empty of mucous after one year of triple therapy with elexacaftor-tezacaftor-ivacaftor.

Figure 5: A) Strong correlations are noted between the change in Brody-II total score, and those of the percentage predicted forced expiratory volume in one second (%) and forced expiratory volume in one second (L) ($r = -0.89$, $p < 0.001$ and $r = -0.88$, $p < 0.001$, respectively), demonstrating that improvements on chest computed tomography (CT) scans correlate with functional improvement. B) A very strong correlation exists between total lung capacity measured on the lung functional test and lung volume measured on CT (before and after one year of elexacaftor-tezacaftor-ivacaftor treatment) ($r = 0.93$, $p < 0.001$ and $r = 0.87$, $p < 0.001$, respectively). FEV₁: forced expiratory volume in one second; ppFEV₁: percent predicted forced expiratory volume in one second; TLC: total lung capacity.

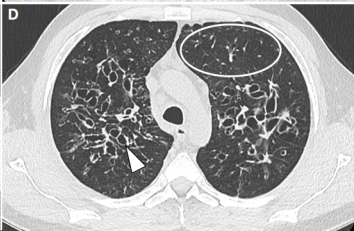
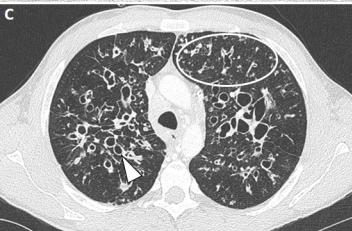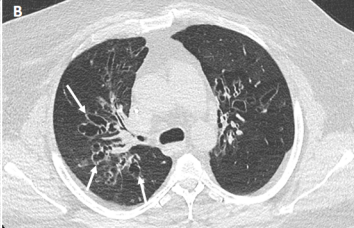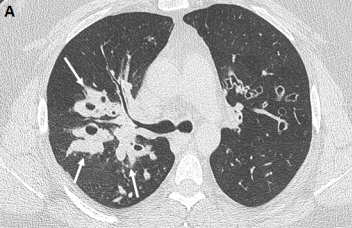
Between April 2018 and November 2021
160 patients with cystic fibrosis were
followed-up

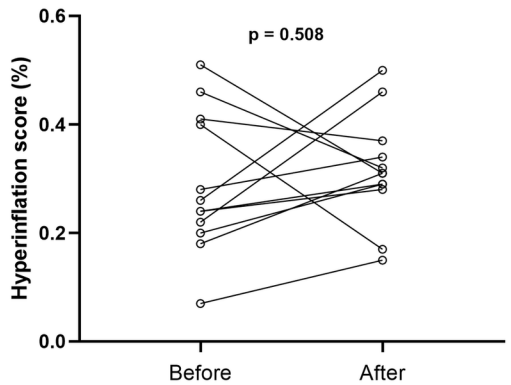
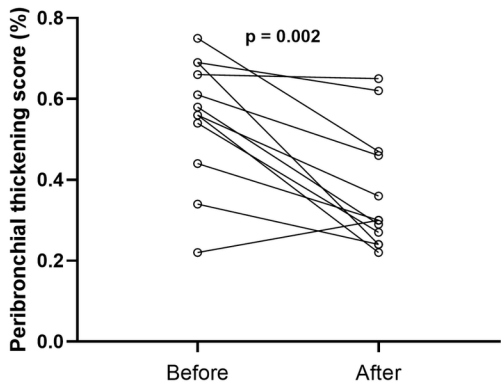
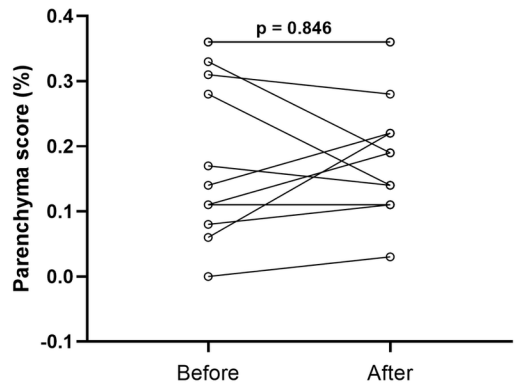
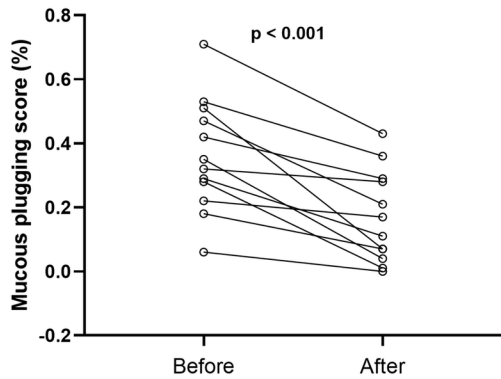
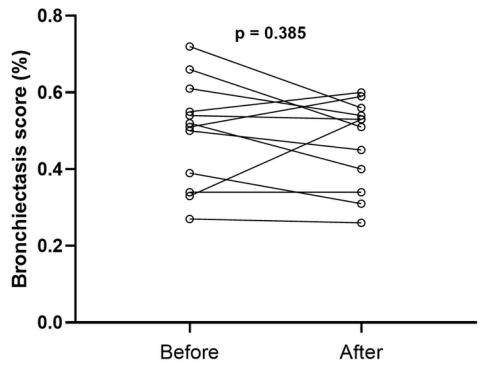
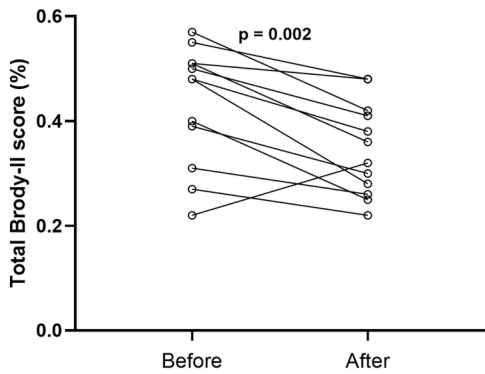
Excluded
not treated with ETI n = 97

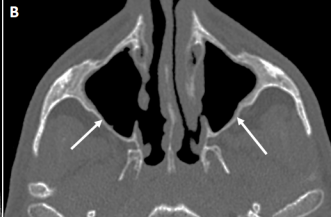
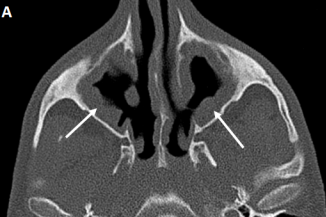
Sixty-three patients were treated with ETI

Excluded
Do not have chest CT before or
after introduction of ETI n = 51

Twelve patients were included







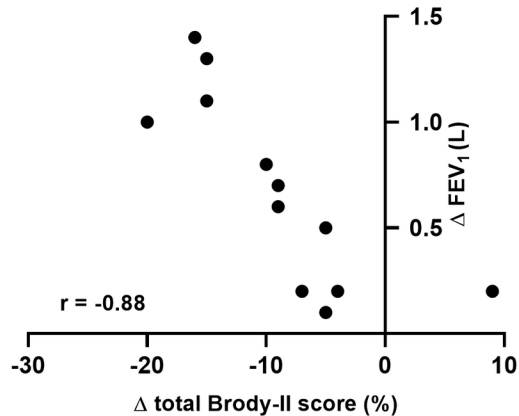
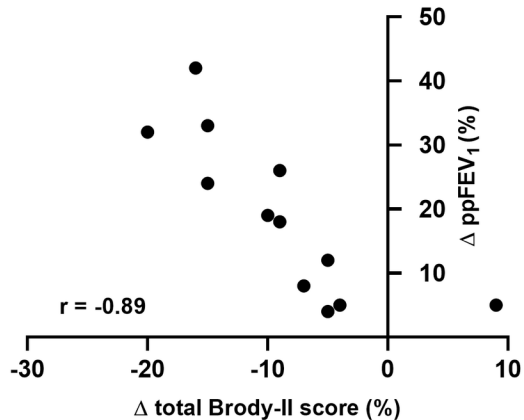
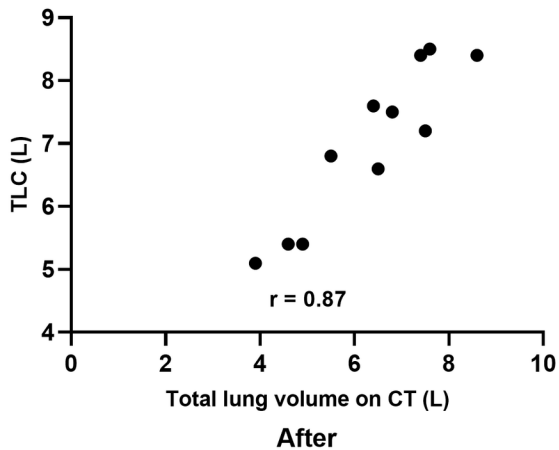
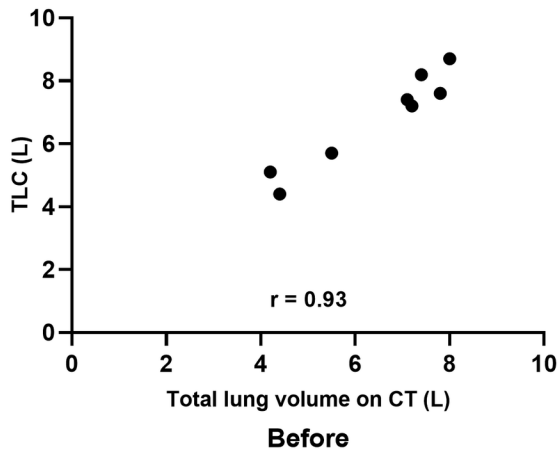
A**B**

Table 1

Characteristics of patients and CT	N = 12
Gender	
Male	10 (83%)
Female	2 (17%)
Age (years)	36 ± 11 [21-60]
Mutation status	
Homozygous ΔF508/ΔF508	5 (42%)
Heterozygous ΔF508/others*	7 (58%)
Delay between the first chest CT and introduction of triple therapy (months)	5 ± 7 [0-24]
Delay between introduction of triple therapy and last chest CT (months)	13 ± 5 [12-20]
Delay between the two chest CT (months)	19 ± 13 [13-41]
Paranasal sinus CT available	
Before ETI	8 (67%)
After one year of ETI	11 (92%)

Note: This table represents the characteristics of patients, mutational status, and imaging available data. Data are expressed as median ± IQR [minimum-maximum] or number (percentage). CT: computed tomography; ETI: Elexacaftor-Tezacaftor-Ivacaftor; *others: ΔI507, 574delA, Leu1335Pro, 1303K, M1V, del exon 22-23

Table 2 Clinical, chest-CT and functional parameters before and after triple therapy

	Before	After	p-value
Weight (kg)	56 ± 15 [37-118]	63 ± 23 [39-114]	0.007
Body mass index	20 ± 6.4 [15-39]	22 ± 5.9 [15-38]	0.007
mBrody score			
Total score	90 ± 24 [46-118]	72 ± 18 [45-99]	0.002
Bronchiectasis score	36 ± 10 [19-52]	34 ± 8 [19-44]	0.385
Mucous plugging score	13 ± 6 [2-26]	6 ± 5 [0-16]	<0.001
Peribronchial thickening score	30 ± 11 [12-41]	16 ± 12 [12-35]	0.002
Parenchyma score	4 ± 2 [0-7]	4 ± 2 [1-7]	0.701
Hyperinflation score	8 ± 4 [2-14]	9 ± 3 [4-14]	0.508
Lung pulmonary volume measure on CT	6.2 ± 1.3 [4.2-8.0]	6.3 ± 1.4 [3.9-8.6]	0.506
Lung function parameters			
Forced VC (L)	2.2 ± 0.7 [1.2-3.3]	3.2 ± 0.9 [1.9-4.9]	0.001
Percent predicted forced VC (%)	51 ± 16 [25-73]	72 ± 20 [33-104]	0.003
FEV ₁ (L)	1.0 ± 0.3 [0.6-1.7]	1.7 ± 0.6 [0.9-2.6]	<0.001
Percent predicted FEV ₁ (%)	26 ± 8 [14-43]	45 ± 15 [19-76]	<0.001
TLC (L)	6.9 ± 1.6 [4.4-8.7]	7.2 ± 1.4 [5.1-8.5]	0.208
FEF 25–75% (L)	0.4 ± 0.2 [0.2-0.7]	0.7 ± 0.4 [0.3-1.3]	0.016
Percent predicted FEF 25–75% (%)	8 ± 2 [5-11]	14 ± 7 [7-28]	0.026
Six-Minute Walk Test (meters)	468 ± 120 [308-636]	597 ± 123 [402-800]	0.024
Pulmonary exacerbations per year	3.3 ± 2.9 [0-9]	0.1 ± 0.3 [0-1]	0.003

Note: This table represents the clinical, imaging, and functional data before and after treatment with Elexacaftor-Tezacaftor-Ivacaftor. Data following normal distribution are expressed as mean ± SD [range] and non-normal distribution median IQR ± [range] CT: computed tomography; VC: vital capacity; FEF: forced expiratory flow; FEV₁: forced expiratory volume in one second; TLC: total lung capacity.