



HAL
open science

Freezing Nodal Disease: Local Control Following Percutaneous Image-Guided Cryoablation of Locoregional and Distant Lymph Node Oligometastases: A 10-Year, Single-Center Experience

Pierre-Alexis Autrusseau, Roberto Luigi Cazzato, Guillaume Koch, Nitin Ramamurthy, Pierre Auloge, Pierre de Marini, Dan Lipsker, Afshin Gangi, Julien Garnon

► To cite this version:

Pierre-Alexis Autrusseau, Roberto Luigi Cazzato, Guillaume Koch, Nitin Ramamurthy, Pierre Auloge, et al.. Freezing Nodal Disease: Local Control Following Percutaneous Image-Guided Cryoablation of Locoregional and Distant Lymph Node Oligometastases: A 10-Year, Single-Center Experience. *JVIR: Journal of Vascular and Interventional Radiology*, 2021, 32 (10), pp.1435-1444. 10.1016/j.jvir.2021.07.002 . hal-03964194

HAL Id: hal-03964194

<https://hal.science/hal-03964194>

Submitted on 22 Jul 2024

HAL is a multi-disciplinary open access archive for the deposit and dissemination of scientific research documents, whether they are published or not. The documents may come from teaching and research institutions in France or abroad, or from public or private research centers.

L'archive ouverte pluridisciplinaire **HAL**, est destinée au dépôt et à la diffusion de documents scientifiques de niveau recherche, publiés ou non, émanant des établissements d'enseignement et de recherche français ou étrangers, des laboratoires publics ou privés.



Distributed under a Creative Commons Attribution - NonCommercial 4.0 International License

Freezing Nodal Disease: Local Control following Percutaneous Image-guided Cryoablation of Loco-regional and Distant Lymph Node Oligometastases – A 10-year Single-centre Experience

Short title: Local tumor control following percutaneous image-guided cryoablation of loco-regional or oligometastatic lymph node metastases

Original article

Pierre-Alexis AUTRUSSEAU¹, MD (pierrealexis.autrusseau@chru-strasbourg.fr)

Roberto Luigi CAZZATO¹, MD, PhD (roberto-luigi.cazzato@chru-strasbourg.fr)

Guillaume KOCH¹, MD (guillaume.koch@chru-strasbourg.fr)

Nitin RAMAMURTHY², MD (nitin_ramamurthy@hotmail.com)

Pierre AULOGE¹, MD (pierre.auloge@chru-strasbourg.fr)

Pierre DE MARINI¹, MD (pierre.demarini@chru-strasbourg.fr)

Dan LIPSKER³, MD, PhD (dan.lipsker@chru-strasbourg.fr)

Afshin GANGI¹, MD, PhD (afshin.gangi@chru-strasbourg.fr)

Julien GARNON¹, MD, PhD (julien.garnon@chru-strasbourg.fr)

¹ Service d'Imagerie Interventionnelle
Hôpitaux Universitaires de Strasbourg
1, place de l'hôpital, 67000 Strasbourg
France

² Department of Radiology
University Hospital Monklands, NHS Lanarkshire
Monkscourt Ave, Airdrie ML6 0JS
United Kingdom

³ Service de dermatologie et d'oncodermatologie
Hôpitaux Universitaires de Strasbourg
1, place de l'hôpital, 67000 Strasbourg
France

Corresponding author:

Pierre-Alexis Autrusseau
pierrealexis.autrusseau@chru-strasbourg.fr
Tel: +33 (0)6 81 63 87 20
Fax : +33 (0)3 69 55 03 02

- 1.** Funding: This study was not supported by any funding.
- 2.** Conflict of interest:
 - Julien Garnon, MD, PhD: Proctor, Galil Medical Ltd.
 - Afshin Gangi, MD, PhD: Proctor, Galil Medical Ltd.
 - Other authors declare that they have no conflict of interest.
- 3.** Availability of data and material: Data is available for this work.
- 4.** Ethical approval: For this type of study formal consent is not required.
- 5.** Informed consent: Informed consent was obtained from all individual participants (or their parent) included in the study.
- 6.** The material of the study wasn't presented at any meeting, including SIR Annual Scientific Meeting.
- 7.** The authors report no acknowledgements.

ABSTRACT**Purpose**

To retrospectively assess technical feasibility, safety and oncologic outcomes following percutaneous image-guided cryoablation (PCA) of loco-regional and distant lymph-node metastases (LNMs).

Materials and methods

All consecutive patients undergoing PCA of LNMs between February 2009 and December 2019 were identified using retrospective database search. Every patient was followed-up at 1-, 3-, 6-, and 12-months post-treatment with contrast-enhanced MRI, and at approximately 3-6 months intervals with CT or PET/CT. Kaplan-Meier method was used to calculate local tumor progression-free survival (LTPFS), disease free survival (DFS) and overall survival (OS). Loco-regional and distant groups were compared using a Fisher's test. Technical success, technique efficacy, complications, and oncologic outcomes were analyzed.

Results

Fifty-six metachronous oligometastatic LNMs (median size 15mm [IQR 13-15, range 9-36mm]) were treated in 37 sessions in 29 patients, and defined as loco-regional (26/37 sessions) or distant (11/37 sessions). Seventeen patients had prior surgery/radiotherapy. Six patients underwent 8 re-treatments for loco-regional progression. An additional visceral oligometastasis was treated in 4/11 distant LNM PCA-sessions. Technical success and primary technique efficacy were 100%. Complication rate was 5.4% (two transient nerve palsies). At median 23-month follow-up, there were 2 instances of LTP (5.6%); 1-, 2-, and 3-year LTPFS was 100%, 94.3%, and 94.3%. Thirteen patients (45%) demonstrated no disease progression. One-, 2- and 3-year OS was 96.2%, 90.5%, and 70%. Patients were free from systemic onco-therapy following 20 sessions (54%), with mean treatment break of 19.1 months.

Conclusion

PCA of lymph-node oligometastases is feasible, safe, and offers promising local tumor control at mid-term follow-up.

ABBREVIATIONS

DFS: Disease-free survival

LNMs: Lymph-node metastasis(es)

LTP: Local tumour progression

LTPFS: Local tumour progression-free survival

OS: Overall survival

PCA: Percutaneous image-guided cryoablation

1. INTRODUCTION

Lymph node metastases (LNMs) are commonly observed in oncologic disease, and may be diagnosed at initial staging (synchronous), or during surveillance (metachronous). LNMs may arise within the lymphatic drainage territory of the primary tumor, corresponding to the N stage of the Tumor Node Metastasis (TNM) staging

system (“loco-regional LNMs”), or in distant lymphatic territories, corresponding to the M stage (“distant LNMs”). Additionally, LNMs may present as oligometastatic disease, a recently established oncologic entity characterized by slow growth of a few treatable metastases (1). Oligometastatic and oligoprogressive LNMs are increasingly common in the context of immunologic therapies and prolonged survival for many tumors; and complex cases with multiple prior therapies are becoming increasingly prevalent (2).

In recent years, there has been a trend towards aggressive local metastasis-directed therapy for oligoprogressive disease, aiming to reduce tumor burden, improve progression-free survival, pause systemic therapy, and potentially alter disease course (1,3). However, conventional surgical lymphadenectomy and radiotherapy are frequently unsuitable in complex patients with local LNM recurrence following prior surgery and/or radiotherapy, due to post-therapeutic adhesions, challenging anatomic localization, and morbidity/toxicity (4); and alternative therapies with lower morbidities have been sought.

Percutaneous imaging-guided Cryoablation (PCA) is an established local therapy which induces cell death by exposing tumors to extreme cold (up to -150°C) (5). It offers several advantages over heat-based ablation, including superior ablation-zone (“iceball”) visualization, facilitating precise intra-procedural monitoring; synergistic combination of multiple adjustable applicators to create large, tailored ablation-zones; intrinsic analgesic effects; safe application following prior surgery or radiotherapy; and non-preclusion of subsequent conventional therapy (6). The technique has been widely used in a range of clinical settings (e.g. lung, renal, and bone tumors (6)), but to date there are only a few case reports and a single series of 18 patients specifically describing its application to achieve local control of oligometastatic LNMs (7–10).

The purpose of this study is to describe the feasibility, safety, local efficacy, and oncologic outcomes following PCA of loco-regional and distant oligometastatic LNMs, and discuss its potential role in overall oncologic management.

2. MATERIALS AND METHODS

This single center retrospective study was approved by the institutional review board with permission to perform chart review, and a waiver of consent for study participation. All patients gave informed consent for procedures.

2.1 Patient Selection

All consecutive patients undergoing PCA of LNMs between February 2009 (date of available computerized data) and December 2019 were retrospectively identified following institutional database search. Thirty-nine consecutive patients underwent PCA of oligometastatic LNMs. Seven patients subsequently treated with

cytoreductive surgery were excluded. Three patients were lost to follow-up. The final study population comprised 29 patients (14 females, 15 males; mean age 56.9 ± 11.8 years [range 29-83 years]). Six patients underwent one (n=4) or two (n=2) further procedures, either as two-stage initial therapy (n=1), or to treat progressive local or regional LNMs (remainder); a total of 37 procedures were therefore performed. Seventeen patients (treated in 24 procedures) had undergone prior surgery (n=7), radiotherapy (n=2), or both (n=8) in the same lymphatic region targeted during PCA. Of the 7 patients who underwent prior surgery, two were referred following failed localization of mediastinal and aorto-lumbar LNMs, with the former procedure complicated by vocal cord paralysis. Systemic chemotherapy was ongoing at the time of referral in 17/36 procedures (46%, accounting for 1 two-stage procedure) in 16 patients.

Fifty-six LNMs (median size of 15mm [IQR 13-15, range 9-36mm], with mean 1.5 ± 0.9 [range 1-5] LNMs treated per lymphatic territory) were defined as loco-regional (within lymphatic drainage territory of primary tumor according to TNM system) in 26/37 sessions (20 patients), and distant (within a distant lymphatic territory) in 11/37 sessions (9 patients). Locations are presented in **Table 1**. All patients had metachronous oligometastatic disease, defined as fewer than 5 LNMs or visceral metastases. None of the patients with loco-regional LNMs had distant metastatic disease. Patients with distant LNMs had either isolated distant nodal disease, or distant nodal and visceral oligometastases. All LNMs were diagnosed on the basis of standard size or metabolic criteria on CT, MR, or PET-CT imaging undertaken at initial staging or during oncologic surveillance (11,12). All patients had current or prior biopsy-proven primary malignancy; a minority (6/29, 20.7%) underwent further pre-procedural percutaneous LNM biopsy to confirm histology at the discretion of the referring clinician.

Patients were referred for PCA following multi-disciplinary tumor board discussion involving medical and radiation oncologists, a tumor surgeon, and an interventional radiologist, either as salvage therapy for recurrent loco-regional LNMs following initial surgery or radiotherapy; or as first-line therapy for distant LNMs \pm visceral oligometastases.

2.2 Cryoablation Procedures

Every patient was hospitalized one day prior to cryoablation for organizational purpose. Anticoagulants were stopped for 5 days, and blood clotting parameters were tested 24 hours before the procedure, ensuring minimum prothrombin time of 50% and platelet count of 50 000/mm³ (13).

All procedures were performed on an inpatient basis by one of six board-certified interventional radiologists (between 2- and 11-years' experience), under general anaesthesia (n=32), spinal anaesthesia (n=1) or moderate sedation (n=4), using strict surgical asepsis and CT (n=15), MR/MR-Fluoroscopy (n=7), combined US/CT (n=11), or combined US/MR (n=4) imaging-guidance. Superficial tumors were targeted using US-guidance; deep tumors were targeted using CT or MR-Fluoroscopy guidance; and CT or MR-guidance was used in all cases for intra-procedural iceball monitoring.

Initially, single or multiple 17G cryoprobes (IceSeed®, IceSphere®, IceRod®, IceForce®; Galil Medical – Boston Scientific, Marlborough, MA 01752, USA) were deployed within or around the LNM margins (at 1.5cm intervals, when multiple), to facilitate complete iceball coverage with a minimum 5mm ablation-margin. For clustered LNMs, all tumors were encompassed within a single large iceball (**Figure 1**). Ancillary thermoprotective techniques (hydrodissection and carbo-dissection) were employed when adjacent critical structures (e.g. skin, nerves, and gastro-intestinal tract) were located within 10mm of the LNM, to avoid collateral thermal damage (14) (**Figure 2**); and where target tumors were close to vascular bundles, to mitigate convectional dissipation of cold energy (“cold sink effect”) and optimize ablation efficacy (7) (**Figure 3**). For both techniques, 22G spinal needles were positioned between the target-tumor and adjacent vulnerable organ(s), and carbon dioxide or 3-5% iodinated contrast medium in normal saline was injected until a minimal 5mm distance between the expected iceball and vulnerable organ(s) was obtained.

Cryoablation was performed using a standard double-freeze protocol (two freezing cycles of 10-minutes interspersed of 9-minutes passive thawing and 1-minute active thawing) (6). Premature termination was considered in the event of iceball encroachment within 2 mm of adjacent critical structures, despite thermoprotective measures.

Technical success was achieved in all procedures (100%), using a mean of 2.1 ± 0.8 cryoprobes (range 1-4), and ancillary thermoprotective techniques in 32/37 procedures (86%; 1/37 carbo-dissection; 31/37 hydrodissection). Mean procedural time was 106.7 ± 39 min (range 60-190 min). Ablation of an additional distant visceral oligometastasis was performed in 4 of 11 procedures undertaken for distant LNMs.

Following the procedure, patients were transferred to a recovery ward for overnight observation, and discharged the next day in the absence of complication and if pain score was inferior to 4 over 10. Mean hospital stay was 2.5 ± 2 days (range 2-14 days).

2.3 Follow-up

All patients underwent targeted clinical (physical examination of the ablation zone) and imaging follow-up with contrast-enhanced MRI at 1-, 3-, 6-, and 12-months post-procedure, in addition to standard oncologic follow-up that included clinical examination and biological restaging with specific oncologic biomarker (if any) every 3 months, as well as restaging CT and/or PET-CT every 3 to 6 months. MRI and CT were interpreted by two radiologists (with 7 and 9 years of experience) not involved in the interventions. Interpretation of PET-CT imaging was performed by 3 nuclear medicine physicians (with 6, 8 and 15 years of experience).

2.4 Data collection and analysis

For each procedure, oncologic outcomes (technical efficacy, local, regional and distant disease progression at last available imaging follow-up, discontinuation of systemic therapy post-procedure, management of disease progression) and complications were retrospectively collected via chart review. The primary outcome was local tumor control following cryoablation of LNMs. Secondary outcomes were disease free survival, overall survival, freedom of systemic therapies and occurrence of complications.

Study definitions (including technical success, technical efficacy, local tumor progression (LTP), loco-regional disease progression, distant disease progression, local tumor progression free survival (LTPS), disease free survival (DFS), and overall survival (OS) are summarized in **Table 2**.

Descriptive statistics were expressed as absolute numbers and percentages for categorical variables, and means and medians with standard deviations and ranges for continuous variables. Freedom from systemic therapy was calculated as mean duration between PCA and onset of subsequent chemotherapy on a per-procedure basis. LTPFS, DFS, and OS were estimated using the Kaplan-Meier method. One patient initially treated in 2 sessions (two-stage procedure) was analyzed as separate procedures for complication-rate, but as a single procedure for freedom from systemic therapy. Fisher's test was used to compare LTPFS, DFS and OS between loco-regional and distant LNM groups, with $p < 0.05$ considered statistically significant. Statistical analysis was performed using R v3.6.3 (R Foundation for Statistical Computing, Vienna, Austria ©).

3. RESULTS

3.1 Oncologic outcomes (Table 3.)

Primary technical efficacy was 100%, with complete ablation of all treated LNMs at 1-month MR-imaging follow-up. At median 23.4 ± 22.1 months (IQR 9.6-45.2 months) follow-up, there were 2 instances of LTP (2/36 sessions [accounting for 1 two-stage procedure]), with one patient developing additional new regional

progressive disease at 15.4 months (treated systemically), and the second re-presenting with isolated LTP at 17.6 months (re-treated with PCA and remaining LTP-free after 52.1 months). One-, 2-, and 3-year LTPFS was 100%, 94.3%, and 94.3%, respectively.

At the time of analysis, 23 patients were alive, including 16 patients with at least 2 years follow-up, and 13 patients (45%) demonstrating no local, regional or distant disease progression. In the whole cohort, 1-, 2- and 3-year OS was 96.2%, 90.5%, and 70%; and 1-, 2- and 3-year DFS was 74%, 39.9%, and 31.9%.

One-, 2- and 3-year OS in the loco-regional group was 100%, 90.9% and 80.8% and 1-, 2- and 3-year OS in the oligo-metastatic group was 88.9%, 88.9% and 44.4%, respectively. No statistically significant difference in overall survival was observed between loco-regional and distant LNM groups at 1-, 2-, or 3-years ($p=0.31$, $p=0.53$ and $p=0.29$, respectively), and there were no inter-group differences in LTPFS or DFS. These results are summarized in **Figure 4**.

3.2 New treatments after lymphatic progression

Overall, 16 patients experienced disease progression (local, regional, distant LNM(s) or visceral metastasis) during follow-up. Eleven patients (37.9%) were managed with systemic therapies and 5 patients (17.2%) were retreated with cryoablation. Four patients underwent a second cryoablation procedure for a regional progression 1.5-, 16-, 18- and 14- months after initial treatment. The first three achieved a complete remission status at 22-, 6- and 12- months of follow-up respectively. The fourth patient had a distant visceral progression at 33 months of follow-up treated with systemic therapies. One patient underwent a second and a third cryoablation procedure for regional progression 17- and 41- months after initial cryoablation.

3.3 Freedom of systemic therapy

Patients achieving a remission status with a local disease control were able for a break in systemic therapy following 20/37 procedures (54%), with a mean freedom of systemic therapy of 19.1 ± 19 months (range 1.4-88.8 months).

3.4 Complications

Minor complication rate was 5.4%, with two grade B SIR adverse events occurring within 24 hours of PCA (2/37 sessions). These were a bitonal voice secondary to collateral thermal injury to the right vagal nerve during

jugulo-carotid LNM ablation, and obturator nerve palsy following PCA of an iliac LNM. Both deficits fully resolved following 6 months' rehabilitation.

4. DISCUSSION

The present study demonstrates the technical feasibility and safety of PCA for loco-regional and distant oligometastatic LNM in a wide range of anatomic locations, with 100% technical success and technique efficacy, and a minor complication rate of 5.4%, confirming findings reported in smaller studies (7–10). Using optimal imaging-guidance (including MR-guidance for tumors inconspicuous on CT or close to neural structures), an ablation margin of 5mm (similar to lethal isotherm measurements for hepatic and renal tumors (16)), and ancillary thermoprotective techniques, even LNM in relatively inaccessible locations abutting neurovascular bundles can be safely and effectively ablated. However, LNM in mediastinal, supra/infraclavicular, and pelvic territories remain challenging due to complex regional anatomy (10); and both minor complications occurred following ablation of neck and iliac/obturator LNM. It is essential to carefully review oncologic history and prior imaging for post-therapeutic adhesions which may preclude or increase risks of PCA, and to thoroughly explain risks and consequences of collateral neural damage to patients during the consent process.

This study demonstrates encouraging LTPFS for loco-regional and distant LNM at intermediate-term follow-up, with 3-year LTPFS estimated at 94.3%, and only 2 patients experiencing LTP at median 23-month follow-up (7.9%, 5.6%, and 3.7% on a per-patient, per-procedure, and per-tumor basis, respectively); one of whom was re-treated and remained LTP-free after 52 months. These results are similar to Tsoumakidou et al., who reported a 4% LTP-rate on a per-tumor basis in a smaller series of 18 patients undergoing PCA of LNM with 15 months follow-up (10); however, direct comparison remains limited due to the authors' use of RECIST criteria to determine LTP, rather than more accurate EORTC/PERCIST criteria (including metabolic imaging) used in the present study (10–12). The results also appear similar to prior thermal ablation studies (including RFA of LNM from HCC, laser ablation of LNM from thyroid cancer, and PCA of extra-nodal soft tissue tumors (17–19)), and to metastasis-directed therapy studies evaluating brachytherapy and radiotherapy for oligometastatic LNM (20–22). For example, Pan et al. demonstrated a 1-year local disease control rate of 72.7% in 46 patients with local and distant LNM from HCC treated using RFA (17); while Franzese et al. reported 1- and 2-year local disease control rates of 87.2% and 76.8% in a large cohort of 278 patients treated with stereotactic radiotherapy (20).

Comparison with surgical lymphadenectomy is limited due to literature heterogeneity, but results nevertheless appear broadly comparable (23–25).

In the present study, 55% of patients survived for at least 2 years; 45% demonstrated no disease progression during follow-up; and 21% underwent repeat PCA following limited loco-regional relapse. 3-year OS and DFS were 70% and 31.9%, respectively. Similarly durable oncologic outcomes have been reported following radiotherapy and surgery for oligometastatic disease (20–26). However, survival rates must be interpreted with caution due to potential selection bias towards relatively good-prognosis patients with limited disease. There is currently little high-quality evidence that PCA (or other local therapies) offer significant overall or disease-free survival benefits in patients with oligometastatic LNMs (17,21,23,24)

Patients were free from systemic therapy following 54% of procedures for a mean of 19.1 months, associated with stable disease or remission; comparable with results following surgical lymphadenectomy, radiotherapy and brachytherapy of LNMs (20–22,27). Although firm conclusions cannot be made, PCA may potentially facilitate delayed treatment intensification in selected cases.

In this study, the majority of patients were referred for salvage therapy of isolated loco-regionally recurrent LNMs following prior surgery or radiotherapy, where repeat conventional therapy was considered unsuitable (particularly for recurrent breast cancer and melanoma) due to potential morbidity (28). A minority of patients were referred for PCA as first-line therapy for distant LNMs, with or without visceral oligometastases. Although stereotactic radiotherapy is frequently recommended in these cases (29), PCA was routinely offered as a first-line procedure, reflecting a high degree of confidence in the technique based on a long-term expertise (30,31). PCA was particularly useful for LNMs in complex locations with high risk of surgical morbidity and failed localization (as 2 patients in this study); and where full dose radiotherapy was contra-indicated by high risks of toxicity and local recurrence (32). PCA retains several advantages over conventional therapies, since it may be combined with LNM biopsy and ablation of visceral metastases (e.g. in 4 patients in this study) to guide subsequent onco-therapy and treat oligometastatic disease; can be safely performed in post-therapeutic fields without precluding subsequent conventional therapy in the event of local progression (33,34); and may possess synergistic cryo-immunologic anti-tumor effects in combination with immunotherapy (35). In selected patients, PCA represents a valuable addition to the current armamentarium of metastasis-directed therapies.

Study limitations include retrospective single-centre study protocol, small sample size, and relatively short follow-up, limiting generalizability and power. The highly selected study population with heterogeneous LNM locations, tumor-types, disease stage, and prior/subsequent onco-therapies, and the absence of control or

alternative treatment groups, also confers significant selection bias (limiting generalizability); precludes comparison with existing treatments; and confounds attribution of survival benefits to PCA alone.

In conclusion, PCA of loco-regional and distant lymph node oligometastases is technically feasible, safe, and offers promising local tumor control with potential freedom from systemic therapy at mid-term follow-up. Larger prospective controlled studies are required to further elucidate its role in multi-disciplinary management of this emerging, complex patient population.

REFERENCES

1. Guckenberger M, Lievens Y, Bouma AB, et al. Characterisation and classification of oligometastatic disease: a European Society for Radiotherapy and Oncology and European Organisation for Research and

- Treatment of Cancer consensus recommendation. *The Lancet Oncology*. 2020;21(1):e18–e28. doi: 10.1016/S1470-2045(19)30718-1.
2. Huang F, Wu G, Yang K. Oligometastasis and oligo-recurrence: more than a mirage. *Radiat Oncol*. 2014;9(1):230. doi: 10.1186/s13014-014-0230-6.
 3. Onderdonk BE, Gutiontov SI, Chmura SJ. The Evolution (and Future) of Stereotactic Body Radiotherapy in the Treatment of Oligometastatic Disease. *Hematology/Oncology Clinics of North America*. 2020;34(1):307–320. doi: 10.1016/j.hoc.2019.09.003.
 4. Wapnir IL, Khan A. Current Strategies for the Management of Locoregional Breast Cancer Recurrence. *Oncology (Williston Park, NY)*. 2019;33(1):19–25.
 5. Baust JG, Gage AA, Bjerklund Johansen TE, Baust JM. Mechanisms of cryoablation: Clinical consequences on malignant tumors. *Cryobiology*. 2014;68(1):1–11. doi: 10.1016/j.cryobiol.2013.11.001.
 6. Cazzato RL, Garnon J, Ramamurthy N, et al. Percutaneous image-guided cryoablation: current applications and results in the oncologic field. *Med Oncol*. 2016;33(12):140. doi: 10.1007/s12032-016-0848-3.
 7. Garnon J, Koch G, Caudrelier J, et al. Percutaneous Image-Guided Cryoablation of Challenging Mediastinal Lesions Using Large-Volume Hydrodissection: Technical Considerations and Outcomes. *Cardiovasc Intervent Radiol*. 2016;39(11):1636–1643. doi: 10.1007/s00270-016-1396-0.
 8. Cornelis F, Paty PB, Sofocleous CT, Solomon SB, Durack JC. Percutaneous Cryoablation for Local Control of Metachronous Inguinal Lymph Node Metastases. *Cardiovasc Intervent Radiol*. 2015;38(5):1369–1372. doi: 10.1007/s00270-014-0946-6.
 9. Kilcoyne A, Frenk NE, Arellano RS. Percutaneous Cryoablation of a Metastatic Right External Iliac Lymph Node with Associated Injury to the Femoral Nerve. *Journal of Vascular and Interventional Radiology*. 2016;27(4):611–612. doi: 10.1016/j.jvir.2015.12.750.
 10. Tsoumakidou G, Mandralis K, Hocquelet A, Duran R, Denys A. Salvage Lymph-Node Percutaneous Cryoablation: Safety Profile and Oncologic Outcomes. *Cardiovasc Intervent Radiol*. 2020;43(2):264–272. doi: 10.1007/s00270-019-02341-3.
 11. Kim JH. Comparison of the EORTC criteria and PERCIST in solid tumors: a pooled analysis and review. *Oncotarget*. 2016;7(36):58105–58110. doi: 10.18632/oncotarget.11171.
 12. Min SJ, Jang HJ, Kim JH. Comparison of the RECIST and PERCIST criteria in solid tumors: a pooled analysis and review. *Oncotarget*. 2016;7(19):27848–27854. doi: 10.18632/oncotarget.8425.
 13. Patel II, Rahim S, Davidson JC, et al. Society of Interventional Radiology Consensus Guidelines for the

Periprocedural Management of Thrombotic and Bleeding Risk in Patients Undergoing Percutaneous Image-Guided Interventions—Part II: Recommendations. *Journal of Vascular and Interventional Radiology*. 2019;30(8):1168-1184.e1. doi: 10.1016/j.jvir.2019.04.017.

14. Garnon J, Cazzato RL, Caudrelier J, et al. Adjunctive Thermoprotection During Percutaneous Thermal Ablation Procedures: Review of Current Techniques. *Cardiovasc Intervent Radiol*. 2019;42(3):344–357. doi: 10.1007/s00270-018-2089-7.

15. Khalilzadeh O, Baerlocher MO, Shyn PB, et al. Proposal of a New Adverse Event Classification by the Society of Interventional Radiology Standards of Practice Committee. *Journal of Vascular and Interventional Radiology*. 2017;28(10):1432-1437.e3. doi: 10.1016/j.jvir.2017.06.019.

16. Shady W, Petre EN, Gonen M, et al. Percutaneous Radiofrequency Ablation of Colorectal Cancer Liver Metastases: Factors Affecting Outcomes—A 10-year Experience at a Single Center. *Radiology*. 2016;278(2):601–611. doi: 10.1148/radiol.2015142489.

17. Pan T, Xie Q-K, Lv N, et al. Percutaneous CT-guided Radiofrequency Ablation for Lymph Node Oligometastases from Hepatocellular Carcinoma: A Propensity Score-matching Analysis. *Radiology*. 2017;282(1):259–270. doi: 10.1148/radiol.2016151807.

18. Mauri G, Cova L, Ierace T, et al. Treatment of Metastatic Lymph Nodes in the Neck from Papillary Thyroid Carcinoma with Percutaneous Laser Ablation. *Cardiovasc Intervent Radiol*. 2016;39(7):1023–1030. doi: 10.1007/s00270-016-1313-6.

19. Littrup PJ, Bang HJ, Currier BP, et al. Soft-Tissue Cryoablation in Diffuse Locations: Feasibility and Intermediate Term Outcomes. *Journal of Vascular and Interventional Radiology*. 2013;24(12):1817–1825. doi: 10.1016/j.jvir.2013.06.025.

20. Franzese C, Badalamenti M, Comito T, et al. Assessing the role of Stereotactic Body Radiation Therapy in a large cohort of patients with lymph node oligometastases: Does it affect systemic treatment's intensification? *Radiotherapy and Oncology*. 2020;150:184–190. doi: 10.1016/j.radonc.2020.06.029.

21. Heinze C, Omari J, Manig M, et al. Efficacy and safety of percutaneous computed tomography-guided high-dose-rate interstitial brachytherapy in treatment of oligometastatic lymph node metastases of retroperitoneal space. *jcb*. 2019;11(5):436–442. doi: 10.5114/jcb.2019.88141.

22. Loi M, Frelinghuysen M, Klass ND, et al. Locoregional control and survival after lymph node SBRT in oligometastatic disease. *Clin Exp Metastasis*. 2018;35(7):625–633. doi: 10.1007/s10585-018-9922-x.

23. Ranasinghe W, Persad R. Oligometastatic Disease in Prostate Cancer: Advances in Diagnosis and

Treatment. In: Mohan R, editor. Prostate Cancer - Leading-edge Diagnostic Procedures and Treatments. InTech; 2016. doi: 10.5772/63370.

24. Konkin DE. Management and Outcomes of Isolated Axillary Node Recurrence in Breast Cancer. *Arch Surg*. 2006;141(9):867. doi: 10.1001/archsurg.141.9.867.

25. Ferrero A, Ditto A, Giorda G, et al. Secondary cytoreductive surgery for isolated lymph node recurrence of epithelial ovarian cancer: A multicenter study. *European Journal of Surgical Oncology (EJSO)*. 2014;40(7):891–898. doi: 10.1016/j.ejso.2013.11.026.

26. Russell CM, Espiritu PN, Kassouf W, et al. Surgical Outcomes in the Management of Isolated Nodal Recurrences: A Multicenter, International Retrospective Cohort. *Journal of Urology*. 2014;192(2):350–356. doi: 10.1016/j.juro.2014.02.010.

27. Claeys T, Van Praet C, Lumen N, et al. Salvage Pelvic Lymph Node Dissection in Recurrent Prostate Cancer: Surgical and Early Oncological Outcome. *BioMed Research International*. 2015;2015:1–6. doi: 10.1155/2015/198543.

28. Al-Hilli Z, Grobmyer SR. Management Strategies for Locally Recurrent Breast Cancer: Redo-Lumpectomy, Redo-Sentinel Node Biopsy, Redo-Radiation. *Ann Surg Oncol*. 2019;26(10):3018–3024. doi: 10.1245/s10434-019-07545-y.

29. Friedman EB, Ferguson PM, Thompson JF. When is surgery for metastatic melanoma still the most appropriate treatment option? *Expert Review of Anticancer Therapy*. 2018;18(10):943–945. doi: 10.1080/14737140.2018.1508346.

30. Buy X, Lang H, Garnon J, Sauleau E, Roy C, Gangi A. Percutaneous Renal Cryoablation: Prospective Experience Treating 120 Consecutive Tumors. *American Journal of Roentgenology*. 2013;201(6):1353–1361. doi: 10.2214/AJR.13.11084.

31. Auloge P, Cazzato RL, Rousseau C, et al. Complications of Percutaneous Bone Tumor Cryoablation: A 10-year Experience. *Radiology*. 2019;291(2):521–528. doi: 10.1148/radiol.2019181262.

32. Ito M, Kodaira T, Koide Y, et al. Role of high-dose salvage radiotherapy for oligometastases of the localised abdominal/pelvic lymph nodes: a retrospective study. *BMC Cancer*. 2020;20(1):540. doi: 10.1186/s12885-020-07033-7.

33. Quarrier S, Katz A, Haas J. Treatment of Prostate Cancer Local Recurrence After Whole-Gland Cryosurgery With Frameless Robotic Stereotactic Body Radiotherapy: Initial Experience. *Clinical Genitourinary Cancer*. 2013;11(2):89–93. doi: 10.1016/j.clgc.2012.09.004.

34. Lanuti M, Sharma A, Willers H, Digumarthy SR, Mathisen DJ, Shepard J-AO. Radiofrequency Ablation for Stage I Non-Small Cell Lung Cancer: Management of Locoregional Recurrence. *The Annals of Thoracic Surgery*. 2012;93(3):921–928. doi: 10.1016/j.athoracsur.2011.11.043.
35. Aarts BM, Klompenhouwer EG, Rice SL, et al. Cryoablation and immunotherapy: an overview of evidence on its synergy. *Insights Imaging*. 2019;10(1):53. doi: 10.1186/s13244-019-0727-5.

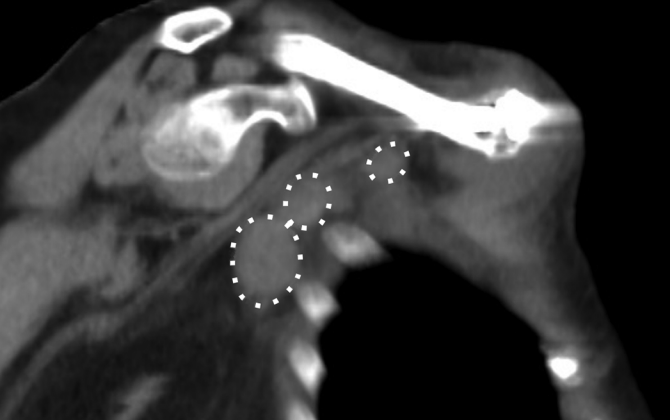FIGURE LEGENDS

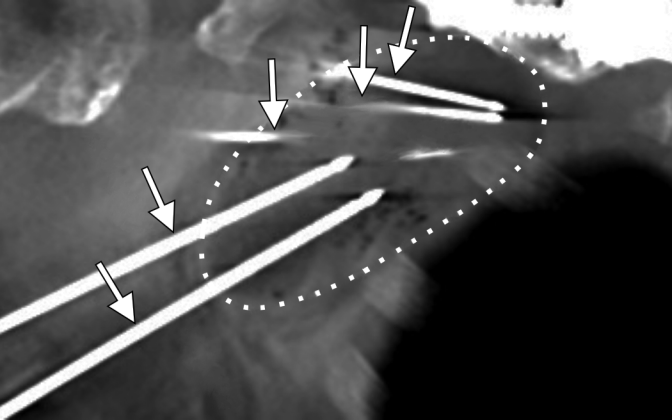
Figure 1. 75-year-old female with oligo-metastatic melanoma referred for cryoablation of right axillary loco-regional LNMs. Pre-operative unenhanced sagittal oblique multi-planar reformatted (MPR) CT (**a**) shows 3 right axillary LNMs (dotted circles), which were encompassed within a single large iceball during PCA (**b**, dotted circle), following placement of 4 cryoprobes (arrows). At 2-year follow-up (**c**), the patient achieved remission without evidence of local tumor recurrence, noting a partially calcified post-ablation scar (arrowheads).

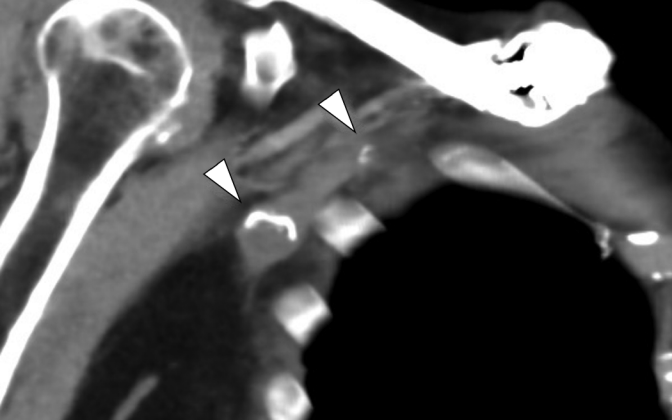
Figure 2. 28-year-old female with left external iliac LNM from melanoma referred for PCA. Pre-operative axial (**a**) PET/CT illustrate hypermetabolic left external iliac LNM in close proximity to neurovascular bundle and anterior abdominal wall (arrow). Axial (**b**) and coronal (**c**) intra-operative MR images demonstrate cryoprobe (arrowhead in **c**) and iceball (arrows) encompassing target-lesion tumor; hydrodissection fluid surrounding ablation-zone and displacing bladder away from iceball (star); and warm saline-filled glove thermally protecting overlying soft tissues (circle). Pressure was applied to the cryoprobe during freezing to manually displace the iceball away from the external iliac neurovascular bundle and anterior abdominal wall, mitigating risk of neural and soft tissue complications, and heat sink effects. (**d**) Axial PET-CT 6-months post-procedure shows complete metabolic response of left external iliac LNM (arrow), with the patient achieving complete remission.

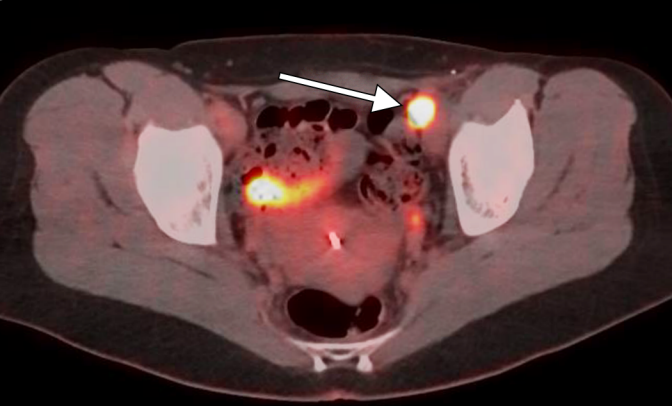
Figure 3. 41-year-old male with prior testicular cancer referred for PCA of aorto-lumbar LNM. Pre-operative axial (**a**) CT illustrates right retrocrural LNM abutting aorta (dotted circles). (**b**, **c**) Initially, hydrodissection was performed using a 22G spinal needle (arrow in **b**) via a transdiscal approach, to separate the aorta (arrowhead) from the LNM (dotted circle) with interstitial fluid (star), and ~~heat~~ cold-sink effect. Two cryoprobes (arrow in **c**) were then deployed within the LNM via a paravertebral approach, to ensure complete ~~lesion~~ tumor coverage by the iceball. (**d**) Axial contrast-enhanced T1 FS MR images at 2-year follow-up demonstrate ongoing complete ablation, and the patient was clinically in complete remission.

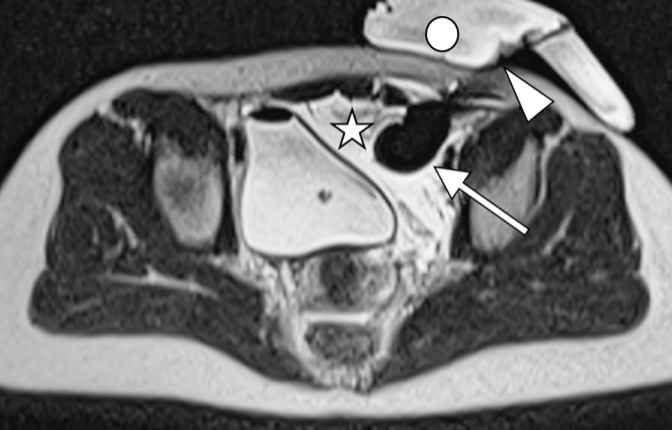
Figure 4. Overall survival (**a**, **b**), local tumor progression-free survival (**c**, **d**) and disease-free survival (**e**, **f**) curves in whole cohort and in loco-regional vs. oligo-metastatic groups.

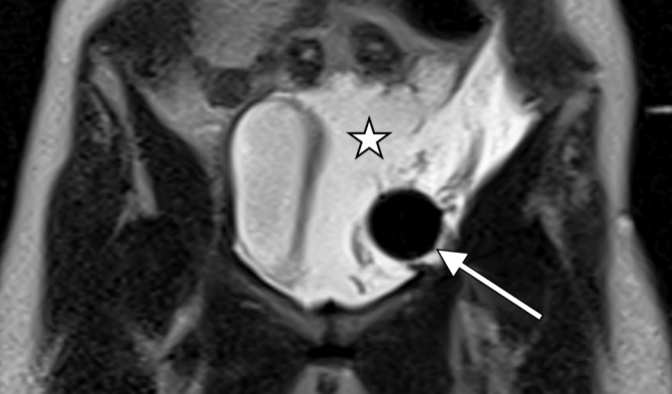


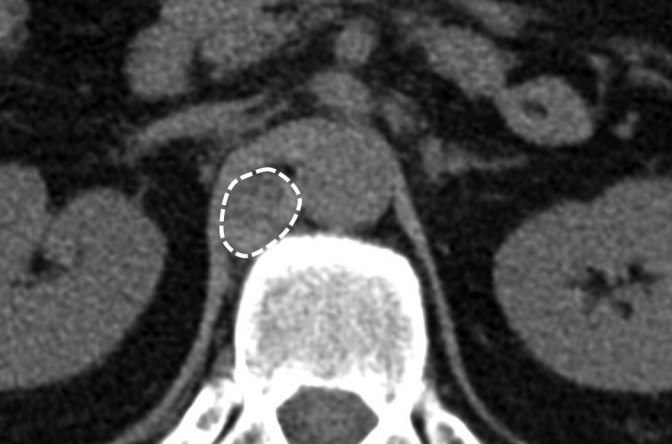

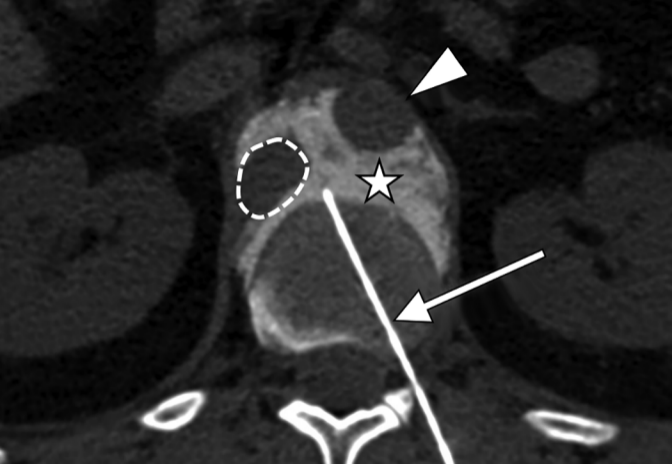



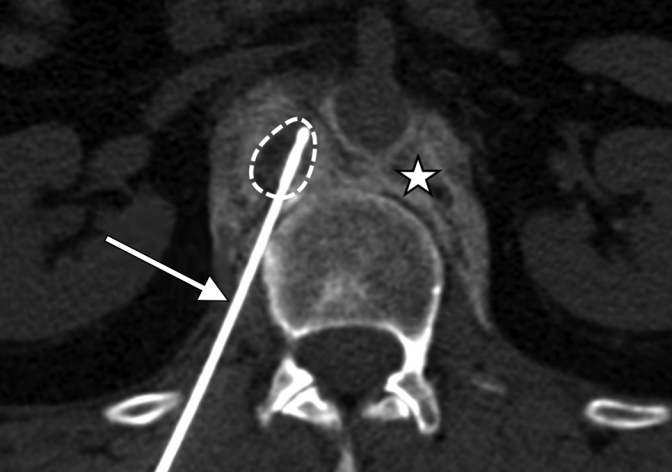


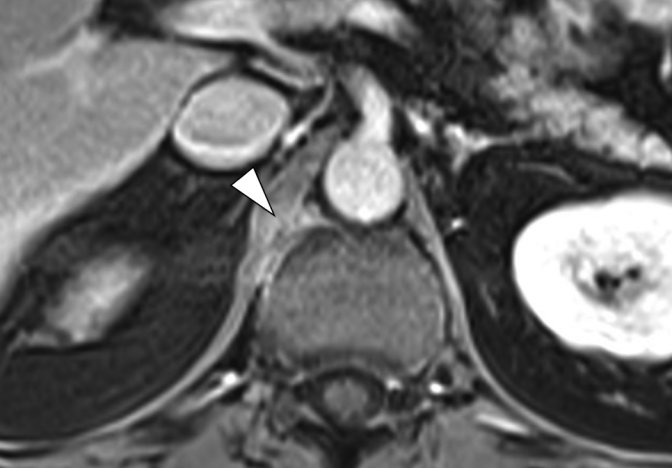

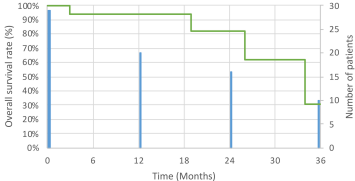




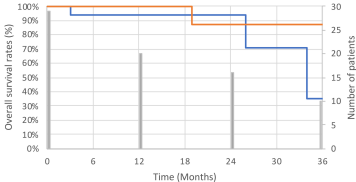




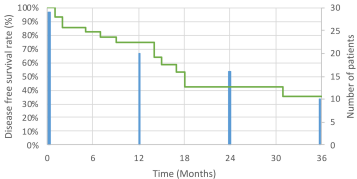
Whole cohort



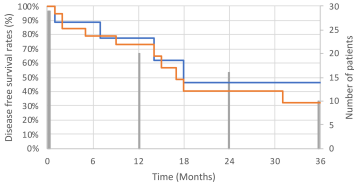
— Loco-regional and — oligo-metastatic



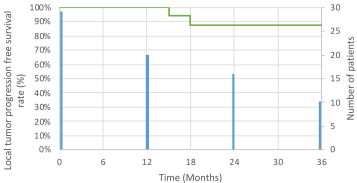
Whole cohort



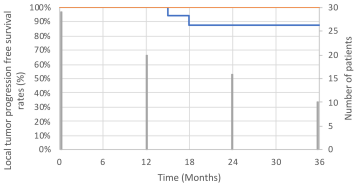
— Loco-regional and — oligo-metastatic



Whole cohort



— Loco-regional and — oligo-metastatic



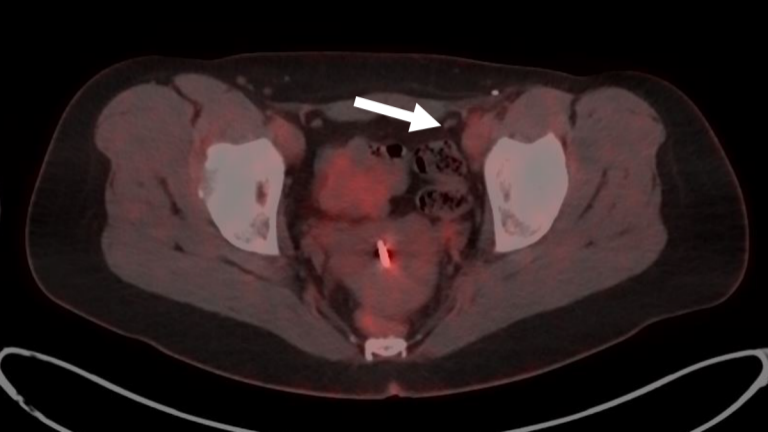


Table 1. Patient and LNM characteristics. F: Female; M: Male; IDC: Invasive Ductal Carcinoma; LIC: Lobular Invasive Carcinoma; SCC: Squamous Cell Carcinoma; HCC: Hepatocellular Carcinoma; IM: Internal mammary; *: Patient treated in two sessions. NP: Not provided.

Patient	Session	Sex	Age	Primary tumor	Histopathological subtype	Location	Number of LNM(s)	LNM long axis (mm)
1	1	F	28	Melanoma	Breslow 2mm	Iliac	1	23
1	2	F	32	Melanoma	Breslow 2mm	Iliac	1	21
1	3	F	33	Melanoma	Breslow 2mm	Iliac	2	13
2	1	F	61	Melanoma	Breslow 4.5mm	Iliac	1	27
3	1	M	68	Melanoma	Unknown	Pectoral	1	12
3	2	M	68	Melanoma	Unknown	Supraclavicular	1	11
4	1	M	46	Melanoma	N. P.	Axillary	5	14
5	1	F	49	Melanoma	Breslow 0.9mm	Inguinal	2	36
6	1	F	48	Melanoma	Breslow 4.5mm	Inguinal	2	32
6	2	F	50	Melanoma	Breslow 4.5mm	Inguinal	1	20
7	1	M	55	Melanoma	Breslow 2.5mm	Coeliac	2	23
8	1	F	75	Melanoma	Breslow 3.5mm	Axillary	4	23
9	1	F	59	Breast	IDC	Axillary	3	15
9	2	F	61	Breast	IDC	Pectoral	1	15
10	1	F	50	Breast	IDC	Axillary	3	14
11	1	F	55	Breast	LIC	Axillary	1	11
12	1	F	53	Breast	IDC	Pectoral	1	18
13	1	M	63	Breast	IDC	Axillary	2	15
14	1	F	49	Breast	IDC	IM	1	15
15	1	F	49	Breast	IDC	Pectoral	2	23
16	1 *	M	61	Thyroid	Medullary	Mediastinal	1	17
16	2 *	M	61	Thyroid	Medullary	Mediastinal	1	17
16	3	M	63	Thyroid	Medullary	Supraclavicular	2	10
17	1	M	49	Thyroid	Papillary	Supraclavicular	1	9
18	1	F	65	Thyroid	Medullary	Cervical	1	13
19	1	F	66	Thyroid	Papillary	Cervical	1	11
20	1	F	56	Thyroid	Papillary	Cervical	1	10
21	1	F	55	Pulmonary	Adenocarcinoma	Aorto-lumbar	1	16
22	1	F	50	Pulmonary	Adenocarcinoma	Iliac	1	21
23	1	M	69	Pulmonary	SCC	Coeliac	1	20
24	1	M	67	Prostate	Adenocarcinoma	Iliac	1	23
25	1	M	62	Prostate	Adenocarcinoma	Iliac	2	12
25	2	M	63	Prostate	Adenocarcinoma	Iliac	1	13
26	1	M	77	Renal	Papillary ISUP 4	Aorto-lumbar	1	13
27	1	M	83	Liver	HVV	Subdiaphragmatic	1	14
28	1	M	62	Stomach	Adenocarcinoma	Supraclavicular	1	20
29	1	M	41	Testes	Germ cell tumor	Aorto-lumbar	1	22

Table 2. Study definitions for technical success, primary technique efficacy, local tumor progression (LTP), loco-regional and distant disease progression, local tumor progression free survival (LTPFS), disease free survival (DFS), and overall survival (OS).

Study Term	Definition
Technical success	Complete LNM coverage by iceball with minimum 5mm ablation margin on intra-procedural CT or MR imaging
Primary technique efficacy	Complete LNM ablation (non-enhancement of ablation-zone) at 1-month contrast-enhanced MR follow-up and absence of FDG uptake on first PET-CT follow-up (typically 6-12 weeks post-procedure)
Local Tumor Progression (LTP)	New enhancement or uptake on CT, MR or PET-CT at treated site, following initial complete LNM ablation.
Loco-regional disease progression	New loco-regional LNMs (distinct from previously treated lesions) on follow-up imaging
Distant disease progression	New distant LNMs (distinct from previously treated lesions) and/or visceral metastases on follow-up imaging
Local tumor progression free survival (LTPFS)	Time from PCA to first radiologic evidence of LTP
Disease free survival (DFS)	Time from PCA to first radiologic evidence of disease progression at any site
Overall Survival	Time from PCA to death from any cause

Table 3. Oncologic outcomes. Rates (standard error) of overall survival, local tumor progression-free survival and disease free-survival for whole cohort, loco-regional LNM group, and oligo-metastatic LNM group.

Overall Survival	Whole cohort	Loco-regional	Oligo-metastatic	<i>p (Fisher)</i>
	n=29	n=20	n=9	
- 1 year	96.2% (3.7)	100% (0)	88.9% (10.5)	0.31
- 2 years	90.5% (6.5)	90.9% (8.7)	88.9% (10.5)	0.53
- 3 years	70% (11.6)	80.8% (12.2)	44.4% (22.8)	0.29
Local tumor progression free survival				
- 1 year	100% (1)	100% (0)	100% (1)	1
- 2 years	94.3% (3.9)	86.5% (7.3)	100% (1)	1
- 3 years	94.3% (3.9)	86.5% (7.3)	100% (1)	1
Disease free survival				
- 1 year	74% (8.5)	72.8% (10.5)	77.8% (13.9)	1
- 2 years	39.9% (11.2)	40.4% (13.4)	46.7% (19)	1
- 3 years	31.9% (11.5)	32.3% (12.3)	46.7% (19)	1