



HAL
open science

Preclinical Study of Radiation on Fat Flap Regeneration under Tissue-engineering Chamber: Potential Consequences for Breast Reconstruction

Damien Cleret, Marion Gradwohl, Lucie Dekerle, Anne-Sophie Drucbert, Thierry Idziorek, David Pasquier, Nicolas Blanchemain, Julien Payen, Pierre Guerreschi, Philippe Marchetti

► To cite this version:

Damien Cleret, Marion Gradwohl, Lucie Dekerle, Anne-Sophie Drucbert, Thierry Idziorek, et al.. Preclinical Study of Radiation on Fat Flap Regeneration under Tissue-engineering Chamber: Potential Consequences for Breast Reconstruction. *Plastic and Reconstructive Surgery, Global Open*, 2022, 10 (12), 10.1097/GOX.0000000000004720 . hal-03960693

HAL Id: hal-03960693

<https://hal.science/hal-03960693v1>

Submitted on 2 Feb 2024

HAL is a multi-disciplinary open access archive for the deposit and dissemination of scientific research documents, whether they are published or not. The documents may come from teaching and research institutions in France or abroad, or from public or private research centers.

L'archive ouverte pluridisciplinaire **HAL**, est destinée au dépôt et à la diffusion de documents scientifiques de niveau recherche, publiés ou non, émanant des établissements d'enseignement et de recherche français ou étrangers, des laboratoires publics ou privés.

Preclinical Study of Radiation on Fat Flap Regeneration under Tissue-engineering Chamber: Potential Consequences for Breast Reconstruction

Damien Cleret, PhD*

Marion Gradwohl, PhD*†‡

Lucie Dekerle, PhD§

Anne-Sophie Drucbert, BSc†¶

Thierry Idziorek, PhD†

David Pasquier, MD ||**

Nicolas Blanchemain, PhD†

Julien Payen, PhD*

Pierre Guerreschi, MD, PhD†§

Philippe Marchetti, MD, PhD†¶

Background: Use of a tissue-engineering chamber (TEC) for growth of fat flap is a promising approach for breast reconstruction. Here, we evaluated in a preclinical model the effects of radiation on adipose tissue growth either before or after 3D-printed bioresorbable TEC implantation.

Methods: Twenty-eight female Wistar rats were distributed into three groups: TEC implantation as nonirradiated controls (G1), TEC insertion followed by irradiation 3 weeks later (G2), and irradiation 6 weeks before TEC insertion (G3). G2 and G3 received 33.3 Gy in nine sessions of 3.7 Gy. Growth of the fat flap was monitored via magnetic resonance imaging. At 6 months after implantation, fat flaps and TECs were harvested for analysis.

Results: Irradiation did not alter the physicochemical features of poly(lactic-co-glycolic acid)-based TECs. Compared with G1, fat flap growth was significantly reduced by 1.6 times in irradiated G2 and G3 conditions. In G2 and G3, fat flaps consisted of mature viable adipocytes sustained by CD31+ vascular cells. However, 37% (3 of 8) of the G2 irradiated adipose tissues presented a disorganized architecture invaded by connective tissues with inflammatory CD68+ cells, and the presence of fibrosis was observed.

Conclusions: Overall, this preclinical study does not reveal any major obstacle to the use of TEC in a radiotherapy context. Although irradiation reduces the growth of fat flap under the TEC by reducing adipogenesis and inducing inconsistent fibrosis, it does not impact flap survival and vascularization. These elements must be taken into account if radiotherapy is proposed before or after TEC-based breast reconstruction. (*Plast Reconstr Surg Glob Open* 2022; 10:e4720; doi: 10.1097/GOX.0000000000004720; Published online 22 December 2022.)

INTRODUCTION

Current breast reconstruction techniques include autologous tissue flap repair, which consists in taking adipose tissue from a part of the body and relocating it to the chest wall to recreate a breast. In an effort to

improve this surgical procedure, tissue engineering and regenerative medicine approaches have been developed. Among these approaches, inserting a vascularized fat flap into a tissue-engineering chamber (TEC) does create a protective environment promoting viable and functional adipose tissue growth.¹ We previously demonstrated that optimal TEC design was necessary for adipose tissue growth, with multiple pores within the dome and a flat base to protect the growing flap from compression.¹ Besides, the TEC works as a bona fide

From the *Lattice Medical, Loos, France; †Univ. Lille, CHU, IRCL, CNRS, Inserm UMR9020-UMR-S, Lille, France; ‡Univ. Lille, UMR9020-U1277 CANTHER, Lille, France; §CHU Lille, Service de chirurgie plastique, Lille, France; ¶CHU Lille, Banque de Tissus, Lille, France; || Centre Oscar Lambret, Lille, France; and **Univ Lille CRISTAL UMR 9189, Lille, France.

Received for publication April 7, 2022; accepted October 21, 2022. Drs. Cleret and Gradwohl share co-authorship of this paper. Drs. Guerreschi and Marchetti share co-seniorship of this paper.

Copyright © 2022 The Authors. Published by Wolters Kluwer Health, Inc. on behalf of The American Society of Plastic Surgeons. This is an open-access article distributed under the terms of the [Creative Commons Attribution-Non Commercial-No Derivatives License 4.0 \(CCBY-NC-ND\)](https://creativecommons.org/licenses/by-nc-nd/4.0/), where it is permissible to download and share the work provided it is properly cited. The work cannot be changed in any way or used commercially without permission from the journal.

DOI: 10.1097/GOX.0000000000004720

Disclosure: Dr. Guerreschi, and Dr. Marchetti are co-inventors of a patent application that covers the design of the TEC and are consultants for Lattice Medical. The other authors have no financial interest to declare. This work was supported by the INTERREG France-Wallonie-Vlaanderen program with support from the European Regional Development Fund (MAT(T)ISSE project).

Related Digital Media are available in the full-text version of the article on www.PRSGlobalOpen.com.

bioreactor promoting adipogenesis via several complementary mechanisms.² Thus, in many preclinical models, TEC promotes significant long-term growth (up to fivefold the initial volume) for fat flaps.³⁻⁵ Furthermore, its clinical feasibility was validated in women with history of postmastectomy reconstruction.⁶ Thus, this promising tissue-engineering technique can become a highly relevant addition to breast reconstruction options, after validation in larger clinical trials.

After surgery, adjuvant radiotherapy can be used in an attempt to reduce breast cancer recurrence and to improve long-term survival. To date, combining radiation therapy with breast reconstruction via autologous fat flap remains challenging. Depending on the sequencing of radiation therapy occurring before or after breast reconstruction, the complications and clinical outcomes can vary considerably.^{7,8} Radiotherapy can result in fibrosis and/or fat necrosis, which trigger clinical complications (contracture and volume loss) and eventually alter the reconstructive properties of the autologous fat flap. Postponing the autologous reconstruction after radiotherapy can reduce the risk of complications since the fat flap is not directly exposed to radiation.⁷

To the best of our knowledge, the use of TEC in an irradiated model of soft tissue reconstruction has yet to be evaluated. This work describes the effects of irradiation on fat flap growth and evaluates tissue quality in a rat TEC-based adipose tissue-engineering model.

In this study, we used a 3D-printed bioresorbable TEC model with an optimized design,¹ allowing the growth of vascularized viable mature adipose tissue without noticeable inflammation. TEC implementation and fractionated irradiation⁹ were used with different sequential timings to replicate the two clinical settings: immediate and delayed autologous reconstructions. Thus, the main objective of this study was to test, in a preclinical model, the possibility of using bioresorbable TEC during radiotherapy. These

Takeaways

Question: How radiation can impact the generation of fat flap within a tissue-engineering chamber: a preclinical study.

Findings: Our study did not reveal any major obstacle to the use of TEC in a radiotherapy context. While irradiation reduces the growth of fat flap under the TEC by reducing adipogenesis and inducing inconsistent fibrosis, it did not impact flap survival and vascularization.

Meaning: This has important implications for the potential application of tissue-engineering techniques in post-mastectomy breast reconstruction.

results may open up new avenues once the use of TEC in breast reconstruction management is validated.

MATERIALS AND METHODS

Animal Model

Animal experiments were performed in accordance to standard protocols at the Department of Laboratory Animal Facility (University of Lille, School of medicine). Protocols were conducted under the regulation of the ethics committee review board (University of Lille, School of medicine) and were submitted to and approved by the regional ethics committee (CEEA 75 North region of France) with the agreement of the French ministry of higher education research and innovation (N°201904011018396). Twenty-eight female Wistar rats (12 weeks old; Janvier Labs, France) weighing 245 to 347 grams were randomly divided into three groups (Fig. 1): group 1 (n = 8) served as nonirradiated control rats with the insertion of a standard TEC; rats in group 2 (n = 10) were irradiated 3 weeks before the TEC insertion; rats in group 3 (n = 10) underwent TEC insertion and were irradiated 6 weeks later.

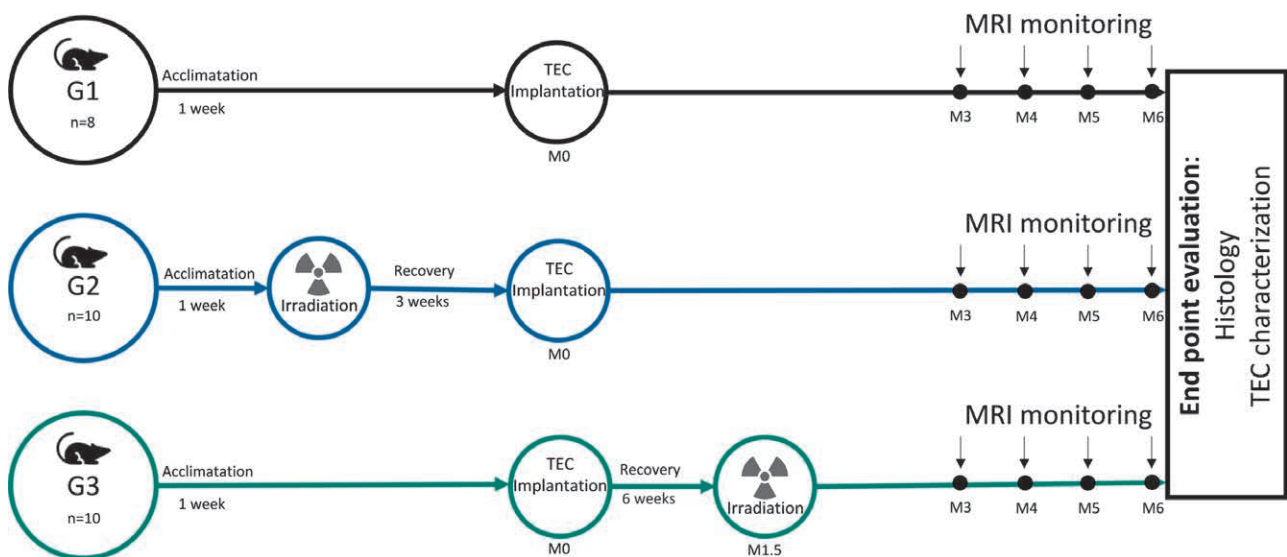


Fig. 1. Experimental design: schematic figure depicting the follow-up of rats implanted with TEC with or without irradiation (see Material and Methods section for details; M, month).

TEC Implantation

Rats were anesthetized with inhaled isoflurane (Abbot; Cham, Switzerland) at 5%, 1 L per minute for induction and at 2%, 1 L per minute for maintenance, in combination with oxygen. TECs were implanted subcutaneously in the thoracolumbar region according to our previously published protocol.¹ (See figure, **Supplemental Digital Content 1**, which displays dorsal implantation of the TEC. For each image, the head of the animal is on the right side. Pictures chronologically describe diagonal dorsal incision, tissue dissection and identification of the crural vessel, fat flap exposure, fat flap measurement using a mold, fat flap with pedicle after cutting, flap placed on the base of the TEC and sutures, lidded chamber secured with nonresorbable sutures, TEC insertion in dorsal position, and wound closure, <http://links.lww.com/PRSGO/C314>.)

Magnetic Resonance Imaging

Flap volume was measured via magnetic resonance imaging (MRI) when indicated.

Tissue Assessment for Histomorphometry and Immunohistochemistry

At the time of euthanasia, all tissues harvested from the chambers were immediately fixed then routinely stained with hematoxylin and eosin or Masson's trichrome as previously detailed (Table 1 and Fig. 1).¹ (See appendix, **Supplemental Digital Content 2**, which displays supplementary materials and methods, <http://links.lww.com/PRSGO/C315>.)

Table 1. Characteristics of TECs Used in This Study

	PURASORB PLG 85:23
Polymer	85:15 Poly(l-lactid-co-glycolid)
Bioresorbable	Yes
3D Printer	Ultimaker 3 (Ultimaker, The Netherlands)
Dome characteristics	
Hole(s) on side(s) for insertion of vessels	1
Theoretical volume of TEC (mm ³)	2300
Height (mm)	10
Thickness (mm)	1,2
Diameter (mm)	23
Dome perforated	Yes
Porosity (%)	21
Pores	
Number	57
Diameter (mm)	2,3
Distribution	Homogeneous
Base characteristics	
Removable base	Yes
Thickness (mm)	1
Diameter (mm)	23
Base perforated	Yes
Porosity (%)	36
Pores	
Number	2,3
Diameter (mm)	Homogeneous
Distribution	

RESULTS

Effects of Radiation on Poly(Lactic-co-glycolic Acid)-based TEC

No macroscopic morphological changes were observed after in vitro irradiation of the poly(lactic-co-glycolic acid) (PLGA)-based TEC (Fig. 2). We also wanted to verify whether radiation affected the physicochemical properties of PLGA domes in vitro (Fig. 2). PLGA domes were irradiated nine times with a dose of 3.7 Gy both in dry and wet conditions after 48 hours of incubation in a PBS solution to mimic in vivo moisture conditions (Fig. 2). Gel permeation chromatography (GPC) analysis showed that the molar mass of PLGA (Mn) was not impacted by irradiation. Differential scanning calorimetry (DSC) analysis demonstrated that irradiation in dry or wet conditions did not yield any change in crystallinity rate, glass transition temperature, or the PLGA melting point. Overall, the physicochemical properties of PLGA were not affected by in vitro irradiation, suggesting that radiotherapy is compatible with TEC reconstruction.

Physicochemical properties of PLGA domes ex vivo were evaluated at 6 months after implantation. Figure 2D shows that PLGA domes became opaque, fragile, and brittle in all groups. We also observed a delamination of the 3D printing layers leading to a structure deformation in all conditions. GPC results analysis revealed that PLGA lost between 70% and 80% of its initial molecular weight without significant differences among the three groups (Fig. 2). The DSC analysis showed that the PLGA level of crystallinity, initially amorphous, rose to higher values between 6% and 10%. However, no significant difference was observed between groups (Fig. 2). Overall, our results indicate that irradiation had no impact on physicochemical properties of PLGA domes after in vivo implantation.

Effects of Radiation on Fat Flap Volume Expansion

During the postimplantation recovery period, very few gross surgical-site complications were reported (Table 2). However, two animals from group G1, two from group G2, and three animals from group G3 were removed from the study due to self-injury. On the irradiated site, the acute radiodermatitis was similar in the two irradiated groups: G2 and G3 (Table 2). Fat flap growth was significantly higher in the nonirradiated control group (G1), with a fourfold volume increase at 6 months, whereas the increase was twofold at 6 months for both irradiated groups (G2 and G3) (Fig. 3A, B). No weight gain difference was observed among the three groups (Fig. 3C). At 6 months, 3D MRI images confirmed the presence of a fat flap inserted into a slightly deformed TEC without any significant changes among the three groups (Fig. 3D).

Histological Examination of the Fat Flap after Irradiation

For a better evaluation of the irradiation impact, fat flaps were sectioned longitudinally for histomorphology analyses (Fig. 4). There was no evidence of PLGA residues

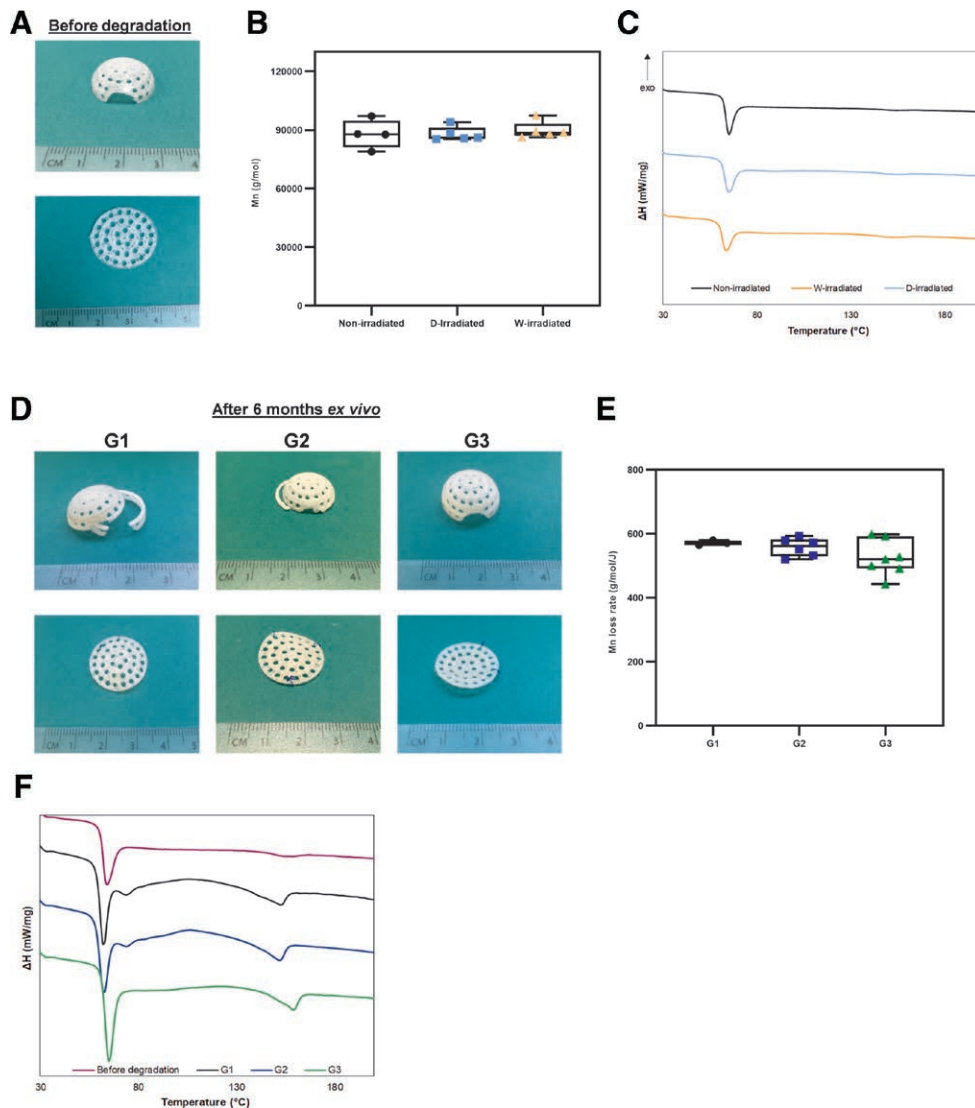


Fig. 2. Effects of radiation on PLGA-based TEC. A, Visual aspect of PLGA TEC irradiated in vitro. B, Number-average molecular weight (M_n) of PLGA from TEC samples nonirradiated (black; $n = 4$) and irradiated in vitro in dry (blue; $n = 5$) or wet (orange; $n = 5$) conditions. C, DSC thermograms of PLGA TEC samples non-irradiated (black) and irradiated in vitro in dry (blue) or wet (orange) conditions (heating rate, 10 K/min). Data are representative of one experiment out of four. D, Visual aspect of PLGA TEC ex vivo after 6 months of implantation. E, Number average molecular weight (M_n) loss rate of PLGA TEC samples ex vivo after 6 months of implantation: G1 (black; $n = 3$), G2 (blue; $n = 6$), and G3 (green; $n = 6$). F, DCS thermograms of PLGA TEC samples ex vivo after 6 months of implantation: G1 (black line), G2 (blue line), and G3 (green line) compared with TEC sample before degradation (purple line).

embedded into the adipose or connective tissues, regardless of the study group (Fig. 4A). For the fat flaps in the G1 control group, hematoxylin and eosin (HE) staining revealed predominant adipose tissue, with normal lobular architecture, sometimes surrounded by a thin layer of connective tissue. In contrast, fat flaps in the G2 group were smaller and inconsistent in shape. The adipose tissue was strongly disorganized by the invasion of connective tissue distributed in clusters, although it was at the significance threshold when compared with control (Fig. 4). Masson's trichrome staining revealed the existence of collagen fibers indicating emerging fibrosis (Fig. 4B). Conversely,

samples in the G3 group conserved a normal architecture with adipose tissue spread out in the central area associated with few or no peripheral connective tissue (Fig. 4).

Regardless of study groups, the fat flap connective tissues were characterized by CD68⁺ macrophage infiltration (Fig. 5). In the irradiated G2 and G3 groups, almost all adipocytes were positive for perilipin, a marker of cell maturity (Fig. 6A). No signs of atrophy or adipose cell death were observed as evidenced by the absence of terminal deoxynucleotidyl transferase dUTP nick end labeling (TUNEL) staining. (See figure, Supplemental Digital Content 3, which displays a representative image

Table 2. Clinical Signs of Animals after TEC Implantation and after Irradiation

	Post Implantation			Post Irradiation		
	(n)	G1	G2	G3	(n)	G2
No observation	5	7	8	No observation	3	0
Wound disunion	0	1	0	Pruritus	8	2
Bite	2	3	0	Depilation	8	9
Seroma	1	1	0	Erythema	0	2
Hematoma	1	0	0	Wound	1	0
Self-injury	2	2	3	Hematuria	1	0

of TUNEL staining of tissues under the TEC, <http://links.lww.com/PRSGO/C316>.)

The low level of lipid peroxidation, highlighted by the lack of 4-hydroxy-2-nonenal (4-HNE) production, validated the absence of acute irradiation damage to the adipose tissue (Fig. 6B). Compared with the G1 control group, the fat flap in the irradiated G2 group and especially the G3 group exhibited less adipocytes per surface area; although this finding was not statistically significant, this reduced growth in the irradiated groups could be attributed in part to lower

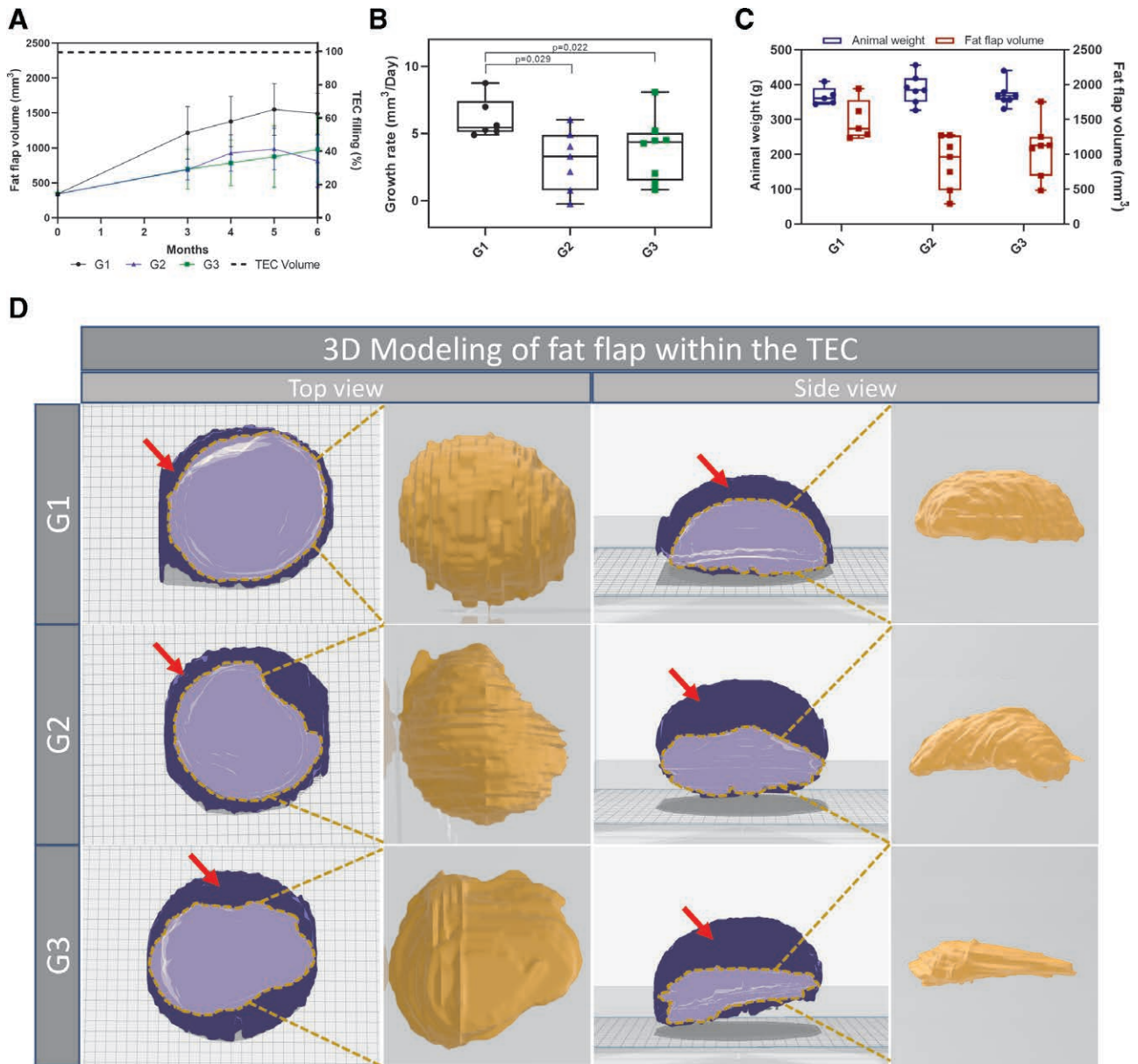


Fig. 3. Effects of radiation on fat flap volume. A, MRI quantitative analysis of in-vivo growth kinetics of fat flaps (right axis) and percentage of TEC filling (left axis). Results are expressed as means \pm SD. Dark dash line: TEC volume, dark line with circle dots: G1, blue line with triangle dots: G2, and green line with square dots: G3. B, Fat flap growth rate between implantation and explantation. Kruskal-Wallis and Mann-Whitney tests. C, Animal weight (left axis) and fat flap volume (right axis) at 6 months after implantation. D, Representative 3D reconstruction of fat flaps (light blue and yellow) into the TEC (dark blue) at 6 months after implantation.

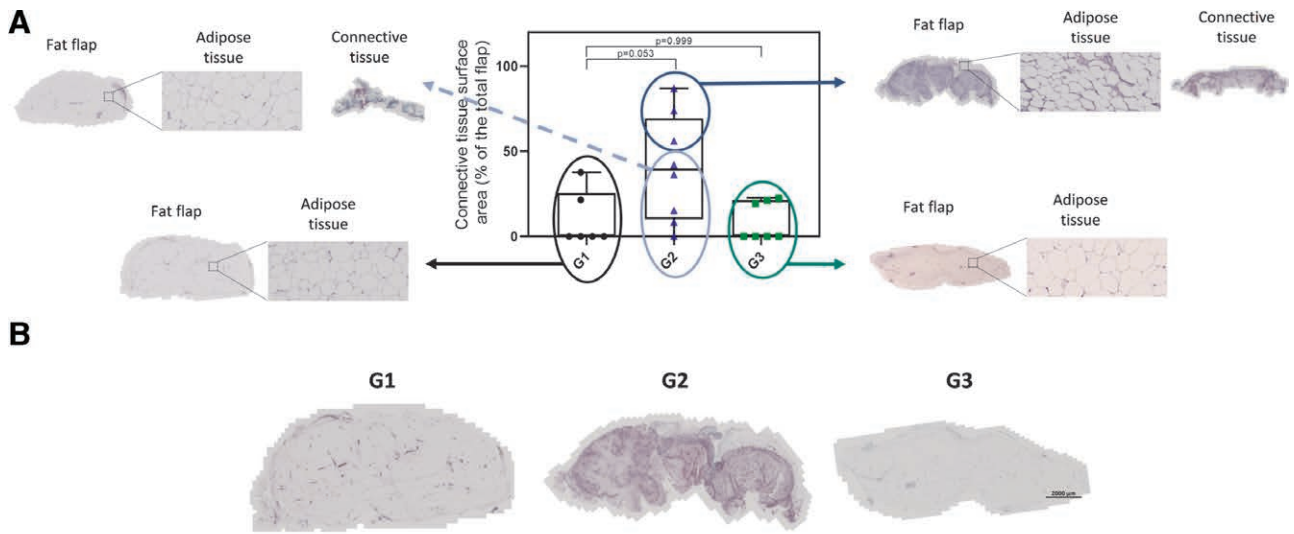


Fig. 4. Histomorphometric analyses of fat flap and connective tissues at 6 months after implantation. A, Representative image of hematoxylin-eosin staining of tissues under the TEC. Thickness of the connective tissue around the fat flap was measured. Data are presented in percentage of the total surface area as whisker bar graphs (median, 5–95 percentile—max–min). B, Representative image of Masson's trichrome stained tissue. Blue areas indicate collagen fibers deposition.

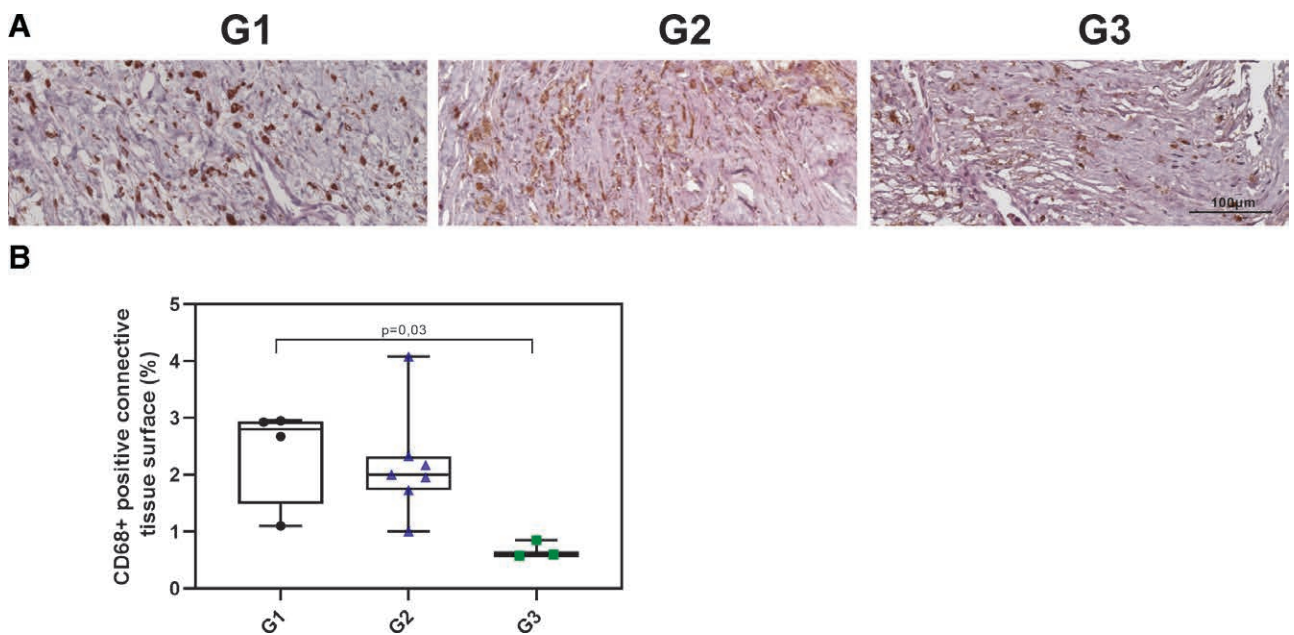


Fig. 5. Histomorphometric analysis of CD68+ macrophage infiltrate in the connective tissue at 6 months after implantation. A, Representative images of anti-CD68-stained cells in the connective tissue are shown. B, Percentage of CD68+ cell surface in the connective tissue. Data are presented in percentage of the total surface area as whisker bar graphs (median, 5–95 percentile—max–min). Mann-Whitney tests.

adipose tissue regeneration (Fig. 6C). Similarly, fat flaps in the G2 and G3 groups had fewer (<20%) small-size adipocytes (surface <4000 µm²), a subpopulation of progenitor cells that regenerate adipose tissue (Fig. 6C).

All groups showed similar adipose tissue vascularization, as illustrated by CD31 immunofluorescence, regardless of irradiation (Fig. 7).

DISCUSSION

Bioresorbable TEC represents a potential innovative option for autologous flap reconstruction after mastectomy. Its many benefits would warrant its translation into clinical settings to enrich breast reconstruction therapeutic options.¹ There are multiple mechanisms underlying the TEC-related adipogenesis.

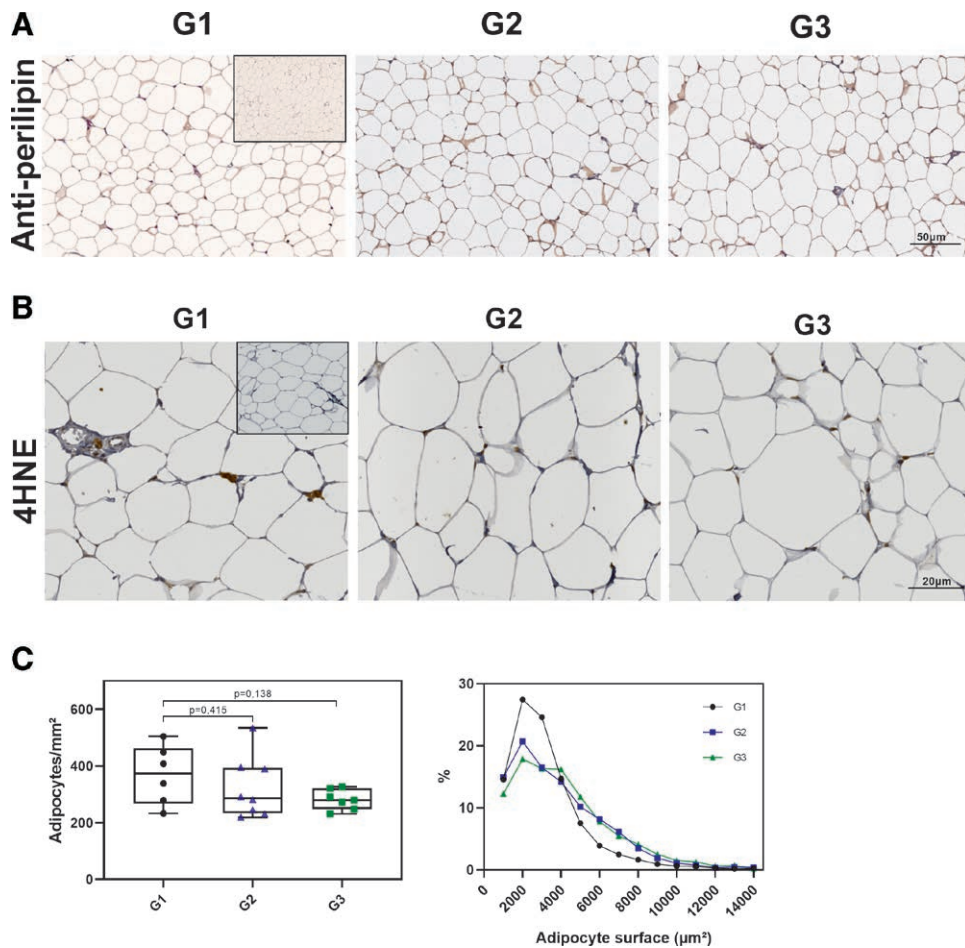


Fig. 6. Characterization of the adipose tissue at 6 months after implantation. A, Representative images of antiperilipin-stained adipose tissue. Insert represents the IgG isotype control; scale bar as indicated. B, Representative images of anti-4-HNE stained cells in the adipose tissue. The window represents the IgG isotype control. C, Comparison of the number of adipocyte cells per mm² (left) and the adipocyte surface distribution (right). Data are presented as whisker bar graphs (median, 5–95 percentile—max–min). Mann-Whitney tests.

(1) TECs create an enclosed space protecting the vascular pedicle from compressive forces that may damage growing tissues. Interestingly, in this article, we observed an undesirable TEC base deformation, leading to a reduced TEC volume remaining available for fat flap growth, regardless of TEC irradiation (Figs. 2, 3). This can be explained by the plasticizing effect of water on the PLGA, which becomes deformed over time by forces exerted by surrounding tissues.

(2) Dome porosity allows cell-secreted (mainly macrophages) angiogenic and growth factors of the surrounding tissues to penetrate the TEC and stimulate flap growth.

(3) The perforated dome allows the formation of a vascular network connecting external tissue vessels to those of the vascularized flap, promoting a high density of neo vessels in the flat’s periphery leading to harmonious neoadipogenesis.¹

Radiotherapy has an important place in the therapeutic array of breast cancer management. However, the use of radiation remains challenging for breast reconstruction.

The use of radiation therapy inexorably exposes normal tissues surrounding the tumor to radiation-induced complications. Radiation-induced injuries of the tissular environment can be categorized as acute radiation injuries or delayed irradiation effects, which could compromise autologous fat flap survival. Indeed, irradiation creates a chronic inflammation, profibrotic environment, and promotes the formation of a fibrotic capsule in these patients. As previously reported, radiotherapy increases the risk of complications in implant-based breast reconstruction.⁷ In this study, using preclinical models, we tested the feasibility of integrating TEC-based reconstruction before or after radiotherapy using fractionation regimen (multifraction: 9 × 3.7 Gy) to approximately recreate the clinical situation.

We first studied the condition (G2 group) where the nonirradiated flap under the TEC was transplanted into a previously irradiated tissue area (transplant bed) to mimic delayed reconstruction. Compared with nonirradiated TEC conditions (G1 group), irradiation of the graft bed led to a significant fat flap growth reduction over time.

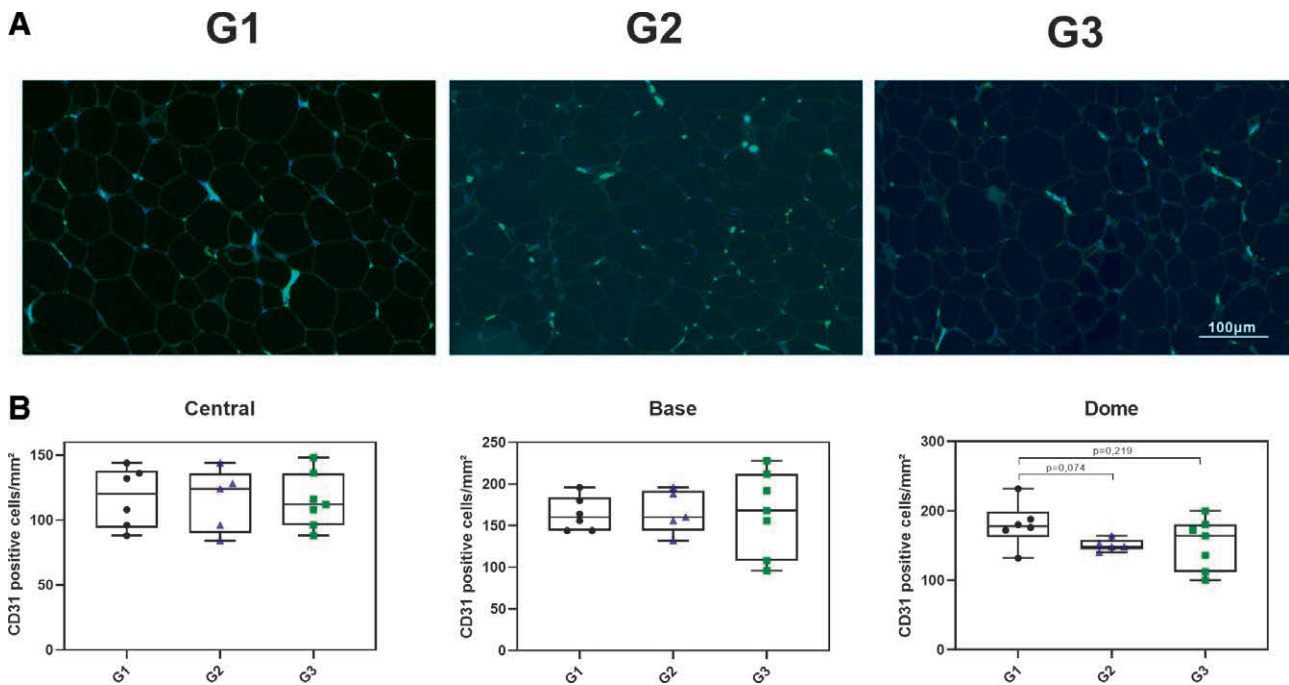


Fig. 7. Characterization of the adipose tissue vascularization at 6 months after implantation. A, Representative photographs of well-vascularized, adipose tissue with CD31+ capillaries. Blood vessel walls are immunostained in green. B, Comparison of the number of CD31+ cells per mm² at the central, base, or dome areas of the fat flap. Data are presented in percentage of the total surface area as whisker bar graphs (median, 5–95 percentile—Max–min). Mann-Whitney tests.

Several reasons can explain this phenomenon. First, in some cases, we observed an invasion of the fat flap by connective tissues, containing both collagen fibers and CD86+ macrophages, which made up almost 80% of the flap. Consistently, a study using rat and human adipose tissues exposed to radiation levels similar to those used in radiotherapy evidenced an inflammatory wound response.¹⁰ Thus, one can imagine that the irradiation of the transplant bed could lead to long-term damages resulting in progressive replacement of adipose tissue with fibrotic tissue. The second reason is the reduction in adipogenesis. Indeed, in the G2 group, we observed a decreased number of small-size adipocytes in the fat flap, corresponding to a reduction in immature stem-like progenitor adipocytes. This negative effect on adipogenesis can only be indirect once, since the flap was not exposed to radiation. This can be explained by the fact that many proinflammatory cytokines, including tumor necrosis factor- α , Interleukin 1 β , interferon- γ , and transforming growth factor- β 1, secreted by connective tissue cells (eg, macrophages and fibroblasts) block adipogenesis.¹¹ In other words, in response to radiation, fibroblasts and macrophages of the peripheral tissues are permanently activated and, thus, continuously generate proinflammatory cytokines, which could affect adipogenesis as well as lead to uncontrolled fibrosis. It should be noted that in our preclinical model, irradiation precedes TEC reconstruction by only 3 weeks. This time frame is much shorter than the one usually observed in clinical settings, where reconstruction can be proposed a few months after radiotherapy. Therefore, it can be hypothesized that a longer delay in TEC reconstruction

after radiotherapy could be associated with less fibrotic and antiadipogenic damage.

We also studied the effect of radiation on the fat flap under the TEC (G3 group), a situation that can be likened to an immediate autologous reconstruction. Interestingly, in this condition, radiation did not alter the TEC's physicochemical properties (Fig. 2). We also did not observe any postoperative complications, such as fat flap necrosis. This is consistent with meta-analyses indicating that immediate autologous reconstruction followed by radiotherapy is safe and sustainable without major complications of the irradiated fat flap.^{7,12} The absence of delayed radiation injury, such as adipocyte cell death (see figure, **Supplemental Digital Content 3**, <http://links.lww.com/PRSGO/C316>), can be explained by the fact that mature, perilipin-positive differentiated cells are originally radioresistant¹³ but also due to the high level of fat flap vascularization, as evidenced by the high proportion of CD31+ cells seen in irradiated conditions. However, as observed in the G2 group, radiation of the fat flap significantly reduced its growth rate with a low proportion of small adipocytes. This is likely due to radiation-induced alterations in proliferation and differentiation potentials of adipocyte progenitors through the induction of oxidative stress as evaluated by the presence of 4-HNE. It has been shown that acute radiation effects (within 7 days) decrease the number and mean size of mature adipocytes.¹⁴ In this study, 6 months after radiation exposure, we failed to find a significant difference in the number of mature adipocytes compared with the G1 control group, suggesting that over time, these alterations are probably reversible.

Study limits include the small number of animals and a single late endpoint, which made it impossible to study acute response and the dynamics of biological event occurrences. However, the follow-up duration was sufficient to study the fate of radiotherapy-associated late complications, such as fibrosis. Our study model was not designed to determine the efficacy of radiotherapy against cancer cells. Radiotherapy regimens for breast cancer classically involve several separate fractions of low doses such as 25 fractions of 2 Gy.¹⁵ Consequently, we adopted a fractionation protocol of nine fractions of 3.7 Gy to replicate clinical protocols. Moreover, this study was not designed to compare the effects of irradiation between immediate and delayed reconstructions. Previous studies demonstrated that the inflammatory response triggered by the repeated radiation of adipose breast tissue decreased the effectiveness of the radiotherapy.¹⁰ Likewise, we observed that the perforated PLGA-based TEC absorbed radiation, and as such, it decreased the effective dose received under the TEC by 13% ± 3%. Thus, the TEC presence may reduce radiotherapy effectiveness on the underlying tissues, and this should be taken into account when calculating the delivered dose for future clinical applications.

In summary, for the first time, we provide experimental evidence to use TEC-based reconstruction alongside radiotherapy. Although radiotherapy can lead to fibrosis and, in some cases, a decreased adipocyte regeneration rate, it does not prevent mature adipocyte growth and flap vascularization under the TEC. These elements must be taken into account if radiotherapy is proposed before or after TEC-based breast reconstruction. TEC is a promising tissue-engineering technique, and its place in breast reconstruction should be validated in larger clinical trials. Further studies are needed to determine the clinical relevance and differential impact of radiotherapy on immediate or delayed TEC-based reconstruction. This has important implications for the potential application of tissue-engineering techniques in postmastectomy breast reconstruction.

Philippe Marchetti, MD, PhD

Centre de Biologie Pathologie–Banque de Tissus
F-59000 Lille Cedex France
Univ. Lille, CHU, IRCL, CNRS
Inserm UMR9020-UMR-S
1277 Canther
F-59000 Lille, France
E-mail: philippe.marchetti@chu-lille.fr;
philippe.marchetti@inserm.fr

Pierre Guerreschi, MD, PhD

Hôpital Salengro–Service de Chirurgie Plastique
CHU de Lille
F-59000 Lille, France
E-mail: pierre.guerreschi@chu-lille.fr

ACKNOWLEDGMENTS

M.G. is a recipient of CIFRE doctoral fellowships attributed by the ANRT. The authors thank Meryem Tardivel and Antonino Bongiovanni (US 41-UMS 2014—PLBS) for their assistance with microscopy analyses. The authors also thank Dr. Nicolas Germain, Dr. Pierre-Marie Danzé, Claire Nahon, and Amélia Jordao for all useful and helpful advice on our manuscript.

REFERENCES

- Faglin P, Gradwohl M, Depoortere C, et al. Rationale for the design of 3D-printable bioresorbable tissue-engineering chambers to promote the growth of adipose tissue. *Sci Rep-uk*. 2020;10:11779.
- Major GS, Simcock JW, Woodfield TBF, et al. Overcoming functional challenges in autologous and engineered fat grafting trends. *Trends Biotechnol*. 2021;40:77–92.
- Donnelly E, Griffin M, Butler PE. Breast reconstruction with a tissue engineering and regenerative medicine approach (systematic review). *Ann Biomed Eng*. 2020;48:9–25.
- Findlay MW, Messina A, Thompson EW, et al. Long-term persistence of tissue-engineered adipose flaps in a murine model to 1 year: an update. *Plast Reconstr Surg*. 2009;124:1077–1084.
- Dolderer JH, Dolderer JH, Doldere JH, et al. Long-term stability of adipose tissue generated from a vascularized pedicled fat flap inside a chamber. *Plast Reconstr Surg*. 2011;127:2283–2292.
- Morrison WA, Marre D, Grinsell D, et al. Creation of a large adipose tissue construct in humans using a tissue-engineering chamber: a step forward in the clinical application of soft tissue engineering. *EBIOM*. 2016;6:238–245.
- Shumway DA, Momoh AO, Sabel MS, et al. Integration of breast reconstruction and postmastectomy radiotherapy. *J Clin Oncol*. 2020;38:2329–2340.
- Kronowitz SJ. Current status of autologous tissue-based breast reconstruction in patients receiving postmastectomy radiation therapy. *Plast Reconstr Surg*. 2012;130:282–292.
- Haviland JS, Owen JR, Dewar JA, et al; START Trialists' Group. The UK standardisation of breast radiotherapy (START) trials of radiotherapy hypofractionation for treatment of early breast cancer: 10-year follow-up results of two randomised controlled trials. *Lancet Oncol*. 2013;14:1086–1094.
- Meng G, Tang X, Yang Z, et al. Implications for breast cancer treatment from increased autotaxin production in adipose tissue after radiotherapy. *FASEB J*. 2017;31:4064–4077.
- Simons PJ, van den Pangaart PS, van Roomen CPAA, et al. Cytokine-mediated modulation of leptin and adiponectin secretion during in vitro adipogenesis: evidence that tumor necrosis factor- α - and interleukin-1 β -treated human preadipocytes are potent leptin producers. *Cytokine*. 2005;32:94–103.
- Hershenhouse KS, Bick K, Shauly O, et al. Systematic review and meta-analysis of immediate versus delayed autologous breast reconstruction in the setting of post-mastectomy adjuvant radiation therapy [Published online 2020]. *J Plastic Reconstr Aesthetic Surg*.
- Bolus NE. Basic review of radiation biology and terminology. *J Nucl Med Technol*. 2017;45:259–264.
- Pogliolo S, Galvani S, Bour S, et al. Adipose tissue sensitivity to radiation exposure. *Am J Pathol*. 2009;174:44–53.
- Harris JR. Fifty years of progress in radiation therapy for breast cancer. *Am Soc Clin Oncol Educ Book*. 2014:21–25.