



HAL
open science

Insights into the aetiologies of hypercementosis: A systematic review and a scoring system

Léa Massé, Elsa Garot, Bruno Maureille, Adeline Le Cabec

► To cite this version:

Léa Massé, Elsa Garot, Bruno Maureille, Adeline Le Cabec. Insights into the aetiologies of hypercementosis: A systematic review and a scoring system. *Archives of Oral Biology*, 2023, 146, pp.105599. 10.1016/j.archoralbio.2022.105599 . hal-03942134

HAL Id: hal-03942134

<https://hal.science/hal-03942134v1>

Submitted on 16 Jan 2023

HAL is a multi-disciplinary open access archive for the deposit and dissemination of scientific research documents, whether they are published or not. The documents may come from teaching and research institutions in France or abroad, or from public or private research centers.

L'archive ouverte pluridisciplinaire **HAL**, est destinée au dépôt et à la diffusion de documents scientifiques de niveau recherche, publiés ou non, émanant des établissements d'enseignement et de recherche français ou étrangers, des laboratoires publics ou privés.

Insights into the aetiologies of hypercementosis: a systematic review and a scoring system

Léa Massé ^{a,b,c,*}, Elsa Garot ^{a,b,c}, Bruno Maureille ^a, Adeline Le Cabec ^{a,d}

Affiliations:

^a Univ. Bordeaux, CNRS, Ministère de la Culture, PACEA, UMR 5199, F-33600 Pessac, France^b Univ. de Bordeaux, UFR des Sciences Odontologiques de Bordeaux, Bordeaux, France

^c CHU de Bordeaux, Bordeaux, France

^d Department of Human Evolution, Max Planck Institute for Evolutionary Anthropology, Deutscher Platz 6, 04103 Leipzig, Germany

*Corresponding author: lea.masse@u-bordeaux.fr

Keywords: dental cementum; palaeopathology; systemic disease; teeth-as-tools; tooth, impacted; tooth root.

Highlights

- Hypercementosis: complex and not yet well-defined aetiologies and manifestations.
- Eight aetiologies identified in this systematic review.
- A new scoring system is proposed to describe qualitatively hypercementosis.
- Patterns of cementum apposition are distinguished depending on different aetiologies.

Abstract

Objectives

This paper aims to better define hypercementosis, investigate its described potential aetiologies, and determine whether there are different patterns of cementum apposition and if they are a function of their supposed aetiology.

Design

A literature review was undertaken using the Medline, DOSS, Scopus and Cochrane Library electronic databases. Two co-authors selected the published works independently, extracted the data in accordance with the PRISMA statement.

Results

Among 546 articles, 75 articles were finally selected. Eight different supposed aetiologies were identified: (1) intensive masticatory effort, (2) systemic disease, (3) carious lesion and apical periodontitis, (4) impaction, (5) periodontal disease, (6) concretion, (7) supereruption, and (8) drugs. Some of these aetiologies can be combined in the same tooth. Hypercementosis manifestations are various in nature and extent with different patterns that may be

aetiology-specific. To improve the description and associated consistency in the characterisation of hypercementosis, in this review but also in future studies, we propose a new qualitative scoring system to quickly characterise hypercementosis and determine its most relevant aetiology.

Conclusions

This systematic review demonstrates that hypercementosis is a complex and not yet well-defined condition. Some forms of apposition are specific to a given aetiology. The hypercementosis characterisation may contribute to document the oral condition and/or the individuals masticatory activity.

1. Introduction

1.1. State-of-the-art about cementum, hypercementosis and its putative aetiologies

As early as during the 17th century, scholars among which Malpighi, van Leeuwenhoek, and a century later Blake, Tenon and Cuvier were the very first to report their observations on cementum (see [Foster, 2017](#) for a review). This mineralised tissue covers the surface of the tooth root and contributes to the attachment of the tooth in its bony socket ([Goldberg, 2015](#)). Cementum is a complex, avascular and non-innervated tissue, which may be subdivided into different types of cementum (e.g., [Schroeder, 1993](#); [Consolaro et al., 2012](#); [Yamamoto et al., 2009](#)). Since these earlier observations, there is a lack of consensus in the nomenclature to distinguish the types of cementum. This is only at the beginning of the 19th century, during which substantial advances in microscopy took place, that Purkinje and Retzius (cited in [Foster, 2017](#)) have produced the first detailed descriptions of cementum, especially differentiating cellular from acellular cementum. Acellular cementum is found in the cervical root half while cellular cementum is preferentially located on the apical root half and in root furcation areas for multirooted teeth ([Schroeder, 1992](#)). Acellular cementum is deposited following an incremental and slow growth pattern, with an assumed yearly periodicity, which was observed to begin with root formation and continue until the death of the individual (e.g., [Naji et al., 2015](#)). Cementochronology relies on counting these yearly increments for estimating adult age at death (e.g., [Naji et al., 2016](#) for a review, [Le Cabec et al., 2019](#), [Newham et al., 2021](#)). Cellular cementum is a heterogeneous tissue which greatly varies in thickness ([Schroeder, 2012](#)) and shows a considerable plasticity. Its growth is generally much faster than that of acellular cementum, and some growth spurts may occur over short periods of time, in a more or less discontinuous cyclic rhythm. This irregular growth enables cellular cementum to rapidly adapt its distribution and

compensate for events that threaten the function and vitality of the tooth (e.g., intensive mechanical solicitations, apical periodontitis) ([Bosshardt and Selvig, 1997](#)). Cellular cementum has several functions among which to maintain the tooth in its bony socket, to repair external root resorption and to protect the dental pulp ([Bosshardt, 2005](#), [Foster et al., 2007](#), [Ho et al., 2010](#), [Schroeder, 2012](#)). An animal study has shown the considerable plasticity of the complex tissue that is cementum, and its role in pulp regeneration procedures. In a study focusing on dogs, scholars have showed the occurrence of true dentine-cementum bridges after apexification therapy (e.g., [Palma et al., 2017](#)).

Under certain conditions, cellular cementum production becomes excessive, beyond the normal threshold and modifying the natural root morphology (e.g., [Le Cabec et al., 2013](#)). When its growth exceeds the physiological limit that allows it to accomplish its normal functions, the term hypercementosis is used ([Fig. 1](#); [Pinheiro et al., 2008](#); [Consolaro et al., 2012](#)). Hypercementosis has been described in contemporary populations (e.g., [Kim et al., 1991](#)) but also in populations of the past (e.g., [Martín-Torres et al., 2011](#)). However, the modalities of cementum apposition are not yet fully elucidated. Several aetiologies have been assumed and the underlying mechanisms remain unclear. In case of archaeological teeth, when authors do report hypercementosis, it is described at the root apex and is frequently interpreted in the frame of the ‘teeth-as-tools’ hypothesis ([Brace, 1962](#), [Kobi, 1956](#), [Wallace et al., 1975](#)) as a physiological and compensatory response to the biomechanical environment of the tooth (e.g., [Consolaro et al., 2012](#); [Le Cabec et al., 2013](#)). The use of teeth for non-dietary purposes has been frequently described in ethnological or archaeological studies (e.g., [Molnar et al., 1972](#); [Pedersen, 1949](#); [Clement et al., 2012](#)). The oldest traces of these activities have been found in the teeth of specimens belonging to the *Homo* genus ([Margvelashvili et al., 2016](#), [Ungar et al., 2001](#)) and most frequently in the Neanderthal lineage (e.g., [Trinkaus, 1983](#); [Estalrich et al., 2017](#), [Spencer and Demes, 1993](#)). The ‘teeth-as-tools’ hypothesis was coined by [Brace \(1962\)](#) and states that Neanderthals were using their anterior teeth as a third hand for non- or para-masticatory activities ([Brace, 1962](#), [Kobi, 1956](#), [Wallace et al., 1975](#)). Several studies have proposed a positive correlation between intensive and repetitive masticatory efforts, and hypercementosis in light of para- and non-masticatory behaviour (e.g., [Martín-Torres et al., 2011](#); [Le Cabec et al., 2013](#); [Garralda et al., 2020](#)). However, these manifestations are not only found in contexts of heavy wear or para-masticatory activities. Some authors describe extensive cementum apposition on the root of carious teeth (e.g., [Tillier et al., 1995](#); [Trinkaus and Pinilla, 2009](#)). Others mention factors related to periodontal disease ([Tillier et al., 1989](#); [García-González et al., 2019](#)).

An isolated left mandibular canine (canine Xb Z8, Grotte du Renne, Arcy-Sur-Cure, France) showing no evidence of occlusal or proximal wear, led the authors to suggest that this canine was impacted. This tooth has a significant amount of hypercementosis covering almost its entire root (Bailey and Hublin, 2006, Leroi-Gourhan, 1961). In cases of contemporary unworn teeth, clinical case reports have also described the presence of hypercementosis (e.g., Kim et al., 1991; Elsayed et al., 2019). Some authors interpret hypercementosis, especially when it affects a large surface area of the root, as resulting from a local factor, such as a local periodontal disease; (e.g., Zhou et al., 2012) or a concrescence (e.g., Neves et al., 2014). Concrecence, especially in this context of hypercementosis, involves the union of two adjacent tooth roots by an abnormal growth of cementum. This phenomenon may occur during or after root formation and its precise aetiology remains unknown. Among possible hypotheses, concrecence may result from a trauma or from crowding of adjacent teeth, such that the interdental bone resorbs, thus favouring the deposition of cementum between adjacent tooth roots and at their contact. Localised hypercementosis may also be a response to an inflammatory condition (e.g., Sugiyama et al., 2007). Other scholars even interpret hypercementosis as a pathological manifestation potentially involving more general factors, such as systemic disorders in which all teeth are affected, for instance in Paget's disease (e.g., Rao & Karasick, 1982). Paget's disease is an osteopathic deformity first described by Sir James Paget in 1876 (cited in Ellis, 2013). It is characterised by an intense and anarchic bone remodelling primarily occurring in the spine, pelvis, femura and skull (Kravets, 2018).

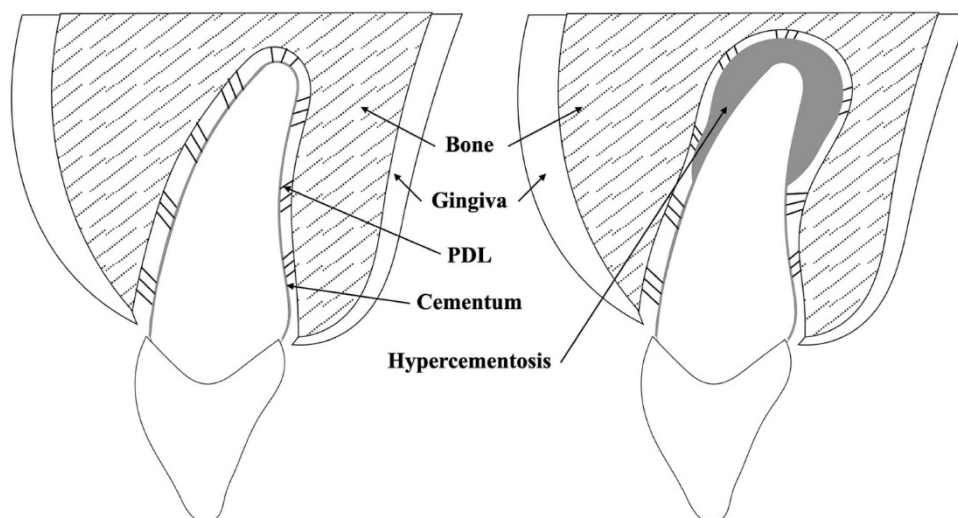


Fig. 1. Schematic representation of the anatomy of an upper incisor and its supporting structure (PDL: periodontal ligament), in a normal physiological condition (left), and in case of hypercementosis (right).

Considering these observations, high and/or frequent mechanical stresses invoked in the ‘teeth-as-tools’ hypothesis may not be the only cause inducing hypercementosis. There appears to be different forms of hypercementosis, which, in addition, may not be limited to the root apex. Within an individual’s dentition, hypercementosis may either concern a single tooth ([Sugiyama et al., 2007](#)) or may be generalised, and thus affect all teeth ([Arendt et al., 1989](#)). Regarding its distribution onto the tooth root surface, hypercementosis can be qualified as ‘diffuse’ when a large portion of the root is covered, or as ‘focal’ when the apposition is tightly localised and delimited ([Schroeder, 1986](#); [d’Incau et al., 2015](#)). If hypercementosis is sometimes described as a physiological phenomenon ([Le Cabec et al., 2013](#), [Martín-Torres et al., 2011](#)), some authors may conversely interpret it as a pathological manifestation ([Rao & Karasick, 1982](#)).

1.2. Rationale

Hypercementosis is thus not yet fully understood. In many instances, the term ‘hypercementosis’ is used without being properly defined (e.g., [Comuzzie & Steele, 1989](#), [Trinkaus et al., 2008](#), [Bailey & Hublin, 2006](#)), or without a consensus framework as attested by some studies providing variable or even contradictory information about its definition, variability, aetiology, or frequency (e.g., [Comuzzie & Steele, 1989](#); [Consolaro et al., 2012](#)). The terms ‘exostosis’, ‘hyperostosis’ or ‘excementosis’ have also been found in the literature (e.g., [Gardner & Goldstein, 1931](#)). This ambiguity surrounding the definition and characterisation of hypercementosis (e.g., diffuse versus focal form, location) leads to ask the following research questions: May hypercementosis be related to a single aetiology or be caused by multiple factors? Does it involve different patterns of apposition (e.g., location, extent)? Should it be considered as a physiological or pathological manifestation?

1.3. Objectives

In light of this, we undertook a systematic review to provide a better overview about the current understanding of potential aetiologies of hypercementosis. The aims were to (1) collect published definitions of hypercementosis, as well as descriptions of its different manifestations and (2) propose hypotheses regarding its possible aetiologies.

2. Materials and methods

The systematic review followed the guidelines of Preferred Reporting Items for Systematic Reviews and Meta-Analyses (PRISMA) checklist ([Moher et al., 2009](#)) was followed both in

the planning and reporting of the review.

2.1. Eligibility criteria

Our literature review included cohort studies, case control studies, cross-sectional studies, and studies comprising human teeth affected by hypercementosis, for which an association between hypercementosis and aetiological factors was proposed. Systematic reviews or meta-analyses, as well as studies using animal models were excluded. No limitation in age constrained the selection of studies involving participants with hypercementosis. Articles in all languages were included and appropriate translations were used.

2.2. Search strategy

In this review, the SPIDER tool ([Cooke et al., 2012](#)) was used to appropriately address our qualitative research according to the following criteria: S (human teeth), P of I (hypercementosis, cementum exostosis, cementum hyperostosis, excessive cementum apposition), D (contemporary case study, archaeological observation or report), E (presence of hypercementosis, description of hypercementosis, aetiologies of hypercementosis), R (cohort studies, case control studies, cross-sectional studies, and studies comprising human teeth affected by hypercementosis). The search strategy was developed by the research team and included the following terms: '(hypercementosis OR (exostosis AND cement*) OR (hyperostosis AND cement*) OR excementosis OR (excessive AND apposition AND cement*))'. The initial search was completed in September 2021, using four electronic databases, which are Medline via PubMed, DOSS via EBSCO, Scopus and the Cochrane Library. The electronic search was complemented by browsing the reference lists of the included studies. If there were multiple studies based on the same sample, only the study which reports the most detailed data was included. To collect these data, a reference management software was used (Zotero 5.0.96.2, GMU, Virginia, USA).

2.3. Study selection

Identified duplicate studies were removed. Titles and abstracts of identified studies were screened by two authors, with any disagreement resolved by consensus or discussion with a third author. If necessary, any unresolved difference was resolved by a consensus agreement by all the authors. Full text was obtained for all titles that met these criteria (e.g., misdiagnosis, no hypercementosis, animal study). Two authors assessed the full texts against the inclusion/exclusion criteria independently, with any disagreement resolved by consensus agreement among all authors.

2.4. Data extraction

Data extraction was performed using spreadsheets (Excel version 2019, Microsoft©, CA, USA) by two authors, with any disagreement resolved following discussion with a third author, and by consensus agreement among all authors. A standardised data extraction form was used to record the following details: study characteristics (i.e., author, publication year, title, study design, and setting), information from archaeological reports (i.e., geographic origin and dating), participant demographics for modern studies (i.e., country of residence and age), total number of individuals in the studied sample, total number of teeth with hypercementosis, method used for recording aetiological factors (e.g., X-ray radiography), investigated aetiological factors, whether a confirmed definition of hypercementosis was noted, or a description of hypercementosis and its location whenever possible.

3. Results

3.1. Studies selection

The article selection process is based on the PRISMA guidelines ([Fig. 2](#)). A total of 546 publications were first identified through searching of electronic databases. After removing duplicates, 289 papers were retained for title and abstract screening. Then, 121 publications underwent full text review after which, 55 remaining publications were finally included in the present review. A total of 80 full-text papers were excluded based on criteria such as misdiagnosis, animal study or absence of hypercementosis (See [Fig. 2](#)). Last, 20 additional studies were added via manual searching. A total of 75 publications were selected, which involve 29 case-reports, 28 archaeological publications, 11 case-control studies and seven cross-sectional studies, dealing with 46 samples from extant populations and 29 samples from archaeological collections or individuals. In these works, various imaging techniques were used, among which microscopy, X-Ray radiography, cone beam computed tomography (CBCT) and microtomography (μ CT), scanning electron microscopy (SEM), and transmission electron microscopy (TEM). The detailed results of this review are presented in [Supplementary Materials Table S1](#).

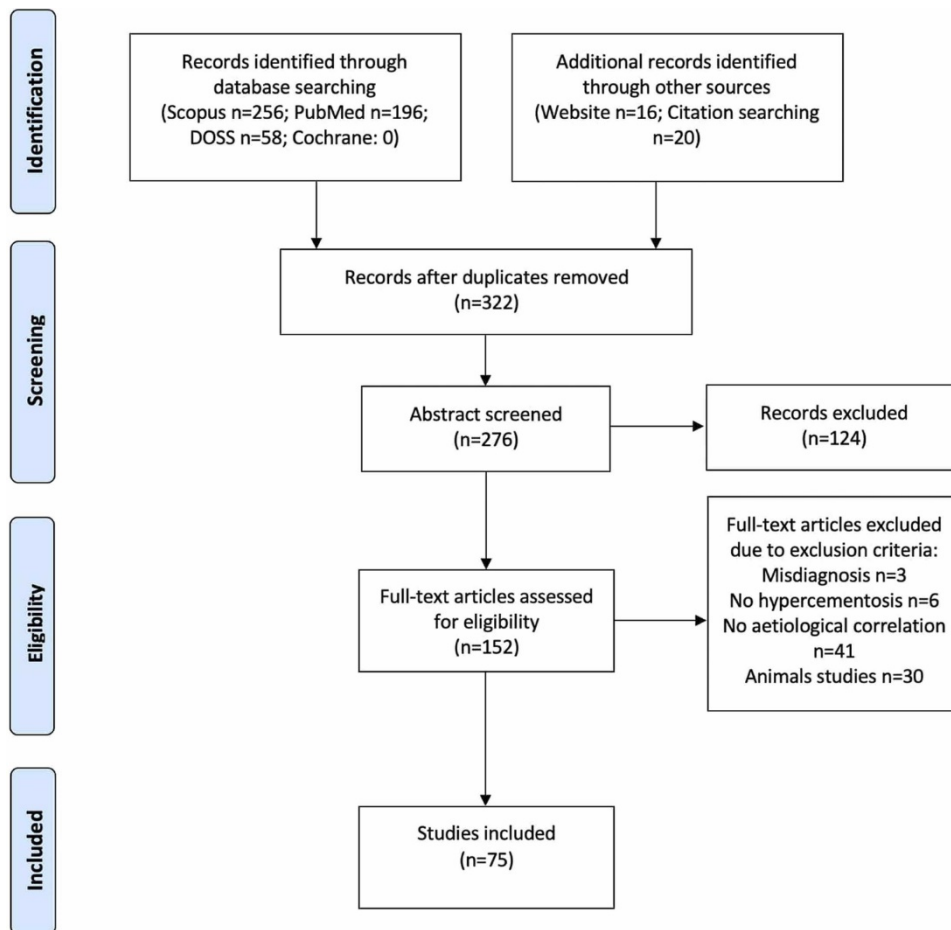


Fig. 2. PRISMA flow diagram of the systematic review which included searches of databases and other sources.

3.2. Definition of hypercementosis

Forty papers do not provide any definition of what they call ‘hypercementosis’. [Pinheiro et al. \(2008\)](#)’s definition is cited in six publications. They describe hypercementosis as an excessive cementum formation, beyond the physiological limits of the tooth. They further explain that the cementum may reach abnormal thickness on the root apex, which appears round in shape and/or with a macroscopic alteration of the root surface ([Pinheiro et al., 2008](#)). [Gardner and Goldstein \(1931\)](#) simply define hypercementosis as diffuse or well-delimited abnormal cementum, which may affect all the teeth or be localised on a single tooth ([Gardner & Goldstein, 1931](#)). The remaining 31 articles either do not cite their source or quote other publications, in which, after control, no formal definition of hypercementosis could be found.

3.3. Description of hypercementosis

The literature currently lacks a consensus on the description of hypercementosis. Some authors describe hypercementosis in qualitative terms, such as ‘bulbous’ (e.g., [Gardner & Goldstein, 1931](#); [Corruccini et al., 1982](#); [Rao & Karasick, 1982](#)), ‘club appearance’ (e.g., [Tillier et](#)

al., 1989) ‘dilatated aspect’ (e.g., [Antunes and Cunha, 1992](#)). Yet only a few of them clearly quantify the amount of hypercementosis (e.g., [Le Cabec et al., 2013](#)). Very few studies, mostly focusing on archaeological samples (e.g., [Trinkaus et al., 2008](#); [Scolan et al., 2012](#); [Le Cabec et al., 2013](#); [Margvelashvili et al., 2016](#)) describe the location and the extent of hypercementosis. For the latter, the notions of ‘diffuse’ vs. ‘focal’ are only rarely used.

3.4. Aetiologies of hypercementosis

Among these 75 publications, eight aetiological hypotheses have been identified ([Fig. 3](#)). Five types of local factors may induce hypercementosis, such as intensive and repetitive masticatory efforts (n = 20 publications; e.g., [Pedersen, 1949](#); [Comuzzie and Steele, 1989](#); [Le Cabec et al., 2013](#)), periodontal disease (n = 5 publications; e.g., [Corruccini et al., 1987](#); [Zhou et al., 2012](#)), impacted teeth (n = 7 publications; e.g., [Azaz et al., 1974](#); [Bailey & Hublin, 2006](#)), carious lesion and apical periodontitis (n = 18 publications; e.g., [Lai et al., 2019](#)), concrescence (n = 3 publications; e.g., [Neves et al., 2014](#)). Only a single study supports the possible correlation between bisphosphonates and hypercementosis ([de Camargo Moraes et al., 2015](#)). [Kim et al. \(1991\)](#) are the only ones to suggest a correlation between hypercementosis and tooth super-eruption. Last, five publications argue for combined causes (e.g., periodontal disease and para-masticatory activities, e.g., [Garralda et al., 2004](#)). Among the papers concerned, some more general causes were identified and classified as systemic diseases (n = 18 publications), among which, Paget's disease (e.g., [Lucas, 1955](#); [Polisetti et al., 2014](#)), Gardner's syndrome (e.g., [Arendt et al., 1989](#)), acromegalia (e.g., [Gardner & Goldstein, 1931](#)), arthritis (e.g., [Leider and Garbarino, 1987](#)) and hyperthyroidism (e.g., [Kupfer, 1951](#)).

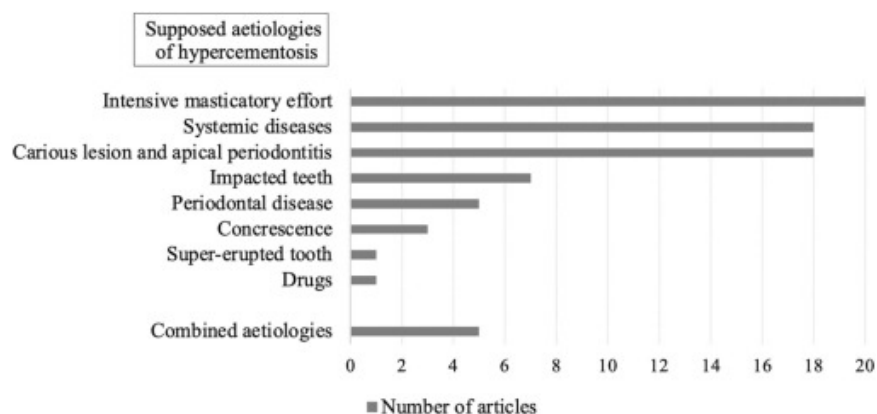

Fig. 3. Overview of the different aetiologies of hypercementosis and number of associated publications as highlighted by the systematic review.

4. Discussion

This systematic review has enabled to explore the variety of descriptions, terminology and aetiologies of hypercementosis. As it is already well-known yet little taken into account in hypercementosis studies, there are different types of cementum apposition and location. Based on the existing descriptions of hypercementosis, we could classify the putative aetiologies within six major groups, which are systemic diseases, intensive masticatory effort, impacted teeth, carious and apical abscess, periodontal disease, and combined causes. We propose a new qualitative scoring system to improve the description of the manifestations of hypercementosis.

4.1. The challenge of defining and characterising hypercementosis

Our systematic review highlighted that hypercementosis is not always clearly defined in the literature, if at all, and when it is, there is no consensus on its description or on the terminology to use. This may actually be due to the challenging understanding of cementum formation and aetiology. Several types of cementum have been identified with different biological roles. If we distinguish them by the presence or absence of cells in their matrix, we can differentiate between acellular cementum whose role is to ensure the attachment of the tooth to its bony alveolus, and cellular cementum which has an adaptive role and whose production is excessive in the case of hypercementosis ([Tang et al., 2015](#)). The origin, structure and methods of observation of these tissues differ and unlike enamel and dentine, the cellular and molecular mechanisms responsible for their genesis and repair are not yet fully elucidated (e.g., [Foster & Somerman, 2012](#)). Although, age is a parameter reported as modulating cementum apposition (e.g., [Azaz et al., 1974](#)), it does not seem to be able to induce alone a hypertrophic growth of cementum. In the papers included in this systematic review, the definition of hypercementosis appears always subjective and not based on any statistically validated criteria. However, the notion of excessive production is always mentioned using terms such as ‘hypertrophic’ (e.g., [Le Cabec et al., 2013](#)), ‘hyperplasia’ (e.g., [Gottlieb and Orban, 1931](#)), ‘excessive deposition’ (e.g., [Dobhal et al., 2018](#)). Authors agree on several points and especially the notion of abnormality (e.g., ‘abnormal’, ‘irregular’ see e.g., [Lacy et al., 2012](#)) although the term ‘pathology’ is barely used. [Garralda et al. \(2004\)](#) consider that hypercementosis is a normal process which is not considered as a pathology. However, in Paget's disease, hypercementosis is described as diffuse and generalised, with a specific histological aspect (e.g., [Lucas, 1955](#); [Rao & Karasick, 1982](#)). This is the exception in which the authors support the notion of ‘pathological hyperce-

mentosis'. The strongest point made by these works, is that in systemic diseases hypercementosis is generalised to the whole dentition, whereas, in contrast, in non-pathological cases, hypercementosis only manifests locally. Some of the aetiologies mentioned in these cases could be infection or apical periodontitis related to carious lesion and/or wear, local periodontal disease or concretion. There are also local factors related to the oral environment (e.g., intensive masticatory effort) and oro-facial growth process (e.g., impaction or super-eruption). Super-eruption is a process in which a tooth, which has lost its antagonist tooth, continues its migration into the oral cavity (i.e., eruption) beyond the occlusal plane. As a consequence, the gum line of this super-erupted tooth is no longer aligned with that of the neighbouring teeth and its crown stands out beyond the occlusal plane of the jaw. The respective influence of each of these factors has rarely been studied in contemporary humans or individuals from past populations.

There is no consensus on the description of hypercementosis, whether localised on a tooth or generalised to the whole dentition, this description differs from one author to another, and the classification of the different forms of hypercementosis is far from being unanimous. There are only a few classifications of the types of hypercementosis, only very rarely reported in the literature (but see [Kim et al., 1991](#); [Pinheiro et al., 2008](#); [d'Incau et al., 2015](#)). To date, no classification takes into account the morphological variability of hypercementosis, and none of them is statistically validated. Only [Kim et al. \(1991\)](#)'s classification is discussed in this review since it is the only one proposing a correlation between the manifestations of hypercementosis and its potential aetiologies. Yet, a drawback in his scoring system is that [Kim et al. \(1991\)](#) only investigated hypercementosis by means of macroscopic observation after tooth extraction or using 2D X-ray, which methods do not take into account the 3D morphological variability of the roots, neither how this may impact the observation of cementum apposition. In addition, hypercementotic teeth are characterised by specific anatomical changes that are directly resulting from or alternatively impacting dental treatment. Some of these are related to the thickness of hyperplastic cementum, others are related to the size and number of apical foramina and have rarely been studied (e.g., [Pinheiro et al., 2008](#)).

4.2. Proposing a new scoring system to better describe hypercementosis

There are different types of cementum apposition and location. Based on the existing descriptions of hypercementosis, we can identify several conditions and propose a new qualitative scoring method ([Fig. 4](#)). First, three types of hypercementosis may be defined based on the extent and morphology of cementum of apposition: 'Type 1' concerns a diffuse apposition of cellular cementum always involving a large portion of the height and circumference of the tooth

root, within various extents; ‘Type 2’ describes a focal cementum apposition restricted to a precise and delimited area on the root; and finally ‘Type 3’ combines the cementum apposition described in both Type 1 and Type 2. Second, the location of cementum apposition, whether it is localised and focal or diffuse and covers a large surface area of the root, may vary along the root length. This can serve defining the following four stages: in ‘Stage 1’ the cementum apposition is restricted to the apical root third; ‘Stage 2’ concerns the middle root third; ‘Stage 3’ concerns the cervical root third while ‘Stage 4’ will be attributed to a tooth for which the cemento-enamel junction cannot be defined (e.g., broken crown, important carious lesion). Note that for the type and stage of cementum deposition, only numerals will be used in the scoring system. Third, and last, hypercementosis may also be characterised by different thickness or extent of formation: in a moderate form, the cementum apposition is thin to medium in thickness, and will be scored ‘m’, while in a marked form, the cementum deposited is much thicker, and will be scored ‘M’. This scoring system proved to be helpful as a guideline to describe the different appositions found in different aetiological conditions reported in the published papers considered in the present systematic review. Thus, with this protocol, hypercementosis will be scored according to the following formula ‘type.stage.form’ (see [Supplementary Materials Table S1](#)). In the case of aetiological factors involving a general condition and especially systemic diseases or syndromes (e.g., Gardner's syndrome, hyperthyroidism, acromegalia, Paget's disease), the pattern of cementum apposition was consistently diffuse and marked covering the tooth root from the apex until the middle or the cervical third (e.g., [Rao & Karasick, 1982](#)), thus leading to a score of ‘1.2–3.M’.

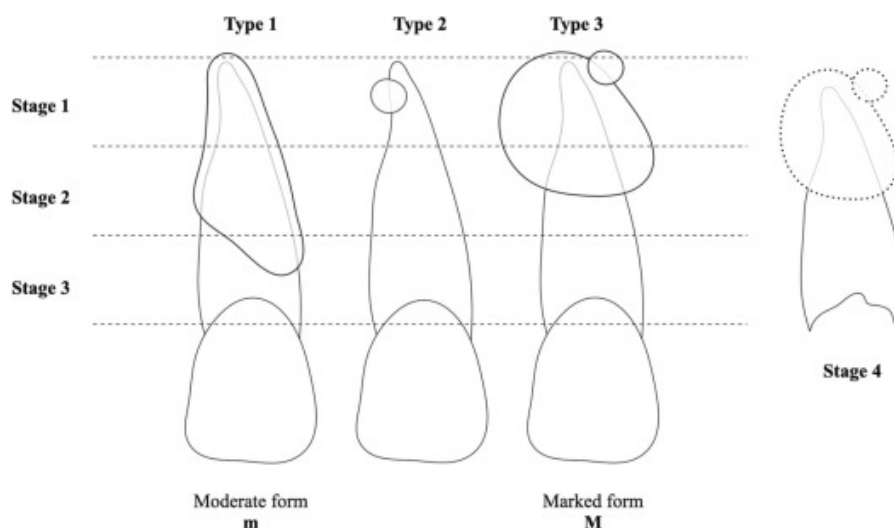


Fig. 4. New hypercementosis scoring method according to the following formula “type.stage.form”. Type 1: diffuse type (cellular cementum apposition covering on a variously broad height and circumference of the root); Type 2: focal or local type (cementum apposition restricted to a precise point of the root); and Type 3: is combination of Type 1 and Type 2. Cementum apposition may be focal (localised) or diffuse and cover the apical root third (Stage 1), the middle root third (Stage 2), or the cervical root third (Stage 3). Stage 4 will be attributed when a

tooth has a partially or fully damaged cemento-enamel junction. Forms are defined by visual estimation of the cementum thickness in regards to the natural shape of the root: moderate form (apposition of small to medium thickness, noted “m”) or marked form (apposition of significant thickness, noted “M”).

4.3. Application of this new scoring system to the eight identified aetiologies for hypercementosis

Most studies or case reports mention a generalised affection of all the teeth within one of the dental arch, with a greater extent on the roots in the post-canine region (e.g., [Venkatesh et al., 2011](#); [Polisetti et al., 2014](#)). However, Paget's disease can be differentiated from other systemic diseases because of the associated specific aspect of hypercementosis under histological investigation. The complete absence of periodontal membrane and lamina dura is only described in Paget's disease, inducing a fusion of the cementum with the alveolar bone, thus forming an ankylosis (e.g., [Lucas, 1955](#)). In these cases, the authors support the notion of ‘pathological hypercementosis’ (e.g., [Rao & Karasick, 1982](#)). In the presence of marked and generalised hypercementosis, Paget's disease or more broadly a systemic disease should be suspected and further investigated by a deeper diagnosis which may involve other physiological parameters.

In addition to systemic pathologies, specific local oral conditions are considered as aetiological factors for hypercementosis, and different patterns of apposition have been identified. When the aetiological factor proposed was the intensive masticatory efforts, hypercementosis mostly scores as ‘1.1.m’ (pers. obs., and see e.g., [Le Cabec et al., 2013](#)). [Gottlieb and Orban \(1931\)](#) described a contemporary case of a 55-year-old man who regularly smoked the pipe and which resulted in forming a pipe hole over time on his front lower teeth. The load of the pipe was born by the lower lateral incisor, which, according to [Gottlieb and Orban \(1931\)](#) resulted in ‘hyperplasias of cementum’ on both the root apex of this lateral incisor and on the root of the neighbouring teeth. In case of archaeological teeth, the cementum accumulation was also reported to be preferentially apical (e.g., [Couture & Tournepiche, 1997](#); [Le Cabec et al., 2013](#)). In the case of biomechanical stimulation, cementum apposition is mostly located at the root apex, with, in some instances, the description of a preferential side. Cementum mostly accumulates on the lingual side of the root (e.g., [Margvelashvili et al., 2016](#); [Le Cabec et al., 2013](#)), and is often absent on the buccal side of the tooth root (e.g., [Trinkaus et al., 2008](#)). In their large sample of Neanderthal teeth, [Le Cabec et al. \(2013\)](#) showed that cementum apposition is also preferential, with an apico-lingual location on maxillary incisors. Cementum apposition seems to correlate with wear, both in amount and location of deposition. [Garralda and Vandermeersch \(2000\)](#) describe that, in Neanderthal teeth, cementum accumulates in a pattern mirroring the worn occlusal edge of the anterior teeth under study. According to the ‘teeth-as-tools’ hypothesis, Neanderthals were using their front teeth as a third hand for para-masticatory activities

([Brace, 1962](#), [Kobi, 1956](#), [Wallace et al., 1975](#)). For instance, they may have hold a piece of meat by one end with one hand, and fastening it by the other end between their anterior teeth, while the other hand makes use of a stone tool to cut off a piece of meat compatible in size with a mouthful. The repeated pulling movements onto the occlusal surface of their front teeth would be related to a lever arm which centre would be located between the cervical and middle root thirds in a single-rooted tooth ([Kronfeld, 1931](#); [Mühlemann and Zander, 1954](#); [Smith & Burstone, 1984](#); [Kupczik, 2003](#)). In the case of incisors, the load is exerted in the buccal direction, therefore the buccal aspect of the root section cervical to the level arm will be put under compression whereas its lingual counterpart will be subjected to tensile stress. Apically to the level arm the situation is reversed ([Fig. 5](#)): the buccal aspect of the root is subjected to tension (i.e., the apex would pull on its periodontal attachment) while the lingual part is under compression (i.e., the apex would be pushed against its periodontium). In terms of cementum activity on the dental root, compression may stimulate cementum formation, while tension is characterised by traction exerted on the periodontal ligament fibres ([Beck and Harris, 1994](#), [Kupczik, 2003](#)). [Le Cabec et al. \(2013\)](#) hypothesised that cementum apposition would be more abundant in areas of compression. [Gottlieb and Orban \(1931\)](#)'s observations support this scenario, and this would as well be the case for an occlusal trauma. In extreme cases of loading on anterior teeth, [Pedersen \(1949\)](#) hypothesised that the formation of hypercementosis may be a mechanism to compensate for root dentine resorption.

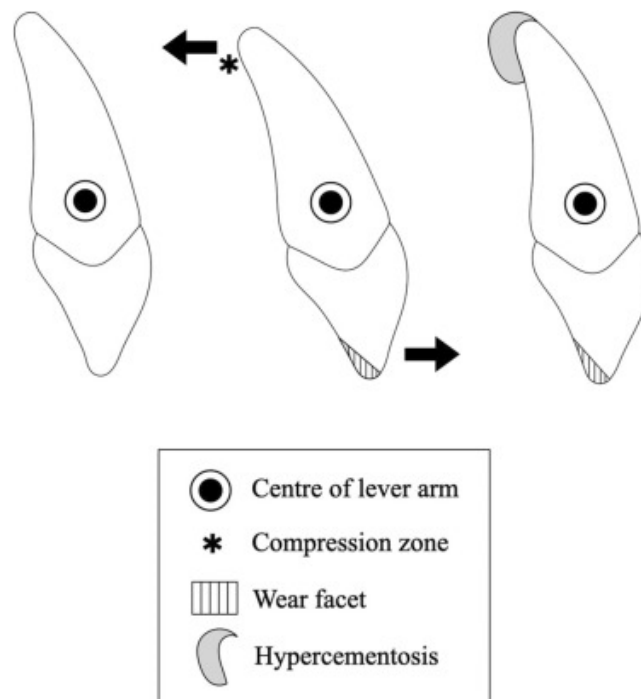


Fig. 5. Schematic representation of cementum apposition in cases of intensive masticatory effort, according to the teeth-as-tools theory. Cementum is apposed at the apex and in the lingual area.

In the case of impacted teeth, hypercementosis covers the entire tooth root surface, yet with a moderate apposition scored at '1.3.m'. Cementum apposition on retained teeth has been described in the literature and the first aetiological factor to explain the observed cementum apposition suggested was age ([Azaz et al., 1977](#)). However, the histological sections performed by [Zemsky \(1931\)](#) showed a preferential cementum apposition, with a noticeable surface irregularity. These observations seem to contradict the idea that an impacted tooth is passive and forms a homogeneously-thick cementum cap along its root length and around its root axis. Since impacted teeth display a normal periodontium, a normal eruption would be to be expected for these teeth. This eruption process is however hindered either because of a malposition of the tooth or because of the presence of an obstacle on its eruption path. This is what [Azaz et al. \(1974\)](#) defend when they refer to continuous impaired eruptive forces which may act as an appositional stimulating factor. We propose that eruption events would exert forces on the periodontal ligament. Compression zones would occur locally on the root (obstructed eruption) and result in irregular apposition which would constitute a reactive response.

Concerning carious lesions and apical abscess, the patterns were different: sometimes marked and diffuse on the whole root (e.g., [Sugiyama et al., 2007](#)) or moderate and covering the root from the apical to the middle root third (e.g., [Pinheiro et al., 2013](#)) or even restricted to localised focal manifestations called 'pearls of cementum' (e.g., [Kohli et al., 2011](#); [Kohli et al., 2013](#)). These differences can perhaps be related to the stage of lesion of the dental pulp. Some external factors (e.g., carious lesion) may lead to the destruction of the surrounding hard tissues protecting the pulp from external aggressions. In this case, the pulp is directly exposed to exogenous irritants. Bacteria are the most common cause of pulp reaction and induce an inflammation called pulpitis. If the inflammation persists and becomes irreversible, this leads to pulp necrosis, which in turn induces inflammatory lesions to the periradicular periodontium (i.e., apical periodontitis; [Piette and Goldberg, 2001](#)). One may therefore speculate on a gradation involving different stages of cementum apposition with, first, moderate forms of hypercementosis as a compensatory reaction to pulpal inflammation (e.g., [Pinheiro et al., 2013](#)), and at a further advanced stage, marked forms of hypercementosis resulting from a compensatory reaction to periapical inflammation or infection (e.g., [Nouman et al., 2015](#)). The type of cementum apposition found in contemporary cases such as those described in [Sarkotić and Šutalo \(1987\)](#) strongly parallels the type of hypercementosis observed in the Neanderthal maxillary incisor KMH27 (Kebara Cave, Israel - 60 ky B.P.; [Chech et al., 2003](#)), which shows extensive decay, and a substantial apposition of cementum on its apical root half ([Tillier et al., 1989](#)). Since KMH27 is affected by a carious lesion ([Tillier et al., 1989](#)), KMH27 most likely exhibits a

significantly different cementum apposition pattern than that described in the large sample of Neanderthal teeth studied by [Le Cabec et al. \(2013\)](#) and would therefore be characteristic of the condition involving a carious lesion.

In the cases of periodontal disease, the published papers retained in this review concerned premolars and molars. Periodontal disease has an infectious origin characterised by bone loss and affects the alveolar bone, periodontal ligament, and cementum (e.g., [Zhou et al., 2012](#)). The pattern of hypercementosis was mostly scored respectively '1.2.M' and '1.3.M', rather marked and diffuse, covering large parts of the root ([Brooks et al., 2020](#), [Corruccini et al., 1987](#)). The damage may be restricted to a single tooth or extended over several teeth.

Last, we also classified combined causes group in which different local factors may be responsible for hypercementosis and could occur in succession over time on the same tooth. They can induce different forms of cementum apposition and the most recent apposition can conceal the previous events of cementum deposition in some cases.

These aetiologies of hypercementosis and their different manifestations are therefore various in nature and extent; they however often remain at best only very superficially referred to in the main body of the studies under consideration in this systematic review. Most importantly, when publications mention hypercementosis, only very few take into consideration the inner root morphology involving the dentine and the pulp cavity (but see e.g., [Le Cabec et al., 2013](#)). Our scoring method can help to quickly characterise hypercementosis and suspect its aetiology. However, the notion of thickness as moderate or marked manifestation is very delicate to handle if there is no detailed information on the internal root morphology (i.e., high resolution computed tomography and 3D images). These observations would justify a 3D analysis comparing cementum apposition patterns of several teeth for which an aetiology is suspected. These apposition patterns specific to each suspected aetiology could then be tested.

5. Conclusion

This review has highlighted that hypercementosis is a complex and not well-defined condition. Based on the information gathered, we can define hypercementosis as an excessive production of cellular cementum, exceeding the normal threshold and modifying the natural morphology of the tooth root. The most common form of hypercementosis will concern a diffuse apposition of cementum and cover a large part of the tooth root, while the focal form is much less frequent and is strictly localised to a specific area of the root; a combination of both forms may be encountered. Hypertrophic cementum deposition may involve only the apical root third or extend up to the middle or cervical root third. Finally, it can slightly modify the root morphology and

have a moderate form or modify it significantly and have a marked form. It is a physiological phenomenon with the exception of that demonstrated in cases of Paget's disease. Several aetiologies are possible, but its manifestations will differ and may reflect the main factors involved. A diffuse, marked and generalised hypercementosis in all the teeth of an individual should prompt the suspicion of a systemic disease or of a syndrome. If this general pathology is ruled out, periodontal disease may be considered. A diffuse, moderate apposition preferentially located at the root apex of anterior teeth may be indicative of para-masticatory activity or occlusal trauma. A diffuse and moderate apposition involving the entire surface of the root can evoke an impaction. Any diffuse and marked apposition may be indicative of an inflammatory or infectious etiological factor. Hypercementosis is a compensatory phenomenon in different conditions, which can be a witness of masticatory or non-masticatory activity and oral health. The tooth and its periodontium evolve during the life of an individual and may encounter several aetiological factors that may result in unclassifiable patterns. A quantitative study could validate or invalidate these apposition patterns specific to a given presumed aetiology. In addition, a re-examination of archaeological collections could provide new information about the life and the use of the teeth of these individuals.

CRedit authorship contribution statement

Léa Massé: Conceptualization, Methodology, Validation, Formal analysis, Investigation, Writing – original draft, Visualization, Funding acquisition. **Elsa Garot:** Investigation, Writing – review & editing. **Bruno Maureille:** Writing – review & editing, Supervision, Resources. **Ade-line Le Cabec:** Conceptualization, Methodology, Investigation, Data Curation, Writing – review & editing, Supervision, Resources, Project administration, Funding acquisition.

Acknowledgements

This research benefited from the scientific framework of the University of Bordeaux's IdEx 'Investments for the Future' program / GPR 'Human Past'.

Appendix A. Supplementary material

(see at the end of this document, p. 35)

References

[Antunes and Cunha, 1992](#)

M.T. Antunes, A.S. Cunha

Neanderthalian remains from Figueira Brava cave, Portugal

Geobios, 25 (5) (1992), pp. 681-692, [10.1016/0016-6995\(92\)80108-P](https://doi.org/10.1016/0016-6995(92)80108-P)

[Article](#)

[Download PDFView Record in ScopusGoogle Scholar](#)

[Arendt et al., 1989](#)

D.M. Arendt, R. Frost, J.C. Whitt, J. Palomboro

Multiple radiopaque masses in the jaws

Journal of the American Dental Association (1939), 118 (3) (1989), pp. 349-351,

[10.14219/jada.archive.1989.0102](https://doi.org/10.14219/jada.archive.1989.0102)

[Article](#)

[Download PDFView Record in ScopusGoogle Scholar](#)

[Azaz et al., 1977](#)

B. Azaz, Y. Michaeli, D. Nitzan

Aging of tissues of the roots of nonfunctional human teeth (impacted canines

Oral Surgery, Oral Medicine, and Oral Pathology, 43 (4) (1977), pp. 572-578,

[10.1016/0030-4220\(77\)90110-4](https://doi.org/10.1016/0030-4220(77)90110-4)

[Article](#)

[Download PDFView Record in ScopusGoogle Scholar](#)

[Azaz et al., 1974](#)

B. Azaz, M. Ulmansky, R. Moshev, J. Sela

Correlation between age and thickness of cementum in impacted teeth

Oral Surgery, Oral Medicine, and Oral Pathology, 38 (5) (1974), pp. 691-694,

[10.1016/0030-4220\(74\)90386-7](https://doi.org/10.1016/0030-4220(74)90386-7)

[Article](#)

[Download PDFView Record in ScopusGoogle Scholar](#)

[Bailey and Hublin, 2006](#)

S.E. Bailey, J.J. Hublin

Dental remains from the Grotte du Renne at Arcy-sur-Cure (Yonne

Journal of Human Evolution, 50 (5) (2006), pp. 485-508,

[10.1016/j.jhevol.2005.11.008](https://doi.org/10.1016/j.jhevol.2005.11.008)

[Article](#)

[Download PDFView Record in ScopusGoogle Scholar](#)

[Beck and Harris, 1994](#)

B.W. Beck, E.F. Harris

Apical root resorption in orthodontically treated subjects: analysis of edgewise and light wire mechanics

American Journal of Orthodontics and Dentofacial Orthopedics, 105 (4) (1994), pp. 350-361, [10.1016/S0889-5406\(94\)70129-6](https://doi.org/10.1016/S0889-5406(94)70129-6)

[Article](#)

[Download PDFView Record in ScopusGoogle Scholar](#)

[Bosshardt, 2005](#)

D.D. Bosshardt

Are cementoblasts a subpopulation of osteoblasts or a unique phenotype

Journal of Dental Research, 84 (5) (2005), pp. 390-406, [10.1177/154405910508400501](https://doi.org/10.1177/154405910508400501)

[View Record in ScopusGoogle Scholar](#)

[Bosshardt and Selvig, 1997](#)

D.D. Bosshardt, K.A. Selvig

Dental cementum: the dynamic tissue covering of the root

Periodontology 2000, 13 (1997), pp. 41-75, [10.1111/j.1600-0757.1997.tb00095.x](https://doi.org/10.1111/j.1600-0757.1997.tb00095.x)

[View Record in ScopusGoogle Scholar](#)

[Brace, 1962](#)

C.L. Brace

Cultural factors in the evolution of the human dentition

M.F.A. Montagu (Ed.), Culture and the Evolution of Man, Oxford University Press, New York (1962), pp. 343-354

[View Record in ScopusGoogle Scholar](#)

[Brooks et al., 2020](#)

J.K. Brooks, E. Kim, L.T. Tran, C.A. Vieira, J.B. Price

Odontoma associated with mandibular transmigrated canine in a geriatric patient: Second case report

Gerodontology, 37 (4) (2020), pp. 411-415, [10.1111/ger.12495](https://doi.org/10.1111/ger.12495)

[View Record in ScopusGoogle Scholar](#)

[Chech et al., 2003](#)

M. Chech, B. Vandermeersch, B. Arensburg, A.M. Tillier

New human remains from Kebara Cave (Mount Carmel). The place of the Kebara hominids in the Levantine Mousterian fossil record

Paléorient, 29 (2003), pp. 35-62

[CrossRefGoogle Scholar](#)

[Clement et al., 2012](#)

A.F. Clement, S.W. Hillson, L.C. Aiello

Tooth wear, Neanderthal facial morphology and the anterior dental loading hypothesis

Journal of Human Evolution, 62 (3) (2012), pp. 367-376,

[10.1016/j.jhevol.2011.11.014](#)

[Article](#)

[Download PDFView Record in ScopusGoogle Scholar](#)

[Comuzzie and Steele, 1989](#)

A.G. Comuzzie, D.G. Steele

Enlarged occlusal surfaces on first molars due to severe attrition and hypercementosis: Examples from prehistoric coastal populations of Texas

American Journal of Physical Anthropology, 78 (1) (1989), pp. 9-15,

[10.1002/ajpa.1330780104](#)

[View Record in ScopusGoogle Scholar](#)

[Consolaro et al., 2012](#)

A. Consolaro, R.B. Consolaro, L.A. Francischone

Cementum, apical morphology and hypercementosis: a probable adaptive response of the periodontal support tissues and potential orthodontic implications

Dental Press Journal of Orthodontics, 17 (1) (2012), pp. 21-30, [10.1590/S2176-](#)

[94512012000100003](#)

[View Record in ScopusGoogle Scholar](#)

[Cooke et al., 2012](#)

A. Cooke, D. Smith, A. Booth

Beyond PICO: The SPIDER tool for qualitative evidence synthesis

Qualitative Health Research, 22 (10) (2012), pp. 1435-1443,

[10.1177/1049732312452938](#)

[View Record in ScopusGoogle Scholar](#)

[Corruccini et al., 1982](#)

R.S. Corruccini, J.S. Handler, R.J. Mutaw, F.W. Lange

Osteology of a slave burial population from Barbados, West Indies

American Journal of Physical Anthropology, 59 (4) (1982), pp. 443-459,

[10.1002/ajpa.1330590414](https://doi.org/10.1002/ajpa.1330590414)

[View Record in ScopusGoogle Scholar](#)

[Corruccini et al., 1987](#)

R.S. Corruccini, K.P. Jacobi, J.S. Handler, A.C. Aufderheide

Implications of tooth root hypercementosis in a Barbados slave skeletal collection

American Journal of Physical Anthropology, 74 (2) (1987), pp. 179-184,

[10.1002/ajpa.1330740206](https://doi.org/10.1002/ajpa.1330740206)

[View Record in ScopusGoogle Scholar](#)

[Couture and Tournepiche, 1997](#)

C. Couture, J.F. Tournepiche

Les restes humains de la grotte de Rochelot (Charente)

Anthropologie et Préhistoire, 108 (1997), pp. 99-108

[View Record in ScopusGoogle Scholar](#)

[d'Incau et al., 2015](#)

E. d'Incau, C. Couture, N. Crépeau, F. Chenal, C. Beauval, V. Vanderstraete, B. Maureille

Determination and validation of criteria to define hypercementosis in two medieval samples from France (Sains-en-Gohelle, AD 7th-17th century; Jau-Dignac-et-Loirac, AD 7th-8th century)

Archives of Oral Biology, 60 (2) (2015), pp. 293-303, [10.1016/j.archoral-bio.2014.10.006](https://doi.org/10.1016/j.archoral-bio.2014.10.006)

[Article](#)

[Download PDFView Record in ScopusGoogle Scholar](#)

[de Camargo Moraes et al., 2015](#)

P. de Camargo Moraes, C.A. Silva, A.B. Soares, F. Passador-Santos, M.E. Corrêa, N.S. de Araújo, V.C. de Araújo

Tooth alterations in areas of bisphosphonate-induced osteonecrosis

Clinical Oral Investigations, 19 (2) (2015), pp. 489-495, [10.1007/s00784-014-1270-](https://doi.org/10.1007/s00784-014-1270-x)

[x](#)

[View Record in ScopusGoogle Scholar](#)

[Dobhal et al., 2018](#)

Y. Dobhal, S. Gupta, M. Srivastava, R. Mehta

Hypercementosis: A case report and review

Journal of PEARLDENT, 9 (1) (2018), pp. 8-11, [10.5958/2229-4457.2018.00002.8](#)

[View Record in ScopusGoogle Scholar](#)

[Ellis, 2013](#)

H. Ellis

Sir James Paget: Paget's disease of the nipple, Paget's disease of bone

Journal of perioperative Practice, 23 (4) (2013), pp. 91-92,

[10.1177/175045891302300406](#)

[View Record in ScopusGoogle Scholar](#)

[Elsayed et al., 2019](#)

S.A. Elsayed, Y. Ayed, A.B. Alolayan, L.M. Farghal, S. Kassim

Radiographic evaluation and determination of hypercementosis patterns in Al-Madinah Al-Munawwarah, Saudi Arabia: A retrospective cross-sectional study

Nigerian Journal of Clinical Practice, 22 (2019), pp. 957-960,

[10.4103/njcp.njcp_614_18](#)

[View Record in ScopusGoogle Scholar](#)

[Estalrrich et al., 2017](#)

A. Estalrrich, J.A. Alarcón, A. Rosas

Evidence of toothpick groove formation in Neandertal anterior and posterior teeth

American Journal of Physical Anthropology, 162 (4) (2017), pp. 747-756,

[10.1002/ajpa.23166](#)

[View Record in ScopusGoogle Scholar](#)

[Foster, 2017](#)

B.L. Foster

On the discovery of cementum

Journal of Periodontal Research, 52 (4) (2017), pp. 666-685, [10.1111/jre.12444](#)

[View Record in ScopusGoogle Scholar](#)

[Foster and Somerman, 2012](#)

B.L. Foster, M.J. Somerman

Cementum

L.C. McCauley, M.J. Somerman (Eds.), Mineralized tissues in oral and craniofacial science, Wiley-Blackwell, Oxford (2012), pp. 169-183

[View Record in ScopusGoogle Scholar](#)

[Foster et al., 2007](#)

B.L. Foster, T.E. Popowics, H.K. Fong, M.J. Somerman

Advances in defining regulators of cementum development and periodontal re-generation

Current Topics in Developmental Biology, 78 (2007), pp. 47-126, [10.1016/S0070-2153\(06\)78003-6](#)

[Article](#)

[Download PDFView Record in ScopusGoogle Scholar](#)

[García-González et al., 2019](#)

R. García-González, Z. Sánchez-Puente, L. Rodríguez, R.M. Quam, J.M. Carretero

Hypercementosis of the Magdalenian human mandibular teeth from El Mirón cave, Cantabria (Spain)

Quaternary International, 515 (2019), pp. 150-158, [10.1016/j.quaint.2018.04.038](#)

[Article](#)

[Download PDFView Record in ScopusGoogle Scholar](#)

[Gardner and Goldstein, 1931](#)

B. Gardner, H. Goldstein

The significance of Hypercementosis

Dental Cosmos (1931), pp. 1065-1069

[View Record in ScopusGoogle Scholar](#)

[Garralda and Vandermeersch, 2000](#)

M.D. Garralda, B. Vandermeersch

Les Néandertaliens de la grotte de Combe-Grenal (Domme, Dordogne, France)
/ The Neanderthals from Combe-Grenal cave (Domme, Dordogne, France)

Paléo, Revue d'Archéologie Préhistorique, 12 (1) (2000), pp. 213-259, [10.3406/pal.2000.1603](#)

[View Record in ScopusGoogle Scholar](#)

[Garralda et al., 2004](#)

M.D. Garralda, B. Maureille, J.P. Rigaud, B. Vandermeersch

La molaire néandertalienne de la grotte Vaufrey (Dordogne, France)

Bulletins et Mémoires Délelött Louisiana Société d'Anthropologie Délelött Paris,
16 (2004), pp. 3-4, [10.4000/bmsap.4023](https://doi.org/10.4000/bmsap.4023)

[View Record in ScopusGoogle Scholar](#)

[Garralda et al., 2020](#)

M.D. Garralda, B. Maureille, A. Le Cabec, G. Oxilia, S. Benazzi, M.M. Skinner, ...,
B. Vandermeersch

The Neanderthal Teeth From Marillac (Charente, Southwestern France): Morphology, comparisons and paleobiology

Journal of Human Evolution, 138 (2020), Article 102683,
[10.1016/j.jhevol.2019.102683](https://doi.org/10.1016/j.jhevol.2019.102683)

[Article](#)

[Download PDFView Record in ScopusGoogle Scholar](#)

[Goldberg, 2015](#)

M. Goldberg

Histologie des céments: structures et ultrastructures

EMC - Médecine Buccale, 10 (6) (2015), pp. 1-9, [10.1016/S1877-7864\(15\)69612-4](https://doi.org/10.1016/S1877-7864(15)69612-4)

[View Record in ScopusGoogle Scholar](#)

[Gottlieb and Orban, 1931](#)

B. Gottlieb, B.J. Orban

Die Veränderungen der Gewebe bei übermässiger Beanspruchung der Zähne

Georg Thieme, Leipzig (1931), pp. 186-190

[Google Scholar](#)

[Ho et al., 2010](#)

S.P. Ho, M.P. Kurylo, T.K. Fong, S.S. Lee, H.D. Wagner, M.I. Ryder, G.W. Marshall

The biomechanical characteristics of the bone-periodontal ligament-cementum complex

Biomaterials, 31 (25) (2010), pp. 6635-6646, [10.1016/j.biomaterials.2010.05.024](https://doi.org/10.1016/j.biomaterials.2010.05.024)

[Article](#)

[Download PDFView Record in ScopusGoogle Scholar](#)

[Kim et al., 1991](#)

S.H. Kim, E.H. Hwang, S.R. Lee

A radiographic study of hypercementosis

The Journal of Korean Academy of Maxillofacial Radiology, 21 (2) (1991), pp. 249-259

[View Record in ScopusGoogle Scholar](#)

[Kobi, 1956](#)

F.E. Kobi

Une incisive Néandertalienne trouvée en Suisse

Verhandlungen der Naturforschenden Gesellschaft in Basel, 67 (1956), pp. 1-15

[Google Scholar](#)

[Kohli et al., 2011](#)

A. Kohli, S.M. Pezzotto, L. Poletto

Hipercementosis apicales y no apicales en raíces dentarias humanas

(<http://dx.doi.org.docelec.u-bordeaux.fr/>)

International Journal of Morphology, 29 (4) (2011), pp. 1263-1267, [10.4067/S0717-](#)

[95022011000400032](#)

[View Record in ScopusGoogle Scholar](#)

[Kohli et al., 2013](#)

A. Kohli, S.M. Pezzotto, L. Poletto

Raíces dentales humanas normales y con perlas de cemento: Comparación histológica de estructuras

International Journal of Morphology, 31 (3) (2013), pp. 1020-1025

[CrossRefView Record in ScopusGoogle Scholar](#)

[Kravets, 2018](#)

I. Kravets

Paget's disease of bone: Diagnosis and treatment

The American Journal of Medicine, 131 (11) (2018), pp. 1298-1303, [10.1016/j.am-](#)

[jmed.2018.04.028](#)

[Article](#)

[Download PDFView Record in ScopusGoogle Scholar](#)

[Kronfeld, 1931](#)

R. Kronfeld

Histologic study of the influence of function on the human periodontal membrane

Journal of the American Dental Association, 18 (1931), pp. 1242-1274,

[10.14219/JADA.ARCHIVE.1931.0191](#)

[Article](#)

[Download PDFView Record in ScopusGoogle Scholar](#)

[Kupczik, 2003](#)

Kupczik, K.F. (2003). Tooth root morphology in primates and carnivores. Doctoral thesis (Ph.D), UCL (University College London), United Kingdom.

[Google Scholar](#)

[Kupfer, 1951](#)

I.J. Kupfer

Correlation of hypercementosis with toxic goiter; A preliminary report

Journal of Dental Research, 30 (5) (1951), pp. 734-736,

[10.1177/00220345510300051701](#)

[View Record in ScopusGoogle Scholar](#)

[Lacy et al., 2012](#)

S.A. Lacy, X.J. Wu, C.Z. Jin, D.G. Qin, Y.J. Cai, E. Trinkaus

Dentoalveolar paleopathology of the early modern humans from Zhirendong, South China

International Journal of Paleopathology, 2 (1) (2012), pp. 10-18, [10.1016/j.ij.06.003](#)

[Article](#)

[Download PDFView Record in ScopusGoogle Scholar](#)

[Lai et al., 2019](#)

P.T. Lai, S.F. Yang, Y.M. Lin, Y.C. Ho

Computer-aided design-guided endodontic microsurgery for a mandibular molar with hypercementosis

Journal of the Formosan Medical Association = Taiwan yi zhi, 118 (10) (2019), pp. 1471-1472, [10.1016/j.jfma.2019.06.007](#)

[Article](#)

[Download PDFView Record in ScopusGoogle Scholar](#)

[Le Cabec et al., 2019](#)

A. Le Cabec, N.K. Tang, V. Ruano Rubio, S. Hillson

Nondestructive adult age at death estimation: Visualizing cementum annulations in a known age historical human assemblage using synchrotron X-ray microtomography

American Journal of Physical Anthropology, 168 (1) (2019), pp. 25-44, [10.1002/ajpa.23702](#)

[Google Scholar](#)

[Le Cabec et al., 2013](#)

A. Le Cabec, P. Gunz, K. Kupczik, J. Braga, J.J. Hublin

Anterior tooth root morphology and size in Neanderthals: Taxonomic and functional implications

Journal of Human Evolution, 64 (3) (2013), pp. 169-193,
[10.1016/j.jhevol.2012.08.011](#)

[Article](#)

[Download PDF](#)[View Record in Scopus](#)[Google Scholar](#)

[Leider and Garbarino, 1987](#)

A.S. Leider, V.E. Garbarino

Generalized hypercementosis

Oral Surgery, Oral Medicine, and Oral Pathology, 63 (3) (1987), pp. 375-380,
[10.1016/0030-4220\(87\)90210-6](#)

[Article](#)

[Download PDF](#)[View Record in Scopus](#)[Google Scholar](#)

[Leroi-Gourhan, 1961](#)

A. Leroi-Gourhan

Les fouilles d'Arcy-sur-Cure (Yonne)

Gallia préhistoire, 4 (1) (1961), pp. 3-16, [10.3406/galip.1961.1182](#)

[View Record in Scopus](#)[Google Scholar](#)

[Lucas, 1955](#)

R.B. Lucas

The jaws and teeth in Paget's disease of bone

Journal of Clinical Pathology, 8 (3) (1955), pp. 195-200, [10.1136/jcp.8.3.195](#)

[View Record in Scopus](#)[Google Scholar](#)

[Margvelashvili et al., 2016](#)

A. Margvelashvili, C.P. Zollikofer, D. Lordkipanidze, P. Tafforeau, M.S. Ponce de León

Comparative analysis of dentognathic pathologies in the Dmanisi mandibles

American Journal of Physical Anthropology, 160 (2) (2016), pp. 229-253,
[10.1002/ajpa.22966](#)

[View Record in Scopus](#)[Google Scholar](#)

[Martinón-Torres et al., 2011](#)

M. Martín-Torres, L. Martín-Francés, A. Gracia, A. Olejniczak, L. Prado-Simón, A. Gómez-Robles, ..., J.M. Bermúdez de Castro

Early Pleistocene human mandible from Sima del Elefante (TE) cave site in Sierra de Atapuerca (Spain): A palaeopathological study

Journal of Human Evolution, 61 (1) (2011), pp. 1-11, [10.1016/j.jhevol.2011.01.004](https://doi.org/10.1016/j.jhevol.2011.01.004)
[Article](#)

[Download PDF](#) [View Record in Scopus](#) [Google Scholar](#)

[Moher et al., 2009](#)

D. Moher, A. Liberati, J. Tetzlaff, D.G. Altman, The PRISMA Group

Preferred reporting items for systematic reviews and meta-analyses: The PRISMA statement

Annals of Internal Medicine, 151 (4) (2009), pp. 264-269, [10.7326/0003-4819-151-4-2009008180-00135](https://doi.org/10.7326/0003-4819-151-4-2009008180-00135)

[Google Scholar](#)

[Molnar et al., 1972](#)

S. Molnar, M.J. Barrett, L. Brian, C.L. Brace, D.S. Brose, J.R. Dewey, ..., G.A. Wright

Tooth wear and culture: A survey of tooth functions among some prehistoric populations [and comments and reply]

Current Anthropology, 13 (5) (1972), pp. 511-526, [10.1086/201284](https://doi.org/10.1086/201284)

[Google Scholar](#)

[Mühlemann and Zander, 1954](#)

H.R. Mühlemann, H.A. Zander

Tooth mobility (III). The mechanism of tooth mobility

Journal of Periodontology, 25 (1954), pp. 128-135, [10.1902/JOP.1954.25.2.128](https://doi.org/10.1902/JOP.1954.25.2.128)

[View Record in Scopus](#) [Google Scholar](#)

[Naji et al., 2015](#)

Naji S., Gourichon L., & Rendu W. (2015) La cémento-chronologie. In Balasse, Brugal, Dauphin, Geigl, Oberlin (Eds.), Messages d'os. archéométrie du squelette animal et humain (pp.172–190).Éditions des Archives Contemporaines.

[Google Scholar](#)

[Naji et al., 2016](#)

S. Naji, T. Colard, J. Blondiaux, B. Bertrand, E. d'Incau, J.P. Bocquet-Appel

Cementochronology, to cut or not to cut

International Journal of Paleopathology, 15 (2016), pp. 113-119, [10.1016/j.ij.05.003](https://doi.org/10.1016/j.ij.05.003)

[Article](#)

[Download PDFView Record in ScopusGoogle Scholar](#)

[Neves et al., 2014](#)

F.S. Neves, K. Rovaris, M.L. Oliveira, P.D. Novaes, D.Q. de Freitas

Concrescence: Assessment of case by periapical radiography, cone beam computed tomography and micro-computed tomography

The New York State Dental Journal, 80 (3) (2014), pp. 21-23

[View Record in ScopusGoogle Scholar](#)

[Newham et al., 2021](#)

E. Newham, P.G. Gill, K. Robson Brown, N.J. Gostling, I.J. Corfe, P. Schneider

A robust, semi-automated approach for counting cementum increments imaged with synchrotron X-ray computed tomography

PloS One, 16 (11) (2021), Article e0249743, [10.1371/journal.pone.0249743](https://doi.org/10.1371/journal.pone.0249743)

[View Record in ScopusGoogle Scholar](#)

[Nouman et al., 2015](#)

N. Nouman, A. Brig Manzoor, J. Nusrat, H. Sadaf

Endodontic treatment of premolar with unusual anatomy and hypercementosis-case report

Pakistan Oral & Dental Journal, 35 (2015), p. 3

[View Record in ScopusGoogle Scholar](#)

[Palma et al., 2017](#)

P.J. Palma, J.C. Ramos, J.B. Martins, A. Diogenes, M.H. Figueiredo, P. Ferreira, ..., J.M. Santos

Histologic evaluation of regenerative endodontic procedures with the use of chitosan scaffolds in immature dog teeth with apical periodontitis

Journal of Endodontics, 43 (8) (2017), pp. 1279-1287, [10.1016/j.joen.2017.03.005](https://doi.org/10.1016/j.joen.2017.03.005)

[Article](#)

[Download PDFView Record in ScopusGoogle Scholar](#)

[Pedersen, 1949](#)

P.O. Pedersen

The East Greenland Eskimo dentition, numerical variations and anatomy. A contribution to comparative ethnic odontography

Copenhagen: Meddelelser om Grønland, 142 (1949), pp. 1-244

[View Record in ScopusGoogle Scholar](#)

[Piette and Goldberg, 2001](#)

Piette, E., & Goldberg, M. (2001). La dent normale et pathologique. (1st ed.). De Boeck Supérieur, (Chapter 5).

[Google Scholar](#)

[Pinheiro et al., 2008](#)

B.C. Pinheiro, T.N. Pinheiro, A.L. Capelozza, A. Consolaro

A scanning electron microscopic study of hypercementosis

Journal of Applied Oral Science: Revista FOB, 16 (6) (2008), pp. 380-384,

[10.1590/s1678-77572008000600005](#)

[View Record in ScopusGoogle Scholar](#)

[Pinheiro et al., 2013](#)

B.C. Pinheiro, R.A. Azeredo, A. Consolaro, L.A.P. de Barros, T.N. Pinheiro

Morfologia do terço apical da raiz e dos canais de dentes com hiper cementose

Dental Press Endodontics, 3 (3) (2013), pp. 23-31

[View Record in ScopusGoogle Scholar](#)

[Polisetti et al., 2014](#)

N. Polisetti, M. Neerupakam, V.S. Prathi, J. Prakash, D. Vaishnavi, S.S. Beeraka, D. Bhavirisetty

Osteonecrosis secondary to Paget's disease: Radiologic and pathologic features

Journal of Clinical Imaging Science, 4 (Suppl 2) (2014), p. 1, [10.4103/2156-](#)

[7514.129262](#)

[Google Scholar](#)

[Rao and Karasick, 1982](#)

V.M. Rao, D. Karasick

Hypercementosis - an important clue to Paget disease of the maxilla

Skeletal Radiology, 9 (2) (1982), pp. 126-128, [10.1007/BF00360497](#)

[View Record in ScopusGoogle Scholar](#)

[Sarkotić and Šutalo, 1987](#)

R. Sarkotić, J. Šutalo

Clinical importance of hypercementosis

Acta Stomatologica Croatica: International Journal of Oral Sciences and Dental Medicine, 21 (4) (1987), pp. 325-330

[View Record in ScopusGoogle Scholar](#)

[Schroeder, 1986](#)

H.E. Schroeder

The periodontium

A. Oksche, L. Vollrath (Eds.), Handbook of microscopic anatomy. *Vol.V/5*, Springer-Verlag, Berlin (1986), pp. 23-129

[CrossRefGoogle Scholar](#)

[Schroeder, 1992](#)

H.E. Schroeder

Biological problems of regenerative cementogenesis: Synthesis and attachment of collagenous matrices on growing and established root surfaces

International Review of Cytology, 142 (1992), pp. 1-59, [10.1016/s0074-7696\(08\)62074-4](https://doi.org/10.1016/s0074-7696(08)62074-4)

[Article](#)

[Download PDFGoogle Scholar](#)

[Schroeder, 1993](#)

H.E. Schroeder

Human cellular mixed stratified cementum: A tissue with alternating layers of acellular extrinsic-and cellular intrinsic fiber cementum

Schweizerische Monatsschrift für Zahnmedizin, 103 (5) (1993), pp. 550-560

[View Record in ScopusGoogle Scholar](#)

[Schroeder, 2012](#)

Schroeder, H.E. (2012). The periodontium (Vol. 5). (2nd ed.) Springer Science & Business Media, (Chapter 4).

[Google Scholar](#)

[Scolan et al., 2012](#)

H. Scolan, F. Santos, A.M. Tillier, B. Maureille, A. Quintard

Des nouveaux vestiges néanderthaliens à Las Pélénos (Monsempron-Libos, Lot-et-Garonne, France)

Bulletins et Mémoires Délelőtt Louisiana Société d'Anthropologie Délelőtt Paris, 24 (2012), pp. 69-95, [10.1007/s13219-011-0047-x](https://doi.org/10.1007/s13219-011-0047-x)

[View Record in ScopusGoogle Scholar](#)

[Smith and Burstone, 1984](#)

R.J. Smith, C.J. Burstone

Mechanics of tooth movement

American Journal of Orthodontics, 85 (4) (1984), pp. 294-307, [10.1016/0002-9416\(84\)90187-8](https://doi.org/10.1016/0002-9416(84)90187-8)

[Article](#)

[Download PDFView Record in ScopusGoogle Scholar](#)

[Spencer and Demes, 1993](#)

M.A. Spencer, B. Demes

Biomechanical analysis of masticatory system configuration in Neandertals and Inuits

American Journal of Physical Anthropology, 91 (1) (1993), pp. 1-20, [10.1002/ajpa.1330910102](https://doi.org/10.1002/ajpa.1330910102)

[View Record in ScopusGoogle Scholar](#)

[Sugiyama et al., 2007](#)

M. Sugiyama, I. Ogawa, Y. Suei, H. Tohmori, K. Higashikawa, N. Kamata

Concrescence of teeth: Cemental union between the crown of an impacted tooth and the roots of an erupted tooth

Journal of Oral Pathology & Medicine, 36 (1) (2007), pp. 60-62, [10.1111/j.1600-0714.2006.00464.x](https://doi.org/10.1111/j.1600-0714.2006.00464.x)

[Google Scholar](#)

[Tang et al., 2015](#)

N. Tang, A. Le Cabec, D. Antoine

Dentine and cementum structure and properties

J.D. Irish, G.R. Scott (Eds.), A Companion to Dental Anthropology, Wiley (2015), pp. 204-222, [10.1002/9781118845486.ch15](https://doi.org/10.1002/9781118845486.ch15)

[View Record in ScopusGoogle Scholar](#)

[Tillier et al., 1989](#)

A.M. Tillier, B. Arensburg, H. Duday

La mandibule et les dents du Néanderthalien de Kebara (Homo 2), Mont Carmel, Israël

Paléorient, 15 (2) (1989), pp. 39-58, [10.3406/paleo.1989.4508](https://doi.org/10.3406/paleo.1989.4508)

[View Record in ScopusGoogle Scholar](#)

[Tillier et al., 1995](#)

A.M. Tillier, B. Arensburg, Y. Rak, B. Vandermeersch

Middle Paleolithic dental caries: New evidence from Kebara (Mount Carmel, Israel)

Journal of Human Evolution, 29 (1995), pp. 189-192

[Article](#)

[Download PDFView Record in ScopusGoogle Scholar](#)

[Trinkaus, 1983](#)

E. Trinkaus

The Shanidar neandertals

Academic Press, New York (1983)

(xxiv)

[Google Scholar](#)

[Trinkaus and Pinilla, 2009](#)

E. Trinkaus, B. Pinilla

Dental caries in the qafzeh 3 middle paleolithic modern human

Paléorient, 35 (1) (2009), pp. 69-76

[CrossRefView Record in ScopusGoogle Scholar](#)

[Trinkaus et al., 2008](#)

E. Trinkaus, B. Maley, A.P. Buzhilova

Brief communication: Paleopathology of the Kiik-Koba 1 Neandertal

American Journal of Physical Anthropology, 137 (1) (2008), pp. 106-112,

[10.1002/ajpa.20833](#)

[View Record in ScopusGoogle Scholar](#)

[Ungar et al., 2001](#)

P.S. Ungar, F.E. Grine, M.F. Teaford, A. Pérez-Pérez

A review of interproximal wear 67 grooves on fossil hominin teeth with new evidence from Olduvai Gorge

Archives of Oral Biology, 46 (4) (2001), pp. 285-292, [10.1016/s0003-9969\(00\)00128-x](#)

[Article](#)

[Download PDFView Record in ScopusGoogle Scholar](#)

[Venkatesh et al., 2011](#)

R. Venkatesh, R.K. Joshi, S. Ballal

Pagetova bolest kostiju: Prikaz slučaja

Acta Stomatologica Croatica: International Journal of Oral Sciences and Dental Medicine, 45 (2) (2011), pp. 125-130

[View Record in ScopusGoogle Scholar](#)

[Wallace et al., 1975](#)

J.A. Wallace, M.J. Barrett, T. Brown, C.L. Brace, W.W. Howells, R.T. Koritzer, ..., K. Zlábek

Did la ferrassie i use his teeth as a tool? [and Comments and Reply]

Current Anthropology, 16 (3) (1975), pp. 393-401, [10.1086/201570](#)

[View Record in ScopusGoogle Scholar](#)

[Yamamoto et al., 2009](#)

H. Yamamoto, T. Niimi, R. Yokota-Ohta, K. Suzuki, T. Sakae, Y. Kozawa

Diversity of acellular and cellular cementum distribution in human permanent teeth

Journal of Hard Tissue Biology, 18 (1) (2009), pp. 40-44, [10.2485/jhtb.18.40](#)

[View Record in ScopusGoogle Scholar](#)

[Zemsky, 1931](#)

J.L. Zemsky

Relationship of hypercementosis to arthritic disturbance

Dent Items Interest, 53 (1931), pp. 159-174

[CrossRefView Record in ScopusGoogle Scholar](#)

[Zhou et al., 2012](#)

J. Zhou, Y. Zhao, C. Xia, L. Jiang

Periodontitis with hypercementosis: Report of a case and discussion of possible aetiologic factors

Australian Dental Journal, 57 (4) (2012), pp. 511-514, [10.1111/j.1834-7819.2012.01725.x](#)

[View Record in ScopusGoogle Scholar](#)

Supplementary Table S1

Detailed results of the systematic review on hypercementosis. The different papers are analysed according to the assumed aetiological causes, the following data were collected for each paper: authors and date of publication, type of publication, information on studied materials (i.e., origin, number of individuals, number of teeth), methods of analysis, whether the definition of hypercementosis was provided in the paper (YES) or not (NO). The scoring system was used where possible to determine the cementum apposition pattern.

Intensive masticatory effort

Bibliographic reference	Type of publications	Materials under study			Methods	Definition of HC	Hypercementosis scoring
		Origin	Number of individuals	Number of teeth			
Antunes & Santinho Cunha 1992	Archaeological publication	ND (Figueira Brava, Portugal) ~30 ky B.P. Four prehistoric sites (Texas coast) Blue Bayou Palm Harbor Oso Creek Cayo Del Oso ~8-5 ky B.P.	NA	n=1	Macroscopy X-Ray Microscopy (SEM)	YES	Premolar 3.2.m (PS)
Comuzzie & Gentry Steele 1989	Archaeological publication	Rochelot cave (Charente, France) OIS 5d (~109ky-123ky)	n=1	n=6	Macroscopy	NO	Premolar 1.2.m (PS) Molar 1.3.m
Garralda & Vandermeersch 2000	Archaeological publication	ND (Combe-Grenal cave, Domme, France) ~60-70 ky B.P.	n=4	n=9	Macroscopy X-Ray Microscopy (SEM)	NO	Anterior teeth 1.1.m (PS)
Garralda et al. 2005	Archaeological publication	ND, Iberian Peninsula (Cueva de El Castillo) ~30 ky B.P.	n=3	n=12	Macroscopy	NO	Anterior teeth 1.1.m
Gilbert 1992	Archaeological publication	Terriers site, Avrillé (Vendée, France)	n=5	n=62	Measurement report	NO	NA

		~3 ky B.P.					
Gottlieb et al. 1931	Case report	H-55 yrs	n=1	n=1	Microscopy	NO	Lateral incisor 1.1.m
Henry-Gambier et al. 2004	Archaeological publication	ND, Brassempouy Grotte des Hyènes, Landes (France) ~34-30 ky B.P.	n=2	n=2	Macroscopy	NO	Incisors 1.2.m (PS)
Kim et al. 1991	Retrospective study Cross sectional	Inflammation Super-erupted Trauma from occlusion Impacted teeth Unknown	n=4236	n=677	NA	NA	NA
Le Cabec et al. 2013	Archaeological publication	ND, EH, Permanent mandibular and maxillary incisors and canines from different sites	NA	n=339	X-Ray Micro-tomography	YES	Anterior teeth 1.1.M (PS)
Maureille et al. 2008	Archaeological publication	ND, Grotte Bocard Bas-de-Morant (Côte-d'or, Bourgogne, France) Middle Palaeolithic	n=1	n=1	Macroscopy X-ray	NO	Incisors 1.1.m (PS)
Margvelashvili et al. 2016	Archaeological publication Case control	Plio-Pleistocene, Dmanisi hominins Georgia ~1.77 My B.P.	n=3	n=43	Macroscopy Microscopy X-ray Micro-tomography (conventional and synchrotron)	YES	Anterior teeth 1.2.m
Martinón-Torres et al. 2011	Archaeological publication	Early Pleistocene human (Sima del Elefante, Atapuerca, Spain) Mandible, ATE9-1 ~1.3 My B.P.	n=1	n=5	Macroscopy X-ray Micro-tomography	YES	Premolar 1.3.m (apical location)

Mussini 2011	Archaeological publication	ND, Les Pradelles (Marillac- le-Franc, Charente, France) ~55 ky B.P.	n=6	n=6	Macroscopy X-ray	NO	Incisors and canines 1.1.m (PS) Molars 1.2.m
Patte 1960	Archaeological publication	ND, Angle-sur-l'anglin (Vienne, France), Mousterian Datation NA	n=1	n=1	Macroscopy X-Ray	NO	
Pedersen 1949	Archaeological publication	Population of Eskimos Arctic 19 th – 20 th centuries	NA	NA	Macroscopy	YES	NA
Prado-Simón et al. 2012	Archaeological publication	Early Pleistocene human (Sima del Elefante, Atapuerca, Spain) Mandible, ATE9-1 ~1.3 My B.P.	n=1	n=5	Macroscopy X-ray Micro-tomography	YES	Premolars and incisors 1.3.m (PS)
Scolan et al. 2012	Archaeological publication	ND, Las Pélénos (Monsempron-Libos, Lot-et- Garonne, France) Mousterian	n=1	n=1	Macroscopy X-ray	NO	Canine 1.1.m
Trinkaus et al. 2008	Archaeological publication	ND, Middle Palaeolithic. The Kiik-Koba 1 Neandertal partial skeleton Crimea Early last glacial or possibly late last interglacial (early OIS 4 or late OIS 5)	n=1	n=1	Macroscopy	NO	Canine 1.3.m (except the cervical 4–5 mm of the labial side)
Waters-Rist et al. 2010	Archaeological publication	Lake Baikal, Siberia, Russia ~8-3.5 ky B.P.	n=25	n=11	Macroscopy Microscopy (SEM)	YES	NA

yrs: years; ky: thousand years; My: million years; B.P.: before present; SEM: scanning electron microscopy; ND: neanderthal; M: male; HC: hypercementosis; NA: not available

Systemic diseases

Bibliographic reference	Type of publications	Materials under study			Methods	Definition of HC	Hypercementosis scoring
		Origin	Number of individuals	Number of teeth			
Arendt et al. 1989	Case report	M - 23 yrs Gardner's syndrome	n=1	NA	X-Ray Histology	NO	Molars 1.2.M
Ather et al. 2013	Case report	M - 32 yrs Lobodontia	n=1	n=20	Macroscopy X-Ray	NO	All teeth 1.3.M
Kupfer 1951	Retrospective study Case control	Goiter and hyperthyroidism study 36 patients' hospital control 36 patients with hyperthyroidism	n=108	NA	X-Ray (not supplied)	YES	NA
Kupfer 1954	Retrospective study Case control	Hyperthyroidism study 92 patients' control 54 patients with hyperthyroidism	n=92	NA	X-Ray	YES	Premolars 1.2-3.M
Dileep Sharma et al. 2007	Case report	F – 21 yrs Pendred Syndrome	n=1	n=27	X-Ray Macroscopy Blood analysis	YES	All teeth 1.2.M
Gardner et al. 1931	Retrospective study Cross sectional	137 patients Acromegalia	n=137	n=587	X-ray	YES	NA
Leider et al. 1987	Case report	F – 76 yrs Arthritis – Hyperthyroidism	n=1	n=24	X-Ray	YES	All teeth 1.3.M
Lucas 1955	Retrospective study Case control	Paget's disease	n=5	NA	Histology	YES	All teeth 1.2-3.M

Pereira et al. 2016	Cases report	M – 18 yrs; F – 49 yrs Gardner’s syndrome	n=2	NA	X-Ray (not supplied)	NO	NA
Peters et al. 1992	Case report	M - 26 yrs Amelogenesis imperfecta	n=1	NA	X-ray Histology	NO	Molars 1.3.M
Polisetti et al. 2014	Case report	M – 70 yrs Paget’s disease	n=1	n=6	X-Ray Macroscopy Histology	NO	All teeth 1.2-3.M
Rao & Karasick 1982	Case report	F - 52 yrs Paget's disease	n=1	NA	X-Ray	YES	All teeth 1.2-3.M
Soni 1966	Retrospective study Cross sectional	Patients (10-15 yrs) sickle cell haemoglobinopathies	n=5	n=6	X-ray	NO	NA
Souza et al. 2018	Retrospective study Case control	Subjects (n=369) were allocated to three groups: sickle cell haemoglobinopathies, trait and control	n=369	NA	X-ray	YES	NA
Srinivaschakravarthi et al. 2015	Case report	F - 50 yrs Paget's disease	n=1	n=14	X-Ray Photography Histology	NO	All teeth 1.2-3.m
Thompson 1948	Case report	M - 49 yrs Parathyroid hyperplasia	n=1	n=21	X-Ray	NO	All teeth 1.2-3.M
Venkatesh et al. 2011	Case report	F - 70 yrs Paget's disease	n=1	n=11	X-Ray Macroscopy	NO	All teeth 1.3.M
Wang et al. 2013	Cases report	3 families Enamel-renal Syndrome	NA	NA	Macroscopy X-ray Microscopy	NO	All teeth 1.3.m

(SEM)
Histology

yrs: years; SEM: scanning electron microscopy; F: female; M: male; HC: hypercementosis; NA: not available

Cariou lesion and apical periodontitis

Bibliographic reference	Type of publications	Materials under study			Methods	Definition of HC	Hypercementosis scoring
		Origin	Number of individuals	Number of teeth			
Brasher et al. 1982	Case report	M - 41 yrs Dental routine examination Endodontic-periodontal cause	n=1	n=1	X-Ray Macroscopy Microscopy	NO	1.2.M Incisors
Dobhal et al. 2018	Case report	M - 73 yrs Apical periodontitis	n=1	n=1	X-Ray Macroscopy Histology	YES	1.3.M Molars
Elsayed et al. 2019	Retrospective study Cross sectional	815 orthopantomograms Women (16-55 yrs) Periodontitis Cariou lesion	n=815	NA	X-Ray	YES	NA
Heredia et al. 2019	Case report	F - 51 yrs Apical periodontitis	n=1	n=1	X-Ray CBCT	YES	1.2.M Molar
Kohli et al. 2011	Retrospective study Case control	Patients (16-79 yrs) 40 extracted teeth due to different causes (20 with HC) Cariou lesions and apical periodontitis	NA	n=20	Radiography Photography	YES	3.3.M Premolars and molars
Kohli et al.	Retrospective study		NA	n=20	Histology	YES	2.m-M

2013	Case control	Patients (16-79 yrs) 40 extracted teeth due to different causes (20 with HC) Carious lesions and apical periodontitis					
Lacy et al. 2012	Archaeological publication	Zhiren 2 - Zhirendong (China) ~106 ky B.P. Cariou lesions	n=1	n=1	Macroscopy X-ray microtomography	YES	1.2-3.m (PS) Molar
Lacy 2014	Archaeological publication	Broken Hill (Kabwe) 1, Middle Pleistocene Zambia (Africa) ~300 ky B.P. Cariou lesions and apical periodontitis	n=1	n=3	Macroscopy X-Ray	YES	1.2-3.m Incisors 1.2-3.M Molars
Lai et al. 2019	Case report	F - 38 yrs Apical abscess Endodontic-periodontal cause	n=1	n=1	X-Ray CBCT	NO	1.2-3.M Molars
Lia et al. 1978	Retrospective study Cross sectional	30 isolated teeth with different degree of carious lesions and HC (20 molars, 9 premolars, 1 canine) Cariou lesions	NA	n=30	Histology	NO	Divers stage and extent
Lucas et al. 1955	Retrospective study Case control	Paget's disease study but one patient presents a different pattern of HC Apical periodontitis	n=1	n=1	Histology	YES	1.2.m (PS) molar
Nouman et al. 2015	Cases report	Patients with chronic apical periodontitis	n=4	n=7	X-Ray	YES	1.1.M premolar

Oktawati et al. 2020	Case report	M - 30 yrs Endodontic-periodontally cause	n=1	n=3	Macroscopy X-Ray CBCT	YES	1.2.M incisor
Pinheiro et al. 2013	Retrospective study Case control	130 teeth 60 HC Cariou lesion	NA	n=60	X-Ray Microscopy	YES	1.3.m-M Molars
Prabhakar et al. 1998	Case report	M - 10 yrs Trauma to a mandibular deciduous central incisor resulted in a rare case of dilaceration and duplication of crown with hypercementosis of the root in the permanent successor. Apical periodontitis Abscess	n=1	n=2	Macroscopy X-Ray	NO	1.2.M incisor
Sarkotić et al. 1987	Cases report	Patients with mixed causes Chronic apical periodontitis	n=4	n=7	X-Ray	YES	1.2-3.M
Sarkotić & Sutalo 1987	Retrospective study Cross sectional	Patients with chronic pulpitis Cariou lesions	n=212	n=14	X-Ray	NO	1.2.m-M
Tillier et al. 1995	Archaeological publication	ND, Kebara cave, Mount Carmel (Israel) - ULI2 ~60 ky B.P. Cariou lesion	n=1	n=1	Macroscopy	NO	1.2.m Incisor

yrs: years; ky: thousand years; B.P.: before present; CBCT: Cone Beam Computed Tomography; ND: neanderthal; F: female; M: male; HC: hypercementosis; NA: not available

Impacted teeth

Bibliographic reference	Type of publications	Materials under study		Methods	Definition of HC	Hypercementosis scoring
		Origin	Number of individuals			
Azaz et al. 1974	Retrospective study Case control	Patients (9-70 yrs) with impacted premolars and canines (n = 60) Patients (9-75 yrs) with sound erupted premolars and canines (n = 10) Impacted canines	NA	n=60	Microscopy	YES Canines 1.1.m
Bailey & Hublin 2006	Archaeological publication	ND, Canine Xb-Z8 (Grotte du Renne, Arcy-sur-Cure, France) Impacted canines Chatelperronian - Upper Palaeolithic	n=1	n=1	Macroscopy	NO Canine 1.3.m (PS)
Dean et al. 2013	Archaeological publication	El Sidrón 2, mandibule SDR 7-8 (Cueva de Sidron, Asturias, Espagne) Impacted canines ~49 ky B.P.	n=1	n=1	Macroscopy X-ray	NO Canine 1.3.m
Kim et al. 1991	Retrospective study Cross sectional	Inflammation Super-erupted Trauma from occlusion Impacted teeth Unknown	n=4236	n=677	NA	NA NA
Raghoobar et al. 1989	Retrospective study Case control	20 Patients (9-27 yrs) with secondarily retained molars (n = 26) Control group with normally erupted molars (n = 6)	n=20	n=26	X-Ray Microscopy (SEM)- Histology	NO 1.3.m

Raghoobar et al. 1992	Retrospective study Case control	Retained teeth Patients (9-25 yrs) with secondarily retained molars (n = 12) Control group with normally erupted molars (n = 6) Retained teeth	n=11	n=12	X-Ray Microscopy	NO	1.3.m
Zemsky 1931	Cases report	Five cases (24-46 yrs) Retained teeth	n=5	n=5	X-Ray Histology	YES	Canines & molars 1.3.m (PS)

yrs: years; ky: thousand years; B.P.: before present; SEM: scanning electron microscopy; ND: neanderthal; HC: hypercementosis; NA: not available

Periodontal disease

Bibliographic reference	Type of publications	Materials under study			Methods	Definition of HC	Hypercementosis scoring
		Origin	Number of individuals	Number of teeth			
Brooks et al. 2020	Case report	F - 66 yrs General periodontitis	n=1	n=5	X-Ray	NO	1.2.M (premolars)
Corruccini et al. 1982	Archaeological publication	Newton Plantation, Barbados collection 18 th -19 th centuries General periodontitis	n=101	n=11	Macroscopy	NO	1.3.M (molars)
Corruccini et al. 1987	Archaeological publication	Newton Plantation, Barbados collection 18 th – 19 th centuries General periodontitis	n=104	NA	Macroscopy	YES	1.3.M (molars)
Elsayed et al. 2019	Retrospective study Cross sectional	815 orthopantomograms F (16-55 yrs) Periodontitis Cariou lesion	n=815	NA	X-Ray	YES	NA
Zhou et al. 2012	Case report	F - 76 yrs Local periodontitis	n=1	n=1	X-Ray Macroscopy Histology	YES	1.3.M (molars)

yrs: years; F: female; HC: hypercementosis

Concrescence

Bibliographic reference	Type of publications	Materials under study			Methods	Definition of HC	Hypercementosis scoring
		Origin	Number of individuals	Number of teeth			
Neves et al. 2014	Case report	NA Concrescence	n=1	n=2	X-Ray Macroscopy	NO	1.2.m-M Molars
Mohan 2014	Case report	F – 30 yrs Concrescence	n=1	n=2	X-Ray Macroscopy	NO	1.2.m Molars
Sugiyama et al. 2007	Case report	F – 61 yrs Concrescence	n=1	n=2	X-Ray Radiography Microscopy	YES	1.2.m Molars

F: female; HC: hypercementosis; NA: not available

Super-eruption

Bibliographic reference	Type of publications	Materials under study			Methods	Definition of HC	Hypercementosis scoring
		Origin	Number of individuals	Number of teeth			
Kim et al. 1991	Retrospective study Cross sectional	Inflammation Super-erupted Trauma from occlusion Impacted teeth Unknown	n=4236	n=677	NA	NA	NA

HC: hypercementosis; NA: not available

Drugs

Bibliographic reference	Type of publications	Materials under study			Methods	Definition of HC	Hypercementosis scoring
		Origin	Number of individuals	Number of teeth			
De Camargo et al. 2015	Retrospective study Cross sectional	Biphosphonate study	n=1	n=1	Macroscopy Histology	YES	1.3.m molar

Combined aetiologies

Bibliographic reference	Type of publications	Materials under study			Methods	Definition of HC	Hypercementosis scoring
		Origin	Number of individuals	Number of teeth			
García-González et al. 2019	Archaeological publication	Magdalenian human skeleton, site of El Mirón cave (Spain) Mandible of 'Red Lady' ~18 ky B.P. Intensive masticatory effort, periodontitis and idiopathic factors	n=1	n=10	X-Ray	YES	1.1-2-3.m-M
Garralda et al. 2004	Archaeological publication	ND, site of Vaufrey Cave (Dordogne, France) ~70 ky B.P. Intensive masticatory effort and Periodontitis	n=1	n=1	Macroscopy X-Ray	YES	1.1-2.m
Scheutzel 1991	Case report	M - 26 yrs Intensive masticatory effort and Occulodontodigital syndrome	n=1	n=3	X-Ray	NO	Molars and premolars 1.1.M and 1.2.m
Shoor et al. 2014	Case report	F - 33 yrs / F - 29 yrs Systemic lupus erythematosus & carious lesion	n=2	n=33	X-Ray	YES	Carious lesions: 1.2.M Others: 1.3.M
Tillier et al. 1989	Archaeological publication	ND, Kebara cave, Mount Carmel (Israel) <i>Homo 2</i> skeletons ~60 ky B.P. Intensive masticatory effort and periodontitis	n=1	n=16	Macroscopy X-Ray	NO	Type 1 but no other information

yrs: years; ky: thousand years; B.P.: before present; ND: neanderthal; F: female; M: male; HC: hypercementosis; NA: not available