



HAL
open science

Segmentation and characterization of the aorta and supra-aortic trunks for neuroradiology procedure planning

Mounir Lahlouh, Yasmina Chenoune, Raphaël Blanc, Michel P. Piotin, Simon Escalard, Robert Fahed, Jérôme Szewczyk, Nicolas Passat

► To cite this version:

Mounir Lahlouh, Yasmina Chenoune, Raphaël Blanc, Michel P. Piotin, Simon Escalard, et al.. Segmentation and characterization of the aorta and supra-aortic trunks for neuroradiology procedure planning. Colloque Français d'Intelligence Artificielle en Imagerie Biomédicale (IABM), Mar 2023, Paris, France. . hal-03932761

HAL Id: hal-03932761

<https://hal.science/hal-03932761>

Submitted on 4 Apr 2023

HAL is a multi-disciplinary open access archive for the deposit and dissemination of scientific research documents, whether they are published or not. The documents may come from teaching and research institutions in France or abroad, or from public or private research centers.

L'archive ouverte pluridisciplinaire **HAL**, est destinée au dépôt et à la diffusion de documents scientifiques de niveau recherche, publiés ou non, émanant des établissements d'enseignement et de recherche français ou étrangers, des laboratoires publics ou privés.



Distributed under a Creative Commons Attribution 4.0 International License

SEGMENTATION AND CHARACTERIZATION OF THE AORTA AND SUPRA-AORTIC TRUNKS FOR NEURORADIOLOGY PROCEDURE PLANNING

Mounir Lahlouh^{1,2,3}, Yasmina Chenoune^{2,4}, Raphaël Blanc^{3,5}, Michel Piotin⁵, Simon Escalard⁵, Robert Fahed^{5,6}, Jérôme Szewczyk^{3,7}, Nicolas Passat¹

¹CRESTIC, Université de Reims Champagne-Ardenne, Reims, France

²ESME Research Lab, Paris, France

³Basecamp Vascular, Paris, France

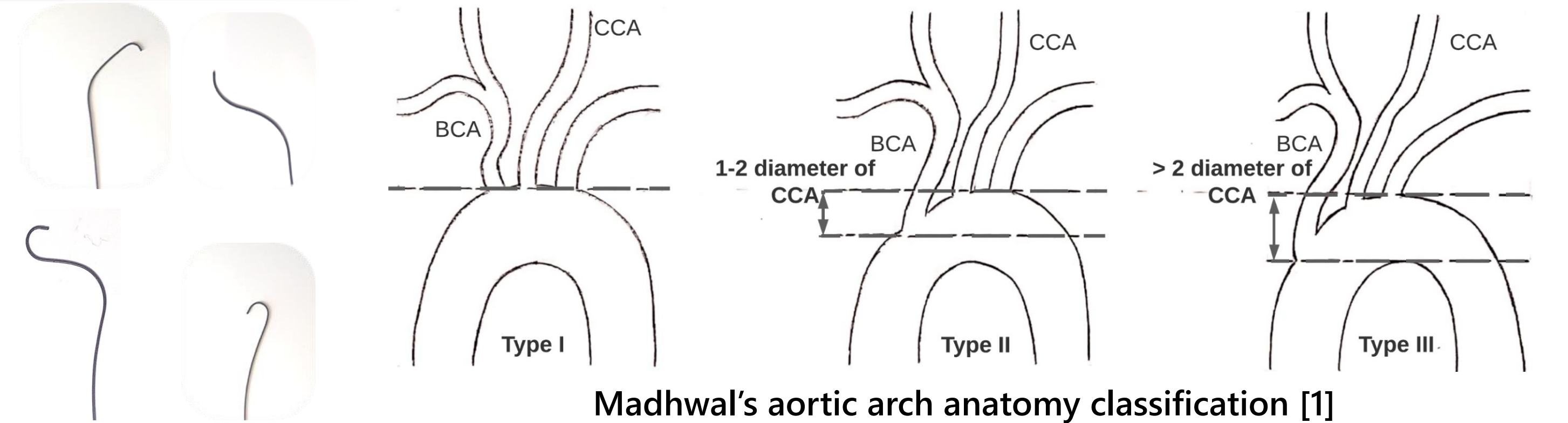
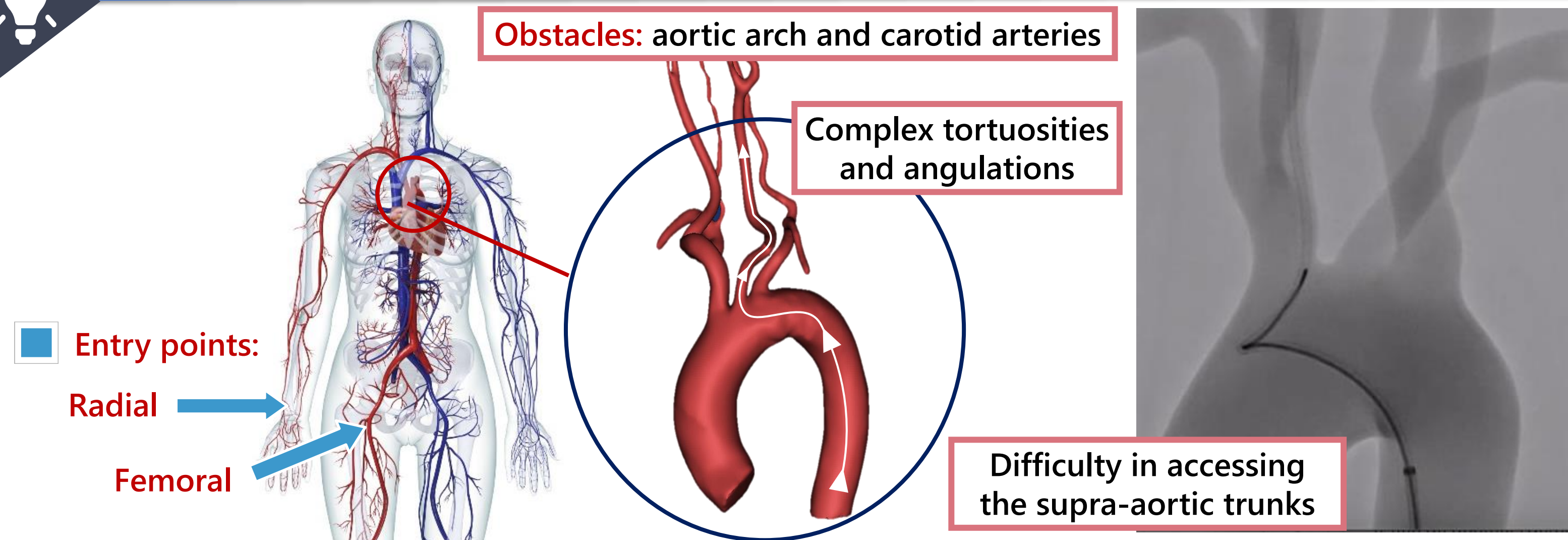
⁴LISSI, Université Paris-Est, Vitry-sur-Seine, France

⁵Fondation Ophtalmologique de Rothschild, Interventional Neuroradiology Department, Paris, France

⁶Department of Medicine, Division of Neurology, The Ottawa Hospital, Ottawa Hospital Research Institute and University of Ottawa, Ottawa, Ontario, Canada

⁷ISIR, Sorbonne Université, Paris, France

1. Clinical background

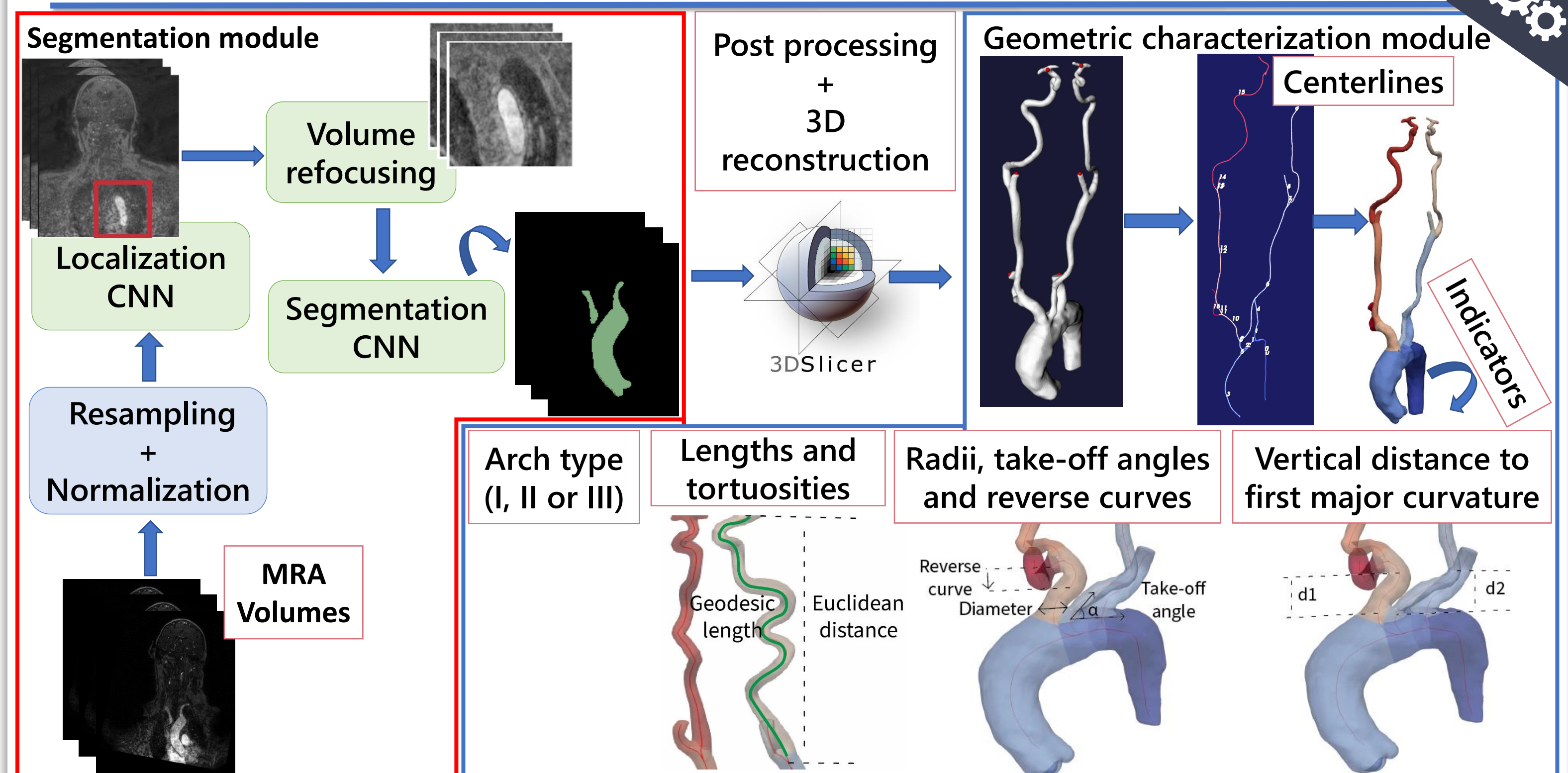


The type of aortic arch provides information on the complexity of navigation to the pathological area and helps to better plan procedures and choose the appropriate catheter.

2. Technical background

Task	Studies
SEGMENTATION	<ul style="list-style-type: none"> Studies are oriented towards the use of CTA volumes. U-Net variants are the most used architectures. Approaches like multi-view 2D CNNs [2] and multi-stage pipelines were used [3]. Segmentation is often pathology oriented e.g. segmentation of type B aortic dissection [3].
CHARACTERIZATION	<ul style="list-style-type: none"> Generic frameworks with sets of functions for geometric quantification of anatomical features and vessel characterization [4, 5]. These frameworks are suitable for engineers for research but not relevant for clinicians to use in a medical setting.

4. Segmentation and characterization pipeline

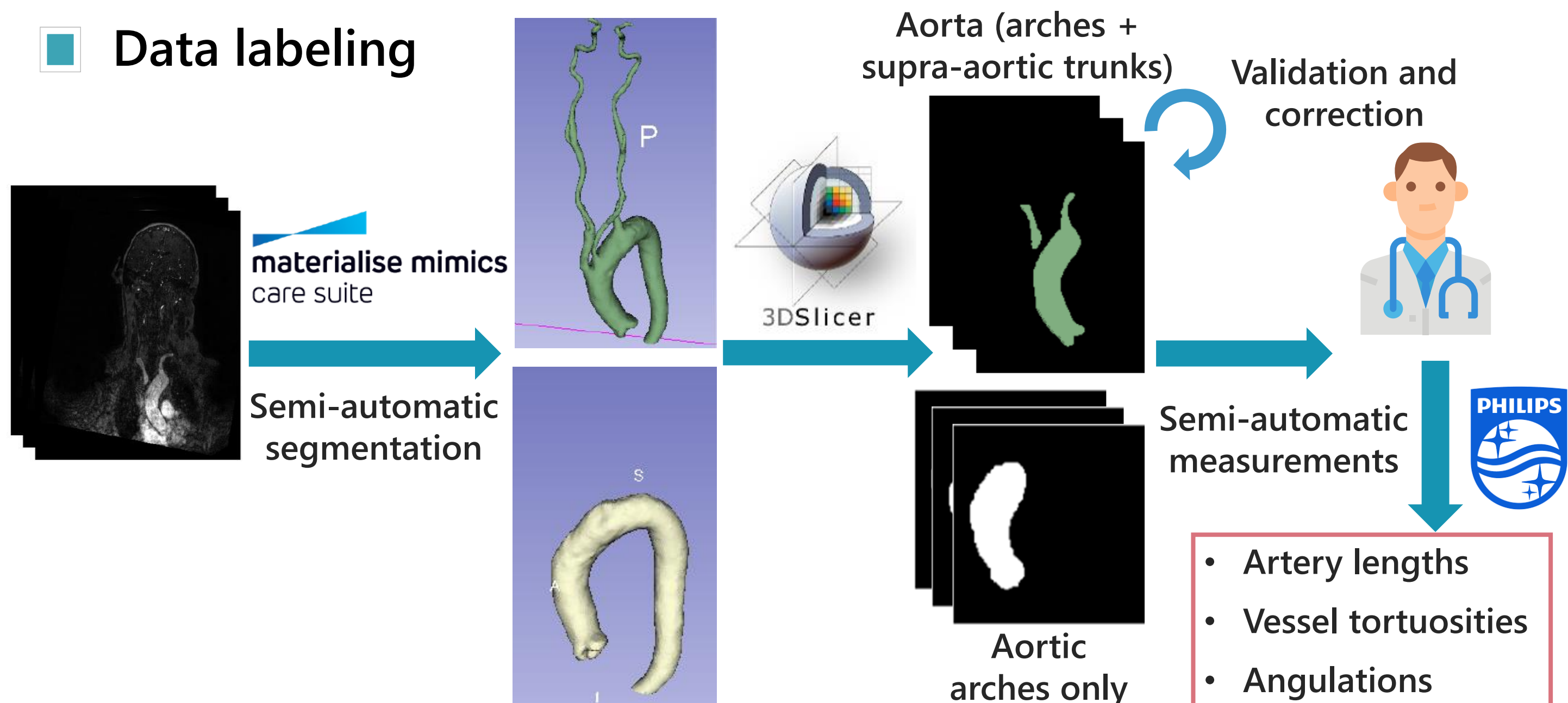


3. Data

22 patients underwent 3T MR exams of aortic arch, supra-aortic branches and intracranial vessels on Philips imaging system (Ingenia 3T, Best, The Netherlands).

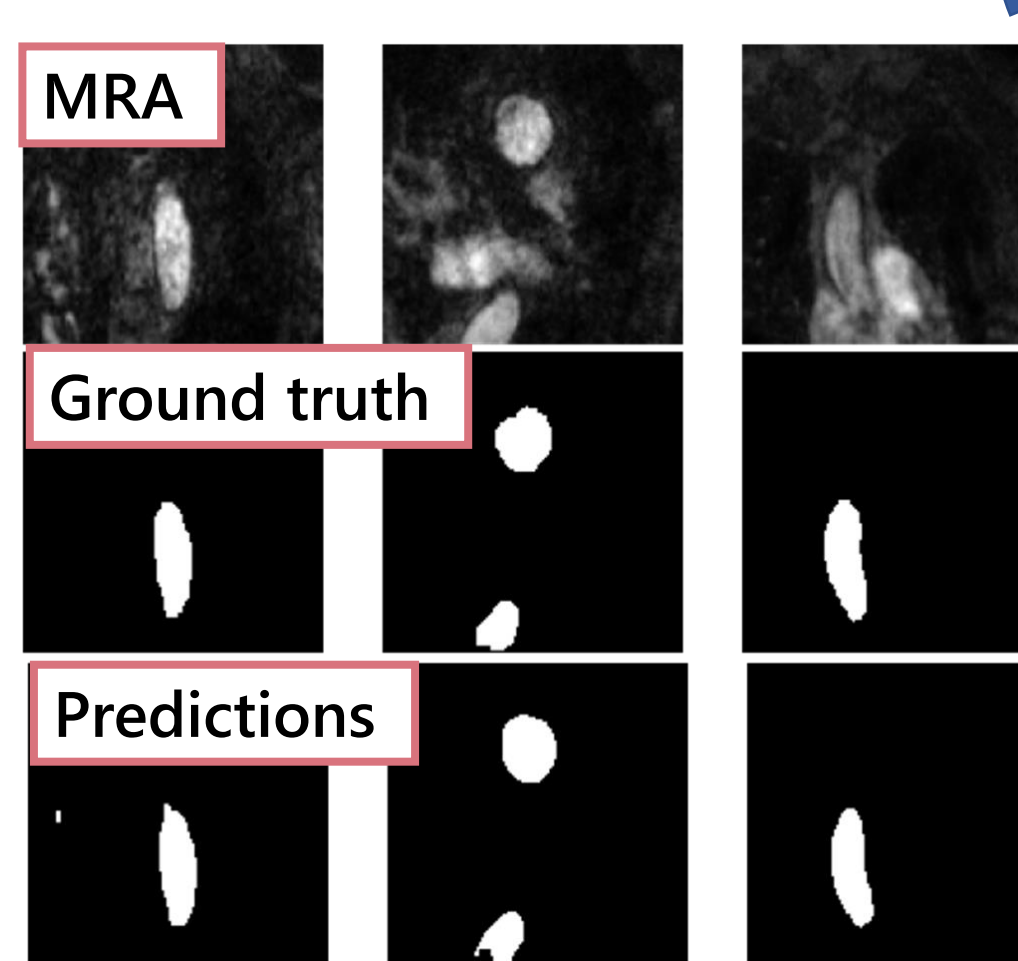
Acquisition parameters: coronal plane covering: 250 slices; active TR/TE = 5.5/2.2 ms; flip angle = 27°; number of excitations = 1; acquisition bandwidth = 476.7 Hz; FOV = 380 x 321; voxel size = 0.5 x 0.5 x 1.0 mm; imaging time = 69 sec; Bolus track injection technique.

Data labeling

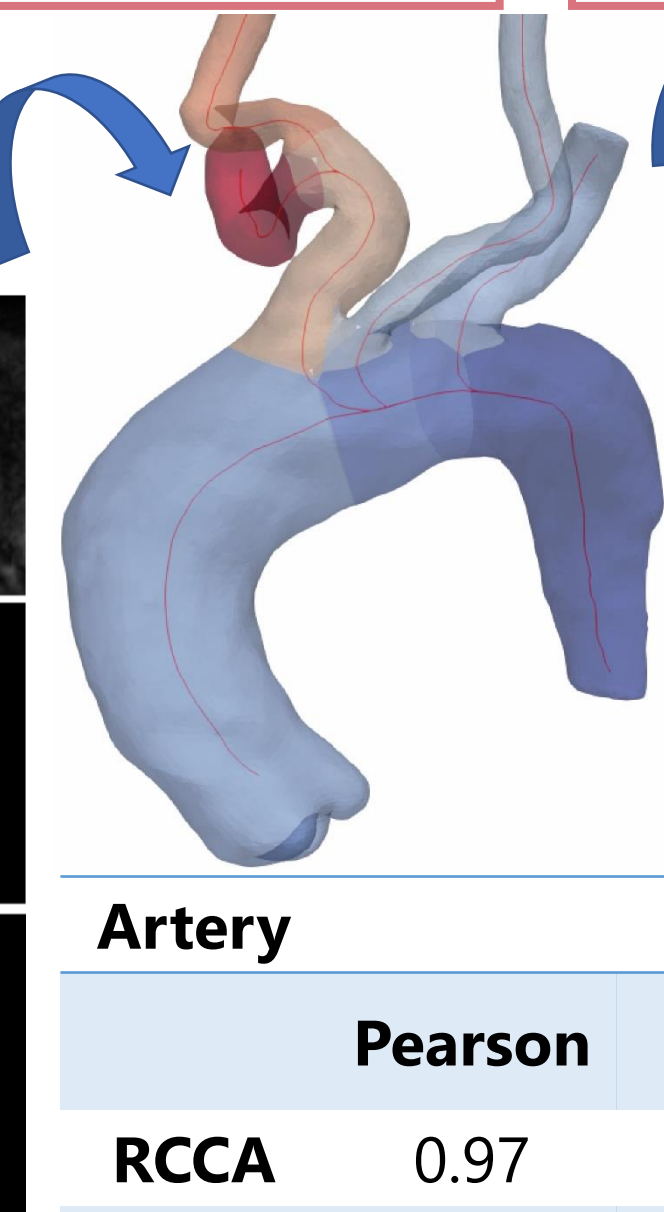


5. Results

- Dice score = 88.07%
- Precision = 84.10%
- Recall = 93.80%



3D reconstruction Geometric characterization

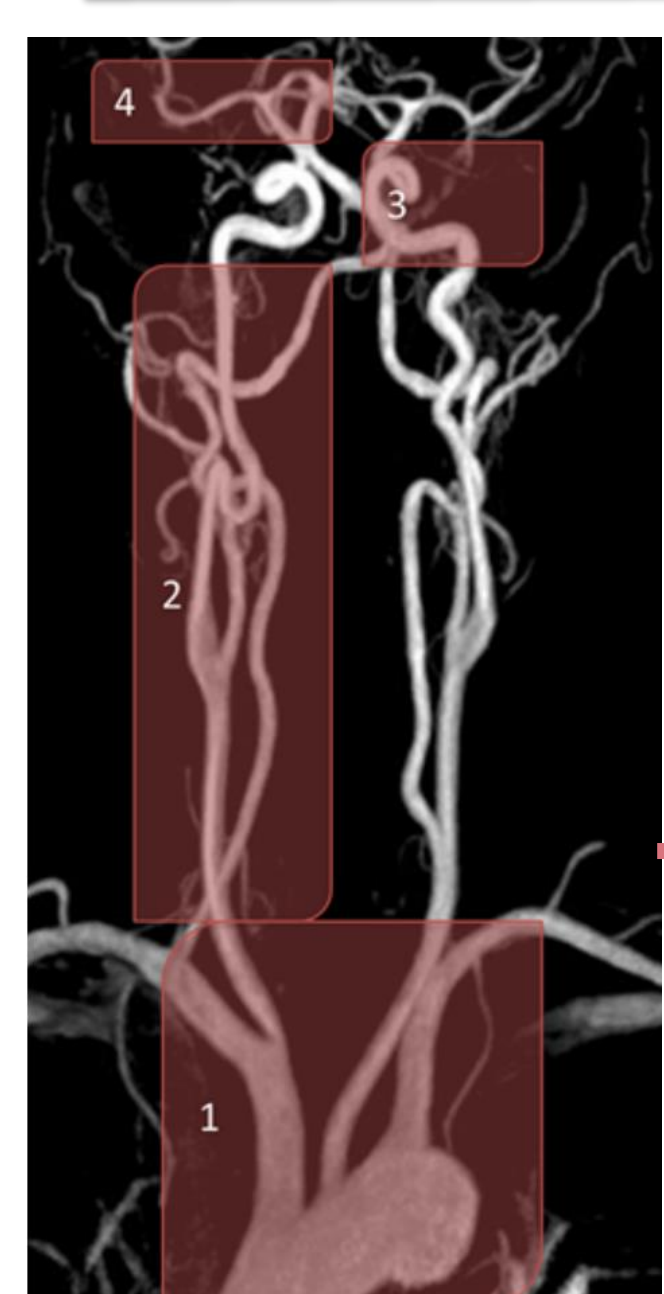


Arch type	Precision	Recall	F1-score
Type I	1.00	1.00	1.00
Type II	0.80	1.00	0.89
Type III	1.00	0.92	0.96

Reverse curves:
 > RCCA: Pearson correlation = 0.88
 > LCCA: Pearson correlation = 0.96

Artery	Length			Tortuosity		
	Pearson	RMSE	MAPE	Pearson	RMSE	MAPE
RCCA	0.97	5.97	1.75	0.93	0.06	3.32
LCCA	0.92	6.80	1.74	0.95	0.04	2.30

6. Conclusion and perspectives



- Complete analysis pipeline, from MRA images to high-level features: arch type, tortuosities, reverse curves, take-off angles and access difficulty after engaging an artery.
- Quantitative and qualitative validation by comparison to the medical reference (manual measurements and segmentations).

Clinical validation of our features on a diversified dataset in terms of demographic, pathological and imaging data of different modalities.

1) and 2) Aortic arch and supra-aortic branches, 3) and 4) intracranial vessels. Vascular structures of different anatomical characteristics: vessels become more tortuous, and their diameter decreases as they ascend to the brain.

3D extension of our CNN pipeline to better capture vessels of different diameters.

References

- S. Madhwal, V. Rajagopal, D. L. Bhatt, C. T. Bajzer, P. Whitlow, and S. R. Kapadia, "Predictors of difficult carotid stenting as determined by aortic arch angiography," *J Invasive Cardiol*, vol. 20, pp. 200-204, 2008.
- A. Fantazzini et al., "3D Automatic Segmentation of Aortic Computed Tomography Angiography Combining Multi-View 2D Convolutional Neural Networks," *Cardiovasc Eng Technol*, vol. 11, no. 5, pp. 576-586, 2020.
- D. Chen et al., "Multi-stage learning for segmentation of aortic dissections using a prior aortic anatomy simplification," *Med Image Anal*, vol. 69, p. 101931, 2021.
- M. Piccinelli, A. Veneziani, D. A. Steinman, A. Remuzzi, and L. Antiga, "A framework for geometric analysis of vascular structures: Application to cerebral aneurysms," *IEEE Trans Med Imaging*, vol. 28, pp. 1141-1155, 2009.
- H. A. Kjeldsberg, A. W. Bergersen, and K. Valen-Sendstad, "morphMan: Automated manipulation of vascular geometries," *J Open Source Soft*, vol. 4, 2019.