



HAL
open science

COVID-19 pandemic-associated chilblains: more links for SARS-CoV-2 and less evidence for high interferon type I systemic response

Didier Bessis, Sophie Trouillet-Assant, Léo-Paul Secco, Nathalie Bardin, Brigitte Blanc, Véronique Blatière, Christine Chable-Bessia, Christophe Delfour, Céline Girard, Jean-Christophe Richard, et al.

► **To cite this version:**

Didier Bessis, Sophie Trouillet-Assant, Léo-Paul Secco, Nathalie Bardin, Brigitte Blanc, et al.. COVID-19 pandemic-associated chilblains: more links for SARS-CoV-2 and less evidence for high interferon type I systemic response. *British Journal of Dermatology*, 2022, 187 (6), pp.1032-1035. 10.1111/bjd.21820 . hal-03930679

HAL Id: hal-03930679

<https://hal.science/hal-03930679>

Submitted on 3 Oct 2023

HAL is a multi-disciplinary open access archive for the deposit and dissemination of scientific research documents, whether they are published or not. The documents may come from teaching and research institutions in France or abroad, or from public or private research centers.

L'archive ouverte pluridisciplinaire **HAL**, est destinée au dépôt et à la diffusion de documents scientifiques de niveau recherche, publiés ou non, émanant des établissements d'enseignement et de recherche français ou étrangers, des laboratoires publics ou privés.



HAL
open science

COVID-19 pandemic-associated chilblains: more links for SARS-CoV-2 and less evidence for high interferon type I systemic response

Didier Bessis, Sophie Trouillet-Assant, Léo-Paul Secco, Nathalie Bardin, Brigitte Blanc, Véronique Blatière, Christine Chable-Bessia, Christophe Delfour, Céline Girard, Jean-Christophe Richard, et al.

► **To cite this version:**

Didier Bessis, Sophie Trouillet-Assant, Léo-Paul Secco, Nathalie Bardin, Brigitte Blanc, et al.. COVID-19 pandemic-associated chilblains: more links for SARS-CoV-2 and less evidence for high interferon type I systemic response. *British Journal of Dermatology*, 2022, 187 (6), pp.1032-1035. 10.1111/bjd.21820 . hal-03930679

HAL Id: hal-03930679

<https://hal.science/hal-03930679>

Submitted on 3 Oct 2023

HAL is a multi-disciplinary open access archive for the deposit and dissemination of scientific research documents, whether they are published or not. The documents may come from teaching and research institutions in France or abroad, or from public or private research centers.

L'archive ouverte pluridisciplinaire **HAL**, est destinée au dépôt et à la diffusion de documents scientifiques de niveau recherche, publiés ou non, émanant des établissements d'enseignement et de recherche français ou étrangers, des laboratoires publics ou privés.

Research letter

COVID-19 pandemic-associated chilblains: more links for SARS-CoV-2 and less evidence for high interferon type I systemic response

DEAR EDITOR, Since the onset of the SARS-CoV-2 pandemic, the direct causative role of the virus in COVID-19-associated chilblains (CAC) has remained under question due to the low rate of positivity to SARS-CoV-2 nasopharyngeal polymerase chain reaction (PCR) and blood serology.¹ Likewise, the suspected pivotal pathogenic role of upregulation of interferon type I (IFN-I) is mainly indirectly supported by assessment of *in situ* immune response.²

From April 2020 to January 2022, we prospectively assessed children and adults with new-onset CAC seen in the dermatology, infectious diseases, and adult and paediatric emergency departments, as well as the intensive care unit of the University Hospital of Montpellier. The study was approved by the local institutional review board (ID: 202000442).

Overall, 50 consecutive outpatients were seen, mostly white European and with a female predominance (sex ratio 1.5), a median age of 21 years (range 6–74) and a median body mass index of 19.8 kg m⁻² (range 14.8–26.6). CAC involved the feet and the hands, respectively, in 86% and 66% of patients. Raynaud phenomenon, BASCULE syndrome (Bier anaemic spots, cyanosis, urticaria-like eruption) and subungual splinter haemorrhages (Figure 1a) were present in 18%, 13% and 8%, respectively. Complete recovery, persistence and recurrence of CAC were noted, respectively, in 93% (median duration 12 weeks, range 1–30), 7% (12 months of follow-up) and 42.9%.

To assess the causal role of SARS-CoV-2 in CAC, we analysed SARS-CoV-2 real-time PCR in nasopharyngeal swabs and SARS-CoV-2 IgG, IgM and/or IgA serologies that were positive, in 10% and 23% of cases, respectively. Neutralizing antibody response using microneutralization assay was present in one case of isolated IgA antibodies. Serum SARS-CoV-2 nucleocapsid antigen detection was positive in 13%. Given all the virological tests, formal proof of SARS-CoV-2 infection could be established in 22% of patients, including 32% of children and 18% of adults. Using multivariate analysis, the comparison of the pertinent clinical, histologic and biologic characteristics of the patients with and without virologically proven SARS-CoV-2 infection was not significantly discriminating.

In total, 30 patients with CAC were assessed for whole-blood interferon-stimulated gene (ISG) expression, showing an increase of ISG compared with controls. To determine whether this ISG upregulation was different between CAC and other COVID-19 phenotypes, we analysed available values of the ISG scores within the first 50 days after onset of infectious symptoms in the cohorts of patients with CAC (*n* = 19), patients with COVID in the intensive care unit (*n* = 72) and nonhospitalized patients with COVID-19 and without CAC (*n* = 8). The latter group had COVID-19 confirmed by real-time PCR nasopharyngeal swab, and had a benign condition not requiring oxygenation, antibiotics, steroids or antiviral agents. The results are represented in Figure 1(b, c). In the CAC cohort, the first ISG measures at day 10 were similar to those of acute infection, and the overall kinetics revealed an identical shape compared with mild or severe COVID-19, turning to normal values around day 20. Two of 47 patients had circulating anti-IFN- α 2 antibodies above the cutoff (> 34 ng mL⁻¹).

In our series, the characteristics of CAC, including an overall balanced sex ratio, predominance of patients with low BMI, and clinical presentation and outcome, were broadly similar to those previously described.^{1,3} We found significant high frequencies of Raynaud phenomenon, BASCULE syndrome and subungual splinter haemorrhages, possibly explained by the prospective study design and an absence of clinical details in some of the large series.

The role of SARS-CoV-2 infection as a trigger of CAC has been widely debated due to the low levels of positive real-time PCR nasopharyngeal and IgG serologies, which are within the ranges, respectively, of 5.5–13.3% and 7.2–11.8%.^{1,4} In our series, by using a microneutralization assay for isolated IgA antibodies and serum SARS-CoV-2 nucleocapsid antigen detection, we found an overall virological confirmation of SARS-CoV-2 infection in 22% of patients, including 32% in children. This latter result is consistent with the frequency of 30–37% of seroconversion observed in previous series of children with asymptomatic and/or mild SARS-CoV-2 infection during the acute and convalescent periods,^{5,6} adding new arguments for a causative role of SARS-CoV-2 in CAC.

We confirmed that IFN-I signalling was increased in whole blood of patients with CAC but the kinetics of ISG over time were like those of SARS-CoV-2 infection without CAC. These results underscore the dynamics of systemic immune response to SARS-CoV-2 infection. Yet, previous histopathological findings revealed that CAC comprise a highly lymphocytic inflammatory process with an IFN-I microenvironment, as evidenced

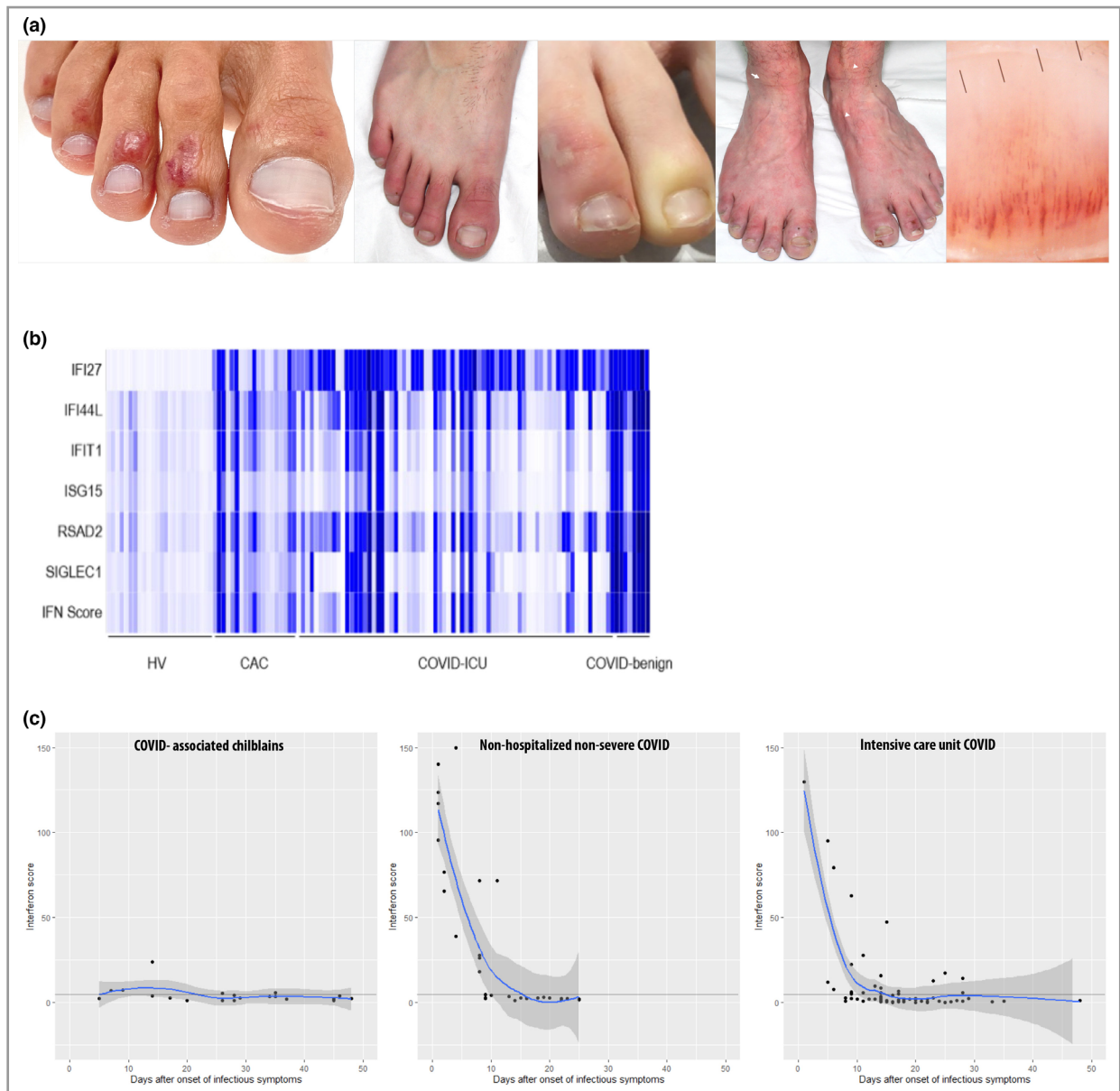


Figure 1 (a) Examples of clinical manifestations of COVID-19-associated chilblains. Left to right: (i) typical chilblain pattern with circumscribed red macules and papules overlying the dorsal and distal phalanges of the toes; (ii) acral erythema pattern with well-delineated symmetrical erythema and slight oedema located on the distal part of the toes; (iii) close-up view of typical chilblains and Raynaud phenomenon of the distal phalanges of the toes; (iv) chilblains of the toes associated with BASCULE syndrome, characterized by Bier anaemic macules, cyanosis, and multiple irregular red-orange macules (white arrows); (v) dilated capillaries and subungual splinter haemorrhages on the distal part of the nail plate. (b) Whole-blood interferon (IFN) score and relative expression of the six interferon-stimulated genes (ISGs) used for the IFN signature in healthy volunteers (HV; $n = 24$), a cohort of patients with COVID 19-associated chilblains (CAC; $n = 19$), a cohort of critically ill patients with COVID-19 in the intensive care unit (ICU; $n = 72$) and a cohort of nonhospitalized patients with nonsevere COVID-19 (benign; $n = 8$). Relative quantification of ISGs was performed using the nCounter analysis system (NanoString Technologies, Seattle, WA, USA). (c) Plasma ISG score (IFN signature). The cutoff value for positive IFN signature was > 3.2 (lower positive = $2.3-3.2$, negative < 2.3). From left to right: patients with COVID 19-associated chilblains ($n = 19$); nonhospitalized patients with nonsevere COVID-19 without CAC ($n = 8$); and critically ill patients with COVID-19 in the intensive care unit ($n = 72$). ISGs were analysed using restricted cubic splines and are displayed as continuous variables.

by extensive epidermal and dermal expression of MxA (myxovirus resistance protein) and pJAK1 (phosphorylated Janus kinase 1) in the endothelial cells and surrounding tissue, and rich presence of plasmacytoid dendritic cells.^{7,8} Thus, if a

pivotal role of IFN-I should be envisaged in the pathogenesis of CAC, it may be rather through local tissue-specific susceptibility to a physiological antiviral IFN-I response than to systemic overexpression of ISGs after COVID-19.

Didier Bessis ^{1,2} Sophie Trouillet-Assant,^{3,4}
 Léo-Paul Secco ¹ Nathalie Bardin,^{5,6} Brigitte Blanc,⁷
 Véronique Blatière,¹ Christine Chable-Bessia,⁸
 Christophe Delfour,⁹ Céline Girard ^{1,2}
 Jean-Christophe Richard,¹⁰ Nathalie Gros,⁸
 Vincent Le Moing,^{11,12} Nicolas Molinari,¹³ Valérie Pallure,¹⁴
 Amandine Pisoni,¹⁵ Nadia Raison-Peyron ¹
 Elisa Reynaud,¹⁶ Émilie Schwob,¹ Rémi Pescarmona,^{16,17,18}
 Quentin Samaran ¹ Marjolaine Willems,¹⁹
 Thierry Vincent,²⁰ Mircea T. Sofonea,^{21,22}
 Alexandre Belot^{17,23,24} and Édouard Tuillon^{2,15}

¹Department of Dermatology, Saint-Eloi Hospital, Competence Centre for Rare Skin Diseases and University of Montpellier, Montpellier, France; ²INSERM U1058, Montpellier, France

Correspondence: Didier Bessis.

Email: didierbessis@gmail.com

A full list of affiliations is available in Appendix S1 (see Supporting Information).

Funding sources: none.

Conflicts of interest: the authors declare they have no conflicts of interest.

Data availability statement: The data that supports the findings of this study are available in the supplementary material of this article.

Supporting Information

Additional Supporting Information may be found in the online version of this article at the publisher's website:

Appendix S1 Full list of affiliations.

References

- 1 Sánchez-García V, Hernández-Quiles R, de-Miguel-Balsa E et al. Are the chilblain-like lesions observed during the COVID-19 pandemic due to severe acute respiratory syndrome coronavirus 2? Systematic review and meta-analysis. *J Eur Acad Dermatol Venerol* 2022; **36**:24–38.
- 2 Arkin LM, Moon JJ, Tran JM et al. From your nose to your toes: a review of severe acute respiratory syndrome coronavirus 2 pandemic-associated pernio. *J Invest Dermatol* 2021; **141**:2791–6.
- 3 Gehlhausen JR, Little AJ, Ko CJ et al. Lack of association between pandemic chilblains and SARS-CoV-2 infection. *Proc Natl Acad Sci USA* 2022; **119**:e2122090119.
- 4 Rocha KO, Zanuncio VV, Freitas BAC, Lima LM. 'COVID toes': a meta-analysis of case and observational studies on clinical, histopathological, and laboratory findings. *Pediatr Dermatol* 2021; **38**:1143–9.
- 5 Toh ZQ, Anderson J, Mazarakis N et al. Comparison of seroconversion in children and adults with mild COVID-19. *JAMA Netw Open* 2022; **5**:e221313.
- 6 Tagarro A, Sanz-Santaefemia FJ, Grasa C et al. Dynamics of reverse transcription-polymerase chain reaction and serologic test results in children with SARS-CoV-2 infection. *J Pediatr* 2022; **241**:126–32.
- 7 Magro CM, Mulvey JJ, Laurence J et al. The differing pathophysiologies that underlie COVID-19-associated pernio and thrombotic retiform purpura: a case series. *Br J Dermatol* 2021; **184**:141–50.
- 8 Aschoff R, Zimmermann N, Beissert S et al. Type I interferon signature in chilblain-like lesions associated with the COVID-19 pandemic. *Dermatopathology (Basel)* 2020; **7**:57–63.