



HAL
open science

Bone marrow edema of the sacroiliac joint and anatomical variations: Look back the posterior bony excess. Comment on: "Spine abnormalities associated with bone edema on sacroiliac joints MRI in patients with non-inflammatory chronic back pain" by Marnas et al. Joint Bone Spine 2022;89:105436

Simon Cadiou, François Robin, Romain Lecigne, Pascal Guggenbuhl, Raphaël Guillin

► **To cite this version:**

Simon Cadiou, François Robin, Romain Lecigne, Pascal Guggenbuhl, Raphaël Guillin. Bone marrow edema of the sacroiliac joint and anatomical variations: Look back the posterior bony excess. Comment on: "Spine abnormalities associated with bone edema on sacroiliac joints MRI in patients with non-inflammatory chronic back pain" by Marnas et al. Joint Bone Spine 2022;89:105436. Joint Bone Spine, 2023, 90 (2), pp.105504. <10.1016/j.jbspin.2022.105504>. <hal-03930058>

HAL Id: hal-03930058

<https://hal.science/hal-03930058v1>

Submitted on 17 Jan 2023

HAL is a multi-disciplinary open access archive for the deposit and dissemination of scientific research documents, whether they are published or not. The documents may come from teaching and research institutions in France or abroad, or from public or private research centers.

L'archive ouverte pluridisciplinaire HAL, est destinée au dépôt et à la diffusion de documents scientifiques de niveau recherche, publiés ou non, émanant des établissements d'enseignement et de recherche français ou étrangers, des laboratoires publics ou privés.



HAL Authorization

Bone marrow edema of the sacroiliac joint and anatomical variations: look back the posterior bony excess. Comment on : “Spine abnormalities associated with bone edema on sacroiliac joints MRI in patients with non-inflammatory chronic back pain” by Marnas et al. Joint Bone Spine 2022;89:105436

Simon Cadiou ^a, François Robin ^b, Romain Lecigne ^{a,c}, Pascal Guggenbuhl, ^b Raphael Guillin ^a

^aRennes University hospital, Rennes, France

^bINSERM, Univ Rennes, INRAE, U1241, Institut NuMeCan (Nutrition Metabolisms and Cancer), Rennes, France

^cRennes 1 university, Rennes, France

Corresponding author : Simon Cadiou

sicadiou@gmail.com

Keywords: sacroiliac, bone marrow edema, anatomical variation, MRI, CT

Journal Pre-proof

We read with much interest the original article about bone marrow edema (BME) on magnetic resonance imaging (MRI) on sacroiliac joints (SIJs) in patients with non-inflammatory chronic back pain [1].

Marnas et al. found that static disorders and degenerative lesions of spine were associated to BME SIJs in patients with chronic back pain. Usually, in case of BME located in the upper and anterior part of the SIJs, the origin is mainly degenerative. If, BME is located in the inferior and central to posterior part of the SIJs, origin is mostly inflammatory [2,3]. Marnas et al. showed in an original study that BME of the SIJs in patients with mechanical back pain could be seen in the inferior (56.3%) and posterior parts (52.1%) too.

Anatomical variations of the SIJs are now well-identified causes of inflammatory sacroiliitis diagnosis false positive on MRI [4]. However they can be truly symptomatic and associated with pain [5]. As recently underlined by Braun et al. [6], anatomical variation of SIJs in healthy population is a very frequent condition (about one third of patients). In case of specific anatomical conditions other than degenerative spine, mechanical stresses and anatomical variations may also lead to abnormal mobility of SIJs. The mobility of SIJs is mainly represented by a movement of nutation and count-nutation in the sagittal plane, like a “swing” movement centered by the interosseous sacroiliac ligament, with an estimated range of motion of $2.27 \pm 1.35^\circ$ [7] and even more in case of ligament injuries. For example, pregnancy can cause SIJs pain due to asymmetric laxity [8]. Hyperlaxity or excessive stiffness with repeated micro-trauma can also cause degenerative and mechanical damages of SIJs [9].

Here, we described a case of a 27-y.o. female with chronic inflammatory low back pain suggestive of axial spondyloarthritis (SpA). A first MRI showed BME of SIJs with normal spine MRI. Given the lack of effectiveness of NSAIDs, the patient was referred to our center to start biological therapy. Clinical examination suggested a sacroiliac origin of the pain with the lack of HLA B27 antigen, a normal protein C reactive level (0.3 mg/dL) and no extra-articular feature of SpA. A new MRI of the SIJs (**Figure 1**) showed a slight BME on the left sacroiliac joint with dysmorphic and mechanical changes in the inferior part of SIJ on CT. A contralateral BME on the iliac and sacral bone was also noticed, without structural changes. We proposed that these bilateral BME was due to a mechanical stress on the right SIJ resulting from a mobility of SIJs favored by the left anatomical variation in the posterior part. In **Figure 2**, we can see a dysmorphic sacroiliac joint of the inferior part of the SIJs. It can be identified as a “circumflex accent” in semicoronal view on CT. The nutation, in a swinging movement, may lead to repeated microtrauma of sacrum on ilium, resulting in sclerosis and BME.

Many authors have described anatomical variations of the SIJ [4,10,11] but it can be difficult to apply this observation in clinical practice, especially on MRI, which visualize poorly the cortical bone and do not allow a semi-axial and semi-coronal reconstruction. As in our case and previous studies [3], a BME may be associated with SIJs pain. Patients with low back pain and posterior anatomical variations of the SIJs with BME can be grouped as a “posterior bony excess”: accessory sacroiliac joint, iliosacral complex and dysmorphic change, which are conditions leading to an excess of contact between ilium and sacrum and then cause BME in the articular part [4,11], like a “swinging” movements. These posterior bony excess variations could be then a specific cause of chronic mechanical low back pain, perhaps accessible to infiltration or local treatment as in Bertolotti’s syndrome or facet syndrome.

Our reports illustrate the usefulness of identifying anatomical variation of SIJs in case of BME, notably with a double assessment by CT and MRI. We suggest that the BME of SIJs in patients with non-inflammatory back pain described by Marnas et al. may not be due only to static disorders and spinal pathologies, but also sometimes to specific anatomical conditions of the SIJs in the posterior part.

References

- [1] Marnas G, Bernardy C, Cole A, Bellier A, Chapuis P, Romand X, et al. Spine abnormalities associated with bone edema on sacroiliac joints MRI in patients with non-inflammatory chronic back pain. *Joint Bone Spine* 2022;89:105436
- [2] O'Shea F, Boyle E, Salonen D, Ammendolia C, Peterson C, Hsu W, et al. Inflammatory and degenerative sacroiliac joint disease in a primary back pain cohort. *Arthritis Care & Research* 2010;62. <https://doi.org/10.1002/acr.20168>.
- [3] Baillet A, Gastaldi R, Ravey J-N, Gaudin P. Bone Marrow Edema in the Sacroiliac Joint- Degenerative Sacroiliac Joint Disease Might Be More Likely Than Spondyloarthritis: Comment on the Article by Turina et al. *Arthritis & Rheumatology (Hoboken, NJ)* 2017;69. <https://doi.org/10.1002/art.40075>.
- [4] El Rafei M, Badr S, Lefebvre G, Machuron F, Capon B, Flipo R-M, et al. Sacroiliac joints: anatomical variations on MR images. *Eur Radiol* 2018. <https://doi.org/10.1007/s00330-018-5540-x>.
- [5] Ziegeler K, Kreuzinger V, Proft F, Poddubnyy D, Hermann KGA, Diekhoff T. Joint anatomy in axial spondyloarthritis: strong associations between sacroiliac joint form variation and symptomatic disease. *Rheumatology (Oxford)* 2021;61:388–93. <https://doi.org/10.1093/rheumatology/keab318>.
- [6] Braun J, Fruth M, Baraliakos X. What's new on the sacroiliac joint ? Comment on: "Joint anatomy in axial spondyloarthritis: strong associations between sacroiliac joint form variation and symptomatic disease." *Rheumatology (Oxford)* 2022;61:475–7. <https://doi.org/10.1093/rheumatology/keab457>.
- [7] Lindsey DP, Perez-Orribo L, Rodriguez-Martinez N, Reyes PM, Newcomb A, Cable A, et al. Evaluation of a minimally invasive procedure for sacroiliac joint fusion – an in vitro biomechanical analysis of initial and cycled properties. *Med Devices (Auckl)* 2014;7:131–7. <https://doi.org/10.2147/MDER.S63499>.
- [8] Damen L, Buyruk HM, Güler-Uysal F, Lotgering FK, Snijders CJ, Stam HJ. Pelvic pain during pregnancy is associated with asymmetric laxity of the sacroiliac joints. *Acta Obstet Gynecol Scand* 2001;80:1019–24. <https://doi.org/10.1034/j.1600-0412.2001.801109.x>.
- [9] Vleeming A, Schuenke MD, Masi AT, Carreiro JE, Danneels L, Willard FH. The sacroiliac joint: an overview of its anatomy, function and potential clinical implications. *J Anat* 2012;221:537–67. <https://doi.org/10.1111/j.1469-7580.2012.01564.x>.
- [10] Tok Umay S, Korkmaz M. Frequency of anatomical variation of the sacroiliac joint in asymptomatic young adults and its relationship with sacroiliac joint degeneration. *Clin Anat* 2019. <https://doi.org/10.1002/ca.23539>.
- [11] Kiil RM, Jurik AG, Zejden A. Anatomical variation at the sacroiliac joints in young adults: estimated prevalence by CT and concomitant diagnostics by MRI. *Skeletal Radiol* 2022;51:595–605. <https://doi.org/10.1007/s00256-021-03843-3>.

Figure 1. Sacroiliac joint on CT showing semi-axial view (A and B) and semi-coronal view (C) in CT, and axial view (D and E) and coronal view (F) in MRI. The white arrow show the posterior dysmorphic change of the left ilium in its inferior, almost as an accessory SIJ. The star show the BME of the right SIJ.

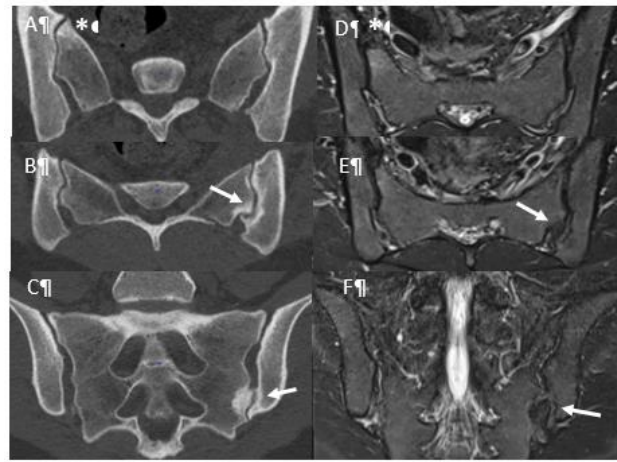


Figure 2. A and B : the coronal and axial view (respectively) on MRI, showing bilateral BME of the inferior and posterior part of the SIJs (arrows). C and D: semi-coronal (dotted line) and semi-axial (full line) on CT, showing in the same area than image A and B, bilateral sclerosis, bone cysts and gas (circumflex accent), suggesting mechanical lesions.

