



HAL
open science

Radiographic analysis of three royal effigies of Abomey (Benin)

Philippe Charlier, Christophe Moulherat, Anthony Abadie, Thierry
Subercazes, Isabelle Huynh-Charlier

► **To cite this version:**

Philippe Charlier, Christophe Moulherat, Anthony Abadie, Thierry Subercazes, Isabelle Huynh-Charlier. Radiographic analysis of three royal effigies of Abomey (Benin). *Forensic Imaging*, 2021, 27, pp.200478. 10.1016/j.fri.2021.200478 . hal-03925590

HAL Id: hal-03925590

<https://hal.science/hal-03925590>

Submitted on 16 Oct 2023

HAL is a multi-disciplinary open access archive for the deposit and dissemination of scientific research documents, whether they are published or not. The documents may come from teaching and research institutions in France or abroad, or from public or private research centers.

L'archive ouverte pluridisciplinaire **HAL**, est destinée au dépôt et à la diffusion de documents scientifiques de niveau recherche, publiés ou non, émanant des établissements d'enseignement et de recherche français ou étrangers, des laboratoires publics ou privés.

Copyright

Title:

Radiographic analysis of three royal effigies of Abomey (Benin)

Authors:

Charlier P (1,2), Moulherat C (1,2), Abadie A (3), Subercazes T (3), Huynh-Charlier I (2,4)

1. Musée du quai Branly - Jacques Chirac, 222 rue de l'Université, 75007 Paris, France.
2. Laboratoire Anthropologie, Archéologie, Biologie (LAAB), Université Paris-Saclay (UVSQ), 2 avenue de la source de la Bièvre, 78180 Montigny-Le-Bretonneux, France.
3. IRCGN – Département balistique, Unité d'expertise Outre-Mer, 5 boulevard de l'Hautil, 95037 Cergy-Pontoise, France.
4. Département de radiologie, CHU Pitié-Salpêtrière (AP-HP), boulevard de l'hôpital, 75013 Paris, France.

Corresponding author:

Philippe Charlier MD PhD LittD

Musée du quai Branly - Jacques Chirac, 222 rue de l'Université, 75007 Paris, France.

philippe.charlier@uvsq.fr

Key-words:

Medical anthropology; restoration; history of art; expertise; firearm wound.

Abstract:

Three magical effigies (*bocio*) dedicated to kings of the ancient kingdom of Danhomey (Abomey) were examined on radiography: their internal constitution and the details of their consecration are thus better known. The results are presented here, as well as the associated anthropological and historical analyses.

Title:

Radiographic analysis of three royal effigies of Abomey (Benin)

Key-words:

Medical anthropology; restoration; history of art; expertise; firearm wound.

Abstract:

Three magical effigies (*bocio*) dedicated to kings of the ancient kingdom of Danhomey (Abomey) were examined on radiography: their internal constitution and the details of their consecration are thus better known. The results are presented here, as well as the associated anthropological and historical analyses.

Text:

Introduction

In 1892, the French military campaign under the authority of colonel (then general) Dodds in the territory of present-day Benin, led to the defeat of King Béhanzin who burnt down his palace in Abomey before the arrival of foreign troops. Many ritual objects have been found in the rubble, but also in pits intended to hide the most precious goods. The most "beautiful", considered by Westerners as works of art, were transported to Europe. When he returned from his expedition, Dodds donated 26 objects to the Musée Ethnographique du Trocadéro (Paris) (**Figure 1**), including 3 life-size statues now kept at the musée du quai Branly - Jacques Chirac.¹ Prior to their restitution process to Benin, following a declaration by the President of the French Republic Emmanuel Macron in 2017, an interdisciplinary scientific study was set up, aiming to better understand the precise context in which these ritual objects were created, and their evolution over time. Here, we will detail the results of the radiological study.

Material and method

The first statue is associated with King Ghézo, who reigned from 1818 to 1858. Measuring 214 centimetres and weighing 220 kilograms, it depicts an individual with a human figure, but whose entire body, painted in dark color, is covered with metal strips (formerly painted?) and a metallic sex-cover also painted (Inv.No. 71.1893.45.1). The second statue corresponds to King Glélé, son of the previous one, who reigned from 1858 to 1889. Measuring 179 centimetres and weighing 57 kilograms, it depicts a human individual with the head of a lion, with the body painted red excluding one kind of short pants of blue colour and a metallic sex-cover of the same colour (Inv. No. 71.1893.45.2). The third and last statue symbolizes King Béhanzin, son of the previous one, who reigned from 1889 to 1894 (Inv. No 71.1893.45.3). Measuring 160 centimetres and weighing 55 kilograms, it depicts a hybrid man-fish individual, painted entirely in water green, without preserved sex-cover.³

Given the impossibility, for reasons of scope, to perform a CT-scan of these three objects, an in-situ X-ray examination was performed according to the following protocol: use of a portable and digital radiography device (Fox-Rayzor Inspection System), associated with a pulse X-ray generator delivering a voltage of 270 kV.

Results / discussion

Far from being mere royal effigies, these statues are also the depositories of part of the sovereign's magic and religious force. They therefore assume a supernatural character, and serve to protect the king's troops, but also nearby dwellings (palaces, pavilions, etc.). We can therefore assimilate them to *bocio*, i.e. these statuettes usually stuck in the ground, coarsely

carved (not figurative but rather symbolic), used to repel evil spirits and to keep them away from homes or living quarters.^{4,5}

Because of its instability and its "foot", the *bocio* of Ghézo was probably stuck in the ground, and therefore motionless in the palace of Abomey. The *bocio* of Glélé and Béhanzin, on the other hand, with their broad and stable base, were with the armies and preceded them to bring them luck, as if it were a part of the king's body which accompanied them and provided them with magic power. All three of them are human/animal hybrid beings (even that of Ghézo, which has been modified *a posteriori*: either that the bird head initially enshrined on the human figure has been removed, or that the bird head has been re-sculpted into a human figure?).

The general appearance of the *bocio* de Ghézo obeys the context of the « strong name » (that is to say the magic and symbolic name of the king pronounced by himself at the time of his consecration): "The *gué* [red cardinal bird] does not set the bush on fire"; thus, it is the figuration of a bird-man who was chosen to suggest the person of the king in this sculpture. The general appearance of Glélé's *bocio* also corresponds to his strong name: "I am the lion cub that sows terror when its teeth have grown" (the lion has become, the symbol of this sovereign). Finally, Béhanzin's *bocio* features a shark in the aftermath of his enthronement declaration: "The daring shark has disturbed the bar" (in other words, the king will be the shark who will overturn the boats of the French troops)..

The radiological examination of Ghézo's *bocio* confirmed the high density of the metal lamellae inserted in the wood matrix, very numerous fasteners being externally invisible due to overlapping by successive layers of paint (**Figure 2**). It was also possible to confirm the "industrial" nature of some of these metal lamellas (probably a reuse of material of Western origin, perhaps of maritime origin?). Other metal structures (large nails, must be bent) correspond to systems of attachment of the upper limbs which are fixed on the trunk of the statue (4 nails on the right side, 2 on the left side). In addition, an optically empty cavity was visualized at the level of the anatomical right shoulder, of approximately 25 cm of long axis (in the shape of "right block"), which can correspond either to a hiding place intended to preserve magic substance at the time of the consecration of this object (textiles or plant elements, taking into account their radio-transparency, and in the absence of an emptying of this cavity), either to fit the end of the right upper limb into the trunk of the statue. No similar cavity exists on the left side. Finally, no exogenous material was observed at the level of the cephalic end.

Radiological examination of Glélé's *bocio* revealed an old fracture of the left upper limb at the level of half of the forearm, with consolidation by two large iron nails and 7 small nails (**Figure 3**). In addition, the upper left member is fixed to the trunk by 5 small nails, while the upper right member is fixed by a very large nail and 6 small nails. The radiographies also revealed the presence of 4 medium-sized nails inserted vertically on the face just in front of the ears, and 11 small nails driven in a circular fashion around the muzzle, which may correspond to the old

attachments of a mane that is now gone, intended to reinforce the feline aspect of the statue. Consolidation with dense exogenous material exists on an old crack at the base of the neck. Five nails are present at the insertion of the tail (driven into the statue), probably intended to support an organic tissue now lost (fur?) Comparable to the normal anatomy of felines (**Figure 4**); three nails overlap, corresponding to the attachment of the loincloth. Finally, a cavity comparable to that of the Ghézo's *bocio* ("right block" of about 30 cm of major axis) was highlighted, with the same diagnostic hypotheses; the presence of a roughly conical formation inserted therein tends to favor the hypothesis of an insertion cavity of the right upper limb. In projection of this cavity, there is a crushed metal formation of approximately 1.4 cm of major axis, visible externally, initially considered as a projectile from a firearm (perhaps related to the shots fired on these royal effigies from the « Senegalese tirailleurs » and local populations during their transport between Abomey and the Atlantic coast, intended to undermine the magic power of the sovereigns through their *bocio*?)¹ A close examination put to light this was a nail.

Radiological examination of Béhanzin's *bocio* made it possible to better specify the attachment system of the three fins (2 lateral and one ventral), each using two large nails (**Figure 5**). The right upper limb, broken (or initially in two parts?) at the level of the fold of the elbow, was consolidated by a large nail and four small nails; the right upper limb is held in place only by one large nail, while the right is held in place by two large nails and four small nails. No cavity is present within the body volume, unlike the *bocio* of Ghézo and Glélé. At the level of the head, two medium-sized nails are located under the mouth (visible from the outside), as well as 9 small nails all around the mouth opening: it is probably an old system of attachment of organic materials (plants?) now gone. At the level of the perineum, four medium-sized nails are still inserted, corresponding to the attachment system of a loincloth (made of metallic material, as for the other two *bocio*?) which has now disappeared. Finally, at the level of the left leg (medial face) and the lower half of the right thigh, the initial matrix of wood has been replaced by quadrangular wood inserts of lower density, corresponding to old restorations (linked to an ancient deterioration *bocio* during its current use? or an old restoration following ballistic wounds caused by gunshot bullets during the conflict of 1892?).¹

Conclusion

This short study will have shown all the interest still being taken in the radiological examination of museum pieces whose overly large size still prevents the carrying out of CT examinations. Here, not only the internal constitution of the objects was informed, but also their mode of manufacture, their various stages of ancient restoration, and the traumatic vicissitudes of their conditions of extraction outside the country of origin. It is the entire biography of these "people-objects" that it has been possible to highlight, for the benefit of the history of art, but also of the history of Benin.

Acknowledgment

To the society Re.S.Artes (Bordeaux), for technical support.

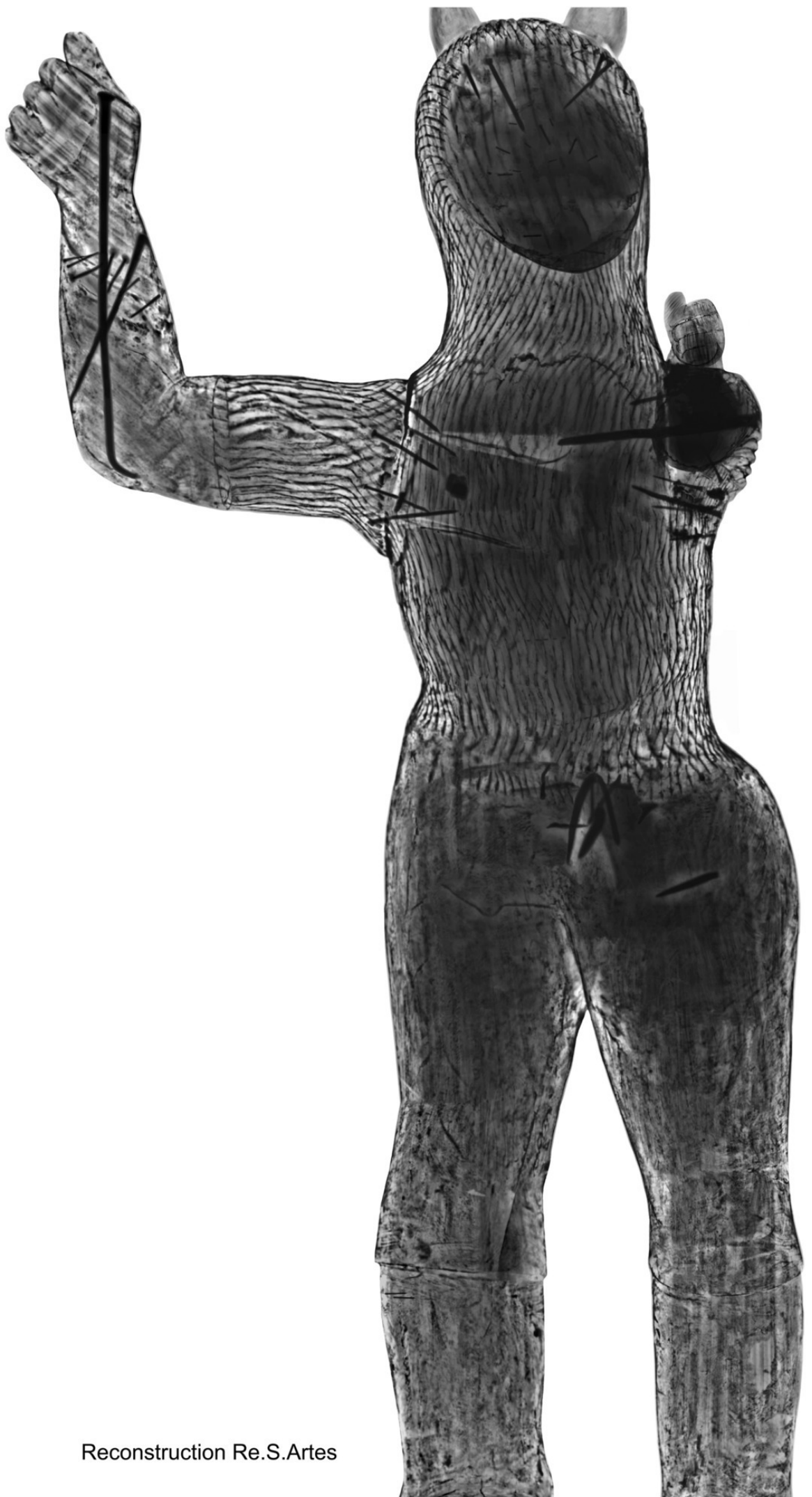
References

1. Beaujean G. L'art de cour à Abomey. Dijon, Presses du réel, 2019.
2. <https://www.elysee.fr/emmanuel-macron/2017/11/28/discours-demmanuel-macron-a-luniversite-de-ouagadougou>
3. Joubert H, Beaujean G. Béhanzin, roi d'Abomey. Cotonou, Fondation Zinsou, 2006.
4. Ono Y, Kerchache J. Vaudou. Paris, Fondation Cartier, 2011.
5. Charlier P. Vaudou. Les hommes, la nature et les dieux (Bénin). Paris, Plon, collection Terre Humaine, 2021.



Abb. 221. Die drei Kämpfer: Bronze, Bildhauer Fritz Koenig, 1921. Die drei Kämpfer sind die drei Kämpfer der Dichtung 'Die drei Kämpfer' von Fritz Koenig.





Reconstruction Re.S.Artes





Reconstruction Re.S.Artes