



**HAL**  
open science

## **Globus Pallidus internus deep brain stimulation: An alternative treatment for Epilepsia partialis continua?**

Edouard Courtin, Etienne Guillaud, Emmanuel Cuny, Jacques Taillard, Pierre Burbaud, Dominique Guehl, Jérôme Aupy

### ► To cite this version:

Edouard Courtin, Etienne Guillaud, Emmanuel Cuny, Jacques Taillard, Pierre Burbaud, et al.. Globus Pallidus internus deep brain stimulation: An alternative treatment for Epilepsia partialis continua?. *Brain Stimulation*, 2022, 15 (3), pp.635-637. <10.1016/j.brs.2022.04.011>. <hal-03923651>

**HAL Id: hal-03923651**

**<https://hal.science/hal-03923651v1>**

Submitted on 13 Mar 2024

**HAL** is a multi-disciplinary open access archive for the deposit and dissemination of scientific research documents, whether they are published or not. The documents may come from teaching and research institutions in France or abroad, or from public or private research centers.

L'archive ouverte pluridisciplinaire **HAL**, est destinée au dépôt et à la diffusion de documents scientifiques de niveau recherche, publiés ou non, émanant des établissements d'enseignement et de recherche français ou étrangers, des laboratoires publics ou privés.



HAL Authorization



## Globus Pallidus internus deep brain stimulation: An alternative treatment for Epilepsia partialis continua?



Dear Sir,

Resective surgery may involve an unacceptable risk of permanent neurological deficits in drug-resistant epilepsies so alternative strategies are required. In this regard, palliative neuromodulation has shown promise [1]. Epilepsia partialis continua (EPC) is an epileptic syndrome defined as a subclass of focal motor status epilepticus manifesting with frequent repetitive epileptic myoclonia affecting the limbs and/or face, usually arrhythmic. Even if its course and underlying aetiologies are largely heterogeneous, EPC frequently tends to become highly medically refractory [2]. However, due to the early involvement of the primary motor cortex, resective epilepsy surgery carries an inherent functional risk. Here we report the first clinical and neurophysiological data obtained in a patient suffering from EPC and receiving unilateral globus pallidus internus (GPI) deep brain stimulation (DBS) treatment, who was implanted with a novel sensing-enabled neurostimulator.

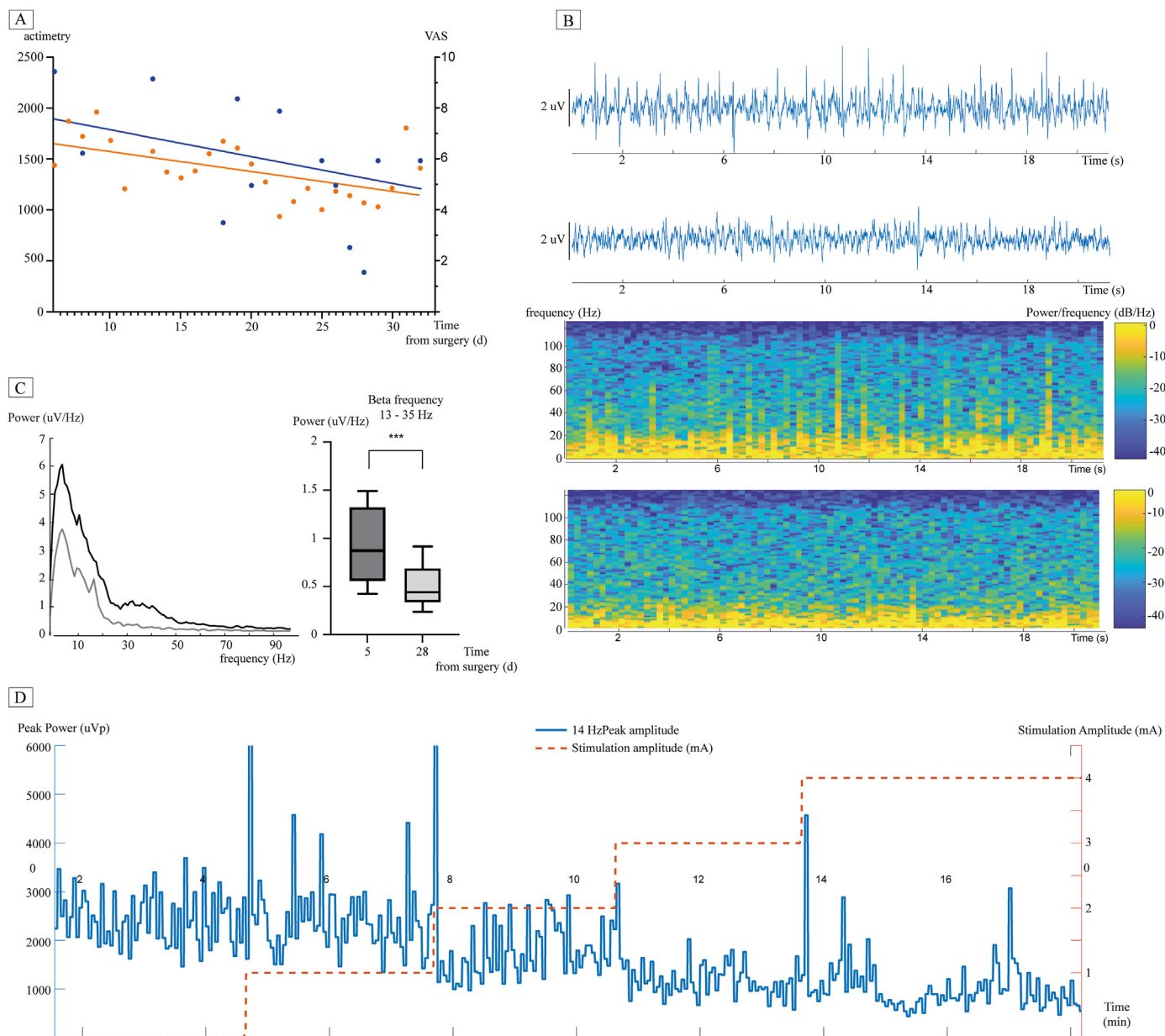
A 32-year-old patient with unremarkable personal and family medical history started his epilepsy in 2008 by right focal motor seizures characterized by left brachiofacial myoclonus and secondary tonic-clonic bilateralisations. Seizures were initially controlled by single antiepileptic medication (AED). MRI was normal. Extensive workup including search for an inflammatory, infectious or paraneoplastic aetiology was negative. In 2017, without any contributing factors, his epilepsy gradually worsened to chronic persistent non-progressive EPC 3a [3] despite adequate medication. One year of vagus nerve stimulation (VNS) was ineffective and he developed permanent left brachiofacial myoclonus with progressive hemiparesis. EEG showed continuous spike-and-wave pseudo-periodic activity concomitant with myoclonic activity (see supplemental data). Due to the high functional risk carried by primary motor cortectomy, a unilateral right quadripolar Percept PC DBS electrode (Medtronic 3389) was implanted in the sensorimotor part of the GPI without per- or postsurgical complications. Therapy was provided as a humanitarian device. DBS electrode localisation was confirmed using the advanced processing pipeline in Lead-DBS (see supplemental Data for coordinates) [4]. AED and VNS were not discontinued.

The patient was monitored three times a week during the month following implantation by three independent neurologists expert in epilepsy and DBS programming (DG/JA/EC). DBS efficacy was evaluated using both visual analogic scale (VAS) and actigraphy recordings (MotionWatch8, Cambridge Neurotechnology, UK, Fig. 1a). Effectiveness was assessed with different monopolar stimulation settings: best stimulation results were obtained with contacts 0 and 1, pulse-width 60 $\mu$ s, frequency 130 Hz, amplitude

3mA. The electrode was connected to a sensing-enabled Percept PC neurostimulator allowing regular local field potential (LFP) recordings with or without stimulation, at rest with eyes closed (bipolar montage between two adjacent contacts, sampling frequency of 250Hz, low pass filter at 100Hz and high pass filter at 1Hz). Systematic bipolar recordings performed off stimulation revealed LFP oscillations in the low beta band (14Hz; between each pair of adjacent contacts). This target frequency was selected for chronic recordings when stimulation was switched on (recordings between contacts 0 and 2, stimulation through contact 1). Post-hoc time-frequency (TF) and power spectrum density (PSD) analyses were performed at day 5 (beginning of daily follow-up) and day 28 (end of daily follow-up) after implantation.

A linear progressive clinical improvement was confirmed by both VAS and actimetry data ( $r^2 = 0.24$  and  $0.3$  respectively; Fig. 1a). Unfortunately, even though their frequency and intensity were reduced, the myoclonic episodes did not abate completely and the patient's disability persisted. LFP recordings in the GPI showed epileptic paroxysms characterized by repetitive spike-and-wave activity that tended to be less frequent at the end of follow-up, as confirmed by TF analysis (Fig. 1b). Concomitantly we observed a decrease in beta- and gamma-LFP PSD amplitude between the beginning and the end of follow-up (respectively  $p < 0.0002$  and  $< 0.0001$  - Fig. 1c). Finally, during continuous GPI LFP recordings (day 28 after implantation) around the low beta frequency ( $14 \pm 2$  Hz), we observed that the LFP oscillations had decreased in amplitude along with an increase in stimulation amplitude, with an apparent dose effect (Fig. 1d).

To our knowledge, this is the first report of clinical and electrophysiological data obtained in a patient suffering from EPC under unilateral GPI DBS. We evidenced a slight clinical improvement in myoclonic activity that was confirmed by both visual analogic scale assessment and actigraphy. This partial improvement could be due to the localisation of the implanted electrode, which might have been positioned too anteriorly and medially to correctly stimulate the sensorimotor part of the GPI. Epileptic paroxysms recorded within the GPI confirmed a potential downstream propagation of seizures from the motor cortex toward the ipsilateral basal ganglia (BGs) network. In addition, GPI LFP activity in the beta band was decreased by high frequency stimulation, suggesting a putative link between epileptic activity generated by the primary motor cortex and oscillatory activity recorded in the BGs. Inferring from correlative relationship between a given frequency band (e.g., beta) and motor dysfunction current theories have assigned prokinetic or anti-kinetic roles to the various oscillatory activities based on their frequency bands [5]. However, it is plausible that



**Fig. 1.** Clinical course with deep electrophysiological recordings during DBS in the sensorimotor part of the GPI in EPC. A: Clinical course after surgery. Orange dots: VAS evolution (0 considered as “no myoclonic activity” and 10 as “maximal myoclonic activity”). Orange line: linear regression analysis of VAS evolution over time ( $r = 0.24$ ). Purple dot: actigraphy evolution (0 considered as no actigraphic activity). Purple line represents linear regression analysis of actigraphy evolution over time ( $r = 0.3$ ). B: LFP recorded in GPI (bipolar montage between contacts 1 and 2, sampling frequency of 250Hz, low-pass filter at 100Hz and high-pass filter at 1Hz) and their respective corresponding time-frequency analyses. In each figure, top trace was recorded 5 days after surgery and shows an almost continuous spike-and-wave activity. Bottom trace recorded 28 days after surgery shows clear-cut incomplete decrease in spike-and-wave activity. C: Left panel shows power spectrum analysis density at day 5 after surgery (dark grey line) and 28 days after surgery (light grey line). A peak around 13 Hz was observed in both conditions. PSD analysis shows a statically significant decrease in beta frequency (13–35 Hz) at day 28 compared to day 5 after surgery (Mann-Whitney test,  $p < 0,0002$ ), suggesting an effect of DBS neuromodulation on GPI beta oscillations. D: Continuous GPI LFP recordings (28 days after surgery) in low beta frequency ( $14 \pm 2$  Hz). It shows that LFP oscillations decreased in amplitude along with an increase in stimulation amplitude with an apparent dose effect. (For interpretation of the references to colour in this figure legend, the reader is referred to the Web version of this article.)

the expression of oscillatory activity in a given frequency band may vary in the various neuronal populations of the basal ganglia cortical network possibly reflecting very different generation mechanisms and likely driving varied motor correlates. The fact that focal seizures involve widespread interaction between the cortices and BGs is now well accepted [6–8]. Other neuromodulation targets might be of potential interest. DBS of the anterior nucleus of the thalamus has been shown to partially reduce seizure

frequency in refractory epilepsies [9]. In addition, a recent study showed that subthalamic nucleus (STN) DBS could reduce interictal spikes acting with a frequency-dependent upstream modulatory effect over the motor cortex [10]. Nevertheless, the results of these studies require confirmation. STN is usually targeted in hypokinetic syndromes (e.g. parkinson’s disease) while GPI is frequently targeted in hyperkinetic syndromes such as dyskinesia. In addition GPI remains in primates the main BGs output structure. Therefore,

Its BDS modulation might offer a more direct opportunity to inhibit thalamo-cortical activity than STN or SNr stimulation. Moreover, we recently showed that acute changes in striatal GABAergic homeostasis induce striato-cortical synchronization, leading to focal bilateral tonic-clonic seizures in non-human primate (NHP) [11]. This is a strong argument in favour of the active role of BGs in controlling cortical activity during focal seizures, as suggested by chemo- or optogenetic manipulation of this subcortical pathway in mice [12]. As GPi activity is modulated by both direct and indirect pathways and inhibits thalamic and thus cortical activity, the GPi sensory-motor territory could be a potential target for refractory EPC in human. Altogether, these results suggest that patients in whom the motor cortex is predominantly involved (focal motor seizures, progressive myoclonic epilepsies, etc) could benefit from GPi neurostimulation due to the involvement of the cortico strio-pallido thalamo cortical motor loop. Although these results need to be confirmed in larger cohorts, we propose that the sensorimotor territory of the GPi could be a potential target for refractory EPC in human.

#### Declaration of competing interest

The authors declare that they have no known competing financial interests or personal relationships that could have appeared to influence the work reported in this paper.

#### Appendix A. Supplementary data

Supplementary data to this article can be found online at <https://doi.org/10.1016/j.brs.2022.04.011>.

#### References

- [1] Ryvlin P, Rheims S, Hirsch LJ, Sokolov A, Jehi L. Neuromodulation in epilepsy: state-of-the-art approved therapies. *Lancet Neurol* 2021;20:1038–47. [https://doi.org/10.1016/S1474-4422\(21\)00300-8](https://doi.org/10.1016/S1474-4422(21)00300-8).
- [2] Mameniskienė R, Wolf P. Epilepsia partialis continua: a review. *Seizure* 2017;44:74–80. <https://doi.org/10.1016/j.seizure.2016.10.010>.
- [3] Mameniskienė R, Bast T, Bentes C, Canevini MP, Dimova P, Granata T, et al. Clinical course and variability of non-Rasmussen, nonstroke motor and sensory epilepsy partialis continua: a European survey and analysis of 65 cases. *Epilepsia* 2011;52:1168–76. <https://doi.org/10.1111/j.1528-1167.2010.02974.x>.
- [4] Horn A, Kühn AA. Lead-DBS: a toolbox for deep brain stimulation electrode localizations and visualizations. *Neuroimage* 2015;107:127–35. <https://doi.org/10.1016/j.neuroimage.2014.12.002>.
- [5] Brown P. Oscillatory nature of human basal ganglia activity: relationship to the pathophysiology of Parkinson's disease. *Mov Disord* 2003;18:357–63. <https://doi.org/10.1002/mds.10358>.
- [6] Devergnas A, Piallat B, Prabhu S, Torres N, Louis Benabid A, David O, et al. The subcortical hidden side of focal motor seizures: evidence from micro-recordings and local field potentials. *Brain* 2012;135:2263–76. <https://doi.org/10.1093/brain/awz134>.
- [7] Aupy J, Wendling F, Taylor K, Bulacio J, Gonzalez-Martinez J, Chauvel P. Cortico-striatal synchronization in human focal seizures. *Brain* 2019;18. <https://doi.org/10.1093/brain/awz062>. 63–14.
- [8] Brodovskaya A, Shiono S, Kapur J. Activation of the basal ganglia and indirect pathway neurons during frontal lobe seizures. *Brain* 2021;144:2074–91. <https://doi.org/10.1093/brain/awab119>.
- [9] Fisher R, Salanova V, Witt T, Worth R, Henry T, Gross R, et al. Electrical stimulation of the anterior nucleus of thalamus for treatment of refractory epilepsy. *Epilepsia* 2010;51:899–908. <https://doi.org/10.1111/j.1528-1167.2010.02536.x>.
- [10] Ren L, Yu T, Wang D, Wang X, Ni D, Zhang G, et al. Subthalamic nucleus stimulation modulates motor epileptic activity in humans. *Ann Neurol* 2020;4. <https://doi.org/10.1002/ana.25776>. S83–32.
- [11] Aupy J, Ribot B, Dovero S, Biendon N, Nguyen T-H, Porras G, et al. Acute striato-cortical synchronization induces focal motor seizures in primates. *Cerebr Cortex* 2020;12. <https://doi.org/10.1093/cercor/bhaa212>. 366–12.
- [12] Chen Bin, Xu C, Wang Y, Lin W, Wang Y, Chen L, et al. A disinhibitory nigro-parafascicular pathway amplifies seizure in temporal lobe epilepsy. *Nat Commun* 2020:1–16. <https://doi.org/10.1038/s41467-020-14648-8>.

Edouard Courtin

Univ. Bordeaux, CNRS, IMN, UMR 5293, F-33000, Bordeaux, France

CHU de Bordeaux, Department of Clinical Neurophysiology, 33076, Bordeaux, France

Etienne Guillaud

Univ. Bordeaux, CNRS, INCIA, UMR 5287, F-33000, Bordeaux, France

Emmanuel Cuny

CHU de Bordeaux, Department of Neurosurgery, 33076, Bordeaux, France

Jacques Taillard

Univ. Bordeaux, CNRS, SANPSY, UMR 3413, F-33000, Bordeaux, France

Pierre Burbaud, Dominique Guehl, Jérôme Aupy\*

Univ. Bordeaux, CNRS, IMN, UMR 5293, F-33000, Bordeaux, France

CHU de Bordeaux, Department of Clinical Neurophysiology, 33076, Bordeaux, France

\* Corresponding author. Univ. Bordeaux, CNRS, IMN, UMR 5293, 146 Rue Leo Saignat, 33076, Bordeaux, France. E-mail address: [jerome.aupy@u-bordeaux.fr](mailto:jerome.aupy@u-bordeaux.fr) (J. Aupy).

7 January 2022

Available online 17 April 2022