



**HAL**  
open science

# Spread of stinging ants to oceanic islands, and the need to raise awareness of prevention and treatment of ant stings

Benjamin D Hoffmann, Frédéric Ducarme, Danakai Bradford, Santiago Martinez

## ► To cite this version:

Benjamin D Hoffmann, Frédéric Ducarme, Danakai Bradford, Santiago Martinez. Spread of stinging ants to oceanic islands, and the need to raise awareness of prevention and treatment of ant stings. *Emergency Medicine Australasia*, 2023, 10.1111/1742-6723.14165 . hal-03921692

**HAL Id: hal-03921692**

**<https://hal.science/hal-03921692v1>**


Submitted on 4 Jan 2023

**HAL** is a multi-disciplinary open access archive for the deposit and dissemination of scientific research documents, whether they are published or not. The documents may come from teaching and research institutions in France or abroad, or from public or private research centers.

L'archive ouverte pluridisciplinaire **HAL**, est destinée au dépôt et à la diffusion de documents scientifiques de niveau recherche, publiés ou non, émanant des établissements d'enseignement et de recherche français ou étrangers, des laboratoires publics ou privés.

## ORIGINAL RESEARCH

# Spread of stinging ants to oceanic islands, and the need to raise awareness of prevention and treatment of ant stings

Benjamin D HOFFMANN <sup>1</sup>, Frédéric DUCARME,<sup>2</sup> DanaKai BRADFORD<sup>3</sup> and Santiago MARTINEZ<sup>4</sup><sup>1</sup>Tropical Ecosystems Research Centre, Commonwealth Scientific and Industrial Research Organisation, Darwin, Northern Territory, Australia,<sup>2</sup>Centre d'Écologie et des Sciences de la Conservation, Muséum National d'Histoire Naturelle, Paris, France, <sup>3</sup>Australian e-Health Research Centre, Commonwealth Scientific and Industrial Research Organisation, Brisbane, Queensland, Australia, and <sup>4</sup>Department of Clinical Sciences, Florida State University, Orlando, Florida, USA

## Abstract

**Objective:** Venomous invasive ants are rapidly dispersing throughout oceanic islands. Medics unfamiliar with envenomation or venom-induced anaphylaxis may be unprepared for the range of possible reactions and corresponding treatments. We detail the suboptimal treatment of a patient suffering anaphylaxis from an ant sting on a remote island and describe what treatment should have been provided.

**Methods:** The patient experienced stings on his feet from an ant later identified as tropical fire ant, *Solenopsis geminata*. Clinical examination revealed throat swelling without obstruction of the airway or pharynx.

**Results:** The patient was provided the following suboptimal treatment: intravenously-administered antihistamine and saline perfusion. Injected epinephrine should be the standard first line of treatment for anaphylaxis, even when not all symptoms are present.

**Conclusion:** A rise in invasive hymenopteran stings on oceanic islands is inevitable, and proactively improving public awareness and medical training could save lives.

**Key words:** *anaphylaxis, fire ant, hymenoptera, invasive species, Solenopsis geminata.*

## Introduction

The rising spread of invasive stinging insects throughout oceanic islands<sup>1</sup> is increasing the risk for local people who have no prior knowledge of sharing their environment with such biota. Likewise, medics who are not familiar with envenomation or venom-induced anaphylaxis may be unprepared for the range of possible reactions and corresponding treatments.

Aculeate hymenoptera are species of ant, bee and wasp with a defensive sting containing venom that can cause allergic reactions in people, including death.<sup>2</sup> There are only a few species of medical concern that cause severe allergic reactions,<sup>3,4</sup> and such allergic reactions to stinging ants are particularly well documented from Australasia and the Americas<sup>4-6</sup> where both native and exotic stinging ants are prevalent. Within Australia, this issue is predominantly related to native bulldog and jack-jumper ants,

## Key findings

- There are medics present who are either unfamiliar with envenomation or venom-induced anaphylaxis, or the optimal treatments for the range of possible reactions.
- Injected epinephrine should be the standard first line of treatment for anaphylaxis, not antihistamines.
- A rise in incidences of anaphylaxis on oceanic islands is inevitable, and proactively improving awareness could save lives.

especially *Myrmecia pilosula* but numerous exotic stinging ant species are now present, and if their distributions increase unabated they could potentially become a greater issue than the native species.

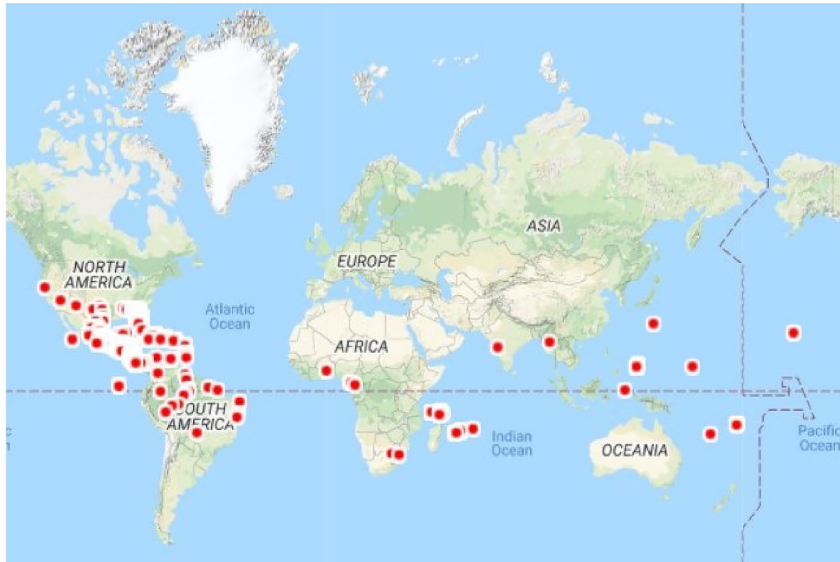Globally, most allergic reactions arising from ant stings are from the fire ants, *Solenopsis* species.<sup>7</sup> Multiple fire ant species have been accidentally dispersed outside of their native range and their global distribution is increasing.<sup>1</sup> These ants have a powerful venom and where they exist there have been cases of anaphylaxis and death.<sup>7-9</sup> The tropical fire ant (*Solenopsis geminata*) is the most widespread of the fire ant species (Fig. 1), with records of allergic reactions to its sting occurring outside of its native range, in countries from India to Australia, Taiwan, Guam and

Correspondence: Dr Benjamin D Hoffmann, Tropical Ecosystems Research Centre, Commonwealth Scientific and Industrial Research Organisation, Private Mail Bag 44, Winnellie, NT 0822, Australia. Email: [ben.hoffmann@csiro.au](mailto:ben.hoffmann@csiro.au)

Benjamin D Hoffmann, PhD, Principal Research Scientist; Frédéric Ducarme, PhD, Associate Lecturer; DanaKai Bradford, PhD, Principal Research Scientist; Santiago Martinez, MD, Clinical Assistant Professor.

This is an open access article under the terms of the [Creative Commons Attribution License](https://creativecommons.org/licenses/by/4.0/), which permits use, distribution and reproduction in any medium, provided the original work is properly cited.

Accepted 17 December 2022



**Figure 1.** Global distribution of tropical fire ant *Solenopsis geminata* (sourced with permission from AntWeb January 2022).

Japan.<sup>4,10–13</sup> This species was recently found for the first time on Mayotte Island, in the Indian Ocean.<sup>13</sup>

There are five different reactions to ant stings and they are classified with increasing severity as normal, large local, rare, toxic and systemic (anaphylaxis).<sup>5</sup> Normal and local reactions are less severe, while rare, toxic and systemic reactions require specialist medical attention. Anaphylactic reactions are caused by allergenic proteins in the venom that induce immunoglobulin E (IgE) production in people who are allergic to fire ant stings. The onset of anaphylaxis is rapid, with hypersensitivity in multiple body systems mediated by vasodilation, fluid extravasation, smooth muscle contraction and increased mucosal secretions.



**Figure 2.** Tropical fire ant worker specimen collected following ant sting on Mayotte Island.

Symptoms include skin reactions, low blood pressure, difficulty breathing, weak and rapid pulse, and fainting. This dramatic pathophysiology can cause death through hypoxemia, due to upper airway obstruction, bronchospasm and mucus plugging, and/or shock resulting from massive vasodilation, fluid shifting out of the veins and into the surrounding tissue and depressed myocardial function.<sup>14</sup>

Clinical management of anaphylaxis is well published with guidelines emphasising early use of intramuscular adrenaline (usually administered through EpiPen) together with a supine position, airway support and intravenous fluid resuscitation. It is not recommended that steroids and antihistamines are used in acute management as their role in anaphylactic mitigation is not proven.<sup>15</sup>

While diagnosis is usually straightforward and management guidelines are published, suboptimal treatment can be provided where characteristic symptoms are not present. Here we describe such a case of a patient with anaphylaxis following tropical fire ant sting on Mayotte Island.

### Case presentation

The patient (male, 31, author FD) was known to be allergic to European

wasp (*Vespula* spp.) venom in 2003, and had undergone allergen immunotherapy in the following years, but was otherwise in good medical condition. At 4 pm on 5 June 2019, while on his garden lawn in Majicavo-Karopa, Mayotte Island, wearing open footwear, he experienced several painful stings on his feet from an ant later identified as *S. geminata* (Fig. 2). Approximately half an hour later, he experienced an itchy sensation on his feet and scalp, a spreading rash from his armpits and groin, a swollen face, and large welts all over his body.

At 5 pm, he was admitted to the emergency ward of a local hospital where he lost consciousness for short periods. The clinical examination revealed throat swelling without obstruction of the airway or pharynx. No bronchospasm was observed, nor abdominal pain. The examination did not reveal pulmonary or cardiovascular concern, despite a very low heart rate and potentially life-threatening hypotension. No neural issues were observed.

Immediately following examination, the patient was intravenously administered an antihistamine, dexchlorpheniramine (Polaramine IV). He was also perfused with saline solution to normalise his blood pressure. The choice was taken not to administer any corticosteroid, in accordance with contemporary recommendations.<sup>15–17</sup> After 2 h of medical care, the swelling and urticaria decreased, leaving only a rash without papules or pruritus. A reassessment was performed at 9:30 pm, and his condition was considered favourable enough for him to return home with a prescription for Polaramine and an epinephrine autoinjector.

### Discussion and conclusions

While some of the guidelines for acute anaphylactic management were followed in our case study, such as placement in a supine position, intravenous fluid resuscitation and monitoring, the administration of intramuscular adrenaline was not undertaken despite an EpiPen being available. Bronchospasm, angioedema and abdominal pain were not present;

however, the patient's hypotension should have been treated as anaphylaxis. Injected epinephrine should be the standard first line of treatment for anaphylaxis, not antihistamines, and it is unclear why this treatment was not conducted. We are also anecdotally aware of four other occasions of patients treated for anaphylaxis due to *S. invicta* in an emergency room in one of the islands of the West Indies, where an EpiPen was not used on any occasion. Together, these reports demonstrate a need for raised awareness on allergen avoidance and acute anaphylactic management in newly colonised locations, such as oceanic islands.

Bees and wasps have high levels of antigenic cross-reactivity, and the same can also apply between bees, wasps and ants.<sup>18</sup> Notably, regardless of personal reactivity to bees or wasps, people are not necessarily aware of personal reactivity to venomous ants, and there are few risk factors to identify individuals at potential risk for ant sting anaphylaxis other than a history of prior anaphylaxis. Unfortunately, even if somebody was aware of a risk, immunotherapy is not available in many Indo-Pacific countries due to a lack of perceived need and expert physicians.<sup>5</sup>

As stinging exotic ants spread to new locations, human medical incidents closely follow. Fire ants are also highly aggressive and rapidly recruit when threatened, so a person is unlikely to be stung by a single individual, rather many individuals, increasing the venom load received by a patient, and the medical risk. In China where red imported fire ant recently established, more than one third of people living in infested areas have already been stung, and nearly 10% have had a strong reaction.<sup>9</sup> Similar statistics have been reported from the USA, with more than 14 million people stung annually.<sup>6</sup>

Holistic research on allergic response rates to stinging ants has consistently found that approximately 3% of the human population will have a strong reaction.<sup>19</sup> Given that there are approximately 4 million people living on oceanic islands in the Pacific (excluding New Zealand and Papua New Guinea), this equates to

approximately 120 000 people potentially at risk of severe stinging ant reactions as these species increase their distribution and abundance in the region. Similar statistics can also be expected for the Indian Ocean. But the rate and severity of outcomes can be reduced through prevention and appropriate treatment. Increasing awareness about venomous ants, including wearing shoes, not disturbing ant nests, and considering professional pest control, will assist in avoiding ant stings. Severity can be reduced by ensuring medical practitioners have the knowledge to identify the ant, diagnose and treat different reactions, in particular the acute management of anaphylaxis (as described in 14), and are equipped with EpiPens. Patients can also be provided with verbal and written anaphylaxis management plans, which cover how to avoid allergens, recognise symptoms and, where there is likelihood of ongoing exposure, use of an EpiPen. Resources for medical practitioners are readily available at <https://www.allergy.org.au/anaphylaxis>.

Our case study serves to highlight, for islands with no native stinging fauna, the increasing risk of invasive hymenopteran stings that are well known to cause hospitalisation and even death. We suggest that a rise in such cases on oceanic islands is inevitable, and proactively improving individual awareness, medical options at facilities and practitioner awareness could save lives.

#### Author contributions

FD, BDH, DB and SM contributed to the study's conception and design. Material preparation, data collection and analysis were performed by FD. The first draft of the manuscript was written by FD and BDH, then DB and SM helped draft subsequent versions of the manuscript. All authors read and approved the final manuscript.

#### Competing interests

FD was the patient of the case study.

#### Data availability statement

All data generated or analysed during this study are included in this published article.

#### References

- Bertelsmeier C, Ollier S, Liebhold AM, Brockerhoff EG, Ward D, Keller L. Recurrent bridgehead effects accelerate global alien ant spread. *Proc. Nat. Acad. Sci. USA* 2018; **115**: 5486–91.
- Golden DBK. Anaphylaxis to insect stings. *Immunol. Allergy Clin. North Am.* 2015; **35**: 287–302.
- Klotz JH, deShazo RD, Pinnas JL *et al.* Adverse reactions to ants other than imported fire ants. *Ann. Allergy Asthma Immunol.* 2005; **95**: 418–25.
- Hoffman DR. Ant venoms. *Curr. Opin. Allergy Clin. Immunol.* 2010; **10**: 342–6.
- Srisong H, Daduang S, Lopata AL. Current advances in ant venom proteins causing hypersensitivity reactions in the Asia-Pacific region. *Mol. Immunol.* 2016; **69**: 24–32.
- Taber SW. *Fire Ants*. College Station, TX: Texas A&M University, 2000.
- Kemp SF, deShazo RD, Moffitt JE, Williams DF, Buhner WA II. Expanding habitat of the imported fire ant (*Solenopsis invicta*): a public health concern. *J. Allergy Clin. Immunol.* 2000; **105**: 683–91.
- Solley GO, Vanderwoude C, Knight GK. Anaphylaxis due to red imported fire ant sting. *Med. J. Aust.* 2002; **176**: 521–3.
- Xu Y, Huang J, Zhou A, Zeng L. Prevalence of *Solenopsis invicta* (Hymenoptera: Formicidae) venom allergic reactions in mainland China. *Fla. Entomol.* 2012; **95**: 961–5.
- Hoffmann DR. Reactions to less common species of fire ants. *J. Allergy Clin. Immunol.* 1997; **100**: 679–93.
- Knight D, Bangs MJ. Cutaneous allergic vasculitis due to *Solenopsis geminata* (Hymenoptera: Formicidae) envenomation in Indonesia. *Southeast Asian J. Trop. Med. Public Health* 2007; **38**: 808–13.
- Potiwat R, Tanyaratsrisakul S, Maneewatcharangsri S *et al.* *Solenopsis geminata* (tropical fire ant)

- anaphylaxis among Thai patients: its allergens and specific IgE-reactivity. *Asian Pac. J. Allergy Immunol.* 2018; 36: 101–8.
13. Rochat J, Gasnier S, Paulus G. Etude de l'entomofaune des environs de l'aéroport de Dzaoudzi-Pamandzi (Mayotte). Rapport d'étude. = Study report of the entomological fauna of the environment of the Dzauo-Pamandzi airport (Mayotte). Reunion Island: Insectarium de La Réunion /SOGREAH/ MEEDDM – SNIA, 2010; 128 (in French).
  14. Brown SGA, Mullins RJ, Gold MS. Anaphylaxis: diagnosis and management. *Med. J. Aust.* 2006; 185: 283–9.
  15. Kirkbright SJ, Brown SGA. Anaphylaxis – recognition and management. *Aust. Fam. Physician* 2012; 41: 366–70.
  16. Shaker MS, Wallace DV, Golden DBK, Oppenheimer J, Bernstein JA, Campbell RL. Anaphylaxis – a 2020 practice parameter update, systematic review, and Grading of Recommendations, Assessment, Development and Evaluation (GRADE) analysis. *J. Allergy Clin. Immunol.* 2020; 145: 1082–123.
  17. Alqurashi W, Ellis AK. Do corticosteroids prevent biphasic anaphylaxis? *J. Allergy Clin. Immunol. Pract.* 2017; 5: 1194–205.
  18. Hoffman DR, Dove DE, Moffitt JE, Stafford CT. Allergens in Hymenoptera venom XXI. Cross reactivity and multiple reactivity between fire ant venom and bee and wasp venoms. *J. Allergy Clin. Immunol.* 1988; 82: 828–34.
  19. Bilo BM, Bonifazi F. Epidemiology of insect-venom anaphylaxis. *Curr. Opin. Allergy Clin. Immunol.* 2008; 8: 330–7.