



HAL
open science

Transvaginal Uterine Biopsy: Robot Comanipulation

Nassim Tajeddine, Marie-Aude Vitrani, R Émi Chalard

► **To cite this version:**

Nassim Tajeddine, Marie-Aude Vitrani, R Émi Chalard. Transvaginal Uterine Biopsy: Robot Comanipulation. SURGETICA 2019, Jun 2019, Rennes, France. <hal-03909952>

HAL Id: hal-03909952

<https://hal.science/hal-03909952v1>

Submitted on 21 Dec 2022

HAL is a multi-disciplinary open access archive for the deposit and dissemination of scientific research documents, whether they are published or not. The documents may come from teaching and research institutions in France or abroad, or from public or private research centers.

L'archive ouverte pluridisciplinaire HAL, est destinée au dépôt et à la diffusion de documents scientifiques de niveau recherche, publiés ou non, émanant des établissements d'enseignement et de recherche français ou étrangers, des laboratoires publics ou privés.



HAL Authorization

Transvaginal Uterine Biopsy: Robot Comanipulation

Nassim TAJEDDINE, Marie-Aude VITRANI and Rémi CHALARD

Sorbonne Universite, CNRS UMR 7222, INSERM U1150, ISIR

ISIR, 4 Place Jussieu, CC173, 75005 Paris

Contact: nassim.tajeddine@etu.upmc.fr

Uterine laparoscopy in sarcoma ablation risks the spread of cancer cells in the abdominal cavity because of the Laparoscopic Power Morcellator (LPM). To adapt the ablation procedure, transvaginal uterine biopsy has been proposed in pre-operative diagnosis. Based on a robot assisted transrectal prostate biopsy, this paper studies the adaptability of the robot to the transvaginal uterine biopsy procedure in order to enhance the precision of the surgeon's movements.

1 Introduction

Every year, 6000 new cases of uterine cancer occur in France [1]. Uterine cancer can be suspected via invasive and non invasive tests: pelvic or transvaginal ultrasound and hysteroscopy to observe the potential cancerous area [2]. The usual method is to remove the suspect lesion using laparoscopy with the Laparoscopic Power Morcellator (LPM) and examine it postoperatively. The major issue with that method is that, if the patient suffers from uterine cancer, the spread of cancer cells in the abdominal cavity is possible, resulting in the possible expansion of cancer to other organs [3]. Indeed, LPMs are used to fragment tissues to allow surgical specimens to be removed through small incisions. To adapt the ablation procedure (laparoscopy vs open surgery) and minimize the risk of expanding cancer cells, the kind of tissue to be removed should be known preoperatively. Based on this consideration, a new cancer detection procedure by using transvaginal uterine biopsy is presented in [4]. That procedure would be performed during routine transvaginal clinical examination and would thus require less preparation than surgery. To locate and reach the suspect regions on the uterus, high precision and stabilization of the clinician's movements are required. Robot-assisted ultrasound-guided biopsies have shown that degree of precision in robot assisted transrectal prostate biopsy described in [5].

This paper presents the adaptability of the robot used for transrectal prostate biopsy to transvaginal uterine biopsy.

2 Anatomical description

The uterus is described in [6]. It is a hollow pear-shaped organ located in the pelvic cavity between the rectum and the bladder and is generally anteflexed and anteverted over the bladder. The basal extremity of the uterus, namely the cervix, is located in the vagina (see Fig.1). The vagina is an elastic muscular canal. Its average dimensions are 9.4cm in length [7].

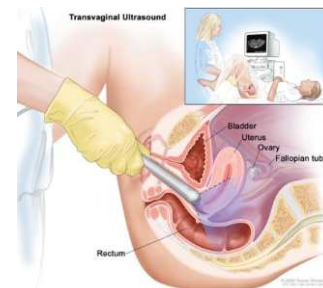


Fig.1: Transvaginal echography with patient anatomy.

It is important to note that the anatomy of the uterus and vagina has strong inter-individual variability. Moreover, the patients undergoing the diagnosis procedures might suffer from uterine cancer, resulting in more variations of the shape, weight and position of these organs. Based on [4], the uterine biopsy procedure should be similar to the gynecological physical exam. The patient is lying down on a gynecological table, her legs are suspended on stirrups. The diagnosis test is described as follows: the ultrasound probe is inserted into the vagina up to the cervix as shown in fig.2. The probe has a small mobility described by the our referent surgeon as a 2 cm square limited by the cervix and the vaginal wall. This area of movement has also been highlighted in other works [8]. The probe can still be moved in many orientations limited by the anatomy of the vagina.

3 Results: Workspace simulation

To test the adaptability of the robot used for transrectal prostate biopsy to transvaginal uterine biopsy, both the workspace of the robot and the estimated workspace of the physician’s movements have been modeled and compared. The robot is presented in [5], it is an anthropomorphic arm with 3 active DoFs and a free-wrist presented in fig.2 and tab.1.

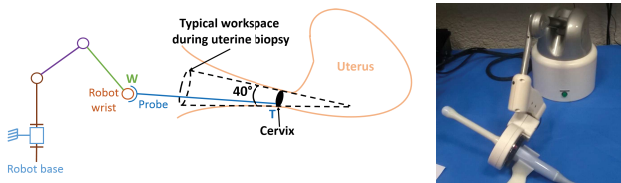


Fig.2: Apollo Robot [5] and its kinematic model.

Table 1: DH parameters of the Apollo robot

i	α_i	a_i	θ_{i+1}	d_{i+1}
0	0	0	θ_1	0
1	$\pi/2$	0	θ_2	0
2	0	25	θ_3	0
3	$-\pi/2$	0	θ_4	-30
4	$-\pi/4$	0	θ_5	0
5	$-\pi/2$	0	θ_6	0

Mechanical constraint: $\theta_2 + \theta_3 < 90^\circ$.

The possible movements of the probe and the anatomical limitations described previously have been modeled using Matlab environment and shown in fig.3.

It is hypothesized that the tip of the probe is located between the cervix and the vaginal wall. They both make up the limits of an area in which the physician can move the tip of the probe and change its orientation with a 20° angle. It is also hypothesized the patient’s organs are of average dimensions and positioning, inter-individual anatomical variability has not yet been taken into account.

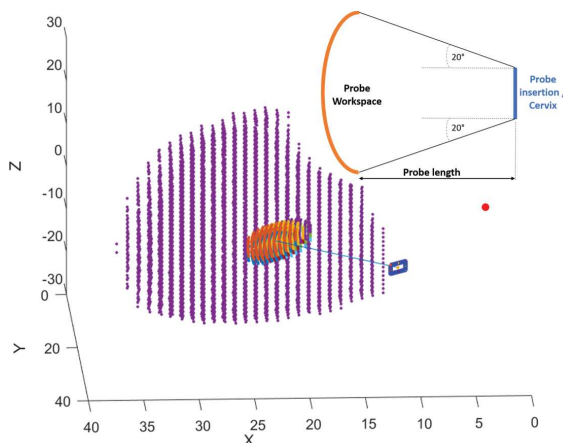


Fig.3: Possible positions of the probe and its orientations within the cropped workspace of Apollo & sketch of the probe workspace

In fig.3, the possible movements of the tip of the ultrasound probe between the vaginal wall and the cervix described in Section.2 are shown by the 2 cm

blue square. The ultrasound probe is modeled by the blue line. The red dot is the origin of the system located in the robot basis. The insertion area and the probe length are known so, as it is highlighted on the 2-D scheme in fig.3, it is possible to model the possible movements of the end of the probe held by the physician during the clinical exam by the arcs as shown in fig.3.

Thanks to the simulation, it appears that all the surgeon’s possible movements during a uterine biopsy session are compatible with the robot workspace (see fig.3). However, during the clinical routine, the patient can be considered as fixed so the surgeon workspace is fixed also. Moreover, the reference position of the robot impacts the robot workspace. Taking into account these two considerations, the position of the robot in the clinical routine appears as a main issue.

4 Application to clinical routine

Based on previous studies, the optimal position of the robot basis is next to the right of the patient’s insertion point (1 in fig.4a) but it is not possible in uterine biopsy due to the leg of the patient being an obstacle to the axis of the robot. With current kinematic parameters and to allow all the physician’s movements, the best position of the robot basis is beside the patient, under her legs laterally to the vulva (2 in fig.4a). However, as shown in fig.4a, this position is also impossible due to the stirrups. The surgeon partner suggested to position the robot directly between the legs of the patient central and lower to the vulva (3 in fig.4a). That position would not allow the physician’s full movements with current kinematic parameters (see fig.4b). Lengthening the a_2 and d_4 parameters respectively to 35 cm and 40 cm as well as increasing the mechanic constraint $\theta_2 + \theta_3 < 90^\circ$ to 135° would make that positioning possible (see fig.4c).

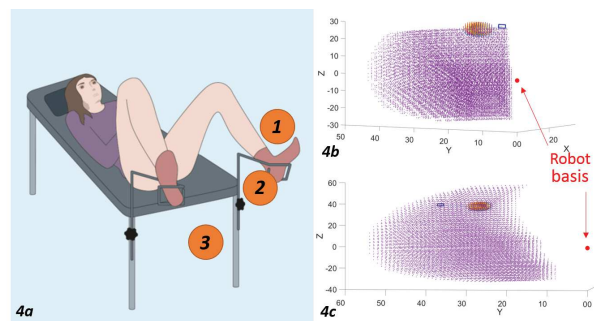


Fig.4: Positions of the robot in relation to the patient during a physical examination [9], modified.

5 Conclusion

Adaptability of the Apollo robot from transrectal prostate biopsy to transvaginal uterine biopsy is possible despite anatomical differences. Positioning of the robot during physical examination is still being studied and is dependant on potential kinematic modifications of the robot.

References

- [1] Sancho-Garnier, H. (2013). Epidémiologie des cancers gynécologiques: utérus, ovaire, vulve, vagin. *Cancers gynécologiques pelviens. Elsevier Masson, Paris*, 85–99.
- [2] American Cancer Society. <https://www.cancer.org/>
- [3] Fda 2014: Laparoscopic power morcellation during uterine surgery for fibroids, 2014.
- [4] Fazel, A. , Vitrani, M.-A., Gaudrard, E. and Baumann, M. (2016) Robotic Biopsy of the Uterus Standardized Technique (ROBUST): A New Technique for Uterine Biopsy Prior to Minimally Invasive Surgery. *Journal of Minimally Invasive Gynecology. Elsevier*, 23(7):227-228.
- [5] Poquet, C. , Mozer, P. , Morel, G. and Vitrani, M.-A. (2013) A novel comanipulation device for assisting needle placement in ultrasound guided prostate biopsies 2013 *IEEE/RSJ International Conference on Intelligent Robots and Systems*, 4084–4091.
- [6] Bouton, J.-M., Dehnez, M. Ebou, F., Hainaut, F., Michelin, J., and Mac Aleese, J. (1990) *Pratique de l'ichographie en gynécologie et obstétrique*.
- [7] Tan, J. S., Lukacz, E. S., Menefee, S. A., Lubber, K. M., Albo, M. E., and Nager, C. W. (2006). Determinants of vaginal length. *American journal of obstetrics and gynecology*, 195(6):1846-1850.
- [8] De Smet, J., Deprest, J., Vander Poorten, E. (2019). In-vivo Force Sensing during Laparoscopic Sacrocolpopexy Vaginal Vault Manipulation. *Journal of Medical Robotics Research*
- [9] <https://www.ameli.fr>