



HAL
open science

Outcomes of surgical resection in microsatellite instable colorectal cancer after immune checkpoint inhibitor treatment

Alexandre Challine, Medhi Karoui, Christelle De La Fouchardière, Thierry André, Magali Svrcek, Pierre Meeus, Aurélien Dupré, François Paye, Stéphane Benoit, Christine Denet, et al.

► To cite this version:

Alexandre Challine, Medhi Karoui, Christelle De La Fouchardière, Thierry André, Magali Svrcek, et al.. Outcomes of surgical resection in microsatellite instable colorectal cancer after immune checkpoint inhibitor treatment. *British Journal of Surgery*, 2022, 10.1093/bjs/znac425 . hal-03903333

HAL Id: hal-03903333

<https://hal.science/hal-03903333>

Submitted on 16 Dec 2022

HAL is a multi-disciplinary open access archive for the deposit and dissemination of scientific research documents, whether they are published or not. The documents may come from teaching and research institutions in France or abroad, or from public or private research centers.

L'archive ouverte pluridisciplinaire **HAL**, est destinée au dépôt et à la diffusion de documents scientifiques de niveau recherche, publiés ou non, émanant des établissements d'enseignement et de recherche français ou étrangers, des laboratoires publics ou privés.

Outcomes of surgical resection in microsatellite instable colorectal cancer after immune checkpoint inhibitor treatment

Challine Alexandre¹ , Karoui Medhi² , De La Fouchardière Christelle³, André Thierry⁴, Svrcek Magali⁵, Meeus Pierre⁶, Dupré Aurélien⁵ , Paye François¹ , Benoit Stéphane⁷, Denet Christine⁸, Eveno Clarisse⁹, Lefèvre Jérémie H.¹  and Parc Yann^{1,*}

¹Department of Digestive Surgery, Sorbonne University, Hôpital Saint Antoine, APHP, Paris, France

²Department of Digestive Surgery, University of Paris, Hôpital Georges Pompidou, APHP, Paris, France

³Department of Medical Oncology, Centre Leon Berard, Lyon, France

⁴Department of Medical Oncology, Sorbonne University, Hôpital Saint Antoine, APHP, Paris, France

⁵INSERM, Unité Mixte de Recherche Scientifique 938 and SIRIC CURAMUS, Centre de Recherche Saint-Antoine, Equipe Instabilité des Microsatellites et Cancer, Equipe labellisée par la Ligue Nationale contre le Cancer, Sorbonne University, Paris, France

⁶Digestive Surgery, Centre Leon Berard, Lyon, France

⁷Department of Digestive Surgery, Paris Saclay University, Hôpital Kremlin Bicêtre, APHP, Kremlin Bicêtre, France

⁸Department of Digestive Surgery, Montsouris Mutualist Institut, Paris, France

⁹Department of Digestive and Oncological Surgery, Claude Huriez University Hospital, Lille, France

*Correspondence to: Yann Parc, Department of Digestive Surgery, Hôpital Saint-Antoine, APHP, 184 rue du Faubourg Saint-Antoine, Paris, France (e-mail: yann.parc@aphp.fr)

Introduction

The detection of the microsatellite instability (MSI) phenotype and/or mismatch repair deficiency in some colorectal cancers (CRCs)^{1–3} has made the identification of Lynch syndrome easier^{4–6}. A major breakthrough in medical oncology was the discovery of immune checkpoint inhibitors (ICIs), such as anti-PD1 or anti-PDL1 monoclonal antibodies, alone or in combination with anti-CTLA4 monoclonal antibodies⁷.

After initial descriptions of ICI use in the palliative setting⁸, ICIs are arguably the treatment of choice for MSI metastatic CRC^{7,9}. At present, this therapy is mainly used for metastatic CRC. However, recent studies have reported encouraging results in the neoadjuvant setting, with high rates of complete histological response^{10–12}. There is a paucity of data on postoperative outcomes in patients who have received ICI therapy. The aim of this study is to report our experience in patients with advanced MSI CRC operated on after ICI treatment, with a specific focus on surgical morbidity, pathological results, and survival.

Methods

A retrospective two-centre observational study was performed on prospectively maintained databases of patients with an MSI tumour undergoing surgery after ICI treatment (nivolumab, pembrolizumab, or dostarlimab alone, or nivolumab combined with ipilimumab), with either a primary non-resectable or locally recurrent or metastatic CRC, between 2015 and 2021.

All patients who received ICI treatment for MSI CRC and had surgery were identified. The decision to perform surgery was decided on in multidisciplinary meetings. The main indications were post-treatment tumour persistence (residual metastasis and or primary tumour) after radiological restaging (RECIST1.1

stable or partial response); symptomatic tumour requiring surgery; and isolated progressive disease in one site (sanctuary site), with partial response at others sites¹³. Patients were followed-up until 30 September 2021.

Short-term postoperative morbidity was defined according to Clavien-Dindo classification within 90 days postoperatively¹⁴. Overall survival was defined as the time from surgery to death. Progression-free survival was defined as the time from surgery to disease progression or death, during the follow-up period.

R software was used for the statistical analysis¹⁵. Descriptive analysis was performed using percentages and proportion, and medians, with interquartile ranges (i.q.r.) reported. A survival analysis was performed.

Results

Thirty-two patients were included. Median patient age was 50 (i.q.r. 43–61) years, and 13 (40 per cent) were women. Sixteen patients (50 per cent) presented a loss of MLH1 ± PMS2. Nineteen (59 per cent) had received chemotherapy ± targeted therapy before ICI treatment. Chemotherapy treatments are described in the [Table S1](#). Indications for ICI treatment were primary locally advanced CRC in four patients (12 per cent), synchronous metastatic tumour in 13 (41 per cent), or 15 (47 per cent) metachronous metastatic CRC after primary resection. ICI treatment toxicity occurred in six patients (19 per cent), which was mostly treated with corticosteroids that were then discontinued before surgery.

Indications for surgery were resection of the residual mass at radiological restaging with RECIST1.1 stable or partial response in 21 patients (66 per cent), progressive disease in a sanctuary site with RECIST1.1 complete or partial response in other site in four (12 per cent), or symptomatic cancer in seven patients (22

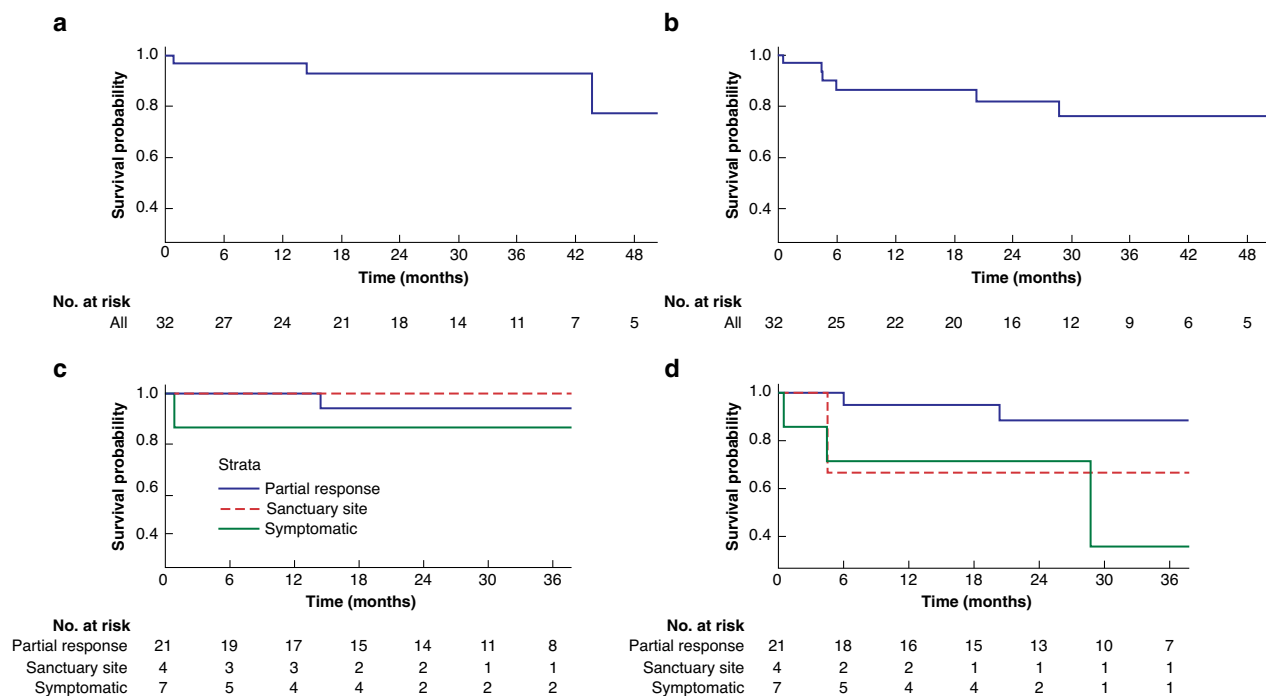


Fig. 1 Kaplan–Meir survival curves

a Overall survival of the global population. **b** Recurrence-free survival of the global population. **c** Overall survival of the population according to the indication for surgery. **d** Recurrence-free survival of the population according to the indication for surgery.

per cent) with obstruction in two, colonic stricture in two, bleeding in one, peritonitis in one, and fistula of the tumour in the abdominal wall in one. The median delay between the beginning of ICI treatment and surgery was 14 (i.q.r. 9–17) months.

Twelve cytoreductions of peritoneal carcinomatosis, 21 colectomies, nine resections of liver metastasis, two adrenalectomies, and one splenectomy were performed. For six patients (19 per cent), the resection was incomplete. Details of procedure are summarized in [Table S1](#).

The 90-day morbidity rate was 31 per cent (10 patients); seven patients had digestive sepsis (22 per cent). Severe complications (90-day-Dindo-Clavien classification of 3 or more) occurred in five patients (16 per cent). One patient treated for symptomatic tumour peritonitis and obstruction died. The patient died from haemorrhagic complications and COVID-19 infection in the early postoperative period.

A complete histological response was observed in 18 patients (56 per cent). This was not different with the primary CRC tumour *in situ* (eight of 17 patients; 47 per cent) or in residual metastatic site (10 of 15 patients; 67 per cent) ($P=0.26$).

For 17 patients treated with the primary CRC tumour *in situ* (four of M0 and 13 of M+), eight (47 per cent) had a complete histological response ypT0N0; one had a near-complete response (less than 10 per cent of residual tumour) and was not classified according to the TNM classification; six had ypT4 and two were ypT3 tumours. Residual tumours were found in the primary colorectal tumour in nine patients, in lymph nodes in five, and in metastases in five. When surgery was performed for residual mass after RECIST1.1 stable or partial response, the rate of complete histological response was 70 per cent (seven of 10 patients).

For 15 patients treated for a residual metastatic mass, a complete histological response was observed in 10 patients (67 per cent). Four patients presented residual tumour but were

operated on for progression RECIST 1.1 in a sanctuary site (adrenal gland in two, spleen in one, and lymph node in one). When surgery was performed for a residual mass after RECIST1.1 stable or partial response, the rate was 91 per cent (10 of 11 patients).

The median duration of follow-up after surgical resection was 23 (i.q.r. 14–31) months. Three patients died with progressive disease: two of peritoneal carcinomatosis and one of neoplastic meningitis. Moreover, three other patients who did not have a complete pathological response were alive, with recurrence observed in lymph nodes in one after 4 months, the adrenal gland in one after 24 months, and peritoneal metastasis after 4 months in one. Overall survival at two years was 0.91 (i.q.r. 0.80–1.00) and progression-free survival was 0.81 (i.q.r. 0.65–1.00) ([Fig. 1](#)).

Discussion

The main finding of this study is that there is a high rate of complete response in patients with MSI CRC treated with ICIs for primary and metastatic disease. Although this is a comparatively small series, the high rate of postoperative morbidity is a concern.

In this series, three patients had sanctuary site progression (defined as progressive disease only in one site with response on the other site after ICI treatment), in the adrenal gland, lymph nodes, and spleen. Adrenal gland metastasis of MSI CRC has been reported previously¹⁶. Such findings might indicate that adrenal glands are more likely to be the site of metastatic MSI tumours or a site where ICI treatment might not be as effective.

Twenty-one of the 32 patients in this series were operated on because they had a residual mass after RECIST1.1 stable or partial response; therefore, the results represent a highly selected population. In this setting the complete response rate

of 81 per cent was unexpected. With these results, a 'watch-and-wait' strategy may have been appropriate. The option is limited for proximal tumours because, unlike in rectal cancer, scar resection is not an option to determine the presence of a complete response¹⁷. Different means for assessing response to ICIs are therefore required.

Surgery in patients with advanced MSI CRC treated with ICIs is questionable. It appears that patients without symptoms or complications have a high rate of complete histological response to ICI treatment; therefore, a decision to offer surgery in this setting should proceed with caution.

Funding

The authors have no funding to declare.

Acknowledgements

This study was previously delivered as an oral presentation at the SFCD-ACHBT congress in 2021 (national French congress); and as a poster presentation at the ESCP congress 2022 in Dublin.

Disclosure

The authors declare no conflict of interest.

Data availability

Data are available on demand, but not in open-access format.

References

- Aaltonen LA, Peltomäki P, Leach FS, Sistonen P, Pylkkänen L, Mecklin JP et al. Clues to the pathogenesis of familial colorectal cancer. *Science* 1993;**260**:812–816
- Ionov Y, Peinado MA, Malkhosyan S, Shibata D, Perucho M. Ubiquitous somatic mutations in simple repeated sequences reveal a new mechanism for colonic carcinogenesis. *Nature* 1993;**363**:558–561
- Thibodeau SN, Bren G, Schaid D. Microsatellite instability in cancer of the proximal colon. *Science* 1993;**260**:816–819
- Fishel R, Lescoe MK, Rao MR, Copeland NG, Jenkins NA, Garber J et al. The human mutator gene homolog MSH2 and its association with hereditary nonpolyposis colon cancer. *Cell* 1993;**75**:1027–1038
- Papadopoulos N, Nicolaides NC, Wei YF, Ruben SM, Carter KC, Rosen CA et al. Mutation of a mutL homolog in hereditary colon cancer. *Science* 1994;**263**:1625–1629
- Canard G, Lefevre JH, Colas C, Coulet F, Svrcek M, Lascols O et al. Screening for lynch syndrome in colorectal cancer: are we doing enough? *Ann Surg Oncol* 2012;**19**:809–816
- Cohen R, Rousseau B, Vidal J, Colle R, Diaz LA Jr, Andre T. Immune checkpoint inhibition in colorectal cancer: microsatellite instability and beyond. *Target Oncol* 2020;**15**:11–24
- Le DT, Uram JN, Wang H, Barlett BR, Kemberling H, Eyring AD et al. PD-1 Blockade in tumors with mismatch-repair deficiency. *N Engl J Med* 2015;**372**:2509–2520
- Andre T, Shiu KK, Kim TW, Jensen BV, Jensen LH, Punt C et al. Pembrolizumab in microsatellite-instability-high advanced colorectal cancer. *N Engl J Med* 2020;**383**:2207–2218
- Chalabi M, Fanchi LF, Dijkstra KK, Van den Berg JG, Aalbers AG, Sikorska K et al. Neoadjuvant immunotherapy leads to pathological responses in MMR-proficient and MMR-deficient early-stage colon cancers. *Nat Med* 2020;**26**:566–576
- Cercek A, Lumish M, Sinopoli J, Weiss J, Shia J, Laùendola-Essel M et al. PD-1 Blockade in mismatch repair-deficient, locally advanced rectal cancer. *N Engl J Med* 2022;**386**:2363–2376
- Kothari A, White MG, Peacock O, Kaur H, Palmquist SM, You N et al. Pathological response following neoadjuvant immunotherapy in mismatch repair-deficient/microsatellite instability-high locally advanced, non-metastatic colorectal cancer. *Br J Surg* 2022;**109**:489–492
- Eisenhauer EA, Therasse P, Bogaerts J, Schwartz LH, Sargent D, Ford R et al. New response evaluation criteria in solid tumours: revised RECIST guideline (version 1.1). *Eur J Cancer* 2009;**45**:228–247
- Dindo D, Demartines N, Clavien P-A. Classification of surgical complications: a new proposal with evaluation in a cohort of 6336 patients and results of a survey. *Ann Surg* 2004;**240**:205–213
- R: A language and environment for statistical computing. R Foundation for Statistical Computing, Vienna, Austria; 2005. <http://www.R-project.org>
- Cohen R, Jonchere V, De La Fouchardiere C, Ratovomanana T, Letourneur Q, Ayadi M et al. Adrenal gland as a sanctuary site for immunotherapy in patients with microsatellite instability-high metastatic colorectal cancer. *J Immunother Cancer* 2021;**9**:e001903
- Rullier E, Vendrely V, Asselineau J, Rouanet P, Tuech JJ, Valverde A et al. Organ preservation with chemoradiotherapy plus local excision for rectal cancer: 5-year results of the GRECCAR 2 randomised trial. *Lancet Gastroenterol Hepatol* 2020;**5**:465–474