



HAL
open science

High-grade atrioventricular block occurring during percutaneous closure of patent foramen ovale: a case report

Marion Kibler, Halim Marzak, Laurence Jesel, Patrick Ohlmann

► **To cite this version:**

Marion Kibler, Halim Marzak, Laurence Jesel, Patrick Ohlmann. High-grade atrioventricular block occurring during percutaneous closure of patent foramen ovale: a case report. *European Heart Journal. Case Reports*, 2020, 4 (4), pp.1 - 5. 10.1093/ehjcr/ytaa141 . hal-03901024

HAL Id: hal-03901024

<https://hal.science/hal-03901024v1>

Submitted on 15 Dec 2022

HAL is a multi-disciplinary open access archive for the deposit and dissemination of scientific research documents, whether they are published or not. The documents may come from teaching and research institutions in France or abroad, or from public or private research centers.

L'archive ouverte pluridisciplinaire **HAL**, est destinée au dépôt et à la diffusion de documents scientifiques de niveau recherche, publiés ou non, émanant des établissements d'enseignement et de recherche français ou étrangers, des laboratoires publics ou privés.



Distributed under a Creative Commons Attribution - NonCommercial 4.0 International License

High-grade atrioventricular block occurring during percutaneous closure of patent foramen ovale: a case report

Marion Kibler ¹, Halim Marzak¹, Laurence Jesel^{1,2}, and Patrick Ohlmann ^{1*}

¹Université de Strasbourg, Pôle d'Activité Médico-Chirurgicale Cardio-Vasculaire, Nouvel Hôpital Civil, Centre Hospitalier Universitaire, BP 426 - 67091 Strasbourg, France; and ²UMR 1260 INSERM Nanomédecine Régénérative Université de Strasbourg, Strasbourg, France

Received 14 November 2019; first decision 12 December 2020; accepted 5 May 2020; online publish-ahead-of-print 25 June 2020

Background

Percutaneous closure of patent foramen ovale (PFO) is recommended for patients presenting with PFO-related stroke. Acute high-grade conduction disturbances occurring during PFO closure procedure have not been previously reported.

Case summary

We describe for the first time a case of reversible complete atrioventricular block which occurred during closure of a PFO.

Discussion

We hypothesized that the block was the result of atrioventricular node compression—likely caused by the right-atrial disc of the 35-mm PFO closure device. We suggest implanting smaller devices in order to prevent atrioventricular conduction disturbances.

Keywords

Atrioventricular node • Cryptogenic stroke • High-grade atrioventricular block • Patent foramen ovale • Percutaneous closure • Case report

Learning points

- During patent foramen ovale closure, the device may rarely compress atrioventricular node and cause high-grade atrioventricular block.
- Correction can be achieved by prompt removal of the device, which should be replaced by a smaller one.
- Interventional cardiologists should be aware of this rare complication.

Introduction

Percutaneous closure of patent *foramen ovale* (PFO) is currently recommended for patients presenting with PFO-related stroke.^{1,2} The potential occurrence of conduction disturbances following PFO

closure remains poorly investigated. To our knowledge, the onset of complete atrioventricular block (AVB) during PFO closure has not been previously reported in patients without a known history of conduction disturbances.

* Corresponding author. Tel: 00 33 369550953, Fax: 00 33 369551736, Email: patrick.ohlmann@chru-strasbourg.fr

Handling Editor: Mohamed Hassan

Peer-reviewers: Domitilla Russo and Richard Ang

Compliance Editor: Anastasia Vamvakidou

Supplementary Material Editor: Peysh A. Patel

© The Author(s) 2020. Published by Oxford University Press on behalf of the European Society of Cardiology.

This is an Open Access article distributed under the terms of the Creative Commons Attribution Non-Commercial License (<http://creativecommons.org/licenses/by-nc/4.0/>), which permits non-commercial re-use, distribution, and reproduction in any medium, provided the original work is properly cited. For commercial re-use, please contact journals.permissions@oup.com

Timeline

Time	Events
April 2018	Cryptogenic stroke.
April 2018	Transthoracic echocardiography: patent foramen oval (PFO) with a large shunt (>30 bubbles). Transoesophageal echocardiography confirmed the diagnosis of PFO.
31 October 2018, time 0	PFO percutaneous closure • 35-mm Amplatzer PFO Occluder®.
31 October 2018, +15 min	Positioning of the right disc of the device: • Complete atrioventricular block (AVB), ventricular escape rhythm at 35 b.p.m. alternating with a second-degree AVB
31 October 2018, +20 min	The right and left discs of Amplatzer PFO Occluder® were consecutively collected in a sheath: normalization of AV conduction.
31 October 2018, +25 min	Decision to implant a smaller Amplatzer PFO Occluder® 30 mm: Good positioning, no recurrence of AVB.
31 October 2018, +45 min	Transfer to the cardiac intensive care unit.
2 November 2018	Electrophysiological study • Normal AV nodal, intra-Hisian, and infra-Hisian conduction. • Location of the device in the proximity of the AV node.
5 November 2018	Discharged from hospital.
March 2019	Follow-up: asymptomatic patient.

Case presentation

A 33-year-old woman was hospitalized for closure of a PFO. In the preceding weeks, she presented with a right hemiparesis deemed secondary to a stroke for which no clear cause was identified (cryptogenic stroke). Her past medical history was unremarkable, and the only routine medication taken by the patient on admission was aspirin 75 mg/day. Patent foramen oval was diagnosed on transthoracic echocardiography. A pre-procedural electrocardiogram did not reveal any atrioventricular or ventricular conduction disturbances (sinus rhythm; heart rate, 69 b.p.m.; PR, 150 ms; QRS, 82 ms; normal QRS axis; [Supplementary material online, File S1](#)). The patient underwent 24-h electrocardiogram monitoring during hospitalization for stroke in the neurovascular unit to identify the potential presence of conduction disorders or atrial fibrillation. Upon induction of general anaesthesia, PFO closure was performed under transoesophageal echocardiography (TEE) guidance and 10 F right femoral venous access. Transoesophageal echocardiography examination confirmed the presence of a PFO characterized by a large shunt (>30 bubbles). Owing to the large tunnel size (16 mm × 4.5 mm) and the presence of an atrial septal aneurysm (size: 10 mm), a 35-mm Amplatzer PFO Occluder® device (Abbott Vascular, Abbott Park, IL, USA; left- and right-atrial disc diameters: 25 and 35 mm, respectively) was selected to repair the defect ([Figure 1](#)).

When the PFO was crossed, the left disc was successfully positioned without complications. However, positioning of the right disc was followed by the onset of a complete AVB. A ventricular escape rhythm at 35 b.p.m. alternating with a second-degree AVB was evident both on the anaesthetist's monitoring screen and the TEE monitoring screen ([Figure 2](#)). Although administration of atropine (0.5 + 0.5 mg) restored atrioventricular conduction within a few seconds, persistent complete AVB relapsed rapidly. We hypothesized that AVB stemmed from a compression of the atrioventricular node elicited by the right disc, which was therefore recaptured. Atrioventricular conduction was normalized as expected and

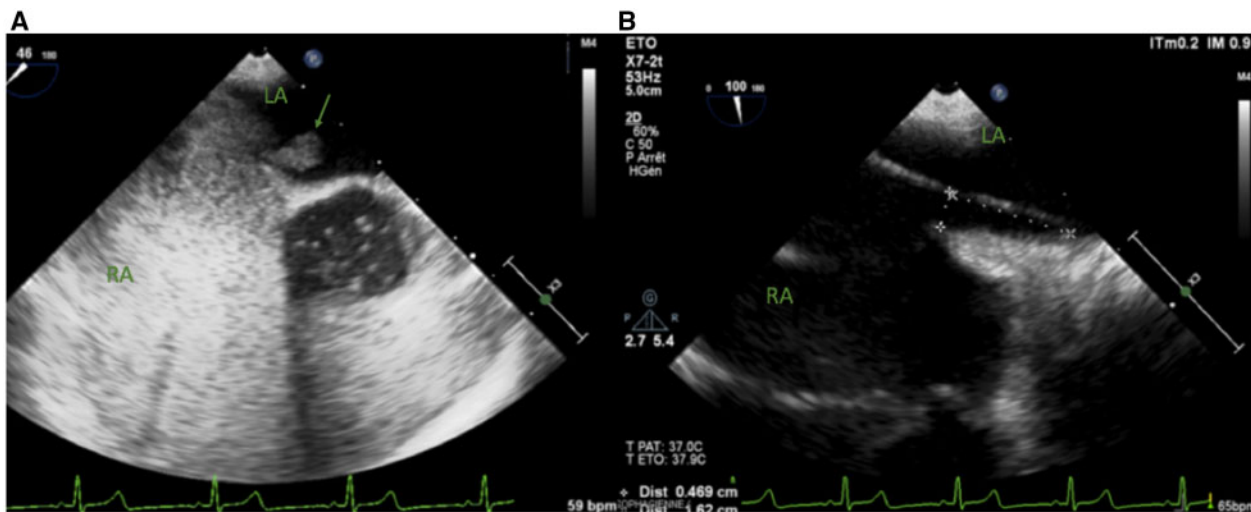


Figure 1 Pre-procedural transoesophageal echocardiography images showing: (A) large right to left shunt (>30 bubbles); (B) length of patent foramen ovale tunnel (16 mm). Green arrow, large shunt; LA, left atrium; RA, right atrium.

transient cardiac pacing was performed through a left femoral venous access. We therefore opted for a smaller Amplatzer PFO Occluder[®] (left and right atrial disc diameters: 30 mm both). The device was successfully positioned and sealing of PFO at the end of the procedure was confirmed by the absence bubbles crossing the septum (through injection of agitated saline with Valsalva manoeuvre). High-grade conduction disturbances did not recur both upon completion of the procedure and in the subsequent 48-h monitoring in the cardiac intensive care unit. The patient did not undergo steroid therapy because no recurrence of atrioventricular conduction disturbances was observed. The post-procedural electrocardiogram did not reveal any atrioventricular or ventricular conduction disturbances (sinus rhythm; heart rate, 86 b.p.m.; PR, 154 ms; QRS, 93 ms; normal QRS axis; [Supplementary material online, File S2](#)). Upon completion of the procedure, a dual antiplatelet therapy (aspirin and clopidogrel) was started and maintained 3 months.

On post-procedural Day 2, we performed an invasive electrophysiological study aimed at assessing the presence of pre-existent atrioventricular conduction disturbances. Recordings of His bundle electrogram were obtained with a diagnostic quadripolar electrode. The study revealed a normal atrioventricular nodal conduction with an AH interval of 80 ms (normal range: 55 - 125 ms). Intra-Hisian and infra-Hisian conduction were both normal, being characterized by a thin Hisian potential and a HV interval of 38 ms (normal range: 35 - 55 ms), respectively ([Figure 3](#)). The device was located as close as 5 mm to the His bundle ([Figure 4A](#)). Moreover, the two proximal electrodes of the catheter were in contact with the umbrella ([Figure 4B](#))—ultimately producing signal artefacts ([Figure 3](#)). Artefacts were due to the contact of the two proximal electrodes with the

right atrial disc during the cardiac cycle. These findings confirmed the close proximity between the device and the atrioventricular node, leading to the hypothesis that the implantation of the 35-mm Amplatzer PFO Occluder[®] device could have exerted a strong compression of the atrioventricular node and triggered AVB.

Post-procedural transthoracic echocardiography confirmed the close proximity of the device to the septal tricuspid valve annulus ([Figure 5](#)). After an unremarkable hospital stay, the patient was discharged on post-procedural Day 5. After a 6-month follow-up, there were no symptomatic recurrences. The electrocardiogram did not reveal any atrioventricular or ventricular conduction disturbances (sinus rhythm; heart rate, 75 b.p.m.; PR, 142 ms; QRS, 91 ms; normal QRS axis).

Discussion

We report a case of complete AVB occurring during the positioning of a 35-mm Amplatzer PFO Occluder[®] device. Notably, the replacement of the original apparatus with one of smaller size led to a complete regression of the conduction disturbances. We specifically hypothesized that the conduction disorder was caused by the right-atrial disc of the PFO Occluder[®] device—which was positioned in close proximity of the atrioventricular node. This in turn led to a compression injury of the adjacent atrioventricular conduction system.

To our knowledge, only a few cases of high-grade AVB during percutaneous atrial septal defect (ASD) closure have been reported, mainly in patients with a known history of conduction disorders. Johnson *et al.*³ compared pre- and post-procedural electrocardiograms of patients who underwent percutaneous closure of ASD or PFO. Two patients developed a clinically significant post-procedural heart block. The first patient had a history of complex congenital cardiomyopathy repair, whereas the second had a pre-procedural second-degree AVB.³ El-Said *et al.*⁴ described a few cases of high-grade AVB occurring after percutaneous closure of ASD—which generally showed a spontaneous regression.

The complete AVB observed in our patient was most likely caused by a direct compression injury to the atrioventricular node originating from the Amplatzer PFO Occluder[®] device. Because the typical path of atrioventricular conduction follows the anterior margin of the *fossa ovalis*,^{3,5,6} we should be aware that these areas might be injured or compressed during PFO closure. A previous report suggested that steroids may promote the recovery from atrioventricular conduction disturbances by decreasing oedema leading to AVB, but solid evidence is still lacking.⁷

Although there has been a report of acute AVB after percutaneous ASD closure,⁴ our patient—who notably had a negative history of previous atrioventricular conduction disorders—was the first to develop an acute high-grade AVB following a PFO closure. A large case series demonstrated that the most common electrophysiological disturbances following PFO closure were atrial fibrillation and delayed AVB—both of them being associated with female sex and a septal disc size larger than 30 mm.⁸

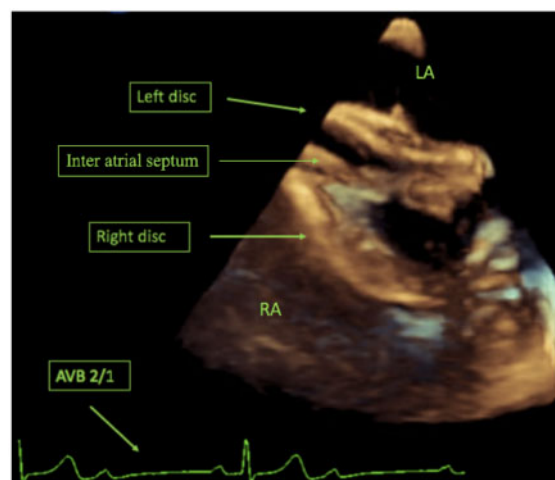


Figure 2 Per-procedural three-dimensional transoesophageal echocardiography showing the positioning of the 35-mm Amplatzer patent foramen ovale Occluder[®] device—which was accompanied by the onset of second-degree atrioventricular block on electrocardiogram. Green arrow, large shunt; LA, left atrium; RA, right atrium.

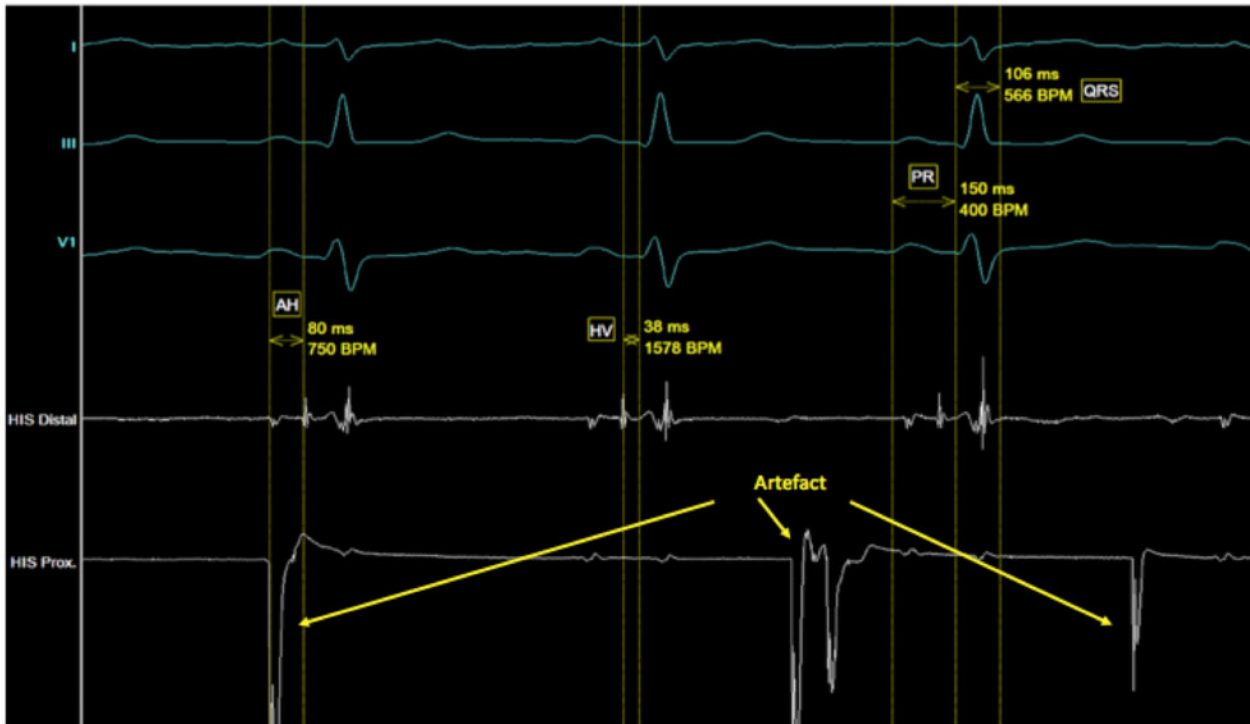


Figure 3 Invasive electrophysiological study showing a normal atrioventricular nodal conduction with an AH interval of 80 ms. Intra-Hisian and infra-Hisian conduction was normal. The proximal electrodes of the catheter were in contact with the umbrella—ultimately producing a signal artefact (yellow arrow).

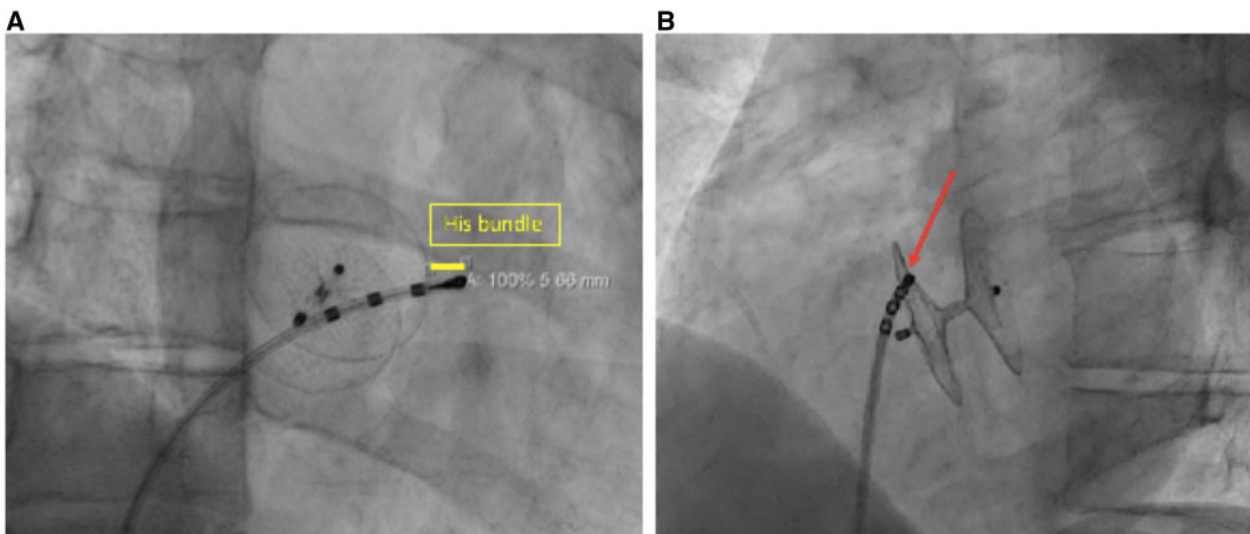


Figure 4 X-ray performed during the invasive electrophysiological study. (A) Right anterior oblique view showing the proximity of the catheter and the right atrial disc of the Amplatzer patent foramen ovale Occluder® device. Note the proximity of the device to the His bundle (yellow line). (B) The red arrow indicates the contact between the proximal electrodes of the catheter and the patent foramen ovale Occluder® device (left anterior oblique view).

Conclusion

We report for the first time a case of complete reversible AVB occurring during percutaneous PFO closure. The block was

probably caused by direct compression of the atrioventricular node by the PFO Occluder® device. Interventional cardiologists should be aware that high-grade AVB may be a rare complication of PFO closure procedure. Correction can be achieved by

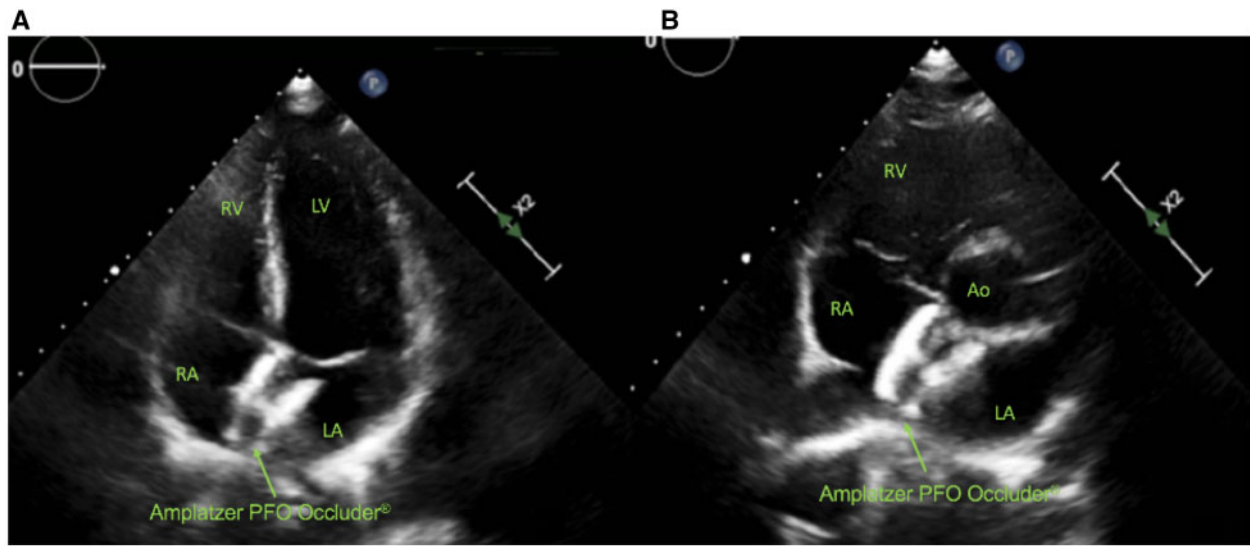


Figure 5 Post-procedural transthoracic echocardiography showing the 30-mm device in place. Note the close proximity of the device to the septal tricuspid valve annulus. (A) Apical four chambers view. (B) Parasternal short-axis view. Ao, aorta; green arrow, large shunt; LA, left atrium; LV, left ventricle; RA, right atrium; RV, right ventricle.

prompt removal of the device, which should be replaced by one of smaller size.

Lead author biography



Marion Kibler is an interventional cardiologist at the University Hospital of Strasbourg (France). She is working also in the cardiac intensive care unit.

Supplementary material

Supplementary material is available at *European Heart Journal - Case Reports* online.

Slide sets: A fully edited slide set detailing this case and suitable for local presentation is available online as [Supplementary data](#).

Consent: The authors confirm that written consent for submission and publication of this case report including images and associated text has been obtained from the patient in line with COPE guidance.

Conflict of interest: none declared.

References

- Mas J-L, Derumeaux G, Guillon B, Massardier E, Hosseini H, Mechtouff L et al Patent foramen ovale closure or anticoagulation vs. antiplatelets after stroke. *N Engl J Med* 2017;**377**:1011–1021.
- Søndergaard L, Kasner SE, Rhodes JF, Andersen G, Iversen HK, Nielsen-Kudsk JE et al Patent foramen ovale closure or antiplatelet therapy for cryptogenic stroke. *N Engl J Med* 2017;**377**:1033–1042.
- Johnson JN, Marquardt ML, Ackerman MJ, Asirvatham SJ, Reeder GS, Cabalka AK et al Electrocardiographic changes and arrhythmias following percutaneous atrial septal defect and patent foramen ovale device closure. *Cathet Cardiovasc Intervent* 2011;**78**:254–261.
- El-Said H, Hegde S, Foerster S, Hellenbrand W, Kreutzer J, Trucco SM et al Device therapy for atrial septal defects in a multicenter cohort: acute outcomes and adverse events: ASD Device Closure in a Multicenter Cohort. *Cathet Cardiovasc Intervent* 2015;**85**:227–233.
- Anderson RH, Ho SY, Becker AE. Anatomy of the human atrioventricular junctions revisited. *Anat Rec* 2000;**260**:81–91.
- McKenzie JA, Edwards WD, Hagler DJ. Anatomy of the patent foramen ovale for the interventionalist. *Cathet Cardiovasc Intervent* 2009;**73**:821–826.
- Suda K, Raboisson MJ, Piette E, Dahdah NS, Miró J. Reversible atrioventricular block associated with closure of atrial septal defects using the amplatzer device. *J Am Coll Cardiol* 2004;**43**:1677–1682.
- Rigatelli G, Zuin M, Pedon L, Zecchel R, Dell'Avvocata F, Carrozza A et al Clinically apparent long-term electric disturbances in the acute and very long-term of patent foramen ovale device-based closure. *Cardiovasc Revasc Med* 2017;**18**:118–122.