



HAL
open science

Delayed pulmonary embolism after COVID-19 pneumonia: a case report

Mohamad Kanso, Thomas Cardi, Halim Marzak, Alexandre Schatz, Loïc Faucher, Lélia Grunebaum, Olivier Morel, Laurence Jesel

► To cite this version:

Mohamad Kanso, Thomas Cardi, Halim Marzak, Alexandre Schatz, Loïc Faucher, et al.. Delayed pulmonary embolism after COVID-19 pneumonia: a case report. *European Heart Journal. Case Reports*, 2020, 4 (6), pp.1 - 4. 10.1093/ehjcr/ytaa449 . hal-03901010

HAL Id: hal-03901010

<https://hal.science/hal-03901010v1>

Submitted on 15 Dec 2022

HAL is a multi-disciplinary open access archive for the deposit and dissemination of scientific research documents, whether they are published or not. The documents may come from teaching and research institutions in France or abroad, or from public or private research centers.

L'archive ouverte pluridisciplinaire **HAL**, est destinée au dépôt et à la diffusion de documents scientifiques de niveau recherche, publiés ou non, émanant des établissements d'enseignement et de recherche français ou étrangers, des laboratoires publics ou privés.



Distributed under a Creative Commons Attribution - NonCommercial 4.0 International License

Delayed pulmonary embolism after COVID-19 pneumonia: a case report

Mohamad Kansa , *Thomas Cardi , Halim Marzak, Alexandre Schatz ,
Loïc Faucher , Lélia Grunbaum, Olivier Morel, and Laurence Jesel

Pôle d'Activité Médico-Chirurgicale Cardiovasculaire, Hôpitaux Universitaires de Strasbourg, 1 Place de l'Hôpital 67091, Strasbourg Cedex, France

Received 2 May 2020; first decision 18 May 2020; accepted 4 November 2020; online publish-ahead-of-print 24 November 2020

Background

Since the onset of the COVID-19 pandemic, several cardiovascular manifestations have been described. Among them, venous thromboembolism (VTE) seems to be one of the most frequent, particularly in intensive care unit patients. We report two cases of COVID-19 patients developing acute pulmonary embolism (PE) after discharge from a first hospitalization for pneumonia of moderate severity.

Case summary

Two patients with positive RT-PCR test were initially hospitalized for non-severe COVID-19. Both received standard thromboprophylaxis during the index hospitalization and had no strong predisposing risk factors for VTE. Few days after discharge, they were both readmitted for worsening dyspnoea due to PE. One patient was positive for lupus anticoagulant.

Discussion

Worsening respiratory status in COVID-19 patients must encourage physicians to search for PE since SARS-CoV-2 infection may act as a precipitant risk factor for VTE. Patients may thus require more aggressive and longer thromboprophylaxis after COVID-19 related hospitalization.

Keywords

COVID-19 • SARS-CoV-2 • Venous thromboembolism • Pulmonary embolism • Lupus anticoagulant • Case report

Learning points

- A deterioration in respiratory status in COVID-19 patients associated with increased D-dimer level must encourage physicians to search for pulmonary embolism.
- COVID-19 patients may require more aggressive and longer thromboprophylaxis after hospital admission since SARS-CoV-2 could be a precipitant factor for venous thromboembolism.
- There may be a potential role of lupus anticoagulant in the pro-thrombotic state in COVID-19 patients.

Introduction

On 11 March 2020, The World Health Organization (WHO) declared the onset of the COVID-19 pandemic; the disease caused by the novel coronavirus, SARS-CoV-2.

Since then, several reports have been published on the cardiovascular implications of this emerging disease.¹ Among them, venous thromboembolism (VTE) appears to be a frequent complication² particularly in patients hospitalized for severe acute respiratory distress syndrome.^{3,4} In this observation, we report two cases of COVID-19 male patients developing acute pulmonary embolism (PE)

* Corresponding author. Tel: +33 3 695 51064, Fax: +33 3 695 51788, Email: mohamad.kanso@chru-strasbourg.fr

Handling Editor: Timothy C Tan

Peer-reviewers: Rafael Vidal-Perez and Sylvia Krupickova

Compliance Editor: Max Sayers

Supplementary Material Editor: Vassilios Parisis Memtsas

© The Author(s) 2020. Published by Oxford University Press on behalf of the European Society of Cardiology.

This is an Open Access article distributed under the terms of the Creative Commons Attribution Non-Commercial License (<http://creativecommons.org/licenses/by-nc/4.0/>), which permits non-commercial re-use, distribution, and reproduction in any medium, provided the original work is properly cited. For commercial re-use, please contact journals.permissions@oup.com

after a first hospitalization for pneumonia of moderate severity. To the best of our knowledge, no cases of pulmonary embolism (PE) occurring secondly after a first hospitalization for COVID-19 non-severe infection have been described yet.

Timeline

Time	Events
Patient 1	
22 March 2020	First symptoms: fever and myalgia
25 March 2020	First hospitalization for the severe respiratory syndrome. RT-PCR testing and computed tomography (CT) scan confirmed COVID-19 pneumonia. Treatment with ceftriaxone, hydroxychloroquine, and enoxaparin. Negative lupus anticoagulant (LA) testing.
3 April 2020	Discharge with no treatment after the progressive withdrawal of oxygen.
5 April 2020	Rehospitalization for rapidly worsening dyspnoea. Second CT scan showing more extensive pneumonia lesions and pulmonary embolism. Positive LA testing.
21 April 2020	Discharge on vitamin K antagonist
Patient 2	
15 March 2020	First symptoms: fever, dry cough, and myalgia
19 March 2020	First hospitalization for dyspnoea. Positive RT-PCR testing for SARS-CoV-2 but no lesions on CT scan. Thromboprophylaxis with enoxaparin.
25 March 2020	Discharge with no treatment.
29 March 2020	Rehospitalization for new-onset dyspnoea (New York Heart Association III). Second CT scan showed subpleural ground-glass opacifications and pulmonary embolism. No LA was found.
7 April 2020	Discharge on apixaban.

Case presentations

Patient 1

Patient 1, aged 68, with history of heavy smoking (60 pack-year) and hypercholesterolaemia presented with polypnoea (22 cycle/min) and low oxygen saturation in room air of 88% after 3 days of fever and myalgia. Physical examination demonstrated coarse crackles in both lower lung fields. Reverse transcription-polymerase chain reaction (RT-PCR) testing on nasopharyngeal swab was positive for SARS-CoV-2. A low-dose computed tomography (CT) scan on the first admission showed peripheral ground-glass opacifications with underlying centrilobular emphysema lesions with an extension of COVID lesions estimated to 10–25% of lung parenchyma (Figure 1A). The

baseline electrocardiogram (ECG) was normal. A modest lymphopenia was present [$750/\text{mm}^3$, referential range (RR) 1000–4000/ mm^3] with increased values of C-reactive protein (CRP) (41 mg/L, RR < 4 mg/L) and D-dimer (1040 $\mu\text{g/L}$, RR < 500 $\mu\text{g/L}$). Brain natriuretic peptide (BNP) and troponin I levels were normal. Lupus anticoagulant (LA) testing was negative. The arterial blood gas on nasal cannula 8 L/min showed PaO₂ 60 mmHg, PCO₂ 37 mmHg, and SaO₂ 90%. Based on these findings, treatments with low molecular weight heparin (LMWH), enoxaparin 40 mg once a day, ceftriaxone, and hydroxychloroquine were started. The following day, oxygen flow was increased to 15 L/min and delivered on a non-rebreather mask. After 8 days, the clinical status improved, and the patient was discharged home after progressive oxygen weaning.

Forty-eight hours after discharge, he presented with rapidly worsening dyspnoea and severe hypoxaemia. D-dimer level was high (>20 000 $\mu\text{g/L}$), and Troponin I and BNP remained normal. A second chest CT evidenced worsening infectious lesions (Figure 1B) with an extension of 30% and filling defects in the right pulmonary artery and its right superior lobe divisions diagnostic for pulmonary embolism (Figure 1C). Unfractionated heparin was then started and switched after 48 h to LMWH twice a day. A second LA testing was positive. Vitamin K antagonist treatment with warfarin was initiated. A second LA test was planned after 3 months to decide whether anticoagulation should be discontinued or not. The patient was advised to consult his cardiologist one month after discharge.

Patient 2

Patient 2, aged 62, was referred for dyspnoea after 5 days of fever, dry cough, and myalgia. He had a history of dilated cardiomyopathy with mildly reduced ejection fraction (42%) and several cardiovascular risk factors (smoking, hypertension, type 2 diabetes mellitus, and hypercholesterolaemia). The physical examination did not demonstrate any abnormalities on admission. No crackles had been detected on lung auscultation. RT-PCR testing on nasopharyngeal swab was positive for SARS-CoV-2. A low-dose CT scan was initially normal (Figure 2A). The baseline ECG showed sinus tachycardia. C-reactive protein was mildly increased (peak value of 20 mg/L) with no leucocytosis. No troponin, BNP, or D-dimer tests were performed during the index hospitalization. Despite subnormal arterial blood gas on room air on admission (PaO₂ of 73 mmHg, PCO₂ of 42 mmHg, SO₂ of 95%), the patient received low flow nasal oxygen (1 L/min) for 2 days. Enoxaparin 40 mg once a day during the hospital stay of 5 days was the sole treatment.

Four days after discharge, he was referred for a worsened dyspnoea (New York Heart Association III). A second CT scan showed multiple subpleural ground-glass opacifications and a filling defect diagnostic for pulmonary embolism in the left inferior lobe (Figure 2B and C). Four chamber view of the heart by CT angiography showed normal right ventricle size and cardiac biomarkers were not elevated [troponin I 10 ng/L (RR < 57 ng/L) and BNP 25 ng/L (RR < 100 ng/L)]. A bedside echocardiography evidenced a left ventricle ejection fraction around 40% with normal right ventricle size and pressures. Inflammation markers were increased [CRP 95 mg/L and fibrinogen 7.16 g/L (RR 2–4 g/L)]. D-dimer level, measured 48 h after initiation of LMWH therapy, was normal (430 $\mu\text{g/L}$). Lupus anticoagulant was not detected, and the patient was switched to apixaban. The planned

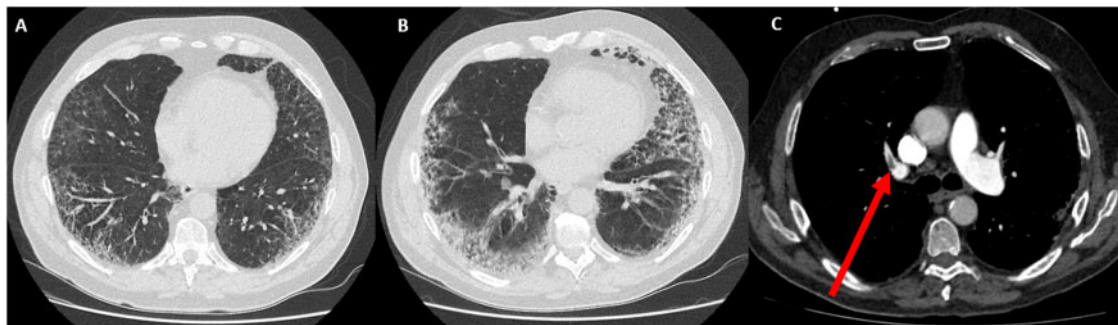


Figure 1 Serial chest computed tomography scans of Patient 1. (A) Low dose computed tomography scan on the first hospitalization showing peripheral ground-glass opacifications with underlying centrilobular emphysema lesions. (B) High resolution computed tomography scan (lung window) on readmission showing an increase in infectious lesions of ground-glass opacifications with an extension of 30% of lung parenchyma with predominant consolidation in the lower lobes. (C) Computed tomography angiography showing filling defect (arrow) in the right pulmonary artery and its right superior lobe divisions.

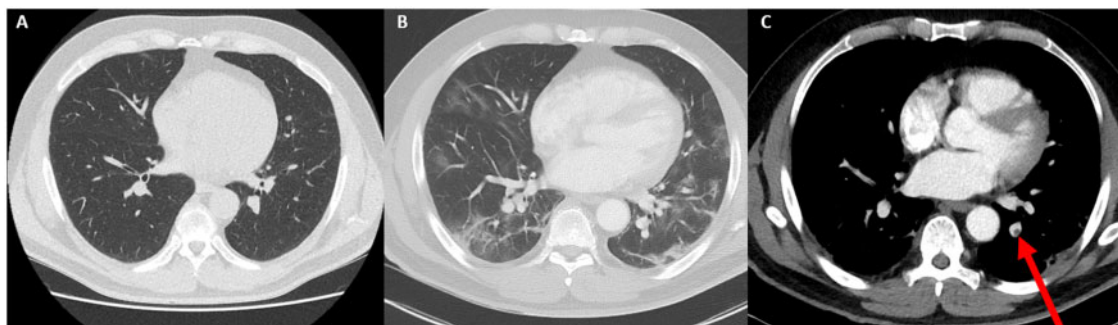


Figure 2 Serial chest computed tomography scans of Patient 2. (A) Low dose computed tomography scan on the first hospitalization showing normal lung parenchyma. (B) High resolution computed tomography scan (lung window) on readmission showing multiple subpleural ground-glass opacifications. (C) Computed tomography angiography showing filling defects (arrow) in the left inferior lobar artery branch.

anticoagulation duration was 3 months and the patient was advised to consult his cardiologist one month after discharge.

Discussion

We describe two cases of COVID-19 patients presenting with post-hospital discharge acute pulmonary embolism despite adequate thromboprophylaxis in a non-intensive care unit setting. Despite the absence of major predisposing risk factors for venous thromboembolism (VTE), the administration of a weight-adjusted thromboprophylaxis during hospitalization and the absence of severe inflammatory syndrome, PE occurred and was associated with a worsening of CT lung injuries. In one case, LA could be evidenced by questioning about the correct anticoagulant treatment and its duration. To the best of our knowledge, no reports of acute pulmonary embolism (PE) after discharge from the hospital have been described yet in non-intensive care unit patients.

The novel Coronavirus Disease outbreak is a global public health challenge. Since the first cases of SARS-CoV-2 were detected in Wuhan, China,⁵ more than 2 500 000 confirmed cases and 175 000 deaths have been documented worldwide.⁶ COVID-19-induced interstitial pneumonia leading potentially to acute respiratory distress syndrome (ARDS) and multi-organ failure is in the spotlight of all medical teams as it often triggers transfer of patients in intensive care units. Recently, it has been evidenced that SARS-CoV-2 could predispose patients to increased thrombotic disease in the venous and arterial circulations.⁷ Severe inflammation, hypoxia, endothelial dysfunction, platelet activation and stasis particularly in intensive care unit patients could explain this pro-thrombotic state. Very recently, in a ARDS population, 16.7% of PE were diagnosed and 88.7% of those patients had positive LA.⁴ Llitjos *et al.* observed that the systematic screening by complete duplex ultrasound in 26 intensive care unit patients showed a peripheral VTE prevalence of 67%.⁸

Interestingly, in the two cases described here, thrombotic events occurred 13–14 days from the onset of COVID-19 symptoms, at home after a first non-intensive care unit hospitalization and in patients clinically recovered.

There were no clinical signs of severe pneumonia, fever nor major inflammatory syndrome when PE occurred. Interestingly, both patients evidenced an increased extension of the peripheral ground-glass opacifications when PE was diagnosed despite a clear clinical improvement before discharge. Thromboprophylaxis during first hospital stay was effective but stopped after discharge. Several reports confirmed that attention should be paid to venous thromboembolism prophylaxis in COVID patients during hospitalization⁹ but no recommendations existed regarding routine post-hospital discharge thromboprophylaxis, recommended agent and/or duration.

Our case report suggests the potential role of SARS-CoV-2 as a major precipitant factor for VTE. Some acute viral infections are known to be associated with LA which are often transient, but can persist and lead to thromboembolic complications by various mechanisms including the release of membrane microparticles and the exposure of pro-thrombotic phospholipids.¹⁰ Although the significance of these antibodies is not well established yet, COVID-19-induced LA could favour the highly frequent thrombo-embolic events in this population and should be systematically tested. COVID-19 patients may thus require longer and more aggressive VTE prophylaxis after discharge. The type of anticoagulant treatment after pulmonary embolism may be adapted according to the presence of COVID-19-induced LA, taking into consideration that oral direct anticoagulants are contraindicated in case of LA in the general population.

Since COVID-19 patients are at high risk of developing PE, a sudden deterioration in respiratory status associated with high level of D-dimers must draw attention to progressive radiographic deterioration on CT and/or pulmonary embolism occurrence.

Lead author biography



Dr Mohamad Kanso is a cardiologist in Strasbourg University Hospital, Strasbourg, France. He graduated from the Cardiovascular Medicine, University of Strasbourg, in 2018 and is actually training in interventional electrophysiology.

Supplementary material

Supplementary material is available at *European Heart Journal - Case Reports* online.

Slide sets: A fully edited slide set detailing this case and suitable for local presentation is available online as [Supplementary data](#).

Consent: The author/s confirm that written consent for submission and publication of this case report including images and associated text has been obtained from the patients in line with COPE guidance.

Conflict of interest: none declared.

Funding: This work was supported by GERCA (Groupe pour l'Enseignement, la prévention et la Recherche Cardiologique en Alsace).

References

1. Driggin E, Madhavan MV, Bikdeli B, Chuich T, Laracy J, Bondi-Zoccai G et al. Cardiovascular considerations for patients, health care workers, and health systems during the coronavirus disease 2019 (COVID-19) pandemic. *J Am Coll Cardiol* 2020;**75**:2352–2371.
2. Klok FA, Kruijff MJHA, van der Meer NJM, Arbous MS, Gommers D, Kant KM et al. Incidence of thrombotic complications in critically ill ICU patients with COVID-19. *Thromb Res* 2020;**191**:145–147.
3. Poissy J, Goutay J, Caplan M, Parmentier E, Duburcq T, Lassalle F et al. Pulmonary embolism in COVID-19 patients: awareness of an increased prevalence. *Circulation* 2020;**142**:184–186.
4. Helms J, Tacquard C, Severac F, Leonard-Lorant I, Ohana M, Delabranche X, et al. CRICS TRIGGERSEP Group (Clinical Research in Intensive Care and Sepsis Trial Group for Global Evaluation and Research in Sepsis). High risk of thrombosis in patients in severe SARS-CoV-2 infection: a multicenter prospective cohort study. *Intensive Care Med* 2020;**46**:1089–1098.
5. Zhu N, Zhang D, Wang W, Li X, Yang B, Song J et al. A novel coronavirus from patients with pneumonia in China, 2019. *N Engl J Med* 2020;**382**:727–733.
6. Coronavirus disease 2019 (COVID-19) Situation Report – 94 [Internet]. https://www.who.int/docs/default-source/coronaviruse/situation-reports/20200423-sit-rep-94-covid-19.pdf?sfvrsn=b8304bf0_4 (23 April 2020).
7. Bikdeli B, Madhavan MV, Jimenez D, Chuich T, Dreyfus I, Driggin E et al. COVID-19 and thrombotic or thromboembolic disease: implications for prevention, antithrombotic therapy, and follow-up. *J Am Coll Cardiol* 2020;**75**:2950–2973.
8. Llitjos J-F, Leclerc M, Chochois C, Monsallier J-M, Ramakers M, Auvray M et al. High incidence of venous thromboembolic events in anticoagulated severe COVID-19 patients. *J Thromb Haemost* 2020;**18**:1743–1746.
9. Wang T, Chen R, Liu C, Liang W, Guan W, Tang R et al. Attention should be paid to venous thromboembolism prophylaxis in the management of COVID-19. *Lancet Haematol* 2020;**7**:e362–e363.
10. Abdel-Wahab N, Talathi S, Lopez-Olivo MA, Suarez-Almazor ME. Risk of developing antiphospholipid antibodies following viral infection: a systematic review and meta-analysis. *Lupus* 2018;**27**:572–583.