



**HAL**  
open science

## Spine slenderness is not an early sign of progression in adolescent idiopathic scoliosis

Claudio Vergari, Wafa Skalli, Kariman Abelin-Genevois, Jean-Claude Bernard, Zongshan Hu, Jack Chun Yiu Cheng, Winnie Chiu Wing Chu, Ayman Assi, Mohammad Karam, Ismat Ghanem, et al.

► **To cite this version:**

Claudio Vergari, Wafa Skalli, Kariman Abelin-Genevois, Jean-Claude Bernard, Zongshan Hu, et al.. Spine slenderness is not an early sign of progression in adolescent idiopathic scoliosis. *Medical Engineering & Physics*, 2022, 108, pp.103879. 10.1016/j.medengphy.2022.103879 . hal-03896692

**HAL Id: hal-03896692**

**<https://hal.science/hal-03896692v1>**

Submitted on 13 Dec 2022

**HAL** is a multi-disciplinary open access archive for the deposit and dissemination of scientific research documents, whether they are published or not. The documents may come from teaching and research institutions in France or abroad, or from public or private research centers.

L'archive ouverte pluridisciplinaire **HAL**, est destinée au dépôt et à la diffusion de documents scientifiques de niveau recherche, publiés ou non, émanant des établissements d'enseignement et de recherche français ou étrangers, des laboratoires publics ou privés.

# Spine slenderness is not an early sign of progression in adolescent idiopathic scoliosis

Claudio Vergari<sup>a,\*</sup>, Wafa Skalli<sup>a</sup>, Kariman Abelin-Genevois<sup>b</sup>, Jean-Claude Bernard<sup>b</sup>, Zongshan Hu<sup>c</sup>, Jack Chun Yiu Cheng<sup>c</sup>, Winnie Chiu Wing Chu<sup>d</sup>, Ayman Assi<sup>e</sup>, Mohammad Karam<sup>e</sup>, Ismat Ghanem<sup>e</sup>, Tito Bassani<sup>f</sup>, Fabio Galbusera<sup>g</sup>, Luca Maria Sconfienza<sup>f,h</sup>, Marco Brayda-Bruno<sup>f</sup>, Isabelle Courtois<sup>i</sup>, Eric Ebermeyer<sup>i</sup>, Raphael Vialle<sup>j</sup>, Tristan Langlais<sup>j</sup>, Jean Dubousset<sup>a</sup>

<sup>a</sup> Arts et Métiers Institute of Technology, Université Sorbonne Paris Nord, IBHGC - Institut de Biomécanique Humaine Georges Charpak, HESAM Université, F-75013, Paris, France

<sup>b</sup> Department of Orthopaedic Surgery and Children Conservative treatment, Croix-Rouge française. Centre Médico-Chirurgical et de Réadaptation des Massues, Lyon, France

<sup>c</sup> SH Ho Scoliosis Research Laboratory, Department of Orthopaedics and Traumatology, Faculty of Medicine, The Prince of Wales Hospital, The Chinese University of Hong Kong, Shatin, Hong Kong SAR

<sup>d</sup> Department of Imaging and Interventional Radiology, Faculty of Medicine, The Prince of Wales Hospital, The Chinese University of Hong Kong, Shatin, Hong Kong SAR

<sup>e</sup> Laboratory of Biomechanics and Medical Imaging, Faculty of Medicine, University of Saint-Joseph, Beirut, Lebanon

<sup>f</sup> IRCCS Istituto Ortopedico Galeazzi, Milan, Italy

<sup>g</sup> Spine Center, Schulthess Clinic, Zurich, Switzerland

<sup>h</sup> Dipartimento di Scienze Biomediche per la Salute, Università degli Studi di Milano, Milan, Italy

<sup>i</sup> Unite Rachis, CHU - Hopital Bellevue, Saint-Etienne, France

<sup>j</sup> Sorbonne Université, Department of Pediatric Orthopaedics, Hôpital Armand Trousseau, Assistance Publique-Hôpitaux de Paris (AP-HP), Paris, France

## ARTICLE INFO

### Keywords:

Buckling  
Mechanical instability  
Biplanar radiography  
3D reconstruction

## ABSTRACT

Adolescent idiopathic scoliosis (AIS) is a three-dimensional deformity of the spine. Spine slenderness, which represents its potential instability to buckling under compressive loads, was shown to be higher in AIS patients than non-scoliotic subjects, but it is not clear at what stage of the progression this difference appeared, nor if slenderness could be used as an early sign of progression. In this study, we hypothesized that slenderness could be an early sign of progression.

One-hundred thirty-eight patients and 93 non-scoliotic subjects were included. They underwent standing biplanar radiography and 3D reconstruction of the spine, which allowed computing vertebra and disc slenderness ratio. Then, patients were followed until progression of the deformity or skeletal maturity (stable patients).

Vertebral slenderness ratio in AIS patients varied between 2.9 [2.7; 3.0] (T9) and 3.4 [3.2; 3.6] (T1), while disc slenderness ranged from 0.6 [0.6; 0.7] at T6-T7 to 1.2 [1.1; 1.3] at L4-L5. Slenderness ratio increased with age, while disc slenderness tended to decrease with age and Cobb angle. Slenderness was similar between progressive and stable patients, and also between patients and non-scoliotic subjects.

In conclusion, spinal slenderness does not appear to be an early sign of progression. Further studies should analyse the development of slenderness during growth, and how it could be affected by non-operative treatment.

## 1. Introduction

Adolescent idiopathic scoliosis (AIS) is a three-dimensional deformity of the spine which affects 1–4% of the population [1]. Most severe AIS cases require surgical correction to reduce the risk of respiratory

function worsening and a significant reduction of quality of life [2–4]. However, only between 23 and 45% of patients progress [5–7], and treatment for mild patients aims to slowing down the progression and reduce the need of surgery. Non-operative treatment of mild cases is often a combination of physical therapy and bracing, which are more

\* Corresponding author at: Institut de Biomécanique Humaine Georges Charpak, Arts et Métiers ParisTech, 151 bd de l'Hôpital, 75013 Paris, France  
E-mail address: [c.vergari@gmail.com](mailto:c.vergari@gmail.com) (C. Vergari).

effective when started early [8]. However, these treatments can be cumbersome for active teenagers, and therefore only those patients who are at risk of progression should be treated. Hence, early detection of progressive scoliosis could have a very high potential clinical impact since it could improve treatment efficacy while minimizing over-treatment.

In this context, several studies focused on the 3-dimensional analysis of the spine, and how 3D morphological parameters can be integrated in predictive algorithms to determine risk of AIS progressions [5,9,10]. Indeed, the scoliotic spinal midline is characterized by a lateral translation and axial rotation which are maximized at the apical vertebra, as well as a flattening of the sagittal profile. This overall displacement of the spinal midline can be accompanied by anterior overgrowth and lateral wedging of the vertebrae [11,12]. Recent works also showed that AIS patients can have increased spinal slenderness compared to asymptomatic controls [13–15]. Slenderness is “the ratio of transverse vertebral diameters to vertebral height [...] combined into various slenderness ratios”, according to the Scoliosis Research Society [16]. It represents a potential instability of the spine to buckling under compressive loads. However, the role of slenderness in the “vicious cycle” of scoliosis is not yet known and, in particular, it is not yet known if it is an early sign of progression, or if it increases later in more severe cases [17,18].

In this work, we hypothesized that vertebral slenderness could be an early sign of progression which could be detected as early as the first radiological examination for scoliosis.

## 2. Material and methods

The study was approved by an ethical committee (CPP Ile de France VI 6001 and local hospitals’ ethical committees). Given the multicentric nature of data collection, different clinical centres followed different procedures. In general, patient informed consent was collected for patients which were included prospectively, and it was waived for retrospective anonymized data which was acquired in clinical routine. All data was processed within the European Union. This cohort was previously reported in studies on a severity index for the prediction of scoliosis progression [5,19], which did not include any analysis of spine slenderness.

### 2.1. Subjects

Patients were included prospectively and retrospectively from six clinical centres in four countries (France, Hong Kong, Lebanon, Italy, with a minimal of 10% of inclusions per team), between 2013 and 2020. Inclusion criteria were confirmed diagnosis of AIS, Cobb angle between 10° and 25°, European Risser sign < 3, age > 10 years and no previous treatment of scoliosis. Exclusion criteria were: supernumerary thoracic vertebrae or transition anomalies, and non-idiopathic scoliosis, which was excluded through clinical and neurological assessment.

Patients were stratified according to their age in order to mitigate the confounding effect of this variable on vertebral slenderness: 10 years, 11 to 12 and 13 or above. Age thresholds were chosen according to the number of patients in each group (Table 1).

Patients were then followed radiologically to determine their outcome as “stable” patients (no progression and no treatment) or

**Table 1**  
Number of subjects in each group by age range (number of females/males in parentheses).

Age range:	10	11–12	>= 13
Total scoliosis cohort	30 (29/1)	60 (48/12)	48 (36/12)
Stable	8 (8/0)	24 (18/6)	31 (24/7)
Progressive	22 (21/1)	36 (30/6)	17 (12/5)
Healthy subjects	24(24/0)	33 (28/3)	36 (21/15)

“progressive” patients (prescription of brace). Quantitative criteria for this classification are provided in Table 2 [20].

An age-matched control group of non-scoliotic subjects was also included. These subjects underwent a radiographic exam for unrelated reasons (participation in other studies, trauma, etc.), and absence of scoliosis was checked radiologically.

### 2.2. Imaging and 3D reconstruction

At inclusion, all subjects (patients and) underwent biplanar radiography (EOS system, EOS Imaging, Paris, France) in free-standing position [21] (Fig. 1). The spine of all patients was reconstructed in 3D from T1 to L5 using a previously validated method [22]. In brief, the spinal midline was manually digitized in the frontal and lateral radiographs, and the software proposed an initial solution consisting in 3D models of vertebrae from T1 to L5. These models were retro projected on the radiographs, and the user could manually adjust the position and shape of the vertebrae to match their outline with the underlying radiograph. Pelvis acetabula and sacral plate were also digitized in both views.

Apical vertebra was defined as the most laterally displaced and most axially rotated vertebra, while the upper and lower end vertebrae were the more tilted vertebrae above and below the apex [23].

Cobb angle and slenderness ratios of vertebrae and discs were computed automatically from the 3D reconstruction. For vertebral slenderness computation, first the upper and lower endplates were automatically isolated in the regionalized 3D model (Fig. 2). The area and moment of area of each endplate was computed. The radius of gyration of the vertebra was also computed, as  $g = \sqrt{A/I}$ , where  $A$  was the average area of the two endplates and  $I$  the average of the smallest second moment of area of each endplate. Finally, vertebra body height  $H$  was computed as the distance between the barycentres of the endplates, which allowed calculating vertebral slenderness as  $r = H\sqrt{A/I}$  [13,24]. Similarly, disc slenderness ratio was calculated between the endplates of each couple of adjacent vertebrae.

### 2.3. Statistics

Analysis of preliminary data allowed to establish that a cohort of 60 patients would allow to detect a significant difference in slenderness ratio of the same magnitude of the previously observed differences between non-scoliotic and AIS patients [13].

Data normality was checked with Lilliefors test. Correlations were analysed with Pearson’s correlation tests between normal variables and with Spearman’s test between non-normal ones. Differences between stable and progressive patients were analysed with t-tests for normally distributed variables, and with Mann-Whitney tests otherwise. Differences in slenderness ratio between age groups were tested with Kruskal Wallis tests.

Quantiles were computed for vertebral slenderness ratio at each level from the whole cohort. Then, the percentage of apexes and lower or upper end vertebrae with higher slenderness than the 3rd quartile was computed. The percentages were compared between stable and progressive patients using Fisher’s exact test. The hypothesis behind this test was that progressive patients should represent the highest values within slenderness distribution, and the stable patients the lower values.

Results were reported as median [1st; 3rd quartile]. Significance was set at  $\alpha = 0.05$ .

**Table 2**  
Definition of stable and progressive patients after follow-up.

Definition	Cobb angle	Vertebral axial rotation	Risser sign
Stable if:	$\leq 25^\circ$	No significant increase	$\geq 3$
Progressive if:	$> 25^\circ$		$\leq 2$
	or $+5^\circ$ in six months		$\leq 2$
	or	$+5^\circ$ in six months	$\leq 2$

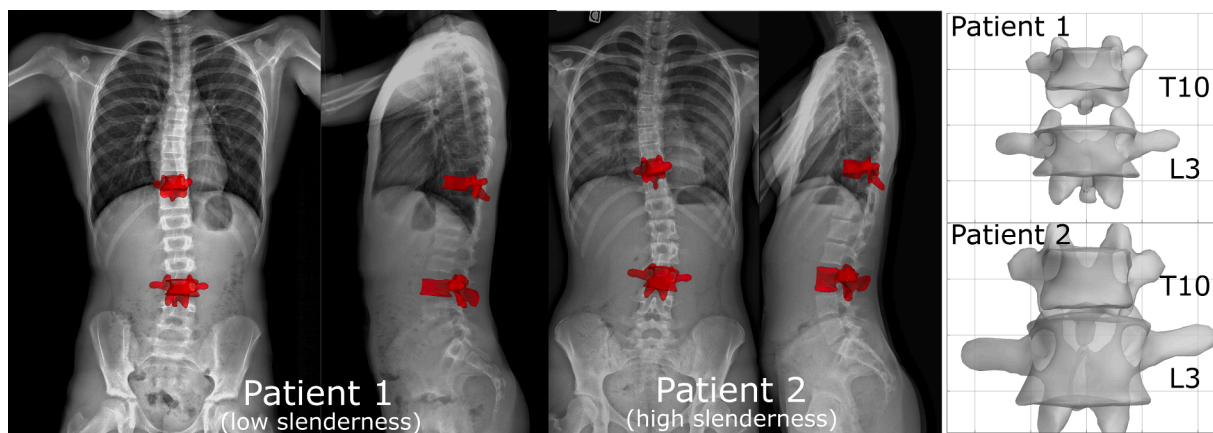


Fig. 1. Examples of biplanar radiographs of two patients with low (Patient 1, 11 years old boy) and high slenderness ratio (Patient 2, 14 years old girl). Zooms on the 3D models of T10 and L3 vertebrae of both patients are shown; vertebrae are represented in the same scale (background grid size is 20 mm). Patient #2 has significantly taller vertebrae than patient #1, and they are only slightly larger; hence, vertebrae of patient #2 have higher slender ratio.

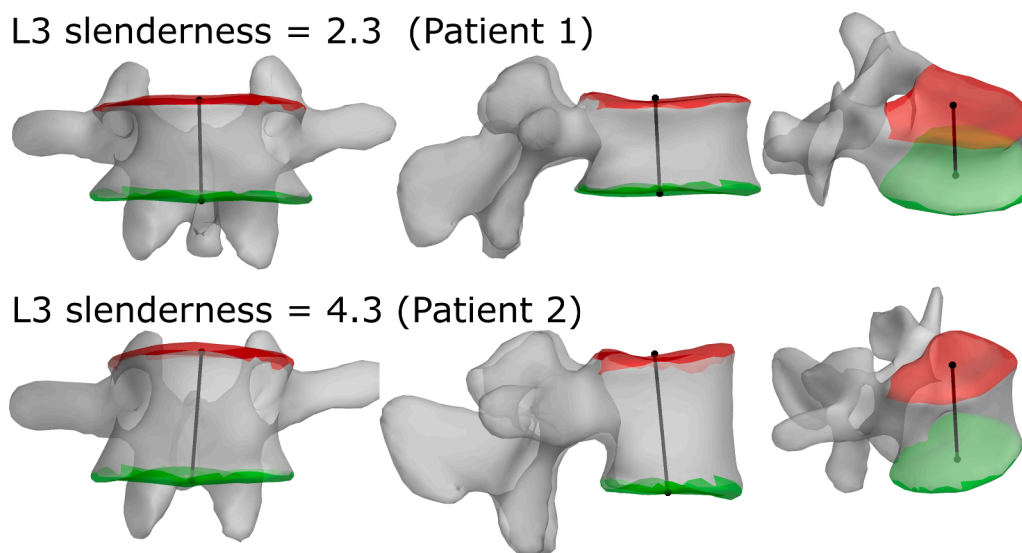


Fig. 2. Examples of two L3 vertebrae with low (Patient #1) and high slenderness (Patient #2) from two patients (x-rays are available in Fig. 1). Upper and lower endplates are highlighted in red and green, respectively, and the vertebral body height is shown as a black line.

### 3. Results

In total, one-hundred thirty-eight patients were included (113 girls and 25 boys, median age 12 years [11; 13], ranging between 10 and 15 years). Number of patients by age are provided in

Table 3. Ninety-three non-scoliotic subjects were also included (75 girls, 18 boys, 12 [10; 13] years old). Non-scoliotic subjects and AIS patients had the same age ( $p = 0.9$ ).

Median Cobb angle was  $16.5^\circ$  [ $13.4^\circ; 19.1^\circ$ ] in AIS patients. After follow-up, 75 patients (54%) resulted progressive while 63 were stable (46%). Stable patients were slightly but significantly older than

progressive (12 [12; 13] years versus 11.3 [10; 12] years,  $p = 0.0003$ ).

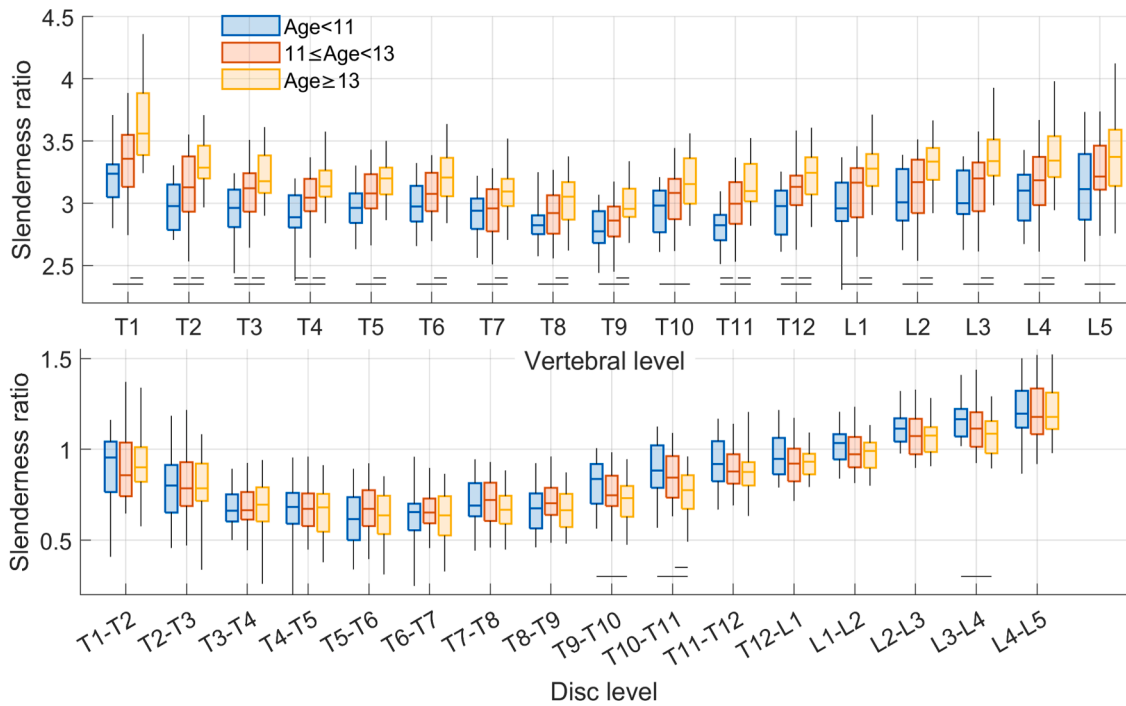
Vertebral slenderness ratio increased significantly with age ( $p < 0.001$ , Fig. 3) and with Risser sign ( $p < 0.01$ ) at all vertebral levels. The pattern was similar in non-scoliotic subjects. No correlation was observed with Cobb angle ( $p > 0.07$  at all levels). Disc slenderness tended to decrease with age at three vertebral levels (T9-T10, T1-T11 and L3-L4, Fig. 3). A negative correlation was found between disc slenderness and Cobb angle, but only at the levels between T2-T3 and T5-T6 discs ( $p < 0.02$ ,  $R > 0.15$ ).

Fig. 4 shows that stable and progressive patients had similar vertebral slenderness at all vertebral levels ( $p > 0.05$ ), independently of age,

Table 3

Percentage of notable vertebrae (apex, upper and lower end vertebrae) presenting a slenderness higher than 3rd quartile of the overall population. All vertebral levels were processed independently (e.g., a T5 apex was compared to the overall range of slenderness of all T5 vertebrae). Differences between stable and progressive patients were not significant ( $p > 0.05$ , Fisher's exact test).  $N$  = number of patients.

Age	N	Stable patients			Progressive patients		
		Upper end Vertebra [%]	Apex [%]	Lower end vertebra [%]	Upper end Vertebra	Apex [%]	Lower end vertebra
Age < 11	30	25	13	13	23	23	27
$11 \leq$ Age 13	60	29	25	25	22	22	28
Age $\geq$ 13	48	32	32	29	24	29	24



**Fig. 3.** Vertebral and disc slenderness ratio at each level by age group. Significant differences (Kruskal-Wallis test,  $p < 0.05$ ) between scoliotic groups are indicated by horizontal lines. Box plots represent median [1st 3rd quartiles] of patients, while whiskers represent the 95th percentile.

and both were similar to non-scoliotic subjects ( $p > 0.1$ ). Disc slenderness showed a similar pattern, but age stratification was not necessary.

Vertebral slenderness ratio was further analysed at the apex and end vertebrae. Table 1 shows that a similar percentage of stable and progressive patients showed “high” slenderness ratio (higher than the 3rd quartile of the whole cohort) at all key levels (apex and end vertebrae). The equality of the percentages between groups was confirmed by Fisher’s exact test ( $p > 0.4$ ). Similar results were obtained by stratifying patients according to Risser sign instead of age.

Fig. 5 shows examples of stable and progressive patients with high and low slenderness.

#### 4. Discussion

In this study, vertebral and disc slenderness were measured in mild scoliotic patients at their first radiological exam for scoliosis. Patients were then followed up until they reached skeletal maturity without significant progression of the deformity, or until they were prescribed a brace to slow down an accelerating progression. Our hypothesis was that spine slenderness could be an early sign of deformity progression, and therefore that it could be used as a parameter to predict progression and as an indication for early treatment.

This initial hypothesis arose from recent studies which showed that mild to severe AIS patients have more slender spines than controls [13, 14]. In particular, it was reported that vertebral slenderness increased with age, while disc slenderness decreased with age and increased with Cobb angle. This raised the question of whether patients already showed different slenderness at their first exam, before their progression or stabilization. However, no differences were observed between stable and progressive patients, once age was accounted for. Furthermore, patients showed similar vertebral and disc slenderness to non-scoliotic subjects, as well as a similar slenderness change with age. This further confirms that morphological alterations of the vertebrae which differentiate AIS patients and non-scoliotic subjects tend to develop later during the progression of the deformity.

From a methodological point of view, the stratification of the cohort by age was necessary to correct for this confounding factor. Table 1

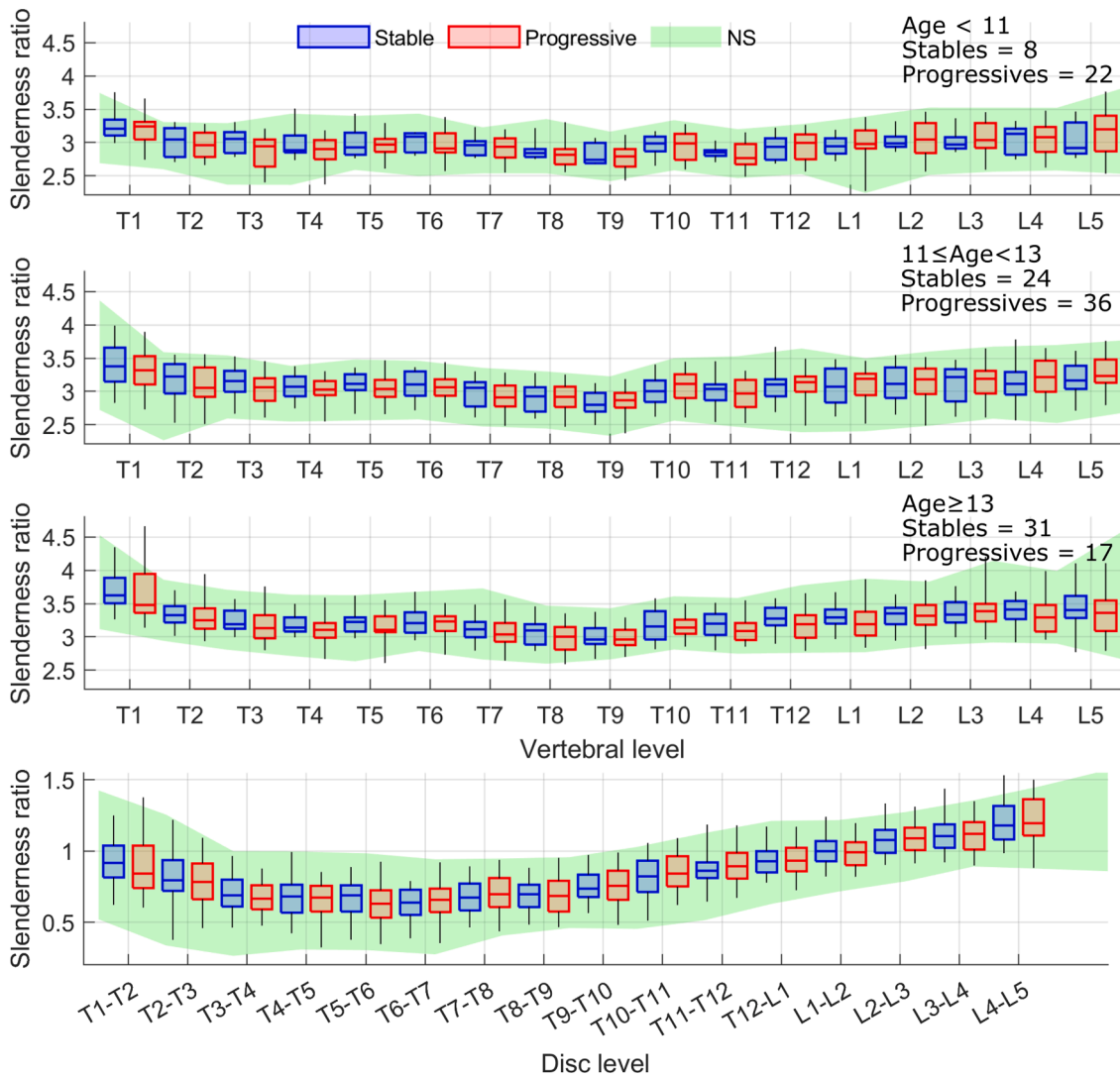
shows that the stable group consists of more patients of age  $\geq 13$  than the progressive group. Without age-correction, slenderness would appear higher in the stable group than the progressive one. This difference disappears once age’s confounding effect was accounted for.

Patient’s follow-up was stopped at the first sign of progression (typically a  $5^\circ$  increase of Cobb angle), which coincided with the beginning of treatment. Treatment invariably alters the patient’s natural history, which introduces several confounding variables when studying progression. In perspective, a different study design should be implemented to study the relationship between slenderness and progression beyond mild cases. In particular, it would be interesting to follow up those patients that are advised treatment by the clinician but refuse it, because natural progression of slenderness could be observed in these progressive patients.

Results of this study give an insight into the development and progression of AIS. Since slenderness appeared normal in the early scoliosis patients of the present cohort, the starting point of the “vicious cycle” leading to the progression of the deformity is not due to this feature, which could appear later in the progression [13]. This is supported by previous research, often based on simulations, which concluded that progression of the deformity requires an initial alteration of vertebral morphology or position [25,26]. Hence, the initiation of the progression must be searched for elsewhere in the multifactorial pathogenesis of AIS [27]. Nevertheless, mechanical instabilities due to rotational effects could be more relevant than lateral buckling, since intervertebral rotations at end vertebrae and higher torsion moments have been previously described [28,29]. Vertebral axial rotation and rotational instability have indeed been pointed out as a prominent characteristics of the scoliotic deformity in adolescents [30–33], and torsional buckling could occur more easily in a slender spine [15].

This work presents some limitations. Firstly, the 3D reconstruction obtained from biplanar radiography does not have the same accuracy as CT-scans. However, biplanar radiography delivers a much lower radiation dose than CT scan [34,35], which makes it more adapted to the routine radiological follow up of AIS patients. Furthermore, previous studies showed that uncertainty of vertebral slenderness measurement from biplanar radiography was 0.17 (6% coefficient of variation), which





**Fig. 4.** Comparison of vertebral and disc slenderness ratio in non-scoliotic subjects (NS), stable and progressive patients at all vertebral levels. No significant differences were observed between groups. Since vertebral slenderness ratio varies with age, patients were stratified according to age. Disc slenderness did not change with age, so data in the bottom panel represent all ages. Shaded area is the 95th percentile of non-scoliotic subjects, box plots represent median [1st-3rd quartiles] of patients, while whiskers represent the 95th percentile.

was sufficient to detect significant differences between age groups and between vertebral levels. Furthermore, biplanar radiography is acquired in standing position, which allows for a more relevant morphology of the discs for the analysis of mechanical buckling, unlike the lying position utilized in other imaging methods where the spine is unloaded. Besides, patient's position would not alter vertebral slenderness, which is a morphological property of the vertebra.

Secondly, intervertebral discs do not appear on radiography, so their slenderness was inferred from the adjacent endplates. This does not account for disc bulging [36], which could be significant in the evaluation of the spine's mechanical instability to buckling.

To our knowledge, this is the first study analysing spine slenderness in mild AIS, in standing position, and to relate it to the natural history of the patient. Results show that slenderness is not an early sign of progression, which, combined with previous results, suggests that slenderness tends to increase during the progression. Further studies should follow-up patients during treatment to characterize the relationship between the progression of the deformity and that of slenderness.

#### Funding disclosures

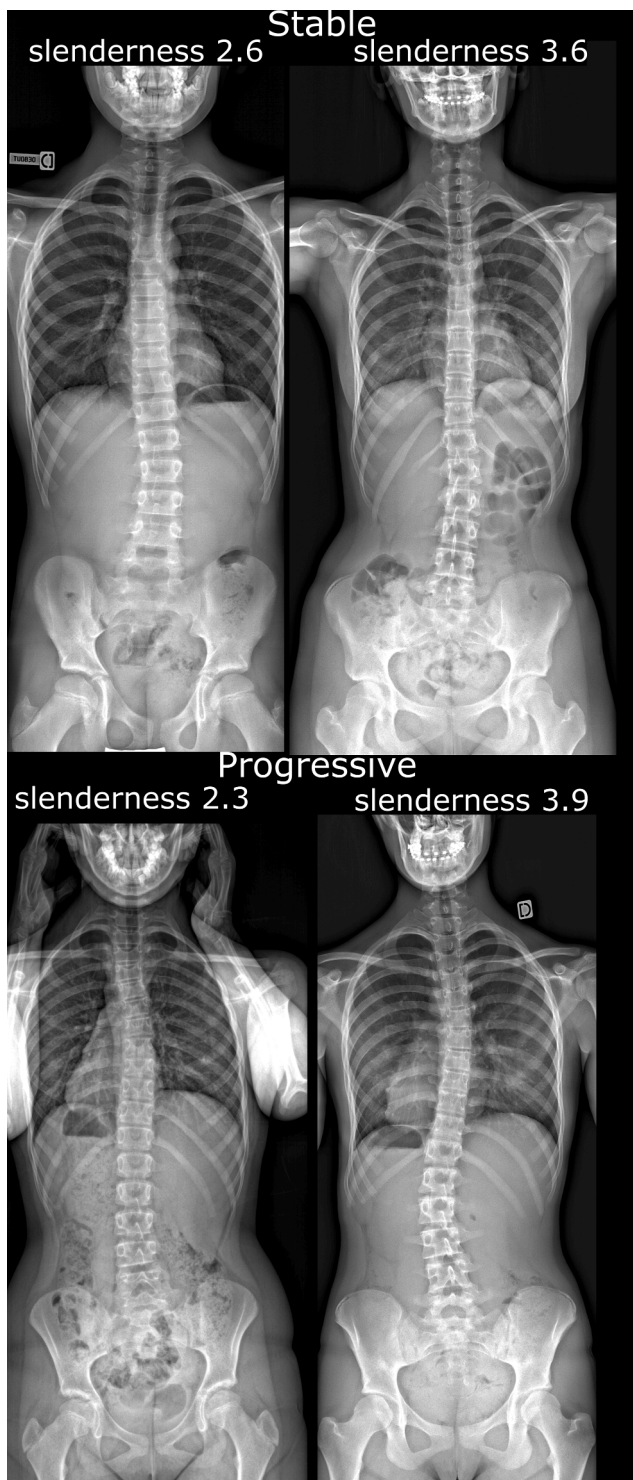
The authors are grateful to the BiomecAM chair program on subject-specific musculoskeletal modelling (with the support of ParisTech and Yves Cotrel Foundations, Société Générale, Covea and Proteor).

#### Ethical approval

The study was approved by ethical committee (CPP Ile-de France VI 6001 and local hospitals' ethical committees). Given the multicentric nature of data collection, different clinical centres followed different procedures. In general, patient informed consent was collected for patients included prospectively, and it was waived for retrospective anonymized data which was acquired in clinical routine. All data was processed within the European Union.

#### CRedit authorship contribution statement

**Claudio Vergari:** Conceptualization, Methodology, Formal analysis, Writing – original draft. **Wafa Skalli:** Conceptualization, Methodology, Formal analysis, Supervision, Funding acquisition, Writing – review &



**Fig. 5.** Examples of two stable and two progressive patients with high and low slenderness.

editing. **Kariman Abelin-Genevois:** Resources, Investigation, Writing – review & editing. **Jean-Claude Bernard:** Resources, Investigation, Writing – review & editing. **Zongshan Hu:** Resources, Data curation, Writing – review & editing. **Jack Chun Yiu Cheng:** Resources, Investigation, Writing – review & editing. **Winnie Chiu Wing Chu:** Resources, Investigation, Writing – review & editing. **Ayman Assi:** Conceptualization, Writing – review & editing. **Mohammad Karam:** Data curation, Writing – review & editing. **Ismat Ghanem:** Resources, Investigation, Writing – review & editing. **Tito Bassani:** Data curation,

Writing – review & editing. **Fabio Galbusera:** Data curation, Writing – review & editing. **Luca Maria Sconfienza:** Resources, Investigation, Writing – review & editing. **Marco Brayda-Bruno:** Resources, Investigation, Writing – review & editing. **Isabelle Courtois:** Resources, Investigation, Writing – review & editing. **Eric Ebermeyer:** Resources, Resources, Investigation, Writing – review & editing. **Raphael Vialle:** Resources, Investigation, Writing – review & editing. **Tristan Langlais:** Resources, Investigation, Writing – review & editing. **Jean Dubouset:** Conceptualization, Writing – review & editing.

#### Declaration Competing Interest

Dr. Skalli has a patent related to biplanar X-Rays and associated 3D reconstruction methods, with no personal financial benefit (royalties rewarded for research and education) licensed to EOS Imaging. Dr. Vialle reports personal fees and grants (unrelated to this study) from EOS Imaging. Prof. Luca Maria Sconfienza has unrelated financial relationships with Esaote, Samsung Medison, Bracco Imaging Italia, Pfizer, Abiogen, Fidia Pharma Group, Novartis, Janssen-Cilag, MSD, Merck Serono

#### References

- [1] Konieczny MR, Senyurt H, Krauspe R. Epidemiology of adolescent idiopathic scoliosis. *J Child Orthop* 2013;7:3–9. <https://doi.org/10.1007/s11832-012-0457-4>.
- [2] Kearon C, Viviani GR, Kirkley A, Killian KJ. Factors Determining Pulmonary Function in Adolescent Idiopathic Thoracic Scoliosis. *Am Rev Respir Dis* 1993;148: 288–94. <https://doi.org/10.1164/ajrccm/148.2.288>.
- [3] Danielsson AJ. Natural history of adolescent idiopathic scoliosis: a tool for guidance in decision of surgery of curves above 50°. *J Child Orthop* 2013;7:37–41. <https://doi.org/10.1007/s11832-012-0462-7>.
- [4] Tones M, Moss N, Polly DWJ. A Review of Quality of Life and Psychosocial Issues in Scoliosis. *Spine (Phila Pa 1976)* 2006;31.
- [5] Vergari C, Skalli W, Abelin-Genevois K, Bernard JC, Hu Z, Cheng JCY, et al. Effect of curve location on the severity index for adolescent idiopathic scoliosis: a longitudinal cohort study. *Eur Radiol* 2021. <https://doi.org/10.1007/s00330-021-07944-4>.
- [6] Danielsson AJ, Hasselius R, Ohlin A, Nachemson AL. A prospective study of brace treatment versus observation alone in adolescent idiopathic scoliosis: a follow-up mean of 16 years after maturity. *Spine (Phila Pa 1976)* 2007;32:2198–207. <https://doi.org/10.1097/BRS.0b013e31814b851f>.
- [7] Lonstein JE, Carlson JM. The prediction of curve progression in untreated idiopathic scoliosis during growth. *J Bone Joint Surg Am* 1984;66:1061–71.
- [8] Hresko MT, Talwalkar V, Schwend R, AOS SRS, POSNA S, Dolan L, Wright J, et al. Early Detection of Idiopathic Scoliosis in Adolescents. *J Bone Joint Surg Am* 2016; 98:e67. <https://doi.org/10.2106/JBJS.16.00224>.
- [9] Dolan LA, Weinstein SL, Abel MF, Bosch PP, Dobbs MB, Farber TO, et al. Bracing in Adolescent Idiopathic Scoliosis Trial (BrAIST): development and Validation of a Prognostic Model in Untreated Adolescent Idiopathic Scoliosis Using the Simplified Skeletal Maturity System. *Spine Deform* 2019;7:890–8. <https://doi.org/10.1016/j.jspd.2019.01.011>. e4.
- [10] Kadoury S, Mandel W, Roy-Beaudry M, Nault ML, Parent S. 3-D Morphology Prediction of Progressive Spinal Deformities from Probabilistic Modeling of Discriminant Manifolds. *IEEE Trans Med Imaging* 2017;36:1194–204. <https://doi.org/10.1109/TMI.2017.2657225>.
- [11] Schlösser TPC, van Stralen M, Chu WCW, Lam T-P, Ng BKW, Vincken KL, et al. Anterior Overgrowth in Primary Curves, Compensatory Curves and Junctional Segments in Adolescent Idiopathic Scoliosis. *PLoS ONE* 2016;11:1–11. <https://doi.org/10.1371/journal.pone.0160267>.
- [12] Parent S, Labelle H, Skalli W, de Guise J. Vertebral Wedging Characteristic Changes in Scoliotic Spines. *Spine (Phila Pa 1976)* 2004;29.
- [13] Vergari C, Karam M, Pietton R, Vialle R, Ghanem I, Skalli W, et al. Spine slenderness and wedging in adolescent idiopathic scoliosis and in asymptomatic population: an observational retrospective study. *Eur Spine J* 2020;29:726–36. <https://doi.org/10.1007/s00586-020-06340-8>.
- [14] Chen H, Schlösser TPC, Brink RC, Colo D, van Stralen M, Shi L, et al. The Height-Width-Depth Ratios of the Intervertebral Discs and Vertebral Bodies in Adolescent Idiopathic Scoliosis vs Controls in a Chinese Population. *Sci Rep* 2017;7:46448.
- [15] de Reuver S, Costa L, van Rheenen H, Tabeing CS, Lemans JVC, Schlösser TPC, et al. Disc and Vertebral Body Morphology From Birth to Adulthood. *Spine (Phila Pa 1976)* 2022. n.d.
- [16] Stokes IA. Three-dimensional terminology of spinal deformity. A report presented to the Scoliosis Research Society by the Scoliosis Research Society Working Group on 3-D terminology of spinal deformity. *Spine (Phila Pa 1976)* 1994;19:236–48.
- [17] Stokes IA, Spence H, Aronsson DD, Kilmer N. Mechanical modulation of vertebral body growth. Implications for scoliosis progression. *Spine (Phila Pa 1976)* 1996;21: 1162–7.

- [18] Villemure I, Aubin CE, Grimard G, Dansereau J, Labelle H. Progression of vertebral and spinal three-dimensional deformities in adolescent idiopathic scoliosis: a longitudinal study. *Spine (Phila Pa 1976)* 2001;26:2244–50. <https://doi.org/10.1097/00007632-2001110150-00016>.
- [19] Vergari C, Gajny L, Courtois I, Ebermeyer E, Abelin-Genevois K, Kim Y, et al. Quasi-automatic early detection of progressive idiopathic scoliosis from biplanar radiography: a preliminary validation. *Eur Spine J* 2019;28:1970–6. <https://doi.org/10.1007/s00586-019-05998-z>.
- [20] Negrini S, Donzelli S, Aulisa AG, Czaprowski D, Schreiber S, de Mauroy JC, et al. 2016 SOSORT guidelines: orthopaedic and rehabilitation treatment of idiopathic scoliosis during growth. *Scoliosis Spinal Disord* 2018;13:3. <https://doi.org/10.1186/s13013-017-0145-8>.
- [21] Faro FD, Marks MC, Pawelek J, Newton PO. Evaluation of a functional position for lateral radiograph acquisition in adolescent idiopathic scoliosis. *Spine (Phila Pa 1976)* 2004;29:2284–9.
- [22] Humbert L, De Guise JA, Aubert B, Godbout B, Skalli W. 3D reconstruction of the spine from biplanar X-rays using parametric models based on transversal and longitudinal inferences. *Med Eng Phys* 2009;31:681–7. <https://doi.org/10.1016/j.medengphy.2009.01.003>.
- [23] O'Brien MF, Kulklo TR, Blanke KM, Lenke LG. *Radiographic Measurement Manual*. Medtronic Sofamor Danek USA 2008. Inc2008.
- [24] Townsend PR, Rose RM, Radin EL. Buckling studies of single human trabeculae. *J Biomech* 1975;8:199–200. [https://doi.org/10.1016/0021-9290\(75\)90025-1](https://doi.org/10.1016/0021-9290(75)90025-1).
- [25] Drevelle X, Dubouset J, Lafon Y, Ebermeyer E, Skalli W. Analysis of the mechanisms of idiopathic scoliosis progression using finite element simulation. *Stud Heal Technol Inf* 2008;140:85–9. <https://doi.org/10.3233/978-1-58603-888-5-85>.
- [26] Villemure I, Aubin CE, Dansereau J, Labelle H. Simulation of Progressive Deformities in Adolescent Idiopathic Scoliosis Using a Biomechanical Model Integrating Vertebral Growth Modulation. *J Biomech Eng* 2002;124:784. <https://doi.org/10.1115/1.1516198>.
- [27] Weinstein SL, Dolan LA, Cheng JC, Danielsson A, Morcuende JA. Adolescent idiopathic scoliosis. *Lancet* 2008;371:1527–37. [https://doi.org/10.1016/S0140-6736\(08\)60658-3](https://doi.org/10.1016/S0140-6736(08)60658-3).
- [28] Thenard T, Vergari C, Hernandez T, Vialle R, Skalli W. Analysis of Center of Mass and Gravity-Induced Vertebral Axial Torque on the Scoliotic Spine by Barycentremetry. *Spine Deform* 2019;7:525–32. <https://doi.org/10.1016/j.jspd.2018.11.007>.
- [29] Langlais T, Vergari C, Rougreau G, Gajny L, Assi A, Ghanem I, et al. Balance, barycentremetry and external shape analysis in idiopathic scoliosis: what can the physician expect from it? *Med Eng Phys* 2021. <https://doi.org/10.1016/j.medengphy.2021.06.004>.
- [30] Castelein RM, Dieën JH van, Smit TH. The role of dorsal shear forces in the pathogenesis of adolescent idiopathic scoliosis – A hypothesis. *Med Hypotheses* 2005;65:501–8. <https://doi.org/10.1016/j.mehy.2005.03.025>.
- [31] Illés TS, Lavaste F, Dubouset JF. The third dimension of scoliosis: the forgotten axial plane. *Orthop Traumatol Surg Res* 2019;105:351–9. <https://doi.org/10.1016/j.otsr.2018.10.021>.
- [32] Karam M, Vergari C, Skalli W, Bizdikian AJ, Mehanna J, Kawkabani G, et al. Assessment of the axial plane deformity in subjects with adolescent idiopathic scoliosis and its relationship to the frontal and sagittal planes. *Spine Deform* 2021. <https://doi.org/10.1007/s43390-021-00443-y>.
- [33] Castelein RM, Pasha S, Cheng JCY, Dubouset J. Idiopathic Scoliosis as a Rotatory Decomensation of the Spine. *J Bone Miner Res* 2020;35:1850–7. <https://doi.org/10.1002/jbmr.4137>.
- [34] Pedersen PH, Vergari C, Alzakri A, Vialle R, Skalli W. A reduced micro-dose protocol for 3D reconstruction of the spine in children with scoliosis: results of a phantom-based and clinically validated study using stereo-radiography. *Eur Radiol* 2019;29:1874–81. <https://doi.org/10.1007/s00330-018-5749-8>.
- [35] Deschenes S, Charron G, Beaudoin G, Labelle H, Dubois J, Miron MC, et al. Diagnostic imaging of spinal deformities: reducing patients radiation dose with a new slot-scanning X-ray imager. *Spine (Phila Pa 1976)* 2010;35:989–94. <https://doi.org/10.1097/BRS.0b013e3181bdcaa4>.
- [36] Heuer F, Schmidt H, Claes L, Wilke HJ. A new laser scanning technique for imaging intervertebral disc displacement and its application to modeling nucleotomy. *Clin Biomech (Bristol, Avon)* 2008;23:260–9. <https://doi.org/10.1016/j.clinbiomech.2007.10.006>.